


**WINSIX**<sup>®</sup>  
PERFORMING IMPLANT SYSTEM 

SINCE 1995  
SCIENTIFIC  
RESEARCH  
FOR BETTER RESULTS




**BIOSAFIN**

*Lo scienziato non è l'uomo che fornisce le vere risposte;  
è quello che pone le vere domande.*

*(Claude Lévi-Strauss)*



H  
100 pm



Zone Mag = 48X

LA RICERCA SCIENTIFICA RAPPRESENTA LA CHIAVE DI VOLTA PER OTTENERE NUOVA CONOSCENZA E NUOVO SAPERE E, DI CONSEGUENZA, POTER DETERMINARE STILI DI VITA MIGLIORI PER GLI INDIVIDUI E LA SOCIETÀ.

In ambito medico e scientifico numerose sono le ricerche che da questo punto di vista hanno segnato svolte epocali per la vita dell'uomo, generando quel progresso tecnico, scientifico e sociale che è alla base di ogni cultura e Paese moderno.

**La moderna Odontoiatria è caratterizzata da un forte dinamismo, che negli ultimi decenni ha visto come disciplina tra le più attive l'Implantologia e l'Implantoprotesi:** discipline che partendo dall'esperienza dei singoli clinici, si sono evolute verso un livello di evidenza scientifica tale da permettere percentuali elevatissime di predicibilità del risultato.

Questo processo ha condotto ad un sensibile miglioramento della qualità di vita dei pazienti sottoposti a riabilitazioni implantosupportate, secondo un principio generale impostosi nell'attualità di sostenibilità economica, sia in termini biologici, che di tempo e di costo.

**Il presente volume di raccolta Bibliografica del Sistema Implantare WINSIX®** è la testimonianza dell'interesse e dell'impegno di Università, Centri di Ricerca e valenti Professionisti in ambito odontoiatrico e maxillo-facciale, che con il loro contributo hanno partecipato allo sviluppo e attuazione di progetti e innovazioni. Dal 1995, attraverso la messa in pratica del principio di *translational research*, il SISTEMA IMPLANTARE WINSIX® è diventato la realtà che è oggi, utilizzata da migliaia di Odontoiatri con convinzione e soddisfazione per gli esiti implantoprotesici che con esso ottengono.

SCIENTIFIC RESEARCH CONSTITUES THE TURNING POINT TO OBTAIN NEW ACQUAINTANCE AND NEW KNOWLEDGE AND AS A CONSEQUENCE, TO SET BETTER STANDARDS OF LIFE FOR PEOPLE AND THE SOCIETY.

*In the medical and scientific fields numerous have been researches which – in this respect – have marked historical turning points for human life, generating that technical, scientific and social progress which lies at the very basis of every culture and of every modern Country.*

*Modern Dentistry is characterized by a strong dynamism, where Implant dentistry and implant prosthetic are among the most active disciplines over the last 10 years: disciplines which starting from the experiences of clinics, have evolved toward such a high level of scientific evidence to reach statistics showing extremely high percentage in the predictability of results.*

*This process has led to a sensitive improvement of the patients' quality of life when undergoing implant supported rehabilitations, according to a general and actual idea of economic sustainability, both in biological terms and in due time and costs.*

*This volume of WINSIX® Implant System Bibliography witnesses the interest and commitment of Universities, Research Centres and worthy Dentists operating in dental and maxillofacial fields, whose contribution has been meaningful for the development and application of projects and innovations. Since 1995, by the implementation of translational research principles, WINSIX® Implant System has become the solid reality of today, used by thousand of convinced and satisfied dentists, due to the prosthetic implant results obtained by its use.*

## I PRINCIPI DI RICERCA BIOSAFIN

L'attività di ricerca condotta da BIOSAFIN è da sempre basata su una rigorosa applicazione nei tre ambiti dell'evidenza scientifica:

- **esperimenti in vitro:** funzionale allo studio di base dei materiali e delle nuove tecnologie mediante modelli sperimentali ben descritti in colture cellulari o analisi diretta dei materiali (ad es. SEM, biologia molecolare, altri...);
- **esperimenti in vivo su modello animale:** funzionale alle prime applicazioni cliniche di nuovi dispositivi, simulando il microambiente orale del paziente. A questo scopo vengono utilizzati modelli animali con caratteristiche biologiche quanto più simili a quelle dell'uomo, sia in termini anatomici che genetici;
- **evidenze cliniche:** l'applicazione clinica di protocolli sperimentali su popolazioni di pazienti sempre più vaste, secondo i criteri dei *clinical trials* al fine di ottenere risultati affidabili ed *evidence based*.

Dal 1995 la ricerca inerente il Sistema Implantare WINSIX® ha investito tutti i suoi aspetti e applicazioni, implementando tutte le variabili:

- effettuati numerosi studi in vitro con utilizzo del microscopio elettronico a scansione (SEM) per lo studio delle superfici implantari e delle cellule del tessuto osseo a contatto con esse, a cui sono seguiti studi di biologia molecolare
- pubblicazione degli studi e ricerche effettuati in riviste peer-reviewed e impact factor, ed in riviste con diffusione capillare negli studi odontoiatrici
- presentazione e discussione degli studi e ricerche in ambito collegiale di congressi scientifici e poster session

La strada evolutiva percorsa dal Sistema WINSIX® che possiamo leggere attraverso le oltre 300 pubblicazioni costituisce un contributo significativo al progresso tecnologico-scientifico della disciplina dell'implantologia orale.

## BIOSAF IN RESEARCH PRINCIPLES

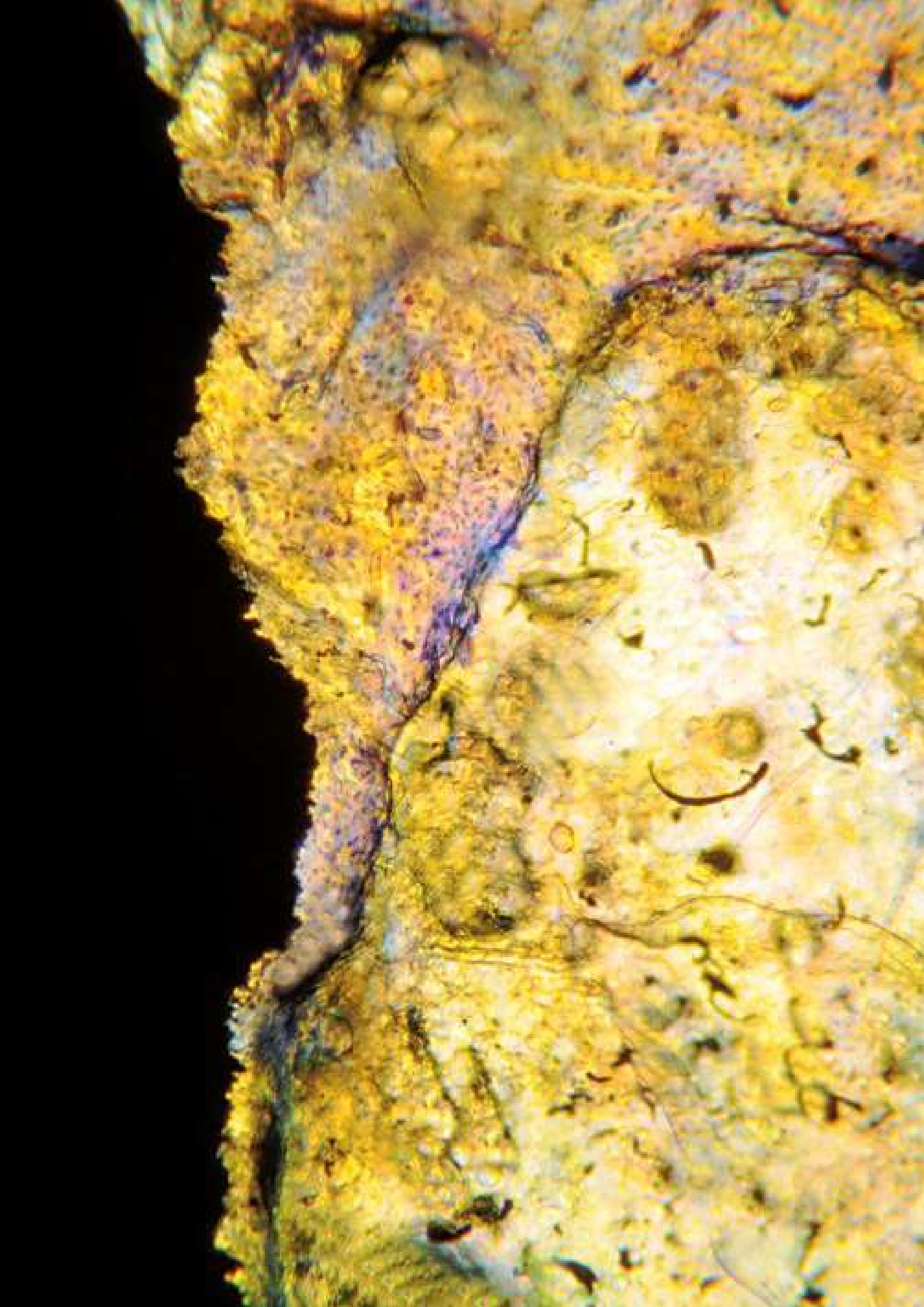*Right from the start, research activity at BIOSAFIN is based on its strict application in the 3 fields defining scientific evidence:*

- ***in vitro trials:*** *functional to the study of materials and new technologies, by means of carefully described experimental models in cellular coltures or direct analysis of materials (e.g. SEM, molecular biology, others...);*
- ***in vivo trials using animal model:*** *functional to the first clinical application of new devices, by simulation of patient oral microenvironment. For this purpose, animal models are used with biological characteristics as close as possible to the human ones, in terms both anatomical and genetic;*
- ***clinical evidence:*** *clinical application of experimental protocols on growing groups of patient population, according to clinical trials criteria, in order to obtain reliable and evidence based results.*

*Since 1995, the research related to WINSIX® Implant System has covered all its aspects and applications, deploying all variables. Specifically:*

- *several in vitro studies, using scanning electron microscope (SEM) functional to study implant surfaces and bone tissue cells in contact with them, followed by molecular biological studies;*
- *publication of studies and researches in peer-reviewed and impact factor journals, and in wide-spread and popular journals among dental offices;*
- *presentation and discussion of studies and researches in scientific congresses and poster sessions.*

*The WINSIX® System evolutionary path that we can read through the over 300 publications, constitutes a significant contribute to the scientific and technological progress of implant dentistry discipline.*



## METODI E RISULTATI

Ricerca e Sviluppo sono stati condotti partendo dalla base di protocolli operativi tradizionali e già ampiamente accreditati dalla comunità scientifica (con posizionamento di impianti in osso guarito e con carico differito), spingendosi verso la possibilità di avere dei dati ben valutabili a livello di impianti in siti post-estrattivi ed in siti rigenerati con osso autologo o con biomateriali, associati o meno a procedure di carico immediato, riabilitazioni minimamente invasive in pazienti edentuli.

Lo sviluppo della componentistica chirurgica e protesica è avvenuto in stretta collaborazione con le più importanti cliniche universitarie, tra cui prioritario il Dipartimento di Odontoiatria dell'Ospedale San Raffaele di Milano. Qui la collaborazione in ambito clinico e di ricerca consente di presentare oggi i dati sistematicamente raccolti di 16 anni di follow-up in riabilitazioni implantoprotesiche su Sistema Implantare WINSIX®, con la messa a punto di protocolli sperimentati e collaudati.

Le riabilitazioni secondo il protocollo JUST ON 4/6® presentano oggi una casistica prospettica a 11 anni con percentuali di successo implantare e soddisfazione dei pazienti al 98,44%.

La ricerca WINSIX® si è spinta fino al trattamento di pazienti con particolari necessità, quali i soggetti HIV - (pazienti HIV tra i più significativi per il maggior rischio infettivo e la difficoltà di compliance) - ed in soggetti in esiti di neoplasie del distretto cervico facciale, dove vanta una casistica tra le più significative relativamente alla riabilitazione implantoprotesica tradizionale ed al carico immediato.

La casistica di applicazione del protocollo JUST ON 4/6® attualmente in essere in pazienti HIV, costituisce un ambito di ricerca assoluto sul piano internazionale.

Attualmente allo studio un impianto dedicato alle riabilitazioni protesiche extraorali ed epitesi facciali.

L'evidenza scientifica è stata raggiunta nello studio della CHIRURGIA PIEZOELETTRICA, anche in questo caso nei tre step della ricerca: in vitro, su animale e in vivo su paziente.

Per quanto riguarda il SOSTITUTIVO OSSEO BIOBONE l'analisi, oltre ad essere stata condotta in modo completo, è stata associata a tecniche di biologia molecolare per lo studio della guarigione del tessuto osseo.

## UN PASSO AVANTI

L'importanza di perseguire standard scientifici in linea con i principi dell'evidenza scientifica presenta fondamentali risvolti clinici che impattano sull'attività quotidiana dell'odontoiatra in studio: la disponibilità di protocolli, materiali e tecnologie accuratamente testati e validati consente di disporre di strumenti fondamentali per il benessere clinico e socio-psicologico dei pazienti edentuli, contribuendo in modo significativo al miglioramento della loro salute e benessere generale.

Le pagine che seguono sono la testimonianza dello straordinario potenziale WINSIX®, intrinseco di innovazione, attraverso l'applicazione tecnologica e organizzata delle scoperte scientifiche che costantemente viene condotta.

## METHODS AND RESULTS

*Research and development have been conducted on the basis of traditional operative protocols, already validated by the scientific community, in cases of late implant insertion in healed bone and in cases of delayed loading. The scope was to fill out data concerning both implant insertion in post extractive sites, and regenerated sites by use of autologous bone or biomaterials, combined or not with immediate loading procedures and minimally invasive rehabilitations in totally edentulous patients.*

*The development of surgical and prosthetic components was done in close cooperation with the most relevant university clinics, among which the San Raffaele Hospital Department of Dentistry in Milan is prior.*

*In this case, cooperation in clinical and research phases, allows today to present data systematically collected throughout 16 years follow-up in prosthetic rehabilitations on WINSIX® Implant System, with finalization of experimented and validated protocols.*

*Rehabilitation case history according to JUST ON 4/6® protocol, shows today a 11 years prospective study, with implant success rate and patient satisfaction up to 98,44%.*

*WINSIX® research was led up to the treatment of patients with special needs, such as HIV subjects (HIV patients are specially meaningful because of the increased infective risk and difficulty in compliance) and in subjects in response to head and neck district neoplasm. In such cases WINSIX® shows one of the most relevant case history concerning traditional implant-prosthetic rehabilitation and immediate loading.*

*JUST ON 4/6® application case history is actually into being in HIV patients and constitutes an exclusive research field internationally.*

*At the moment, a new implant dedicated to extra oral prosthetic rehabilitations and to facial epitheses is being studied.*

*Scientific evidence has been reached in the study of PIEZOELECTRIC SURGERY, and also thanks to research conducted as always in 3 steps: in vitro, in vivo trials using animal model, in clinical evidence.*

*As far as BIOBONE BONE SUBSTITUTE, the analysis was fully carried out. Moreover, it was associated to molecular biology techniques relative to the study of bone tissue healing.*

## ONE STEP FORWARD

*The importance to pursue top scientific standards according to scientific evidence principles carries fundamental clinical implications, acting directly on the daily dental office activity. The availability of protocols, materials and technologies carefully tested and validated, offers the use of fundamental instruments for the clinical and socio-psychological status of edentulous patients, so contributing to the improvement of their health and general comfort.*

*The following pages witness the extraordinary WINSIX® potential, inherent of innovation, through the organized and technological application of scientific discoveries which is daily prosecuted.*

## DOPPIO PERCORSO DI QUALITÀ

BIOSAFIN persegue criteri di qualità Aziendale e di Prodotto. A questo scopo, il solido background scientifico ed il rigore della ricerca condotta creano le premesse per l'ottenimento delle relative certificazioni:

ISO 9001: pertinente ai processi di lavoro aziendali a 360°

ISO 13485: pertinente in modo specifico alla qualità dei dispositivi medici.

## SUI LUPPO COERENTE E ORGANICO DEL SISTEMA IMPLANTARE WINSIX®

Lo sviluppo dei dispositivi WINSIX® tiene conto e si basa sull'osservazione delle evoluzioni socio-sanitarie della popolazione.

Innovazione e tecnologia vengono perseguite mantenendo criteri di coerenza con la produzione precedente, evitando così al Team odontoiatrico impegnativi cambiamenti di iter operativi o dispendiose sostituzioni di materiali, consentendo al contempo di offrire prestazioni e terapie all'avanguardia.

## CERTIFICAZIONI AZIENDALI

Il mantenimento dei parametri qualitativi richiesti dalle Certificazioni viene periodicamente esaminato e rivalutato secondo le normative.

## ASSICURAZIONI

I dispositivi del Sistema Implantare WINSIX® beneficiano delle assicurazioni RCT (Responsabilità civile Conto Terzi) e RCP (Responsabilità civile).

## TUTELA INTERNAZIONALE DEL BRAND WINSIX®

WINSIX® è un marchio registrato e il Sistema Implantare gode di diversi brevetti.

## THE COMPANY DOUBLE QUALITY SYSTEM

*BIOSAFIN production and management comply with Quality policy. For this purpose, the solid scientific background ad strict research criteria create the conditions for the obtaining of relative certifications.*

*ISO 9001: which certifies the whole work process at 360°*

*ISO 13485: relates specifically to the Quality of the Medical Devices*

## WINSIX® IMPLANT SYSTEM COHERENT AND LINEAR DEVELOPMENT

*Development of WINSIX® devices takes into consideration and is based on the observation of the population social and health evolution.*

*Innovation and technology are pursued observing coherence with the previous product lines, so avoiding the operative Team demanding changes in operative sequences and costly substitution of materials. At the same time this makes possible to offer updated performances and therapies.*

## COMPANY CERTIFICATIONS

*Quality compliance to the Certifications required parameters undergoes periodical tests, according to specific regulations themselves.*

## INSURANCES

*WINSIX® Implant System enjoys civil and third parties liability insurance (RCP + RCT).*

## INTERNATIONAL WINSIX® BRAND PROTECTION

*WINSIX® Implant System is a registered brand and enjoys various patents.*

BREVETTI:  
PATENTS:

**CAB - Clip Abutment Bar**  
International and European Patent

Brevetto Internazionale ed Europeo:  
PCT/EP2011/072448  
EP Patent n.11425032.7

**Moncone TRUMPET**  
TRUMPET Abutment

EP Patent n.3424460

CERTIFICAZIONI PRODOTTO  
PRODUCT CERTIFICATIONS



MARCHI REGISTRATI:  
REGISTERED TRADEMARKS



- 1995 WINSIX®
- 1998 Free Tense System®
- 2001 Bioactive Covering®
- 2001 Free Lock®
- 2007 Full Contact Covering FCC®
- 2009 Flat Shift System®
- 2009 Micro Rough Surface MRS®
- 2010 Extreme Abutment®
- 2010 Teeth Just On 4®
- 2010 Teeth Just On 6®
- 2010 Torque Type®
- 2011 Clip Abutment Bar CAB®
- 2012 WINClinic®
- 2013 WINPeek® Abutment
- 2016 Extreme Abutment Multifunctional®
- 2016 Linea KAPPA®
- 2019 Linea SLIM®
- 2020 Linea KE®
- 2020 Moncone TRUMPET®
- 2021 Linea K25®
- 2023 Linea BAC®



- 2017 BiAligner®
- 2020 BIOSAFIN CREA®
- 2022 GUIDED SURGERY®



- 2009 BioBone®
- 2009 Easy Surgery®
- 2015 Easy Weld®
- 2015 Easy Light®
- 2015 Easy Physio®





**1 Progetto digitale integrato in impianto-protesi: case report**

R.Sgreccia, G.Toma, L.Franceschi, S.Ferri, V.Pensa

Doctor OS Maggio 2023 XXXIV 05

**2 L'utilizzo del Magnetic Mallet per l'estrazione di un elemento dentale e per la preparazione del sito implantare:****case report e revisione della letteratura**

C.Oddi, G.Collina, M.Todaro, I.Cusenza, C.Ferraro, V.Pensa

Doctor OS Maggio 2023 XXXIV 05

**3 Impianti dentali in pazienti affetti da patologie sistemiche: studio prospettico longitudinale di 5 anni.**

M.G.Broglio, C.Ruscica, R.D.Cunto, G.Bellantoni

Doctor OS Marzo 2023 XXXIV 03

**4 Riabilitazione impianto protesica: case report**

M.Cardili, G.Toma, P.Bisi, C. Dal Pos, C.De Rubertis, F.Panerai

Ariesdue Marzo 2023

**5 Riabilitazione mascellare e mandibolare completa a carico immediato su quattro impianti in età avanzata: studio retrospettivo follow-up a 8 anni**

M.Longoni, L.Paternoster, T.Arduini, G.Toma, L.Franceschi

Doctor OS Gennaio 2023- XXXIV 01

## FOCUS ON DIGITAL DENTISTRY

## Progetto digitale integrato in implanto-protesi: case report



**Roberto Sgreccia\***, **Greta Toma\***,  
**Lorenzo Franceschi\***, **Serena Ferri\***, **Vittorio Pensa\***

\*  
Odontoiatra, Dipartimento di Odontoiatria, IRCCS  
Ospedale San Raffaele, Milano (Direttore Prof. E.  
Gherlone)

## PAROLE CHIAVE

**Protesi fissa, procedimento digitale,  
riever sistematica.**

### SCOPO DEL LAVORO

Lo scopo di questo lavoro è quello di descrivere attraverso un case report una riabilitazione implanto-protetica in zona estetica 22 ridando armonia all'intero sorriso della paziente.

Grazie all'introduzione di nuovi dispositivi e software, la professione odontoiatrica sta cambiando completamente. Ad oggi, è possibile pianificare in dettaglio dalle procedure chirurgiche a quelle restaurative, con l'ausilio di modellazione sia 3D che 2D.

### MATERIALI E METODI

Una giovane donna di 25 anni in visita presso il Dipartimento di Odontoiatria dell'IRCCS Ospedale San Raffaele di Milano riferisce dolenzia a livello del 22, dove si evidenzia lesione apicale visibile radiograficamente e una frattura dell'elemento stesso. Vie-

ne deciso di eseguire una riabilitazione implanto-protetica con progettazione protetica digitale. È stato realizzato uno smile-design 2D con software digitale. Successivamente si è proceduto alla riabilitazione implantare con il posizionamento di due impianti post-estrattivi.

### RISULTATI E CONCLUSIONI

La riabilitazione implanto-protetica mediante progettazione protetica digitale ha rispettato in pieno le richieste estetiche e funzionali della paziente, permettendo un intero ripristino dell'apparato stomatognatico.

### INTRODUZIONE

Il concetto di digitalizzazione in campo odontoiatrico non è più considerabile come esperienza di nicchia, ma bensì uno strumento utilizzabile nel-

## FOCUS ON DIGITAL DENTISTRY

la vita quotidiana in ogni settore odontoiatrico.

L'aiuto fornito da un workflow digitale si riflette sulla qualità di vita nello studio odontoiatrico, permettendo di sostituire una serie di procedure odontoiatriche tradizionali creando dei risultati estetici e funzionali migliori.

Con questi strumenti alla portata di tutti, l'odontoiatria restaurativa non dovrebbe essere intrapresa senza una chiara comprensione delle aspettative del paziente e dei limiti della terapia restaurativa. Il risultato finale dovrebbe essere visualizzato e realizzato tramite un mock-up prima di eseguire una procedura irreversibile. In questo contesto, uno strumento come il digital smile design, che permette uno studio approfondito e una comunicazione ottimale con il paziente, risulta indispensabile soprattutto in caso di restauri in zona estetica.

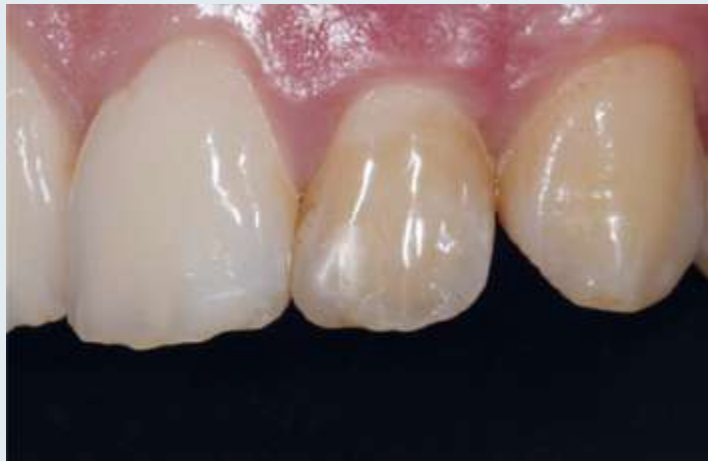In queste case report è descritto un caso di riabilitazione estetica implanto-protetica con digital smile design.

### CASE REPORT

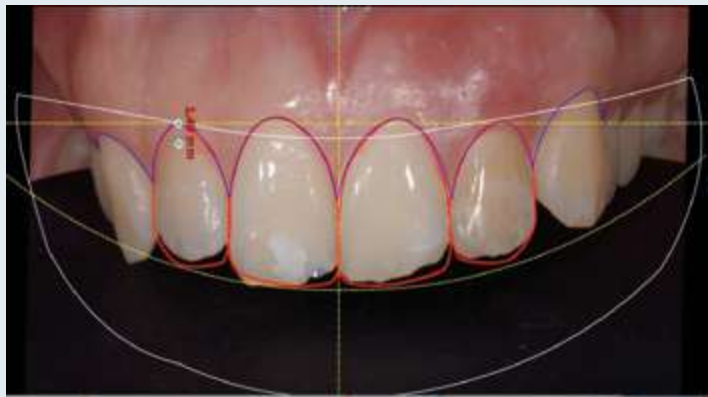
Una paziente donna di 22 anni è giunta all'attenzione del Dipartimento di Odontoiatria, IRCCS Ospedale San Raffaele di Milano (Direttore Prof. E. Gherlone) con lesione periapicale del 22 e frattura dell'elemento stesso, lamentando dolore (fig. 1). Dopo un'attenta anamnesi clinica e radiografica è stata effettuata una valutazione oclusale e fonetica, ed è stata proposta alla paziente una riabilitazione implanto-protetica coadiuvata da progetto di digital smile design.

La richiesta iniziale della paziente era un miglioramento estetico soprattutto del settore frontale e quindi per progettare al meglio la riabilitazione si è proceduto ad elaborare un progetto coadiuvato con digital smile design.

Successivamente è stata scattata una fotografia del volto sorridente, facen-



**Fig. 1** Elemento 22 fratturato e con lesione periapicale.



**Fig. 2** Progettazione digitale tramite software Digital 2D.

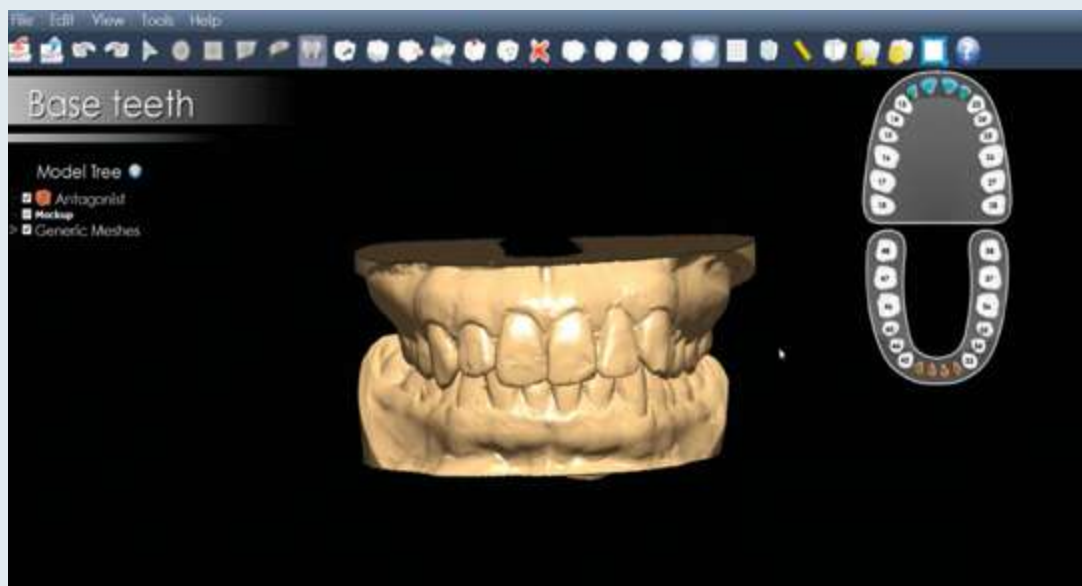
do indossare alla paziente un apposito calibratore, sul quale è possibile individuare i punti di riferimento. La fotografia è stata inserita nel software Digital 2D e, grazie al calibratore utilizzato, il software ha elaborato misurazioni accurate (fig. 2).

All'interno del software prescelto è stato realizzato un disegno digitale del

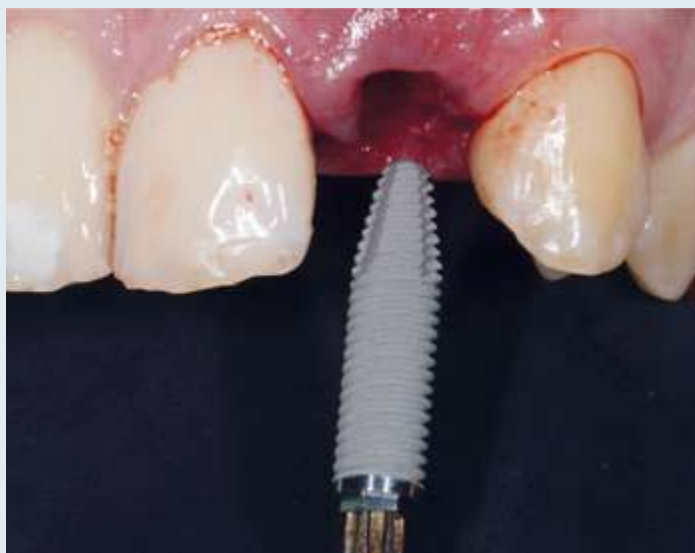sorriso ideale del paziente, elaborato sulla base dello studio delle linee facciali di riferimento, utilizzando le librerie dentali contenute all'interno del software stesso.

Lo studio preliminare del design protesico, infine, è stato ricevuto dal paziente per una pre-visualizzazione estetica. A questo punto sono state

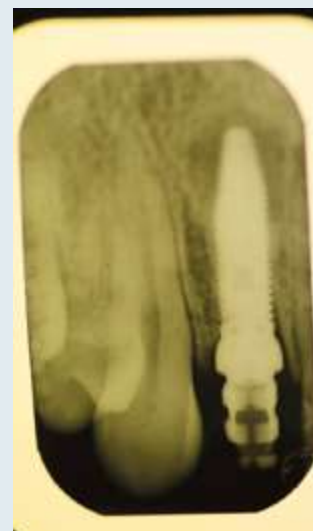FOCUS ON DIGITAL DENTISTRY



**Fig. 3** Impronta ottica superiore e inferiore.



**Fig. 4** Inserimento fixture implantare in sede 22.



**Fig. 5** Rx postoperatoria: evidente la lesione periapicale presente inizialmente.

## FOCUS ON DIGITAL DENTISTRY

---

prese le impronte ottiche della paziente (fig. 3).

Successivamente, seguendo il piano di trattamento presentato inizialmente alla paziente si è proceduto all'estrazione dell'elemento 22, fratturato e con lesione apicale importante. Nella stessa seduta operatoria è stata inserita la fixture implantare in sede 22 (fig. 4-5).

Il protocollo chirurgico prevedeva la somministrazione prima dell'intervento di:

- 2 g di amoxicillina 1 ora prima dell'intervento;
- sciacquo con collutorio alla clorexidina 0,2%;
- sciacquo con perossido di idrogeno 1%.

Pravia anestesia locale con articaina 1:100.000, è stata eseguita l'estrazione atraumatica dell'elemento dentale, permettendo così il mantenimento dell'integrità delle pareti alveolari residue. Eseguita l'estrazione, si è proceduto al curettage chirurgico dell'alveolo post-estrattivo e al lavaggio con soluzione fisiologica.

Seguendo il protocollo chirurgico dedicato alla tipologia implantare (WinSix, BioSAFin S.r.l., Ancona), si è preparata la sede implantare. L'impianto inserito aveva una superficie rugosa MRS (micro-rough surface) ottenuta tramite processo di sottrazione, per sabbatura e mordenzatura, direttamente della superficie in titanio dell'impianto. Le dimensioni (diametro e lunghezza) implantari sono state determinate in base alla morfologia dell'alveolo residuo per garantire un appoggio su almeno una parete o massimo 3 pareti (palatale, mesiale e distale), evitando la compressione diretta dell'impianto sul piatto buccale. La stabilità primaria è stata ottenuta mediante l'ingaggio dei 3-4 mm apicali all'alveolo. L'impianto è stato posizionato all'incirca 1 mm sotto il livello crestale.

In seguito all'intervento chirurgico sono stati prescritti:

---

## FOCUS ON DIGITAL DENTISTRY

- 1 g di amoxicillina ogni 8 ore per 6 giorni;
- antinfiammatori non steroidei al bisogno;
- sciacqui con collutorio a base di clorexidina 0,12% durante le prime 2 settimane;
- tutti i pazienti sono stati istruiti a evitare lo spazzolamento traumatico.

L'impianto è stato caricato con protesi provvisoria dal momento che la stabilità primaria era buona. L'occlusione nella zona operata è chiaramente assente.

Per riabilitare esteticamente il settore anteriore in accordo con la paziente si è proceduto quindi con le ricostruzioni estetiche di 12, 11 e 21. Previamente è stata eseguita la gengivectomia con laser a diodo del 12 (2 Watt, continuo wave) (fig. 2).

A 4 mesi finalizzeremo l'elemento 22 con corona avvitata sulla base del nuovo disegno che abbiamo stabilito nello smile design (fig. 6).

## RISULTATI

Nel caso di riabilitazione implanto-protetica appena descritto per la parte protetica si è eseguito un work-flow totalmente digitale per ottenere il risultato desiderato dalla paziente sia in termini estetici che funzionali. L'utilizzo del progetto digitale e ha consentito una completa valutazione iniziale dal punto di vista estetico, permettendo al clinico di pianificare tutto nei minimi dettagli e al paziente di pre-visualizzare il risultato finale. Al termine della fase riabilitativa il paziente si è dichiarato soddisfatto sia dal punto di vista estetico che funzionale.

## DISCUSSIONE

Gli scanner intraorali sono dispositivi digitali utilizzati non solo per ottenere modelli di studio ma anche per

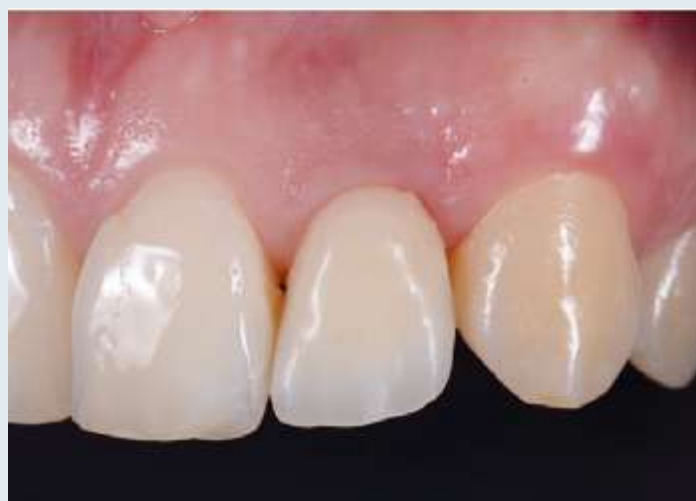

Fig. 6 Protesizzazione con corona metallo-ceramica dell'elemento 22 a sei mesi dall'intervento.

il rilevamento di impronte necessarie per la modellazione di restauri protesici. Negli ultimi anni, la varietà delle applicazioni, insieme ai vantaggi di queste apparecchiature, hanno reso gli scanner intraorali dispositivi molto interessanti. Sul mercato esistono diversi scanner intraorali, ma l'elemento più importante da considerare dovrebbe essere l'accuratezza, ovvero la qualità dei dati derivati dalla scansione, una combinazione di veridicità e precisione. Esistono già segnalazioni in letteratura specializzata che hanno studiato l'accuratezza dei diversi scanner intraorali disponibili. Il processo digitale può ridurre gli errori manuali, come Cattoni et al. hanno spiegato nel 2019. Lo studio ha mostrato una differenza di precisione tra i modelli tradizionali stampati e fressati, riportando che il metodo digitale consente una maggiore precisione. Un altro vantaggio del work-flow digitale è la possibilità di avere un modello preoperatorio che consente al paziente sia di vedere l'impatto del nuovo sorriso

prima di eseguire delle procedure irreversibili e, inoltre, ne aumenta l'educazione e l'accettazione. La simulazione del trattamento virtuale consente anche la simulazione di procedure interdisciplinari prima di iniziare il trattamento vero e proprio. Questo aiuta il clinico ad avere una migliore visualizzazione dei problemi, un migliore processo decisionale e meno errori intraoperatori. Per quanto riguarda la realizzazione di restauri definitivi, le macchine CAD/CAM Cerec sono attualmente utilizzate per produrre restauri in ceramica basati sulla progettazione assistita da computer e produrre un restauro in un singolo appuntamento dal dentista. Recentemente i sistemi CAD-CAM, in particolare i sistemi di impronta digitale, stanno unendo studi odontoiatrici e laboratori odontotecnici, con conseguente miglioramento della comunicazione e del restauro. In un articolo di Chen del 2015 viene descritta l'importanza di comunicazione tra clinico e paziente nell'accettazione dei restauri prote-

## FOCUS ON DIGITAL DENTISTRY

sici da parte dei pazienti. Carlsson ha suggerito che i fattori psicologici sono cruciali nell'accettazione e nell'adattamento alle riabilitazioni protesiche. In considerazione di quanto sopra, alcuni dei potenziali benefici dell'odontoiatria digitale includono: miglioramento della pianificazione del trattamento e del processo di "design del sorriso", trasformando il paziente in un co-autore del proprio nuovo sorriso. Anche Gastaldi et al. nel 2019 hanno spiegato che la percezione del miglioramento del sorriso del paziente è davvero importante per aumentare il benessere del paziente. Quindi lo sviluppo di un protocollo di comunicazione efficace facilita un'odontoiatria interdisciplinare, con l'aumento del valore percepito del trattamento odontoiatrico e conseguentemente della sua accettazione attraverso una migliore educazione e motivazione. Nelle conclusioni dell'articolo di Chen viene dichiarato che i pazienti con una comunicazione ottimale con il clinico presentavano una migliore accettazione del restauro protesico. Il processo protesico digitale semplifica anche la comunicazione tra il clinico e il laboratorio. Tutto il trasferimento di dati digitali, dalla pianificazione 3D clinica al processo CAD/CAM di laboratorio, è più semplice, veloce e prevedibile. Questa comunicazione semplificata tra clinico e laboratorio porta naturalmente alla produzione di restauri precisi e accurati, come dichiarato da Gherlone et al. in uno studio retrospettivo in cui manufatti protesici prodotti con processo CAD-CAM sono risultati molto precisi ed accurati.

C'è anche da notare che, come descritto da Joda et al. in una revisione sistematica del 2017, manca ancora un'evidenza scientifica supportata da un numero consistente di RCT che descrivono i processi digitali per diverse tipologie di protesi sia su impianti che su denti naturali.

In questo caso, contemporaneamente alla riabilitazione protesica è stato effettuato anche un rialzo della DVO che ha permesso di ristabilire una giusta funzione e di migliorare l'estetica delle labbra rispettando la richiesta iniziale della paziente. Nel caso appena presentato è descritta una riabilitazione implanto-protesica in cui la parte protesica è stata interamente eseguita mediante progettazione digitale. La progettazione digitale sembra quindi aiutare molto il clinico anche in riabilitazioni complesse, sia estetiche che funzionali. Con tutti i limiti del presente studio è possibile affermare che il work-flow digitale permetta di produrre manufatti protesici di alta qualità e che aiuti molto la progettazione insieme al paziente di riabilitazioni complesse. In conclusione, la digitalizzazione in fase diagnostica e operativa può aiutare il clinico, nella pianificazione del disegno di riabilitazione del paziente, a mantenere il progetto iniziale durante le fasi di lavoro e a rispettare la funzione e l'estetica del paziente.

### CONCLUSIONI

La riabilitazione descritta in questo case report ha mostrato come ad oggi un workflow protesico full-digital sia una procedura affidabile. ●

### Integrated digital project in implant-prosthesis: case report

#### Aim of the work

*The purpose of this work is to describe, through a case report, a prosthetic implant rehabilitation in aesthetic zone 22, restoring harmony to the patient's entire smile.*

*Thanks to the introduction of new devices and software, the dental profession is completely changing. To date, it is possible to plan in detail from*

*surgical to restorative procedures, with the aid of both 3D and 2D modeling.*

#### Materials and methods

*A 25-year-old woman visiting the Department of Dentistry of the IRCCS San Raffaele Hospital-Milan reports discomfort at the level of 22, due to an apical lesion visible radiographically and a fracture of the element itself. It was decided to perform an implant-prosthetic rehabilitation with digital prosthetic design. A 2D smile-design was created with digital software. Subsequently, the implant rehabilitation was carried out with the placement of two post-extraction implants.*

#### Results and conclusions

*The implant-prosthetic rehabilitation through digital prosthetic design fully complied with the aesthetic and functional requirements required by the patient, allowing a complete restoration of the stomatognathic system.*

#### Keywords

*Fixed prosthesis, digital procedure, systematic review.*

#### Bibliografia

1. Cattoni F, Mastrangelo F, Gherlone EF, Gastaldi G. A New Total Digital Smile Planning Technique (3D-DSP) to Fabricate CAD-CAM Mockups for Esthetic Crowns and Veneers. *Int J Dent.* 2016;2016:6282587. doi: 10.1155/2016/6282587. Epub 2016 Jul 10.
2. Rosenstiel SF, Rashid RG. Public preferences for anterior tooth variations: a web-based study. *J Esthet Restor Dent* 2002;14(2):97-106
3. Sarver DM. The importance of incisor positioning in the esthetic smile: the smile arc. *Am J Orthod Dentofacial Orthop* 2001;120(2): 98-111.
4. Parekh SM, Fields HW, Beck M, Rosenstiel S. Attractiveness of variations in the smile arc and buccal corridor space as judged by orthodontists and laymen. *Angle Orthod* 2006;76(4):557-563.
5. Chen JH, Huang HL, Lin YC, Chou TM, Ebin-



## FOCUS ON DIGITAL DENTISTRY

- ger J, Lee HE. Dentist-Patient Communication and Denture Quality Associated with Complete Denture Satisfaction Among Taiwanese Elderly Wearers. *Int J Prosthodont*. 2015 Sep-Oct;28(5):531-7. doi: 10.11607/ijp.4223. PMID: 26340016.
6. Gherlone E, Mandelli F, Capparè P, Pantaleo G, Traini T, Ferrini F. A 3 years retrospective study of survival for zirconia-based single crowns fabricated from intraoral digital impressions. *J Dent*. 2014 Sep;42(9):1151-5. doi: 10.1016/j.jdent.2014.06.002. Epub 2014 Jun 12. PMID: 24930869
  7. Blatz MB, Chiche G, Bahat O, Roblee R, Coachman C, Heymann HO. Evolution of Aesthetic Dentistry. *J Dent Res*. 2019 Nov;98(12):1294-1304. doi:10.1177/0022034519875450. PMID: 31633462
  8. Carlsson GE. Clinical morbidity and sequelae of treatment with complete dentures. *J Prosthet Dent*. 1998 Jan;79(1):17-23. doi: 10.1016/s0022-3913(98)70188-x. PMID: 9474536.
  9. Reshad M, Cascione D, Magne P. Diagnostic mock-ups as an objective tool for predictable outcomes with porcelain laminate veneers in esthetically demanding patients: a clinical report. *J Prosthet Dent*. 2008 May;99(5):333-9. doi: 10.1016/S0022-3913(08)00056-5. PMID: 18456043.
  10. Ker AJ, Chan R, Fields HW, Beck M, Rosenstiel S. Esthetics and smile characteristics from the layperson's perspective: a computer-based survey study. *J Am Dent Assoc*. 2008 Oct;139(10):1318-27. doi: 10.14219/jada.archive.2008.0043. PMID: 18832267.
  11. Joda T, Zarone F, Ferrari M. The complete digital workflow in fixed prosthodontics: a systematic review. *BMC Oral Health*. 2017 Sep 19;17(1):124. doi: 10.1186/s12903-017-0415-0. PMID: 28927393; PMCID: PMC5606018.
  12. Guichet DL. Digital Workflows in the Management of the Esthetically Discriminating Patient. *Dent Clin North Am*. 2019 Apr;63(2):331-344. doi: 10.1016/j.cden.2018.11.011. Epub 2019 Feb 2. PMID: 30825994.
  13. Cattoni F, Tetè G, Calloni AM, Manazza F, Gastaldi G, Capparè P. Milled versus moulded mock-ups based on the superimposition of 3D meshes from digital oral impressions: a comparative in vitro study in the aesthetic area. *BMC Oral Health*. 2019 Oct 29;19(1):230. doi: 10.1186/s12903-019-0922-2.
  14. Cattoni F, Tetè G, Uccioli R., Manazza F., Gastaldi G., Perani D. "An fMRI Study on Self-Perception of Patients after Aesthetic Implant-Prothetic Rehabilitation". *Int J Environ Res Public Health* 2020 Gen 16;17(2):588. doi: 10.3390/ijerph17020588.
  15. Gastaldi G, Gherlone E, Manacorda M, Ferrini F, Bova F, Vinci R, Cattoni F. Una tecnica CAD/CAM 3-D nelle riabilitazioni implanto-protesi integrali: la procedura implantoprotesica virtuale (tecnica VIPP) . Uno studio prospettico longitudinale. *Journal of Osteointegration Open Access* Volume 10, Issue 1, 2018, pagine 2-10
  16. McGarry TJ, Nimmo A, Skiba JF, Ahlstrom RH, Smith CR, Koumjian JH, et al. Classification system for the completely dentate patient. *J Prosthet Dent* 2004;13:73-82.
  17. Aragón ML, Pontes L, Bichara L, Flores-Mir C, Normando D. Validity and reliability of intraoral scanners compared to conventional gypsum models measurements: a systematic review. *Eur J Orthod*. 2016;38:429-34.

## FOCUS ON DIGITAL DENTISTRY

## L'utilizzo del Magnetic Mallet per l'estrazione di un elemento dentale e per la preparazione del sito implantare: case report e revisione della letteratura



Carlo Oddi\*, Giorgio Collina\*\*, Marta Todaro\*\*,  
Irene Cusenza\*\*, Costanza Ferraro\*\*,  
Vittorio Pensa\*\*

\* Dipartimento di Odontoiatria, IRCCS Ospedale San Raffaele, Milano (Direttore: Prof. E. Gherlone)

\*\* Scuola di Specializzazione in Chirurgia Orale, Università Vita-Salute San Raffaele, Milano (Direttore: Prof. R. Vinci)

## PAROLE CHIAVE

Magnetic Mallet, estrazione dentale, sito implantare, impianto dentale.

## SCOPO DEL LAVORO

Lo scopo di questo articolo è dimostrare come il Magnetic Mallet possa essere utilizzato, in modo prevedibile e sicuro, non solo per facilitare l'estrazione dei denti, ma anche per la preparazione del sito implantare.

## MATERIALI E METODI

Un paziente di 58 anni si è recata presso il Dipartimento di Odontoiatria dell'IRCCS Ospedale San Raffaele di Milano con l'obiettivo di riabilitare l'elemento 22 dal punto di vista estetico e funzionale. In un primo momento, utilizzando il Magnetic Mallet, è stato avulso l'elemento dentale, successivamente è stato preparato il sito implantare ed è stato poi inserito un impianto Winsix TTI 3,8x11.

## RISULTATI

L'ortopantomografia, eseguita a sei mesi di follow-up, ha confermato il successo dell'osteointegrazione ed ha mostrato un contatto intimo tra osso e impianto, con un'apparente assenza di tessuto fibroso interposto.

## CONCLUSIONI

Gli autori sono concordi sulla sicurezza, predicibilità e facilità di utilizzo del Magnet Mallet, sia per le estrazioni dentali che per la preparazione del sito implantare.

## INTRODUZIONE

Con l'aumento dell'età media della popolazione mondiale, è sempre più fre-

## FOCUS ON DIGITAL DENTISTRY

quente trovare casi di edentulismo singolo o multiplo nella pratica odontoiatrica (1). L'inserimento di impianti dentali, per ripristinare l'estetica e la funzione di questi pazienti, sembra essere una valida opzione di trattamento con ottimi risultati prognostici (2).

Una tecnica prevedibile per l'inserimento di impianti endossei è quella relativa all'utilizzo del Magnetic Mallet (3). Si tratta di uno strumento che trova impiego in chirurgia orale ed ha l'obiettivo di ridurre le sequele postoperatorie generate dall'utilizzo dei classici martelli chirurgici (4).

Il Magnetic Mallet viene utilizzato nelle tecniche di rialzo del seno mascellare, nello split crest, ma anche nella preparazione del sito implantare (5). Alla base del suo funzionamento c'è un effetto elettromagnetico: un manipolo eccitato da un alimentatore elettronico ha la capacità di controllare le forze e il momento della loro applicazione (6). Le forze emesse saranno più forti ma meno durature. Ciò consente di trasmettere alla punta del manipolo un'onda d'urto regolabile e calibrata in modo da ottenere una deformazione plastica dell'osso, per un periodo tale che la forza non venga dissipata in tutta la scatola cranica (7).

Quando si utilizzano i classici martelli chirurgici, è comune che il paziente sviluppi una vertigine posizionale parossistica benigna (BPPV), un sintomo postoperatorio piuttosto frequente. Con il Magnetic Mallet, grazie all'utilizzo calibrato delle forze applicate alla componente ossea, questa sequela chirurgica può essere ridotta, se non del tutto eliminata (8,9). Lo strumento è quindi in grado di rendere le manovre chirurgiche tollerabili dal paziente e di rendere possibile l'eventuale divisione di una struttura ossea, laddove necessario, al fine di creare un alveolo chirurgico adatto all'inserimento dell'impianto (10).

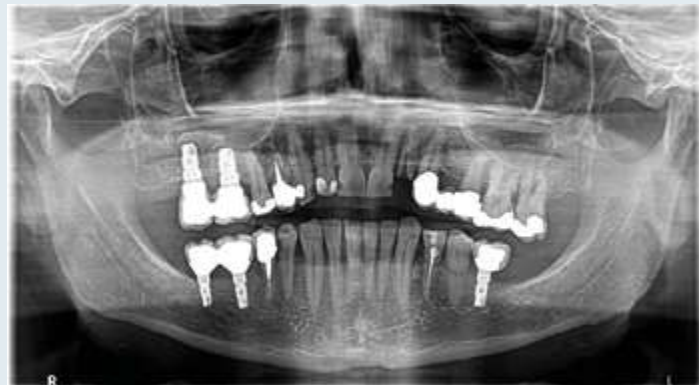

Fig. 1 Ortopantomografia preoperatoria.

Lo scopo di questo articolo è dimostrare come il Magnetic Mallet possa essere utilizzato, in modo prevedibile e sicuro, non solo per facilitare l'estrazione dei denti, ma anche per la preparazione del sito implantare. E infine, per ridurre la vertigine posizionale parossistica benigna (BPPV).

#### Case report

Il paziente, un uomo di 58 anni, si è rivolto presso il Dipartimento di Odon-

toiatria dell'IRCCS Ospedale San Raffaele di Milano con l'obiettivo di riabilitare l'elemento 22 dal punto di vista estetico e funzionale. All'esame obiettivo intraorale, si osserva l'elemento 22 con una corona protesica Richmond. Successivamente, è stato eseguito un esame radiografico di primo livello, l'ortopantomografia (OPT) (fig. 1), che ha mostrato la presenza di una frattura verticale con decorso medio-distale della radice residua.

Successivamente, dopo aver eseguito

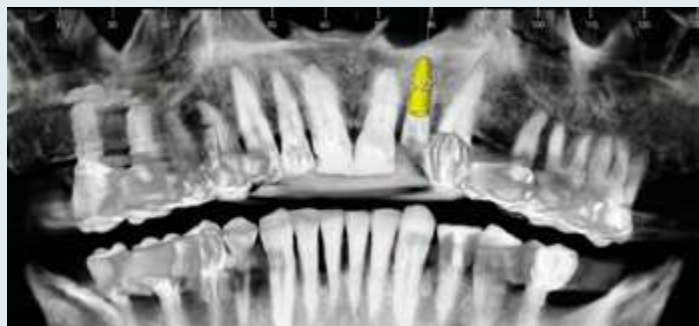
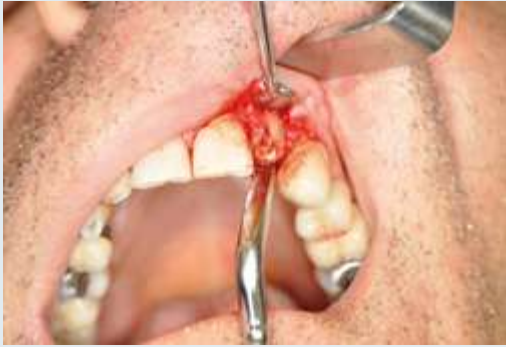
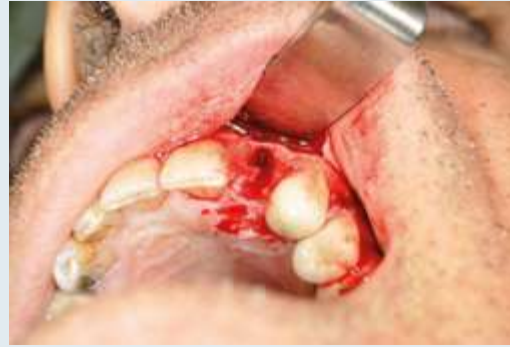Fig. 2 Pianificazione del posizionamento implantare su CBCT.

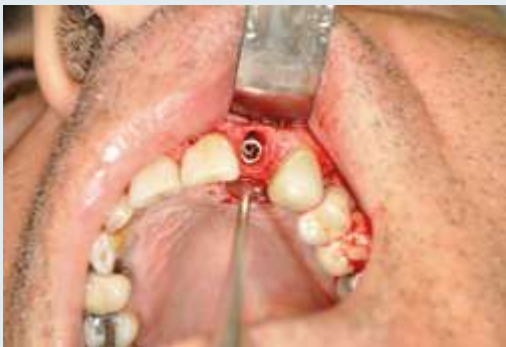## FOCUS ON DIGITAL DENTISTRY



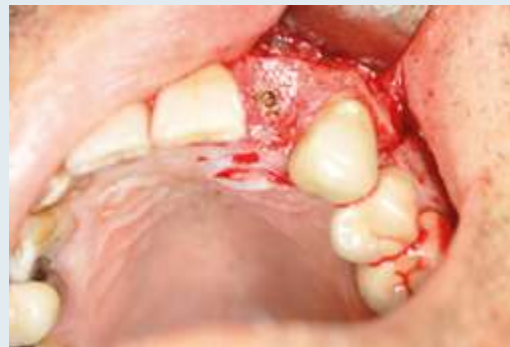**Fig. 3** Estrazione della radice dentale con MM.



**Fig. 4** Alveolo post-estrattivo.



**Fig. 5** Posizionamento dell'impianto.



**Fig. 6** Inserimento del Bio-Oss e dell'osso autologo.

una CBCT (Cone Beam Computed Tomography, un esame di secondo livello), è stato possibile pianificare la futura posizione dell'impianto utilizzando il software CREA-3D Guided Surgery (CREA-3D, Guided Surgery, Biosafin S.r.L., Italia) (fig. 2). Inoltre, nella zona dell'elemento 22 è stato possibile osservare un difetto osseo.

Il piano di trattamento prevede l'avulsione della radice residua e il successivo inserimento di un impianto osteointegrato. Dopo la firma del consenso informato e del trattamento implan-

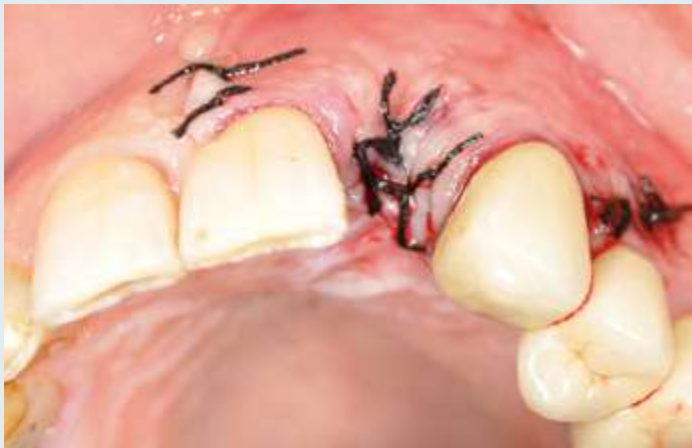to-protetico, il paziente è stato informato sulle possibili complicanze intra e postoperatorie.

Successivamente, è stata eseguita una seduta di igiene orale professionale. La fase chirurgica è stata eseguita in anestesia locale (Optocaina 20 mg/ml con adrenalina 1:80.000; Molteni Dental, Firenze, Italia). La prima fase dell'intervento ha previsto il disegno di un lembo trapezoidale con scollamento a spessore totale dall'elemento 2.1 all'elemento 2.3. Quindi l'avulsione della radice residua è stata eseguita nel modo

più conservativo possibile con l'ausilio del Magnetic Mallet (fig. 3). Utilizzando il cucchiaio alveolare Lucas, è stata eseguita la revisione dell'alveolo post-estrattivo. Successivamente, sono stati eseguiti lavaggi con soluzione fisiologica. La fig. 4 mostra l'alveolo post-estrattivo.

Dopo aver preparato il sito implantare con l'ausilio del Magnetic Mallet, è stato inserito l'impianto Winsix TTI 3,8x11 (TTx, Winsix, Biosafin, Ancona, Italia) con metodica a cielo aperto e un torque di inserimento pari a 30

## FOCUS ON DIGITAL DENTISTRY



**Fig. 7** Riposizionamento del lembo e sutura.

N (fig. 5).

Per coprire il difetto vestibolare, è stato impiegato dell'osso autologo in bozza canina mediante Bone Scraper (Meta Technologies S.r.l., Italia) e, una volta miscelato con Bio-Oss (Geistlich Bio-Oss, Geistlich Biomaterials, Italy S.r.l.), è stato posizionato nella sede del difetto (fig. 6).

Il lembo precedentemente sollevato è stato quindi riposizionato e suturato con sutura non riassorbibile 4-0 (Vicryl; Ethicon, Johnson & Johnson, New Brunswick, NJ, USA) (fig. 7).

Dopo l'intervento, al paziente è stata prescritta la seguente terapia farmacologica: sciacqui con una soluzione contenente clorexidina digluconato (0,12% o 0,2%), due volte al giorno per 10 giorni; 1 g di amoxicillina e acido clavulanico (Augmentin, GlaxoSmithKline) due volte al giorno per 6 giorni dopo l'intervento e farmaci antinfiammatori non steroidei (Naproxene Sale Sodico 550 mg, Synflex, Recordati, Industria Chimica e Farmaceutica S. p. A., Italia) al bisogno. Infine, al paziente è stato consigliato di evitare qualsiasi

trauma da spazzolamento sul sito chirurgico ed inoltre è stato sconsigliato di fumare. Dopo una settimana, il paziente è stato sottoposto a una visita di controllo e contemporaneamente sono state rimosse le suture.

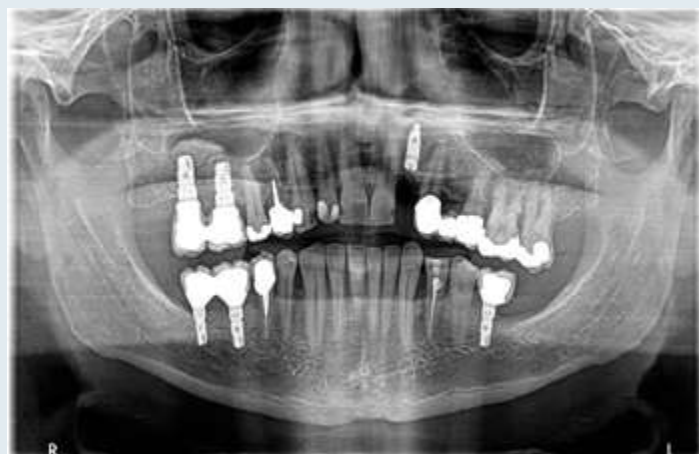Circa sei mesi dopo l'intervento, per ottenere la completa guarigione dei tessuti e la corretta osteointegrazione dell'impianto, è stato possibile inserire una corona protesica definitiva.

#### Follow up

Le visite di follow-up, finalizzate all'esame clinico e radiografico, sono state effettuate una settimana dopo l'inserimento dell'impianto. Successivamente, a tre mesi e a sei mesi. Il paziente è stato istruito da un igienista dentale sul controllo meccanico della placca utilizzando uno spazzolino elettrico o manuale, spazzolini da denti e filo interdentale del tipo Super Floss (Oral B, Procter & Gamble, Cincinnati, OH, USA).

#### RISULTATI

Tasso di sopravvivenza dell'impianto  
Nel caso clinico discusso è stato osservato che a sei mesi di follow-up l'impianto non è stato perso. L'OPT eseguita a sei mesi di follow-up (fig. 8)



**Fig. 8** Ortopantomografia eseguita dopo sei mesi di follow-up.



## FOCUS ON DIGITAL DENTISTRY

ha confermato il successo dell'osteointegrazione e ha mostrato un contatto intimo tra osso e impianto, con un'apparente assenza di tessuto fibroso interposto. L'osteointegrazione dell'impianto è stata favorita dal corretto posizionamento dell'impianto, basato sulla stabilità primaria, ottenuta grazie al torque di 30 N (14).

### Vertigine posizionale parossistica benigna (BPPV)

Trattasi di sequela postoperatoria caratterizzata da parossismi di vertigine scatenati da cambiamenti di posizione della testa in direzione della gravità (12). La BPPV è la causa più comune di vertigini in tutto il mondo, con una prevalenza nel corso della vita del 2,4%, una prevalenza a 1 anno dell'1,6% e un'incidenza a 1 anno dello 0,6% [13].

Grazie all'utilizzo calibrato delle forze applicate alla componente ossea, il Magnetic Mallet ha permesso di eliminare questa sequela chirurgica; il paziente, infatti, non ha riferito alcun disagio.

### DISCUSSIONE

Quando si esegue l'estrazione di un dente, il parodontio subisce un trauma che varia a seconda della tecnica utilizzata. Di norma, il trauma subito dall'osso è difficile da evitare, perché uno dei principi dell'estrazione dentale è l'espansione dell'alveolo (15). Inoltre, l'estrazione traumatica può essere responsabile di danni ai tessuti molli e di una scarsa guarigione a causa del basso flusso sanguigno (16).

In letteratura sono state descritte diverse tecnologie che consentono estrazioni dentali minimamente invasive, tra cui la tecnologia magnetodinamica. La revisione della letteratura di Bennardo F. et al. riporta che tutte le procedure chirurgiche con Magnetic

Mallet non hanno mostrato complicanze legate all'estrazione del dente, con un tasso di sopravvivenza dell'impianto del 98,9% dopo 9-66 mesi di follow-up; inoltre, nessun paziente ha riportato vertigini posizionali parossistiche benigne (BPPV) (10).

Lo studio clinico prospettico di Crespi R. et al. ha confrontato l'utilizzo del martello manuale rispetto al Magnetic Mallet (Meta-Ergonomica, Turbigo, Milano, Italia) per le estrazioni dentali. Gli autori dello studio non hanno osservato complicanze nella guarigione dei tessuti, fratture o traumi all'osso corticale. Ciò è stato possibile grazie ai movimenti assiali applicati sulla punta della lama che hanno permesso il distacco della radice del dente dall'osso circostante (9).

La tecnologia Magnetic Mallet consente anche la preparazione del sito implantare in alternativa alle frese, al fine di ridurre il trauma chirurgico, ottenere un maggiore controllo del taglio, aumentare la stabilità primaria e secondaria e, infine, ridurre i tempi di guarigione (4).

Tra il 2012 e il 2016, Crespi et al. hanno condotto studi prospettici sulla preparazione del sito implantare eseguita con il Magnetic Mallet. Gli autori hanno inserito 218 impianti dentali in un totale di 140 pazienti. Dopo 36 mesi di follow-up, il tasso di sopravvivenza dell'impianto era pari al 96% (7).

Nello studio randomizzato di Crespi et al. nessun paziente trattato con il Magnetic Mallet ha riportato vertigini posizionali parossistiche benigne (BPPV). Ciò è dovuto all'applicazione di forze controllate. Al contrario, i pazienti hanno riportato BPPV in seguito alla preparazione del sito implantare quando sono stati utilizzati martelli manuali (4).

### CONCLUSIONI

Con i limiti di questo studio, gli autori concordano sul fatto che il Magnet

Mallet è sicuro, prevedibile, rapido e facile da usare, sia per le estrazioni dentali che per la preparazione del sito implantare. Tuttavia, sono necessari ulteriori studi per confermare questo risultato. ●

### The use of the Magnetic Mallet for the extraction of a dental element and for the preparation of the implant site: case reports and review of the literature

#### Aim of the work

*The purpose of this article is to demonstrate how the Magnetic Mallet can be used, predictably and safely, not only to facilitate tooth extraction, but also for implant site preparation.*

#### Material and methods

*A 58-year-old patient went to the Dentistry Department of the IRCCS San Raffaele Hospital in Milan with the aim of rehabilitating element 22 from an aesthetic and functional point of view. At first, using the Magnetic Mallet, the tooth was removed, then the implant site was prepared and a Winsix TTI 3.8x11 implant was then inserted.*

#### Results

*The orthopantomography, performed at a six-month follow-up, confirmed the success of the osseointegration and showed an intimate contact between bone and implant, with an apparent absence of interposed fibrous tissue.*

#### Conclusions

*The authors agree on the safety, predictability and ease of use of the Magnet Mallet, both for tooth extractions and for the preparation of the implant site.*

#### Keywords

*Magnetic Mallet, tooth extraction, implant site, dental implant.*

## FOCUS ON DIGITAL DENTISTRY

## Bibliografia

1. Tetè G, Polizzi E, D'orto B, Carinci G, Capparè P. How to consider implant-prosthetic rehabilitation in elderly patients: a narrative review. *J Biol Regul Homeost Agents*. 2021 Jul- Aug;35(4 Suppl. 1):119-126. doi: 10.23812/21-4suppl1-11.
2. Lee DJ, Saponaro PC. Management of Edentulous Patients. *Dent Clin North Am*. 2019 Apr;63(2):249-261. doi: 10.1016/j.cden.2018.11.006. Epub 2019 Jan 30.
3. Davis LL. The Use of the Electro-Magnetic Mallet. *Dent Regist*. 1889Apr;43(4):174-178.
4. Crespi R, Capparè P, Gherlone E. A comparison of manual and electrical mallet in maxillary bone condensing for immediately loaded implants: a randomized study. *Clin Implant Dent Relat Res*. 2014 Jun;16(3):374-82. doi: 10.1111/j.1708-8208.2012.00485.x. Epub 2012 Aug 15.
5. Crespi R, Capparè P, Gherlone E. Sinus floor elevation by osteotome: hand mallet versus electric mallet. A prospective clinical study. *Int J Oral Maxillofac Implants*. 2012 Sep-Oct;27(5):1144-50.
6. Maercklein BJ. The Electric Mallet. *Dent Regist*. 1910 May 15;64(5):234-237.
7. Crespi R, Capparè P, Gherlone EF. Electrical mallet in implants placed in fresh extraction sockets with simultaneous osteotome sinus floor elevation. *Int J Oral Maxillofac Implants*. 2013 May-Jun;28(3):869-74. doi: 10.11607/jomi.2679.
8. Crespi R, Bruschi GB, Capparè P, Gherlone E. The utility of the electric mallet. *J Craniofac Surg*. 2014 May;25(3):793-5. doi: 10.1097/SCS.0000000000000523.
9. Crespi R, Capparè P, Gherlone E. Electrical mallet provides essential advantages in maxillary bone condensing. A prospective clinical study. *Clin Implant Dent Relat Res*. 2013 Dec;15(6):874-82. doi: 10.1111/j.1708-8208.2011.00432.x. Epub 2012 Jan 11.
10. Bennardo F, Barone S, Vocaturo C, Nucchi L, Antonelli A, Giudice A. Usefulness of Magnetic Mallet in Oral Surgery and Implantology: A Systematic Review. *J Pers Med*. 2022 Jan 14;12(1):108. doi: 10.3390/jpm12010108.
11. Marchio V, Derchi G, Cinquini C, Miceli M, Gabriele M, Alfonsi F, Barone A. Tissue level implants in healthy versus medically compromised patients: a cohort comparative study. *Minerva Stomatol*. 2020 Oct;69(5):295-301. doi: 10.23736/S0026-4970.20.04359-9
12. Kim JS, Zee DS. Clinical practice. Benign paroxysmal positional vertigo. *N Engl J Med*. 2014 Mar 20;370(12):1138-47. doi: 10.1056/NEJMcp1309481.
13. von Brevern M, Radtke A, Lezius F, Feldmann M, Ziese T, Lempert T, Neuhauser H. Epidemiology of benign paroxysmal positional vertigo: a population based study. *J Neurol Neurosurg Psychiatry*. 2007 Jul;78(7):710-5. doi: 10.1136/jnnp.2006.100420. Epub 2006 Nov 29.
14. Villa R, Polimeni G, Wikesjö UM. Implant osseointegration in the absence of primary bone anchorage: a clinical report. *J Prosthet Dent*. 2010 Nov;104(5):282-7. doi: 10.1016/S0022-3913(10)00146-0.
15. Saund D, Dietrich T. Minimally invasive tooth extraction: doorknobs and strings revisited! *Dent Update*. 2013 May;40(4):325-6, 328-30. doi: 10.12968/denu.2013.40.4.325.
16. Hong B, Bulsara Y, Gorecki P, Dietrich T. Minimally invasive vertical versus conventional tooth extraction: An interrupted time series study. *J Am Dent Assoc*. 2018 Aug;149(8):688-695. doi: 10.1016/j.adaj.2018.03.022. Epub 2018 May 24.

## STUDIO PROSPETTICO

## Impianti dentali in pazienti affetti da patologie sistemiche: studio prospettico longitudinale di 5 anni

**Marco Guido Broglio \***, **Corrado Ruscica\*\*\***,  
**Renato De Cunto\***, **Giorgia Bellantoni\***

\* Dipartimento di Odontoiatria, IRCCS Ospedale San Raffaele, Milano (Direttore: Prof. E. F. Gherlone)

\*\* Scuola di Specializzazione in Chirurgia Orale, Università Vita-Salute San Raffaele, Milano (Direttore: Prof. R. Vinci)

## PAROLE CHIAVE

**Implantologia, patologie sistemiche, riabilitazioni full-arch, diabete.**

## SCOPO DEL LAVORO

*L'obiettivo di questo studio è valutare se le percentuali di successo e di sopravvivenza di impianti singoli, multipli e riabilitazioni full-arch siano ridotte in pazienti con patologie sistemiche.*

*L'OMS considera l'edentulia come una forma di compromissione fisica, dal momento che i pazienti affetti da tale patologia sono parzialmente impossibilitati nello svolgere attività fondamentali per la loro sopravvivenza.*

*L'utilizzo di riabilitazioni implanto-protesiche fisse potrebbe essere in grado di migliorare la qualità della vita di questi soggetti dal punto di vista fisico, psicologico e sociale.*

## MATERIALI E METODI

*Per questo studio sono stati selezionati pazienti edentuli che necessitavano di una riabilitazione implanto-protesica,*

*affetti da una delle seguenti patologie diagnosticcate: malattie cardiovascolari, diabete di tipo I e II, sindrome di Sjögren, osteoporosi e artrite reumatoide. I pazienti in terapia con farmaci anti-riassorbitivi non sono stati inclusi nella seguente analisi.*

*In totale sono stati selezionati 90 pazienti, suddivisi in tre sottogruppi in base al tipo di riabilitazione implanto-protesica eseguita: singola (impianto singolo), parziale (settoriale) e full-arch (intera arcata). Complessivamente sono stati estratti 298 elementi dentali hopeless. A 3 mesi dall'estrazione, 190 impianti dentali (Winsix Implant System, Biosafin, Ancona) sono stati posizionati nei siti edentuli, seguendo un protocollo di carico differito. I parametri clinici perimplantari e i livelli di osso marginale, misurati confrontando radiografie endorali, sono stati valutati a 6, 12, 24, 36 e 60 mesi dal posizionamento implantare.*



## STUDIO PROSPETTICO

## RISULTATI

*Nello studio sono stati inclusi 90 pazienti, a cui sono state effettuate complessivamente 298 estrazioni dentarie. Al follow-up a 5 anni il tasso di sopravvivenza implantare è stato di 94,21% con 11 fallimenti implantari dei 190 posizionati. Per quanto riguarda il gruppo con riabilitazione full-arch il tasso di sopravvivenza implantare è stato più alto, pari a 97,62% con 2 fallimenti su 84 impianti posizionati. L'analisi delle radiografie endorali ha rivelato una perdita di osso marginale medio di  $1,54 \pm 0,66$  mm.*

## CONCLUSIONI

*Entro i limiti del presente studio e alla luce dei risultati ottenuti, sembrerebbe che la chirurgia implantare in pazienti affetti da alcune patologie sistemiche possa essere considerata una procedura sicura e predicibile, al pari di altre categorie di pazienti.*

*Il tasso di sopravvivenza implantare, infatti, è stato > 90% in tutte e tre le categorie riabilitative (impianto singolo, riabilitazione settoriale, riabilitazione full-arch).*

*Rimane, tuttavia, fondamentale identificare e correggere gli eventuali fattori di rischio modificabili (quali fumo e scarsa igiene orale), programmando rigorose sedute di follow-up.*

## INTRODUZIONE

Lo scopo del presente studio consiste nel valutare il tasso di sopravvivenza delle riabilitazioni implanto-protesiche in pazienti affetti da patologie sistemiche. Studi scientifici hanno mostrato risultati contrastanti per quanto riguarda il successo, a medio e lungo termine, di riabilitazioni implanto-protesiche in pazienti affetti da patologie sistemiche (1-4).

Secondo l'Organizzazione Mondiale della Sanità (OMS) il numero di pazien-

ti geriatrici è destinato ad aumentare nei prossimi decenni in tutto il mondo (5); l'invecchiamento della popolazione è accompagnato da un inevitabile aumento del carico delle patologie sistemiche.

L'edentulia, parziale o totale, è, a sua volta, destinata ad aumentare con l'aumento della popolazione anziana. L'OMS considera l'edentulia una patologia invalidante e i pazienti affetti come portatori di handicap, in quanto la loro capacità di svolgere attività fondamentali per la vita è severamente compromessa. Risulta quindi fondamentale intervenire su pazienti affetti da patologie sistemiche ed affetti da edentulia, con lo scopo di migliorare la loro qualità di vita.

Il trattamento implanto-protesico può fornire beneficio a soggetti edentuli migliorando il loro benessere dal punto di vista fisico, psicologico e sociale.

## MATERIALI E METODI

In questo studio sono stati selezionati pazienti parzialmente o completamente edentuli che necessitavano di una riabilitazione implanto-protesica e che erano affetti da una patologia sistemica monitorata. Le condizioni sistemiche prese in considerazione sono state le seguenti: patologie cardiovascolari, diabete di tipo I e II, sindrome di Sjögren, osteoporosi e artrite reumatoide. Sono stati esclusi da questo studio i soggetti in terapia con bifosfonati, anticorpi monoclonali (come il Denosumab) e farmaci anti-riassorbitivi in genere.

In totale sono stati analizzati 90 pazienti, suddivisi in 3 categorie a seconda delle procedure chirurgiche attuate e della loro invasività: riabilitazioni implantari singole, settoriali e full-arch. Complessivamente, sono stati estratti 298 elementi dentali hopeless e, a guarigione alveolare avvenuta (almeno 3 mesi), si è programmato l'intervento di posizionamento implantare.

Il giorno dell'intervento, previa profilassi antibiotica somministrata 1 ora prima della procedura chirurgica (con 2 compresse di amoxicillina 875 mg + acido clavulanico 125 mg), in anestesia locale (articaina 40 mg/ml 1:100.000 adrenalina) sono state eseguite le fasi di incisione del lembo, scollamento a spessore totale e osteotomia del sito implantare al fine di poter inserire impianti di diametro minimo pari a 3,3 mm e lunghezza minima pari a 9 mm. Gli impianti inseriti (serie TTx o TTI, Winsix implant System, Biosafin, Ancona) avevano un torque implantare superiore a 30 Ncm. Il protocollo perseguito è stato quello di una procedura chirurgica bifasica a carico differito. Quindi, al termine delle procedure chirurgiche di posizionamento implantare, le rispettive viti-tappo sono state posizionate e i lembi chirurgici accostati attraverso l'utilizzo di sutura 3/0 in seta, con il fine di ottenere una guarigione per prima intenzione.

Tutti i pazienti sono rivisti a 7 giorni dall'intervento chirurgico, per valutare l'iniziale guarigione ed effettuare la rimozione suture.

Il tasso di sopravvivenza implantare è stato stimato a 5 anni, attraverso controlli clinici periodici ed esami radiografici (rx endorali periapicali). I livelli di osso marginale sono stati misurati ponendo a confronto radiografie endorali eseguite a 6, 12, 24, 36 e 60 mesi dal posizionamento delle fixture implantari.

## RISULTATI

In questo studio sono stati inclusi 90 soggetti ai quali sono state effettuate complessivamente 298 estrazioni e inseriti 190 impianti dentali. Al follow-up a 5 anni il tasso di sopravvivenza implantare è stato del 94,21% con 11 fallimenti implantari. Il tasso di sopravvivenza implantare nel gruppo

## STUDIO PROSPETTICO

Livello osseo marginale	Riabilitazioni implantari singole	Riabilitazioni implantari multiple	Riabilitazioni full arch
6 mesi	1.20 ± 0.32 mm	1.41 ± 0.41 mm	1.21 ± 0.31 mm
12 mesi	1.14 ± 0.21 mm	1.52 ± 0.21 mm	1.15 ± 0.35 mm
24 mesi	1.25 ± 0.45 mm	1.67 ± 0.32 mm	1.25 ± 0.41 mm
36 mesi	1.31 ± 0.69 mm	1.83 ± 0.56 mm	1.21 ± 0.61 mm
60 mesi	1.38 ± 0.71 mm	1.89 ± 0.64 mm	1.35 ± 0.63 mm

Tab. 1 | dati inerenti alle variazioni ossee marginali a 6, 12, 24, 36 e 60 mesi, nei tre sottogruppi.

delle riabilitazioni full-arch è stato del 97,62% per un totale di 2 fallimenti implantari su 84.

L'analisi radiologica endorale rivela una perdita d'osso marginale media di  $1,54 \pm 0,66$  mm nei follow-up a 5 anni. I dati inerenti alle variazioni ossee marginali a 6, 12, 24, 36 e 60 mesi, nei tre sottogruppi, sono riassunti in tabella 1. Nei pazienti cardiopatici in terapia anticoagulante non si sono verificate problematiche di emorragia intra o postoperatoria e il tasso di sopravvivenza implantare è stato del 98%. Nonostante ci sia un alto rischio di fallimento implantare nei pazienti diabetici, ottimizzando il controllo glicemico è stato riscontrato un miglioramento nella guarigione ossea, permettendo a questo gruppo di pazienti di avere un rischio di fallimento sovrapponibile a quello riscontrato nella popolazione sana.

## CONCLUSIONI

Dai risultati ottenuti in questo studio si evince che attenendosi ad uno specifico programma di cure postoperatorio, un soddisfacente tasso di sopravvivenza può essere ottenuto anche in soggetti con patologie sistemiche.

Questo studio sembra suggerire che al fine di ottenere dei risultati soddisfacenti sia fondamentale sottoporre i pazienti a periodiche sedute di igiene orale professionale e istruirli alle corrette manovre di igiene orale domiciliare. Risulta, inoltre, fondamentale attuare

una gestione multidisciplinare del paziente sistemico con lo scopo di valutare eventuali controindicazioni dei farmaci assunti con i processi biologici di osteointegrazione.

Entro i limiti di questo studio i risultati ottenuti sembrano suggerire che le riabilitazioni implanto-protesiche in pazienti affetti da patologie sistemiche non peggiorino le loro condizioni di salute generale ma siano in grado di garantire ottimi risultati clinici; questo tipo di riabilitazioni possono quindi essere considerate procedure sicure e predicibili nel tempo.

Si conclude che il tasso di sopravvivenza implantare in pazienti sistemici non è quindi indice di controindicazione assoluta o relativa per la chirurgia implantare, come suggerito da alcuni studi scientifici (1,2); risulta però fondamentale individuare e agire su tutti i fattori di rischio modificabili che possono causare fallimento implantare (scarsa igiene orale, fumo e glicemia non controllata). ●

## DENTAL IMPLANTS IN PATIENTS AFFECTED BY SYSTEMIC DISEASES: A 5-YEAR PROSPECTIVE LONGITUDINAL STUDY

### Abstract

#### Aim of the work

The objective of this study was to evaluate if success and survival rates of single implants, multi-implants and full-arch implant rehabilitations are

reduced in patients with compromised medical conditions. The World Health Organization (WHO) considers edentulism to be a form of physical impairment because edentulous patients are impaired, in their ability to perform fundamental life tasks; these problems should be avoided by individuals who already suffer from other diseases. The number of geriatric patients is expected to grow within the next decades, according to WHO statistics. The use of fixed implant-supported rehabilitation may provide benefits to this kind of patients, improving their physical, psychological and social situation.

#### Materials and methods

For this study edentulous patients requiring implant-prosthetic rehabilitation were selected. In order to be eligible for this study, the subjects had to be affected by one of the following controlled systemic diseases, as cardiovascular diseases, diabetes type I, Sjogren's syndrome, osteoporosis and rheumatoid arthritis. Patients under bisphosphonates therapy were not included in the study. The ninety patients selected for this study were divided into three groups based on surgical invasiveness: single implant rehabilitation, multiple implant rehabilitation and full arch rehabilitation. After 3 months from extracting of 298 hopeless teeth, 190 dental implants (Winsix implant System, Biosafin, Ancona, Italy) were

## STUDIO PROSPETTICO

placed in edentulous sites and a delayed loading protocol was followed. Marginal bone levels and clinical parameters, measured comparing intraoral digital x-rays, were evaluated at 6, 12, 24 and 36 months after implant placement.

**Results**

A total of 298 hopeless teeth on 90 patients enrolled in this study. At 5 years follow-up, overall survival rate was 94,21 % with 11 implant failures. Considering the full arch rehabilitation group, survival rate was higher, 97,62 % with 2 implant failures out of 84. Intraoral x-rays analysis revealed a mean marginal bone loss of  $1,54 \pm 0,66$  mm at 5-year follow-up.

**Conclusions**

According with this study, and within

its limitations, the placement of dental implants in systemic patients seems to be a predictable and safety treatment option.

The survival rate of dental implants placed in systemic patients was >90% in the three groups (single implant, multi-implants and full-arch rehabilitation). It's important to identify and address modifiable risk factors for implant failure (smoking, poor oral hygiene) and schedule strict follow-up visits.

**Keywords**

Implantology, systemic disease, full-arch rehabilitation, diabetes.

**Bibliografia**

1. Carr AB; Revuru VS, Lohse CM. Association

of systemic conditions with dental implant failures in 6.384 patients during a 31-year follow-up period. *Int.J.Oral.Maxillofac:Implants.* 2017;32(5):1153-1161.

2. Guobis Z, Pacauskiene I, Astramskaite I. General Diseases Influence on Peri-Implantitis Development: a Systematic Review. *J Oral Maxillofac Res.* 2016 Sep 9;7(3):e5. doi: 10.5037/jomr.2016.7305. PMID: 27833730; PMCID: PMC5100645.
3. Vissink A, Spijkervet F, Raghoobar GM. The medically compromised patient: Are dental implants a feasible option? *Oral Dis.* 2018 Mar;24(1-2):253-260. doi: 10.1111/odi.12762. PMID: 29480621.
4. Okamoto T, Hoshi K, Fukada K, Kataoka, Kumasaka A, Kaibuchi N, Fukuzawa S, Ando T. Factors Affecting the Occurrence of Complications in the Early Stages After Dental Implant Placement: A retrospective Cohort Studi. *Implant Dent.* 2018 Mar 19. doi:10.1097
5. Rudnicka E, Napierała P, Podfigurna A, Męćzekalski B, Smolarczyk R, Grymowicz M. The World Health Organization (WHO) approach to healthy ageing. *Maturitas.* 2020 Sep;139:6-11. doi: 10.1016/j.maturitas.2020.05.018. Epub 2020 May 26. PMID: 32747042; PMCID: PMC7250103.

## Riabilitazione impianto protesica: case report

MANUEL CARDILI\*, GRETA TOMA\*, PAOLO BISI\*, CHIARA DAL POS\*, CHIARA DE RUBERTIS\*, FRANCESCA PANERAI\*

\*Dipartimento di Odontoiatria, IRCCS Ospedale San Raffaele, Milano (Direttore Prof. E. Gherlone)

### RIASSUNTO

**Obiettivo** Questo case report descrive una riabilitazione impianto-protetica al primo sestante, prevedendo un'estrazione degli elementi naturali con compromissione radicolare e il successivo inserimento di due impianti con l'ausilio di moderne tecnologie, come la Cone Beam Computed Tomography (CBCT) e di software dedicati per la pianificazione implantare.

**Materiali e metodi** Un paziente di 58 anni si presenta in prima visita per dolore ricorrente nel primo sestante. Si è eseguita un'attenta valutazione del caso attraverso l'anamnesi medico-odontoiatrica, l'esame obiettivo e esami radiografici di primo livello, in cui si sono evidenziati sondaggi profondi a carico degli elementi 1.4, 1.5 e 1.6 e fratture radicolari a carico degli elementi 1.4 e 1.6. Si è programmata, pertanto, l'estrazione di tali elementi per una successiva riabilitazione impianto-protetica. Eseguite le estrazioni, a distanza di 6 mesi, si è eseguita una CBCT per valutare la guarigione ossea e progettare il successivo intervento chirurgico.

Dalla valutazione dell'intervento, avvenuta tramite CBCT, si è deciso l'inserimento di due impianti in sede 14 e 16. Il giorno dell'intervento, previa firma del consenso informato e profilassi antibiotica, si è proceduto in anestesia locale ad un'incisione crestale dall'elemento 13 all'elemento 17. Successivamente, si sono preparati i siti implantari per l'inserimento di un impianto TTI 3.8X11 in sede 14 e impianto TTI 4.5X9 in sede 16. Terminato l'intervento sono stati posizionati 3 punti di sutura semplici e uno incrociato con sutura 3/0 seta.

**Risultati** alla visita di controllo, avvenuta a 3 mesi dall'intervento si è ottenuta l'osteointegrazione degli impianti, una corretta guarigione dei tessuti molli e un aumento della quota di gengiva cheratinizzata.

**Conclusioni** Le nuove tecnologie possono essere di aiuto non solo agli odontoiatri più esperti, per eseguire interventi complessi con maggior sicurezza, ma anche agli odontoiatri meno esperti, per eseguire una corretta diagnosi e pianificazione del piano di trattamento e dell'intervento chirurgico.

**KEYWORDS** Riabilitazione implantare, CBCT

### INTRODUZIONE

Per un odontoiatra è fondamentale capire le richieste e le esigenze del paziente, avendo le conoscenze e gli strumenti adeguati per effettuare un corretto piano di trattamento e diagnosi da poter proporre nella stessa seduta al paziente.

La terapia implantare al giorno d'oggi è un trattamento sempre più diffuso e predicibile, soprattutto se affiancato a strumenti di diagnosi e di progettazione adeguati.

### MATERIALI E METODI

Un paziente di 58 anni si è presentato presso la nostra struttura per una prima visita, in quanto da diversi mesi percepiva un dolore intermittente localizzato nel primo sestante. Al quesito anamnestico non sono state sottolineate criticità. Ad una prima valutazione extra orale non si sono evidenziate tumefazioni o edemi nell'area interessata e in altre zone. In una successiva valutazione intra orale, si è evidenziato una scarsa igiene orale con presenza di tartaro, sanguinamento al sondaggio, infiammazione diffusa dei tessuti e sondaggio puntiforme negli elementi 14, 15 e 16. Successivamente, alla valutazione radiografica della ortopantomografia, si sono riscontrate diverse zone di riassorbimento osseo e tartaro. Al paziente sono state evidenziate tutte le problematiche, le possibili complicanze e i diversi piani di cura da poter adottare. Il paziente ci riferisce di voler prima risolvere il dolore ricorrente nel primo sestante mediante l'estrazione degli elementi 14, 15, 16 con la successiva riabilitazione impianto protesica con carico differito, e solo successivamente continuare le cure necessarie e consigliate. Pertanto, è stata prescritta una terapia antibiotica con 2 compresse di amoxicillina + acido clavulanico 875 mg + 125 mg per 6 giorni. Successivamente si è proceduto all'estrazione degli elementi dentari. A distanza di 3 mesi dalle estrazioni, è stata effettuata una visita di controllo e una Cone Beam Computed Tomography (CBCT) per valutare lo stato di guarigione dei tessuti molli e duri, oltre che la valutazione e pianificazione dell'intervento chirurgico per l'inserimento degli impianti. Grazie all'impiego della CBCT e di software dedicati, si è riusciti a misurare la quantità



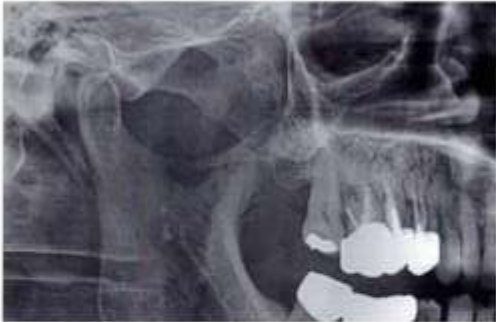

FIG. 1 OPT del primo sestante in prima visita.

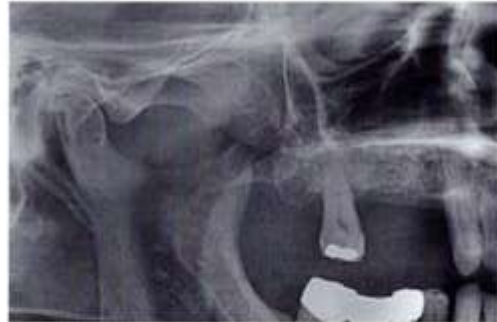

FIG. 2 OPT di controllo pre intervento implantare per la valutazione dello stato di guarigione ossea post estrazione

ossea disponibile e a simulare la posizione degli impianti al fine di minimizzare il rischio di complicanze intra e post operatorie. Per questo caso abbiamo riscontrato la possibilità di inserire un impianto in sede 14 con lunghezza fino a 11mm e un impianto in sede 16 con lunghezza fino a 9mm.

Una volta pianificato l'intervento, sono state fornite al paziente tutte le indicazioni pre operatorie insieme alla prescrizione antibiotica con 2 compresse di amoxicillina 875 mg al giorno, a partire dalla sera prima dell'intervento.

Il giorno dell'intervento, previa firma del consenso informato e presa visione dei comportamenti da adottare successivamente all'intervento, si è proceduto all'esecuzione dell'anestesia locale con articaina.

Verificata la corretta presa dell'anestetico sulla zona interessata, si è proceduto ad un'incisione crestale a tutto spessore con bisturi e lama 15C, dall'elemento 13 all'elemento 17 e allo scollamento del lembo. Innanzitutto, è stata preparata la sede implantare in sede 14 ed inserito impianto Winsix TTI 3.8X11. Successivamente è stato posizionato l'impianto Winsix TTI 4.5X9 in sede 16.

Nonostante il torque di inserimento sia stato superiore ai 30N per entrambi gli impianti, si è comunque preferito procedere con un carico differito.

Infine, è stato posizionato un punto di sutura semplice distale all'elemento 13, un punto semplice mesiale all'elemento 17, un punto semplice e un punto incrociato tra i due impianti.

Non è stata effettuata la passivizzazione dei lembi per ottenere il loro accostamento e la guarigione di prima intenzione, ma si è ricercata una guarigione per seconda intenzione al fine di aumentare la quota di gengiva cheratinizzata circostante gli impianti.

## RISULTATI

Alla visita di controllo a 3 mesi dall'intervento, la guarigione dei tessuti molli risulta ottimale, con un aumento

della quota di gengiva cheratinizzata perimplantare e dall'esame radiografico si evince l'avvenuta osteointegrazione degli impianti, senza un riassorbimento osseo a livello del colletto coronale implantare.

## DISCUSSIONI E CONCLUSIONE

L'impiego della CBCT durante la programmazione implantare, aiuta nella programmazione del posizionamento della fixture, agevolando la stesura di un piano di trattamento che sia il meno invasivo possibile e il più predicibile possibile. Le tecnologie oggi disponibili, permettono, sia ad odontoiatri esperti che neofiti, di eseguire interventi con maggior sicurezza, grazie alla possibilità di studiare le strutture anatomiche e le sue varianti, oltre a pianificare l'intervento minimizzando le possibili complicazioni intra e post operatorie.

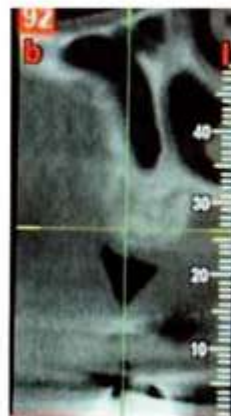


FIG. 3 Cross section sede 1.4.

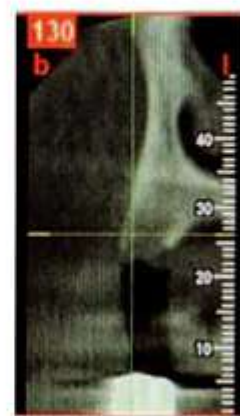


FIG. 4 Cross section sede 1.6.

JO

Riabilitazione impianto protesica: case report

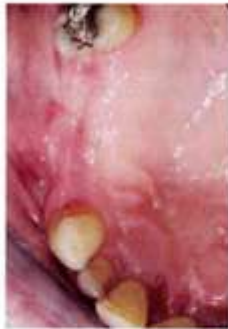

FIG. 5 Foto pre chirurgica in cui è possibile osservare la cicatrice di guarigione.

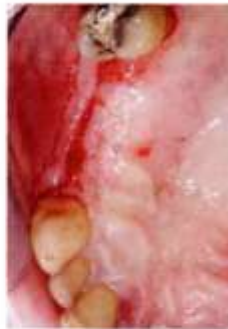

FIG. 6 Incisione crestale e scollamento a tutto spessore.

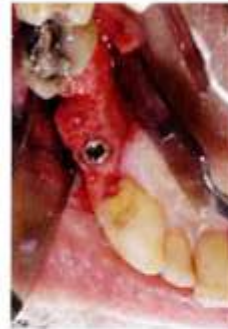

FIG. 7 Inserimento impianto sede 1.4.

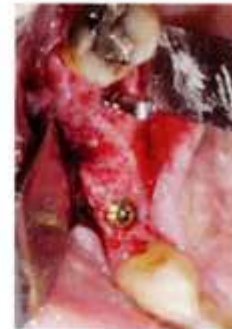

FIG. 8 Inserimento pin sede 1.6.



FIG. 9 Foto inserimento due impianti.

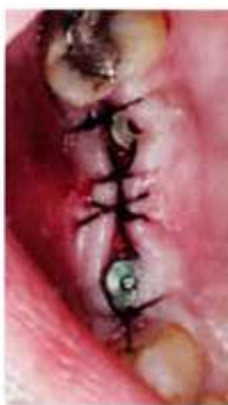

FIG. 10 Sutura.

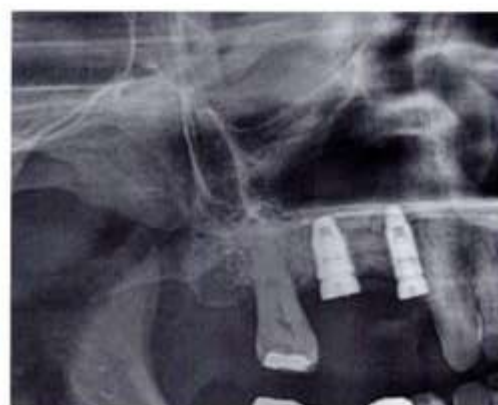

FIG. 11 OPT post intervento.

Per gli interventi di implantologia le immagini cross ottenute tramite la CBCT permettono, grazie ad un'alta accuratezza delle immagini, di valutare:

- Difetti ossei e siti di prelievo intraorale.
- Lo stato di salute del seno mascellare.
- Il seno mascellare e individuazione di canali arteriosi nella parete laterale del seno.
- La quantità di osso residuo, sia in senso verticale, per calcolare la profondità massima di preparazione del sito implantare e la successiva fixture, che in senso orizzontale, per calcolare il diametro massimo degli impianti.
- La qualità e densità ossea.
- Il corretto asse d'inserzione implantare.

È fondamentale conoscere e rimanere aggiornati sulle nuove tecnologie che di anno in anno sono sempre più presenti nel lavoro quotidiano di un odontoiatra. Le nuove tecnologie però non possono e non devono sostituire le conoscenze e l'esperienza dell'odontoiatra, ma

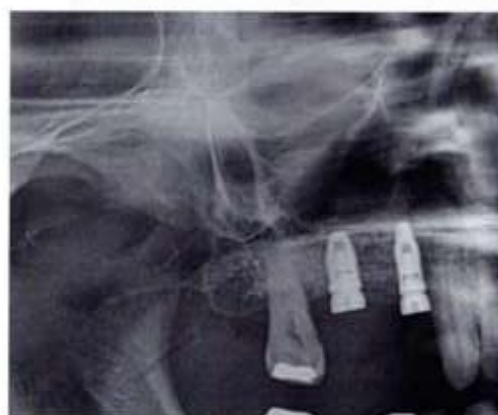

FIG. 12 OPT a 3 mesi.

Cardilli M. et al.

devono saper essere impiegate nei casi in cui offrono effettivamente un aiuto al clinico.

### ABSTRACT

**Aim** This case report describes an implant-prosthetic rehabilitation of the first quadrant, with extractions of the natural elements with root compromise and subsequent placement of two implants using modern technologies such as Cone Beam Computed Tomography (CBCT) and dedicated software for implant planning.

**Materials and methods** An 58-year-old patient presented at the first visit for recurrent pain in the first sector. A careful evaluation of the case was performed through medical-dental history, objective examination and first radiographic examinations, in which punctiform probing and root fractures were revealed in elements 14, 15 and 16. Therefore, the extraction of these elements and subsequent implant-prosthetic rehabilitation was decided. After the extractions were performed 6 months apart, CBCT was performed to assess bone healing and plan the subsequent surgery.

From the evaluation of the surgery by CBCT, it was decided to place two implants at site 14 and 16. On the day of surgery after signing informed consent and antibiotic prophylaxis, a crestal incision from element 13 to element 17 was performed under local anesthesia. Subsequently, implant sites were prepared for the insertion of a 3.8X11 TTI implant in site 14 and 4.5X9 TTI implant in site 16. After the surgery was finished, 3 simple sutures and one crossed suture with 3/0 silk were placed.

**Results** At the follow-up visit 3 months after surgery, osseointegration

of the implants, proper soft tissue healing, and an increase in the proportion of keratinized gingiva were obtained.

**Conclusions** New technologies can help not only more experienced dentists to perform complex procedures with greater confidence but also less experienced dentists to perform proper diagnosis and planning of the treatment plan and surgery.

**KEYWORDS** Riabilitazione implantare, CBCT

### BIBLIOGRAFIA

1. «Antibiotici e implantologia: un'associazione necessaria?», il dentista moderno, 2012.
2. J. Reinhold, S. Benjamin, M. Codari, H. Bassam e M. M. Bornstein, «Cone beam computed tomography in implant dentistry: recommendations for clinical use.» BMC Oral Health, 2018 May.
3. V. D. Stelt, «Oral and maxillofacial radiology: laws and regulations,» Ned Tijdschr Tandheelkd, 2015.
4. Z. Zheng, A. Xiaogang, X. Peng, J. Fan e C. Wenchuan, «The biological width around implant,» J Prosthodont Res, 2021.
5. R. Vinci, F. Bova, E. Gherlone e M. Manacorda, «Pianificazione implantoprotesica digitale. Progettazione e realizzazione di riabilitazioni "full arch" a carico immediato,» DoctorOS, 2016.
6. E. Gherlone, Riabilitazioni implantoprotesiche e Chirurgia minimamente invasiva, Comar Ariesdue Ed., 2013.
7. M. Manacorda, R. Vinci, F. Bova, M. Nagni e E. Gherlone, «Riabilitazione dei mascellari edentuli: presentazione di una nuova tecnica software assistita,» DoctorOS, 2013.



## FOCUS ON CHIRURGIA ORALE

## Riabilitazione mascellare e mandibolare completa a carico immediato su quattro impianti in età avanzata: studio retrospettivo follow-up a 8 anni



Martina Longoni\*, Luisa Paternoster\*,  
Tanya Arduini\*, Greta Toma\*, Lorenzo Franceschi\*

\*  
Odontoiatra, Dipartimento di Odontoiatria, IRCCS  
Ospedale San Raffaele, Milano (Direttore prof. E.  
Gherlone)

## PAROLE CHIAVE

Sopravvivenza implantare in pazienti in età  
avanzata, carico immediato, riabilitazioni in  
mascellare edentulo

## SCOPO DEL LAVORO

L'obiettivo del presente studio è quello di valutare che effetto abbia l'età sulla sopravvivenza implantare in pazienti che hanno effettuato delle riabilitazioni implantoprotetiche con quattro impianti (in mandibola o nel mascellare superiore) a carico immediato con follow up a 8 anni.

## MATERIALI E METODI

Sono stati inseriti nel protocollo pazienti che necessitavano di una riabilitazione implantoprotetica supportata da quattro impianti con età pari o superiore a 70 anni.

Sono stati analizzati come parametri la percentuale di sopravvivenza implantare e le complicanze protesiche. Tutti i pazienti sono stati inseriti in un protocollo di igiene professionale.

## RISULTATI

Sono stati inclusi nello studio 12 pazienti per un totale di 48 impianti. In un solo caso è stata riscontrata una mancanza di osteointegrazione ed è stato registrato come fallimento implantare. La percentuale totale di sopravvivenza implantare è stata del 97,91%.

Si è verificata una sola frattura protesica nell'arcata provvisoria e due chipping della protesi definitiva.

## CONCLUSIONI

Nel corso degli 8 anni di follow-up la sopravvivenza implantare in pazienti con età maggiore o uguale a 70 anni si è dimostrata in linea con la letteratura. Questo protocollo, quindi, risulta essere un'opzione terapeutica anche per pazienti più anziani con età superiore a 70 anni.

## INTRODUZIONE

Secondo i dati Istat, in Italia, un quarto della popolazione è rappresentata da ultrasessantacinquenni e, nel 2050, gli anziani over 65 saranno 20 milioni di persone, ovvero un terzo della popolazione e di questi, 4 milioni avranno più di 85 anni. Ciò determina un inevitabile cambiamento delle esigenze della popolazione, soprattutto di quella più anziana. L'invecchiamento fisiologico comporta anche la perdita degli elementi dentali e questo impatta negativamente sulla qualità della vita.

Gli impianti endossei come opzione terapeutica risultano quindi essere una necessità crescente a causa della maggior longevità della popolazione (1).

La letteratura non è però univoca nel valutare la correlazione tra l'osteointegrazione degli impianti e l'avanzamento anagrafico.

Lo studio Cáceres M. et al. ha esami-



## FOCUS ON CHIRURGIA ORALE

nato le risposte cellulari associate alla guarigione delle ferite gengivali nell'invecchiamento, affermando che la migrazione cellulare, la differenziazione miofibroblastica, il rimodellamento di collagene e la proliferazione sono diminuiti nei fibroblasti invecchiati. Inoltre, la migrazione cellulare alterata nella guarigione delle ferite può essere attribuibile non solo a difetti cellulari ma anche a cambiamenti nei fattori sierici associati al processo di senescenza (2).

Invece, secondo altri autori, sembra essere di più la struttura protesica a influenzare negativamente l'osteointegrazione a lungo termine e non il processo di invecchiamento stesso che, secondo Bertl et al., non sembra compromettere l'osteointegrazione se non in stati avanzati (3, 4). Anche in una revisione di Srinivasan et al. è riportato un tasso di sopravvivenza implantare di 97,7% nella popolazione più anziana (5), così come altri studi evidenziano che non ci sono differenze statisticamente significative (6). Tuttavia, le riabilitazioni implantoprotesiche sono considerate un'opzione terapeutica altamente predicibile e soddisfacente in pazienti edentuli (7).

## MATERIALI E METODI

## Selezione del paziente

Sono stati inclusi nel presente studio tutti quei pazienti che necessitavano di una riabilitazione full-arch sia in mandibola che in mascella e rientrassero nei seguenti criteri:

- edentulismo totale o parziale (con elementi dentali definiti hopless);
- grave atrofia mascellare/mandibolare posteriore causata da riassorbimento osseo orizzontale e verticale;
- volume osseo mascellare/mandibolare anteriore adeguato;
- età  $\geq 70$  anni;
- tutti i pazienti dovevano essere indipendenti nelle attività quotidiane, comprendere le tecniche di igiene domestica, mantenere l'igiene professionale nel tempo.

## Criteri di esclusione

- Scarsa igiene orale
- Immunosoppressione
- Diabete incontrollato
- Terapia attiva con bifosfonati
- Fumo ( $> 20$  sigarette/giorno)
- Radioterapia alla testa e al collo entro 5 anni
- Abitudini parafunzionali (bruxismo, serramento)
- Infezione attiva nell'area di posizionamento dell'impianto proposto.

Tutti i pazienti sono stati valutati radiograficamente attraverso un'ortopantomografia e tomografia computerizzata cone beam (CBCT) per valutare il volume osseo residuo.

Ogni paziente dello studio ha ricevuto una spiegazione dettagliata delle varie alternative terapeutiche disponibili per la riabilitazione mascellare e mandibolare e un'attenta analisi rischio-beneficio per ciascuna strategia.

Successivamente, da ciascun paziente è stato ottenuto un dettagliato consenso informato scritto per questo protocollo terapeutico con il dettaglio delle varie fasi chirurgiche e protesiche, a seguito del quale sono state prese le impronte convenzionali per i modelli di studio e le protesi provvisorie.

## Protocollo

Tutte le chirurgie sono state eseguite da un solo operatore. Il giorno della chirurgia al paziente è stata somministrata 1 ora prima dell'intervento la profilassi antibiotica (2 g di amoxicillina + acido clavulanico; oppure in soggetti allergici 500 mg di claritromicina).

In seguito ad anestesia locale (opticalina 20 mg/ml con adrenalina 1:80000) è stata eseguita un'incisione in cresta con due incisioni di scarico distali in modo da poter elevare un lembo a tutto spessore. Successivamente è stata effettuata un'osteoplastica per regolarizzare la cresta e sono stati inseriti quattro impianti (TTx, WinSix®, BioSAFin, Ancona, Italia). I due impianti posteriori sono

stati posizionati con un angolo di circa 25-30 gradi rispetto al piano occlusale, emergendo in corrispondenza del secondo premolare per ridurre la lunghezza del cantilever e mantenere un'adeguata distanza inter-impianto. I due impianti anteriori invece sono stati posizionati assialmente.

L'inserimento dell'impianto ha seguito le procedure standard (Winsix®, Biosafin) ottenendo un torque di inserzione compreso tra 30 e 40 N-cm in modo da ottenere un'elevata stabilità primaria e poterli protesizzare immediatamente.

Per poter raggiungere l'emergenza protesica desiderata sono stati inseriti degli abutment angolati (Extreme Abutment, EA® WinSix, BioSAFin). Infine, è stato riposizionato il lembo mediante suture riassorbibili 4/0 (Vicryl; Ethicon®, Johnson & Johnson, New Brunswick, NJ, USA).

Infine, è stata consegnata al paziente la protesi provvisoria entro le 24h dal posizionamento implantare.

## Follow-up

Le visite di follow-up sono state eseguite a 3 e 6 mesi e poi annualmente fino al follow-up di 8 anni dopo l'inserimento dell'impianto. Ogni 6 mesi dopo il posizionamento dell'impianto, un igienista dentale ha eseguito procedure di igiene orale e registrato i parametri clinici, inclusi l'indice di sanguinamento, l'indice di placca e la profondità di sondaggio intorno agli impianti.

## RISULTATI

Sono stati inclusi nello studio 12 pazienti per un totale di 48 impianti.

In un solo caso è stata riscontrata una mancanza di osteointegrazione dopo 2 mesi dalla chirurgia ed è stato registrato come fallimento implantare. La percentuale totale di sopravvivenza implantare è stata del 97,91%.

Per quanto concerne le complicanze protesiche, invece, si è verificata una sola frattura protesica nell'arcata prov-

## FOCUS ON CHIRURGIA ORALE

visoria e due chipping della protesi definitiva.

## DISCUSSIONE

Questo studio, confrontando i dati in letteratura, non riporta differenze legate all'età nella sopravvivenza dell'impianto durante il follow-up di 8 anni in 12 pazienti che hanno ricevuto riabilitazione implantoprotesiche con carico immediato di 4 impianti. In letteratura non sono presenti molti dati riguardanti le riabilitazioni dell'intera arcata con carico immediato in una popolazione anziana (>70 anni) nonostante questa metodologia riabilitativa sia ampiamente accettata dalla letteratura scientifica (8).

Il presente studio ha mostrato che la riabilitazione fissa a carico immediato, mediante il posizionamento di due impianti anteriori assiali e due posteriori inclinati, è una procedura adeguata, riportando un tasso di sopravvivenza totale dell'impianto del 97,91%.

Ci sono due diverse opinioni sulla sopravvivenza implantare: Muller et al. afferma che la riabilitazione implantare dovrebbe essere limitata ai pazienti con una buona igiene orale e senza cattive abitudini (9), così come Gherlone E. F. et al. sottolineano l'importanza dell'igiene orale a lungo termine (10). Srinivasan et al. invece sottolineano tutti quei fattori da considerare nei pazienti più anziani, come per esempio la guarigione ossea che potrebbe influenzare l'osteointegrazione e anche il biofilm orale alterato nell'invecchiamento.

## CONCLUSIONI

La riabilitazione implantoprotesica a carico immediato rappresenta una valida opzione terapeutica anche in pazienti con età maggiore di 70 anni. Pertanto, sulla base dei risultati di questo studio e con i limiti a esso associati, l'età è considerata solo una variabile secondaria per le riabilitazioni full-arch, rispetto allo stato di igiene

orale e alle cattive abitudini orali dei pazienti. Sono necessari ulteriori studi per valutare con un follow-up più lungo il tasso di complicità. ●

## REHABILITATION WITH IMMEDIATE LOADING OF FOUR IMPLANTS IN ELDERLY PATIENTS: AN 8-YEAR RETROSPECTIVE STUDY

## Abstract

## Aim of the work

*The aim of this study was to evaluate in an 8-year follow-up the influence of patient's age on implant survival when rehabilitation was performed using four immediately loaded dental implants.*

## Materials and methods

*Patients aged 70 years or older who needed an implant-prosthetic rehabilitation supported by four implants were included in this study. All patients were enrolled in a professional hygiene protocol. Implant survival rate and prosthetic complications were analyzed.*

## Results

*Twelve patients were included in the study and a total of 48 dental implants were placed. Lack of osseointegration was observed in only one case, which was recorded as implant failure. Thus, the survival rate was 97.91%. Considering the prostheses, one fracture was observed in the temporary prosthesis whereas two chipping were found in the definitive ones.*

## Conclusions

*During this 8-year follow-up, the implant survival rate in patients aged 70 years or older was in accordance with the literature. Based on these results, rehabilitation with immediately loaded dental implants represents a valuable therapeutic option also for older patients.*

## Keywords

*Implant survival rate in elderly patients,*

*immediate loading, rehabilitations in edentulous maxilla*

## Bibliografia

1. Tetè, G et al. "How to consider implant-prosthetic rehabilitation in elderly patients: a narrative review." *Journal of biological regulators and homeostatic agents* vol. 35,4 Suppl. 1 (2021): 119-126. doi:10.23812/21-4suppl-11
2. Cáceres, M et al. "Defective Wound-healing in Aging Gingival Tissue." *Journal of dental research* vol. 93,7 (2014): 691-7. doi:10.1177/0022034514533126
3. Bertl K, Ebner M, Knibbe M, Pandis N, Kuchler U, Ulm C, Stavropoulos A. How old is old for implant therapy in terms of early implant losses?. *Journal of Clinical Periodontology*. 2019 september. doi: 10.1111/JCPE.13199
4. Papez J, Dostálová T, Chleborád K, Kríz P, Strnad J. Chronological age as factor influencing the dental implant osseointegration in the jaw bone. *Prague Medical Report/Vol. 119 (2018) No. 1, p. 43-51. Doi: 10.14712/23362936.2018.4*
5. Srinivasan M, Meyer S, Mombelli A, Muller F. Dental implants in the elderly population: a systematic review and meta-analysis. *Clin Oral Implant Res.* 2017 Aug;28(8):920-930.
6. Chappuis V, Buser R, Bragger U, Bornstein MM, Salvi GE, Buser D. Long-term outcomes of dental implants with a titanium plasma-sprayed surface: a 20-year prospective case series study in partially edentulous patients. *Clin Impl Dent Relat Res.* 2013;15: 780-790.
7. Gonçalves, Gabriela Sumie Yaguinuma et al. "Oral health-related quality of life and satisfaction in edentulous patients rehabilitated with implant-supported full dentures all-on-four concept: a systematic review." *Clinical oral investigations*, 10.1007/s00784-021-04213-y. 13 Oct. 2021, doi:10.1007/s00784-021-04213-y.
8. Maló, Paulo et al. "The All-on-4 treatment concept for the rehabilitation of the completely edentulous mandible: A longitudinal study with 10 to 18 years of follow-up." *Clinical implant dentistry and related research* vol. 21,4 (2019): 565-577. doi:10.1111/cid.12769
9. Muller F, Duvermay E, Loup A., Vazquez L, Hermann FR, Schimmel M. Implant-supported Mandibular Overdentures in very Old Adults: A Randomized Controlled Trial. *J Dent Res.* 2013;92(12 Suppl):154S-60S
10. Gherlone EF, Capparé P, Tecco S, Polizzi E, Pantaleo G, Gastaldi G, Grusovin MG. A Prospective Longitudinal Study on Implant Prosthetic Rehabilitation in Controlled HIV-Positive Patients with 1-Year Follow-Up: The Role of CD4+ Level, Smoking Habits, and Oral Hygiene. *Clin Implant Dent Relat Res.* 2016 Oct;18(5):955-964



**1 Tilted Implants and Sinus Floor Elevation Techniques Compared in Posterior Edentulous Maxilla: A Retrospective Clinical Study over Four Years of Follow-Up**

E.Gherlone, B.D'Orto, M.Nagni, P.Capparè, R.Vinci

Applied sciences 02/07/2022,12,6729

---

**2 Soft and hard tissue changes after immediate implant placement with or without a sub-epithelial connective tissue graft:**

**Results from a 6-month pilot randomized controlled clinical trial**

D.Guglielmi, G.L.Domenico, S.Aroca, F.Vignoletti, V.Ciaravino, R.Donghia, M.de Sanctis

Journal of Clinical Periodontology Accepted: 12 June 2022

20  
22

Article

# Tilted Implants and Sinus Floor Elevation Techniques Compared in Posterior Edentulous Maxilla: A Retrospective Clinical Study over Four Years of Follow-Up

Enrico Felice Gherlone <sup>1,2</sup>, Bianca D'Orto <sup>1,2,\*</sup>, Matteo Nagni <sup>1,2</sup>, Paolo Cappare <sup>1,2</sup>  and Raffaele Vinci <sup>1,2</sup>

<sup>1</sup> Dental School, Vita-Salute San Raffaele University, 20132 Milan, Italy; gherlone.enrico@hsr.it (E.F.G.); nagnimatteo@libero.it (M.N.); cappare.paolo@hsr.it (P.C.); vinci.raffaele@hsr.it (R.V.)

<sup>2</sup> Department of Dentistry, IRCCS San Raffaele Hospital, 20132 Milan, Italy

\* Correspondence: b.dorto@libero.it

**Abstract:** The aim of this study was to evaluate the implant survival rate, marginal bone loss, and surgical and prosthetic complications of implants placed through sinus floor elevation and tilted implants engaged in basal bone to bypass the maxillary sinus. Sixty patients were enrolled for this study. According to the residual bone height of the posterior maxilla, the sample was divided into three groups of 20 patients: Group A (lateral sinus floor elevation), Group B (transcrestal sinus floor elevation), and Group C (tilted implants employed to bypass the sinus floor). Follow-up visits were performed one week after surgery, at three and six months, and then once a year for the next 4 years. The outcomes were the implant survival rate, marginal bone loss, and surgical and prosthetic complications. Although Groups A, B, and C demonstrated implant survival rates of 83.3%, 86.7%, and 98.3%, respectively, the statistical analysis showed no statistically significant difference between groups. Statistically significant differences between groups were also not found concerning marginal bone loss, as recorded by intra-oral X-ray measurements during follow-up examinations. Regarding complications, it was not possible to perform a statistical analysis. To reduce possible surgical risks, implant placement in basal bone could be preferred.

**Keywords:** posterior edentulous maxilla; maxillary sinus; sinus floor elevation; tilted implants



**Citation:** Gherlone, E.F.; D'Orto, B.; Nagni, M.; Cappare, P.; Vinci, R. Tilted Implants and Sinus Floor Elevation Techniques Compared in Posterior Edentulous Maxilla: A Retrospective Clinical Study over Four Years of Follow-Up. *Appl. Sci.* **2022**, *12*, 6729. <https://doi.org/10.3390/app12136729>

Academic Editor: Vittorio Checchi

Received: 27 April 2022

Accepted: 29 June 2022

Published: 2 July 2022

**Publisher's Note:** MDPI stays neutral with regard to jurisdictional claims in published maps and institutional affiliations.



**Copyright:** © 2022 by the authors. Licensee MDPI, Basel, Switzerland. This article is an open access article distributed under the terms and conditions of the Creative Commons Attribution (CC BY) license (<https://creativecommons.org/licenses/by/4.0/>).

## 1. Introduction

Fixed rehabilitation of an atrophic maxilla may represent a real challenge for clinicians. Following tooth loss, the physiological process of bone resorption is combined with sinus pneumatization, which often impedes traditional implant placement in posterior sectors [1–3].

To allow patients to receive fixed rehabilitations, several therapeutic alternatives such as bone grafting and sinus lift techniques have been proposed to increase residual bone height; although these procedures have provided good long-term results [4,5], several complications, including Schneider's membrane perforation, grafted material infection and/or resorption, implant dislocation in the maxillary sinus, acute or chronic sinusitis, alveolo-antral artery injury, and benign paroxysmal vertigo, could occur [6,7].

To avoid these risks and the clinical time required, short [8] and tilted [9] implants could be considered a viable solution to engage basal bone.

In the choice between categories, considering the micromovements and peri-implant stresses and strains associated with ultra-short (5 mm length) implants [10,11], tilted implants or sinus floor elevation via a lateral approach is promoted in the case of severe bone atrophy (less than 5 mm) [12–15], and the transcrestal sinus lift technique is recommended if the residual bone height is at a minimum of 5 mm [16–18].

Although tilted implants might be the least risky choice [9], the following prerequisites should always be provided: adequate bone volume in the retrocanine area for implant placement at least 10 mm in length and combination with an axial implant [19,20].

In addition, implant placement in basal bone should always be considered in the presence of any conditions that could represent a possible contraindication to sinus augmentation, such as sinusitis, including allergic rhinitis, polyp, cyst, or tumor in the maxillary sinus, and a history of sinus surgery [21,22].

The aim of this retrospective clinical study was to evaluate and compare the implant survival rate (first outcome), marginal bone loss (second outcome), and surgical and prosthetic complications of implant prosthetic rehabilitation through implants placed via sinus floor elevation techniques (lateral approach and osteotome-mediated technique) and tilted implants engaged in basal bone to bypass the maxillary sinus.

## 2. Materials and Methods

### 2.1. Patient Selection

This retrospective study was performed at the Department of Dentistry, San Raffaele Hospital, Milan, Italy. The ethics committee approval number is 190/INT/2021.

The investigation was conducted according to the principles of the Declaration of Helsinki. STROBE (Strengthening the Reporting of Observational Studies in Epidemiology) guidelines were followed (<http://www.strobe-statement.org/> (accessed 1 on April 2019)).

During the period from January 2015 to April 2019, patients with posterior edentulous maxilla (Applegate–Kennedy Class I, II, or III [23]) or severe impairment of residual teeth in the posterior maxilla were consecutively enrolled.

The eligibility criteria were as follows: patients over 18 years old with unilateral or bilateral partial edentulism of the maxilla, with residual bone height equal to or less than 6 mm or severe impairment of residual teeth in the posterior maxilla with maximum residual bone height of 6 mm after the healing period, and requiring fixed prosthetic rehabilitation to replace three or four teeth.

Patients with immunodeficiency, those with uncontrolled systemic diseases, those under bisphosphonate therapy or subjected to head and neck radiotherapy less than one year prior, those having severe malocclusion or parafunction, those unable to adhere to home and professional hygiene maintenance protocols, and smokers were excluded.

All diagnoses were made clinically and radiographically. The radiographic examination was conducted at the first level via panoramic radiography and at the second level via cone beam computed tomography (CBCT) to identify the residual bone height and whether the patient satisfied the inclusion criteria of the study (residual bone height of 6 mm or less). According to bone volume, the sample was divided in three groups (Table 1).

**Table 1.** Sample division according to residual bone height, bone volume in the retrocanine area, possibility or not of combining a tilted implant with an axial one, and presence or absence of any contraindication to sinus augmentation.

	Group A (Sinus Floor Augmentation via Lateral Approach)	Group B (Transcrestal Sinus Floor Elevation)	Group C (One Tilted and One Axial Implants)
Residual bone height	Less than 5 mm, inadequate bone volume in the retrocanine area for tilted implant placement at least 10 mm long, impossibility of combining a tilted implant with an axial one and absence of any contraindication to sinus augmentation [15–19]	Minimum of 5 mm [20–22]	Less than 7 mm, adequate bone volume in the retrocanine area for tilted implant placement at least 10 mm long, possibility of combining a tilted implant with an axial one and contraindication to sinus augmentation [18–22]

Written informed consent for implant prosthetic rehabilitation was obtained from all patients prior to the beginning of the study, and the local ethical committee approved the study; professional oral hygiene was provided before surgery.

## 2.2. Surgical Procedures

### *Group A: Sinus floor elevation through a Lateral Window Technique*

All surgical procedures were performed by the same surgeon with advanced surgical experience. As for the other surgery types, one hour prior, patients received 2 g amoxicillin and clavulanic acid, and they received another 1 g twice a day for a week after the surgical procedure (clarithromycin was prescribed as an alternative in case of allergy, 2 g before surgery and 1 g twice a day for the following week).

Surgery was performed under anesthesia induced by local infiltration of optican solution with adrenaline 1:80,000 (AstraZeneca, Milan, Italy). The same protocol was applied for all techniques.

The first incision was made on the top of the alveolar crest, shifted on the palatal side to obtain the same level of keratinized mucosa on both flap sides. Then, distal and mesial vertical release incisions were performed to expose the underlying bone crest. The full-thickness flap was elevated to preserve anatomical subperiosteal structures.

The flap was detached to expose the anterior piriform cortex and canine draft, used as landmarks, and to identify the maxillary sinus, often available in transparency from the lateral bone wall. A bony window was drawn using a sterile pencil on the lateral wall, behind the canine draft, according to the size and location of the maxillary sinus and the implant insertion site. Then, a high-speed handpiece with a diamond bur was employed to outline the antrostomy. A bone scraper was used to obtain autologous bone chips from the bony window. To preserve the Schneiderian membrane from injuries, a piezoelectric instrument was employed for bony window detachment.

The elevation degree was set according to the vertical defect's extension, proceeding from the inferior-medial sinus wall to the distal.

The implant sites were prepared using a lance-shaped drill followed by drills of increasing diameter; fixtures were then placed. The implants placed for this group belonged to the K line (Winsix, Biosafin, Ancona, Italy); this implant type has a cylindrical shape with a truncated conical body characterized by a self-threading coil with differentiated depth and thickness and variable geometry to modulate primary stability during surgery. The macromorphology is characterized by variable geometry, the coils gradually varying from square to triangular and varying in depth to favor vertical micro-expansion and progressive horizontal expansion; it has wide and deep unloading grooves for the deposition of bone chips and the formation of clots during the screwing phase. Due to the properties of these implants, they were chosen for both methods of sinus lift (lateral approach and transcrestal approach), by agreement of the surgeon and prosthetist.

The autologous bone graft obtained from the bony window was the only biomaterial applied, and it was placed around implants to promote bone regeneration [24].

An adsorbable hemostatic gelatin (Spongostan, Ethicon, Johnson & Johnson, New Brunswick, NJ, USA) was employed to promote clot formation and to contain the exposed sinus area following the removal of the bony opening that provided access to the cavity.

Flap adaptation and suturing were performed using 3–0 non-resorbable sutures (Vicryl; Ethicon, Johnson & Johnson, New Brunswick, NJ, USA).

### *Group B: Sinus floor elevation through an Osteotome-Mediated Technique*

The first incision was made on the top of the alveolar crest, shifted on the palatal side to obtain the same level of keratinized mucosa on both sides of the flap. Distal and mesial vertical release incisions were performed to create a full-thickness flap, exposing the underlying bone crest and preserving anatomical epiperiosteal structures. A lance-shaped drill was employed for 2 mm to drill the cortical bone. A pilot drill of  $\varnothing$  2.00 was applied to create an implant insertion site and to define the fixture's setting. Then, osteotomes of progressively increasing diameter were gradually driven to sinus floor fracture and

Schneiderian membrane elevation. The diameter of the last osteotomy was less than the fixture diameter to promote primary mechanical stability. Any biomaterial was applied before implant placement. Only an adsorbable hemostatic gelatin (Spongostan, Ethicon, Johnson & Johnson, New Brunswick, NJ, USA) was employed to promote clot formation and to retain membrane elevation. Flap adaptation and suturing were performed using 3–0 non-resorbable sutures (Vicryl; Ethicon, Johnson & Johnson, New Brunswick, NJ, USA).

#### *Group C: Tilted implants*

The first incision was made on the top of the alveolar crest, shifted on the palatal side to obtain the same level of keratinized mucosa on both sides of the flap. Then, distal and mesial vertical release incisions were performed to expose the underlying bone crest.

The obtained full-thickness flap allowed us to preserve subperiosteal anatomical structures from injuries and to expose the canine draft and maxillary sinus, often available in transparency from the lateral bone wall. The tilted implant was placed first, in the vestibulo-palatal direction and adjacent to the mesial wall of the maxillary sinus; when possible, the apex of the fixtures engaged the inferior-medial wall of the inferior-distal cortical of the piriform opening.

Every tilted implant was associated with an axial implant, placed according to the traditional system in the canine or lateral incisor region. Straight implant placement always occurred after tilted implant insertion according to their position and angulation.

The implants placed for this group belonged to the TT line (Winsix, Biosafin, Ancona, Italy), which has a single implant body with a specific macromorphology to achieve maximum implant stability; it is also excellent for immature loading and differs in having either an internal hex (TTi) or an external hex (TTx). On a macromorphological level, they have double-threaded, double-principled coils for easy implant insertion with half the number of turns. The groove in the lower part of the loop decompresses the bone by dissipating forces and facilitates clot deposition. At the same time, it increases the implant surface by facilitating the neoformation of cells. The apex is conical and undersized by 1.3 to 1.8 with respect to the diameter of the implant; it is strongly tapered to obtain an osteotomic effect and to facilitate the inclined insertion of implants, even in the case of reduced bone availability.

Because of their characteristics and eligibility for immediate loading, they were selected for this group by agreement of the surgeon and prosthetist.

A lanceolate drill was employed to perforate cortical bone. A pilot drill of  $\varnothing$  2.00 was applied to create an implant insertion site and to define the fixture's setting. A positioning pin was plugged to verify the implant location, emergence, and angulation.

Drills of progressive diameter were employed up to the final fixture's diameter. The site was over-prepared vertically and sub-prepared transversely to promote primary mechanical stability. The implant neck was aimed to be positioned at bone level. The insertion torque ranging between 30 and 40 N·cm before final seating of the implant, allowing for immediate loading.

A manual screwdriver was applied when incomplete seating of the implant occurred, and bi-cortical anchorage was established whenever possible.

To compensate for the lack of parallelism between implants, angulated abutments (Extreme Abutment, EA<sup>®</sup> Winsix, Biosafin) at 30 degrees were screwed on tilted implants; straight abutments were screwed on axial implants. The flap was adapted around the structure. Suturing was performed using 3–0 non-resorbable sutures (Vicryl; Ethicon, Johnson & Johnson, New Brunswick, NJ, USA).

#### Post-Surgical Protocol

Immediately after surgery, intra-oral X-rays were performed to verify the correct implant position.

Antibiotic therapy (amoxicillin and clavulanic acid 1 g or clarithromycin 1 g in case of allergy, twice daily for 7 days after surgery) and analgesic therapy (non-steroidal anti-inflammatory drugs, as needed) were prescribed for each patient. Mouth rinsing with a



chlorhexidine-digluconate-containing solution (0.12% or 0.2%) was recommended twice daily for 10 days. One week after the surgical procedure, sutures were removed. The same post-surgical protocol was applied for all procedures.

### 2.3. Prosthetic Protocol

In both sinus floor elevation procedures (Group A and Group B), the implants were covered for about 4 months; then, reopening was performed, and cap screws were replaced with healing screws. An acrylic provisional prosthesis composed of three or four teeth according to the antagonist arch and the presence or absence of adjacent teeth was delivered to each patient. Screw access holes were covered with provisional resin (Fermit, Ivoclar Vivadent, Naturno, Bolzano, Italy). We performed the appropriate evaluation checks of the device, and after another four months, the provisional prosthesis was replaced with a metal ceramic or resin implant-supported final prosthesis composed of three or four units.

Unlike these procedures, which involved a deferred load, in Group C, in accordance with several prior research results, patients were subjected to immediate loading [25,26].

One week before surgery, preliminary traditional impressions were taken to obtain an all-acrylic resin provisional prosthesis composed of three or four teeth.

To enable manufacture of a high-density baked all-acrylic prosthesis with titanium cylinders, pickup impressions (Permadyne, ESPE, Seefeld, Germany) of the implants were made after suturing.

About 3 h after the surgery, a screw-retained acrylic provisional prosthesis with three or four teeth was delivered. Provisional resin (Fermit, Ivoclar Vivadent, Naturno) was used to cover screw access holes. Four months later, the provisional prosthesis was replaced with a metal ceramic or resin implant-supported final prosthesis composed of three teeth.

In all groups, articulating papers (40 µm Bausch Articulating Paper) were applied to obtain central contacts made on all masticatory units (stating occlusion) in the provisional prosthesis and dynamic occlusion, involving premolar guidance, definitively.

### 2.4. Follow-Up

Follow-up visits were performed 1 week after surgery, at 3 and 6 months, and then once a year for the next 4 years. Each patient was placed in a professional oral hygiene program that would allow both for limiting complications [27,28] and for monitoring and interception of any complications.

1. *Implant survival rate.* The implant survival rate was dependent on the number of implants lost during the follow-up period due to mobility associated with progressive marginal bone loss due to peri-implantitis. Implant loss was classified according to the period: if it occurred within 6 months of fixture placement, it was called early failure; after 6 months, it was called late failure. Early failure was usually intercepted at the reopening stage, when there was a lack of osseointegration of the implant. In the case of late failure, there were signs of peri-implantitis, implant mobility, radiolucent areas around fixtures, mucosal suppuration, and/or pain during the follow-up period.
2. *Marginal bone loss (MBL).* The MBL was evaluated via digital phosphor intra-oral radiography performed for each patient using the parallel cone technique at 6, 12, 24, 36, and 48 months. To assess marginal bone trends, measurements were performed only after image calibration. Digora 2.5 software (Soredex, Tuusula, Finland) was used as an analysis platform, making use of the specific measurement tool contained therein. As a first step, calibration (pixels/mm) of the instrument was performed, using the implant diameter of the survey site as the known unit. Next, any changes in the height of the peri-implant marginal bone in relation to the most coronal part of the implant and the point of contact between the implant and marginal ridge were measured. To evaluate bone resorption, a line passing over the shoulder of the implant was considered as a reference point for measurement from which a straight line was drawn parallel to the long axis of the implant to the most coronal point where the bone met the fixture both mesially and distally. The software automatically

provided, in relation to the calibration, the distance between the two points measured in millimeters. To reduce human error, this measurement was performed by three operators, and the average of the three measurements was considered. To evaluate the marginal bone level, first the mesial and distal measurements were taken, then the averages of the mesial, of the distal, and between the two values of a single implant site (MBL, marginal bone level) were calculated, as reported in Section 3. Marginal bone levels detected were divided into two categories according to the implant position, whether mesial (Implant 1/I1) or distal (Implant 2/I2). The first group included only axial implants; the second group also included tilted fixtures, always placed distally and in association with a mesial axial implant (Implant 1/I1). The data thus obtained were then statistically investigated.

3. *Surgical complications.* Surgical complications were divided according to the surgical procedure.
4. *Prosthetic complications.* These included fracture of the provisional prosthesis, unscrewing of temporary crowns and/or abutments (Group C), unscrewing of final crowns and/or abutments (Group C), and chipping.

#### 2.5. Statistical Analysis

Statistical analysis was performed for numerical parameters using SPSS for Windows version 18.0 (SPSS Inc., Chicago, IL, USA). Descriptive analysis was performed using the mean  $\pm$  standard deviation.

The different implant survival rates between the surgical procedures, based on the number of implants lost in each group, were compared using the test of between-subject effects according to one-way analysis of variance (ANOVA).

Analysis of variance was used to investigate changes in the bone level over time. All statistical comparisons were conducted at the 0.05 significance level. The null hypothesis was that there would be no difference in mean marginal bone changes between implants. Regarding complications, due to the few cases observed, a statistical analysis could not be performed.

### 3. Results

According to the inclusion and exclusion criteria, 60 patients (32 males, 28 females) with an edentulous posterior maxilla (Applegate–Kennedy Class I, II, or III) or the need for avulsion of residual teeth in the posterior section were enrolled for this study. The mean age was 64 years (range: 52–76). The sample was divided into three groups of 20 according to the surgical procedure they received.

Every surgery involved the placement of two implants to support screw-retained prostheses of a minimum of three and a maximum of four dental units according to the antagonist arch (presence or absence of the lower first molar) and presence or absence of adjacent distal teeth. Fixtures were placed at sites 14 and 16, sites 14 and 15, or sites 14, 15, and 16 and in the same sites in the contralateral semi-arch.

A total of 144 dental implants (K or TTi or TTx, Winsix, Biosafin, Ancona, Italy) were placed. Group A received 48 implants, Group B received 46 implants, and Group C received 50 implants (Table 2).

Immediate loading was performed only in Group C; in both sinus floor elevation techniques, implant loading occurred approximately 4 months after implant placement.

1. *Implant survival rate.* In the lateral sinus floor elevation technique (Group A), no implants were lost in the first six months after surgery; two fixtures were lost in the following period. In the transcresal approach (Group B), one implant was lost in the first six months after surgery, and only one was lost later. Only one tilted implant (Group C) was lost early; no implants were lost in the following period.

Group A, Group B, and Group C demonstrated implant survival rates of 95.83%, 95.65%, and 98%, respectively (Table 3).

**Table 2.** Number, diameter, and length of dental implants classified by group.

		Dental Implant Details			
		Length 9 mm	Length 11 mm	Length 13 mm	Length 15 mm
<b>Group A</b> (sinus floor augmentation via lateral approach) n = 48	diameter 3.3 mm	6	7	0	0
	diameter 3.8 mm	29	6	0	0
<b>Group B</b> (transcrestal sinus floor elevation) n = 46	diameter 3.3 mm	2	3	1	0
	diameter 3.8 mm	16	21	3	0
<b>Group C</b> (one tilted and one axial implant) n = 50	diameter 3.3 mm	0	0	4	4
	diameter 3.8 mm	0	2	29	11

**Table 3.** Implant failure before or after the osseointegration period (6 months) and implant survival rates according to the surgical procedure at the end of the follow-up period (4 years).

	Implants Placed	Early Failure	Late Failure	Implant Survival Rate
Group A	48	0	2	95.83%
Group B	46	1	1	95.65%
Group C	50	1	0	98%

However, a one-way analysis of variance (ANOVA) revealed no differences among groups in terms of the proportion of lost implants ( $F(2, 60) = 0.54, p = 0.59, n.s.$ ). Although seemingly different from one another, the estimated mean values did not differ statistically (Table 4).

**Table 4.** Differences among groups in terms of the proportion of lost implants.

Dependent Variable: Prop_lost Dental Implants					
Source	Type III Sum of Squares	Df	Mean Square	F	Sig.
<b>Corrected Model</b>	0.036 <sup>a</sup>	2	0.018	0.539	0.586
<b>Intercept</b>	0.363	1	0.363	10.775	0.002
<b>Group</b>	0.036	2	0.018	0.539	0.586
<b>Error</b>	1.920	57	0.034		
<b>Total</b>	2.319	60			
<b>Corrected Total</b>	1.956	59			

<sup>a</sup> R Squared = 0.019 (Adjusted R Squared = -0.016).

- Marginal Bone Loss.** Statistical analysis was also performed for marginal bone loss, evaluated 6 months after the surgical procedure, 12 months after the surgical procedure, and once a year subsequently. The values obtained were divided into two categories according to the fixture position (Tables 5 and 6).

**Table 5.** Average marginal bone loss (millimeters) of mesial implants (I1) observed during follow-up.

Descriptive Statistics				
	Group	Mean	Std. Deviation	N
I1_MBL 6 months (mm)	A	0.970	0.1455	20
	B	0.915	0.1387	20
	C	0.920	0.1508	20
	Total	0.935	0.1448	60
I1_MBL 12 months (mm)	A	1.095	0.1356	20
	B	1.085	0.1663	20
	C	1.040	0.1847	20
	Total	1.073	0.1625	60

Table 5. Cont.

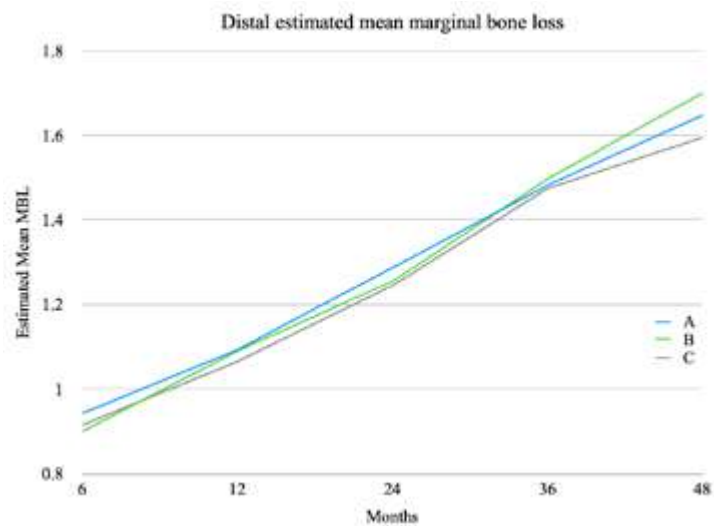
Descriptive Statistics				
	Group	Mean	Std. Deviation	N
I1_MBL 24 months (mm)	A	1.250	0.1235	20
	B	1.260	0.1729	20
	C	1.255	0.1572	20
	Total	1.255	0.1501	60
I1_MBL 36 months (mm)	A	1.470	0.0801	20
	B	1.500	0.1338	20
	C	1.475	0.0786	20
	Total	1.482	0.1000	60
I1_MBL 48 months (mm)	A	1.695	0.1986	20
	B	1.720	0.2238	20
	C	1.585	0.0933	20
	Total	1.667	0.1875	60

Table 6. Average marginal bone loss (millimeters) of distal implants (I2) observed during follow-up.

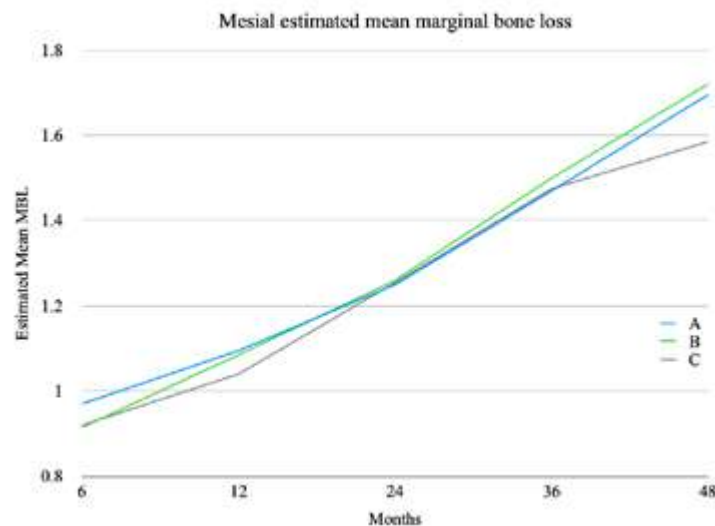
Descriptive Statistics				
	Group	Mean	Std. Deviation	N
I2_MBL 6 months (mm)	A	0.918	0.1131	17
	B	0.888	0.1310	16
	C	0.936	0.1447	14
	Total	0.913	0.1279	47
I2_MBL 12 months (mm)	A	1.094	0.1249	17
	B	1.088	0.1708	16
	C	1.100	0.1177	14
	Total	1.094	0.1374	47
I2_MBL 24 months (mm)	A	1.306	0.1345	17
	B	1.238	0.1258	16
	C	1.236	0.1336	14
	Total	1.262	0.1328	47
I2_MBL 36 months (mm)	A	1.488	0.0781	17
	B	1.481	0.1109	16
	C	1.450	0.1092	14
	Total	1.474	0.0988	47
I2_MBL 48 months (mm)	A	1.588	0.0857	17
	B	1.681	0.1328	16
	C	1.600	0.1569	14
	Total	1.623	0.1306	47

Regarding Implant 1, as shown in Figure 1, a 3 (groups)  $\times$  5 (time) MANOVA revealed a main effect of time ( $F(1, 57) = 786.11, p < 0.001$ ), while other effects did not reach the conventional threshold of statistical significance. In other words, the MBL for Implant 1 tended to increase over the five time periods, regardless of the surgical approach (i.e., group) (Figure 1).

Regarding Implant 2, as shown in Figure 2, a 3 (groups)  $\times$  5 (time) MANOVA revealed a main effect of time ( $F(1, 44) = 680.31, p < 0.001$ ), while other effects did not reach the conventional threshold of statistical significance. In other words, the MBL for Implant 2 tended to increase over the five time periods, regardless of the surgical approach (i.e., group) (Figure 2).



**Figure 1.** MBL for Implant 1, which tended to increase over the five time periods, irrespective of surgical approach.



**Figure 2.** MBL for Implant 2, which tended to increase over the five time periods, irrespective of surgical approach.

- Surgical Complications.** All recorded complications were related to the lateral sinus floor elevation technique (Group A) or transcrestal sinus floor elevation (Group B). In Group C, there were no intra-operative complications. Three membrane perforations were reported in Group A. The complication was resolved intra-operatively by further detaching the Schneider membrane from the inferior-medial region to reposition the hole under the bone wall. This avoided leakage of the graft material and possible subsequent infection. In the same group, no other complications were reported. In Group B, the only problem encountered was paroxysmal benign positional vertigo

(PPBV), associated with the percussive action induced by the surgical mallet. After about one month, the complication resolved itself in all four cases where it was found.

4. *Prosthetic Complications.* No prosthetic complications were reported during the follow-up period.

#### 4. Discussion

In this retrospective clinical study, three different surgical techniques for the rehabilitation of a posterior maxilla with insufficient residual bone height for the placement of axial implants were compared.

Sinus lift techniques have been extensively discussed, and several authors have reported good short- and long-term results on implant survival rate.

Concerning a lateral sinus lift, Canullo et al., in their multicenter prospective study at 2 years of follow-up, reported an implant survival rate of 97% in patients with residual bone height between 1 and 4 mm who were treated with a lateral sinus augmentation using a nano-crystalline hydroxyapatite sole bone filler, simultaneous implant placement, and a deferred loading protocol [29].

Similar results were obtained by Schmitt et al. in their retrospective clinical study at 10 years of follow-up, in which they reported an implant survival rate of 95.45% in patients undergoing sinus lift via a lateral approach using autologous bone graft, implant placement after a four-month healing period, and a deferred loading protocol [30].

These results are similar to those obtained in this study, where the implant survival rate of fixtures placed by sinus lift via a lateral approach was 95.83%.

Beretta et al. [31], in their retrospective clinical study at 15 years of follow-up, compared implant survival in patients subjected to sinus lift with that in patients subjected to a lateral approach, depending on the implant placement protocol and biomaterial used. Implants placed at the same time as the sinus lift (residual bone height above 4 mm) provided similar results to implants placed after the healing period; autologous bone, according to other studies [32], provided better results than a heterologous bone graft. Although autologous bone is currently considered the gold standard in bone regeneration [33], good medium- and long-term results have been obtained in both sinus lift techniques even without bone grafting [34].

Considering these results, in the present study, autologous bone chips obtained from the lateral bone window were applied as the only bone regeneration material.

Concerning transcrestal sinus lift, Bruschi et al., in their retrospective clinical study at  $10.43 \pm 5.01$  years (ranging from 5 to 16 years) of follow-up, reported a survival rate of 95.45% [35].

Similar results were obtained by Qian et al., in their randomized controlled trial at 10 years of follow-up, in which they reported an implant survival rate of 90.7% in the case of osteotome sinus floor elevation with deproteinized bovine bone mineral and 95.0% without bone grafting [36].

According to these authors, the transcrestal sinus lift, applied when residual bone height was at least 5 mm, was performed through an osteotome-mediated technique and without biomaterials, recording an implant survival rate of 95.65%.

Concerning tilted implants applied to bypass the sinus floor, the implant survival rate recorded in our study (98%) could be compared with those in other studies.

Aparicio et al., in their retrospective clinical study at 5 years of follow-up, reported an implant survival rate of 95.2% in immediate-loading rehabilitations of posterior edentulous maxilla with the placement of one axial and one tilted implant, concluding that tilted implants, longer than traditional ones, could increase the implant-to-bone contact area, promoting primary stability, reducing the prosthetic cantilever, and engaging basal bone [37].

Similar results were obtained by Fortin et al. [38] and Pozzi et al. [39], who reported implant survival rates of 100% at 5 years of follow-up and 96.3% at 3 years of follow-up, respectively, in the absence of intra- or post-operative surgical complications.



Regarding marginal bone loss, as reported by Antonoglou et al. in their systematic review and meta-analysis of clinical trials [40] and as confirmed by our results, implants placed via sinus lift techniques show values similar to those of implants placed via traditional methods.

The rationale for choosing between the different surgical procedures considered in this study could therefore be related to possible complications of sinus augmentation techniques, such as perforation of Schneider's membrane, graft infection, implant or graft dislocation in the maxillary sinus, acute or chronic sinusitis, injury of the alveolus-antral artery, and benign paroxysmal vertigo, which could occur [41,42].

In our study, the only recorded complication in Group A was Schneiderian membrane perforation, which is considered a prevalent occurrence in sinus floor augmentation via a lateral approach [43]; a similar situation occurred in Group B, where the only complication was paroxysmal benign positional vertigo [44].

According to several authors and the results of this study, where no complications were recorded in Group C, when possible, tilted implants could be proposed as a possible alternative in the rehabilitation of partially or totally edentulous maxilla [45–47], avoiding more invasive techniques and allowing immediate loading [9,37,45].

Regardless of possible complications, studying the cone beam CT scan before proceeding with any type of surgical approach may be crucial to evaluate the residual bone height and maxillary sinus conformation and, subsequently, to make the most appropriate surgical choice [15–22,48].

Furthermore, once the surgical technique that we consider most appropriate according to the above parameters has been chosen, pre-surgical planning is a valuable confirmation aid and an indication of how to perform surgery in a predictable way [49–51].

Since there may be discrepancies between the pre-surgical planning obtained from the cone beam CT scan and the clinical procedure [52,53], the surgeon's experience may be crucial in managing these variables and possible complications [54,55].

Also, in our case, the choice of an experienced surgeon supported by the aid of second-level radiographic examinations and pre-surgical planning may have had a positive influence on the obtained results.

However, for a more in-depth analysis, multicenter clinical studies with more variables, such as surgeon, prosthetist, and registrar, could be useful to compare the different techniques, also obtaining a larger sample of patients.

The choice of surgical procedure between sinus lift with a lateral or transcrestal approach and tilted implants may depend on several criteria such as the residual bone height, maxillary sinus conformation, and presence of any pathology affecting the maxillary sinus; as with any other surgical procedure, a risk–benefit ratio assessment could be crucial [12–14].

Although the results of the present study did not show any statistically significant differences between the groups, the finding that sinus lift techniques might involve a higher inherent risk of complications could be considered as one of the parameters of treatment choice [7].

## 5. Conclusions

Within the limitations of the present study, the obtained results suggest tilted implants as a possible alternative to sinus floor elevation procedures. Although there were no statistically significant differences in implant survival and marginal bone loss between the groups, tilted implants placed in the available bone presented fewer complications compared to sinus elevation via a lateral window approach or osteotome-mediated technique. It is possible to perform immediate partial rehabilitation over maxillary tilted implants with minimal complications. However, the surgical qualifications of the clinician may be crucial to performing all the listed procedures correctly. Further studies with enlarged samples may be necessary to confirm the obtained results.

**Author Contributions:** Conceptualization, E.F.G. and B.D.; methodology, P.C.; validation, R.V., P.C. and B.D.; formal analysis, M.N.; investigation, R.V.; resources, M.N.; data curation, B.D.; writing—original draft preparation, B.D.; writing—review and editing, M.N.; visualization, P.C.; supervision, E.F.G.; project administration, E.F.G. All authors have read and agreed to the published version of the manuscript.

**Funding:** This research received no external funding.

**Institutional Review Board Statement:** The study was conducted according to the guidelines of the Declaration of Helsinki and approved by the Institutional Review Board (or Ethics Committee) of Vita-Salute University, Milan, Italy.

**Informed Consent Statement:** Informed consent was obtained from all subjects involved in the study.

**Data Availability Statement:** The data presented in this study are available on reasonable request from the corresponding author.

**Conflicts of Interest:** The authors declare no conflict of interest.

## References

- Gerken, U.; Esser, F.; Möhlhenrich, S.C.; Bartella, A.K.; Hölzle, F.; Fischer, H.; Raith, S.; Steiner, T. Objective computerised assessment of residual ridge resorption in the human maxilla and maxillary sinus pneumatization. *Clin. Oral Investig.* **2020**, *24*, 3223–3235. [[CrossRef](#)] [[PubMed](#)]
- Lim, H.C.; Kim, S.; Kim, D.H.; Herr, Y.; Chung, J.H.; Shin, S.I. Factors affecting maxillary sinus pneumatization following posterior maxillary tooth extraction. *J. Periodontal. Implant Sci.* **2021**, *51*, 285–295. [[CrossRef](#)] [[PubMed](#)]
- Chen, Y.W.; Finkelman, M.; Papaspirisdakos, P.; César-Neto, J.B.; Weber, H.P.; de Souza, A.B. Comparative analysis of dimensional alterations following extraction of maxillary molars using three-dimensional images' superimposition: A CBCT study. *Odontology* **2021**, *109*, 514–523. [[CrossRef](#)] [[PubMed](#)]
- Vinci, R.; Teté, G.; Lucchetti, F.R.; Capparé, P.; Gherlone, E.F. Implant survival rate in calvarial bone grafts: A retrospective clinical study with 10 year follow-up. *Clin. Implant Dent. Relat. Res.* **2019**, *21*, 662–668. [[CrossRef](#)] [[PubMed](#)]
- Ha, J.; Son, J.H.; Sung, I.Y.; Cho, Y.C.; Choi, J.H. Clinical outcome of implants placed in grafted maxillary sinus via lateral approach: A 10-year follow-up study. *J. Dent. Sci.* **2020**, *15*, 270–277. [[CrossRef](#)] [[PubMed](#)]
- Aloy-Prósper, A.; Carramolino-Cuellar, E.; Peñarrocha-Oltra, D.; Soto-Peñaloza, D.; Peñarrocha-Diago, M. Intraoral onlay block bone grafts versus cortical tenting technique on alveolar ridge augmentations: A systematic review. *Med. Oral Patol. Oral Cir. Bucal.* **2022**, *27*, e181–e190. [[CrossRef](#)]
- Leung, M.; Alghamdi, R.; Guallart, I.F.; Bergamini, M.; Yu, P.Y.; Froum, S.J.; Cho, S.C. Patient-Related Risk Factors for Maxillary Sinus Augmentation Procedures: A Systematic Literature Review. *Int. J. Periodont. Restor. Dent.* **2021**, *41*, e121–e128. [[CrossRef](#)]
- Carosi, P.; Lorenzi, C.; Lio, F.; Laureti, M.; Ferrigno, N.; Arcuri, C. Short implants ( $\leq 6$  mm) as an alternative treatment option to maxillary sinus lift. *Int. J. Oral Maxillofac. Surg.* **2021**, *50*, 1502–1510. [[CrossRef](#)]
- Asawa, N.; Bulbule, N.; Kakade, D.; Shah, R. Angulated implants: An alternative to bone augmentation and sinus lift procedure: Systematic review. *J. Clin. Diagn. Res.* **2015**, *9*, ZE10-3. [[CrossRef](#)]
- Desai, S.R.; Singh, R.; Karthikeyan, I. 2D FEA of evaluation of micromovements and stresses at bone-implant interface in immediately loaded tapered implants in the posterior maxilla. *J. Indian Soc. Periodontol.* **2013**, *17*, 637–643. [[CrossRef](#)]
- Sumra, N.; Desai, S.; Kulshrestha, R.; Mishra, K.; Singh, R.V.; Gaonkar, P. Analysis of micromovements and peri-implant stresses and strains around ultra-short implants—A three-dimensional finite-element method study. *J. Indian Soc. Periodontol.* **2021**, *25*, 288–294. [[CrossRef](#)] [[PubMed](#)]
- Gallucci, G.O.; Avrampou, M.; Taylor, J.C.; Elpers, J.; Thalji, G.; Cooper, L.F. Maxillary Implant-Supported Fixed Prosthesis: A Survey of Reviews and Key Variables for Treatment Planning. *Int. J. Oral Maxillofac. Implants* **2016**, *31*, S192–S197. [[CrossRef](#)] [[PubMed](#)]
- Hong, D.G.K.; Oh, J.H. Recent advances in dental implants. *Maxillofac. Plast. Reconstr. Surg.* **2017**, *39*, 33. [[CrossRef](#)] [[PubMed](#)]
- Messias, A.; Nicolau, P.; Guerra, F. Different Interventions for Rehabilitation of the Edentulous Maxilla with Implant-Supported Prosthesis: An Overview of Systematic Reviews. *Int. J. Prosthodont.* **2021**, *34*, S63–S84. [[CrossRef](#)] [[PubMed](#)]
- Khehra, A.; Levin, L. Maxillary sinus augmentation procedures: A narrative clinical review. *Quintessence Int.* **2020**, *51*, 578–584. [[CrossRef](#)]
- Lundgren, S.; Cricchio, G.; Hallman, M.; Jungner, M.; Rasmusson, L.; Sennerby, L. Sinus floor elevation procedures to enable implant placement and integration: Techniques, biological aspects and clinical outcomes. *Periodontol.* **2000** **2017**, *73*, 103–120. [[CrossRef](#)]
- Agliardi, E.L.; Teté, S.; Romeo, D.; Malchiodi, L.; Gherlone, E. Immediate function of partial fixed rehabilitation with axial and tilted implants having intrasinus insertion. *J. Craniofac. Surg.* **2014**, *25*, 851–855. [[CrossRef](#)]
- De Vico, G.; Bonino, M.; Spinelli, D.; Schiavetti, R.; Sannino, G.; Pozzi, A.; Ottria, L. Rationale for tilted implants: FEA considerations and clinical reports. *Oral Implantol.* **2011**, *4*, 23–33.

19. Hsu, Y.T.; Rosen, P.S.; Choksi, K.; Shih, M.C.; Ninneman, S.; Lee, C.T. Complications of sinus floor elevation procedure and management strategies: A systematic review. *Clin. Implant. Dent. Relat. Res.* **2022**. [\[CrossRef\]](#)
20. Summers, R.B. A new concept in maxillary implant surgery: The osteotome technique. *Compendium* **1994**, *15*, 154–156, 158; discussion 162.
21. Summers, R.B. The osteotome technique: Part 3—Less invasive methods of elevating the sinus floor. *Compendium* **1994**, *15*, 698, 700, 702–704; discussion 710. [\[PubMed\]](#)
22. Andrés-García, R.; Ríos-Santos, J.; Herrero-Climent, M.; Bullón, P.; Fernández-Farhall, J.; Gómez-Menchero, A.; Fernández-Palacín, A.; Ríos-Carrasco, B. Sinus Floor Elevation via an Osteotome Technique without Biomaterials. *Int. J. Environ. Res. Public Health* **2021**, *18*, 1103. [\[CrossRef\]](#) [\[PubMed\]](#)
23. Ulmer, F.C., Jr. Kennedy-Applegate classification of partially edentulous dental arches. *NADL J.* **1983**, *30*, 37–40. [\[PubMed\]](#)
24. Sakkas, A.; Schramm, A.; Winter, K.; Wilde, F. Risk factors for post-operative complications after procedures for autologous bone augmentation from different donor sites. *J. Craniomaxillofac. Surg.* **2018**, *46*, 312–322. [\[CrossRef\]](#)
25. Menini, M.; Signori, A.; Tealdo, T.; Bevilacqua, M.; Pera, F.; Ravera, G.; Pera, P. Tilted implants in the immediate loading rehabilitation of the maxilla: A systematic review. *J. Dent. Res.* **2012**, *91*, 821–827. [\[CrossRef\]](#)
26. Pathan, M.R.; Mehta, S.P.; Sutariya, P.V.; Upadhyay, H.H.; Patel, S.R.; Kantharia, N.D.G. Clinical success between tilted and axial implants in edentulous maxilla: A systematic review and meta-analysis. *J. Indian Prosthodont. Soc.* **2021**, *21*, 217–228. [\[CrossRef\]](#)
27. Polizzi, E.; D'Orto, B.; Tomasi, S.; Tetè, G. A micromorphological/microbiological pilot study assessing three methods for the maintenance of the implant patient. *Clin. Exp. Dent. Res.* **2021**, *7*, 156–162. [\[CrossRef\]](#)
28. Cattoni, F.; Tetè, G.; D'orto, B.; Bergamaschi, A.; Polizzi, E.; Gastaldi, G. Comparison of hygiene levels in metal-ceramic and stratified zirconia in prosthetic rehabilitation on teeth and implants: A retrospective clinical study of a three-year follow-up. *J. Biol. Regul. Homeost. Agents* **2021**, *35*, 41–49. [\[CrossRef\]](#)
29. Canullo, L.; Patacchia, O.; Sisti, A.; Heinemann, F. Implant restoration 3 months after one stage sinus lift surgery in severely resorbed maxillae: 2-year results of a multicenter prospective clinical study. *Clin. Implant Dent. Relat. Res.* **2012**, *14*, 412–420. [\[CrossRef\]](#)
30. Schmitt, C.; Karasholi, T.; Lutz, R.; Wiltfang, J.; Neukam, F.-W.; Schlegel, K.A. Long-term changes in graft height after maxillary sinus augmentation, onlay bone grafting, and combination of both techniques: A long-term retrospective cohort study. *Clin. Oral Implants Res.* **2014**, *25*, e38–e46. [\[CrossRef\]](#)
31. Beretta, M.; Poli, P.; Grossi, G.B.; Pieroni, S.; Maiorana, C. Long-term survival rate of implants placed in conjunction with 246 sinus floor elevation procedures: Results of a 15-year retrospective study. *J. Dent.* **2015**, *43*, 78–86. [\[CrossRef\]](#) [\[PubMed\]](#)
32. Al-Moraissi, E.; Alkhutari, A.; Abotaleb, B.; Altairi, N.; Del Fabbro, M. Do osteoconductive bone substitutes result in similar bone regeneration for maxillary sinus augmentation when compared to osteogenic and osteoinductive bone grafts? A systematic review and frequentist network meta-analysis. *Int. J. Oral Maxillofac. Surg.* **2020**, *49*, 107–120. [\[CrossRef\]](#) [\[PubMed\]](#)
33. Stumbras, A.; Krukis, M.M.; Januzis, G.; Juodzbalys, G. Regenerative bone potential after sinus floor elevation using various bone graft materials: A systematic review. *Quintessence Int.* **2019**, *50*, 548–558. [\[CrossRef\]](#)
34. Lie, S.; Claessen, R.; Leung, C.; Merten, H.-A.; Kessler, P. Non-grafted versus grafted sinus lift procedures for implantation in the atrophic maxilla: A systematic review and meta-analysis of randomized controlled trials. *Int. J. Oral Maxillofac. Surg.* **2022**, *51*, 122–132. [\[CrossRef\]](#) [\[PubMed\]](#)
35. Bruschi, G.B.; Crespi, R.; Cappare', P.; Gherlone, E. Transcrestal sinus floor elevation: A retrospective study of 46 patients up to 16 years. *Clin. Implant Dent. Relat. Res.* **2012**, *14*, 759–767. [\[CrossRef\]](#) [\[PubMed\]](#)
36. Qian, S.; Mo, J.; Si, M.-S.; Qiao, S.; Shi, J.-Y.; Lai, H. Long-term outcomes of osteotome sinus floor elevation with or without bone grafting: The 10-year results of a randomized controlled trial. *J. Clin. Periodontol.* **2020**, *47*, 1016–1025. [\[CrossRef\]](#)
37. Aparicio, C.; Perales, P.; Rangert, B. Tilted implants as an alternative to maxillary sinus grafting: A clinical, radiologic, and periosteal study. *Clin. Implant Dent. Relat. Res.* **2001**, *3*, 39–49. [\[CrossRef\]](#)
38. Fortin, T.; Isidori, M.; Bouchet, H. Placement of posterior maxillary implants in partially edentulous patients with severe bone deficiency using CAD/CAM guidance to avoid sinus grafting: A clinical report of procedure. *Int. J. Oral Maxillofac. Implants* **2009**, *24*, 96–102.
39. Pozzi, A.; Sannino, G.; Barlattani, A. Minimally invasive treatment of the atrophic posterior maxilla: A proof-of-concept prospective study with a follow-up of between 36 and 54 months. *J. Prosthet. Dent.* **2012**, *108*, 286–297. [\[CrossRef\]](#)
40. Antonoglou, G.; Stavropoulos, A.; Samara, M.; Ioannidis, A.; Benić, G.; Papageorgiou, S.; Sándor, G. Clinical Performance of Dental Implants Following Sinus Floor Augmentation: A Systematic Review and Meta-Analysis of Clinical Trials with at Least 3 Years of Follow-up. *Int. J. Oral Maxillofac. Implants* **2018**, *33*, e45–e65. [\[CrossRef\]](#)
41. Călin, C.; Petre, A.; Drafta, S. Osteotome-mediated sinus floor elevation: A systematic review and meta-analysis. *Int. J. Oral Maxillofac. Implants* **2014**, *29*, 558–576. [\[CrossRef\]](#) [\[PubMed\]](#)
42. Geminiani, A.; Tsigarida, A.; Chochlidakis, K.; Pappaspyridakos, P.V.; Feng, C.; Ercoli, C. A meta-analysis of complications during sinus augmentation procedure. *Quintessence Int.* **2017**, *48*, 231–240. [\[CrossRef\]](#)
43. Bacevic, M.; Compeyron, Y.; Lecloux, G.; Rompen, E.; Lambert, F. Intraoperative and postoperative outcomes of sinus floor elevation using the lateral window technique versus the hydrodynamic transalveolar approach: A preliminary randomized controlled trial. *Clin. Oral Investig.* **2021**, *25*, 5391–5401. [\[CrossRef\]](#) [\[PubMed\]](#)

44. Molina, A.; Sanz-Sánchez, I.; Sanz-Martín, I.; Ortiz-Vigón, A.; Sanz, M. Complications in sinus lifting procedures: Classification and management. *Periodontol. 2000* **2022**, *88*, 103–115. [[CrossRef](#)]
45. Küçükkurt, S.; Alpaslan, G.; Kurt, A. Biomechanical comparison of sinus floor elevation and alternative treatment methods for dental implant placement. *Comput. Methods Biomech. Biomed. Engin.* **2017**, *20*, 284–293. [[CrossRef](#)]
46. Brinkmann, J.C.-B.; García-Gil, I.; Pedregal, P.; Peláez, J.; Prados-Frutos, J.; Suárez, M. Long-Term Clinical Behavior and Complications of Intentionally Tilted Dental Implants Compared with Straight Implants Supporting Fixed Restorations: A Systematic Review and Meta-Analysis. *Biology* **2021**, *10*, 509. [[CrossRef](#)]
47. Cappare, P.; Ferrini, F.; Mariani, G.; Nagni, M.; Cattoni, F. Implant rehabilitation of edentulous jaws with predominantly monolithic zirconia compared to metal-acrylic prostheses: A 2-year retrospective clinical study. *J. Biol. Regul. Homeost. Agents* **2021**, *35* (Suppl. S1), 99–112. [[CrossRef](#)]
48. Yücesoy, T.; Gökteş, T. Evaluation of Sinus Pneumatization and Dental Implant Placement in Atrophic Maxillary Premolar and Molar Regions. *Int. J. Oral Maxillofac. Implants* **2022**, *37*, 407–415. [[CrossRef](#)]
49. Dagassan-Berndt, D.C.; Clemens, W.; Zitzmann, N.U.; Schulze, R.K. Influence of Three-dimensional Imaging on Implant Treatment Planning: Implant Diameter and Length. *J. Contemp. Dent. Pract.* **2018**, *19*, 704–711. [[CrossRef](#)]
50. Fortes, J.H.; de Oliveira-Santos, C.; Matsumoto, W.; da Motta, R.J.G.; Tirapelli, C. Influence of 2D vs 3D imaging and professional experience on dental implant treatment planning. *Clin. Oral Investig.* **2019**, *23*, 929–936. [[CrossRef](#)]
51. Dagassan-Berndt, D.C.; Zitzmann, N.U.; Walter, C.; Schulze, R. Implant treatment planning regarding augmentation procedures: Panoramic radiographs vs. cone beam computed tomography images. *Clin. Oral Implants Res.* **2016**, *27*, 1010–1016. [[CrossRef](#)] [[PubMed](#)]
52. Chmielewski, K.; Ryncarz, W.; Yüksel, O.; Goncalves, P.; Baek, K.-W.; Cok, S.; Dard, M. Image analysis of immediate full-arch prosthetic rehabilitations guided by a digital workflow: Assessment of the discrepancy between planning and execution. *Int. J. Implant Dent.* **2019**, *5*, 26. [[CrossRef](#)] [[PubMed](#)]
53. Schneider, D.; Sax, C.; Sancho-Puchades, M.; Hämmerle, C.H.; Jung, R.E. Accuracy of computer-assisted, template-guided implant placement compared with conventional implant placement by hand-An in vitro study. *Clin. Oral Implants Res.* **2021**, *32*, 1052–1060. [[CrossRef](#)]
54. Marei, H.F.; Abdel-Hady, A.; Al-Khalifa, K.; Al Mahalawy, H. Influence of surgeon experience on the accuracy of implant placement via a partially computer-guided surgical protocol. *Int. J. Oral Maxillofac. Implants* **2019**, *34*, 1177–1183. [[CrossRef](#)]
55. Han, X.-Y.; Xu, X.-M.; Ju, Y.-Q.; Tian, Z.-J. Analysis of implant placement accuracy using freehand in 68 consecutive patients with 97 implants. *Shanghai Kou Qiang Yi Xue* **2020**, *29*, 440–444. [[PubMed](#)]

Received: 2 March 2022 | Revised: 8 June 2022 | Accepted: 12 June 2022

DOI: 10.1111/jcpe.13685

## ORIGINAL ARTICLE

Journal of Clinical  
Periodontology

WILEY

## Soft and hard tissue changes after immediate implant placement with or without a sub-epithelial connective tissue graft: Results from a 6-month pilot randomized controlled clinical trial

Davide Guglielmi<sup>1</sup> | Giovanna Laura Di Domenico<sup>1</sup>  | Sofia Aroca<sup>2,3</sup>  |  
Fabio Vignoletti<sup>4,5</sup>  | Vincenzo Ciaravino<sup>1</sup> | Rossella Donghia<sup>6</sup> |  
Massimo de Sanctis<sup>1</sup> 

<sup>1</sup>Department of Periodontology, Università Vita-Salute San Raffaele, Milan, Italy

<sup>2</sup>26K Center for Clinical Research, Paris, France

<sup>3</sup>Department of Periodontology, Bern University, Bern, Switzerland

<sup>4</sup>Thinking Perio Research, Verona, Italy

<sup>5</sup>Department of Periodontology, Faculty of Odontology, Complutense University, Madrid, Spain

<sup>6</sup>Department of Epidemiology, National Institute of Gastroenterology "S. De Bellis" Research Hospital, Castellana Grotte, Italy

### Correspondence

Massimo de Sanctis, Department of Periodontology, Università Vita-Salute San Raffaele, Milan, Italy.  
Email: [massimodesanctis53@gmail.com](mailto:massimodesanctis53@gmail.com)

### Funding information

BioSAF IN Srl

### Abstract

**Aim:** The present pilot RCT aimed to investigate the influence of a connective tissue graft (CTG) in combination with the immediate implant placement (IIP) on hard and soft tissue healing, without a bone replacement graft in the gap between the implant and the socket walls.

**Materials and Methods:** Thirty patients requiring extraction of one anterior tooth (from premolar to premolar) were randomly assigned to one of the two treatment groups (test: IIP + CTG; control: IIP). Cone-beam computed tomography and optically scans were performed before tooth extraction and at 6-month follow-up. Then, DICOM files were superimposed in order to allow the evaluation of osseous ridge and buccal bone changes, while the superimposition of DICOM and Standard Tessellation Language files allowed for evaluating of soft tissue contour. For testing the differences between the two groups, the non-parametric test as Wilcoxon rank-sum test, was used.

**Results:** Twenty-six of the 30 enrolled patients attended the 6-month follow-up visit. The four patients of the control group that were lost to follow-up were analysed under the intention-to-treat principle. No statistically significant differences between the groups were observed for the vertical buccal bone resorption ( $p = .90$ ), as well as for the horizontal buccal bone resorption at all measured levels. Significant differences were found between the test and control groups in the horizontal dimensional changes of osseous ridge at the most coronal aspect ( $p = .0003$  and  $p = .02$ ). Changes in tissue contour were between  $-0.32$  and  $-0.04$  mm in the test group and between  $-1.94$  and  $-1.08$  mm in the control group, while changes in soft tissue thickness varied between 1.33 and 2.42 mm in the test group and between  $-0.16$  and 0.88 mm in the control group, with statistically significant differences for both variables at all measured levels. At 6 months, the mean volume increase was  $6.76 \pm 8.94$  mm<sup>3</sup> and  $0.16 \pm 0.42$  mm<sup>3</sup> in the test and control groups, respectively, with a statistically significant difference.

**Conclusions:** The findings of the present study indicate that the adjunct of a CTG at the time of IIP, without bone grafting, does not influence vertical bone resorption.

Within the limits of this study, it can be suggested that the adjunct of a CTG at the time of IIP, without bone grafting, reduces the horizontal changes of the alveolar ridge. Moreover, it allows maintenance of the tissue contour due to an increase in soft tissue thickness.

#### KEYWORDS

bone changes, connective tissue graft, immediate implant placement, soft tissues management

#### Clinical relevance

*Scientific rationale for study:* No clinical study has evaluated the effect of a connective tissue graft (CTG) per se at the time of immediate implant placement (IIP). Hence, it is unknown whether the CTG may influence the hard and soft tissue changes that occur.

*Principal findings:* Minor dimensional changes in the horizontal ridge dimension were observed in the IIP + CTG group at the most coronal aspect. Moreover, a minor reduction in tissue contour was reported in the test group, due to a pronounced soft thickness gain.

*Practical implications:* IIP plus a CTG may be a valid treatment option, to compensate for hard tissue morphological changes and to maintain the tissue contour.

## 1 | INTRODUCTION

Immediate implants have shown to be a predictable treatment for the replacement of non-restorable teeth (Lang et al., 2012; Vignoletti & Sanz, 2014a, 2014b). The surgical protocol presents clear advantages in terms of reducing the number of interventions, and the overall treatment time. However, compromised aesthetic has been anticipated especially when utilized in the upper anterior maxilla (Sanz et al., 2010; Cosyn et al., 2013; Cecchinato et al., 2015). There are several factors that may influence aesthetic outcomes, being the buccal bone wall integrity and thickness (Sanz et al., 2010; Ferrus et al., 2010; Tomasi et al., 2010), implant position (Evans & Chen, 2008), and the use of bone grafts within the gap (Sanz et al., 2017), among the most relevant. Hence, it should be considered as a complex surgical procedure that should only be performed in case of ideal anatomic conditions (Tonetti et al., 2019). Several studies demonstrated that immediate implant placement (IIP) fails to prevent the horizontal and vertical ridge alterations following tooth extraction (Araujo et al., 2005; Discepoli et al., 2015; Vignoletti, Discepoli et al., 2012; Vignoletti & Sanz, 2014a, 2014b). Although several studies demonstrated that immediate implant placement (IIP) fails to prevent the horizontal and vertical ridge alterations following tooth extraction (Araujo et al., 2005; Discepoli et al., 2015; Vignoletti, Discepoli et al., 2012; Vignoletti & Sanz, 2014a, 2014b). Although it has been suggested that these bone dimensional changes are compensated by soft tissues during early healing (Chappuis et al., 2017), nevertheless the reduction of soft tissue contour on long-term follow-up may greatly affect the aesthetic outcome of the prosthetic reconstruction. In a recent study, Sanz-Martín et al. (2019) investigated the interplay between hard and soft tissues after flapless IIP in combination with a buccally inserted xenogeneic bovine bone graft and a xenogeneic porcine collagen matrix in the aesthetic area. The authors reported an overall horizontal osseous ridge resorption (ORR) of about 50% of the

original dimension. This was in part compensated by an increase in thickness of the buccal soft tissues. Notwithstanding this fact, a mean of  $0.67 \pm 0.65$  mm of linear horizontal soft tissue reduction as compared to baseline was observed.

Therefore, it becomes apparent that soft tissue management with the use of connective tissue graft (CTG) around implants is of utmost importance to mimic natural ideal conditions, and for this reason, it has become a topic of growing interest for clinicians.

To the best of the authors' knowledge, no randomized controlled clinical trial has compared the outcome of a CTG on buccal bone changes following immediate implant positioning without a bone replacement graft in the implant-socket gap.

Recently in the literature, there is a growing body of evidence suggesting that the soft tissue thickness can exert a protective activity towards bone resorption. This effect was proposed for implant inserted in healed sites, where the soft tissue thickness demonstrated an influence over crestal bone changes at 1 year (Linkevicius et al., 2009; Puisys & Linkevicius, 2015). In a recent systematic review with meta-analyses on the efficacy of soft tissue augmentation procedures and their impact on peri-implant health, authors stated that bilateral techniques with CTG or collagen matrix showed beneficial effects on marginal bone-level stability (Tavelli et al., 2021). Similar conclusions were described by De Angelis et al. (2021) in a systematic review of the effect of soft tissue augmentation on the clinical and radiographical outcomes following IIP: authors reported that a statistically significant reduced change of the marginal bone loss and vestibular recession is associated with soft tissue augmentation. Nevertheless, the 6th EAO Consensus on soft tissue management at implants stated that "the present scientific evidence does not consistently demonstrate a benefit of soft tissue augmentation procedures in terms of marginal bone level changes" (Thoma et al., 2021).

Therefore, the purpose of the present pilot RCT was to investigate the influence of a CTG in combination with the IIP



on hard and soft tissue healing, without a bone replacement graft in the gap between the implant and the socket walls. The primary objective was to evaluate radiologically the vertical buccal bone dimensional changes, whereas the secondary objectives were to evaluate horizontal dimensional changes of buccal bone and of osseous ridge and linear and volumetric soft tissue changes.

## 2 | MATERIALS AND METHODS

### 2.1 | Study design

The study was designed as a pilot randomized controlled clinical trial with a parallel design and single-blinded approach, performed at the Dental Department of San Raffaele Hospital (Milan, Italy). The study protocol was approved by the Ethical Committee of San Raffaele Hospital (with number of protocol "Winsix 1"—EC Reg. N. 71/INT/2017), registered on [ClinicalTrials.gov](https://clinicaltrials.gov) (NCT03784430) and performed in accordance with the Helsinki Declaration of Human Studies. All subjects gave written informed consent.

### 2.2 | Patient samples

Adults ( $\geq 18$  years of age) were screened on the basis of having a single hopeless tooth candidate for extraction in the maxillary or mandibular area (from second premolar to second premolar) in need of a single implant-supported fixed prosthetic rehabilitation.

Patients were selected on the basis of fulfilment of the following inclusion criteria:

- The presence of the intact walls of the socket after tooth extraction, or presenting a maximum of 3 mm of buccal dehiscence;
- The distance between interdental bone crest and buccal bone crest  $\leq 3$  mm after tooth extraction.

Patients were excluded if they had any of these conditions: general contraindications for dental and/or surgical treatments; inflammatory and autoimmune disease of oral cavity; uncontrolled diabetes; concurrent or previous immunosuppressant, bisphosphonate, or high-dose corticosteroid therapy; concurrent or previous radiotherapy of head area; smokers ( $>10$  cigarettes a day); pregnancy; or lactating women.

### 2.3 | Randomization, allocation concealment, blinding, and calibration

Patients were assigned to one of the two treatment groups with the use of computer-generated randomization table (test group: immediate implant + CTG; control group: immediate implant). Treatment assignment was concealed to the treating surgeon by opaque envelopes that were opened only after completion of tooth extraction and

final assessment of the feasibility of IIP. Clinical and radiographic measures and statistical analyses were performed blind with respect to treatment assignment.

For calibration of clinical measurements, the examiner (G.L.D.D.) measured the keratinized tissue width of 10 patients twice, at 1 week interval. After repeated measurements, the inter-class correlation coefficients for intra-examiner reliability were 0.958 (95% CI: 0.664, 0.955).

All radiographic measurements were carried out by one calibrated and blinded examiner (V.C.), who superimposed and measured baseline and 6-month cone-beam computed tomography (CBCT) and Standard Tessellation Language (STL) images of 10 randomly selected cases twice, at 1 week interval. After repeated measurements, the inter-class correlation coefficient was 0.978 (95% CI: 0.884–0.966).

### 2.4 | Study interventions

Surgeries were performed by one surgeon (D.G.) at the Dental Clinic of the San Raffaele Hospital.

After local anaesthesia, a buccal split-full-split-thickness envelope flap, as described for the treatment of multiple gingival recessions by Zucchelli and de Sanctis (2000), was elevated, and the tooth was extracted atraumatically.

The flap was incised according to the indications of Zucchelli and de Sanctis (2000), utilizing the site of implant positioning as the center of rotation of the flap. The mesial and distal anatomic papillae were maintained in place.

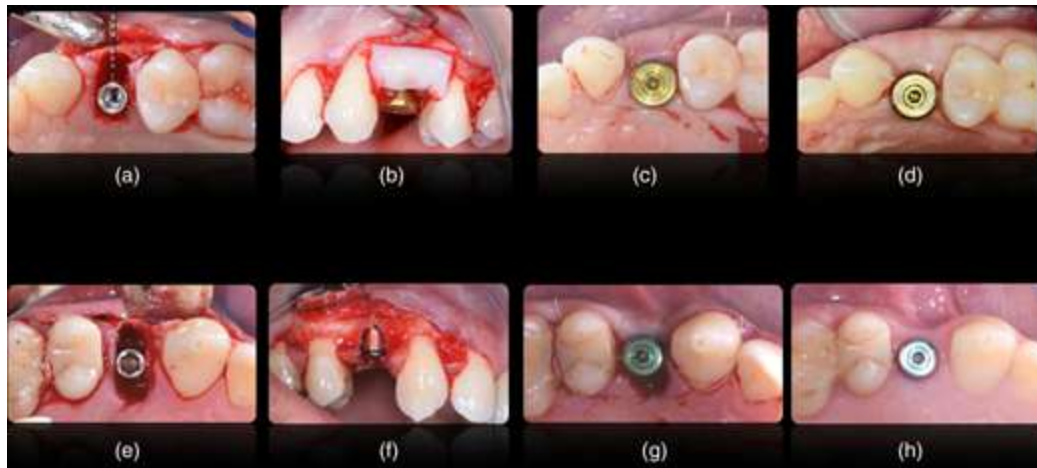
The osteotomy was prepared with the surgical drill of the surgical kit (Winsix, BioSAF IN Srl, Ancona, Italy) at 1200 rpm under saline irrigation. An implant (Winsix KE, Winsix, BioSAF IN Srl) was immediately inserted with 1 mm of its transmucosal portion positioned under the buccal bone crest, as suggested by previous pre-clinical and clinical studies (Caneva et al., 2010; Vignoletti & Sanz, 2014a, 2014b; Calvo-Guirado et al., 2018; Linkevicius et al., 2020).

In the test group, a CTG resulting from the extra-oral de-epithelialization of a free gingival graft harvested from the palate was positioned coronal to the buccal bone crest and anchored to the anatomic papillae. It was carefully positioned in contact with the implant surface, in such a way that it completely covered the buccal gap, and the buccal crest 2 mm in the apical direction.

In both groups of implants, healing abutments were positioned. The buccal flap was coronally advanced by means of deep and superficial split-thickness incisions and the flap was tightly adapted to the healing abutment. Modified sling sutures were performed to accomplish an accurate adaptation of the buccal flap and to stabilize every single surgical papilla over the inter-dental connective tissue bed of the anatomical papilla.

Examples of the two treatment groups are shown in Figure 1.

Patients were instructed to rinse twice a day (starting the day after surgery) with 0.2% chlorhexidine and received antibiotics (amoxicillin with clavulanic acid 1 g) twice a day for 6 days and analgesic medication (ibuprofen 600 mg) if needed.



**FIGURE 1** Intra-operative view of the two treatment modalities. Clinical case from the test group depicting: (a) the implant placed in the fresh extraction socket, (b) the connective tissue graft sutured to the anatomic papillae, (c) the suture of the flap, and (d) the implant site at 6 months of follow-up. Clinical case from the control group depicting: (e) the occlusal view of the implant placed in the fresh extraction socket, (f) the buccal view of the implant, (g) the suture of the flap, and (h) the implant site at 6 months of follow-up [Colour figure can be viewed at [wileyonlinelibrary.com](http://wileyonlinelibrary.com)]

No implant-supported temporary restorations were used for the first 6 months.

At 6 months after the implant placement, the patient returned for the clinical and radiographic evaluation.

## 2.5 | Outcomes and study power

The primary outcome of the study was the comparison of the vertical buccal bone resorption (VBRR) at 6 months following IIP in the test and control groups. The study was powered to detect a minimum clinically significant difference in radiographic changes of buccal bone height on CBCT of 1 mm using  $\alpha = .05$ , a power of 80%, and a hypothesized within-group sigma of 0.9 mm, obtained from previous studies (Jung et al., 2013). As a minimum, 14 patients per treatment arm were selected for power analysis calculation. To compensate for missing data and attrition, a sample size of 30 was selected.

Secondary outcomes included the following: (i) comparison of horizontal buccal bone resorption (HBRR) and osseous ridge resorption (ORR); (ii) comparison of changes in soft tissues parameters—width of keratinized mucosa, soft tissue contour, soft tissue thickness, soft tissue volume; and (iii) comparison of patient experience with the surgical procedures, using a visual analogue scale (VAS) score.

## 2.6 | Clinical measurements

Clinical measurements were performed at the time of implant placement by a blind and calibrated examiner (G.L.D.D.) to the nearest

millimetre using a periodontal probe (Hu-Friedy Diagnostic Probe UNC15 Qulix, Hu-Friedy Mfg. Co. Inc.).

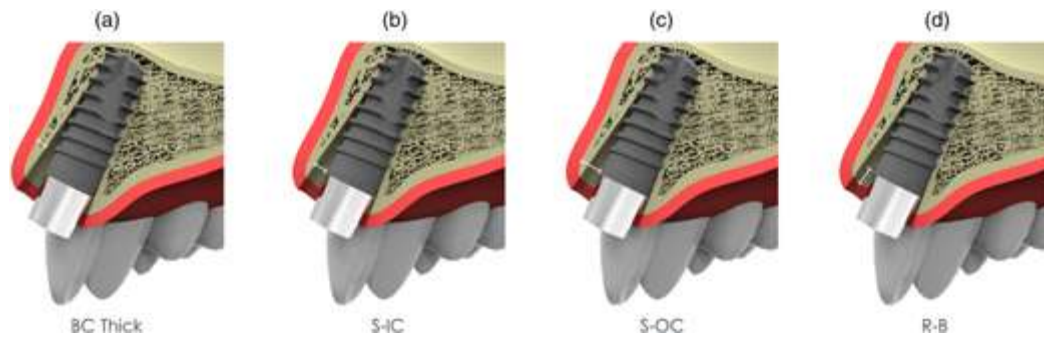
The width of keratinized tissue (KT width) was measured at the buccal aspect, prior to tooth extraction. After the extraction and flap elevation, the thickness of the buccal bone wall (BC thick), was measured 2 mm apical of the most coronal buccal bone crest using a calliper (Iwanson calliper, DP720; Bontempi snc, Quirurgical Bontempi, Barcelona, Spain).

After implant placement, a gap occurred between the implant surface and the buccal bone wall of the extraction socket. The following measurements were taken (Figure 2):

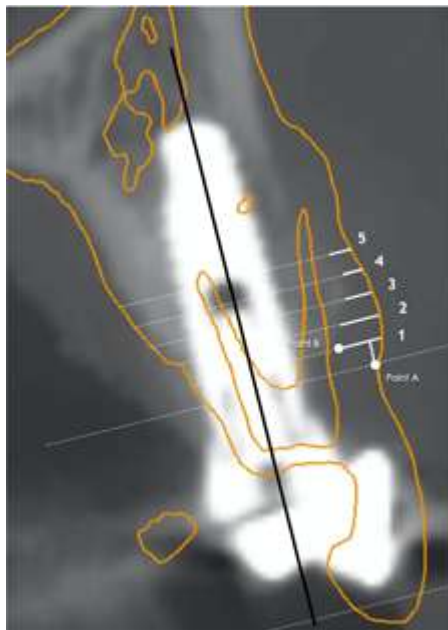
- S-IC, internal horizontal buccal gap dimension, that is, the width of the gap between the implant surface and the inner surface of buccal bone crest;
- S-OC, horizontal buccal crest dimension (bucco-lingual dimension), that is the distance between the implant surface and the outer surface of the buccal bone crest;
- R-B, vertical distance between the implant shoulder to top of the buccal bone crest. Since the implants were placed 1 mm below the buccal bone plate, this measure had a value of -1 mm for all the implants.

## 2.7 | Hard tissue measurements

For each patient, a CBCT scan (NewTom VGi evo, QR S.r.l., Verona) of the relevant site was performed prior to tooth extraction (BL) and



**FIGURE 2** Clinical measurements. (a) BC thick: Thickness of the buccal bone. (b) S-IC: Internal horizontal buccal gap dimension. (c) S-OC: Horizontal buccal crest dimension (bucco-lingual dimension). (d) R-B: Vertical distance between the implant shoulder to top of the buccal bone crest [Colour figure can be viewed at [wileyonlinelibrary.com](http://wileyonlinelibrary.com)]



**FIGURE 3** Superimposition of baseline DICOM (orange) and 6-month follow-up. Horizontal white lines represent the assessment of the horizontal buccal bone resorption (HBBR) at 1, 2, 3, 4, and 5 mm below the most coronal point of the buccal osseous ridge (point A). Vertical white line represents the measurement of vertical buccal bone resorption (VBBR) [Colour figure can be viewed at [wileyonlinelibrary.com](http://wileyonlinelibrary.com)]

6 months after implant placement (6M), to evaluate hard tissue dimensional changes.

Baseline DICOM files were first converted into an STL file and then superimposed to 6M DICOM file, by selecting common reference

points from the adjacent tooth surfaces. The screenshot representing the mesio-distal center of the dental implant was selected to perform linear measurements, using an image analysis software program (ImageJ, National Institutes of Health, MD, USA). All radiographic superimpositions and measurements were carried out as described by Sanz-Martín et al. (2019), by one calibrated and blinded examiner (V.C.).

The following landmarks were identified in the cross-sectional image:

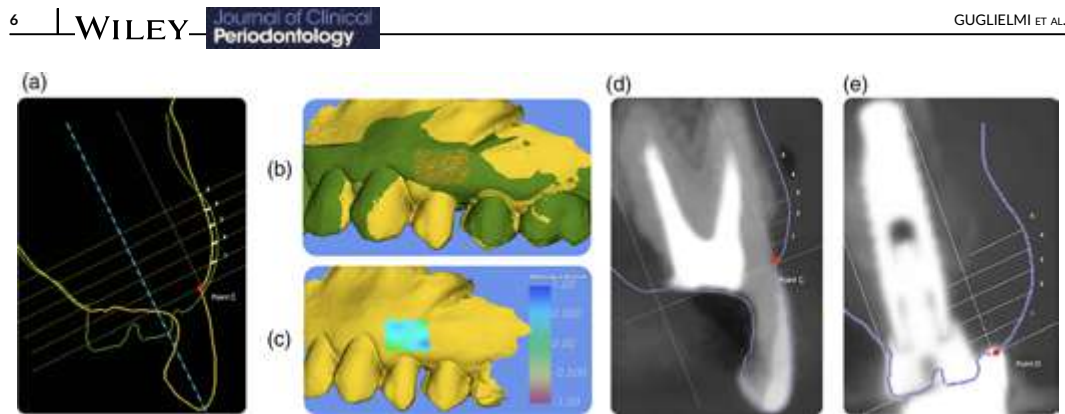
- point A, the most coronal point of the buccal crest of the baseline socket;
- point B, the most coronal point of the buccal crest at 6 months after implant insertion.

Five parallel lines were drawn perpendicular to a line coinciding with the longitudinal axis of the implant and at 1, 2, 3, 4, and 5 mm below to the point A and the following parameters were recorded (Figure 3):

- VBBR, which was calculated by measuring the vertical linear distance from point A to point B.
- HBBR, which was the horizontal linear distance between the outer surface of buccal bone at BL and that at 6M (measurements were expressed in mm and %);
- ORW, osseous ridge width, which was the horizontal linear distance from the outer surface of buccal bone to the outer surface of palatal/lingual bone, measured at baseline and at 6 months. The ORR in millimetres (mm) and in percentage (%ORR) were also calculated.

## 2.8 | Soft tissue measurements

The relevant upper/lower jaw segment was optically scanned using a 3D scanner (Cerec Omnicam, Dentsply Sirona, York, PA, USA) in order to create STL files and assess soft tissue dimensional changes occurring between BL examination and 6 months after implant placement.



**FIGURE 4** Soft tissue measurements. (a) Cross-sectional view of superimposition of baseline (yellow) and 6-month (green) Standard Tessellation Language (STL) files. White lines represent the linear measurements made 1, 2, 3, 4, and 5 mm below the gingival margins (point C). (b) Superimposition of baseline (yellow) and 6-month (green) STL files showing the area of interest for volumetric analysis (orange). (c) Superimposition showing gradients of volumetric variations. (d) Baseline DICOM and STL files superimposed allowing for the evaluation of baseline soft tissue thickness. White lines represent the soft tissue thickness 1, 2, 3, 4, and 5 mm below the gingival margin (point C). (e) Six-month DICOM and STL files superimposed allowing for the evaluation of baseline soft tissue thickness. White lines represent the soft tissue thickness 1, 2, 3, 4, and 5 mm below the gingival margin (point D) [Colour figure can be viewed at [wileyonlinelibrary.com](http://wileyonlinelibrary.com)]

### 2.8.1 | Soft tissue contour

STL file superimpositions and soft tissue dimensional changes measurements were executed by one calibrated and blinded examiner (V.C.), using a volume comparative software program (SMOP, Swissmeda AG, Zurich, Switzerland) and an image analysis software program (ImageJ, National Institutes of Health, Maryland, USA), as described by Sanz-Martin et al. (2019).

Linear measurements were performed by selecting the cross section representing the mesio-distal center of the tooth crown. A screenshot of the selected cross section was uploaded to five parallel lines drawn perpendicular to a line coinciding with the longitudinal axis of the tooth crown and at 1, 2, 3, 4, and 5 mm apical to the BL gingival margin (point C). Then, the buccal soft tissue contour changes ( $\Delta$  STC) were calculated by measuring at these different heights, the horizontal linear distance between the buccal soft tissue contour at BL to the one at 6M and were expressed in millimetres (Figure 4).

Volumetric measurements were performed by selecting an area of interest delimited apico-coronally by the gingival margin of the tooth and the mucogingival line and mesiodistally by a vertical line passing through the center of inter-dental papillae (Figure 4). The software calculated the volume changes in cubic millimetres.

### 2.8.2 | Soft tissue thickness

Superimposition of DICOM file, representing hard tissue volume, to STL file representing soft tissue contour, was used to measure the buccal soft tissue thickness in the two different treatment groups. DICOM-STL analysis were performed by one calibrated and blinded examiner (V.C.) adopting a methodology reported by Sanz-Martin et al. (2019).

DICOM files at BL and 6M were matched to STL file respectively at BL and 6M using the same digital imaging software mentioned for STL files superimposition (SMOP, Swissmeda AG, Zurich, Switzerland). Screenshots of the cross-section images representing the mesio-distal center of the tooth at BL and the mesio-distal center of the implant at 6M were then exported to the previously mentioned image processing software program (ImageJ, National Institutes of Health, MD, USA).

A common vertical axis was selected for both the BL and 6M cross-section images. Five parallel lines were drawn perpendicular to this axis at 1, 2, 3, 4, and 5 mm respectively apical to the BL and 6M gingival margin (points C and D, respectively). The buccal soft tissue thickness (STT) was then evaluated by measuring at these different heights, the linear distance between the buccal soft tissue outline to the buccal bone at BL and 6M and was expressed in millimetres (Figure 4).

## 2.9 | Statistical analysis

Mean and standard deviation for continuous variables were used as indices of centrality and dispersion of the variable distribution. For testing the differences between the two groups, the non-parametric test as Wilcoxon rank-sum test was used.

The Spearman rank correlation coefficient was used to test the strength and direction of association that may exist between the percentage of osseous ridge resorption (%ORR) and the following variables: BC thick, S-IC, S-OC, soft tissue total thickness (that includes STT at baseline and the CTG thickness), and CTG thickness. When testing the null hypothesis of no association, the probability level of error at two tails was 0.05.

All analyses were based on the intention-to-treat principle with mean imputation technique (ITT analysis, i.e., the mean value of a

variable is used in place of the missing data value for that same variable). Primary and secondary endpoints were also evaluated in the per-protocol collective (PP analysis).

Statistical computations were made using StataCorp 2021 (Stata Statistical Software: Release 17, StataCorp LLC, College Station, TX).

### 3 | RESULTS

#### 3.1 | Study population

Patient recruitment was conducted from November 2018 to December 2020. The causes for the tooth extraction were several and included root fracture, caries, root resorption, or endodontic failure.

Thirty patients were enrolled; of these, four patients of the control group did not complete the follow-up evaluation. Hence, a total of 26 patients attended the 6-month follow-up visit. The four patients who were lost to follow-up were analysed under the intention-to-treat principle. In this way, all 30 patients were included in the statistical analysis.

The sample consisted of 17 women and 13 men with a mean age of  $53.4 \pm 12.2$  years (range: 34–74 years) (Figure 5).

Twenty-four implants were placed in the maxilla and six in the mandible. Five implants (1 central incisor, 2 lateral incisors, 1 canine) were located at anterior sites and 23 at premolar sites. Twenty-four implants were 3.8 mm in diameter (the corresponding diameter of the endo-osseous portion was 4.0 mm), while six implants were 4.5 mm (the corresponding diameter of the endo-osseous portion was 4.7 mm) (Table 1). A CTG was applied in 15 implants (test group).

#### 3.2 | Clinical outcomes

At baseline, the thickness of the buccal bone measured at 2 mm from bone margin ranged from a minimum of 0.2 mm to a maximum of 1.9 mm, but did not reveal any statistically significant differences between the two treatment groups (ITT analysis—test group:  $0.84 [0.39]$  mm, control group:  $1.03 [0.49]$  mm,  $p = .16$ ; PP analysis—test group:  $0.84 [0.39]$  mm, control group:  $1.04 [0.58]$ ,  $p = .41$ ).

After IIP, the mean horizontal buccal gap (S-IC) was  $2.59 \pm 0.77$  and  $2.73 \pm 0.90$  mm, in the control and test group, respectively. The difference between the groups was not statistically significant ( $p = .70$ ).

All implants healed adequately without any complications.

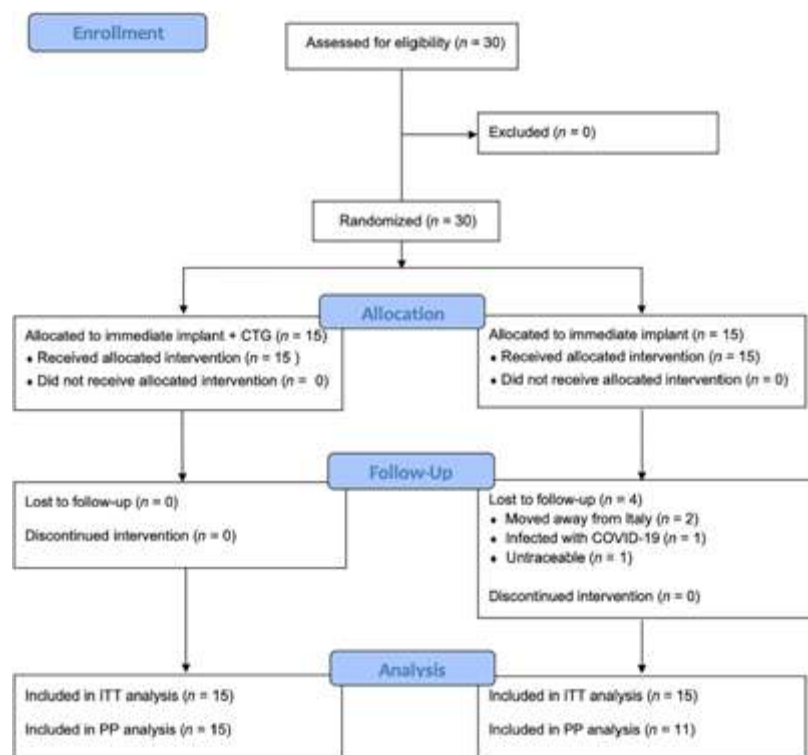


FIGURE 5 CONSORT flow diagram [Colour figure can be viewed at [wileyonlinelibrary.com](http://wileyonlinelibrary.com)]

**TABLE 1** Characteristics of the implants

	Per-protocol analysis		Intention-to-treat analysis	
	Control group (n = 11)	Test group (n = 15)	Control group (n = 15)	Test group (n = 15)
Arch (upper/lower)	9/2	13/2	12/3	12/3
Position (anterior/premolar)	0/11	3/12	2/13	3/12
Diameter (3.8/4.5 mm)	8/3	12/3	12/3	12/3
Length (9/11/13/15 mm)	2/6/3	0/6/7/2	2/10/3	0/6/7/2

**TABLE 2** Changes in horizontal and vertical dimensions of buccal bone (HBBR and VBBR) and in osseous ridge width (ORR) among the two treatment groups

	Per-protocol analysis			Intention-to-treat analysis		
	Control group (n = 11)	Test group (n = 15)	p value*	Control group (n = 15)	Test group (n = 15)	p value*
VBBR (mm)	-0.66 (0.75)	-0.66 (0.53)	.75	-0.66 (0.63)	-0.66 (0.53)	.90
HBBR 1 (mm)	-1.59 (0.63)	-1.36 (1.17)	.13	-1.59 (0.54)	-1.36 (1.17)	.05
HBBR 2 (mm)	-1.13 (0.47)	-0.89 (0.70)	.19	-1.13 (0.4)	-0.89 (0.70)	.10
HBBR 3 (mm)	-0.96 (0.44)	-0.73 (0.53)	.18	-0.96 (0.37)	-0.73 (0.53)	.13
HBBR 4 (mm)	-0.79 (0.40)	-0.69 (0.39)	.55	-0.79 (0.34)	-0.69 (0.39)	.37
HBBR 5 (mm)	-0.7 (0.40)	-0.66 (0.45)	.27	-0.78 (0.34)	-0.66 (0.45)	.14
HBBR 1 (%)	44.62 (19.86)	38.82 (26.56)	.55	44.6 (16.8)	38.82 (26.56)	.20
ORR 1 (mm)	-2.08 (0.65)	-1.16 (0.5)	.003**	-2.09 (0.53)	-1.16 (0.5)	.0003**
ORR 2 (mm)	-1.66 (0.95)	-1.03 (0.66)	.084	-1.66 (0.79)	-1.03 (0.66)	.02**
ORR 3 (mm)	-1.45 (0.89)	-0.95 (0.6)	.244	-1.45 (0.76)	-0.95 (0.6)	.10
ORR 4 (mm)	-1.13 (0.69)	-1.05 (0.68)	.721	-1.13 (0.59)	-1.05 (0.68)	.72
ORR 5 (mm)	-1.06 (0.58)	-0.94 (0.56)	.443	-1.06 (0.49)	-0.94 (0.56)	.31
ORR 1 (%)	22 (6)	14 (6)	.018**	22 (5)	14 (6)	.006**
ORR 2 (%)	17 (9)	11 (7)	.095	17 (7)	11 (7)	.04**
ORR 3 (%)	15 (8)	10 (6)	.239	15 (7)	10 (6)	.10
ORR 4 (%)	12 (7)	11 (7)	.678	12 (6)	11 (7)	.69
ORR 5 (%)	11 (6)	10 (5)	.467	11 (5)	10 (5)	.42

Abbreviations: HBBR, horizontal buccal bone resorption; ORR, osseous ridge resorption; VBBR, vertical buccal bone resorption.  
\*Wilcoxon rank-sum test (Mann-Whitney). \*\* Statistically significant.

### 3.3 | Hard tissue dimensional changes

#### 3.3.1 | Vertical changes

The mean loss in height (VBBR) amounted to  $-0.66 \pm 0.53$  mm in the test group and  $-0.66 \pm 0.53$  mm in the control group, with no significant differences ( $p = .9$ ). For results of the PP analysis, see Table 2.

#### 3.3.2 | Horizontal changes

The majority of the horizontal changes of the buccal bone (HBBR) occurred at 1 mm below the most coronal aspect of the buccal wall with similar changes between the two treatment groups (Table 2). Changes were in fact  $-1.59 \pm 0.54$  mm for the control group and  $-1.36 \pm 1.17$  mm for the test group, without statistically significant differences ( $p = .05$ ).

When evaluating the ORR, that is, the mean reduction of the alveolar crest in the bucco-lingual width (measured as difference

**TABLE 3** Spearman correlation between bone and soft tissue baseline dimensions and osseous ridge resorption at 1 mm (%)

	Per-protocol analysis (n = 26) %ORR 1*	Intention-to-treat analysis (n = 30) %ORR 1*
BC thick	0.04 (0.42)	-0.084 (0.68)
S-IC	0.14 (0.49)	0.19 (0.33)
S-OC	0.13 (0.53)	0.07 (0.70)
Soft tissue total thick	-0.464 (0.02)**	-0.597 (0.0012)**
CTG thick	-0.457 (0.02)**	-0.57 (0.002)**

Abbreviations: CTG; connective tissue graft; %ORR, percentage of osseous ridge resorption.

\* $\rho$ , Rho di Spearman and p value.

\*\*Statistically significant.

between ORW at baseline and ORW at 6 months), the results indicated  $-2.09 \pm 0.53$  mm and  $-1.16 \pm 0.5$  mm of horizontal dimensional changes at 1 mm and  $-1.66 \pm 0.79$  mm and  $-1.03 \pm 0.66$  mm at 2 mm, in control and test groups, respectively. These differences



**TABLE 4** Changes in linear and volumetric soft tissue contour ( $\Delta$  STC) and in soft tissue thickness ( $\Delta$  STT) among the two treatment groups

	Per-protocol analysis			Intention-to-treat analysis		
	Control group (n = 11)	Test group (n = 15)	p value*	Control group (n = 15)	Test group (n = 15)	p value*
$\Delta$ STC 1 (mm)	-1.94 (0.99)	-0.32 (0.97)	.002**	-1.94 (0.83)	-0.32 (0.97)	.0007**
$\Delta$ STC 2 (mm)	-1.85 (0.92)	-0.04 (0.74)	<.0001**	-1.85 (0.78)	-0.04 (0.74)	.00003**
$\Delta$ STC 3 (mm)	-1.57 (0.75)	0.11 (0.66)	<.0001**	-1.57 (0.63)	0.11 (0.66)	.00001**
$\Delta$ STC 4 (mm)	-1.30 (0.75)	0.18 (0.70)	.0002**	-1.30 (0.64)	0.18 (0.70)	.00006**
$\Delta$ STC 5 (mm)	-1.08 (0.80)	0.13 (0.81)	.003**	-1.08 (0.80)	0.13 (0.81)	.004**
$\Delta$ STC volume (mm <sup>3</sup> )	0.16 (0.49)	6.76 (8.94)	.002**	0.16 (0.42)	6.76 (8.94)	.0015**
$\Delta$ STT 1 (mm)	-0.16 (0.72)	1.47 (1.08)	.0001**	-0.16 (0.61)	1.47 (1.08)	.00005**
$\Delta$ STT 2 (mm)	0.12 (0.83)	2.04 (1.18)	.0002**	0.12 (0.70)	2.04 (1.18)	.00008**
$\Delta$ STT 3 (mm)	0.81 (1.14)	2.42 (1.63)	.007**	0.81 (0.96)	2.42 (1.63)	.003**
$\Delta$ STT 4 (mm)	0.88 (1.05)	2.07 (1.22)	.02**	0.88 (0.88)	2.07 (1.22)	.008**
$\Delta$ STT 5 (mm)	0.11 (0.90)	1.33 (1.17)	.01**	0.11 (0.76)	1.33 (1.17)	.005**

\*Wilcoxon rank-sum test (Mann-Whitney).

\*\*Statistically significant.

were statistically significant ( $p = .0003$  and  $p = .02$ , respectively). The corresponding values in percentage were  $22 \pm 5\%$  and  $14 \pm 6\%$  at 1 mm and  $17 \pm 7\%$  and  $11 \pm 7\%$  at 2 mm, in control and test groups, respectively (Table 2).

### 3.3.3 | Factors influencing bone resorption

The correlation analysis identified only a significant (negative) relationship between the resorption of osseous ridge width (% ORR) and the soft tissue total thickness, which includes STT at baseline and the CTG thickness ( $r = -0.464$ ,  $p = .02$ ) (Table 3). Scatterplots of the different correlations tested are shown in the Supplementary file 1.

## 3.4 | Soft tissues dimensional changes

### 3.4.1 | Tissue contour

At 6-month follow-up examination, a horizontal reduction in the dimensions of the tissue contours was observed in both test and control groups. This change in horizontal dimension was between  $-0.32$  and  $-0.04$  mm in the test group, and between  $-1.94$  and  $-1.08$  mm in the control group. The pairwise analysis showed statistically significant differences between the two groups at all levels (Table 4).

At 6 months, the mean volume increase was  $6.76 \pm 8.94$  mm<sup>3</sup> and  $0.16 \pm 0.42$  mm<sup>3</sup> in the test and control groups, respectively, with statistically significant difference ( $p = .0015$ ). For results of the PP analysis, see Table 4.

### 3.4.2 | Soft tissue thickness

After 6 months, the test group experienced significantly more tissue thickness gain at 1, 2, 3, 4, and 5 mm from the gingival margin than

the control group compared with baseline. This change ranged between 1.33 and 2.42 mm in the test group, and between  $-0.16$  and 0.88 mm in the control group (Table 4).

### 3.4.3 | KT width

At 6-month follow-up, the mean keratinized width was  $3.64 \pm 1.29$  mm and  $4.53 \pm 1.36$  mm in the control and test groups respectively, with no statistically significant difference ( $p = .14$ ). There was a gain in the dimension of KT, which was of  $0.14 \pm 1.28$  mm and of  $0.6 \pm 1.71$  mm in the control and test groups, respectively ( $p = .51$ ).

## 3.5 | Patient-reported outcomes

Post-operative pain and discomfort were evaluated with questionnaires using VAS at the 1-week post-operative appointment. Although both procedures were well tolerated, a significant difference was observed comparing the two procedures (ITT analysis—test group: 2.73 [1.62]; control group: 1.07 [0.70];  $p = .0009$ ; PP analysis—test group: 2.73 [1.62]; control group: 1.09 [0.83];  $p = .0049$ ).

## 4 | DISCUSSION

### 4.1 | Hard tissue dimensional changes

IIP was introduced in order to reduce the number of surgical procedures and potentially limit physiological reduction of the ridge dimensions following tooth extraction (Schulte & Heimke, 1976; Lazzara, 1989). The present study confirms findings from previous investigations that this procedure fails to prevent the horizontal and vertical ridge alterations (Araujo et al., 2005; Vignoletti, Discepoli, et al., 2012; Vignoletti,



Matesanz, et al., 2012; Vignoletti & Sanz, 2014a, 2014b; Discepoli et al., 2015).

Data of the current study reveal a reduction of the bone height at 6 months of 0.6 mm, both in test (SD 0.53 mm) and control groups (SD 0.75 mm). These data suggest that the height of the bone is only slightly modified during the healing phases, that is, a stable clinical bone-to-implant relation can be achieved even in the presence of a thin buccal socket wall (<1 mm). These data are in agreement with the study by Sanz et al. (2017), which reported 0.3 mm of vertical changes at the buccal crest both in the test and the control groups.

When evaluating horizontal ridge resorption, results of the present study show a reduction of  $2.09 \pm 0.53$  mm (22 ± 5%) for the control group and  $1.16 \pm 0.51$  mm (14 ± 6%) for the test group, with statistically significant differences. The amount of horizontal ORR observed in the control sites is comparable to the data reported by previous studies, namely Sanz et al. (2017) (16%).

On the other hand, results from the test group are similar to the results obtained with the use of a bone substitute graft in the gap between the implant surface and the bone wall: Sanz et al. (2017) reported horizontal mean changes of  $-1.26 \pm 1.75$  mm (11%), whereas Clementini et al. (2019) reported a change of  $-1.29 \pm 0.38$  mm (14.9 ± 4.9%). Therefore, it is conceivable that the CTG will exert a protective effect on the crestal bone loss, both augmenting the STT and providing a precise closure of the gap.

Neither initial buccal bone thickness nor horizontal gap width are significantly correlated with the amount of ORR. These results are in agreement with previous findings (Tomasi et al., 2010; Morimoto et al., 2015; Sanz et al., 2017). As a matter of fact, in the current study bucco-lingual dimensions of the alveolar crest were only influenced moderately by soft tissue total thickness, which includes the gingival thickness at baseline and the CTG thickness. This result is in contrast with the suggestion that the surgical intervention utilized for the application of the CTG could induce higher buccal bone loss because of the disruption in the vascularization between the mucosa and periosteum (Zuiderveld et al., 2021). On the contrary, the utilization of the proposed surgical technique, the modified coronal advanced flap with split-full-split approach, maintains the integrity of the periosteal vascularization in to the flap and it is ideal for flap closure that should be passive and tension-free. Also, this technique presents other advantages due to the absence of vertical incisions, which will improve both flap vascularization and stability (Zucchelli et al., 2009), while the coronal position of the margin will reduce the risk of flap shrinkage (Baldini et al., 2010). Also, it must be underlying that interdental papillae were not elevated, but maintained in position, this could be another factor could explain the buccal bone protective effect.

In the current study, the mean buccal bone loss found is  $44.6 \pm 16.8\%$  for the control group and  $38.82 \pm 26.56\%$  for the test group, without statistically significant difference. The control group data are similar to the results of Sanz et al., which showed

38% of buccal hard tissue loss in the non-grafted sites, and to those of Botticelli et al., which found 56% of buccal bone loss (Botticelli et al., 2004; Sanz et al., 2017).

Our results are not in accordance with Zuiderveld et al.: in their work the connective tissue grafted sites showed higher buccal bone loss resorption when compared to control ones (Zuiderveld et al., 2021). The difference between the two studies could be explained by the different surgical modalities (bone graft was used to fill the gap in both groups) and by the different measurement methodologies; in fact, the buccal bone resorption was measured from the neck of the implant, while in the current study the reference point for the measurement is the most coronal point of buccal bone.

#### 4.2 | Soft tissue findings

Volumetric measurements using STL data demonstrated a pronounced augmentation in tissue contour for the CTG group ( $6.76 \pm 8.94$  mm<sup>3</sup>) when compared to control sites ( $0.16 \pm 0.42$  mm<sup>3</sup>) at 6-month follow-up visit.

The observed loss of tissue volume that occurred in the control group may be due to the reduction in width of the osseous ridge, which was not completely compensated by the physiological increase in STT (Chappuis et al., 2015).

The tissue contour in the test group was maintained at all level of the measurements, including in the most coronal zone: this result can be explained due to the position of the CTG, which was sutured to the anatomical papillae, at the level of implant shoulder, so to cover the gap between implant and buccal bone wall, in contrast with Sanz-Martin et al.'s studies (2018, 2019).

When comparing the effect of a CTG on tissue contours after IIP, it should be taken into account that all previous investigations have utilized bone grafting in the gap. Nevertheless, results from the current study were comparable to a recent study by Jiang et al. (2020), which showed a similar contour reduction for the test groups, although bone grafting was used.

Because extraction process itself may cause transient changes in the dimension of the bone and soft tissues (Chappuis et al., 2015), in the present study, we considered data before tooth extraction as the baseline data to allow a more precise evaluation.

STT had a statistically significant increase for CTG sites when compared to control group at 6-month follow-up. Hence, it appears clear that the placement of a CTG maintained the tissue contour and compensated for bone resorption.

When considering the keratinized tissue dimension, it is interesting to notice that although the utilization of CTG, in the test group the KT width did not differ from the control group. This finding is in accordance with the study by Tavelli et al. (2021), which suggests that the absence of the effect could be due to the different composition of peri-implant soft tissues and vascularization when compared with teeth. The absence of the increment of KT could also be explained by the absence of shrinkage of the buccal flap.

For a correct interpretation of the present study, the following limitations need to be taken into account. The present RCT is a pilot study, due to the lack of previous articles at the time of this protocol design, which compare the effect of a CTG on radiographic vertical buccal bone loss after IIP. The primary outcome and the corresponding sample size calculation were based on vertical bone loss, which could explain the lack of significant differences in some secondary outcomes (HBRR) between both treatment groups.

At the same time though, significant differences were found for soft tissue findings, although the power analysis does not apply to them. Hence, these findings should be interpreted with caution until further studies are performed.

In addition, four subjects in the control group did not complete the follow-up and an intention-to-treat analysis was performed in order to overcome this bias.

Furthermore, the present results should be interpreted considering the limited sample size analysed and a skewed distribution of the implant location in the premolar region, which could have an influence on the evaluation of hard tissue changes.

Data showing whether the bone resorption and the soft tissue contour remain stable over the time, as well as data on the aesthetic appearance and acceptance by the patient, should be included in the future trials conducted with long-term follow-up on homogeneous sample.

## 5 | CONCLUSIONS

The findings of the present study indicate that the adjunct of a CTG at the time of IIP, without bone grafting, does not influence vertical bone resorption. Nevertheless, the use of CTG seems to reduce the horizontal changes of the alveolar ridge that occur. Moreover, it allows maintenance of the tissue contour due to an increase in STT. Nevertheless, data from the present study have to be considered cautiously due to the dimensional limitation. Further trials with long-term follow-up and a larger sample of patients are needed.

### AUTHOR CONTRIBUTIONS

**Davide Guglielmi**: data acquisition (surgery); study design. **Giovanna Laura Di Domenico**: data acquisition; data interpretation; manuscript revision. **Sofia Aroca**: study conception. **Fabio Vignoletti**: data acquisition. **Vincenzo Ciaravino**: data acquisition. **Rossella Donghia**: data analysis. **Massimo de Sanctis**: study design, manuscript revision, final approval.

### CONFLICT OF INTEREST

The authors report no conflicts of interests related to the study.

### DATA AVAILABILITY STATEMENT

The data that support the findings of this study are available from the corresponding author upon reasonable request.

### ETHICS STATEMENT


The project "Winsix 1" was approved by the Ethical Committee of San Raffaele Hospital (Milan, Italy) and it was partially supported by a grant from BioSAF IN Srl (Ancona, Italy).

### ORCID

**Giovanna Laura Di Domenico**  <https://orcid.org/0000-0001-5956-2161>

**Sofia Aroca**  <https://orcid.org/0000-0001-8927-0303>

**Fabio Vignoletti**  <https://orcid.org/0000-0002-4574-3671>

**Massimo de Sanctis**  <https://orcid.org/0000-0002-5915-566X>

### REFERENCES

- Araújo, M. G., da Silva, J. C. C., de Mendonça, A. F., & Lindhe, J. (2015). Ridge alterations following grafting of fresh extraction sockets in man. A randomized clinical trial. *Clinical Oral Implants Research*, 26(4), 407–412. <https://doi.org/10.1111/clr.12366>
- Araujo, M. G., Sukekava, F., Wennstrom, J. L., & Lindhe, J. (2005). Ridge alterations following implant placement in fresh extraction sockets: An experimental study in the dog. *Journal of Clinical Periodontology*, 32, 645–652. <https://doi.org/10.1111/j.1600-051X.2005.00726.x>
- Baldini, A., Zucchelli, G., & de Sanctis, M. (2010). A novel surgical technique for soft tissue in a aesthetic areas of the mouth at implant placement. *Journal de Parodontologia & d'Implantologie Orale*, 29(4).
- Botticelli, D., Berglundh, T., & Lindhe, J. (2004). Hard-tissue alterations following immediate implant placement in extraction sites. *Journal of Clinical Periodontology*, 31(10), 820–828. <https://doi.org/10.1111/j.1600-051X.2004.00565.x>
- Calvo-Guirado, J. L., López-López, P. J., Pérez-Albacete Martínez, C., Javed, F., Granero-Marín, J. M., Sánchez, M., de Val, J. E., & Ramírez Fernández, M. P. (2018). Peri-implant bone loss clinical and radiographic evaluation around rough neck and microthread implants: A 5-year study. *Clinical Oral Implants Research*, 29(6), 635–643. <https://doi.org/10.1111/clr.12775>
- Caneva, M., Salata, L. A., de Souza, S. S., Baffone, G., Lang, N. P., & Botticelli, D. (2010). Influence of implant positioning in extraction sockets on osseointegration: Histomorphometric analyses in dogs. *Clinical Oral Implants Research*, 21(1), 43–49. <https://doi.org/10.1111/j.1600-0501.2009.01842.x> PMID: 20070746
- Cecchinato, D., Lops, D., Salvi, G. E., & Sanz, M. (2015). A prospective, randomized, controlled study using OsseoSpeed™ implants placed in maxillary fresh extraction socket: Soft tissues response. *Clinical Oral Implants Research*, 26, 20–27.
- Chappuis, V., Araújo, M. G., & Buser, D. (2017). Clinical relevance of dimensional bone and soft tissue alterations post-extraction in esthetic sites. *Periodontology* 2000, 73(1), 73–83. <https://doi.org/10.1111/prd.12167>
- Chappuis, V., Engel, O., Shahim, K., Reyes, M., Katsaros, C., & Buser, D. (2015). Soft tissue alterations in esthetic postextraction sites: A 3-dimensional analysis. *Journal of Dental Research*, 94(9 Suppl), 1875–1935. <https://doi.org/10.1177/0022034515592869>
- Clementini, M., Agostinelli, A., Castelluzzo, W., Cugnata, F., Vignoletti, F., & De Sanctis, M. (2019). The effect of immediate implant placement on alveolar ridge preservation compared to spontaneous healing after tooth extraction: Radiographic results of a randomized controlled clinical trial. *Journal of Clinical Periodontology*, 46, 776–786. <https://doi.org/10.1111/jcpe.13125>
- Cosyn, J., DeBruyn, H., & Cleymaet, R. (2013). Soft tissue preservation and pink aesthetics around single immediate implant restorations: A 1-year prospective study. *Clinical Implant Dentistry and Related Research*, 15, 847–857.

- De Angelis, P., Manicone, P. F., Gasparini, G., De Angelis, S., Liguori, M. G., De Filippis, I., & D'Addona, A. (2021). Influence of immediate implant placement and provisionalization with or without soft tissue augmentation on hard and soft tissues in the esthetic zone: A one-year retrospective study. *BioMed Research International*, 5, 8822804. <https://doi.org/10.1155/2021/8822804>
- Discepoli, N., Vignoletti, F., Laino, L., de Sanctis, M., Munoz, F., & Sanz, M. (2015). Fresh extraction socket: Spontaneous healing vs. immediate implant placement. *Clinical Oral Implants Research*, 26, 1250–1255. <https://doi.org/10.1111/clr.12447>
- Evans, C. D., & Chen, S. T. (2008). Esthetic outcomes of immediate implant placements. *Clinical Oral Implants Research*, 19(1), 73–80. <https://doi.org/10.1111/j.1600-0501.2007.01413.x>
- Ferrus, J., Cecchinato, D., Pjetursson, E. B., Lang, N. P., Sanz, M., & Lindhe, J. (2010). Factors influencing ridge alterations following immediate implant placement into extraction sockets. *Clinical Oral Implants Research*, 21, 22–29.
- Jiang, X., Di, P., Ren, S., Zhang, Y., & Lin, Y. (2020). Hard and soft tissue alterations during the healing stage of immediate implant placement and provisionalization with or without connective tissue graft: A randomized clinical trial. *Journal of Clinical Periodontology*, 47(8), 1006–1015. <https://doi.org/10.1111/jcpe.13331>
- Jung, R. E., Philipp, A., Annen, B. M., Signorelli, L., Thoma, D. S., Hämmerle, C. H., Attin, T., & Schmidlin, P. (2013). Radiographic evaluation of different techniques for ridge preservation after tooth extraction: A randomized controlled clinical trial. *Journal of Clinical Periodontology*, 40(1), 90–98. <https://doi.org/10.1111/jcpe.12027>
- Lang, N. P., Pun, L., Lau, K. Y., Li, K. Y., & Wong, M. C. (2012). A systematic review on survival and success rates of implants placed immediately into fresh extraction sockets after at least 1 year. *Clinical Oral Implants Research*, 23(Suppl 5), 39–66. <https://doi.org/10.1111/j.1600-0501.2011.02372.x>
- Lazzara, R. G. (1989). Immediate implant placement into extraction sites: Surgical and restorative advantages. *International Journal of Periodontics and Restorative Dentistry*, 9(5), 332–343.
- Linkevicius, T., Apse, P., Grybauskas, S., & Puisys, A. (2009). The influence of soft tissue thickness on crestal bone changes around implants: A 1-year prospective controlled clinical trial. *The International Journal of Oral & Maxillofacial Implants*, 24(4), 712–719.
- Linkevicius, T., Puisys, A., Linkevicius, R., Alkimavicius, J., Gineviciute, E., & Linkeviciene, L. (2020). The influence of submerged healing abutment or subcrestal implant placement on soft tissue thickness and crestal bone stability: A 2-year randomized clinical trial. *Clinical Implant Dentistry and Related Research*, 22(4), 497–506. <https://doi.org/10.1111/cid.12903>
- Morimoto, T., Tsukiyama, Y., Morimoto, K., & Koyano, K. (2015). Facial bone alterations on maxillary anterior single implants for immediate placement and provisionalization following tooth extraction: A superimposed cone beam computed tomography study. *Clinical Oral Implants Research*, 26(12), 1383–1389. <https://doi.org/10.1111/clr.12480>
- Puisys, A., & Linkevicius, T. (2015). The influence of mucosal tissue thickening on crestal bone stability around bone-level implants. A prospective controlled clinical trial. *Clinical Oral Implants Research*, 26(2), 123–129. <https://doi.org/10.1111/clr.12301>
- Sanz, M., Cecchinato, D., Ferrus, J., Pjetursson, E. B., Lang, N. P., & Lindhe, J. (2010). A prospective, randomized-controlled clinical trial to evaluate bone preservation using implants with different geometry placed into extraction sockets in the maxilla. *Clinical Oral Implants Research*, 21(1), 13–21. <https://doi.org/10.1111/j.1600-0501.2009.01824.x>
- Sanz, M., Lindhe, J., Alcaraz, J., Sanz-Sanchez, I., & Cecchinato, D. (2017). The effect of placing a bone replacement graft in the gap at immediately placed implants: A randomized clinical trial. *Clinical Oral Implants Research*, 28(8), 902–910. <https://doi.org/10.1111/clr.12896>
- Sanz-Martin, I., Encalada, C., Sanz-Sánchez, I., Aracil, J., & Sanz, M. (2019). Soft tissue augmentation at immediate implants using a novel xenogenic collagen matrix in conjunction with immediate provisional restorations: A prospective case series. *Clinical Implant Dentistry and Related Research*, 21(1), 145–153. <https://doi.org/10.1111/cid.12696>
- Sanz-Martin, I., Permuy, M., Vignoletti, F., Nuñez, J., Muñoz, F., & Sanz, M. (2018). A novel methodological approach using superimposed micro-CT and STL images to analyze hard and soft tissue volume in immediate and delayed implants with different cervical designs. *Clinical Oral Implants Research*, 29(10), 986–995. <https://doi.org/10.1111/clr.13365>
- Schulte, W., & Heimke, G. (1976). The Tübingen immediate implant. *Die Quintessenz*, 27(6), 17–23.
- Tavelli, L., Barootchi, S., Avila-Ortiz, G., Urban, I. A., Giannobile, W. V., & Wang, H. L. (2021). Peri-implant soft tissue phenotype modification and its impact on peri-implant health: A systematic review and network meta-analysis. *Journal of Periodontology*, 92(1), 21–44. <https://doi.org/10.1002/JPER.19-0716>
- Thoma, D. S., Cosyn, J., Fickl, S., Jensen, S. S., Jung, R. E., Raghoobar, G. M., Rocchietta, I., Rocuzzo, M., Sanz, M., Sanz-Sánchez, I., Scarlat, P., Schou, S., Stefanini, M., Strassling, M., & Bertl, K. (2021). Soft tissue management at implants: Summary and consensus statements of group 2. The 6th EAO consensus conference 2021. *Clinical Oral Implants Research*, 32(Suppl. 21), 174–180. <https://doi.org/10.1111/clr.13798>
- Tomasi, C., Sanz, M., Cecchinato, D., Pjetursson, B., Ferrus, J., Lang, N. P., & Lindhe, J. (2010). Bone dimensional variations at implants placed in fresh extraction sockets: A multilevel multivariate analysis. *Clinical Oral Implants Research*, 21, 30–36. <https://doi.org/10.1111/j.1600-0501.2009.01848.x>
- Tonetti, M. S., Jung, R. E., Avila-Ortiz, G., Blanco, J., Cosyn, J., Fickl, S., Figuero, E., Goldstein, M., Graziani, F., Madianos, P., Molina, A., Nart, J., Salvi, G. E., Sanz-Martin, I., Thoma, D., Van Assche, N., & Vignoletti, F. (2019). Management of the extraction socket and timing of implant placement: Consensus report and clinical recommendations of group 3 of the XV European workshop in periodontology. *Journal of Clinical Periodontology*, 46(Suppl 21), 183–194. <https://doi.org/10.1111/jcpe.13131>
- Vignoletti, F., Discepoli, N., Muller, A., de Sanctis, M., Munoz, F., & Sanz, M. (2012). Bone modelling at fresh extraction sockets: Immediate implant placement versus spontaneous healing. An experimental study in the beagle dog. *Journal of Clinical Periodontology*, 39, 91–97. <https://doi.org/10.1111/j.1600-051X.2011.01803.x>
- Vignoletti, F., Matesanz, P., Rodrigo, D., Figuero, E., Martin, C., & Sanz, M. (2012). Surgical protocols for ridge preservation after tooth extraction. A systematic review. *Clinical Oral Implants Research*, 23(Suppl 5), 22–38. <https://doi.org/10.1111/j.1600-0501.2011.02331.x>
- Vignoletti, F., & Sanz, M. (2014a). Immediate implants at fresh extraction sockets: From myth to reality. *Periodontology* 2000, 66(1), 132–152. <https://doi.org/10.1111/prd.12044>
- Vignoletti, F., & Sanz, M. (2014b). Immediate implants at fresh extraction sockets: From myth to reality. *Periodontology*, 2000(66), 132–152. <https://doi.org/10.1111/prd.12044>
- Zucchelli, G., & De Sanctis, M. (2000). Treatment of multiple recession-type defects in patients with esthetic demands. *Journal of Periodontology*, 71(9), 1506–1514. <https://doi.org/10.1902/jop.2000.71.9.1506>
- Zucchelli, G., Mele, M., Mazzotti, C., Marzadori, M., Montebugnoli, L., & De Sanctis, M. (2009). Coronally advanced flap with and without vertical releasing incisions for the treatment of multiple gingival recessions: A comparative controlled randomized clinical trial. *Journal of Periodontology*, 80(7), 1083–1094. <https://doi.org/10.1902/jop.2009.090041>
- Zuiderveld, E. G., van Nimwegen, W. G., Meijer, H. J. A., Jung, R. E., Muhlemann, S., Vissink, A., & Raghoobar, G. M. (2021). Effect of

connective tissue grafting on buccal bone changes based on cone beam computed tomography scans in the aesthetic zone of single immediate implants: A 1-year randomized controlled trial. *Journal of Periodontology*, 92, 553–561. <https://doi.org/10.1002/JPER.20-0217>

#### SUPPORTING INFORMATION

Additional supporting information can be found online in the Supporting Information section at the end of this article.

**How to cite this article:** Guglielmi, D., Di Domenico, G. L., Aroca, S., Vignoletti, F., Ciaravino, V., Donghia, R., & de Sanctis, M. (2022). Soft and hard tissue changes after immediate implant placement with or without a sub-epithelial connective tissue graft: Results from a 6-month pilot randomized controlled clinical trial. *Journal of Clinical Periodontology*, 1–13. <https://doi.org/10.1111/jcpe.13685>

**1 Digital Smile Designed Computer - Aided Surgery versus traditional Workflow in "All on Four" Rehabilitations: A Randomized Clinical Trial with 4 - Years Follow- Up**

F. Cattoni, L. Chirico, A. Merlone, M. Manacorda, R. Vinci and E.F.Gherlone  
International Journal of Environmental Research and Public Health - 26 Marzo 2021

---

**2 Peri-Implant Tissue Adaptation after Implant Rehabilitation with Shoulderless Abutments with 24 Months of Follow-Up**

L.Casula, A.Gillone, D.Musu  
Hindawi Case Reports in Dentistry - 8 Gennaio 2021



## Article

# Digital Smile Designed Computer-Aided Surgery versus Traditional Workflow in “All on Four” Rehabilitations: A Randomized Clinical Trial with 4-Years Follow-Up

Francesca Cattoni, Luca Chirico <sup>\*</sup>, Alberto Merlone, Michele Manacorda, Raffaele Vinci and Enrico Felice Gherlone

Department of Dentistry, IRCCS San Raffaele Hospital, 20132 Milan, Italy; cattonif@tiscali.it (F.C.); albertomerlone@tiscali.it (A.M.); micmanacorda@gmail.com (M.M.); raffaelevinci@libero.it (R.V.); gherlone.enrico@hrs.it (E.F.G.)

\* Correspondence: lucach31@gmail.com



**Citation:** Cattoni, F.; Chirico, L.; Merlone, A.; Manacorda, M.; Vinci, R.; Gherlone, E.F. Digital Smile Designed Computer-Aided Surgery versus Traditional Workflow in “All on Four” Rehabilitations: A Randomized Clinical Trial with 4-Years Follow-Up. *Int. J. Environ. Res. Public Health* **2021**, *18*, 3449. <https://doi.org/10.3390/ijerph18073449>

**Academic Editors:**  
Monika Lukomska-Szymanska and  
Jorma Virtanen

Received: 15 February 2021

Accepted: 23 March 2021

Published: 26 March 2021

**Publisher’s Note:** MDPI stays neutral with regard to jurisdictional claims in published maps and institutional affiliations.



**Copyright:** © 2021 by the authors. Licensee MDPI, Basel, Switzerland. This article is an open access article distributed under the terms and conditions of the Creative Commons Attribution (CC BY) license (<https://creativecommons.org/licenses/by/4.0/>).

**Abstract:** The aim of the present study was to evaluate and compare the traditional “All on Four” technique with digital smile designed computer-aided “All on Four” rehabilitation; with a 4-years follow-up. The protocol was applied to a total of 50 patients randomly recruited and divided in two groups. Digital protocol allows for a completely virtual planning of the exact position of the fixtures, which allows one to perform a flapless surgery procedure with great accuracy (mini-invasive surgery) and also it is possible to use virtually planned prostheses realized with Computer-Aided Design/Computer-Aided Manufacturing (CAD/CAM) (methods for an immediate loading of the implants. After 4 years from the treatments 98% of success were obtained for the group of patients treated with the traditional protocol and 100% for the digital protocol. At each time interval a significant difference in peri-implant crestal bone loss between the two groups was detected; with an average Marginal Bone Loss (MBL) at 4 years of  $1.12 \pm 0.26$  mm in the traditional group and  $0.83 \pm 0.11$  mm in the digital group. Patients belonging to the digital group have judged the immediate loading (92%), digital smile preview (93%), the mock-up test (98%) and guided surgery (94%) as very effective. All patients treated with a digital method reported lower values of during-surgery and post-surgery pain compared to patients rehabilitated using traditional treatment. In conclusion, the totally digital protocol described in the present study represents a valid therapeutic alternative to the traditional “All on Four” protocol for implant-supported rehabilitations of edentulous dental arches.

**Keywords:** dental implant; digital dentistry; full-arch rehabilitations; All on Four; implant survival; implant-prosthetic restorations

## 1. Introduction

The therapeutic efficacy of rehabilitations based on the use of a reduced number of implants, with a high aesthetic and functional yield is now universally recognized [1–4]. Among the most adopted implantology protocols for the treatment of dental arches with moderate/severe bone atrophy, the “All on Four” technique continues to achieve great success among the scientific community [5–8]. This method involves the placement of four implants: two axial ones positioned in the anterior sector and two inclined at about 30–35° with respect to the occlusal plane in the lateral alveolar areas. This inclination allows it to distalize the implant emergency and to provide support to a prosthetic arch up to the first molar, and to avoid any damage the noble structures such as the maxillary sinus (upper arch) and the inferior alveolar vascular-nerve bundle (lower arch). This also prevents the bone regeneration procedure in the presence of severe atrophies [5]. In recent years, digital technologies have significantly changed the clinical dental practice with regards to diagnosis, prosthetic planning, guided surgery and implant-supported

rehabilitations [9–11]. With the recent introduction of software specifically programmed for clinicians and dental technicians, it is possible to combine the aforementioned procedures [12]. It is therefore possible to elaborate an implant-prosthetic rehabilitation, even in the more complex scenarios, through the use of a software, thus having the opportunity to previsualize the final result and consequently improve the communication between the clinician and the patient, and between the prosthodontist, surgeon and dental technician, also achieving a better quality of the project and the final result [13,14].

From 2014, clinicians of the Department of Dentistry of the Vita-Salute San Raffaele University have developed and applied a specific digital protocol, which involves digital implant-prosthetic planning, flapless-guided surgery and digital impression. Additionally, more than 4 years later, the results of this work highlighted the main differences between a digital and a traditional method.

The aim of the present study is therefore to describe and assess the two protocols on two homogeneous groups of patients, evaluating:

- Marginal bone level values (at 12, 24, 36 and 48 months) by radiographic evaluation;
- Implant and prosthetic complications and failures;
- Appreciation by the patient of the procedures used;
- Evaluation of operative and post-operative pain.

## 2. Materials and Methods

### 2.1. Patients Selection

The implant-prosthetic protocol was conducted including a population of 50 patients aged between 46 and 85, who underwent rehabilitation of the edentulous maxilla with a reduced number of implants, At the Department of Dentistry (San Raffaele-Milan), directed by Prof. E. F. Gherlone.

Twenty-five patients were randomly selected and subjected to the implant-prosthetic protocol with the digital method. The remaining twenty-five underwent the traditional “All on Four” protocol (Figure A5).

Inclusion criteria were: patients of any ethnicity over 18 years of age, male and female; patients with good general health, without chronic disease (immunosuppression, untreated coagulation problems, chemotherapy and radiotherapy, assumption of bisphosphonate drugs, cardiac conditions and uncompensated diabetes). The selected patient must have had at least one totally edentulous arch or with few hopeless elements, upper mouth opening wider than 50 mm, sufficient bone available for implant fixtures placement: for the edentulous maxilla the anatomical inclusion criterion was a residual ridge crest of a minimum of 4 mm wide buccolingually and higher than 10 mm high from canine to canine; for the lower maxilla a residual ridge crest at least 4 mm wide buccolingually and higher than 8 mm high in the intraforaminal area.

Exclusion criteria were: smoking and drug habits, pregnancy, irregular or thin bone crest and high smile line in the maxilla that would have needed bone reduction.

### 2.2. Clinical Procedure

#### 2.2.1. First Appointment

In the Dentistry department of the Vita-Salute University of San Raffaele, patients from both groups were examined in a preliminary oral examination.

During the appointment, after a detailed compilation of the medical and dental history, the clinicians would confirm the presence of an edentulous maxilla or treat the patients with few hopeless elements before the procedure with full mouth extractions and delivery of a temporary immediate total prosthesis.

After that, the clinician prescribed an initial orthopantomography to the patient and takes alginate impressions for the construction of occlusal rim, in order to produce a total diagnostic prosthesis correct from an aesthetic and functional point of view.

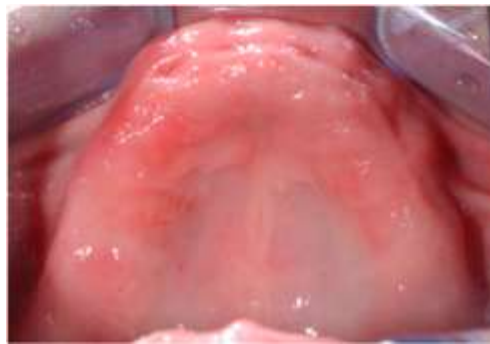
Once it was clear that a patient could be included in the clinical protocol, he or she signed a specific informed consent form for implant surgery with immediate loading.



Before the next session, the patients were divided into two groups through a randomization process: 25 patients underwent the digital protocol, and the remaining 25 was treated with the traditional protocol. Randomization processes occurred by lots in closed envelopes and were performed by a blinded operator.

#### 2.2.2. Second Appointment

The patient underwent a professional oral hygiene session of the antagonist arch. Photos of the edentulous jaw were taken (Figure 1) and the wax wall was “functionalized” using a traditional method.



**Figure 1.** Edentulous maxilla.

#### 2.2.3. Third Appointment (Traditional Protocol)

A prosthetic device structure and functionality test and an aesthetic/phonetic evaluation test were performed. Each patient filled out a one-dimensional Verbal Rating Scale (VRS) for the assessment of his appreciation of the aesthetic test (1—very effective, 2—effective and 3—ineffective) (Figure A1). All these procedures then led to the realization of a traditional provisional prosthetic device.

#### 2.2.4. Fourth Appointment (Traditional Protocol): Surgical Phase and Immediate Loading Prosthesis

One hour before surgery the patient received 2 g of amoxicillin (Zimox, Pfizer Italia, Latina-Italy), who continued to assume 1 g twice a day for the week after surgical procedure.

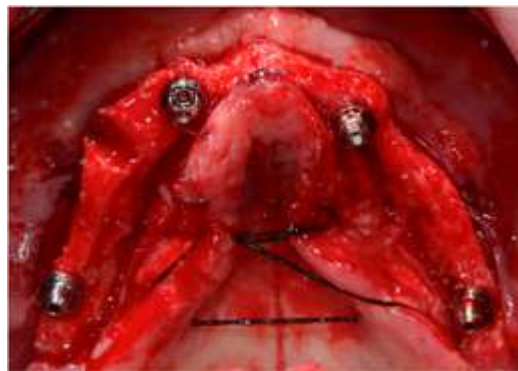After local anesthesia (4% articaine with 1:200.000 adrenaline), an incision was made starting on the center of the ridge alongside the entire length of the ridge, from the area of the first molar to the area of the first contralateral molar, with bilateral discharge incisions; a full-thickness mucoperiosteal flap was elevated and a bone remodeling were performed, if necessary to obtain a uniformly leveled bone crest.

Two-implant fixtures were inserted in the lateral alveolar areas, tilted by about 30–45 degrees relative to the occlusal plane. Then the two axial fixtures were inserted in the anterior sector (Figure 2).

Winsix TTx implants (Biosafin S.R.L., Ancona-Italy) with a diameter of 3.3 or 3.8 and length of 13 or 15 mm (Table 1) were used.

In the presence of bone with a well-represented trabecular portion, an under-preparation has been performed, to obtain a high primary stability, necessary for the following immediate loading. The insertion torque range of all implants was 35–55 N/m.

EATx Winsix extreme abutments (Biosafin S.R.L., Ancona, Italy) of 0°, 17° or 30° were screwed in at 10–20 N/m, in order to compensate for the lack of parallelism between the implants; the angle was chosen to obtain the position of the screw access hole at the occlusal or lingual level of the prosthesis. The access flap was adapted and sutured with absorbable 4-0 sutures.



**Figure 2.** Open flap surgery for implant positioning (traditional protocol).

**Table 1.** Implants' diameters (D) and lengths (L).

			L 11 mm	L 13 mm	L 15 mm
Traditional protocol (n = 100)	Upper maxilla (n = 60)	D 3.3	0	16	0
		D 3.8	0	27	17
	Lower maxilla (n = 40)	D 3.3	0	12	0
		D 3.8	0	19	9
Digital protocol (n = 100)	Upper maxilla (n = 68)	D 3.3	6	14	0
		D 3.8	12	32	6
	Lower maxilla (n = 32)	D 3.3	0	6	0
		D 3.8	4	22	0

At the end of the surgery, specific temporary abutments for immediate loading (EAX, Biosafin S.R.L., Ancona, Italy) were placed, mucosa was isolated with a dental dam and the prosthesis was adapted and relined directly into the patient's mouth with cold resin.

The prosthesis was then refined and polished in the on-site laboratory, where the palatal portion was removed. Finally, the prosthetic device was screwed back in the patient's mouth to obtain immediate loading of the implants.

#### 2.2.5. Third Appointment (Digital Protocol)

During the third visit, an occlusal rim was tested. The rim was previously functionalized according to traditional phonetic and aesthetic criteria.

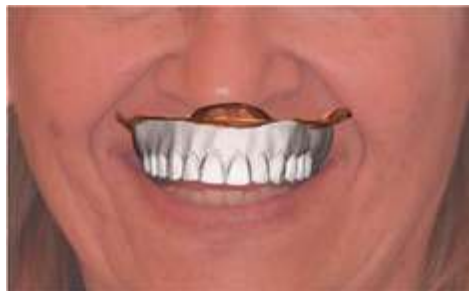The specific photographic protocol for digital planning, including intraoral and extraoral photos of the patient was performed. All the pictures were taken with the occlusal rim positioned inside the patient's mouth with landmarks positioned on the anterior portion of the rim. These landmarks allow for the alignment of the photograph and the Standard Triangle Language (STL) file inside the CAD Software (on both sides the canine line and the intermediate line between canine line and median line).

Two extraoral photos were also taken with a specific measurement marker positioned on the side of the patient's face. These will be used for the realization of a two-dimensional digital project of the new smile (smile design). A VRS one-dimensional scale (1—very effective, 2—effective and 3—ineffective) for assessing the patient's appreciation of the computerized previsualization of the prosthetic project was submitted to the patients (Figure A3).

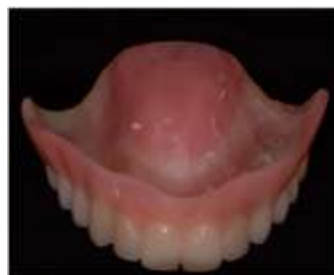Between the third and fourth appointments two-dimensional digital project of the new smile was realized using the Smile Lynx software (8853 S.P.A., Milan, Italy).

The scans of the edentulous model and the previously mentioned occlusal rim were obtained using a laboratory scanner (MyRay 3Di TS, Cefla, Italy). Then, the scans were

matched with the 2D digital project within the CAD software (CAD Lynx 8853 S.P.A., Milan, Italy), thus allowing the three-dimensional design of the prosthesis (Figure 3). The provisional total prosthesis complete with the palatal portion was milled in PMMA (Poly(methyl methacrylate)) by a five-axis CAD/CAM milling machine (Figure 4).



**Figure 3.** Three-dimensional digital project.



**Figure 4.** PMMA total provisional prosthetic device.

#### 2.2.6. Fourth Appointment (Digital Protocol)

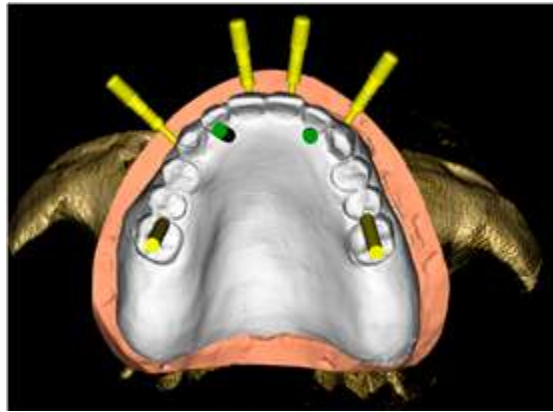
A mock-up test, using the provisional prosthesis, was performed trying the aesthetic appearance of the definitive prosthetic device. The patients then filled a one-dimensional VRS scale for the assessment of their appreciation of the mock-up test (Figure A1).

A specific device with the radiographic landmark (Evo-Bite with 3D-Marker, 3DIEMME, Como, Italy) was then adapted to the prosthesis directly in the oral cavity with radio-transparent silicon and delivered to the patient at the end of the appointment for the radiological exam.

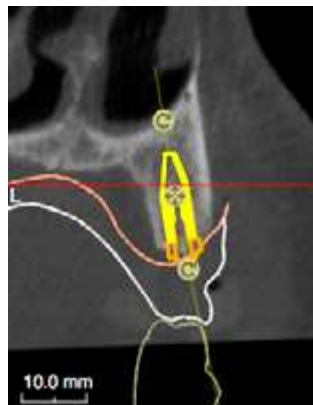
Various scans were then acquired with the same spatial coordinates: one of the stereolithographic model alone, one of the temporary prosthesis placed on the model and one of the prosthesis on the model with the Evo bite positioned on it (3D-Marker, 3DIEMME, Como, Italy).

A CBCT (Cone Beam Computed Tomography) was prescribed to the patient. This exam had to be taken with the patient wearing the temporary prosthesis with the Evo-Bite positioned on it, including an additional radiopaque marker to be used as a reference for the following radiologic evaluation (Scan Marker, 3DIEMME, Como, Italy).

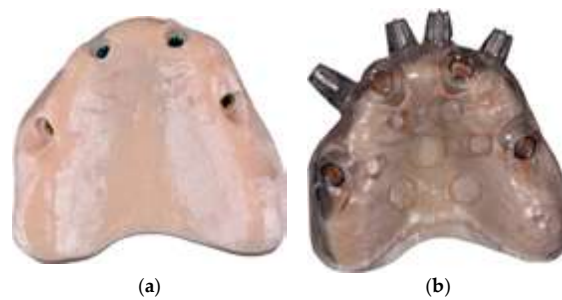
Using the RealGuide Implant Design Software (3DIEMME, Milan, Italy), the Digital Imaging and Communications in Medicine (DICOM) data of the patient's CBCT was then matched within the STL data of the previously mentioned scans, and the virtual position of the implants was planned, based on the aesthetic prosthetic project (Figures 5 and 6). The implant project was then sent to the laboratory for the realization of the stereolithographic model, which reported the exact sites for the placement of the analogs, and the surgical guide (3DIEMME, Milan, Italy) (Figure 7).



**Figure 5.** Virtual positioning of the implants, based on the aesthetic prosthetic project.



**Figure 6.** Virtual positioning of the implants, based on the aesthetic prosthetic project.

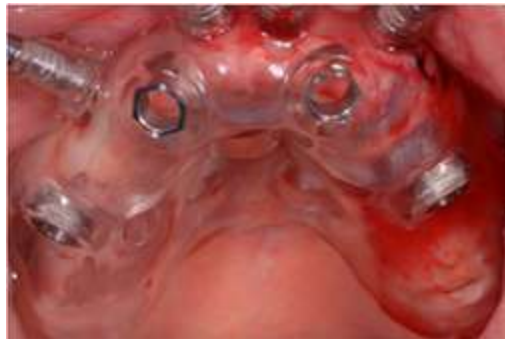

**Figure 7.** (a) Stereolithographic model with analogs. (b) Surgical guide.

#### 2.2.7. Fifth Appointment (Digital Protocol): Surgical Phase and Immediate Loading Prosthesis

An hour before the surgery, 2 g of amoxicillin+clavulanic acid were given to the patient, which continued to assume for the following week (1 g twice a day).

After local anesthesia (4% articaine with 1:200.000 adrenaline), the surgical template was positioned and fixed in the patient's oral cavity (Figure 8). The implants were inserted through the surgical guide, with the flapless technique, using a preordained sequence of drills dedicated to guided surgery (Figure 9). The two-implant fixtures were inserted in the lateral alveolar areas, tilted by about 30–45 degrees relative to the occlusal plane. Then the two axial fixtures were carried out in the anterior portion (Figure 1). Winsix TTx implants (Biosafin S.R.L., Ancona, Italy) with a diameter of 3.3 or 3.8, 11 or 13 mm length for the axial fixtures and 13 or 15 mm length for the tilted implants (Table 1) were used. All implants were inserted with 35–55 N/m torque.



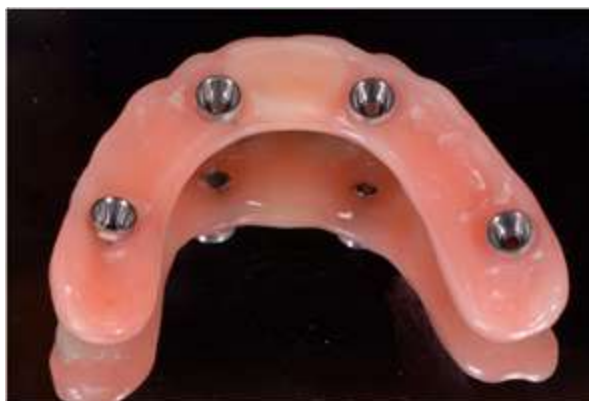**Figure 8.** Surgical template positioned and fixed in the oral cavity.



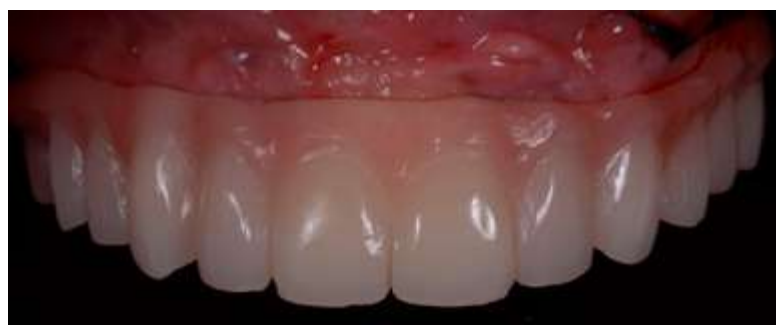**Figure 9.** Flapless surgery.

The EATx WinSix extreme abutments (Biosafin SRL, Ancona, Italy) of 0°, 17° or 30° were screwed on at 10–20 N/cm, previously selected according to the prosthetic-implant project within the specific software for guided surgery, to offset for the lack of parallelism between implants. The angle was chosen to obtain the position of the screw access hole at the occlusal or lingual level of the prosthesis.

Specific temporary abutments (EAX, Biosafin S.R.L., Ancona, Italy) were placed, and the mucosa was isolated with a dental dam sheet. Immediate loading was then performed, positioning the provisional prosthetic device that had adapted and relined directly with pink cold resin. The device was then refined in the laboratory, where the palatal portion was removed (Figure 10). Finally, the prosthetic device was screwed back in the patient's mouth (Figure 11).



**Figure 10.** Adapted, relined and refined provisional prosthesis.



**Figure 11.** Provisional prosthesis screwed in the patient's mouth.

After all the surgical-prosthetic procedures, a visual analog scale (VAS.) was submitted to both groups to evaluate pain (during and post surgery), with values from 0 (absent pain) to 10 (the maximum possible pain) (Figure A2).

#### 2.2.8. Final Prosthesis

Four months after the surgery, an impression was taken.

From the traditional group, prosthetic rehabilitations were manufactured using conventional pick-up impression. Impression transfers were screwed over the fixtures and the impression material used was Impregum (Impregum Penta, 3M Italia, Pioltello, Italy).

In the digital group, an intraoral scanner was used. Scan bodies (for TTx, Winsix, Biosafin S.R.L., Ancona, Italy) were screwed over the fixtures and splinted together. The intraoral scanner used was a Carestream CS 3500 (Version 2.5 Acquisition Software, Carestream Dental LLC, Atlanta, GA, USA).

Monolithic zirconia with vestibular ceramization final prostheses were delivered using CAD-CAM technology in both groups (Figure 12).

A final orthopantomography was prescribed to the patient (Figure 13).

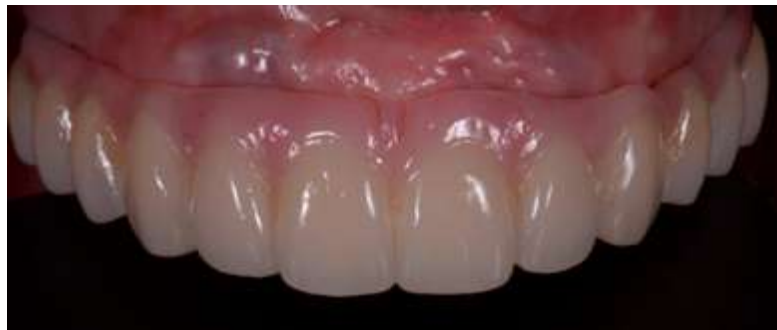

Figure 12. Monolithic zirconia final prosthesis.

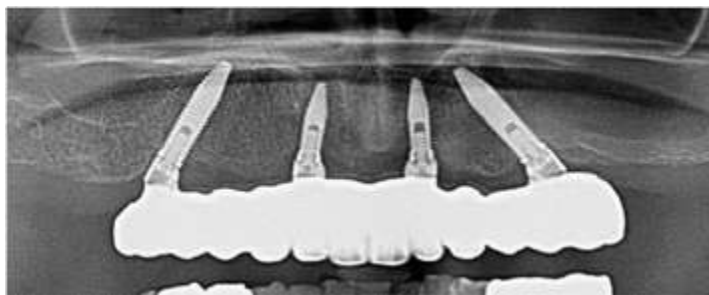

Figure 13. Final orthopantomography.

### 2.3. Follow-Up

Follow-up visits were performed at 12, 24, 36 and 48 months after the surgery. These appointments provided for radiographic analysis for the evaluation of marginal bone loss. The intraoral radiographs were made with the long cone parallel technique, performing the radiography perpendicular to the longitudinal axis of the implant, using a custom occlusal model to measure the level of the marginal bone. It was then possible to measure the difference in bone level through specific software (DIGORA 2.5, Soredex, Tuusula, Finland), calibrated for each image using the implant diameter calculated on the most coronal portion of the implant neck. The linear distance between the most coronal point of the BIC (bone–implant contact) and the coronal margin of the implant neck was measured on both mesial and distal sides, at the value closest to 0.01 mm, and then a mean value was calculated.

Besides, professional oral hygiene procedures were performed six months after implant placement and every four months after that.

### 2.4. Statistical Analysis

Dedicated software (GraphPad Prism 8.1.2, GraphPad Software Inc., California, United States) was used for statistical analysis. Peri-implant bone level measurements were reported as mean  $\pm$  standard deviation values at 12, 24, 36 and 48 months. Through the one-way ANOVA test ( $p < 0.05$ ), peri-implant bone loss was compared between the two groups at each time interval (12, 24, 36 and 48 months) and within each group by analyzing each time stage with the following ones.



### 3. Results

From March 2014 to January 2015, 50 patients were selected at the Department of Dentistry of the IRCCS Ospedale San Raffaele in Milan. A total of 200 Winsix TTx implants (Biosafin SRL, Ancona, Italy) of a diameter of 3.3 or 3.8 mm were positioned. Of them 100 were used in 25 cases of full-arch rehabilitations performed with the traditional All on Four method. The other 100 implants were used in 25 cases of full-arch rehabilitations performed with the digital method (Table 1).

All patients received a temporary prosthetic device and, after 6 months from the procedure, a definitive prosthetic device. All implants were inserted at a torque of at least 35 Ncm and were subjected to immediate loading.

#### 3.1. Implant Failure and Complications

Among the patients rehabilitated according to the traditional protocol, during the first 4 months after implant insertion, 2 failures were recorded, one in the upper maxilla and one in the lower maxilla, both concerning tilted implants (Table 2). The implant fixtures were immediately replaced without compromising the prosthetic function. In patients rehabilitated with the digital protocol 100% implant survival was achieved.

**Table 2.** Survival rate.

		Implants Positioned	Failed Implants	Implant Survival (%)
		Traditional Protocol		
Upper maxilla (n = 60)	Axial	30	0	100%
	Tilted	30	1	96.67%
Lower maxilla (n = 40)	Axial	20	0	100%
	Tilted	20	1	95.00%
		Digital protocol		
Upper maxilla (n = 68)	Axial	34	0	100%
	Tilted	34	0	100%
Lower maxilla (n = 32)	Axial	16	0	100%
	Tilted	16	0	100%

A patient treated with the traditional protocol showed discomfort, pain, swelling and the presence of pus three months after surgery, while no episode of peri-implantitis, pain, paresthesia or pus was observed among the patients rehabilitated according to the digital protocol (Table 3).

**Table 3.** Implant failure and complications.

Months	Traditional Protocol								Digital Protocol							
	12		24		36		48		12		24		36		48	
	n	%	n	%	n	%	n	%	n	%	n	%	n	%	n	%
Implant failures	2	2%	0	0	0	0	0	0	0	0	0	0	0	0	0	0
Peri-implantitis	1	1%	0	0	0	0	0	0	0	0	0	0	0	0	0	0
Fixture fractures	0	0	0	0	0	0	0	0	0	0	0	0	0	0	0	0
Unscrewing	3	3%	1	1%	0	0	1	1%	2	2%	1	1%	1	1%	1	1%
Provisional prosthetic fractures	2	n.a	/	/	/	/	/	/	2	n.a	/	/	/	/	/	/
Definitive prosthetic Chipping	1	n.a	0	0	0	0	0	0	0	0	1	n.a	0	0	0	0
Pus	1	n.a	0	0	0	0	0	0	0	0	0	0	0	0	0	0
Pain	1	n.a	0	0	0	0	0	0	0	0	0	0	0	0	0	0
Paresthesia	0	0	0	0	0	0	0	0	0	0	0	0	0	0	0	0

Two fractures of the provisional prosthetic device were recorded for each group. Occlusal screw loosening of provisional prosthesis was observed in five cases: three were treated with a traditional method and two with the digital method. In the definitive prostheses, a 24-month and 48-month unscrewing was reported in rehabilitations performed

with a traditional method, while in digitally treated patients an unscrewing at 24 months, one at 36 months and a further 48 (Table 3).

At 12 months, a case of chipping of the definitive device obtained using the traditional method was found. At 24 months a case of chipping of a definitive prosthesis obtained by the digital method was observed (Table 3). In both cases, direct repair of the existing prosthesis was performed.

### 3.2. Marginal Bone Level

The marginal bone level (MBL) was recorded during follow-up at 12, 24, 36 and 48 months (Table 4) through radiographic evaluation.

**Table 4.** Marginal bone level.

		12 Months	24 Months	36 Months	48 Months
		Traditional protocol			
		mm	mm	mm	mm
Upper maxilla	Axial ( $n = 30$ )	$1.02 \pm 0.33$	$1.08 \pm 0.34$	$1.10 \pm 0.32$	$1.11 \pm 0.32$
	Tilted ( $n = 30$ )	$1.05 \pm 0.27$	$1.08 \pm 0.26$	$1.11 \pm 0.25$	$1.13 \pm 0.24$
Lower maxilla	Axial ( $n = 20$ )	$1.04 \pm 0.28$	$1.05 \pm 0.26$	$1.06 \pm 0.26$	$1.08 \pm 0.25$
	Tilted ( $n = 20$ )	$1.05 \pm 0.29$	$1.09 \pm 0.25$	$1.12 \pm 0.23$	$1.13 \pm 0.23$
Total	$n = 100$	$1.04 \pm 0.29$	$1.08 \pm 0.28$	$1.10 \pm 0.27$	$1.12 \pm 0.26$
		Digital protocol			
Upper maxilla	Axial ( $n = 34$ )	$0.65 \pm 0.10$	$0.72 \pm 0.13$	$0.76 \pm 0.11$	$0.8 \pm 0.10$
	Tilted ( $n = 34$ )	$0.69 \pm 0.11$	$0.78 \pm 0.11$	$0.81 \pm 0.11$	$0.85 \pm 0.10$
Lower maxilla	Axial ( $n = 16$ )	$0.69 \pm 0.19$	$0.73 \pm 0.16$	$0.79 \pm 0.14$	$0.82 \pm 0.15$
	Tilted ( $n = 16$ )	$0.71 \pm 0.14$	$0.77 \pm 0.11$	$0.80 \pm 0.10$	$0.84 \pm 0.10$
Total	$n = 100$	$0.68 \pm 0.13$	$0.75 \pm 0.13$	$0.79 \pm 0.11$ *	$0.83 \pm 0.11$ *
<i>p</i> value (Total Traditional vs. Total Digital)		<0.0001	<0.0001	<0.0001	<0.0001

\*  $p < 0.05$  vs. 12 months digital group.

As for patients treated with the traditional protocol, the loss of peri-implant crestal bone over time has remained constant. At 48 months the mean value for bone loss for axial implants in the maxilla was  $1.11 \pm 0.32$  mm ( $n = 30$ ),  $1.13 \pm 0.24$  mm for tilted implants in the maxilla ( $n = 30$ ),  $1.08 \pm 0.25$  for axial implants in the jaw ( $n = 20$ ) and  $1.13 \pm 0.26$  for jaw tilted implants ( $n = 20$ ) (Table 4).

Bone loss in patients treated with the digital protocol at 48 months was  $0.8 \pm 0.10$  mm for axial jaw implants ( $n = 34$ ),  $0.85 \pm 0.10$  mm for tilted jaw implants ( $n = 34$ ),  $1.08 \pm 0.25$  mm for axial implants in the lower maxilla ( $n = 16$ ) and  $1.13 \pm 0.23$  mm for tilted implants in the lower maxilla ( $n = 16$ ) (Table 4).

The difference in the MBL between the two groups was statistically significant ( $p < 0.0001$ ) in each time interval. The difference within each group at different time intervals was significant only between the average MBL of the digital group at 12 months compared to the same group at 36 months ( $p = 0.0066$ ) and 48 months ( $p < 0.0001$ ).

### 3.3. Patients' Appreciation

Patients treated with the traditional protocol considered immediate loading with a temporary prosthesis to be very effective (95%). As for the mock-up test, 45% of the patients considered it very effective, 37% effective and 18% considered it ineffective. Traditional surgery was rated as very effective by 71% of patients and effective for the remaining 29% (Table 5). Patients treated with the digital protocol considered digital smile previsualization (93%), mock-up test (98%), guided surgery (94%) and immediate loading (92%) to be very effective (Table 5).

**Table 5.** Patients' appreciation.

	Very Effective	Effective	Ineffective
	Traditional protocol		
Mock-up test	45%	37%	18%
Traditional surgery	71%	29%	0%
Immediate loading	95%	5%	0%
	Digital protocol		
Digital smile previsualization	93%	7%	0%
Mock-up test	98%	2%	0%
Guided surgery	94%	6%	0%
Immediate loading	92%	8%	0%

At the end of the surgical procedures and after seven days (Figure A4), a visual analog scale (VAS) was submitted to the patients for the evaluation of postoperative pain. All patients belonging to the group treated with the digital method, which provides flapless surgery, reported a significantly lower value of pain compared to patients treated with the traditional method.

#### 4. Discussion

The aim of this study was to evaluate the survival rate of implant-prosthetic rehabilitations in patients with an edentulous arch, rehabilitated according to an entirely digital protocol, in order to understand the value of this approach in the prosthetic and surgical phases of treatment, comparing with the traditional "All on Four" method, already validated by numerous studies in the literature [5–8].

Capparé et al. and Gherlone et al. demonstrate that "All on Four" method can also be used in HIV-positive patients with a stable immune system [15–17].

The digital planning of the implant-prosthetic rehabilitation begins with the use of Smile Design, which allows one to obtain a two-dimensional project of the patient's future smile. This allows a correct planning of rehabilitation in aesthetic terms, improves the interaction between specialists and communication with the patient, all of whom have been shown to appreciate the previsualization, and therefore allows a higher quality of treatment, as already described by Coachman et al. in 2017 [18].

Patients' appreciation of digital aesthetic planning has also been described by Cattoni et al. in 2016, through the use of a VAS-type scale, which would measure the happiness of each subject with final aesthetic result of the placement of ceramic crowns and veneers in the anterior areas [19].

It has also been evaluated by Cattoni et al. in 2020 that there's a possible neurocognitive measure of how the perception of oneself can change as a significant consequence of aesthetic prosthetic rehabilitation reduced for all the other conditions, including self-portraying pictures before the intervention, and pictures of others. Most importantly, the study reports that, among all self-retracting faces in the different stages of the prosthetic rehabilitation, those portraying the subject in her/his actual physiognomy have a somewhat special status in eliciting selectively greater brain activation in the supplementary motor area (SMA) [20].

A specific software that allows the transition from the two-dimensional previsualization of the smile to a three-dimensional volumetric study and then a CAD-CAM processing for the realization of the prosthetic product were used, as also described by Coachman et al. in 2017 [18].

It was reported in the literature in 2014 by Kapos et al. that the survival rates of crowns, abutments and superstructures made with the CAD-CAM technology are similar to those of the same manufactured with traditional methods [21].

The digital construction of the prosthetic device can be accompanied by the digital planning of the surgical procedure, due to the matching between the data of the prosthetic project and the data obtained by the CBCT, as described by several authors [22,23].

Schneider et al. in 2009 and Vinci et al. in 2020, and other authors, showed the efficacy and accuracy of computer-assisted implant surgery [24,25].

The overlap of intra- and extra-oral photographs, models, intraoral scans and CBCT is recognized as a reliable procedure by the fifth Consensus Conference of the European Association of Osseointegration of 2015 [26].

Meloni et al. in 2010 in a retrospective analysis conducted on 15 patients, described the possibility of planning implant surgery in a guided and flapless way and with immediate loading [27]. This has also been confirmed by other authors such as Komiya et al. in 2012 [28].

The present study involves the use of a mucosal-supported surgical templates, and Gallardo et al. in 2016 and Vinci et al. in 2020 confirmed that this is a predictable procedure for implant placement [25,29].

It is widely known that a method that involves flapless implant insertion greatly reduces post-operative pain and discomfort during and after surgery, compared to open flap procedures, as also demonstrated in the present study [30,31].

Similarly, the main advantages of computer-assisted implant surgery, as already described by Hultin et al. in 2012, are the significant reduction of pain and postoperative discomfort for the patient, and the possibility of creating a temporary prosthesis to be used for the immediate functionalization of the implants [32].

The main disadvantages of guided surgery, as already described in 2009 by Schneider et al., Vinci et al. in 2020 and D'Haese et al. in 2009 are [24,25,33]:

- A potential damage to the bone due to insufficient irrigation;
- The inability to visualize the surgical anatomical landmarks;
- The increased risk of error in implant positioning with increasing degrees of maxillary bone atrophy;
- A disparity between the virtual plan and the actual position of the implant in the oral cavity at the end of the surgery;
- Difficulty in positioning the surgical template both during the CBCT Scan and during the surgical procedures.

As Malo et al. said in 2007, there are several contraindications, which include: insufficient bone volume, remaining teeth that interfere with the planning for implant placement, insufficient mouth opening to accommodate surgical instrumentation of at least 50 mm or bone reduction needed due to a high smile line in the maxilla, irregular bone crest or thin bone crest [34]. Inclusion criteria of the present study included all these contraindications, especially insufficient bone volume.

Accuracy and predictability of the intraoral scanner for implant full-arch rehabilitations are demonstrated by many authors so digital impressions is a viable alternative to analog techniques [35,36].

The levels of peri-implant bone loss obtained in the present study have proved to be similar to those reported by other authors in the literature, both for the group of patients treated with traditional surgery, and for the group treated with guided surgery [7,34,37].

The present clinical trial has some limitations, the main one is the follow-up. This type of studies would need longer follow-up. Further studies with a larger number of patients are also needed.

## 5. Conclusions

The obtained results show that the present protocol that is entirely digital, represents a valid therapeutic alternative to the traditional "All on Four" protocol for implant-supported rehabilitation of edentulous arches. However more long-term prospective clinical trials are needed to confirm the effectiveness of the surgical-prosthetic protocols used in this study and it is good not to underestimate the design difficulties: to be successful, a broad knowledge and mastery of topographical anatomy, radiographic imaging, surgical techniques and prosthetic procedures are essential.

It is necessary to select more carefully the clinical cases subject to both methods, as described previously in the inclusion and exclusion criteria.

Ultimately with the evolution of technologies, it is hoped that a digital workflow can be further simplified and increasingly within reach of each clinician.

**Author Contributions:** Conceptualization, F.C. and M.M.; methodology, F.C., L.C., A.M., M.M.; software, M.M. and A.M.; validation, F.C. and R.V.; formal analysis, L.C.; investigation, F.C. and M.M.; data curation, F.C., L.C., M.M.; writing—original draft preparation, F.C. and L.C.; writing—review and editing, F.C., L.C., M.M.; supervision, F.C., R.V., E.F.G.; project administration, F.C., R.V., E.F.G.; All authors have read and agreed to the published version of the manuscript.

**Funding:** This research received no external funding.

**Institutional Review Board Statement:** The study was conducted according to the guidelines of the Declaration of Helsinki and approved by the Ethics Committee of San Raffaele Hospital (approval number: CE/INT/10/2015).

**Informed Consent Statement:** Informed consent was obtained from all subjects involved in the study.

**Data Availability Statement:** Not applicable.

**Conflicts of Interest:** The authors declare no conflict of interest.

## Appendix A



The image shows a questionnaire form with the following fields and options:

- Logo of the institution in the top left and top right.
- Signature e Name \_\_\_\_\_
- Nome ed indirizzo dell'istituzione / servizio ospedaliero:
  - 1. Servizio di Radiologia
  - 2. Ufficio
  - 3. Ospedale
- Nome \_\_\_\_\_
- Data \_\_\_\_\_
- Nome completo di trattamento:
  - tradizionale gruppo
  - digital group

Figure A1. Questionnaire 1.

Cognome e Nome \_\_\_\_\_  
 Come valuti la tua strategia?  
 1. Molto efficace  
 2. Efficace  
 3. Inefficace  
 Come valuti il carico immediato fornito dalla prova subito dopo l'intervento?  
 1. Molto efficace  
 2. Efficace  
 3. Inefficace  
 Quanto è stato durato l'intervento (tempo)?  
 0 1 2 3 4 5 6 7 8 9 10  
 Nessuna prova Prova moderata Prova gestita  
 Nome \_\_\_\_\_  
 Data \_\_\_\_\_  
 Per la raccolta di informazioni:  
 Tradizionale group  
 Digital group

**Figure A2.** Questionnaire 2.

Cognome e Nome \_\_\_\_\_  
 Come valuti la prova di efficacia di gestione del servizio?  
 1. Molto efficace  
 2. Efficace  
 3. Inefficace  
 Nome \_\_\_\_\_  
 Data \_\_\_\_\_

**Figure A3.** Questionnaire 3.

Questionnaire 4

Scala: 0 (nessuna risposta) a 10 (molto alta risposta)

Parto-manual all'assessori:

- Tradizionale gruppo
- Digitale gruppo

Figure A4. Questionnaire 4.

Appendix B



CONSORT 2010 Flow Diagram

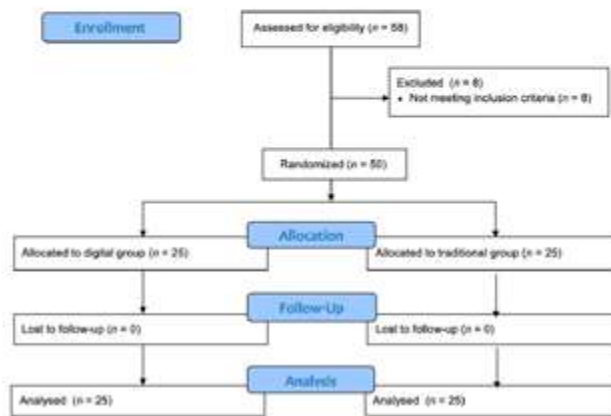


Figure A5. Consort flow diagram.



## References

1. Brånemark, P.I.; Hansson, B.O.; Adell, R.; Breine, U.; Lindström, J.; Hallén, O.; Ohman, A. Osseointegrated implants in the treatment of the edentulous jaw. Experience from a 10-year period. *Scand. J. Plast. Reconstr. Surg. Suppl.* **1977**, *16*, 1–132.
2. Duyck, J.; Van Oosterwyck, H.; Sloten, J.V.; De Cooman, M.; Puers, R.; Naert, I. Magnitude and distribution of occlusal forces on oral implants supporting fixed prostheses: An in vivo study. *Clin. Oral Implant. Res.* **2000**, *11*, 465–475. [[CrossRef](#)] [[PubMed](#)]
3. Capelli, M.; Zuffetti, F.; Del Fabbro, M.; Testori, T. Immediate rehabilitation of the completely edentulous jaw with fixed prostheses supported by either upright or tilted implants: A multicenter clinical study. *Int. J. Oral Maxillofac. Implant.* **2007**, *22*, 639–644.
4. Hinze, M.; Thalmair, T.; Bolz, W.; Wachtel, H. Immediate loading of fixed provisional prostheses using four implants for the rehabilitation of the edentulous arch: A prospective clinical study. *Int. J. Oral Maxillofac. Implant.* **2010**, *25*, 1011–1018.
5. Malo, P.; Rangert, B.; Nobre, M. “All-on-Four” immediate function concept with Brånemark system implants for completely edentulous mandibles: A retrospective clinical study. *Clin. Implant Dent. Res.* **2003**, *5* (Suppl. 1), 2–9. [[CrossRef](#)]
6. Schnitman, P.A.; Wöhrle, P.S.; Rubenstein, J.E.; DaSilva, J.D.; Wang, N.H. Ten-year results for Brånemark implants immediately loaded with fixed prostheses at implant placement. *Int. J. Oral Maxillofac. Implant.* **1997**, *12*, 495–503.
7. Crespi, R.; Vinci, R.; Capparé, P.; Romanos, G.E.; Gherlone, E. A clinical study of edentulous patients rehabilitated according to the “all on four” immediate function protocol. *Int. J. Oral Maxillofac. Implant.* **2012**, *27*, 428–434.
8. Engstrand, P.; Grondahl, K.; Öhrnell, L.-O.; Nilsson, P.; Nannmark, U.; Brånemark, P.-I. Prospective Follow-Up Study of 95 Patients with Edentulous Mandibles Treated According to the Brånemark Novum Concept. *Clin. Implant. Dent. Relat. Res.* **2003**, *5*, 3–10. [[CrossRef](#)] [[PubMed](#)]
9. Makkad, R.S.; Hamdani, S.; Agrawal, A. *Cone Beam Computed Tomography in Dentistry: Principle, Application & Diagnosis*; Lap Lambert Academic Publishing: Saarbrücken, Germany, 2012.
10. Jung, R.E.; Schneider, D.; Ganeles, J.; Wismeijer, D.; Zwahlen, M.; Hämmerle, C.H.F.; Tahmaseb, A. Computer technology applications in surgical implant dentistry: A systematic review. *Int. J. Oral Maxillofac. Implant.* **2009**, *24*, 92–109.
11. Joda, T.; Bragger, U. Complete digital workflow for the production of implant-supported single-unit monolithic crowns. *Clin. Oral Implant. Res.* **2013**, *25*, 1304–1306. [[CrossRef](#)] [[PubMed](#)]
12. Coachman, C.; Calamita, M.A.; Coachman, F.G.; Coachman, R.G.; Sesma, N. Facially generated and cephalometric guided 3D digital design for complete mouth implant rehabilitation: A clinical report. *J. Prosthet. Dent.* **2017**, *117*, 577–586. [[CrossRef](#)]
13. Gastaldi, G.; Gherlone, E.; Manacorda, M.; Ferrini, F.; Bova, F.; Vinci, R.; Cattoni, F. A 3-D CAD/CAM technique in full-arch implant supported rehabilitations: The Virtual Implant-Prosthetic Procedure (VIPP Technique). A prospective longitudinal study. *J. Osseointegr.* **2018**, *10*, 2–10.
14. Marradi, F.; Staderini, E.; Zimbalatti, M.A.; Rossi, A.; Grippaudo, C.; Gallenzi, P. How to Obtain an Orthodontic Virtual Patient through Superimposition of Three-Dimensional Data: A Systematic Review. *Appl. Sci.* **2020**, *10*, 5354. [[CrossRef](#)]
15. Capparé, P.; Teté, G.; Romanos, G.E.; Nagni, M.; Sannino, G.; Gherlone, E.F. The ‘All-on-four’ protocol in HIV-positive patients: A prospective, longitudinal 7-year clinical study. *Int. J. Oral Implantol.* **2019**, *12*, 501–510.
16. Gherlone, E.F.; Capparé, P.; Tecco, S.; Polizzi, E.; Pantaleo, G.; Gastaldi, G.; Grusovin, M.G. A Prospective Longitudinal Study on Implant Prosthetic Rehabilitation in Controlled HIV-Positive Patients with 1-Year Follow-Up: The Role of CD4+ Level, Smoking Habits, and Oral Hygiene. *Clin. Implant. Dent. Relat. Res.* **2015**, *18*, 955–964. [[CrossRef](#)]
17. Gherlone, E.F.; Capparé, P.; Tecco, S.; Polizzi, E.; Pantaleo, G.; Gastaldi, G.; Grusovin, M.G. Implant Prosthetic Rehabilitation in Controlled HIV-Positive Patients: A Prospective Longitudinal Study with 1-Year Follow-Up. *Clin. Implant. Dent. Relat. Res.* **2016**, *18*, 725–734. [[CrossRef](#)] [[PubMed](#)]
18. Coachman, C.; Calamita, M.; Sesma, N. Dynamic Documentation of the Smile and the 2D/3D Digital Smile Design Process. *Int. J. Periodontics Restor. Dent.* **2017**, *37*, 183–193. [[CrossRef](#)]
19. Cattoni, F.; Mastrangelo, F.; Gherlone, E.F.; Gastaldi, G. A New Total Digital Smile Planning Technique (3D-DSP) to Fabricate CAD-CAM Mockups for Esthetic Crowns and Veneers. *Int. J. Dent.* **2016**, *2016*, 1–5. [[CrossRef](#)] [[PubMed](#)]
20. Cattoni, F.; Teté, G.; Uccioli, R.; Manazza, F.; Gastaldi, G.; Perani, D. An fMRI Study on Self-Perception of Patients after Aesthetic Implant-Prosthetic Rehabilitation. *Int. J. Environ. Res. Public Health* **2020**, *17*, 588. [[CrossRef](#)] [[PubMed](#)]
21. Kapos, T.; Evans, C. CAD/CAM Technology for Implant Abutments, Crowns, and Superstructures. *Int. J. Oral Maxillofac. Implant.* **2014**, *29*, 117–136. [[CrossRef](#)]
22. Lee, C.Y.; Ganz, S.D.; Wong, N.; Suzuki, J.B. Use of cone beam computed tomography and a laser intraoral scanner in virtual dental implant surgery: Part 1. *Implant Dent.* **2012**, *21*, 265–271. [[CrossRef](#)] [[PubMed](#)]
23. Joda, T.; Bragger, U.; Gallucci, G. Systematic Literature Review of Digital Three-Dimensional Superimposition Techniques to Create Virtual Dental Patients. *Int. J. Oral Maxillofac. Implant.* **2015**, *30*, 330–337. [[CrossRef](#)]
24. Schneider, D.; Marquardt, P.; Zwahlen, M.; Jung, R.E. A systematic review on the accuracy and the clinical outcome of computer-guided template-based implant dentistry. *Clin. Oral Implant. Res.* **2009**, *20*, 73–86. [[CrossRef](#)]
25. Vinci, R.; Manacorda, M.; Abundo, R.; Lucchina, A.; Scarano, A.; Crocetta, C.; Muzio, L.L.; Gherlone, E.; Mastrangelo, F. Accuracy of Edentulous Computer-Aided Implant Surgery as Compared to Virtual Planning: A Retrospective Multicenter Study. *J. Clin. Med.* **2020**, *9*, 774. [[CrossRef](#)]
26. Hammerle, C.F.; Cordaro, L.; Van Assche, N.; Benic, G.I.; Bornstein, M.; Gamper, F. Digital technologies to support planning, treatment and fabrication processes and outcome assessments in implant dentistry. summary and consensus statements. The 4th EAO consensus conference, 2015. *Clin. Oral Implant. Res.* **2015**, *26*, 97–101.

27. Meloni, S.M.; De Riu, G.; Pisano, M.; Cattina, G.; Tullio, A. Implant treatment software planning and guided flapless surgery with immediate provisional prosthesis delivery in the fully edentulous maxilla. A retrospective analysis of 15 consecutively treated patients. *Eur. J. Oral Implantol.* **2010**, *3*, 245–251. [[PubMed](#)]
28. Komiyama, A.; Klinge, B.; Hultin, M. Treatment outcome of immediately loaded implants installed in edentulous jaws following computer-assisted virtual treatment planning and flapless surgery. *Clin. Oral Implant. Res.* **2008**, *19*, 677–685. [[CrossRef](#)]
29. Gallardo, Y.N.R.; Da Silva-Olivio, I.R.T.; Mukai, E.; Morimoto, S.; Sesma, N.; Cordaro, L. Accuracy comparison of guided surgery for dental implants according to the tissue of support: A systematic review and meta-analysis. *Clin. Oral Implant. Res.* **2017**, *28*, 602–612. [[CrossRef](#)]
30. Fortin, T.; Bosson, J.L.; Isidori, M.; Blanchet, E. Effect of flapless surgery on pain experienced in implant placement using an image-guided system. *Int. J. Oral Maxillofac. Implant.* **2006**, *21*, 298–304.
31. Yamada, J.; Kori, H.; Tsukiyama, Y.; Matsushita, Y.; Kamo, M.; Koyano, K. Immediate Loading of Complete-Arch Fixed Prosthesis for Edentulous Maxillae After Flapless Guided Implant Placement: A 1-Year Prospective Clinical Study. *Int. J. Oral Maxillofac. Implant.* **2015**, *30*, 184–193. [[CrossRef](#)] [[PubMed](#)]
32. Hultin, M.; Svensson, K.G.; Trulsson, M. Clinical advantages of computer-guided implant placement: A systematic review. *Clin. Oral Implant. Res.* **2012**, *23* (Suppl. 6), 124–135. [[CrossRef](#)]
33. D’Haese, J.; Van De Velde, T.; Elaut, L.; De Bruyn, H. A Prospective Study on the Accuracy of Mucosally Supported Stereolithographic Surgical Guides in Fully Edentulous Maxillae. *Clin. Implant. Dent. Relat. Res.* **2009**, *14*, 293–303. [[CrossRef](#)] [[PubMed](#)]
34. Malo, P.; Nobre, M.D.A.; Lopes, A. The use of computer-guided flapless implant surgery and four implants placed in immediate function to support a fixed denture: Preliminary results after a mean follow-up period of thirteen months. *J. Prosthet. Dent.* **2007**, *97* (Suppl. 6), S26–S34. [[CrossRef](#)]
35. Cappare, P.; Sannino, G.; Minoli, M.; Montemezzi, P.; Ferrini, F. Conventional versus Digital Impressions for Full Arch Screw-Retained Maxillary Rehabilitations: A Randomized Clinical Trial. *Int. J. Environ. Res. Public Health* **2019**, *16*, 829. [[CrossRef](#)] [[PubMed](#)]
36. Gherlone, E.F.; Ferrini, F.; Crespi, R.; Gastaldi, G.; Cappare, P. Digital Impressions for Fabrication of Definitive “All-on-Four” Restorations. *Implant. Dent.* **2015**, *24*, 125–129. [[CrossRef](#)] [[PubMed](#)]
37. Krekmanov, L.; Kahn, M.; Rangert, B.; Lindstrom, H. Tilting of posterior mandibular and maxillary implants of improbe prosthesis support. *Int. J. Oral Maxillofac. Implant.* **2000**, *15*, 405–414.

Hindawi  
Case Reports in Dentistry  
Volume 2021, Article ID 6689446, 8 pages  
<https://doi.org/10.1155/2021/6689446>



## Case Report

# Peri-Implant Tissue Adaptation after Implant Rehabilitation with Shoulderless Abutments with 24 Months of Follow-Up

Luca Casula <sup>1</sup>, Alex Gillone <sup>2</sup>, and Davide Musu <sup>3</sup>

<sup>1</sup>Oral Surgery Resident, Vita Salute University, Milan, Italy

<sup>2</sup>Division Director of Periodontology, East Carolina University, Greenville, USA

<sup>3</sup>Department of Endodontology, Academic Centre for Dentistry Amsterdam (ACTA), Amsterdam, Netherlands

Correspondence should be addressed to Davide Musu; [davidemusu.dds@gmail.com](mailto:davidemusu.dds@gmail.com)

Received 4 October 2020; Revised 13 December 2020; Accepted 28 December 2020; Published 8 January 2021

Academic Editor: Samir Nammour

Copyright © 2021 Luca Casula et al. This is an open access article distributed under the Creative Commons Attribution License, which permits unrestricted use, distribution, and reproduction in any medium, provided the original work is properly cited.

An 11-year-old girl presented with agenesis of the maxillary lateral incisors. Orthodontic treatment was performed to close the midline diastema and create adequate space between the central incisors and canines to replace the missing maxillary lateral incisors on both sides. Two-piece implants were placed, and shoulderless abutments were prepared following the “biologically oriented preparation technique” (BOPT) protocol. The soft tissues were allowed to heal directly on the prosthetic emergence profile of the interim crown restorations after implant exposure. Two months later, the gingival tissue adapted to the prosthetic components in a specular manner. No complications were noted at 24 months. The BOPT protocol, originally described for natural teeth, may be applied to dental implants with shoulderless abutments.

## 1. Introduction

Implant abutment morphology influences marginal bone loss and the biologic width of the peri-implant mucosa [1–5]. Souza et al. [4] reported that an implant abutment design with a wide and more divergent emergence profile induces an apical displacement of the peri-implant biologic width and an increased bone loss compared to an implant abutment with a narrower emergence profile. Agustín-Panadero et al. compared implants with divergent transmucosal collars to those with a convergent collar design and observed that the latter resulted in decreased bone loss [5]. A smaller abutment diameter, relative to the implant platform, seems to reduce the postrestorative crestal bone remodeling, which results in greater bone preservation [6, 7]. However, the role of the abutment design in marginal bone loss and peri-implant soft tissue stability is currently unknown [8, 9]. The crown is usually adapted against the horizontal finish line of the implant-supported cement-retained prosthesis, and together, they form the emergence profile of the implant-supported restoration [10]. The emergence profile of the implant-supported restoration is determined by the

contour of the crown as it relates to the adjacent tissues [11]. Similar to natural abutment teeth [12–14], a shoulderless implant abutment has a vertical area without a finish line where the crown margin is placed [15]. The absence of a defined horizontal finish line allows the interim restoration to move in an apical or coronal direction, allowing the tissue to adapt to the emergence profile of the crown restoration in a specular manner [12]. This concept, which was introduced with the biologically oriented preparation technique (BOPT) protocol [12–14], allows for the thickening of the soft tissues in the coronal direction and results in excellent esthetics with both the implants [16–19] and natural teeth [20, 21]. The use of the “adaptation forms and profiles concept” [12] in rehabilitative treatment involving natural teeth [12–14, 20, 21] and implants with shoulderless abutments [16–19] has been well documented; however, the adaptation of the gingiva to the emergence profile of prosthetic crowns has not been reported for the implant-supported cement-retained restorations methodically. This clinical case report describes a patient with agenesis of the maxillary lateral incisors. Orthodontic treatment was performed to create space for implant placement. Two implant-supported cement-

retained prostheses were provided, using a protocol similar to the BOPT for natural teeth [12]. The step-by-step gingival movement toward the crown emergence profile during tissue maturation is described up to two years after crown delivery.

## 2. Case Report

An 11-year-old girl was referred to the Department of Dentistry at the San Raffaele Hospital in Milan, Italy. The patient expressed dissatisfaction with smile, due to misaligned teeth and spaces between the anterior teeth. Radiographic examination revealed the agenesis of the maxillary lateral incisors (Figure 1(a)). A multidisciplinary treatment plan was formulated, which included orthodontic treatment for the midline diastema closure, focusing on creating adequate space between the central incisors and the canines to replace the missing maxillary lateral incisors on both sides. Two implant-supported cement-retained prostheses were planned at the end of the peak of adolescent growth for replacing the lateral incisors [22].

After orthodontic treatment, the patient wore a removable retainer to maintain the space gained for replacement of the lateral incisors with implants (Figure 1(b)). The maxillary implant surgery was performed with the aid of cone beam computed tomography (CBCT) when the patient was 19 years old. Two 3.3 mm diameter implants (Win-Six Biosafin, Italy) were placed in the area of the lateral incisors, with the implant platform positioned at the buccal crest level and with an insertion torque of 30 Ncm.

Immediate loading was avoided, and the patient wore a removable retainer during osseointegration of the implant [23]. Four months after implant placement, two periapical radiographs were taken confirming that the implant platforms were at the level of the bone crest (Figure 2(a)). After confirmation, we proceeded to the second stage of maxillary surgery. First, the two alginate impressions were made, and wax interocclusal records in maximal intercuspation were taken and sent to the dental laboratory for fabrication of the interim complete crown restorations. The gingival thickness at the implant site was determined to be 4 mm by inserting a K-file with an endodontic stop at the center of the edentulous ridges. Subsequently, the implants were exposed by raising a minimal full-thickness flap and moving the occlusal keratinized tissue to the buccal aspect.

The impression copings (Win-Six Biosafin, Italy) were connected to the implants, and an impression was made with vinyl polysiloxane material (Putty and Light Elite HD, Zhermack, Italy), using a perforated custom tray. Two implant analogs were connected to the copings inside the impression, and the cast was immediately poured using the type 4 dental stone. Two modifiable cylindrical shoulderless implant abutments (MF, Win-Six Biosafin, Italy) were connected to the analogs and adjusted (prepared without a finish line) directly on the cast to achieve the appropriate inclination for placement of the temporary crowns. The shoulderless abutments were prepared in the same manner as the natural abutment teeth in the BOPT protocol [12–14] (Figure 2(b)), and the

interim complete crown restorations were directly relined over the implant abutments on the implant cast, resulting in an augmented emergence profile (Figure 2(c)) [12]. The interim restorations were placed 3 mm coronally from the analogs that corresponded to the implant platforms (bone crest level), based on the previously measured gingival thickness (4 mm). This ensured that the adequate space remained for biologic width formation (Figure 2(c)) [24]. The temporary abutments were fixed to the implants, and the interim restorations were cemented using a temporary cement (Temp Bond, Kerr, USA). The keratinized mucosa taken from the occlusal space was supported by the overcontoured emergence profile [11] of the crown during the healing process on the buccal aspect (Figure 3).

After the interim restoration placement, the patient returned to the dental department periodically for 2 months during the healing process, which was documented using photographs. Four days after interim restoration placement, the keratinized tissue appeared inflamed and was in a more coronal position (Figure 3(c)) than before (Figure 3(b)). During the one week follow-up, the keratinized tissue appeared swollen, reddened, and more coronally elongated compared to that during the previous appointment (Figure 3(d)). During the second week of follow-up, the redness and swelling disappeared, and the keratinized tissue appeared to recede more apically (Figure 4(a)). At the 1-month follow-up, the gingival tissue appeared healthy and had adapted to the prosthetic emergence profile of the interim restoration in a specular manner (Figure 4(b)). At the 2-month follow-up, the interdental spaces were completely filled by the interdental papillae, and the crown margins were located 1 mm subgingivally (Figure 4(c)). The tissue appeared pink and healthy, even in the transmucosal area. On the occlusal view, the rounded profile of the gingiva was appreciable and specular to the emergence profile [11] of the interim crowns (Figure 5(a)). The adaptation of the tissue against the overcontoured emergence profile of the crowns was clearly appreciable on the lateral view (Figure 5(b)). After the previously described 2 months of tissue maturation, the patient visited the department for final impressions. The temporary restorations and analogs were removed, and the height of the transmucosal soft tissue was determined, with a dental probe placed between the implant platform and the gingival margin, to be 4 mm for both implants. The bone impression copings (Win-Six Biosafin, Italy) were connected to the implants, and an impression was made with vinyl polysiloxane material (Putty and Light Elite HD, Zhermack, Italy) using a perforated custom tray. An alginate impression of the mandibular arch and interocclusal record in maximal intercuspation were obtained and sent to the dental laboratory for the fabrication of two definitive implant abutments with a single zirconia framework for each. The dental technician was instructed to prepare wax patterns and cast customized titanium abutments without a finish line. The dental technician was also instructed to place the margins of the final crowns 1 mm subgingivally, according to the conditioned soft tissue during the interim stage. A reinforced collar was fabricated by the dental technician, to strengthen the feather-edged margin (Figure 5(c)) [10]. Thus, the ceramic

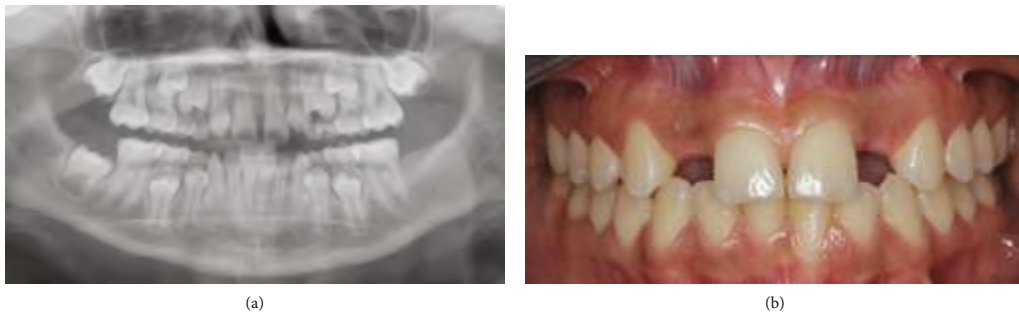

FIGURE 1: (a) Panoramic radiograph showing agenesis of both maxillary lateral incisors. (b) Facial view at the end of the orthodontic treatment showing the space maintained with the removable orthodontic retainer.

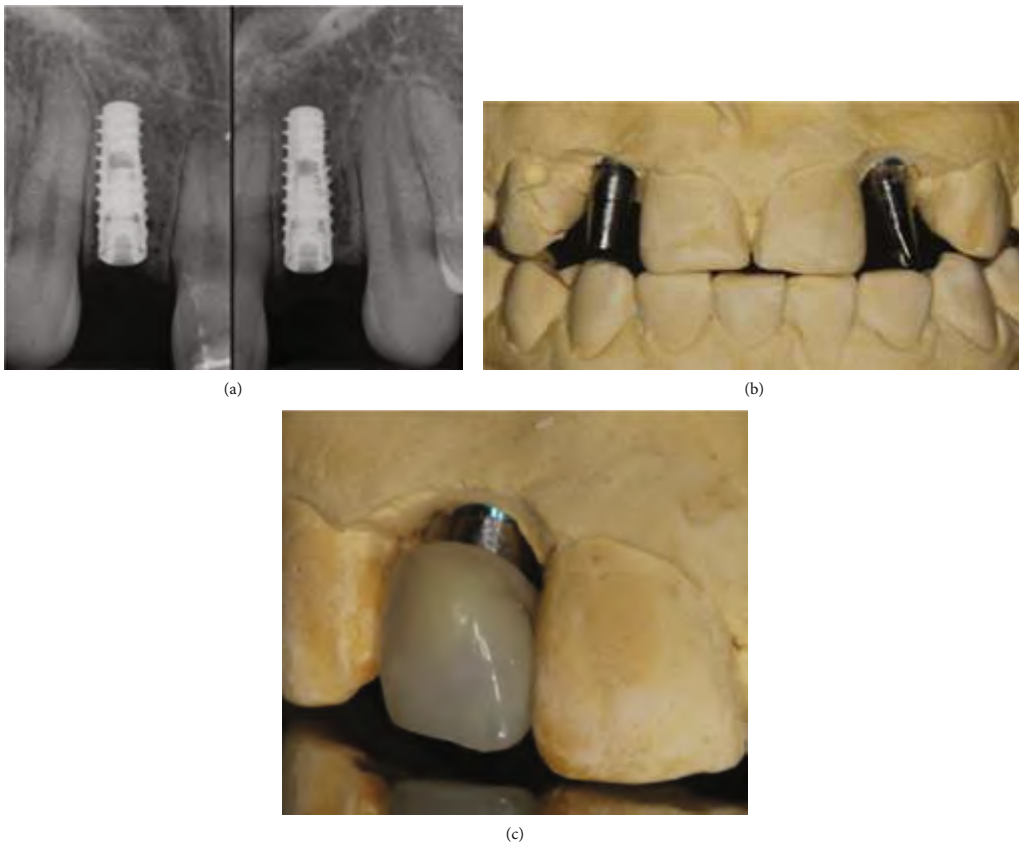


FIGURE 2: (a) Implants on lateral incisors positioned 4 months after placement. (b) The shoulderless abutments directly adjusted on the master cast. (c) The crown was placed 3 mm away from the analog (3 mm from the bone crest).

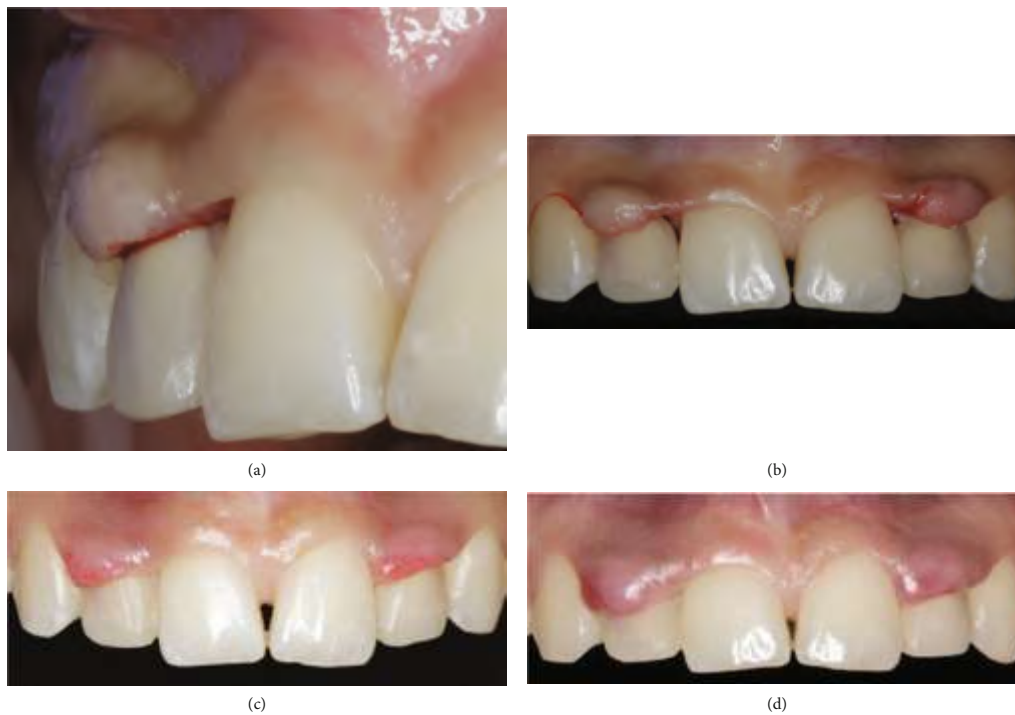


FIGURE 3: (a) The keratinized tissue moved from the occlusal side and was sustained by the augmented emergence profile of the crown. (b) Peri-implant mucosa formation and gingival adaptation along with the emergence profile of the crown restoration: inflammatory phase with the soft tissues sustained by the immediately placed crowns. (c) Soft tissues at four days of follow-up with minimal inflammation. (d) Soft tissues appeared inflamed and elongated in a more coronal position at one week of follow-up.

layering of the framework was performed along the reinforced collar of the chamfer, to prevent the fabrication of a crown with a thin ceramic margin.

At the following clinical visit, the abutments and zirconia frameworks were evaluated, and new interocclusal wax in maximal intercuspation was made to check the occlusion again. The accuracy of the framework's fit was confirmed clinically with dual-cured paste (Fit Checker Advanced, Gc Corporation, Japan). A framework transfer impression with polysiloxane material (Putty and Light Elite HD, Zhermack, Italy) was made, to capture the framework-soft tissue relationship. The impression was sent to the dental technician with a request that the final restorations be shaped in a manner that allowed the emergence profile to sustain the mature soft tissues. The final restorations were clinically checked and sent for the final glaze. At the final appointment, the finished crowns were cemented with temporary cement (Temp Bond, Kerr, USA), and the patient expressed satisfaction with the esthetics.

At the 24-month follow-up visit, no biological or technical complications were noted, and the gingiva appeared thick, pink, healthy, and completely adapted to the definitive restoration (Figure 6). The papillary filling was achieved in the interdental spaces. At the 24-month follow-up, minimal

bone remodeling of approximately 0.5 mm was detected, which was attributed to abutment installation and initial loading (Figure 6) [25].

### 3. Discussion

The healthy coexistence of dental restorations and the peri-implant structures is essential and is the primary goal of a prosthodontist. The peri-implant tissues should not bleed on probing, and a tight seal should exist between the peri-implant mucosa and the transmucosal component [25]. The abutment design for natural teeth and implants presents a well-defined horizontal finish line or a vertical area without a finish line for the crown margin [10, 26]. A vertical preparation without a finish line in natural abutment teeth [12] results in the formation of an overcontoured cervical portion of the prosthetic crown [27] and has been suspected to have serious implications for the periodontal health of the supporting tissues [28]. The BOPT protocol includes a prosthetic subgingival preparation of the natural abutment teeth without a finish line [12–14] and ensures a good periodontal condition [20, 21]. The “adaptation forms and profiles concept” [12] applied to the natural abutment teeth treated with BOPT [12–14] is applicable for implant-supported cement-retained



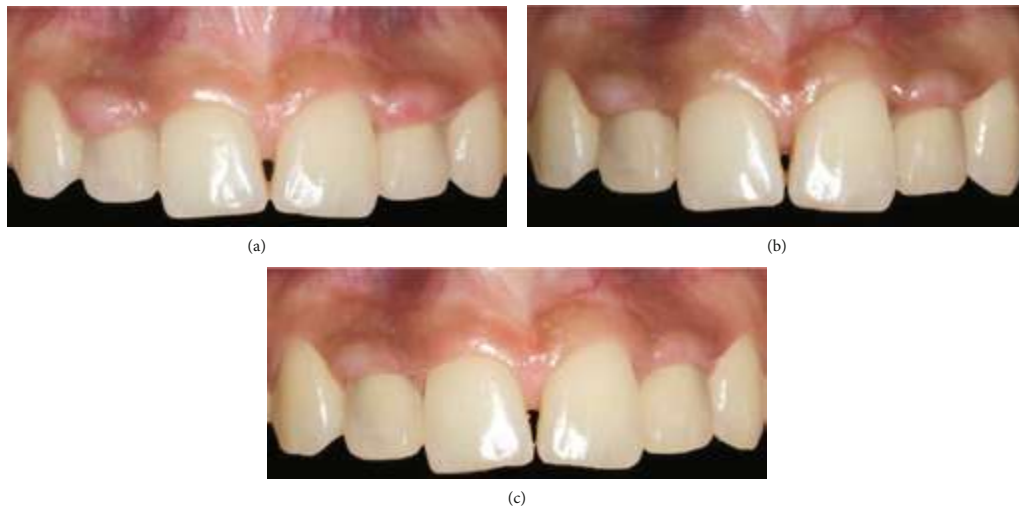

FIGURE 4: Peri-implant mucosa formation and gingival adaptation along with the emergence profile of the crown restoration: adaptation phase. (a) Soft tissues at two weeks of follow-up receded in an apical position and appeared without inflammation. (b) Soft tissues at 1 month of follow-up were adapted along the emergence profile of the crowns. (c) Soft tissues at 2 months of follow-up were stable, and the interdental spaces were completely filled by the interdental papillae.

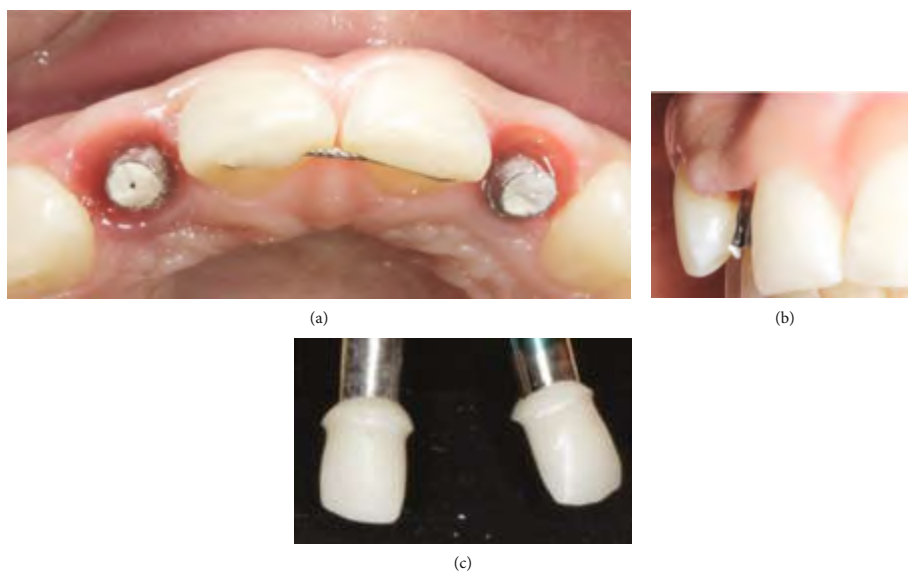


FIGURE 5: (a) Occlusal view of the peri-implant mucosa 2 months after interim restoration placement. (b) Lateral view showing that the keratinized gingiva adapted and conformed to the prosthetic emergence profile of the interim restoration in a specular way. (c) The definitive restoration frameworks with the reinforced collars that allowed a thick layer of ceramic at the margin of the crown.

restorations [11] if shoulderless abutments are used [16–19]. In this case report, the interim restorations were shaped with an augmented contour [12–14] and placed on the shoulder-

less abutments immediately after flap elevation, while waiting for peri-implant mucosa formation around the restorative components (Figure 3). The positions of the prosthetic



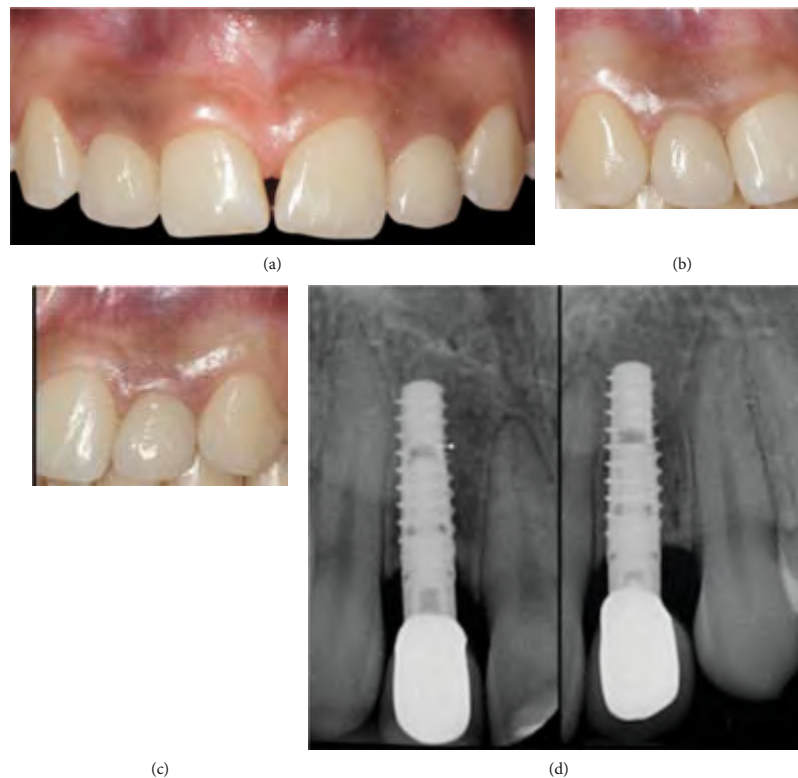


FIGURE 6: (a) Facial view of the definitive restorations at the 24-month follow-up. (b) Right lateral view of the definitive restorations at the 24-month follow-up. (c) Left lateral view of the definitive restorations at the 24-month follow-up. (d) Periapical radiographs at the 24-month follow-up.

crowns and their distance from the bone crest (4 mm at both sites) were clinically determined based on the thickness of the keratinized gingiva, measured at the center of the edentulous ridges before flap elevation. In the scientific literature, the peri-implant mucosal height is reported to be approximately 3 to 4 mm [29], and minimal bone remodeling is expected after the initial loading [25]. Therefore, we placed the interim restorations 3 mm from the bone crest, leaving adequate space for the peri-implant biologic width [23, 29, 30] (Figure 3(c)). Two months after implant loading, the peri-implant mucosa appeared pink, healthy, and completely adapted to the emergence profile [11] of the interim restorations. The healing stages of the peri-implant mucosa documented in this case report are in accordance with the healing stages in animal studies [29]. The first week was characterized by low-grade inflammation of the peri-implant mucosa, which healed and stabilized at the 1-month follow-up [30] and reached complete maturation with a pink and healthy appearance at the 2-month follow-up [29, 30]. The influence of abutment morphology on peri-implant mucosa formation has not been properly elucidated [8, 9, 29, 31], and currently, there are no studies comparing the implant

abutments with a finish line with the shoulderless abutments. Nevertheless, the horizontal finish line in implant abutments acts as a vertical stop for seating the crown [10]. In shoulderless abutments, the crown restoration may instead be moved in an apical or coronal direction without invading the biologic width [12–19]. Therefore, the emergence profile and the crown margin can be modified until healthy and stable soft tissues are achieved if the inflammation occurs during the interim stage [16–19].

The BOPT approach used for implant rehabilitation in this study demonstrated a good clinical outcome in the esthetic zone at the 24-month follow-up, with healthy peri-implant mucosa, pink and stippled gingiva, and interdental spaces completely filled by the interdental papillae. The interim crowns were not positioned according to the healed soft tissue, but the soft tissue was allowed to adapt itself against the prosthetic components during the healing stage. The position of the crown was predetermined and was based on the gingival tissue thickness and biologic width dimension. A limitation is apparent in cases in which the gingival thickness is not sufficient to ensure adequate space for the biologic width. Moreover, the technique is time consuming

## Case Reports in Dentistry

7

because the interim abutments must be adjusted by the dentist during the second stage surgery, which requires ample experience. The technique has not been backed by scientific literature, and long-term clinical studies are still required to understand the role of the abutment design in peri-implant mucosa formation and to better evaluate, both clinically and scientifically, the outcomes of shoulderless implant abutments.

**Data Availability**

The data that support the findings of this study are available from the corresponding author upon reasonable request.

**Consent**

Informed consent was obtained from the patient, and the San Raphael Hospital ethic committee approved this clinical study.

**Conflicts of Interest**

The authors deny any conflicts of interest related to this paper.

**References**

- [1] Z. Chen, C. Y. Lin, J. Li, H. L. Wang, and H. Yu, "Influence of abutment height on peri-implant marginal bone loss: a systematic review and meta-analysis," *The Journal of Prosthetic Dentistry*, vol. 122, no. 1, pp. 14–21.e2, 2019.
- [2] R. Patil, R. van Brakel, K. Iyer, J. H. Slater, C. de Putter, and M. Cune, "A comparative study to evaluate the effect of two different abutment designs on soft tissue healing and stability of mucosal margins," *Clinical Oral Implants Research*, vol. 24, no. 3, pp. 336–341, 2013.
- [3] R. Judgar, G. Giro, E. Zenobio et al., "Biological width around one- and two-piece implants retrieved from human jaws," *BioMed Research International*, vol. 2014, Article ID 850120, 5 pages, 2014.
- [4] A. B. Souza, A. Alshihri, P. W. Kämmerer, M. G. Araújo, and G. O. Gallucci, "Histological and micro-CT analysis of peri-implant soft and hard tissue healing on implants with different healing abutments configurations," *Clinical Oral Implants Research*, vol. 29, no. 10, pp. 1007–1015, 2018.
- [5] R. Agustín-Panadero, N. Martínez-Martínez, L. Fernández-Estevan, J. Faus-López, and M. F. Solá-Ruiz, "Influence of transmucosal area morphology on peri-implant bone loss in tissue level implants," *International Journal of Oral and Maxillofacial Implants*, vol. 34, pp. 947–952, 2019.
- [6] L. Canullo, G. Pellegrini, C. Allievi, L. Trombelli, S. Annibaldi, and C. Dellavia, "Soft tissues around long-term platform switching implant restorations: a histological human evaluation. Preliminary results," *Journal of Clinical Periodontology*, vol. 38, no. 1, pp. 86–94, 2011.
- [7] R. J. Lazzara and S. S. Porter, "Platform switching: a new concept in implant dentistry for controlling postrestorative crestal bone levels," *International Journal of Periodontics and Restorative Dentistry*, vol. 26, no. 1, pp. 9–17, 2006.
- [8] S. Bishti, J. R. Strub, and W. Att, "Effect of the implant-abutment interface on peri-implant tissues: a systematic review," *Acta Odontologica Scandinavica*, vol. 72, no. 1, pp. 13–25, 2013.
- [9] E. Rompen, "The impact of the type and configuration of abutments and their (repeated) removal on the attachment level and marginal bone," *The European Journal of Oral Implantology*, vol. 5, pp. S83–S90, 2012.
- [10] R. Cocchetto and L. Canullo, "The 'hybrid abutment': a new design for implant cemented restorations in the esthetic zones," *International Journal of Esthetic Dentistry*, vol. 10, no. 2, pp. 186–208, 2015.
- [11] I. K. Aidsman, "The glossary of prosthodontic terms," *The Journal of Prosthetic Dentistry*, vol. 94, no. 1, pp. 10–92, 2005.
- [12] I. Loi and A. Di Felice, "Biologically oriented preparation technique (BOPT): a new approach for prosthetic restoration of periodontally healthy teeth," *The European Journal of Esthetic Dentistry*, vol. 8, no. 1, pp. 10–23, 2013.
- [13] R. Agustín-Panadero, M. F. Solá-Ruiz, C. Chust, and A. Ferreiroa, "Fixed dental prostheses with vertical tooth preparations without finish lines: a report of two patients," *Journal of Prosthetic Dentistry*, vol. 115, no. 5, pp. 520–526, 2016.
- [14] R. Agustín-Panadero and M. F. Solá-Ruiz, "Vertical preparation for fixed prosthesis rehabilitation in the anterior sector," *Journal of Prosthetic Dentistry*, vol. 114, no. 4, pp. 474–478, 2015.
- [15] L. Canullo, R. Cocchetto, F. Marinotti, D. O. Oltra, M. P. Diago, and I. Loi, "Clinical evaluation of an improved cementation technique for implant-supported restorations: a randomized controlled trial," *Clinical Oral Implants Research*, vol. 27, no. 12, pp. 1492–1499, 2016.
- [16] L. Canullo, M. Menini, U. Covani, and P. Pesce, "Clinical outcomes of using a prosthetic protocol to rehabilitate tissue-level implants with a convergent collar in the esthetic zone: a 3-year prospective study," *The Journal of Prosthetic Dentistry*, vol. 123, no. 19, pp. 246–251, 2020.
- [17] M. F. Solá-Ruiz, J. Del Rio Highsmith, C. Labaig-Rueda, and R. Agustín-Panadero, "Biologically oriented preparation technique (BOPT) for implant-supported fixed prostheses," *Journal of Clinical Experimental Dentistry*, vol. 9, no. 4, pp. 603–607, 2017.
- [18] G. Cabanes-Gumbau, A. Pascual-Moscárdó, D. Peñarrocha-Oltra, B. García-Mira, J. Aizcorbe-Vincente, and M. Peñarrocha-Diago, "Volumetric variation of peri-implant soft tissues in convergent collar implants and crowns using the biologically oriented preparation technique (BOPT)," *Medicina Oral Patología Oral y Cirugía Bucal*, vol. 24, no. 5, pp. 643–651, 2019.
- [19] L. Canullo, M. Tallarico, G. Pradies, F. Marinotti, I. Loi, and R. Cocchetto, "Soft and hard tissue response to an implant with a convergent collar in the esthetic area: preliminary report at 18 months," *The International Journal of Esthetic Dentistry*, vol. 12, no. 3, pp. 306–323, 2017.
- [20] R. Agustín-Panadero, B. Serra-Pastor, A. Fons-Font, and M. F. Solá-Ruiz, "Prospective clinical study of zirconia full-coverage restorations on teeth prepared with biologically oriented preparation technique on gingival health: results after two-year follow-up," *Operative Dentistry*, vol. 43, no. 5, pp. 482–487, 2018.
- [21] B. Serra-Pastor, I. Loi, A. Fons-Font, M. F. Solá-Ruiz, and R. Agustín-Panadero, "Periodontal and prosthetic outcomes on teeth prepared with biologically oriented preparation technique: a 4-year follow-up prospective clinical study," *Journal of Prosthodontic Research*, vol. 63, no. 4, pp. 415–420, 2019.

- [22] L. A. Loomba-Albrecht and D. M. Styne, "Effect of puberty on body composition," *Current Opinion in Endocrinology, Diabetes, and Obesity*, vol. 16, no. 1, pp. 10–15, 2009.
- [23] M. Tallarico, A. Vaccarella, G. Marzi, A. Alviani, and V. Campana, "A prospective case-control clinical trial comparing 1- and 2-stage Nobel Biocare TiUnit implants: resonance frequency analysis assessed by Osstell Mentor during integration," *Quintessence International*, vol. 42, no. 8, pp. 635–644, 2011.
- [24] C. Tomasi, F. Tessarolo, I. Caola, J. Wennström, G. Nollo, and T. Berglundh, "Morphogenesis of peri-implant mucosa revisited: an experimental study in humans," *Clinical Oral Implants Research*, vol. 25, no. 9, pp. 997–1003, 2014.
- [25] S. Renvert, G. R. Persson, F. Q. Pirih, and P. M. Camargo, "Peri-implant health, peri-implant mucositis, and peri-implantitis: case definitions and diagnostic considerations," *Journal of Periodontology*, vol. 45, no. S1, pp. S278–S285, 2018.
- [26] G. I. Pardo, "A full cast restoration design offering superior marginal characteristics," *Journal of Prosthetic Dentistry*, vol. 48, no. 5, pp. 539–543, 1982.
- [27] J. Abduo and K. M. Lyons, "Interdisciplinary interface between fixed prosthodontics and periodontics," *Periodontology 2000*, vol. 74, no. 1, pp. 40–62, 2017.
- [28] C. J. Goodacre, W. V. Campagni, and S. A. Aquilino, "Tooth preparations for complete crowns: an art form based on scientific principles," *Journal of Prosthetic Dentistry*, vol. 85, no. 4, pp. 363–376, 2001.
- [29] M. G. Araujo and J. Lindhe, "Peri-implant health," *Journal of Clinical Periodontology*, vol. 45, no. S20, pp. 230–236, 2018.
- [30] T. Berglundh, I. Abrahamsson, M. Welander, N. P. Lang, and J. Lindhe, "Morphogenesis of the peri-implant mucosa: an experimental study in dogs," *Clinical Oral Implants Research*, vol. 18, no. 1, pp. 1–8, 2007.
- [31] F. Schwarz, J. Derks, A. Monje, and H. L. Wang, "Peri-implantitis," *Journal of Clinical Periodontology*, vol. 45, no. S20, pp. S246–S266, 2018.



**1 A micromorphological/ microbiological pilot study assessing three methods for the maintenance of implant patient**

E. Polizzi, B. D'Orto, S.Tomasi, G.Tetè

WILEY - Clinical and Experimental Dental Research - 10 Ottobre 2020

---

**2 Accuracy of Edentulous Computer-Aided Implant Surgery as Compared to Virtual Planning: A Retrospective Multicenter Study**

R. Vinci, M. Manacorda, R. Abundo, A. G. Lucchina, A. Scarano, C. Crocetta,

L. Lo Muzio, E. F. Gherlone, F. Mastrangelo

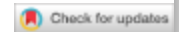Journal of Clinical Medicine - 12 marzo 2020

---

**3 Tecniche rigenerative dei mascellari atrofici: revisione della letteratura e case report**

L. Redi, G. Turbiglio, L. Abbruzzese, L. Pinto, F. Mottola, M. Nagni, R. Vinci

Doctor OS Febbraio 2020 XXXI 02



Received: 26 June 2020 | Revised: 3 October 2020 | Accepted: 10 October 2020  
 DOI: 10.1002/cre2.345

## ORIGINAL ARTICLE

Clinical and Experimental Dental Research Open Access WILEY

## A micromorphological/microbiological pilot study assessing three methods for the maintenance of the implant patient

Elisabetta Polizzi<sup>1</sup> | Bianca D'orto<sup>1</sup> | Simone Tomasi<sup>2</sup> | Giulia Tetè<sup>1</sup>

<sup>1</sup>Department of Dentistry, IRCCS San Raffaele Hospital, Vita Salute University, Milan, Italy

<sup>2</sup>Freelance Dental Hygienist, Milan, Italy

## Correspondence

Giulia Tetè, IRCCS San Raffaele Hospital and Dental School, Vita Salute University, Via Olgettina N.48, 20123 Milan, Italy.  
 Email: tetegiulia92@gmail.com

## Abstract

**Objective:** The aim of this study was to evaluate and compare the effectiveness of the ultrasonic piezoelectric inserts of EMS Steel Tip A, EMS Peek, and IS-TIP-STS-3E<sup>®</sup> in reducing peri-implant bacterial load without compromising the surface of implants during professional oral hygiene in the follow-up.

**Materials and methods:** Thirteen implants were examined (Winsix, Biosafin, Ancona, Italy). The implants were divided into five groups and analyzed with a SEM microscope and microbiological analysis to evaluate the possible modification of structure and the bacterial load reduction.

**Results:** The control and A, B, and C test groups were initially contaminated in vitro with *Streptococcus mutans*. Subsequently, the A, B, and C test groups were treated by an only expert operator in standard conditions. Test groups A, B, and C were inoculated for 3 hr and, furthermore, microbiologically analyzed.

**Conclusion:** The gold standard of an implant maintenance is a significant reduction of the bacterial load without becoming aggressive. According to our results, despite the limitations of the study, the authors recommend the least aggressive IS-TIP-STS-3E<sup>®</sup>, but combined with an antimicrobial agent to reduce the bacterial load, because the IS-TIP-STS-3E<sup>®</sup> did not show appreciable results versus the EMS Peek in reducing the bacterial load.

## KEYWORDS

implants surface, maintenance therapy, osteoblasts, peri-implantitis, piezoelectric ultrasonic

### 1 | INTRODUCTION

Osseointegrated dental implants, supporting fixed prostheses, are an effective therapeutic alternative to replace missing teeth (Cattoni et al., 2020).

When bone level is too reduced compared to traditional placement of straight implants, different procedures are proposed as an alternative, in order to obtain fixed rehabilitation: bone grafting (Salvato & Agliardi, 2007; Vinci, Tetè, Raimondi Lucchetti, Capparè, & Gherlone, 2019), crest augmentation (Crespi, Capparè, Polizzi, & Gherlone, 2014; McAllister &

Haghighat, 2007), sinus floor elevation techniques (lateral approach or osteotome-mediated technique) (Lundgren et al., 2017), short implants (Kim, Ku, Kim, Yun, & Kim, 2018) and tilted implants (Capparè et al., 2019; Krekmanov, Kahn, Rangert, & Lindström, 2000).

Despite the surgical technique, maintenance of professional hygiene is fundamental for the success of implant-prosthetic rehabilitation as peri-implantitis can be considered as a direct consequence of poor oral hygiene (Lindhe & Meyle, 2008).

The accumulation of bacterial plaque around the implants associated with other causes, such as absence of keratinized mucosa,

This is an open access article under the terms of the Creative Commons Attribution License, which permits use, distribution and reproduction in any medium, provided the original work is properly cited.

© 2020 The Authors. *Clinical and Experimental Dental Research* published by John Wiley & Sons Ltd.

systemic pathologies, smoking habits, and occlusal overload, could cause implant loss (Klinge, 2012; Levin, 2013).

During the hygienic maintenance therapy, several instruments for debridement were proposed: curettes, air polishing, and ultrasound devices.

The association of chemical agents and local antimicrobials with mechanical instrumentation has shown benefits in implant maintenance therapy (Calderini, Pantaleo, Rossi, Gazzolo, & Polizzi, 2013).

The aim of this study was to evaluate and compare the effectiveness of the EMS Steel Tip A, EMS Peek, and IS-TiP-STS-3E<sup>®</sup> ultrasonic piezoelectric inserts in reducing the peri-implant bacterial load without compromising the implant surface during professional oral hygiene in the follow-up. According to several studies, mechanical tools during professional hygiene are recommended; however, they can damage the implant surface (Cha et al., 2019; Louropoulou, Slot, & Van der Weijden, 2012).

Furthermore, ultrasonic instruments, compared to manual procedures, can be considered more effective (Vyas et al., 2019; Vyas, Grewal, Kuehne, Sammons, & Walmsley, 2020; Walmsley, Walsh, & Et, 1990).

## 2 | MATERIALS AND METHODS

Thirteen sand-blasted and acidified implants, having a diameter of 4.5 mm and a length of 15 mm, were examined by gamma ray sterilization, (Winsix, Biosafin, Ancona, Italy). The implants were divided into five groups consisting of:

- SEM control: one untreated implant.
- Microbiological control: three inoculated and untreated implants.
- Test group A: three contaminated implants and treated with EMS steel tip A.
- Test group B: three contaminated implants and treated with EMS Peek tip.
- Test group C: three contaminated implants and treated with IS-TiP-STS-3E<sup>®</sup> tip.

An in vitro model was recreated, and the microbiological analysis was conducted by experts at our university microbiology laboratory; while for the morphological analyzes, an expert conducted the preparations and analyzes in a double-blind.

### 2.1 | Bacterial contamination protocol

Bacterial colonies of *Streptococcus mutans* were initially pre-inoculated from a frozen stock and allowed to grow in 1 ml of Todd Hewitt Broth culture medium (Manufacturer: Becton Dickinson Sparks, MD) overnight.

The following day, the bacterial solution was diluted in order to obtain an O.D (optical density) of 480 nm = 0.1 CFU (Colony forming units, i.e., the bacterial quantity). The optimal wavelength for *Streptococcus mutans* colonies has been validated with previous experiments (Lundgren et al., 2017).

Standard curves for OD determinations were generated and compared with direct bacteria count by Acridine orange and subsequent visualization below epifluorescence microscope.

The two bacterial counts were consistent with each other; the OD measurement was thus used for subsequent determinations. The bacteria solution, OD 480 Nm = 0.1 CFU, was employed in order to contaminate both microbiological control implants and A, B, and C test groups' implants.

The inoculation was carried out under stirring, in the bacterial solution, for 10 hr. Subsequently, the A, B, and C test groups were subjected to the instrumentation treatment as per protocol. Following the instrumental treatment, the implants were inoculated for further 3 hr, under stirring, in a sterile medium. The soil solutions obtained were used for the measurement of the OD. Before being sent to the SEM scanning procedures, the implants were subjected to a bacterial fixing treatment on the surface by immersing 16% Glutaraldehyde for 30 min and then washed with distilled water.

### 2.2 | Instrumentation protocol

Clinical procedures of scaling near the area of the peri-implant sulcus were reproduced in vitro. The instrumentation steps were carried out in a horizontal and oblique direction in relation to the long axis of the implant. To define and encode an average instrumentation time for the samples under examination, the literature was examined and a maximum time of mechanical instrumentation of 4–6 min was applied (Decker, 2001).

For the study in question, simulating a supragingival instrumentation or mostly in the gingival sulcus, a time of 60 min was agreed for the instrumentation of each sample. As regards the working power of the Piezon EMS ultrasound device, a minimum power of 20,000 cycles per second has been calibrated.

All the movements of the instrumentation around the systems were carried out by the same expert operator in standard conditions.

Group A was assigned a mechanical instrumentation with Piezon ultrasonic handpiece (EMS) with steel tip "A" (EMS); the three samples making up the group were instrumented with the coded time of 60 min, with horizontal and oblique movements on the circumference of the implant.

Group B was assigned a mechanical instrumentation with Piezon ultrasonic handpiece (EMS) with Peek tip (EMS); the three samples making up the group were instrumented with the coded time of 60 min, with horizontal and oblique movements on the circumference of the implant.

Group C was assigned a mechanical instrumentation with Piezon ultrasound handpiece (EMS) with IS TiP STS-3E<sup>®</sup> tip; the three samples making up the group were instrumented with the coded time of 60 min, with horizontal and oblique movements on the implant circumference.

After instrumentation on the A, B, and C test groups, the microbiological analysis was carried out, and subsequently they were sent to the ESEMIR Sas laboratory (Di Battaini Paolo & C); where they were initially subjected to 1 metallization cycle with gold (the instrument



used is an Agar Auto Sputter Coater of the company AGAR SCIENTIFIC LTD), in order to make them electron conductive and, therefore, analyzed with the scanning electron microscope (SEM).

SEM observations were performed with a Cambridge Stereoscan 120 instrument digitized with the Adda II system and equipped with electronic energy dispersion microanalysis (EDS). The main parameters of the analysis—electron acceleration potential (=EHT), Working distance (=WD), and magnification (=MAG)—are shown on the black strip at the bottom of each scan. Three different magnification images were taken, both for the SEM control and for the A, B, and C test groups. Magnifications were made at  $\times 100$ ,  $\times 500$ , and  $\times 1,000$  on the A-B-C test groups, an image for each sample belonging to the group. The individual scans were compared for the same magnification with the SEM control.

A, B, and C test groups were compared with the control group in order to evaluate the possible damages induced by mechanical instrumentation with different treatments, so as to identify possible modifications made to the treated implant structure. After a  $\times 500$  magnification, considered the most significant for image quality, the highest definition images of different instruments were selected: EMS steel tip A, EMS Peek, IS-TIP-STS-3E<sup>®</sup>, and thus compared with each other and with the SEM control with the same magnification.

### 3 | RESULTS

#### 3.1 | Microbiological results

From the analyzes carried out after the instrumentation on the A, B, and C test groups with respect to the microbiological control, it was found that:

**Group A:** there was no reduction of the bacterial count, but an increase of it in the following 3 hours of inoculation with a standard deviation of 3%.

**Group B:** a highly significant reduction in bacterial count occurred with a standard deviation of 8%.

**Group C:** a significant reduction in bacterial count occurred with a standard deviation of 4%.

It is recalled, looking at the graph (Figure 1), that for P to have statistical significance, it must be less than 0.01. It is, therefore, deduced that the implants of groups B and C have reached a high statistical significance of bacterial reduction,  $p < .01$ .

#### 3.2 | Morphological results

Test group (A) vs SEM control at  $\times 500$ .

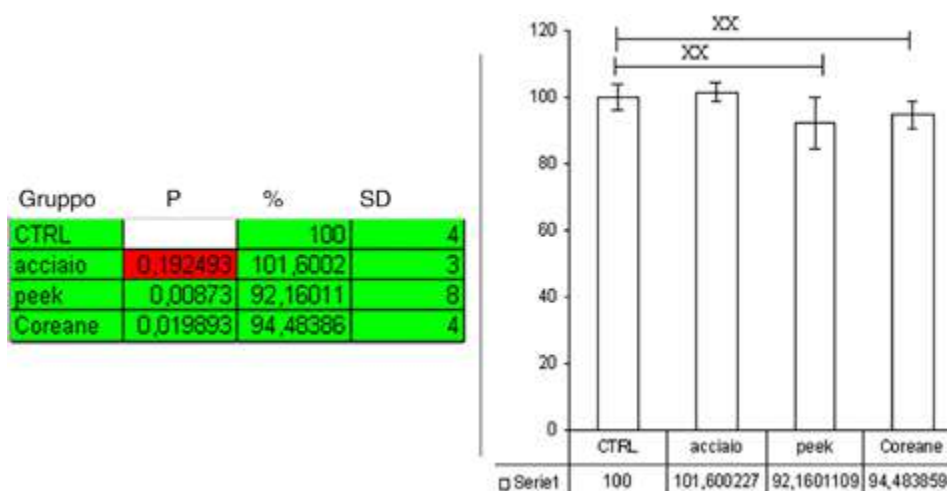
In the 500x scans, in addition to the scratching and surface smoothing areas, titanium “flakes,” presumably caused by the instrumentation performed with an EMS steel tip, are appreciated. (Figure 2a-d).

Test group (B) Vs SEM control at  $\times 500$ .


In the 500x scans, the marked sanding areas of the surface remain more visible between the normal weaving of the implant with a vertical and horizontal trend, due to the action of the Peek tip mounted on the ultrasound handpiece. (Figure 3a-d).

Test group (C) Vs SEM control at  $\times 500$ .


In the 500x scans, it can be seen that the insert has not significantly changed the implant surface, there is a slight smoothing of the surface, due to the action of the tip mounted on the ultrasound handpiece. Even at this magnification, the partial conservation of the




**FIGURE 1** The graph shows for each individual insert the degree of effectiveness in removing the amount of surface bacteria. It can be seen that the insert with the highest bacterial removal capacity is the steel one, in second place the Korean tips, and lastly the peek tip



**FIGURE 2** In the  $\times 500$  scans instrumented with EMS steel insert (b–d) we can see, with respect to the virgin control (a), areas of scratching and surface smoothing with the presence of titanium “flakes” presumably caused by the instrumentation made with EMS steel tip. Gruppo test (A) versus Controlo SEM a  $\times 500$



**FIGURE 3** In the  $\times 500$  scans instrumented with a peek insert (b–d), compared to the virgin control (a), the areas of marked sanding of the surface with a vertical and horizontal trend, due to the action of the Peek tip mounted on the ultrasonic handpiece, remain more visible between the normal implant texture of the implant. Gruppo test (B) versus Controlo SEM a  $\times 500$




**FIGURE 4** In the  $\times 500$  scans, instrumented by means of the IS TiP insert (b–d) with respect to the control (a) it can be seen that the insert has not considerably modified the implant surface, a slight smoothing of the surface is observed, due to the action of the tip mounted on the ultrasound handpiece. Also, at this magnification the partial preservation of the surface morphology of the implant origin can be observed. Scan No. 12 showed the presence of a clear deposit; when analyzed by metallography it was found to be the alloy of which the IS-TiP-STS-3E insert is composed (Figure 6). Gruppo test (C) versus Controlo SEM a  $\times 500$

surface morphology of the origin of the implant can be observed. (Figure 4a–d).

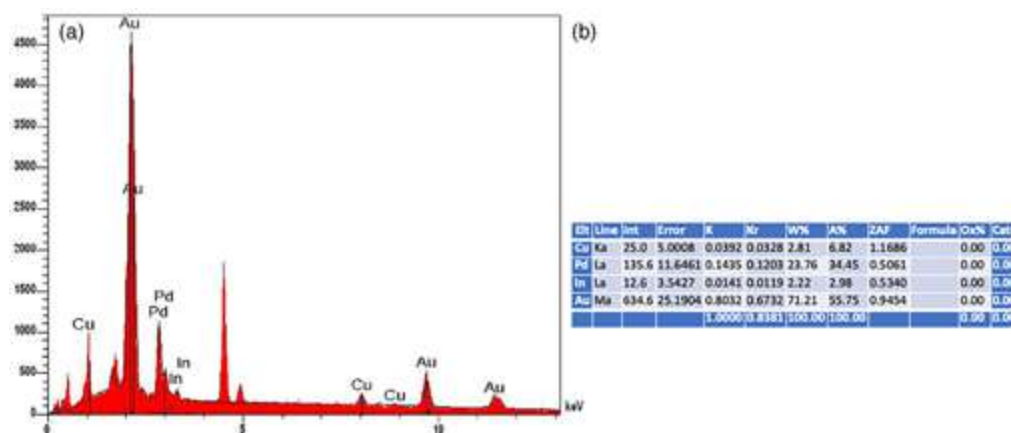
In the scan no 41, the presence of a clear deposit was verified; analyzed by metallography, it was found to be the alloy of which the

IS-TiP-STS-3E<sup>®</sup> insert is composed (Figure 2d) in comparison at  $\times 500$  of the test groups A, B, and C Vs SEM control.

The images of all the instruments (Steel A EMS, Peek EMS, IS-TiP-STS-3E<sup>®</sup>) were compared at a magnification of  $\times 500$ , which is



**FIGURE 5** Most significant images of the three types of inserts used for mechanical instrumentation (b–d) compared with the control (a). Comparazione a  $\times 500$  dei Gruppo test A-B-C versus Controllo SEM



**FIGURE 6** (a and b) Graph shows a gold deposit on the surface of the implant found in scan no. 12 due to wear and tear during the instrumentation of the IS-TIP inserts, which are entirely gold-plated

considered the most significant image quality. It was pointed out that the IS-TIP-ST3-3E<sup>®</sup> tip (Figure 5a–d) was the least aggressive compared to the Peek and Steel inserts (A). The Peek tip (Figure 5b) was, in turn, less aggressive than the steel insert. The steel insert was, therefore, the most aggressive (Figure 5c).

#### 4 | DISCUSSION

Osseointegrated dental implants supporting fixed prostheses could effectively be considered the gold standard in the rehabilitation of patients with partial or total edentulism (Cattoni et al., 2020; Spitznagel, Horvath, & Gierthmuehlen, 2017).

Implant survival depends on the effectiveness of maintenance therapy and the selection of different instruments, such as currettes, ultrasonic scalers, air-powder abrasive systems, lasers, chemicals, and local antimicrobials (Brookshire, Nagy, Dhuru, Ziebert, & Chada, 1997;

Duarte, Reis, de Freitas, & Ota-Tsuzuki, 2009; Garcia Canas, Khoully, Sanz, & Loomer, 2015).

After mechanical instrumentation, any damage to the surface of the implants can be recorded (Cha et al., 2019; Louropoulou et al., 2012).

As reported by several studies, the alteration of the implant surface negatively affects the proliferation and response of osteoblasts, so their attachment may be easier on surfaces with rougher microtopography (Bordji et al., 1996; Lincks et al., 1998).

The use of ultrasonic scalers may cause various changes on the implant surfaces (Harrel, Wilson Jr, Pandya, & Diekwisch, 2019; Ramaglia, di Lauro, Morgese, & Squillace, 2006).

Therefore, only professional oral hygiene is not sufficient for implant maintenance, and good oral health needs to be improved with home hygiene (Tecco et al., 2018).

The aim of this study was to evaluate and compare the effectiveness of the EMS Steel Tip A, EMS Peek, and IS-TIP-ST3-3E<sup>®</sup>

ultrasonic piezoelectric inserts in reducing the peri-implant bacterial load without compromising the implant surface during professional oral hygiene in the follow-up.

The data obtained in our in vitro study are similar to the evidence-based and in vivo studies of many Authors (Matarasso et al., 1996; Rapley, Swan, Hallmon, & Mills, 1990).

The SEM images had  $\times 100$ ,  $\times 500$ , and  $\times 1,000$  magnifications, and showed how all test groups (A, B, and C) analyzed reported visible damage on the implant surface.

Our results showed that the EMS A tip was too aggressive, the EMS Peek tip was mildly aggressive, and IS TIP STS-3E<sup>®</sup> caused minor surface damage to be considered almost irrelevant. However, after the metallography analysis, in scan no 42 at  $\times 500$  magnification, an evident deposit of IS-TIP-STS-3E<sup>®</sup> was found, which is considered irrelevant given its composition (gold alloy) and the remote randomness of identification (Figure 5d).

Our results are in accordance with scientific evidence; several studies, in fact, underline that mechanical instruments leave traces on the surface of the implant with removal of substance (Mengel, Buns, Mengel, & Flores-de-Jacoby, 1998).

However, some authors show that a nonmetallic ultrasonic tip is less aggressive, and results similar to those of the control groups are obtained (Bailey, Gardner, Day, & Kovanda, 1998).

Despite the limitations of the study to simple size, it would reserve further investigation; therefore, our SEM images showed that mechanical instrumentation could cause significant damage to the implant surface (Figure 6).

Microbiological results show that the less aggressive IS-TIP-STS-3E tip has a significant reduction in bacterial load with a standard deviation of 4%, but lower than the Peek EMS tip, which showed a standard deviation of 8%, while the more aggressive tip showed a poor reduction in bacterial load with a standard deviation of 3%. The microbiological results are again in line with the literature; in fact, several studies point out that the use of a metal tip can be effective in removing bacteria from contaminated surfaces (Park et al., 2013; Toma, Behets, Brex, & Lasserre, 2018).

However, some authors always recommend the combination with an antimicrobial agent to make the reduction of the bacterial load more effective (Polizzi et al., 2020).

The Gold standard of tips used in oral hygiene maintenance therapy is a tip that is not aggressive towards the implant surface but effective in reducing the bacterial load (Palmer & Floyd, 1995).

Therefore, comparing our results obtained from the morphostructural SEM analysis and the microbiological analysis, the IS-TIP-STS-3E tip is the least aggressive even if it did not obtain the best result in terms of bacterial load reduction. To solve this problem, the literature suggests combining the tip with an antimicrobial agent such as chlorhexidine (Calderini et al., 2013).

With the limitations of the study, we can state that the IS-TIP-STS-3E tip used with a microbial agent that increases its bacterial load reduction power, for example, chlorhexidine, could be a combination therapy of choice during the maintenance of the implant as it is not very aggressive and with a sufficient reduction of the bacterial load.

Furthermore, the hygienist plays a fundamental role in the dental team for home motivational education, in monitoring patients with a pre- and post-operative recall program and in promptly intercepting any problems to be reported to the surgeon.

## 5 | CONCLUSIONS

Within the limitations of this study, according to the obtained results, the authors recommend the association between the IS-TIP-STS-3E tip<sup>®</sup> and an antimicrobial agent. Further long-term in vitro and in vivo studies are needed to confirm these results.

### CLINICAL RELEVANCE

#### Scientific rationale for the study

Nonresident bacteria in the oral cavity are responsible for many oral diseases; professional oral hygiene in patients who have implant rehabilitation is critical to minimize the risk of peri-implantitis and avoid implant failure.

#### Principal findings and practical implications

Although the literature is unfavorable to ultrasonic metal tips, our results tell that TIP STS-3E metal tip associated with a microbial agent not only minimizes the presence of bacterial colonies but surprisingly is not aggressive to the implant surface.

### CONFLICT OF INTEREST

All the authors declare that there are no conflicts of interest regarding the publication of this paper.

### AUTHOR CONTRIBUTIONS

Elisabetta Polizzi and Simone Tomasi conceived idea; Bianca D'orto and Giulia Tetè collected and analyzed the data. Elisabetta Polizzi reviewed the paper and was the supervisor.

### ORCID

Giulia Tetè  <https://orcid.org/0000-0002-9461-469X>

### REFERENCES

- Bailey, G. M., Gardner, J. S., Day, M. H., & Kovanda, B. J. (1998). Implant surface alterations from a nonmetallic ultrasonic tip. *The Journal of the Western Society of Periodontology/Periodontal Abstracts*, 46(3), 69–73.
- Bordji, K., Jouzeau, J. Y., Mainard, D., Payan, E., Netter, P., Rie, K. T., ... Hage-Ali, M. (1996). Cytocompatibility of Ti-6Al-4V and Ti-5Al-2.5Fe alloys according to three surface treatments, using human fibroblasts and osteoblasts. *Biomaterials*, 17, 929–940.
- Brookshire, F. V., Nagy, W. W., Dhuru, V. B., Ziebert, G. J., & Chada, S. (1997). The qualitative effects of various types of hygiene instrumentation on commercially pure titanium and titanium alloy implant abutments: An in vitro and scanning electron microscope study. *The Journal of Prosthetic Dentistry*, 78, 286–294.

- Calderini, A., Pantaleo, G., Rossi, A., Gazzolo, D., & Polizzi, E. (2013). Adjunctive effect of chlorhexidine antiseptics in mechanical periodontal treatment: First results of a preliminary case series. *International Journal of Dental Hygiene*, 11(3), 180–185.
- Cappare, P., Tetè, G., Romanos, G. E., Nagni, M., Sannino, G., & Gherlone, E. F. (2019). The 'All-on-four' protocol in HIV-positive patients: A prospective, longitudinal 7-year clinical study. *International Journal of Oral Implantology*, 12(4), 501–510.
- Cattoni, F., Tetè, G., Uccioli, R., Manazza, F., Gastaldi, G., & Perani, D. (2020). An fMRI study on self-perception of patients after aesthetic implant-prosthetic rehabilitation. *International Journal of Environmental Research and Public Health*, 17(2), 588.
- Cha, J. K., Paeng, K., Jung, U. W., Choi, S. H., Sanz, M., & Sanz-Martín, I. (2019). The effect of five mechanical instrumentation protocols on implant surface topography and roughness: A scanning electron microscope and confocal laser scanning microscope analysis. *Clinical Oral Implants Research*, 30(6), 578–587.
- Crespi, R., Cappare, P., Polizzi, E. M., & Gherlone, E. F. (2014). Tissue remodeling after bone expansion in grafted and ungrafted sockets. *The International Journal of Oral & Maxillofacial Implants*, 29(3), 699–704.
- Decker, E. M. (2001). The ability of direct fluorescence-based, two-colour assays to detect different physiological states of oral streptococci. *Applied Microbiology*, 33(3), 188–192. Department of Conservative Dentistry, School of Dental Medicine, Germany.
- Duarte, P. M., Reis, A. F., de Freitas, P. M., & Ota-Tsuzuki, C. (2009). Bacterial adhesion on smooth and rough titanium surfaces after treatment with different instruments. *Journal of Periodontology*, 80, 1824–1832.
- García Canas, P., Khoully, I., Sanz, J., & Loomer, P. M. (2015). Effectiveness of systemic antimicrobial therapy in combination with scaling and root planing in the treatment of periodontitis: A systematic review. *Journal of the American Dental Association*, 146(3), 150–163.
- Harrel, S. K., Wilson, T. G., Jr., Pandya, M., & Diekwisch, T. G. H. (2019). Titanium particles generated during ultrasonic scaling of implants. *Journal of Periodontology*, 90(3), 241–246.
- Kim, S. Y., Ku, J. K., Kim, H. S., Yun, P. Y., & Kim, Y. K. (2018). A retrospective clinical study of single short implants (less than 8 mm) in posterior edentulous areas. *Journal of Advanced Prosthodontics*, 10(3), 191–196.
- Klinge, B. (2012). Meyle J; working group 2. Peri-implant tissue destruction. The third EAO consensus conference 2012. *Clinical Oral Implants Research*, 23(Suppl. 6), 108–110.
- Krekmanov, L., Kahn, M., Rangert, B., & Lindström, H. (2000). Tilting of posterior mandibular and maxillary implants for improved prosthesis support. *The International Journal of Oral & Maxillofacial Implants*, 15(3), 405–401.
- Levin, L. (2013). Peri-implantitis: The disease of the future. *Quintessence International*, 44, 643.
- Lincks, J., Boyan, B. D., Blanchard, C. R., Lohmann, C. H., Liu, Y., Cochran, D. L., ... Schwartz, Z. (1998). Response of MG63 osteoblast-like cells to titanium and titanium alloy is dependent on surface roughness and composition. *Biomaterials*, 19, 2219–2232.
- Lindhe, J., & Meyle, J. (2008). Peri-implant diseases: Consensus report of the sixth European workshop on periodontology. *Journal of Clinical Periodontology*, 35(8 Suppl), 282–285.
- Louropoulou, A., Slot, D. E., & Van der Weijden, F. A. (2012). Titanium surface alterations following the use of different mechanical instruments: A systematic review. *Clinical Oral Implants Research*, 23(6), 643–658.
- Lundgren, S., Cricchio, G., Hallman, M., Jungner, M., Rasmusson, L., & Sennerby, L. (2017). Sinus floor elevation procedures to enable implant placement and integration: Techniques, biological aspects and clinical outcomes. *Periodontology 2000*, 73(1), 103–120.
- Matarasso, S., Quaremba, G., Coraggio, F., Vaia, E., Cafiero, C., & Lang, N. P. (1996). Maintenance of implants: An in vitro study of titanium implants surface modifications subsequestered to the application of different prophylaxis procedures. *Clinical Oral Implants Research*, 7(1), 64–72.
- McAllister, B. S., & Haghghat, K. (2007). Bone augmentation techniques. *Journal of Periodontology*, 78(3), 377–396.
- Mengel, R., Buns, C. E., Mengel, C., & Flores-de-Jacoby, L. (1998). An in vitro study of the treatment of implant surfaces with different instruments. *International Journal of Oral and Maxillofacial Implants*, 13(1), 91–96.
- Palmer, R. M., & Floyd, P. D. (1995). Periodontology: A clinical approach. Non-surgical treatment and maintenance. *Dental Journal*, 8, 263–268.
- Park, J. B., Jang, Y., Koh, M., Choi, B., Kim, K., & Ko, Y. (2013). In vitro analysis of the efficacy of ultrasonic scalers and a toothbrush for removing bacteria from resorbable blast material titanium disks. *Journal of Periodontology*, 84(8), 1191–1198. <https://doi.org/10.1902/jop.2012.120369>
- Polizzi, E., Tetè, G., Bova, F., Pantaleo, G., Gastaldi, G., Cappare, P., & Gherlone, E. F. (2020). Antibacterial properties and side effects of chlorhexidine based mouthwashes. A prospective, randomized clinical study. *Journal of Osseointegration*, 12, 230.
- Ramaglia, L., di Lauro, A. E., Morgese, F., & Squillace, A. (2006). Profilometric and standard error of the mean analysis of rough implant surfaces treated with different instrumentations. *Implant Dentistry*, 15, 77–82.
- Rapley, J. W., Swan, R. H., Hallmon, W. W., & Mills, M. P. (1990). The surface characteristics produced by various oral hygiene instruments and materials on titanium implant abutments. *International Journal of Oral and Maxillofacial Implants*, 5(1), 47–52.
- Salvato, G., & Agliardi, E. (2007). Calvarial bone grafts in severe maxillary atrophy: Preprosthetic surgery with sedation. *Implant Dentistry*, 16(4), 356–361.
- Spitznagel, F. A., Horvath, S. D., & Gierthmuehlen, P. C. (2017). Prosthetic protocols in implant-based oral rehabilitations: A systematic review on the clinical outcome of monolithic all-ceramic single- and multi-unit prostheses. *European Journal of Oral Implantology*, 10(Suppl 1), 89–99.
- Tecco, S., Sciarra, C., Pantaleo, G., Nota, A., Visone, A., Germani, S., ... Gherlone, E. F. (2018). The association between minor recurrent aphthous stomatitis (RAS), children's poor oral condition, and underlying negative psychosocial habits and attitudes towards oral hygiene. *BMC Pediatrics*, 18(1), 136. <https://doi.org/10.1186/s12887-018-1094-y>
- Toma, S., Behets, C., Brex, M. C., & Lasserre, J. F. (2018). In vitro comparison of the efficacy of peri-implantitis treatments on the removal and recolonization of *Streptococcus gordonii* biofilm on titanium disks. *Materials (Basel)*, 11(12), 2484. <https://doi.org/10.3390/ma11122484>
- Vinci, R., Tetè, G., Raimondi Lucchetti, F., Cappare, P., & Gherlone, E. F. (2019). Implant survival rate in Calvarial bone grafts: A retrospective clinical study with 10 year follow-up. *Clinical Implant Dentistry and Related Research*, 21(4), 662–668. <https://doi.org/10.1111/cid.12799> Epub May 28, 2019.
- Vyas, N., Grewal, M., Kuehne, S. A., Sammons, R. L., & Walmsley, A. D. (2020). High speed imaging of biofilm removal from a dental implant model using ultrasonic cavitation. *Dental Materials*, 36(6), 733–743.
- Vyas, N., Manmi, K., Wang, Q., Jadhav, A. J., Barigou, M., Sammons, R. L., ... Walmsley, A. D. (2019). Which parameters affect biofilm removal with acoustic cavitation? A review. *Ultrasound in Medicine & Biology*, 45(5), 1044–1055.
- Walmsley, A. D., Walsh, T. F., & Et, A. (1990). Effects of cavitation activity on the root surface of teeth during ultrasonic scaling. *Journal of Clinical Periodontology*, 17(5), 306–312.




**How to cite this article:** Polizzi E, D'orto B, Tomasi S, Tetè G. A micromorphological/microbiological pilot study assessing three methods for the maintenance of the implant patient. *Clin Exp Dent Res*. 2020;1–7. <https://doi.org/10.1002/cre2.345>





## Article

## Accuracy of Edentulous Computer-Aided Implant Surgery as Compared to Virtual Planning: A Retrospective Multicenter Study

R. Vinci <sup>1,†</sup>, M. Manacorda <sup>2,†</sup>, R. Abundo <sup>3</sup>, A.G. Lucchina <sup>4</sup>, A. Scarano <sup>5</sup> , C. Crocetta <sup>6</sup> ,  
L. Lo Muzio <sup>7</sup> , E.F. Gherlone <sup>8</sup> and F. Mastrangelo <sup>7,\*</sup>

<sup>1</sup> Dental Clinic, Ateneo Vita Salute, San Raffaele Milan, 20019, Italy; [vinci.raffaele@univr.it](mailto:vinci.raffaele@univr.it)

<sup>2</sup> Private Practice, 20021 Milan, Italy; [manacorda.michele@univr.it](mailto:manacorda.michele@univr.it)

<sup>3</sup> Private Practice, 10121 Turin, Italy; [robabund@yahoo.it](mailto:robabund@yahoo.it)

<sup>4</sup> Department of Oral and maxillofacial Sciences, University of Piemonte Orientale, 10121 Turin, Italy; [arlucchina@gmail.com](mailto:arlucchina@gmail.com)

<sup>5</sup> Department of Medical, Oral and Biotechnological Sciences, University of Chieti, 66100 Chieti, Italy; [ascarano@unich.it](mailto:ascarano@unich.it)

<sup>6</sup> Department of Economics, University of Foggia, 71121 Foggia, Italy; [corrado.crocetta@unifg.it](mailto:corrado.crocetta@unifg.it)

<sup>7</sup> Department of Clinical and Experimental Medicine, University of Foggia, 71122 Foggia, Italy; [lorenzo.lomuzio@unifg.it](mailto:lorenzo.lomuzio@unifg.it)

<sup>8</sup> Dental Clinic, Ateneo Vita Salute, San Raffaele Milan, Italy; [gherlone.enrico@univr.it](mailto:gherlone.enrico@univr.it)

\* Correspondence: [filibertomastrangelo@hotmail.com](mailto:filibertomastrangelo@hotmail.com) or [filiberto.mastrangelo@unifg.it](mailto:filiberto.mastrangelo@unifg.it); Tel.: +39-335-8390720

† Contributed equally.

Received: 5 February 2020; Accepted: 9 March 2020; Published: 12 March 2020



**Abstract:** Purpose: To evaluate the accuracy of computer-aided dental implant positions obtained with mucosal-supported templates as compared to Three-Dimensional (3D) planning. Materials and methods: One-hundred implants were inserted into 14 edentulous patients using the All-on-4/6 protocol after surgical virtual planning with RealGUIDE, 3DIEMME, and Geomagic software. After 6 months, three-dimensional neck (V) and apex (S) spatial coordinates of implants and angle inclination displacements as compared to virtual plans were evaluated. Results: The S maxilla coordinates revealed a significant discrepancy between clinical and virtual implant positions ( $p$ -value = 0.091). The V coordinates showed no significant differences ( $p$ -value = 0.71). The S ( $p$ -value = 0.017) and V ( $p$ -value = 0.038) mandible coordinates showed significant discrepancies between the clinical and virtual positions of the screws. Implant evaluation showed a 1-mm in average of the horizontal deviation in the V point and a 1.6-mm deviation in the S point. A mean 5° angular global deviation was detected. The multivariate permutation test of the S ( $p$ -value = 0.02) confirmed the difference. Greater errors in the mandible were detected as compared to the maxilla, and a higher S discrepancy was found in the posterior jaw compared to the anterior section of both the mandible and maxilla. Conclusions: Computer-aided surgery with mucosal-supported templates is a predictable procedure for implant placement. Data showed a discrepancy between the actual dental implant position as compared to the virtual plan, but this was not statistically significant. However, the horizontal and angle deviations detected indicated that flap surgery should be used to prevent implant positioning errors due to poor sensitivity and accuracy in cases of severe jaw atrophy.

**Keywords:** guided surgery; titanium dental implant; Three-Dimensional implant accuracy; Three-Dimensional software implant; planning; permutation tests; non-parametric combination; multivariate analysis; osseointegration; immediate-load dental implants

## 1. Introduction

Immediate implant-supported prosthetic rehabilitation is considered to be a routine procedure with a high success rate [1–3]. Presently, Three-Dimensional (3D) preoperative planning through cone beam computed tomography analysis (CBCT) allows for the verification of the maxillary anatomy and qualitative and quantitative bone structures before dental implant placement [4,5]. The CBCT Standard Triangulation Language (STL) files elaborated through specific surgical software, together with stereolithographic (SL) models, promote individual virtual planning [6] that allows an immediate prosthetic loading of the implants with a reduction in surgical times, increasing the comfort of the patients [7,8] and the predictability of surgical results [9,10]. In the literature, computer-aided surgical systems have shown high accuracy rates in terms of implant position, depth, and angle, avoiding intraoperative surgical complications and poor positioning of implants which can compromise the primary stability and/or success of immediate-load restoration techniques [11–13]. However, in a recent systematic review of static navigation systems, Tahmeseb A. et al. found a 1.2-mm (1.04–1.44 mm) mean horizontal deviation at the coronal entry point and a 1.48-mm (1.28–1.58 mm) deviation in the apical endpoint, respectively, with a mean angular deviation of 3.5° (3.0–3.96°) [14]. However, numerous variables have been found to affect virtual planning and the in vivo position of the dental implant [15]. Thus, it is necessary to evaluate the accuracy of the virtual and clinical measurements of lengths and angles [16] due to the many errors related to the different phases of data acquisition, as well as to data elaboration during digital and surgical workflow [17]. Many studies have been carried out to compare the planned position of dental implants with their actual insertion position in the maxilla, using implant neck/apex points or 3D coordinates (X, Y, Z axes) to analyze the sensitivity of the software and to determine predictability of the results. The aim of the study was to evaluate the accuracy of the virtual computer-aided approach in the overall digital workflow using mucosal-supported templates Computer-Aided Design and Manufacturing (CAD-CAM) as compared to the clinical position of immediate-load dental implants in atrophic areas of bone in totally edentulous patients.

## 2. Materials and Methods

### 2.1. Patient Selection

Fourteen patients (6 male/8 female; mean age 58) were selected from four different private dental clinics from November 2014 to July 2017. All presented with good health, total edentulism of the jaws, and the need for dental implant rehabilitation. Inclusion criteria were: an upper opening of the mouth wider than 50 mm, edentulism of the maxilla arches, and sufficient bone available for positioning the implant fixture. The exclusion criteria were: cardiac disease, chemotherapy, radiotherapy, bisphosphonate therapy, pregnancy, asthmatic problems, decompensated diabetes, smoking habit (more than 10 cigarettes/day), and maxillary parafunctions. No bone regeneration was requested. In order to reduce the study variables, all surgeons had the same level of expertise and used the same digital work flow for the computer-guided surgery, with the same 3D device and the same implant system. All patients were examined through preliminary CBCT analysis (NewTom Evo - NewTom, Verona, Italy) using a prosthesis with a radiopaque marker, and underwent standardized CBCT scanning with an interocclusal index. To complete the digital data, some optical scans (Activity 885, Smart Optics, Bochum, Germany) were performed. The 3D STL files were imported into 3Diagnosys (3DIEMME, Italy) to match the CBCT Dicom data and to perform virtual planning (RealGUIDE, 3DIEMME, Milan, Italy). All data were collected using software with an adapting algorithm, called “best-fit”, to optimize the anatomic curves of the maxillo-facial complex as well as the regular geometry of the radiological markers. After digital image segmentation, the virtual implants were placed in the optimal position according to the anatomy and prosthetic planning. The STL data were processed with the Plasty-CAD-3DIEMME system (DWS 20D, DWS SYSTEMS, Bergamo Italy) and surgical guide templates were created with mucous support and a stabilizing system with bi-cortical bone fixation pins. After administration of local anesthetic (4% articaine with



1: 200.000 adrenaline), the surgical guide was positioned on the maxillary arch of the patients and anchored by three bi-cortical bone pins. After flapless surgery, only Winsix TTx implants (diameter: 3.8 or 4.5 mm) with external hexagonal connections were placed using the “Just on-four” or “Just on-six” techniques. All implants were inserted with 35–55 N/m torque and immediately loaded with a provisional prosthesis. (Table 1)

**Table 1.** The 100 dental implants in the maxilla or mandible site positions.

Arch	Site	Implants Numbers
Anterior Maxilla	11	4
	12	6
	13	2
	21	2
	22	6
	23	3
Posterior Maxilla	14	3
	15	11
	24	3
	25	10
	26	1
Anterior Mandible	31	3
	32	8
	33	1
	42	9
	43	2
Posterior Mandible	34	4
	35	6
	36	3
	44	5
	45	6
	46	2
		Total 100


## 2.2. Computerized and Statistical Analysis

The control CBCT procedure was used to verify the differences between the clinical implant fixture position after the surgery as compared to that in virtual planning. Geomagic Studio software (3D SYSTEM, Geomagic, Morrisville, North Carolina -USA) was used. For the evaluation of the three spatial coordinates ( $x_v, y_v, z_v$  e  $x_s, y_s, z_s$ ) of each dental implant, the angles formed by the axes of inclination between the implants were calculated. (Table 2) The neck (V) and the apex (S) points were chosen to understand the accuracy and the sensitivity of virtual planning as compared with the clinical results. To evaluate the three-dimensional spatial position (x, y, z) of single implants (Figure 1) post-surgery, the CBCT analysis used a specific algorithm to minimize the relative distance according to an interactive process of the files matching, guaranteeing precise and repeatable overlaying. Following the alignment process, a mean error value was calculated using the distance of the points between the two surfaces (from the STL and the DICOM files), which were considered acceptable when less than 0.1–0.15 mm (on the entire arch). To calculate the Euclidean distances (S and V), the formulas  $= \sqrt{(x_s^2 + y_s^2 + z_s^2)}$  and  $V = \sqrt{(x_v^2 + y_v^2 + z_v^2)}$  were used. The Smean and Vmean were calculated for each implant of each patient, wher were used. Therefore, Smean and Vmean were calculated for each implant of each patient where

$$S_{mean} = \frac{\sum_{i=1}^n S_i}{n}, V_{mean} = \frac{\sum_{i=1}^n V_i}{n} \quad (1)$$

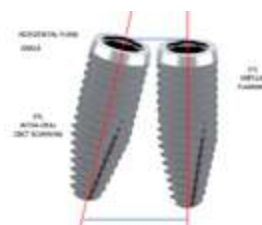
**Table 2.** The horizontal apex (S) and neck (V) implant discrepancies.

Implant Discrepancy	APEX (S) mm	NECK (V) mm
Maxillary sites	0.30 mm (range: 0.10–1.57 mean 0.89)	0.37 mm (range: 0.30–1.77 mean 0.67)
Mandible sites	0.43 mm (range: 0.30–1.77 mean 0.31)	0.28 mm (range: 0.08–1.18 mean 0.12)
Anterior area	0.44 mm (range: 0.17–2.66 mean 0.88)	0.31 mm (range: 0.08–1.30 mean 0.41)
Posterior area	0.40 mm (range: 0.10–3.54 mean 0.79)	0.38 mm (range: 0.27–1.77 mean 0.31)
Global mean value	0.43 mm (range: 0.10–2.02 mean 0.75)	0.35 mm (range: 0.27–1.77 mean 0.56)



**Figure 1.** The 3D spatial software reconstruction of dental implant screws in pre-surgical virtual planning vs actual clinical position after the surgical procedure.

All measurements were repeated three times, by two blinded researchers to evaluate the reliability and reproducibility of the records. A non-parametric permutation method was used to data collected to establish a null hypothesis for all entitles of disturbance, including the P distribution. These tests do not depend on the type of distribution of the population, they are not based on the parameters of the distribution and it is possible to apply them even in cases of qualitative data. This tests are suggested when the variables do not have a Gaussian distribution (they are very asymmetric or present more than one peak); the sample is small; the observations are of ordinal type. The mean differences were evaluated by the permutation test, comparing the planned position and the real one. To obtain a multivariate and global result for both the Euclidean distances, as every implant was interested by different variables, the non-parametric combination (NPC) of partially dependent tests was adopted [15,18]. Two distinct permutation tests, for S and for V, that were combined with an adequate combination function. Tests were carried out separately but simultaneously, resulting in a global test. To be able to jointly consider the two variables, considering the structure of dependence between them (unknown), it is necessary to base the two tests of permutation on the same entire permutation. Figures 2 and 3 explained for the no surgeons, and the allon 4 implants surgical procedure in the mandible sites.



**Figure 2.** The 3D STL intra-oral cone-beam analysis (CBCT) scanning position data as compared to the STL virtual planning data in millimetric horizontal and spatial angle evaluation. Software reconstruction of dental implant virtual planning vs clinical position after the surgical procedure.

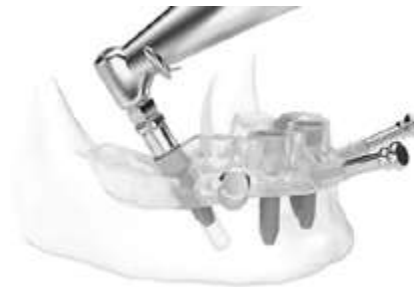

Figure 3. Just-on-4 surgical work-flow with a mucosa-supported template.

### 3. Results

100 dental implants immediate loaded were placed in 14 total edentulous maxilla with using a surgical template mucosa supported. In 12 upper jaws a total of 51 implants were placed, 23 implants in the anterior area and 28 in the posterior area. While in 11 mandibles total 49 implants were placed, 23 in the anterior and 26 in the posterior area. The sites 15, 25, and 42 were most treated with 11, 10, and 9 implants respectively. (Table 1) No intraoperative complications and no implant failure after 1 yr follow-up were detected. All virtual planning data were matched with the CBCT-STL post-surgery procedure and the implant fixture showed an error value. In maxillary area, 0.30 mm (range: 0.10–1.57 mean 0.89) S discrepancy and 0.37 mm (range: 0.30–1.77 mean 0.67) V discrepancy between virtual planning to clinical result were detected. In mandible implant sites, S difference 0.43 mm (range: 0.30–1.77 mean 0.31) and V difference 0.28 mm (range: 0.08–1.18 mean 0.12) were observed. The implant S discrepancy global mean value was 0.43 mm (range: 0.10–2.02 mean 0.75) and V mean value showed 0.35 mm (range: 0.08–1.77 mean 0.56). In the anterior area the S discrepancy between virtual planning to clinical result was 0.44 mm (range: 0.17–2.66 mean 0.88) while V value was 0.31 mm (range: 0.08–1.30 mean 0.41). In the posterior area 0.40 mm (range: 0.10–3.54 mean 0.79) S discrepancy and 0.38 mm (range: 0.27–1.77 mean 0.31) at V point were detected (Table 2). Global  $p$ -value = 0.001 of the multivariate permutation test was detected to study differences between the two Euclidean distances (virtual and real).

The partial coordinates were examined  $x_s$ ,  $y_s$ , and  $z_s$  and  $x_v$ ,  $y_v$ , and  $z_v$ , separately for S and V. Multivariate S coordinates permutation test detect global  $p$  value = 0.02 confirming the difference between the virtual and real implant positions. Significant difference was related to the  $x_s$  coordinate:  $p(x) = 0.001$ ;  $p(y) = 0.43$ ;  $p(z) = 0.98$ . Non-significant global  $p$ -value (= 0.12) resulted in V coordinates while a significant difference on the coordinates  $x_v$ :  $p(x) = 0.036$ ;  $p(y) = 0.84$ ;  $p(z) = 0.2$  is found. In both arches the permutation test confirmed the results obtained with the entire sample of implants (global  $p$  value =  $p_s = p_v = 0.001$ ). In the maxilla, for S coordinates a significant level was obtained with a global  $p$  value = 0.091 ( $x_s$ :  $p(x) = 0.068$ ;  $p(y) = 0.28$ ;  $p(z) = 0.20$ ). For the V coordinates no significant difference was found with global  $p$  value = 0.71 ( $p(x) = 0.22$ ;  $p(y) = 0.85$ ;  $p(z) = 0.89$ ). In the mandible, for the S coordinate a significant global  $p$  value = 0.017 was obtained ( $x_s$ :  $p(x) = 0.002$ ;  $p(y) = 0.95$ ;  $p(z) = 0.17$ ). For the V coordinates, the global  $p$  value was significant (0.038) above all for the coordinate  $z_v$ :  $p(x) = 0.063$ ;  $p(y) = 0.92$ ;  $p(z) = 0.021$ . The entire sequence of the implants was divided into two groups according to the position the anterior (positions 1,2,3) or in the posterior (positions 4,5,6) of the mouth. After applying the multivariate permutation test on the S and V variables, the results obtained were confirmed for the sample of all the implants global  $p$  value =  $p(S) = p(V) = 0.001$  in anterior sector as well as the posterior one. Examining the coordinates of the apex a nonsignificant global difference was found (global  $p$  value = 0.23), but on examination of the partial coordinates a significant difference was found for the coordinates  $x_s$ :  $p(x) = 0.02$ ;  $p(y) = 0.87$ ;  $p(z) = 0.96$ . No evidence was obtained in V coordinates (global  $p$  value = 0.13). In the posterior area, the S coordinate showed a 10% global difference (global  $p$  value = 0.065). In partial coordinates a significant difference was found

for the following coordinates  $x_s$ :  $p(x) = 0.007$ ;  $p(y) = 0.35$ ;  $p(z) = 0.99$ . For the implant V coordinates no significant difference was found for the global test as well as for the partial ones: global  $p$  value = 0.35;  $p(x) = 0.44$ ;  $p(y) = 0.35$ ;  $p(z) = 0.31$ . (Tables 3 and 4).

**Table 3.** Statistical 3D evaluation of discrepancies between the clinical and virtual implant positions in single patients using multivariate permutation tests.

Patients	S mean Value	Y mean Value	Global Mean
1	0.579	0.461	2.51
2	0.800	0.506	2.49
3	0.732	0.685	2.30
4	0.967	0.732	3.73
5	0.952	0.699	2.63
6	0.872	0.665	2.44
7	1.043	0.990	1.91
8	1.175	0.856	2.64
9	0.845	0.796	2.53
10	1.060	0.551	2.00
11	0.834	0.624	2.44
12	0.802	0.778	2.86
13	0.920	0.770	4.74
14	0.767	0.692	1.11

**Table 4.** Statistical 3D evaluation of discrepancies using multivariate permutation tests in maxillae vs mandibles and anterior vs posterior areas using clinical and virtual apex (S) and neck (V) implant positions.

Distance/Coordinates	Apex (S)	Neck (V)
MAXILLA		
Euclidean Distance	0.09	0.71
x	0.07	0.22
y	0.28	0.85
z	0.20	0.89
MANDIBLE		
Euclidean Distance	0.02	0.04
x	0.00	0.06
y	0.95	0.92
z	0.17	0.02
ANTERIOR AREA		
Euclidean Distance	0.23	0.13
x	0.02	0.03
y	0.87	0.46
z	0.96	0.54
POSTERIOR AREA		

Table 4. Cont.

Distance/Coordinates	Apex (S)	Neck (V)
Euclidean Distance	0.07	0.35
x	0.01	0.44
y	0.35	0.35
z	0.99	0.31
FULL MOUTH		
Euclidean Distance	0.02	0.12
x	0.00	0.04
x	0.43	0.84
z	0.98	0.20

#### 4. Discussion

Computer-aided systems are valid tools for flapless virtual planning surgery using presurgical CBCT data implementation, with specific software to reduce postoperative morbidity and to improve patient compliance. The absence of surgical flap incisions, the pre-determination of the implant positions and fixture parameters, the control of cutter depth and stitching, and the previsualization and production of prostheses before surgery for immediate loading of implants contribute to a reduction in surgical time and errors. Moreover, the accuracy of guided surgery systems must be carefully studied in order to respond to the growing needs of patients and increase the predictability of surgical results and the success of treatments. In computer-aided implant surgery, the absence of incisions and flaps and the pre-determination of exact implant positions and the depths and the sequences of the drills contribute to reducing the surgical time and patient discomfort. However, this technique has some disadvantages, including potential damage to the bone due to insufficient irrigation and the inability to visualize the surgical anatomical landmarks, with increased risk of error in implant positioning with increasing degrees of maxillary bone atrophy. Many studies have been conducted to assess the accuracy of virtual implant planning, and in all cases a discrepancy has been demonstrated between the virtual plan and the actual position of the implant in the oral cavity at the end of the surgery. The surgical problems with implant fixture are relative to the deviations in the three spatial dimensions of the screw position, which are higher in horizontal points and lower in the vertical points, as described in the literature, confirming that implant rehabilitation through computer-aided surgery is a predictable procedure that requires constant verification, especially in flapless surgery, to reduce the high risk of error in implant positioning during surgical procedures that use supported surgical templates. The first crucial factor affecting clinical result accuracy is the stability of the surgical template during the CBCT analysis and during surgical procedures with respect to surgical template positioning on the bone with pins to avoid damaging noble anatomic structures such as nerves, vessels, etc., because any small deviations may cause surgical errors and iatrogenic anatomical lesions, which are reported in the literature to occur in 9.1% of all cases. The second crucial factor affecting computer-aided surgery accuracy for the correct angle of insertion of the implant drills, is relates to the area of surgery and the mouth-opening capacity because in 2.3% of cases in the posterior maxillary area there is a limited interocclusal distance [15]. The third crucial factor that affects accuracy is related to the bone volume and bone architecture in atrophic bone areas of the jaws, together with potential micromovements of the surgical mucosa-supported template due to the typical resilience of the oral mucosa [15,16]. Mucosa-supported guided surgery is a tool used to preoperatively study the anatomical conditions of the jaws, pre-view the best implant insertion method, and plan the implant dimensions integrated into the predictable prosthetic rehabilitation workflow to prepare immediate-load provisional restoration, avoiding complications [17,18]. At present, mucosa-supported guided surgery scientific literature is scarce and more in vitro and vivo studies should be carried out to understand surgical accuracy. [19] A

recent review and meta-analysis compared three types of guides (bone, mucosa, or tooth-supported), with a total 345 implants placed with mucosa-supported guides, concluding that more clinical studies should be performed to provide evidence about the accuracy of guided surgery, as well as to evaluate the variables that could affect the precision of the technique. [20] In the literature, few scientific studies have correlated implant dimensions and bone density with guided surgery implant placement accuracy [21], and there are only simple theoretical references to bone density, mouth opening, visibility, surgical guide stability, skill of the surgeon, and patient movements during surgical procedures. [22] However, during bone drilling and implant insertion, mucosa-supported guided surgery is a blind technique, and thus to obtain predictable clinical results, presurgical 3D implant planning should be highly accurate in order to translate the virtual planning data into clinical surgical practice and to place the implants in the correct prosthetic positions, avoiding damage to important anatomic structures such as nerves, roots, or maxillary sinuses. [23] In 2014, Schneider et al. showed that metal sleeves with a degree of tolerance to the surgical templates allowed cutter entrance and movement during surgical procedures. This specific tolerance could make them deviate during the drilling procedures, altering the angle of surgical site formation and final implant placement into the bone. Furthermore, long cutters promote greater angular or horizontal deviations. Thus, the length of the implants could also influence the accuracy of the clinical result [24]. Recently, Hoffmann et al. [25] reported statistically significant differences in implant surgical computer-aided accuracy, with mean angular deviations of  $4.2 \pm 1.8$  and  $11.2 \pm 5$ , respectively. In 2018, Chang-Kai et al. reported  $1.50 \pm 0.79$  mm horizontal deviation values at the apical endpoint. Implant placement accuracy with computer-aided static navigation systems was shown to be better ( $6.02 \pm 3.71$ ) compared to the manual implant placement ( $9.26 \pm 3.62$ ) [12,26]. Augmented reality devices could be used to display the virtual planning image as compared to the reality of the surgical field [12]. In a recent study, Verduyssen et al. [27] showed a high accuracy error of 0.9 mm (range: 0.1–4.5, mean 0.8) at the neck and of 1.2 mm (range: 0.2–4.9, mean 1.1) at the apex, with an angular deviation error of 2.7 (range: 0.0–6.6, mean 2.3). In 2016, Schneider described accuracy through an evaluation of implant apex deviation in terms of height, showing a 1.07 mm deviation at the neck point, a 1.63-mm deviation at the apex, and a 5.26 angular discrepancy [15]. Our study confirmed a risk of error between the virtual plan and the clinical implant position in surgical mucosa-supported templates, however with lower values than those found in the scientific literature. Indeed, the data obtained showed a 0.30 mm discrepancy at the apex with a 0.37 mm global horizontal discrepancy at the neck in the maxilla, and a 0.43-mm discrepancy at the apex with a 0.28 mm global horizontal discrepancy at the neck in the mandible. A 0.43 mm global mean value at the apex and a 0.35 mm discrepancy at the neck were detected. The multivariate scale permutation test confirmed the accuracy discrepancy in 3D spatial coordinates. Significant differences were shown in the mandible at the apex ( $p = 0,017$ ), while higher values were found in the posterior area than the anterior for the apex ( $p = 0,001$ ) and for the angle in the maxillary area. In conclusion, computer-aided surgery with a mucosa-supported template seems to be a predictable and reproducible procedure capable of reducing surgical times and patient discomfort [28–31]. However, our study has shown an inaccuracy of the virtual projection, with a horizontal and angle discrepancy between the clinical position of the dental implant as compared to virtual planning. Although virtual planning reproduces in detail the anatomical and clinical characteristics of the future implant site, it should be noted that the accuracy required within the flapless surgical procedure does not seem to be sufficient in cases of severe atrophy of the jaws and in the presence of particular anatomies of the maxillary bone and in the posterior areas of the maxilla, with risks of error present in the procedure.

**Author Contributions:** Conceptualization, M.M. and R.A.; Data curation, A.G.L., A.S., L.L.M., E.F.G., and F.M.; Investigation, R.V., M.M., R.A., A.S., and F.M.; Methodology, M.M., A.S., C.C., L.L.M., and E.F.G.; Project administration, M.M. and F.M.; Resources, M.M. and Raffaele Vinci; Writing—original draft, F.M.; Writing—review and editing, F.M. and R.A. All authors have read and agreed to the published version of the manuscript.

**Funding:** This research received no external funding.

**Acknowledgments:** The authors are grateful for the assistance of the statistician from the Economy Department of the University of Foggia and the professional English language translator Morgan Glynis (a native English-speaker). The authors also declare that they were fully independent in preparing the protocol, conducting the research, interpreting the results, and preparing the manuscript.

**Conflicts of Interest:** The authors declare no conflict of interest.

## References

- Hämmerle, C.H.F.; Jung, R.E.; Feloutzis, A. A systematic review of the survival of implants in bone sites augmented with barrier membranes (guided bone regeneration) in partially edentulous patients. *J. Clin. Periodontol.* **2002**, *29*, 226–231. [[CrossRef](#)] [[PubMed](#)]
- Pjetursson, B.E.; Bragger, U.; Lang, N.P.; Zwahlen, M. Comparison of survival and complication rates of tooth-supported fixed dental prostheses (fdps) and implant-supported fdps and single necks (scs). *Clin. Oral Implant. Res.* **2007**, *18*, 97–113. [[CrossRef](#)] [[PubMed](#)]
- Jung, R.E.; Pjetursson, B.E.; Glauser, R.; Zembic, A.; Zwahlen, M.; Lang, N.P. A systematic review of the 5-year survival and complication rates of implant-supported single neck. *Clin. Oral Implant. Res.* **2008**, *19*, 119–130.
- Schulze, D.; Heiland, M.; Thurmann, H.; Adam, G. Radiation exposure during midfacial imaging using 4- and 16-slice computed tomography, cone beam computed tomography systems and conventional radiography. *Dentomaxillofacial Radiol.* **2004**, *33*, 83–86. [[CrossRef](#)] [[PubMed](#)]
- Guerrero, M.E.; Jacobs, R.; Loubele, M.; Schutyser, F.; Suetens, P.; Van Steenberghe, D. State-of-the-art on cone beam CT imaging for preoperative planning of implant placement. *Clin. Oral Investig.* **2006**, *10*, 1–7. [[CrossRef](#)]
- Jung, R.E.; Schneider, D.; Ganeles, J.; Wismeijer, D.; Zwahlen, M.; Hämmerle, C.H.F.; Tahmaseb, A. Computer technology applications in surgical implant dentistry: A systematic review. *Int. J. Oral Maxillofac. Implant.* **2009**, *24*.
- Chen, X.; Yuan, J.; Wang, C.; Huang, Y.; Kang, L. Modular Preoperative Planning Software for Computer-Aided Oral Implantology and the Application of a Novel Stereolithographic Template: A Pilot Study. *Clin. Implant. Dent. Relat. Res.* **2009**, *12*, 181–193. [[CrossRef](#)]
- Tahmaseb, A.; Wismeijer, D.; Coucke, W.; Derksen, W. Computer technology applications in surgical implant dentistry: A systematic review. *Int. J. Oral Maxillofac. Implant.* **2014**, *29*, 25–42. [[CrossRef](#)]
- Kupeyan, H.K.; Shaffner, M.; Armstrong, J. Definitive CAD/CAM-guided prosthesis for immediate loading of bone-grafted maxilla: A case report. *Clin. Implant. Dent. Relat. Res.* **2006**, *8*, 161–167. [[CrossRef](#)]
- Hämmerle, C.; Stone, P.; Jung, R.E.; Kapos, T.; Brodala, N. Consensus statements and recommended clinical procedures regarding computer-assisted implant dentistry. *Int. J. Oral Maxillofac. Implant.* **2009**, *24*.
- Gargallo-Albiol, J.; Barootchi, S.; Salomó-Coll, O.; Wang, H.-L. Advantages and disadvantages of implant navigation surgery. A systematic review. *Ann. Anat. - Anat. Anz.* **2019**, *225*, 1–10. [[CrossRef](#)] [[PubMed](#)]
- Alfonso Mediavilla, G.; Elena Riad, D.; Álvaro, Z.-M.; Rubén, A.-P.; Sofía Hernández, M. Accuracy of Computer-Aided Dynamic Navigation Compared to Computer-Aided Static Navigation for Dental Implant Placement: An in Vitro Study. *J. Clin. Med.* **2019**, *8*, 2123. [[CrossRef](#)] [[PubMed](#)]
- Widmann, G.; Bale, R. Accuracy in computer-aided implant surgery—a review. *Int. J. Oral Maxillofac. Implant.* **2006**, *21*, 305–313.
- Tahmaseb, A.; Wu, V.; Wismeijer, D.; Coucke, W.; Evans, C.; Wu, V. The accuracy of static computer-aided implant surgery: A systematic review and meta-analysis. *Clin. Oral Implant. Res.* **2018**, *29*, 416–435. [[CrossRef](#)]
- Schneider, D.; Marquardt, P.; Zwahlen, M.; Jung, R.E. A systematic review on the accuracy and the clinical outcome of computer-guided template-based implant dentistry. *Clin. Oral Implant. Res.* **2009**, *20*, 73–86. [[CrossRef](#)]
- D'Haese, J.; Van De Velde, T.; Elaut, L.; De Bruyn, H. A Prospective Study on the Accuracy of Mucosally Supported Stereolithographic Surgical Guides in Fully Edentulous Maxillae. *Clin. Implant. Dent. Relat. Res.* **2009**, *14*, 293–303. [[CrossRef](#)]



17. Ruth, V.; Kolditz, D.; Steiding, C.; Kalender, W.A. Metal Artifact Reduction in X-ray Computed Tomography Using Computer-Aided Design Data of Implants as Prior Information. *Investig. Radiol.* **2017**, *52*, 349–359. [[CrossRef](#)]
18. Tahmaseb, A.; De Clerck, R.; Eckert, S.; Wismeijer, D. Reference-based digital concept to restore partially edentulous patients following an immediate loading protocol: A pilot study. *Int. J. Oral Maxillofac. Implant.* **2011**, *26*, 707–717.
19. Vercruyssen, M.; Laleman, I.; Jacobs, R.; Quirynen, M. Computer supported implant planning and guided surgery: A narrative re- view. *Clin. Oral Implant. Res.* **2015**, *26*, 69–76. [[CrossRef](#)]
20. Gallardo, Y.N.R.; Silva-Olivio, I.R.T.; Mukai, E.; Morimoto, S.; Sesma, N.; Cordaro, L. Accuracy comparison of guided surgery for dental implants according to the tissue of support: A systematic review and meta-analysis. *Clin. Oral Implant. Res.* **2016**, *28*, 602–612. [[CrossRef](#)]
21. Cassetta, M.; Di Mambro, A.; Giansanti, M.; Stefanelli, L.V.; Cavallini, C. The intrinsic error of a stereolithographic surgical template in im- plant guided surgery. *Int. J. Oral Maxillofac. Surg.* **2013**, *42*, 264–275. [[CrossRef](#)] [[PubMed](#)]
22. Van Assche, N.; Quirynen, M. Tolerance within a surgical guide. *Clin. Oral Implant. Res.* **2010**, *21*, 455–458. [[CrossRef](#)] [[PubMed](#)]
23. Andoni, J. Accuracy of mucosa supported guided dental implant surgery. *Clin. Case Rep.* **2018**, *6*, 2131–2139.
24. Schneider, D.; Schober, F.; Grohmann, P.; Hämmerle, C.H.F.; Jung, R.E. In-vitro evaluation of the tolerance of surgical instruments in templates for computer-assisted guided implantology produced by 3-D printing. *Clin. Oral Implant. Res.* **2014**, *26*, 320–325. [[CrossRef](#)] [[PubMed](#)]
25. Hoffmann, J.; Westendorff, C.; Reinert, S.; Gomez-Roman, G. Accuracy of navigation-guided socket drilling before implant installation compared to the conventional free-hand method in a synthetic edentulous lower jaw model. *Clin. Oral Implant. Res.* **2005**, *16*, 609–614. [[CrossRef](#)] [[PubMed](#)]
26. Chen, C.-K.; Yuh, D.-Y.; Huang, R.-Y.; Fu, E.; Tsai, C.-F.; Chiang, C.-Y. Accuracy of Implant Placement with a Navigation System, a Laboratory Guide, and Freehand Drilling. *Int. J. Oral Maxillofac. Implant.* **2018**, *33*, 1213–1218. [[CrossRef](#)]
27. Vercruyssen, M.; Cox, C.; Naert, I.; Jacobs, R.; Teughels, W.; Quirynen, M. Accuracy and patient-centered outcome variables in guided implant surgery: A RCT comparing immediate with delayed loading. *Clin. Oral Implant. Res.* **2015**, *27*, 427–432. [[CrossRef](#)]
28. Pesarin, F.; Salmaso, L. *Permutation Tests for Complex Data*; Wiley series in probability and statistics; Wiley: Hoboken, NJ, USA, 2010.
29. Antonucci, L.; Bolzan, M.; Carrozzo, E.; Crocetta, C.; Di Gioia, L.; Manacorda, M.; Mastrangelo, F.; Russo, M.; Salmaso, L. Accuracy of computer guided implant dentistry: A permutation testing approach. *Electron. J. Appl. Stat. Anal. (EJASA)* **2019**, *12*, 542–551.
30. Bover-Ramos, F.; Cervera-Ballester, J.; Viña-Almunia, J.; Peñarrocha-Diago, M.; García-Mira, B. Accuracy of Implant Placement with Computer-Guided Surgery: A Systematic Review and Meta-Analysis Comparing Cadaver, Clinical, and In Vitro Studies. *Int. J. Oral Maxillofac. Implant.* **2018**, *33*, 101–115. [[CrossRef](#)]
31. Wenjuan, Z.; Zhounghao, L.; Liansheng, S.; Chia-Ling, K.; David, M.S. Clinical Factors affecting the accuracy of guided implant surgert- A systematic review and meta-analysis. *J. Evid. Based Dent. Pr.* **2018**, *18*, 28–40.



© 2020 by the authors. Licensee MDPI, Basel, Switzerland. This article is an open access article distributed under the terms and conditions of the Creative Commons Attribution (CC BY) license (<http://creativecommons.org/licenses/by/4.0/>).



## CASO CLINICO

## Tecniche rigenerative dei mascellari atrofici: revisione della letteratura e case report

*Regenerative techniques of atrophic jaws: literature review and a case report*

✉ lorenzoredi2906@gmail.com

### SCOPO DEL LAVORO

Lo scopo di questo lavoro è quello di descrivere le procedure di espansione e/o rigenerazione ossea maggiormente conosciute, atte ad ottenere volumi ossei idonei al posizionamento di impianti osteointegrati, garantendo così una stabilità biologica della nostra riabilitazione nel tempo e di descrivere un caso clinico risolto mediante espansione del mascellare con tecnica "split crest".

### MATERIALI E METODI

Dopo una ricerca sul web e la lettura di 30 articoli, 16 sono stati inclusi in questa revisione.

Abbiamo descritto le procedure rigenerative ed espansive più studiate e abbiamo descritto un caso risolto con la tecnica "split crest" dopo 7 anni di follow-up.

### RISULTATI

Secondo la letteratura possiamo affermare che la tecnica split crest rappresenta il gold standard in caso di difetti orizzontali con 3 mm di spessore residuo dell'osso alveolare.

### CONCLUSIONI

Dopo 7 anni di follow-up possiamo osservare come l'osso marginale è stabile e la riabilitazione è appropriata per il paziente.

**L**e neoplasia plasmacellulari sono caratterizzate da una proliferazione neoplastica monoclonale di plasmacellule.

Nel corso degli ultimi decenni sono state descritte svariate tecniche di ricostruzione ossea pre-implantare in caso di mascellari atrofici. Le ricostruzioni ossee rendono possibile il posizionamento di impianti in volumi ossei adeguati e ottenere un risultato estetico-funzionale adeguato alla richiesta dei nostri pazienti.

La formazione di un'interfaccia diretta osso-impianto (osteointegrazione) è un requisito fondamentale nell'ambito delle riabilitazioni implanto-protetico.

Per questo è necessario avere a disposizione una quantità e qualità di osso sufficienti a garantire un posizionamento implantare congruo proteticamente e biologicamente stabile nel tempo e nell'immediato (stabilità primaria).

In alcuni casi ci troviamo ad affrontare situazioni nelle quali le basi ossee residue risultano inadeguate al posizionamento implantare.

La perdita di osso alveolare può essere dovuta a danno iatrogeno (protesi mobili incongrue, estrazioni cruente ecc.); malattia parodontale e traumi alveolo-dentali.

Il ripristino dei volumi ossei è argomento di discussione da svariati decenni: gli autori hanno descritto negli anni vari protocolli chirurgici peri-



rigenerazione ossea, split crest, volume osseo, book flap, bundle bone, tecnica piezoelettrica

bone regeneration, split crest, bone volume, book flap, piezoelectric technique



**Lorenzo Redi\***  
**Guglielmo Turbiglio\***  
**Luca Abbruzzese\***  
**Luca Pinto\*\***  
**Francesca Mottola\*\***  
**Matteo Nagni\*\***  
**Raffaele Vinci\*\*\***

\*  
 Dipartimento di Odontoiatria, Università Vita-Salute San Raffaele, Milano

\*\*  
 Specializzando in Chirurgia orale, Dental School Università Vita-Salute San Raffaele, IRCCS Ospedale San Raffaele, Milano

\*\*\*  
 Professore associato Malattie Odontostomatologiche, Cattedra di Chirurgia orale, Direttore Scuola di Specializzazione in Chirurgia orale, Responsabile Unità Dipartimentale di Chirurgia orale Università Vita-Salute San Raffaele, Milano

## CASO CLINICO

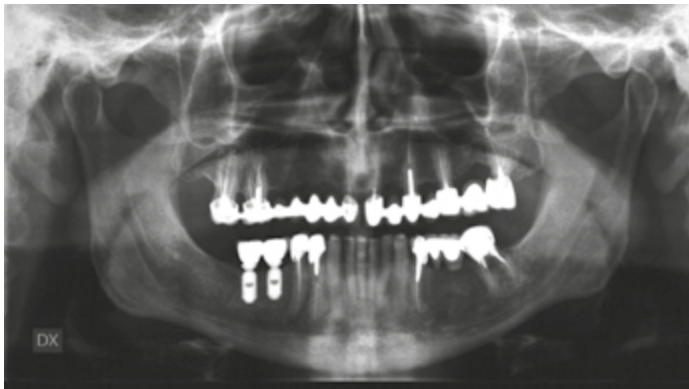


Fig. 1 Rx OPT pre-operatoria.

mentando varie tecniche e materiali.

Le tecniche rigenerative ad oggi più utilizzate e conosciute sono:

1. innesti di osso autologo;
2. rigenerazione ossea guidata (GBR);
3. tecniche espansive (split crest);
4. osteogenesi distrazionale.

#### Innesti di osso autologo

Rappresentano, ad oggi, il gold standard in termini di predicibilità del risultato e qualità ossea risultante (1-3).

Sono classificati in base alla sede di prelievo (intra-extra orali) e alla morfologia (particolato o blocchi).

Questi tipi di innesti risultano i più predicibili in quanto il materiale innestato è autologo, quindi meno soggetto ad infezioni (2).

Come fattore negativo troviamo la necessità di un sito donatore che potrebbe comportare maggiore dolore e/o gonfiore post-operatori ai nostri pazienti.

I primi studi furono condotti da Branemark et al. nel 1975 (1). Analizzarono 31 casi di ricostruzione di mandibole atrofiche (post resezioni oncologiche e traumi) realizzate con blocchi di osso autologo fissati con placche da osteosintesi.

I risultati furono eclatanti in termini di predicibilità e stabilità nel tempo.

#### Rigenerazione ossea guidata

Comprende un ampio panorama di materiali e tecniche da utilizzare e prevede

l'utilizzo di sostituti ossei eterologhi e/o alloplastici.

Le tecniche rigenerative ossee guidate prevedono inoltre l'ausilio di membrane riassorbibili e non e di materiali da osteosintesi in titanio come placche e viti (6-7).

La maggior parte degli autori utilizza i materiali eterologhi miscelati ad osso autologo particolato prelevato nelle zone limitrofe alla zona da rigenerare in equazione 50:50 circa. Utilizzando infatti dei "bone collector" è possibile recuperare piccole quantità di osso autologo da miscelare al sostituto (4-7).

In caso di interventi rigenerativi più estesi si dovrà ricorrere ad un sito di prelievo (branca montante della mandibola, mento, arco zigomatico).

L'utilizzo di molti ausili di natura artificiale rende questi tipi di interventi più sog-

getti a complicanze di tipo infettivo: l'eposizione precoce delle membrane di ricoprimento rappresenta la prima causa di fallimento di questi interventi.

La GBR odierna basa i propri principi su quelli della GTR (guided tissue regeneration).

La rigenerazione tissutale guidata è stata oggetto di studio per autori come Nyman et al. sin dagli inizi degli anni '80 (4); gli studi si basavano sul concetto biologico secondo il quale cellule specifiche contribuiscono alla formazione di tessuti specifici. Melcher nel 1976 descrisse come l'esclusione dell'epitelio e del tessuto connettivo attraverso l'utilizzo di membrane in difetti parodontali favorisse la proliferazione di tessuti più lenti nell'istodifferenziarsi come osteoblasti, cementoblasti e cellule del legamento parodontale (5). Per ottenere ciò era necessario creare una barriera tra i tessuti molli e l'osso sottostante che durasse almeno 6-8 settimane (tempo necessario per l'istodifferenziazione) (4-5).

Così, a partire da quegli anni, autori come Dahlin e colleghi iniziarono a sperimentare vari sostituti ossei e membrane in difetti ossei più estesi (6).

Furono quindi realizzati protocolli operativi che comprendono l'utilizzo di barriere di varia natura (titanio, gore-tex, PTFE .. ecc) e di sostituti ossei eterologhi, alloplastici o omologhi (5-7).

#### Tecniche espansive

Le ossa dei mascellari possono essere espanse a patto che conservino le corticali esterne e la midollare (non meno di 3 mil-

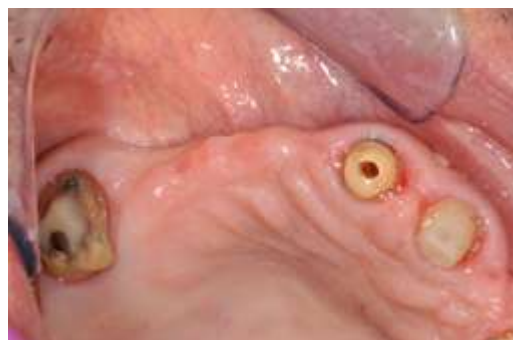

Fig. 2 Vista occlusale dell'area edentula.

## CASO CLINICO

limetri di spessore osseo residuo suddivisi in 1 mm corticale vestibolare - 1 mm midollare - 1 mm corticale palatina) (9).

L'ausilio della strumentazione ultrasonica e di particolari inserti dedicati ha reso l'espansione ossea una tecnica meno operatore dipendente rispetto al passato e quindi applicabile in un numero di casi sempre maggiore.

La tecnica espansiva più conosciuta è quella della "split crest" ampiamente descrit-

ta da vari autori: questa può essere realizzata in una o due fasi chirurgiche in base al grado di atrofia e all'abilità dell'operatore (8-11).

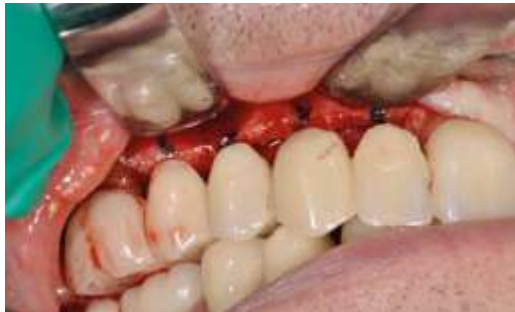Nel 1986, Nentwig descrisse una tecnica di "divisione" della cresta alveolare che permettesse simultaneamente l'espansione crestale ed il posizionamento implantare (8).

L'autore infatti mise a punto un protocollo chirurgico che prevedeva la divisione del-

la cresta alveolare in due parti: l'apertura centrale ed il conseguente gap osseo venivano colmati in parte dall'impianto e in parte da osso autologo e/o sostituiti ossei.

L'autore definì questa procedura operatore-dipendente ma, una volta acquisita una certa esperienza, risulta efficace e predicibile (8).

Successivamente autori come Bruschi e Scipioni maturarono notevole esperienza con la tecnica e misero a punto tecniche e protocolli chirurgici validissimi ancora oggi (9-11).



**Fig. 3** L'emergenza protesica viene riportata sul segmento scheletrico.

#### Osteogenesi distrazionale

L'osteogenesi distrazionale trova le sue prime applicazioni in campo ortopedico: il primo ad utilizzarla fu Alessandro Codivilla agli inizi del XX secolo per realizzare un allungamento di femore (12-13). La procedura fu successivamente sviluppata ed adattata ad altri distretti e con l'ausilio della radiologia era possibile confermare le crescite anche da un punto di vista radiografico.

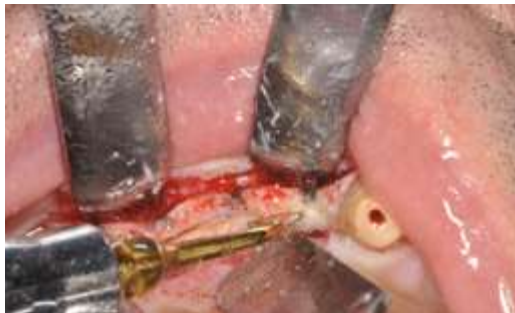Solamente alla fine degli anni '80 Joseph McCarthy codificò i principi dell'osteodistrazione applicati al distretto craniomaxillofaciale (14).

Secondo gli autori questa tecnica risulta vantaggiosa in quanto consente la ricostruzione del tessuto duro e molle all'unisono: durante il processo distrazionale il tessuto molle prolifera seguendo la crescita ossea.

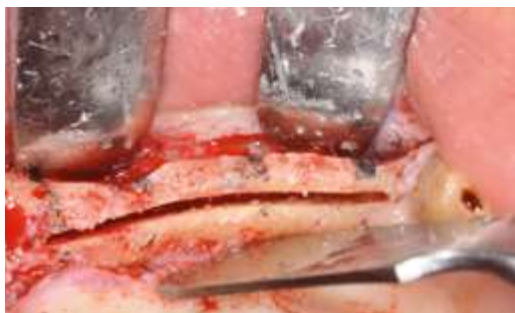La tecnica prevede l'utilizzo di distrattori, particolari apparecchi che variano per forma e dimensione in base alla lunghezza e posizione anatomica del segmento da distrarre.

Il protocollo chirurgico è relativamente semplice: dopo l'incisione di un lembo a spessore totale fino a centro cresta (il lembo non deve essere scollato nel versante linguale o palatale) si realizzano i tagli osteotomici (orizzontale, verticale mesiale e verticale distale) avendo cura di non ledere il periostio linguale o palatale (14-16). Si applica quindi il distrattore fissando le estremità all'osso basale e al segmento osseo da distrarre.

I segmenti vengono lasciati separati tra loro di circa 1-2 mm e i lembi vengono su-



**Fig. 4a, 4b** Incisione della cresta alveolare con strumento piezoelettrico.



**Fig. 4b**



## CASO CLINICO

turati lasciando fuoriuscire il braccio per l'attivazione dell'apparecchio.

È imprescindibile che sia il segmento osseo sia l'apparecchio non interferiscano con i movimenti masticatori.

Dopo 10 giorni circa l'apparecchio viene attivato producendo 1 mm circa di distrazione giornaliera: il paziente infatti attiva di 0,5 mm l'apparecchio al mattino e 0,5 mm alla sera.

Una volta ottenuta l'altezza desiderata (attivare per 5-15 gg) si passa alla fase di stabilizzazione: l'apparecchio viene bloccato in posizione finale mantenendo il segmento osseo immobile per circa 3 mesi (14-16). Successivamente si procederà alla rimozione del distrattore e al posizionamento degli impianti.

Questa tecnica può rappresentare un'alternativa in caso di aumenti in senso verticale della cresta: non si ottengono infatti benefici in senso trasversale.

I fattori negativi sono rappresentati dal costo dell'apparecchio, l'ingombro di esso ed eventuali errori di posizionamento che possono portare da una compromissione del risultato fino ad una completa necrosi del segmento mobilizzato.

È inoltre legato alla compliance del paziente: ad esso infatti viene affidato il compito delle attivazioni domiciliari e un cambio di dieta per 4 mesi circa onde evitare movimenti anomali dell'apparecchio e/o del segmento osseo (15-16).

## MATERIALI E METODI

Si presenta alla nostra attenzione, presso l'unità dipartimentale di Chirurgia Orale dell'Ospedale San Raffaele di Milano, un paziente 57enne di sesso maschile.

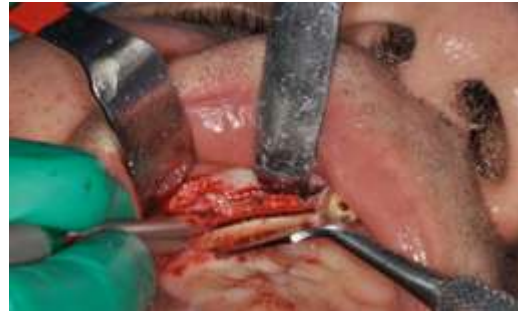All'anamnesi medica non si riscontra niente di rilevante: paziente classificabile ASA I.

L'anamnesi odontoiatrica evidenzia interventi di implantologia e cure odontoiatriche primarie e il paziente riferisce una sensazione di fastidio spontaneo e alla masticazione nel primo e secondo quadrante ed un elevato sanguinamento durante e dopo le manovre di igiene domiciliare.

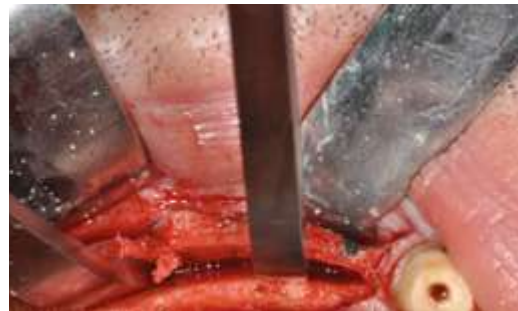All'esame obiettivo si rileva la presenza di una riabilitazione fissa tipo "full arch" su

**Fig. 5a, 5b**

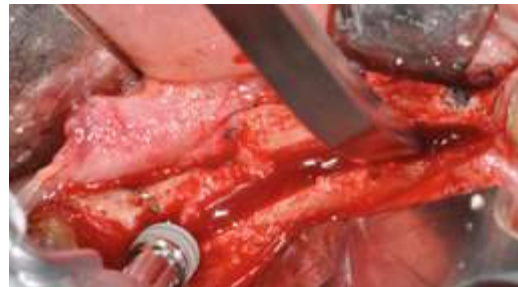Finalizzazione dell'espansione con scalpelli manuali: la frattura a legno verde nella porzione più distale rappresenta una complicanza relativa in quanto il tassello verrà nutrito dal periostio.



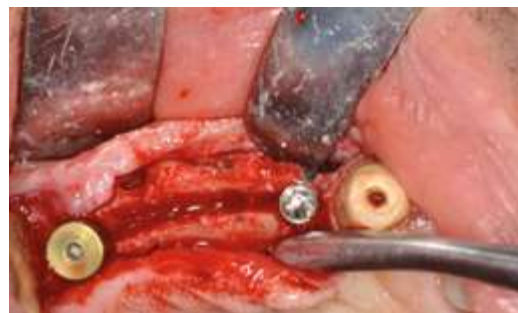**Fig. 5b**



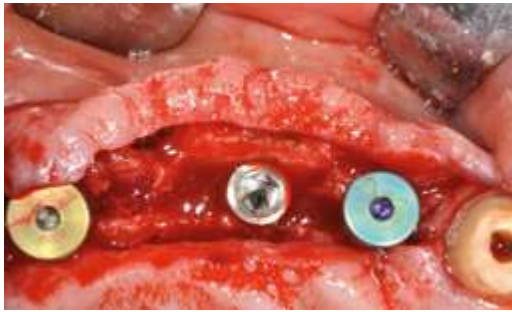
**Fig. 6a, 6b** Sequenza operativa del posizionamento implantare.



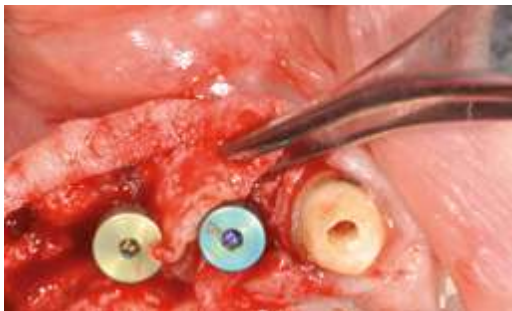**Fig. 6b**



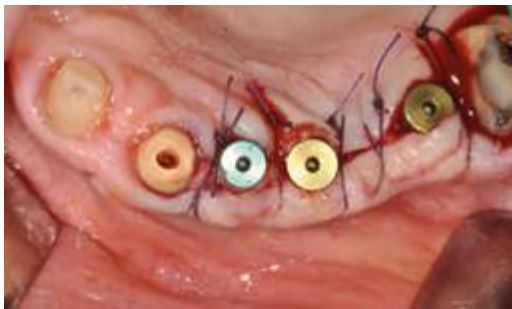## CASO CLINICO



**Fig. 7a, 7b**  
Finalizzazione del posizionamento impiantare e gestione del gap osseo.



**Fig. 7b**



**Fig. 8** Sutura.



**Fig. 9** Rx endorale.

monconi naturali all'arcata superiore divisa in due segmenti: ponte da 1.1 a 1.7 (monconi 1.1, 1.6 e 1.7) e ponte da 2.1 a 2.7 (monconi 2.1, 2.3, 2.5 e 2.7).

Nell'arcata inferiore erano invece presenti due impianti in posizione 4.6 e 4.7, due corone su elementi naturali 4.5 e 4.4 e un ponte da 4.4 a 4.7. I restanti elementi presentavano cure conservative e mobilità.

Il ponte superiore risultava con margini debordanti su 1.7 e 1.6 e la travata protesica risultava troppo estesa.

L'elemento 2.7 risultava cariato sulla radice e l'elemento 2.3 presentava rarefazione apicale, il manufatto risultava inoltre debordante su tutti i monconi.

Si è dunque deciso per il recupero dei monconi 1.7, 1.6, 1.1, 2.1, 2.3, 2.5; inserimento di impianti in sede 1.2, 1.3, 1.5 e 1.6 e successivo rifacimento protesico di tutta l'arcata superiore realizzando corone unite su 1.7 e 1.6, ponte su impianti 1.2-1.5, ponte da 1.1 a 2.5 e corona singola su 2.6.

Come conseguenza della perdita degli elementi dentali al primo quadrante in giovane età, il paziente presentava atrofia trasversale (IV classe di Cawood-Howell).

L'opzione di trattamento proposta è stata quindi una espansione mascellare tipo "split crest" con conseguente inserimento di impianti in sede 1.2, 1.3 e 1.5.

## FASE CHIRURGICA

In anestesia locale, previa profilassi antibiotica, si procede all'allestimento di un lembo tipo "book flap" a spessore totale, esponendo solamente la porzione coronale della cresta alveolare, da 1.1 a 1.7: lo scollamento ridotto permette il mantenimento della vascolarizzazione corticale.

Le future emergenze implantari vengono riportate sul segmento scheletrico denudato utilizzando come riferimento il provvisorio.

Viene eseguita l'incisione osteotomica occlusale al centro della cresta alveolare: sono stati lasciati circa 2mm di osso in spessore su ambi i versanti della cresta. L'osteotomia è stata realizzata con manipolo ultrasonico e inserto osteotomico. Il segmento osseo vestibolare è stato mobilizzato utilizzando scalpelli manuali.

## CASO CLINICO

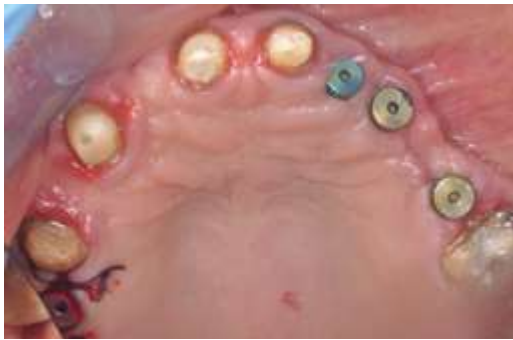

Fig. 10 Controllo clinico a 10 gg dal posizionamento implantare.

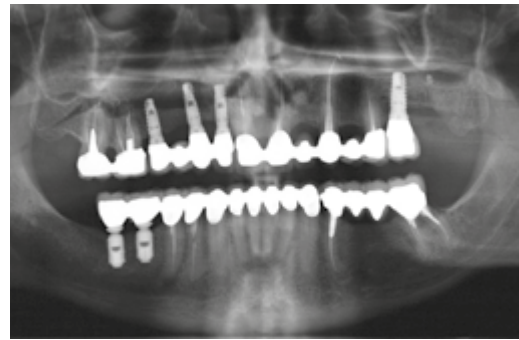


Fig. 11 Controllo radiografico a 7 anni.

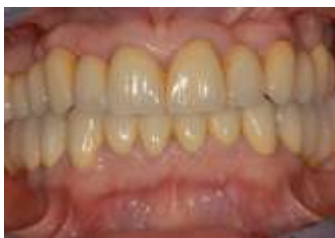

Fig. 12a

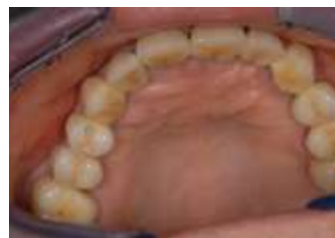

Fig. 12b

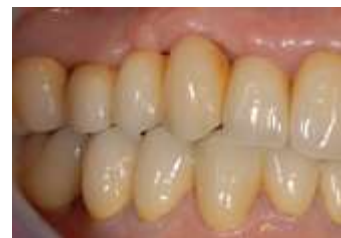

Fig. 12c

Fig. 12a, 12b, 12c Controllo clinico a 7 anni.

Dopo aver ottenuto un gap di circa 2-3 mm fra le due pareti ossee viene lasciato inserito l'ultimo scalpello utilizzato per espandere nella porzione mediana del segmento scheletrico, viene effettuata una minima preparazione dei siti implantari 1.2 e 1.5 e vengono dunque inseriti gli impianti in posizione 1.2 (Winsix TTi 3.3 mm x 13 mm) e in posizione 1.5 (Winsix TTi 3.8 mm x 11 mm). Dopo aver rimosso lo scalpello dal segmento scheletrico, è stata effettuata una minima preparazione del sito implantare 1.3 e viene inserito l'ultimo impianto (Winsix TTi 3.8 mm x 13 mm). Tutti gli impianti hanno raggiunto un torque di inserimento > 40 n/cm: questo è dovuto alla sottopreparazione dei siti implantari e alla capacità osteotomica degli impianti Torque Type. Dopo aver posizionato le viti di guarigione, è stato realizzato un innesto di connettivo pedunculato e ruotato in sede 1.2 con prelievo dal palato: è stato quindi possibile sigillare la porzione coronale di osso splittato. Il

lembo vestibolare è stato rilasciato incidendo il periostio e i lembi sono stati suturati ottenendo una chiusura per prima intenzione. Gli impianti non sono stati caricati.

Le emergenze implantari, precedentemente verificate con il provvisorio, risultavano congrue.

Il paziente è stato tenuto sotto controllo tramite richiami periodici fino ad avvenuta integrazione degli impianti (4 mesi) e, dopo la realizzazione dei manufatti definitivi è stato inserito nel protocollo di mantenimento che prevede 3-4 sedute di igiene annuali.

#### RISULTATI

Dopo un follow-up di 7 anni, la riabilitazione appare ben tollerata dal paziente e non sono presenti alterazioni né meccaniche né biologiche, non si evidenziano segni di patologia peri-implantare e di riassorbimento della cresta marginale residua.

Questa tecnica è indicata quando gli spessori ossei residui lo consentono: sono infatti necessari almeno 3mm di osso residuo preferibilmente suddiviso in 1mm di corticale vestibolare e palatale e 1mm di midollare.

#### CONCLUSIONI

L'utilizzo di questa tecnica ci ha permesso di ottenere un bundle-bone sufficiente e necessario al mantenimento degli impianti nel tempo sfruttando l'osso residuo del paziente, senza l'utilizzo di bio-sostituti: questo aumenta la predicibilità del nostro atto chirurgico.

#### AIM OF THE WORK

The aim of this article is to describe the different kind of surgical procedures purposes to regenerate or expand atrophic maxillary bones due or prior of the implant placement.

these techniques guarantee us an adequate bundle-bone around our implants and a primary stabi-



## CASO CLINICO

lity, as written by literature.

In this article is also described a case report solved with the "split-crest" technique, with its follow-up after 7 years from the prosthesis placement.

### MATERIAL AND METHODS

After a web searching and the lecture of 30 articles 16 were included in this review.

We described the most investigated regenerative and expansive procedures and we described a case solved with "split-crest" technique after 7 years of follow-up.

### RESULTS

According to the literature we can affirm that the split-crest technique represents the gold standard in case of horizontal defects with 3mm of residual alveolar bone thickness.

### CONCLUSIONS

After 7 years follow-up we can observe how the marginal bone is stable and the rehabilitation is appropriate to the patient.

### BIBLIOGRAFIA

1. Branemark PI; Linstrom J; Breine U; Jeppson PH; Ohman A. Reconstruction of the defective mandible. *Scand J Plast Reconstr Surg* 1975; 9: 116-28.
2. Misc CE, editor. Bone augmentation for implant placement: keys to bone grafting. Contemporary implant dentistry. St. Louis, MO: Mosby; 1999 p.457.
3. Cordaro L; Torsello F; Miuccio MT; di Torresanto VM; Eliopoulos D. Mandibular bone harvesting for alveolar reconstruction and implant placement: subjective and objective cross-sectional evaluation of donor and recipient site up to 4 years. *Clin Oral Implants Res* 2011; 22:1320-6.
4. Nyman S; Karring T; Lindhe J; Planten S. Healing following implantation of periodontitis-affected roots into gingival connective tissue. *J Clin Periodontol* 1980; 7(5): 394-401.
5. Melcher AH. On the repair potential of periodontal tissues. *J periodontol* 1976; 47(5): 256-60.
6. Dahlin C; Gottlow J; Linde A; Nyman S. Healing of maxillary and mandibular defects using a membrane technique. An experimental study in monkeys. *Scand J Plast Reconstr Surg Hand Surg* 1990; 24(1): 13-9
7. Simion M; Trisi P; Piattelli A. A vertical ridge augmentation using a membrane technique associated with osseointegrated implants. *Int J Periodontics Restorative Dent* 1994; 14(6) : 496-511.
8. Nentwig GH. Technique of bone splitting for alveolar recession in anterior maxillary region. *Quintessence* 1986; 37:1825-34.
9. Scipioni A; Bruschi GB; Calesini G. The edentulous ridge expansion technique: a five-year study. *Int J Periodontics Restorative Dent* 1994; 14:451-9.
10. Crespi R; Bruschi GB; Gastaldi G; Cappare P; Gherlone EF. Immediate loaded implants in split-crest procedure. *Clin Implant Dent Relat Res* 2015; 17: 692-8.
11. Simion M; Baldoni M; Zaffe D. Jawbone enlargement using immediate implant placement associated with a split-crest technique and guided tissue regeneration. *Int J Periodontics Restorative Dent* 1992; 12: 462-73.
12. Codivilla A. On the means of lengthening, in the lower limbs, the muscles and tissues which are shortened through deformity. *J Bone Joint Surg Am* 1905;2(2):353-69.
13. Codivilla A. Sulla correzione delle deformità di frattura del femore. *Bull Sci Med (Bologna)* 1903; 3:246-9.
14. McCarthy JG. Distraction osteogenesis in maxillofacial surgery using internal devices: review of 5 cases. *Oral and Maxillofacial Surgery*; January 1996; Vol. 54; issue 1; Pag. 54.
15. Ilizarov GA. The tension-stress effect on the genesis and growth of tissues Part 1. The influence of stability of fixations and soft-tissue preservation. *Gen Orthop Relat Res* Jan 1989; (238) : 249-81.
16. Ilizarov GA. The tension-stress effect on the genesis and growth of tissues. Part 2. The influence of the rate and frequency of distraction. *Clin Orthop Relat Res* Feb 1989; (239) : 269-85.



- 1 The 'All-on-four' protocol in HIV-positive patients:  
A prospective, longitudinal 7 -year clinical study**  
P.Capparè, G.Tetà, G.E.Romanos, M.Nagni, G.Sannino, E.Gherlone  
Int J Oral Implantol 2019;12 (4): 501-510

---

- 2 Studio comparativo sulla precisione dell'interfaccia impianto-abutment tra  
abutment originali e compatibili connessi all'impianto originale**  
M.Gallullo, H.Panajoti, M.Nagni, A.Russo,G.Gastaldi  
Doctor OS Settembre 2019 XXX 07

---

- 3 The effect of immediate implant placement on alveolar ridge preservation  
compared to spontaneous healing after tooth extraction: Radiographic results of  
randomized controlled clinical trial**  
M.Clementini,A.Agostinelli,W.Castelluzzo,F.Cugnata,F.Vignoletti,M.de Sanctis  
Journal of Clinical Periodontology 2019

---

- 4 Immediate Loading Mandibular Rehabilitation with Reduced Number of  
Implants**  
A.Cardarelli, M.Grechi, P.Montemezzi, M.Piro, P.Capparè  
BAOJ Dentistry,Volume 5; Issue 1;050

---

- 5 Relationship Between Crestal Bone Levels and Crown-to-Implant Ratio of Ultra-  
Short Implants With a Microrough Surface: A Prospective Study With 48 Months  
of Follow-Up**  
L.Malchiodi,E.Giacomazzi,A.Cucchi,G.Ricciotti,R.Caricasulo,D.Bertossi,E.Gherlone  
Journal of Oral Implantology Vol.XLV/No.One/2019

---

- 6 Augmented reality for dental implantology: a pilot clinical report of two cases**  
G.Pellegrino, C.Mangano,R.Mangano,A.Ferri,V.Taraschi,C.Marchetti  
BMC Oral Health 2019

## ORIGINAL ARTICLE

Paolo Capparé, Giulia Teté, Georgios E. Romanos, Matteo Nagni, Gianpaolo Sannino, Enrico Felice Gherlone

## The 'All-on-four' protocol in HIV-positive patients: A prospective, longitudinal 7-year clinical study

### KEY WORDS

*dental implant, HIV-patients, immediate loading, oral rehabilitation, tilted implant*

### ABSTRACT

**Purpose:** This prospective study aims to evaluate the clinical outcomes of 'All-on-four' rehabilitations in controlled human immunodeficiency virus (HIV)-positive patients.

**Materials and methods:** Edentulous patients requiring an implant prosthetic restoration of one or both jaws were enrolled in the present study. Each patient received at least one fixed full-arch prosthesis. Four implants, immediately loaded, were placed in each jaw using the 'All-on-four' protocol. Marginal bone loss, implant and prosthetic failure, biological and mechanical complications, and serological levels (CD4 cell count, CD4/CD8 ratio, and HIV viral load) were recorded up to 7-year follow-up.

**Results:** A total of 116 implants were placed in 24 patients, and 29 rehabilitations based on the 'All-on-four' concept were achieved. Implant failures were registered in four patients (10 of 116 implants), and the implant survival rate was 91.37%. At the 7-year radiographic evaluation, peri-implant crestal bone loss averaged  $1.91 \pm 1.3$  mm for upright maxillary implants ( $n = 30$  implants) and  $1.79 \pm 1.28$  mm for tilted maxillary implants ( $n = 30$  implants). In the mandible, mean peri-implant crestal bone loss was  $1.54 \pm 1.27$  mm for upright implants ( $n = 28$ ) and  $1.5 \pm 1.3$  mm for tilted implants ( $n = 28$ ). No statistically significant correlation was found between serological parameters and marginal bone levels at 6 months, or through 7 years of annual follow-up ( $P > 0.05$ ). A statistically significant linear correlation ( $P < 0.001$ ) was found between early implant failure and HIV viral load. The CD4/CD8 ratio was significantly correlated with late implant failure ( $P = 0.009$ ).

**Conclusions:** Within the limitations of this prospective 7-year longitudinal study, HIV-positive patients with a stable immune system can be candidates for the 'All-on-four' treatment concept.

**Conflict of interest statement:** *The authors declare there are no conflicts of interest.*

### Introduction

Human immunodeficiency virus (HIV) causes progressive immune system failure, weakening the body's defence against pathogens<sup>1</sup>. HIV-positive patients become vulnerable to the development of opportunistic infections. HIV-associated oral

lesions, such as oral candidiasis, hairy leukoplakia, HIV-associated gingivitis and periodontitis, Kaposi sarcoma, non-Hodgkin lymphoma, xerostomia, and destructive carious disease<sup>1</sup>, can be very common. Atypical periodontal necrotic ulcerations and an increased incidence of herpetic infections have also been documented<sup>2</sup>.

## Capparé et al Clinical study on All-on-4 protocol in HIV-positive patients

With the advent of highly active antiretroviral therapy (HAART), HIV infection has become a chronic disease with a lower incidence of transition to acquired immunodeficiency syndrome (AIDS), and survival among HIV-positive patients has significantly increased. Because of this improvement in the systemic health of affected patients, new treatment options have become available, and implant-supported prosthetic rehabilitation has become a valid alternative to removable prosthesis in restoring dental aesthetics, function and quality of life in partially and fully edentulous patients. The use of titanium oral implants to support fixed restorations has greatly increased patient satisfaction and comfort, compared to mucosa-supported dentures<sup>3</sup>, allowing improvement of various aspects of patient experience, such as psychological acceptance, retention, stability, function, phonetics and food choices, as well as self-esteem.

A prospective single-centre trial<sup>4</sup> conducted at the Istituto di Ricovero e Cura a Carattere Scientifico (IRCCS) (Institute of Recovery and Cure with Scientific Characterization) at the San Raffaele Hospital, Milan, reported that implant prosthetic rehabilitation in HIV-positive patients with stable disease and good oral hygiene represented a suitable treatment option with results slightly worse than those observed in the healthy population. Indeed, the removal of teeth causes loss of alveolar height and width, often equal to 50% of the alveolar mass of the area<sup>5</sup>. To improve the quality of life and encourage social rehabilitation of affected patients<sup>6</sup>, the 'All-on-four' concept has been introduced; it comprises a predictable method to rehabilitate completely edentulous arches with an immediate prosthetic restoration, supported by four implants<sup>7</sup>. Maló et al<sup>8</sup> reported a cumulative implant survival rate of 95.4% after 7 years of follow-up, with excellent marginal bone level (MBL) outcomes and a low incidence of complications for this protocol.

When rehabilitating atrophic edentulous arches, tilting of implants can be used to obtain increased prosthetic support with a better anterior-posterior load distribution<sup>9</sup>, as well as implant stability, without the requirement for bone grafting in the maxilla or transposition of the mandibular nerve;

notably, these procedures can expose patients to increased risks of morbidity and complications<sup>8,10</sup>. The placement of four implants, with the anterior two placed axially and the posterior two angled distally, that are immediately loaded according to an 'All-on-four' protocol may be a safer, simpler and more predictable option than potentially hazardous extended surgical procedures, especially in immunocompromised patients. The aim of the present prospective 7-year longitudinal study was to evaluate the clinical outcomes of 'All-on-four' rehabilitations in controlled human immunodeficiency virus (HIV)-positive patients.

## Materials and methods

### Patient selection

This study was conducted in accordance with the tenets of the Declaration of Helsinki and followed the Strengthening the Reporting of Observational Studies in Epidemiology (STROBE) guidelines for cohort studies (<http://www.strobe-statement.org>). This single-centre clinical trial was performed at the San Luigi Centre for Infective Diseases, IRCCS San Raffaele Hospital, Milan, Italy. During the period from December 2010 to February 2012, HIV-positive patients undergoing appropriate HAART who had severely atrophic mandible or maxilla were consecutively enrolled. The main inclusion criteria were the need for complete rehabilitation of the edentulous arches and the presence of sufficient residual bone volume to receive four implants.

The eligibility criteria were as follows:

- age > 18 years
- total or partially edentulous in one or both arches
- adequate bone volume (divisions A, B or C based on the Misch classification of bone available<sup>11</sup>)
- appropriate bone density (class D1, D2 or D3 based on the Misch classification<sup>12</sup>).

Exclusion criteria were:

- severe immunodeficiency with a high recurrence of opportunistic infections



- uncontrolled diabetes
- severe malocclusion
- severe parafunction (bruxism)
- inadequate bone volume (division D based on the Misch classification<sup>11</sup>)
- inadequate bone density (class D4 based on the Misch classification<sup>12</sup>)
- disorders for which surgical procedures were contraindicated
- lack of collaboration
- lack of oral hygiene.

All diagnoses were made clinically and radiographically. A written informed consent for immediate implant loading was obtained from all patients prior to the beginning of the study and the local ethical committee approved the study; professional oral hygiene was provided before surgery. Conventional impressions were taken for study casts and provisional prostheses; to assess bone volume (according to Cawood and Howell classification<sup>13</sup>) and bone density in each patient, the diagnosis was conducted as first level with panoramic radiography and at second level with cone beam computed tomography (CBCT).

A few days before surgery, periodontal health check-ups were performed by a calibrated hygienist to evaluate the Bleeding Index (BI), Plaque Index (PI) and probing depths (PD) in the patients who had remaining dentition. This was the T0 stage for clinical periodontal parameters. Serological parameters (e.g. CD4 cell count, HIV viral load, CD4/CD8 ratio, and blood clotting function) were measured in each patient prior to surgery and each 6 months up to the 7-year follow-up.

### Surgical procedure

All surgeries were performed by a single experienced surgeon. On the day of surgery, implants were positioned after antibiotic prophylaxis with 2 g amoxicillin and clavulanic acid (Augmentin, GlaxoSmithKline, Brussels, Belgium), which was administered 1 hour prior to surgical incision. The implant surgery was performed under local anaesthesia (Optocain 20 mg/ml with adrenaline 1:80,000; Molteni Dental, Firenze, Italy).

In edentulous mandibles, a crestal incision with bilateral releasing incisions was made from the first molar region to the contralateral side. Sub-periosteal dissection was performed on the lingual and vestibular surfaces; a full-thickness buccal flap was raised, exposing the buccal bone wall and allowing detection of the mental foramina. In edentulous maxillae, a crestal incision was performed on the alveolar crest from the pterygomaxillary region to the contralateral side with bilateral releasing incisions; a mucoperiosteal buccal flap was elevated, exposing the vestibular bony wall. Before implant insertion, all compromised teeth with a poor prognosis were atraumatically extracted, and the sockets were carefully debrided and cleaned to minimise infection.

The two posterior implants (TTx, Winsix, Biosafin, Ancona, Italy) were placed bilaterally immediately anterior to the mental foramina in edentulous mandibles; following the anterior sinus wall in edentulous maxillae, the implants were distally tilted at approximately 25 to 30 degrees relative to the occlusal plane, emerging at the second premolar position to shorten the cantilever length and maintain a large inter-implant distance<sup>8</sup>. The two anterior implants always followed the jaw anatomy in direction.

Bone density was assessed by CBCT as previously described, during the early phase of drilling by the clinician's experience and sensation, and scored in accordance with the Lekholm and Zarb classification<sup>14</sup>. The diameter of the final drill was chosen based on bone quality to optimise implant stability. The insertion of the implants followed standard procedures (Winsix), although under-preparation was used in soft bone to achieve an insertion torque ranging between 30 and 40 Ncm before final seating of the implant, thereby obtaining high primary stability and immediate function. A manual wrench was also used when incomplete seating of the implant occurred. The implant neck was aimed to be positioned at bone level, and bicortical anchorage was established whenever possible<sup>8</sup>.

Surgical placement of the implants always aimed to achieve ideal prosthetically driven implant positioning; therefore, to allow optimal prosthetic screw access and placement of holes in an occlusal

**Capparé et al** Clinical study on All-on-4 protocol in HIV-positive patients

or lingual location, angulated abutments (Extreme Abutment, EA Winsix, Biosafin) for anterior implants were set at 17 degrees, and those for posterior implants were set at 30 degrees to compensate for the lack of parallelism between implants. Flap adaptation and suturing were performed with 4-0 non-resorbable suture (Vicryl; Ethicon, Johnson & Johnson, New Brunswick, NJ, USA).

After surgery, mouth rinsing with a chlorhexidine digluconate-containing solution (0.12% or 0.2%), twice per day for 10 days, was prescribed in addition to the recommended standard post-surgical medication: 1 g amoxicillin and clavulanic acid (Augmentin, GlaxoSmithKline) two times per day for 7 days after surgery, and non-steroidal anti-inflammatory drugs (ibuprofen 600 mg, Brufen, Abbott Laboratories, Chicago, IL, USA) as needed. All patients were instructed to avoid brushing and any trauma to the surgical site, and were recommended to follow a soft diet (avoiding bread and meat) for 2 months. One week after implant placement, sutures were removed.

**Prosthetic protocol**

After surgery, provisional complete-arch all-acrylic resin prostheses were delivered in all patients based on preliminary impressions. Pick-up impressions (Permadyne, Espe, Seefeld, Germany) of the implants were made at the end of the surgery (after suturing) to enable manufacture of a high-density baked all-acrylic prosthesis with titanium cylinders. No more than 3 hours after the surgery, a screw-retained, metal-reinforced, acrylic provisional prosthesis with 10 teeth was delivered: no cantilevers were used in the provisional prostheses<sup>8</sup>. The torque for tightening the prosthetic screws was 20 N. Screw access holes were covered with provisional resin (Fermit, Ivoclar Vivadent, Naturno, Bolzano, Italy). A metal-ceramic or resin implant-supported final prosthesis was delivered no sooner than 4 months after surgery. In the final prosthesis, the occlusion reproduced the natural dentition with distal cantilevers up to the first molar. The pontic areas had an ovate design and the prosthesis provided an intimate contact with the underlying soft tissues but with the cleaning

space necessary for the home oral hygiene. Articulating paper (Bausch, Nashua, NH, USA) was used to check the occlusion and adjust it, if necessary. Static occlusion consisted of central contacts established on all masticatory units. Dynamic occlusion included canine/premolar guidance, regardless of the opposite arch settings. The screw access holes were covered with acrylic resin (Fermit).

**Follow-up evaluation**

Follow-up visits that included clinical and radiological examination were performed at 3 and 6 months, then annually until the 7-year follow-up after implant placement. In accordance with the procedures of the Infectious Disease Unit, the serological parameters (CD4 cell count, CD4/CD8 ratio, and HIV RNA viral load) were assessed every 6 months, the day before the oral hygiene procedures. Every 6 months after implant placement, a dental hygienist performed oral hygiene procedures and recorded clinical parameters, including BI, PI, and PD around implants<sup>14</sup>. Appointments with the dental hygienist were also scheduled every 2 months during the follow-up. The maintenance protocol was conducted according to Jepsen et al<sup>15</sup>.

As reinforcement for the home oral hygiene, patients were instructed on the proper use of aids such as interproximal brush, mono tuft toothbrush, and super floss (Oral B, Procter & Gamble, Cincinnati, OH, USA). Moreover, patients occasionally failed to visit the hygienist, but were always recalled for another appointment.

**Outcome measures**

- Prosthesis failure: when a prosthesis had to be replaced due to implant failure.
- Implant failure: implant removal dictated by mobility, progressive marginal bone loss due to peri-implantitis, any mechanical complication rendering the implant not usable (e.g. implant fracture). The follow-up occurred 6 months after implant insertion and then each year, with the stability of each individual implant being assessed manually by tightening the abutment screws with the removed prostheses.



- Biological and prosthetic complications (number and type) were recorded as single episodes for each implant. Particular attention was used to assess peri-implantitis (defined as progressive bone loss with sign of infections around an osseointegrated implant), presence of pain, presence of pus, paraesthesia in the mandible and implant fracture.
- Peri-implant marginal bone level changes (MBLCs): radiographic assessments were made using periapical radiographs obtained immediately after surgery and at each follow-up visit. Bone level measurements were performed on the mesial and distal aspects of each implant using the implant-abutment junction as a reference point<sup>16</sup>; these were made perpendicular to the long axis of the implant with the long-cone parallel technique using an occlusal custom template to measure the MBL. A dedicated dental practitioner measured the changes in crestal bone height over time. The difference in bone level was measured radiographically through custom software (DIGORA 2.5, Soredex, Tuusula, Finland). The software was calibrated for each image using the known implant diameter at the most coronal portion of the neck of the implant. The linear distance between the most coronal point of bone-to-implant contact and the coronal margin of the implant collar was measured to the nearest 0.01 mm at both the mesial and distal sides, and then averaged. Marginal bone loss was calculated as the difference in peri-implant bone level between the first (immediately after fixture placement) and last (during the recall visits) radiographs, and the change in crestal bone height was measured over time. Bone level changes at single implants were averaged at the patient level.

#### Statistical analysis

Dedicated software (SPSS 11.5.0, IBM, Armonk, NY, USA) was used for all statistical analyses. Data were analysed at the patient level and are reported as mean  $\pm$  standard deviation (SD). The height, diameter and position of the inserted fixtures were recorded for all patients, and the frequencies of

the types of prosthetic rehabilitation (maxillary 'All-on-four' and mandibular 'All-on-four') were calculated for the whole sample. For the outcome measures, numbers of implant failures, prosthetic failures, peri-implantitis, episodes of pus, pain, paraesthesia and fracture of fixtures were reported as absolute values and/or percentages for all patients. To investigate the correlation between MBLs and serological levels of CD4 cell count, the CD4/CD8 ratio and HIV RNA at different time points (from 6 months after surgery and then annually until the 7-year follow-up), linear regression analysis was performed. Pearson's correlation coefficient was calculated, and significance was set at  $P < 0.05$ . To compare MBLs between axial and tilted implants in the maxilla and mandible at 6 months and annually until the 7-year follow-up, Student's *t* tests were applied at a significance level of  $P < 0.05$ .

#### Results

From December 2010 to February 2012, 150 HIV-positive patients (age > 18 years) were screened at the San Luigi Centre for Infectious Diseases, IRCCS San Raffaele Hospital, Milan, where HIV-infected patients are monitored and given medical assistance. Among them, 24 patients met the eligibility criteria and medical parameters for stable disease and were included in the study; they underwent treatment from December 2010 to February 2012. A total of 116 implants were placed in 24 patients (Table 1). Among them, 12 patients were smokers. Five patients received rehabilitation of both arches, 10 patients received maxillary rehabilitation, and nine received mandibular rehabilitation. A total of 29 'All-on-four' rehabilitations, each supported by four implants, were achieved.

#### Implant failure

Implant failure was registered in four patients (10 of 116 fixtures); all four were smokers. All implant failures were due to primary infection and unsuccessful osseointegration. They occurred before the 6-month follow-up in three patients, and at 6 months after immediate loading in one

## Capparé et al Clinical study on All-on-4 protocol in HIV-positive patients

Table 1 Implant dimensions and positions

Arch	Implant	Diameter (mm)	Number of implants placed		
			Length 13 mm	Length 15 mm	Length 11 mm
Maxilla (n = 60)	Upright (n = 30)	3.3	13	0	5
		3.8	8	0	4
	Tilted (n = 30)	3.3	3	13	2
		3.8	3	9	0
Mandible (n = 56)	Upright (n = 28)	3.3	12	0	3
		3.8	7	0	6
	Tilted (n = 28)	3.3	2	12	0
		3.8	4	10	0

Table 2 Details of implant failures

Patient no.	Failed implants (n)	Position	Time of failure (from implant placement)
1	4	All	2 months
2	1	Maxilla, right mesial	1 month
3	4	All	1 month
4	1	Maxilla, left distal	6 months

patient (Table 2). Implants of the same length and larger diameter were replaced by changing the implant seat when possible. The implant survival rate was 91.37%, and no implant fracture occurred.

#### Biological and prosthetic complications

Peri-implantitis was observed at the 7-year follow-up in 5 of 116 implants (4.3%) and two of 24 patients (8.7%). It did not occur in patients who lost implants. There were no instances of pus, pain or paraesthesia.

#### Prosthesis failure

Fracture of provisional prostheses occurred in two patients and in two of 29 rehabilitations (one maxillary and one mandibular) before the 6-month follow-up (representing a fracture rate of 6.9%, and a prosthetic survival rate of 93.1%). No prosthetic complications in the definitive prostheses were registered in any of the patients.

#### Peri-implant MBLCs

MBL outcomes are reported in Table 3. Both axial and tilted implants showed good maintenance of bone levels. At the 7-year radiographic evaluation, peri-implant crestal bone loss averaged  $1.91 \pm 1.3$  mm for upright maxillary implants (n = 30 implants) and  $1.79 \pm 1.28$  mm for tilted maxillary implants (n = 30 implants). In the mandible, the mean peri-implant crestal bone loss was  $1.54 \pm 1.27$  mm for upright implants (n = 28) and  $1.5 \pm 1.3$  mm for tilted implants (n = 28). No statistically significant differences in MBL between tilted and axially placed implants was observed in either arch at any of the follow-up evaluations ( $P > 0.05$ ).

#### Serological parameters

Serological parameters (CD4 cell count, CD4/CD8 ratio, and HIV RNA) were measured every 6 months to identify any variations in patients' immune statuses and to verify patient compliance and response to antiretroviral treatment (Table 4). No statistically significant linear correlation was reported at any of the follow-up evaluations. A

## Capparé et al Clinical study on All-on-4 protocol in HIV-positive patients

**Table 3** Marginal bone loss at different time points (mean  $\pm$  standard deviation, in mm)

Bone loss	Upright		Tilted	
	maxilla (n = 30)	mandible (n = 28)	maxilla (n = 30)	mandible (n = 28)
6 months	0.48 $\pm$ 0.24	0.53 $\pm$ 0.29	0.52 $\pm$ 0.30	0.49 $\pm$ 0.22
1 year	0.85 $\pm$ 0.28	0.90 $\pm$ 0.33	0.88 $\pm$ 0.23	0.91 $\pm$ 0.30
2 years	1.08 $\pm$ 0.45	1.04 $\pm$ 0.61	1.02 $\pm$ 0.67	1.09 $\pm$ 0.56
3 years	1.31 $\pm$ 0.68	1.18 $\pm$ 0.73	1.16 $\pm$ 0.88	1.24 $\pm$ 0.68
4 years	1.45 $\pm$ 0.83	1.33 $\pm$ 0.89	1.32 $\pm$ 1.00	1.30 $\pm$ 0.80
5 years	1.65 $\pm$ 1.04	1.61 $\pm$ 1.10	1.42 $\pm$ 1.15	1.42 $\pm$ 1.10
6 years	1.73 $\pm$ 0.87	1.69 $\pm$ 0.45	1.47 $\pm$ 1.02	1.46 $\pm$ 1.00
7 years	1.91 $\pm$ 1.30	1.79 $\pm$ 1.28	1.54 $\pm$ 1.27	1.50 $\pm$ 1.30

**Table 4** Serological levels at different time points (mean  $\pm$  standard deviation; CD4 = cell/ $\mu$ l; HIV RNA = copies/ml)

Serological levels	CD4 cell count	CD4/CD8 ratio	HIV RNA
6 months	798.79 $\pm$ 347.37	0.896 $\pm$ 0.384	10.65 $\pm$ 18.45
1 year	820.18 $\pm$ 372.18	0.892 $\pm$ 0.361	11.12 $\pm$ 24.20
2 years	798.32 $\pm$ 325.85	0.889 $\pm$ 0.278	9.64 $\pm$ 15.92
3 years	784.12 $\pm$ 355.85	0.893 $\pm$ 0.342	10.00 $\pm$ 18.92
4 years	796.22 $\pm$ 315.85	0.892 $\pm$ 0.310	9.70 $\pm$ 17.80
5 years	778.42 $\pm$ 310.85	0.886 $\pm$ 0.378	9.14 $\pm$ 17.92
6 years	810.22 $\pm$ 345.65	0.888 $\pm$ 0.270	10.24 $\pm$ 16.92
7 years	800.09 $\pm$ 312.21	0.800 $\pm$ 0.223	9.32 $\pm$ 19.09

statistically significant linear correlation ( $P < 0.001$ ) was found between HIV viral load and early implant failure due to primary infection and failed osseointegration. Patients who lost implants due to a primary infection had higher HIV RNA values than did patients who had not lost their implants. The CD4/CD8 ratio was significantly correlated with late implant failure ( $P = 0.009$ ); patients with lower CD4/CD8 ratios were more likely to develop late implant failure.

## Discussion

The purpose of this study was to evaluate the outcomes of immediately loaded implants using 'All-on-four' treatment in immunocompromised but immunologically stable patients with good oral hygiene. Since the introduction of HAART<sup>17</sup>, the availability of effective and well-tolerated antiretroviral treatments has led to a great increase in

patient survival, thereby modifying health care priorities. Indeed, as their general health condition and longevity have improved, HIV-infected patients have become candidates for dental implants. A single case report<sup>18</sup> reported the successful placement of one endosseous implant, placed immediately post-extraction, in an HIV-positive patient under strict medical control, with good aesthetic and functional results after an observation period of 18 months. Similarly, Strietzel et al<sup>19</sup> performed dental implant treatment in three HIV-positive patients with CD4 cell counts between 250 and 800/ml and viral load below the lower detectable limit ( $< 50$ /ml), providing predictable results and high patient satisfaction. In a prospective non-randomised clinical trial involving 20 HIV-positive and nine HIV-negative patients requiring implant-supported mandibular overdentures, Stevenson et al<sup>20</sup> reported a success rate of 100% for both test and control group, as well as osseointegration of all implants after 6 months of follow-up.



**Capparé et al** Clinical study on All-on-4 protocol in HIV-positive patients

More recently, a clinical trial by Gherlone et al<sup>4</sup> showed a cumulative implant survival rate of 92.11%, as well as a relatively high incidence of peri-implant infections in HIV-positive patients within the first 6 months after implant placement; this may be due to variations in individual susceptibility and immunological status. Therefore, a strict protocol of infection control is needed for treatment of HIV-positive patients, and close collaboration with the Infectious Disease Department is essential for successful treatment outcomes, as blood clotting parameters are critical in patient selection and should be checked periodically to evaluate patient immune status. The need for implementation of strict follow-up protocols to prevent the onset and progression of peri-implant diseases in HIV-positive patients was highlighted in a case series by Gay-Escoda et al<sup>21</sup>, who reported significantly better results for all peri-implant parameters in compliant patients who attended regular periodontal maintenance visits, compared with non-compliant patients.

Scientific evidence of increased risk during invasive dental treatment procedures and a predisposition to postoperative complications in HIV-positive patients is conflicting. In a case report, Baron et al<sup>22</sup> documented osseointegration in all implants placed in an HIV-positive patient; there were no signs of inflammation, and uneventful healing of both soft and hard tissue was observed, supporting the hypothesis that minor surgery does not represent an increased risk for controlled HIV-infected patients. Similar outcomes were reported by Achong et al<sup>23</sup>, who suggested that low CD4 cell counts at the time of implant insertion are not correlated with implant outcome. Other authors have investigated the role of CD4 cell count and its relationship with implant survival. In a pilot study of 25 HIV-positive and 15 HIV-negative volunteers, Oliviera et al<sup>24</sup> showed high success rates without clinical complications for all implants placed in the study participants, and no statistically significant relationships between bone resorption and CD4 cell count, viral load or type of antiretroviral therapy (ART). In a recent study, Gherlone et al<sup>25</sup> evaluated associations between implant survival and patient-related characteristics (e.g. smoking habits, oral hygiene, and CD4 cell count) in HIV-infected patients. No significant

associations were found, except in heavy smokers (> 10 cigarettes/day), who experienced more frequent implant failures, peri-implantitis, episodes of pus, and pain compared with non-smokers and light smokers ( $\leq$  10 cigarettes/day).

Long-term success rates for implant prosthetic rehabilitations in HIV-positive patients were reported in two studies<sup>21,26</sup>. Gay-Escoda and colleagues<sup>21</sup> reported implant survival and success rates of 98.3% and 68.4%, respectively, after 5 to 9 years of follow-up. Similarly, Ata-Ali et al<sup>27</sup> assessed the evidence for an increased risk of implant failure after up to 10 years and found no significant difference in success rates between HIV-positive and HIV-negative patients.

A recent systematic review<sup>28</sup> investigated the impact of HIV virus on dental implant osseointegration, as bone metabolic alterations are frequent in the context of HIV infection. The authors showed the prognosis for implant placement in HIV-positive patients to be similar in both the test and control groups, especially when HAART, controlled CD4 cell count, and administration of prophylactic antibiotic therapy were present. According to the prior literature and the results obtained in the present study, successful implant survival rates in HIV-infected patients seem to be more closely related to proper patient selection, appropriate surgical technique, meticulous follow-up, and strict antimicrobial protocols than to values of specific markers in HIV-positive individuals. However, the degree of immunosuppression, in terms of HIV viral load and the CD4/CD8 ratio, seems to be an important variable; further research is needed to clarify this issue.

The immune system in HIV-positive patients is not the same as in HIV-negative patients, but the present study shows that primary stability is not impacted and postoperative complications such as non-healing wounds or risk of infection occurred in low percentages, if there was an adequate level of CD4<sup>+</sup> and there was no neutropenia<sup>29</sup>.

In a meta-analysis review, it was found that before HAART therapy the complications but also the patient's tolerance to surgery were different; however, values of success and tolerance have been found to be similar to those of the rest of the population<sup>30</sup>.

Kolhatkar et al<sup>31</sup> documented the successful placement of immediate implants into fresh extraction sockets in two HIV-positive individuals. Immediate placement reduced total treatment time and allowed preservation of alveolar bone levels during failed healing events. There is very limited clinical evidence regarding immediate implant loading in HIV-infected patients. One case report with a long-term follow-up study<sup>21</sup> described a fixed implant-supported immediate-loading protocol in an edentulous asymptomatic HIV-positive patient, showing the validity of this type of oral rehabilitation in immunocompromised patients.

## Conclusion

Within the limitations of this prospective 7-year longitudinal study, HIV-positive patients with stable immune system can be candidates for the 'All-on-four' treatment concept.

## References

- Patton L, Glick M. Clinician's guide to treatment of HIV-infected patients. 3rd ed. Baltimore: American Academy of Oral Medicine, 2001.
- Melnick S, Engel D, Truelove E. Oral mucosal lesions: Association with the presence of antibodies to the human immunodeficiency virus. *Oral Surg Oral Med Oral Pathol* 1989;68:37–43.
- Lechner SK, Roessler D. Strategies for complete denture success: beyond technical excellence. *Compend Contin Educ Dent* 2001;22:553–559.
- Gherlone E, Capparé P, Tecco S, et al. Implant prosthetic rehabilitation in controlled HIV-positive patients: a prospective longitudinal study with 1-year follow-up. *Clin Implant Dent Relat Res* 2016;18:725–734.
- Bruschi GB, Crespi R, Capparé P, et al. Localized management of sinus floor technique for implant placement in fresh molar sockets. *Clin Implant Dent Relat Res* 2013;15: 243–250.
- Att W, Stappert C. Implant therapy to improve quality of life. *Quintessence Int* 2003;34:573–581.
- Maló P, Rangert B, Nobre M. "All-on-Four" immediate function concept with Brånemark system implants for completely edentulous mandibles: a retrospective clinical study. *Clin Implant Dent Res* 2003;5(Suppl 1): 2–9.
- Maló P, de Araújo Nobre M, Lopes A, Ferro A, Gravito I. All-on-4 treatment concept for the rehabilitation of the completely edentulous mandible: A 7-year clinical and 5-year radiographic retrospective case series with risk assessment for implant failure and marginal bone level. *Clin Implant Dent Relat Res* 2015;17(Suppl 2): e531–e541.
- Sannino G. All-on-4 concept: a three-dimensional finite element analysis. *J Oral Implantol* 2015;41:163–171.
- Patzelt S, Bahat O, Reynolds M, Strub J. The all-on-four treatment concept: a systematic review. *Clin Implant Dent Relat Res* 2014;16:836–855.
- Misch CE. Divisions of available bone in implant dentistry. *Int J Oral Implantol* 1990;7:9–17.
- Misch CE. Bone classification, training keys to implant success. *Dent Today* 1989;8:39–44.
- Cawood JL, Howell RA. A classification of the edentulous jaws. *Int J Oral Maxillofac Surg* 1988;17:232–236.
- Lekholm U, Zarb GA. Patient selection and preparation. In: Brånemark P-I, Zarb GA, Albrektsson T (eds). *Tissue-integrated prostheses: osseointegration in clinical dentistry*. Chicago: Quintessence, 1985:199–209.
- Jepsen S, Berglundh T, Genco R, et al. Primary prevention of peri-implantitis: managing peri-implant mucositis. *J Clin Periodontol* 2015;42(Suppl 16):152–157.
- Bruschi GB, Capparé P, Bravi F, et al. Radiographic evaluation of crestal bone level in split crest and immediate implant placement: minimum 5-year follow-up. *Int J Oral Maxillofac Implants* 2017;32:114–120.
- García de Olalla P, Knobel H, Carmona A, et al. Impact of adherence and highly active antiretroviral therapy on survival in HIV-infected patients. *J Acquir Immune Defic Syndr* 2002;30:105–110.
- Rajnav ZW, Hochstetter RL. Immediate placement of an endosseous root-form implant in an HIV-positive patient: Report of a case. *J Periodontol* 1998;69: 1167–1171.
- Strietzel FP, Rothe S, Reichart PA, Schmidt-Westhausen AM. Implant-prosthetic treatment in HIV-infected patients receiving highly active antiretroviral therapy: Report of cases. *Int J Oral Maxillofac Implants* 2006;21: 951–956.
- Stevenson GC, Riano PC, Moretti AJ, Nichols CM, Engelmeier RL, Flaitz CM. Short-term success of osseointegrated dental implants in HIV-positive individuals: a prospective study. *J Contemp Dent Pract* 2007;8:1–10.
- Gay-Escoda C, Pérez-Alvarez D, Camps-Font O, Figueredo R. Long-term outcomes of oral rehabilitation with dental implants in HIV-positive patients: a retrospective case series. *Med Oral Patol Oral Cir Bucal* 2016;21:e 385–e391.
- Baron M, Gritsch F, Hansy AM, Haas R. Implants in an HIV-positive patient: a case report. *Int J Oral Maxillofac Implants* 2004;19:425–430.
- Achong RM, Shetty K, Arribas A, Block MS. Implants in HIV-positive patients: 3 case reports. *J Oral Maxillofac Surg* 2006;64:1199–1203.
- Oliviera MA, Gallottini M, Pallos D, Maluf PS, Jablonka F, Ortega KL. The success of endosseous implants in human immunodeficiency virus-positive patients receiving antiretroviral therapy: a pilot study. *J Am Dent Assoc* 2011;142:1010–1016.
- Gherlone E, Capparé P, Tecco S, et al. A prospective longitudinal study on implant prosthetic rehabilitation in controlled HIV-positive patients with 1-year follow-up: the role of CD4+ level, smoking habits and oral hygiene. *Clin Implant Dent Relat Res* 2016;18: 955–964.
- Rania V, Pellegrino P, Donati G, Ghezzi M, Clementi E, Sparaco A. Long-term efficacy of dental implants in HIV-positive patients. *Clin Infect Dis* 2015;61:1208–1209.
- Ata-Ali J, Ata-Ali F, Di-Benedetto N, Bagán L, Bagan JV. Does HIV infection have an impact upon dental implant osseointegration? A systematic review. *Med Oral Patol Oral Cir Bucal* 2015;20:e347–e356.



## Capparé et al Clinical study on All-on-4 protocol in HIV-positive patients

28. Kolhatkar S, Khalid S, Rolecki A, Bholá M, Winkler JR. Immediate dental implant placement in HIV-positive patients receiving highly active antiretroviral therapy: a report of two cases and a review of the literature of implants placed in HIV-positive individuals. *J Periodontol* 2011;82:505–511.
29. Becker W, Goldstein M. Immediate implant placement: Treatment planning and surgical steps for successful outcome. *Periodontol* 2000 2008;47:79–89.
31. Romanos GE. *Advanced immediate loading*. Chicago: Quintessence Publishing, 2012.
32. Romanos GE, Goldin E, Marotta L, Froum S, Tarnow DP. Immediate loading with fixed implant-supported restorations in an edentulous patient with an HIV infection: a case report. *Implant Dent* 2014;23:8–12.



Paolo Capparé

**Paolo Capparé, MD, MFS**

Researcher, Dental School, Vita-Salute University and IRCCS San Raffaele Hospital, Milan, Italy

**Giulia Teté, DDS**

Specialization School in Oral Surgery, Vita-Salute San Raffaele University, Milan, Italy

**Georgios E. Romanos, DDS, PhD, Prof Dr med dent**

Professor of Periodontology, Stony Brook University, School of Dental Medicine, Stony Brook, NY, USA; and Johann Wolfgang Goethe University Frankfurt, Department of Oral Surgery and Implant Dentistry, Frankfurt, Germany

**Matteo Nagni, DDS**

Specialization School in Oral Surgery, Vita-Salute San Raffaele University, Milan, Italy

**Gianpaolo Sannino, DDS, PhD**

Consultant, Department of Dentistry, IRCCS San Raffaele Hospital, Milan, Italy

**Enrico Felice Gherlone, MD, DMD**

Full Professor and Chairman, Dental School, Vita-Salute University and IRCCS San Raffaele Hospital, Milan, Italy

**Correspondence to:**

Dr Giulia Teté, Dentistry Department, IRCCS San Raffaele Hospital, Via Olgettina n.48, 20132 Milan, Italy. Email: tetegiulia92@gmail.com

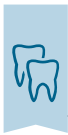**Literature abstract**

*Clin Oral Implants Res*, doi: 10.1111/clr.13547 [Epub ahead of print 12 Oct 2019]

**Guida L, Annunziata M, Esposito U, Sirignano M, Torrisi P, Cecchinato D. 6-mm-short and 11-mm-long implants compared in the full-arch rehabilitation of the edentulous mandible: A 3-year multicenter randomized controlled trial**

**Objective:** The aim of this multicenter parallel-group randomised controlled trial is to compare 6-mm-short with 11-mm-long implants in the rehabilitation of totally edentulous mandible in a completely comparable clinical situation, from anatomical, surgical, and prosthetic point of view. **Material and methods:** 30 patients were selected in three study centers to receive a fixed full-arch mandibular rehabilitation supported by five interforaminal implants. Patients were randomly allocated, at the time of surgery, half to the test group (6-mm-long implants) and half to the control group (11-mm-long implants). No bone augmentation procedure was performed. After 3 months, a screw-retained full-arch prosthesis with distal cantilevers was positioned (baseline). Peri-implant marginal bone level change (MBLc), implant and prosthesis survival rate and biological/technical complications were evaluated after 1 and 3 years. **Results:** 30 subjects (150 implants) were evaluated after 1 year and 28 (140 implants) after 3 years. No implant or prosthesis loss occurred. No significant inter-group difference for biological/technical complications was registered. No statistically significant ( $P > 0.025$ ) intra-group or inter-group difference in the mean MBLc values was registered. The mean MBLc were  $0.01 \pm 0.19$  mm and  $-0.04 \pm 0.21$  mm at 1 year, and  $-0.10 \pm 0.24$  mm and  $0.02 \pm 0.25$  mm at 3 years (test and control group, respectively). **Conclusions:** 6-mm-short implants may be a reliable option when used in the rehabilitation of total edentulous mandibles. These results need to be confirmed by longer follow-up data from well-designed randomized controlled clinical trials. **Correspondence to:** luigi.guida@unicampania.it

© 2019 John Wiley & Sons A/S. Published by John Wiley & Sons Ltd.



## STUDIO COMPARATIVO

## Studio comparativo sulla precisione dell'interfaccia impianto-abutment tra abutment originali e compatibili connessi all'impianto originale

*Comparison of the fit accuracy at the implant-abutment interface in original abutment and copy compatible abutment connected to original implant*



matteo.galullo@gmail.com

### SCOPO DEL LAVORO

Lo scopo dello studio è stato quello di confrontare la precisione a livello dell'interfaccia impianto-abutment tra abutment originali e compatibili connessi all'impianto originale.

### MATERIALI E METODI

Abbiamo preso in esame un abutment originale e uno compatibile, con connessione esagonale interna, i quali sono stati connessi all'impianto originale.

Il sistema, nel suo complesso, è stato sezionato a metà e analizzato al microscopio elettronico a scansione (SEM), al fine di misurare la precisione delle connessioni tra impianto e abutment. I valori dei microgap una volta misurati sono stati tabulati con Microsoft Excel 10 e sono state calcolate la media e la deviazione standard.

### RISULTATI

Dall'analisi dei dati raccolti è stato dimostrato come il gap tra impianto e abutment compatibile sia notevolmente maggiore rispetto a quello riscontrato tra impianto e abutment originale.

### CONCLUSIONI

Considerando i risultati preliminari ottenuti dallo studio

condotto, sembrerebbe quindi sconsigliabile l'uso di abutment compatibili per evitare eventuali complicanze di natura sia biologica che meccanica.

Tuttavia, è obbligatorio precisare che, date le limitazioni dello studio condotto, è necessario approfondire l'argomento trattato, eseguendo ulteriori ricerche che prendano in esame un campione più vasto.

**N**egli ultimi anni la ricerca in implantologia è stata indirizzata verso il miglioramento di due elementi: le superfici implantari e l'interfaccia impianto-abutment. Lo sviluppo di superfici implantari con migliori performance ha permesso di ottenere una più rapida ed efficace osteointegrazione. Il miglioramento sia strutturale che funzionale della connessione tra l'impianto e l'abutment ha invece permesso di raggiungere un'ottima stabilità nel tempo dei tessuti duri e molli perimplantari permettendo il successo a lungo termine delle riabilitazioni impianto-protesiche.

La connessione impianto-abutment è un punto di



Interfaccia impianto-abutment, microgap a livello dell'interfaccia abutment-impianto, connessione esagonale interna, abutment cloni

Implant-abutment interface, microgap at fixture-abutment interface level, internal hex connection, copy compatible abutment



**Matteo Galullo\***  
**Henri Panajoti\***  
**Matteo Nagni\***  
**Aldo Russo\*\***  
**Giorgio Gastaldi\*\*\***

Dental School Università Vita Salute San Raffaele, IRCCS Ospedale San Raffaele, Milano


\*  
Specializzando in Chirurgia Orale

\*\*  
Professore a.c. presso il Corso di Laurea Magistrale in Odontoiatria e Protesi Dentaria


\*\*\*  
Professore associato, titolare dell'insegnamento di Protesi nel Corso di Laurea Magistrale in Odontoiatria e Protesi Dentaria, Direttore della Scuola di Specializzazione in Ortognatodonzia



## STUDIO COMPARATIVO



**Fig. 1** Immagine al SEM con aree di riferimento contrassegnate nella sezione A (potere di ingrandimento 55x): impianto-abutment originale. I quadrati evidenziano le 4 aree prese in esame, che verranno indicate nel corso dello studio come area 1, 2, 3 e 4.



**Fig. 2** Immagine al SEM con aree di riferimento contrassegnate nella sezione B (potere di ingrandimento 57x): impianto-abutment compatibile. I quadrati evidenziano le 4 aree prese in esame, che verranno indicate nel corso dello studio come area 1, 2, 3 e 4.

notevole rilevanza per il successo negli anni di una riabilitazione implanto-protesica, difatti se è presente uno scarso adattamento tra i componenti implantari possono verificarsi complicanze di natura sia biologica che meccanica. Le complicanze biologiche sono rappresentate da un aumento dell'infiltrato infiammatorio (1, 2). Le complicanze di tipo meccanico invece sono rappresentate dall'aumento dell'incidenza di micromovimenti, progressivo allentamento della vite di connessione ed eventuale frattura della stessa (6).

La prima geometria implantare ad essere introdotta fu la connessione esagonale esterna che, secondo quanto riportato, può frequentemente presentare ampi micro-gap. In seguito è stata introdotta la connessione esagonale interna, attualmente tra quelle più in uso (5). L'interfaccia tra una connessione esagonale interna o esterna e l'abutment influisce notevolmente sulle tolleranze meccaniche del complesso impianto-abutment riguardanti l'adattamento, la fatica ciclica e il precarico.

Le percentuali di successo dei sistemi implantari sono rilevanti solo per gli impianti e i componenti valutati e testati in combinazione tra loro (4,6). Pertanto, l'efficacia e la predicibilità dei componenti del complesso impianto-abutment, come dimostra-

to da test di laboratorio e clinici, può non essere la stessa se non si adoperano le stesse componenti, oggetto dello studio, o nel caso in cui adoperiamo le stesse componenti, queste devono essere combinate con le medesime componenti secondarie utilizzate negli studi in questione (3-5). Pertanto la scelta della corretta componentistica per un sistema implantare è di fondamentale importanza per il successo a lungo termine di una riabilitazione implanto protesica.

I produttori di un sistema implantare determinano i requisiti di tolleranza meccanica dei loro impianti sulla base di test rigorosi, ideati specificatamente per conoscere le tolleranze meccaniche necessarie per il successo a lungo termine del sistema implantare. Quando un'azienda terza produce un abutment compatibile per un sistema implantare, tali componenti compatibili possono presentare notevoli differenze da quanto previsto dal produttore originale, che potrebbero condurre ad uno scostamento dai livelli di precisione presentati dalla componentistica originale (7). Infatti l'uso di abutment compatibili potrebbe portare nel lungo termine a complicanze, tra cui l'allentamento dell'abutment, l'allentamento della vite di connessione ed eventuale frattura della vite stessa (6-8).

### Scopo dello studio

Data l'importanza che la precisione dell'interfaccia impianto-abutment riveste nel successo a lungo termine di una riabilitazione implanto-protesica, lo scopo dello studio è stato quindi quello di confrontare la precisione a livello dell'interfaccia impianto-abutment tra abutment originali e compatibili connessi all'impianto originale.

### MATERIALI E METODI

#### Materiali

Abbiamo preso in esame un abutment originale e uno compatibile, con connessione esagonale interna, i quali sono stati connessi all'impianto originale.

La tipologia di impianto preso in esame è:

- Impianto a connessione esagonale interna 3.8 x 11 mm (Sistema implantare WINSIX della BioSAFin; torque type).


Le specifiche dell'abutment originale sono:

- Abutment in titanio, dritto 3.8mm di diametro (connessione esagonale interna).


Non ci è possibile fornire le specifiche dell'abutment compatibile, poiché l'azienda produttrice non ha concesso l'autorizzazione a dichiararle.

## STUDIO COMPARATIVO


**Fig. 3** Sezione A; area 1 (potere d'ingrandimento: 5000x): nella prima area da analizzare sono stati presi in esame due punti, di cui è stata anche calcolata la deviazione in gradi dalla retta a cui i punti appartengono, ovvero la chiusura marginale a livello dell'IAI. Dall'analisi di questa prima area presa in esame è stato evidenziato un gap di 2.286  $\mu\text{m}$  nel primo punto (Pa R1) e un gap di 2.637  $\mu\text{m}$  nel secondo punto (Pa R2).



**Fig. 4** Sezione A area 2 (potere d'ingrandimento 5000x) Dall'analisi della seconda area presa in esame è stato evidenziato un gap di 1.470  $\mu\text{m}$  nel primo punto (Pa R1) e un gap di 2.701  $\mu\text{m}$  nel secondo punto (Pa R2).



**Fig. 5** Sezione A area 3 (potere d'ingrandimento 5000 x) Dall'analisi della terza area presa in esame è stato evidenziato un gap di 1.502  $\mu\text{m}$  nel primo punto (Pa R1) e un gap di 996.1 nanometri (quindi meno di 1  $\mu\text{m}$ ) nel secondo punto (Pa R2).



## Metodo

La metodologia adottata nel presente studio è descritta nelle sezioni seguenti:

1. L'abutment clone e quello originale sono stati entrambi connessi ad un impianto originale con il torque indicato dall'azienda costruttrice.
2. È stata tracciata una linea per segnare il centro del complesso impianto-abutment. Il sezionamento è stato effettuato verticalmente lungo l'asse lungo del complesso impianto-abutment utilizzando la linea di riferimento contrassegnata.
3. L'interfaccia impianto-abutment di ogni campione di prova è stata analizzata al microscopio elettronico a scansione con un ingrandimento di 2000x per studiare l'abutment compatibile e di 5000x per studiare l'abutment originale.
4. Nel presente studio, il microgap a livello dell'interfaccia impianto-abutment di ciascun campione sezionato è stato misurato individualmente in 2 punti a 100  $\mu\text{m}$  di distanza uno dall'altro in ciascuna area di riferimento (nelle figure 1 e 2 sono indicate le aree prese in esame). Utilizzando un software di misurazione dei pixel fornito con il microscopio elettronico a scansione sono state ottenute le misurazioni dei microgap tra abutment e impianto. I microgap sono stati misurati con la scala di misura lineare del software. Per ogni campione, sono stati misurati i microgap in 8 punti diversi lungo la superficie dell'interfaccia impianto-abutment (2 punti per ogni area esaminata).
5. I valori dei microgap una volta misurati, sono stati tabulati con Microsoft Excel 10 e sono state calcolate la media e la deviazione standard. (fig. 1, 2)

## RISULTATI

- Sezione A - Complesso Impianto-Abutment Originale (fig. 3-6)
- Sezione B - Complesso Impianto-Abutment Compatibile (fig. 7-10)

Misurati i gap in 2 punti in ciascuna delle 4 aree prese in esame, è stata calcolata la media tra i 2 punti per ogni area così da

## STUDIO COMPARATIVO

Gap a livello dell'IAI	Area 1	Area 2	Area 3	Area 4	Media	Deviazione Standard
Sezione A	2.4615 $\mu\text{m}$	2.0855 $\mu\text{m}$	1.296 $\mu\text{m}$	1.4075 $\mu\text{m}$	1.81 $\mu\text{m}$	0.48
Sezione B	22.195 $\mu\text{m}$	22.78 $\mu\text{m}$	21.02 $\mu\text{m}$	22.41 $\mu\text{m}$	22.10 $\mu\text{m}$	0.65
Differenza tra i gap (il valore mostrato indica di quanto maggiore sia il gap nella sezione B)	19.7335 $\mu\text{m}$	20.6945 $\mu\text{m}$	19.724 $\mu\text{m}$	21.0025 $\mu\text{m}$	20.28 $\mu\text{m}$	

**Tab. 1** Differenze tra i gap della sezione A (impianto-abutment originale) e della sezione B (impianto-abutment compatibile).

ottenere un unico valore utile per lo studio comparativo.

Le differenze tra i gap della sezione A (impianto-abutment originale) e della sezione B (impianto-abutment compatibile) sono state illustrate nella tabella 1.

Come si può facilmente capire dai risultati mostrati nella tabella 1, il gap a livello dell'IAI (interfaccia impianto-abutment), prendendo in considerazione le stesse aree sia nella sezione A che nella sezione B, è considerevolmente maggiore nella sezione B (impianto-abutment compatibile).


Il valore di deviazione standard ottenuto nella sezione A è indice di un'ampia variabilità dei valori del microgap lungo la superficie dell'IAI e possiamo notare che ciò dipende da una più intima adesione tra le superfici impianto e abutment nell'area 3 e 4.

Invece nella sezione B il valore di deviazione standard ottenuto indica una bassa variabilità del gap lungo la superficie dell'IAI.


## DISCUSSIONE

Negli ultimi anni, le soluzioni implantari sono diventate sempre più importanti nel campo della riabilitazione orale di pazienti parzialmente o completamente edentuli e una terapia implantare di successo richiede un equilibrio tra fattori biologici e meccanici che influenzano l'efficacia degli impianti stessi (15, 16, 17, 18).

**Fig. 6** Sezione A area 4 (potere d'ingrandimento 5000x). Dall'analisi della quarta area è stato evidenziato un gap di 1.173  $\mu\text{m}$  nel primo punto (Pa R1) e un gap di 1.642  $\mu\text{m}$  nel secondo punto (Pa R2).



**Fig. 7** Sezione B; area 1 (potere di ingrandimento: 2000x). Dall'analisi di questa prima area presa in esame è stato evidenziato un gap di 22.12  $\mu\text{m}$  nel primo punto (Pa R1) e un gap di 22.27  $\mu\text{m}$  nel secondo punto (Pa R2).



## STUDIO COMPARATIVO

Il sistema implantare è costituito da due componenti, l'impianto che viene inserito durante la prima fase chirurgica, e l'abutment che viene successivamente avvitato sull'impianto per supportare i restauri protesici (9, 10, 26, 28). Le superfici di accoppiamento dell'impianto e del suo abutment costituiscono l'interfaccia impianto-abutment e sono considerate un aspetto cruciale nel design dell'impianto. La progettazione dell'interfaccia fixture-abutment può avere un impatto sulla quantità di perdite microbiche tra le due parti (1, 18, 19, 20). Diversi problemi sono stati segnalati da molti autori con abutment che presentavano un rilevante microgap, tra cui l'allentamento della vite (6, 19, 20, 23,

24), microinfiltrazioni (13, 18, 24), abrasione, usura dei componenti (23) e potenziale perdita di tessuto osseo (22, 23).

Sebbene molti studi abbiano dimostrato l'importanza dell'adattamento dell'impianto all'abutment, non è stato stabilito alcun metodo standardizzato per la misurazione del microgap (11, 12, 14).

Sono stati descritti vari metodi di misurazione del gap a livello dell'interfaccia impianto-abutment tra cui visualizzazione diretta o misurazione dell'interfaccia a margine, misurazione trasversale dopo il sezionamento, utilizzando la tecnica d'impronta, misurando il grado di libertà nella rotazione, oppure attraverso la misurazione digitale del microgap su immagini

acquisite tramite microscopio ottico ed elettronico a scansione (4, 6, 24, 25, 26). Molti autori hanno raccomandato di applicare le tecniche sopra descritte sui complessi impianto-abutment sezionati così da consentire un'osservazione più approfondita dell'adattamento lungo l'interfaccia impianto-abutment. Infatti la visuale in sezione trasversale permette una maggiore precisione nella riproducibilità dei punti di riferimento tra campioni rispetto alla visuale in sezione circonferenziale (19). Per il nostro studio abbiamo scelto di sezionare a metà il complesso impianto-abutment e di acquisire le immagini al SEM che presenta potere d'ingrandimento, risoluzione e profondità di campo maggiori rispetto al microscopio ottico.

Inoltre tutte le fasi discusse nella metodologia per la preparazione dei campioni di prova sono state eseguite da un unico operatore per evitare errori basati sull'operatore. Per la standardizzazione degli impianti sono stati utilizzati impianti in titanio delle stesse dimensioni con il disegno esagonale interno.


I produttori di impianti, progettano e producono impianti e componenti secondarie in modo tale che vi sia una adesa connessione tra i componenti all'interfaccia impianto-abutment. L'obiettivo è che il complesso impianto-abutment raggiunga una connessione fisicamente adesa.

La precisione di adattamento tra i componenti dell'impianto gioca un ruolo importante nella prognosi a lungo termine della riabilitazione impianto-protesica. Un adattamento imperfetto tra impianto e abutment porta a micro movimenti dei componenti dell'impianto durante la funzione masticatoria, causando la proliferazione dei batteri attraverso l'interfaccia impianto-abutment e il progressivo allentamento della vite di connessione.


Diversi studi dimostrano come discrepanze superiori a 10  $\mu\text{m}$  causano colonizzazione batterica e allentamento della vite di connessione, che può portare nel tempo a frattura della stessa (27).

Dato che le misurazioni per l'abutment compatibile sono risultate essere sempre al di sopra di 10  $\mu\text{m}$ , i dati ottenuti sembrerebbero sconsigliare l'uso di abutment

**Fig. 9** Sezione B; area 3 (potere di ingrandimento 2000x). Dall'analisi della terza area presa in esame è stato evidenziato un gap di 20.80  $\mu\text{m}$  nel primo punto (Pa R1) e un gap di 21.24  $\mu\text{m}$  nel secondo punto (Pa R2).



**Fig. 8** Sezione B; area 4 (potere di ingrandimento 2000x). Dall'analisi della quarta ed ultima area presa in esame è stato evidenziato un gap di 21.97  $\mu\text{m}$  nel primo punto (Pa R1) e un gap di 22.85  $\mu\text{m}$  nel secondo punto (Pa R2).



## STUDIO COMPARATIVO

compatibili per evitare complicanze biologiche e meccaniche.

Tuttavia lo studio condotto presenta alcune limitazioni:

- è stato preso in esame solo un campione di abutment compatibile e uno di abutment originale;
- lo studio è stato eseguito in vitro;
- non è stata eseguita una analisi al FEM per comprendere come tale differenza nel gap possa esprimersi a livello di resistenza dell'intero complesso impianto-abutment.

## CONCLUSIONI

In conclusione, i dati ricavati dallo studio dimostrano chiaramente che gli abutment compatibili presentano un gap considerevolmente maggiore a livello dell'interfaccia abutment-impianto.

Considerando i risultati preliminari ottenuti dallo studio condotto, sembrerebbe quindi sconsigliabile l'uso di abutment compatibili per evitare eventuali complicanze di natura sia biologica che meccanica.

Tuttavia, è obbligatorio precisare che, date le limitazioni dello studio condotto, è necessario approfondire l'argomento trattato, eseguendo ulteriori ricerche che prendano in esame un campione più vasto.

## AIM OF THE WORK

The aim of the present in-vitro study was to compare the accuracy at the implant-abutment interface between the original and compatible abutments connected to the original implant.

## MATERIALS AND METHODS

We examined one original and one compatible abutment, with an internal hex connection, which were connected to the original implant.

The system as a whole was cut in half and analyzed under a scanning electron microscope (SEM) to measure the accuracy of the connection between the implant and the abutment.

Once measured, the microgap values were tabulated with Microsoft Excel 10 and the mean and standard deviation were calculated.

## RESULTS

Analysis of the data collected showed that the gap

between the implant and the compatible abutment was significantly greater than that between the implant and the original abutment.

## CONCLUSIONS

Considering the preliminary results obtained from the study conducted, it would seem inadvisable to use compatible abutments to avoid any biological or mechanical complications.

However, it should be pointed out that, given the limitations of the study conducted, it is necessary to gather more evidence by carrying out further research that considers a larger sample

## BIBLIOGRAFIA

1. Al-Jadaa A, Attin T, Peltomäki T, Heumann C, Schmidlin PR. Impact of dynamic loading on the implant-abutment interface using a gas enhanced permeation test In Vitro. *Open Dent J*, 2015;9:112-119.
2. Alonso-Perez R, Bartolome JF, Ferreiroa A, Salido MP, Pradies G. Evaluation of the mechanical behavior an marginal accuracy of stock and laser-sintered implant abutments. *Int J Prosthodont* 2017;30:136-138.
3. Apicella D, Veltri M, Chieffi N, Polimeni A, Giovannetti A, Ferrari M. Implant adaptation of stock abutments versus CAD/CAM abutments: a radiographic and scanning electron microscopy study. *Annali di Stomatologia* 2010;1(3-4):9-13.
4. Baixe S, Fauxpoint G, Arntz Y, Etienne O. Microgap between zirconia abutments and titanium implants. *Int J Oral Maxillofac Implants* 2010;25:455-460.
5. Bajoghli F, Amjadi M, Akouchekian M, Narimani T. Bacterial leakage and microgap along implant-abutment connection in three different implant systems. *Int J of Adv Biotech and research* 2016;7:4
6. Baldassarri M, Hjerpe J, Romeo D. Marginal accuracy of three implant-ceramic abutment configurations. *Int J Oral Maxillofac Implants* 2012;27:537-543.
7. Barbosa SGA, Simamoto Junior PC, Fernandes Neto AJ, Mattos MGC, Neves FD. Prosthetic laboratory influence on the vertical misfit at the implant/ ucla abutment interface. *Braz Dent J* 2007;18(2):139-43.
8. Barbosa GAS, Bernardes SR, das Neves FD, Fernandes Neto AJ, de Mattos Mda G, Ribeiro RF. Relation between implant/abutment vertical misfit and torque loss of abutment screws. *Braz Dent J* 2008;14(4):358-63.
9. Berberi A, Tehini G, Rifai K, Eddine FBN, Badran B, Akl H. In vitro evaluation of leakage of implant-abutment connection of three implant systems having the same prosthetic interface using Rhoamine B. *International journal of dentistry* 11 may 2014
10. Berberi A, Tehini G, Rifai K, Eddine FBN, Badran B, Akl H. Leakage evaluation of original and compatible implant-abutment connections: In vitro study using Rhodamine B. *J Dent Biomechanics* 2014;5:01-07.
11. Binon PP. Implants and components: Entering the new millennium. *Int J Oral Maxillofac Implants* 2000;15(1):77-95.
12. Binon PP. Evaluation of machining accuracy and consistency of selected implants, standard abutments and laboratory analogs. *Int J Prosthodont* 1995;8(2):162-78.
13. Broggnini N, McManus LM, Hermann JS, Medina RU, Oates TW, Schenk RK, Buser D, Mellonig JT, Cochran DL. Persistent acute inflammation at the implant-abutment interface. *J Dent Res* 2003;82(3):232-37.
14. Byrne D, Houston F, Cleary R, Claffey N. The fit of cast and premachined implant abutments. *J Prosthet Dent* 1998;80:184-92.
15. Faria R, May LG, de Vasconcellos DK, Volpato CAM, Bottino MA. Evaluation of the bacterial leakage along the implant-abutment interface. *J Dent Implants* 2011;1(2):51-57.
16. Fernández M, Delgado L, Molmeneu M, Garcia D, Rodríguez D. Analysis of the misfit of dental implant-supported prosthesis made with three manufacturing processes. *J Prosthet Dent* 2014;111:116-23.
17. Gehrke SA, Shibli JA, Aramburu Junior JS, de Val JEMS, Calvo-Girardo JL, Dedavid BA. Effects of different torque levels on the implant-abutment interface in a conical connection. *Braz Oral Res* 2016;30(1):e-40.
18. Gherlone EF, Capparé P, Pasciuta R, Grusovin MG, Mancini N, Burioni R. Evaluation of resistance against bacterial microleakage of a new conical implant-abutment connection versus conventional connections: an in vitro study. *New Microbiologica* 2016;39:49-56.
19. Hamilton A, Judge RB, Palamara JE, Evans C. Evaluation of the fit of CAD/CAM abutments. *Int J Prosthodont*. 2013;26(4):370-380.
20. Shenava A. Failure mode of implant abutment connections an overview. *J Dent Med Sci*. 2013;11(3):32-35.
21. Goodacre Charles J, Kan JYK, Runcharassang K. Clinical complications with implants and implant prostheses. *J Prosthet Dent* 2003;90(2):121-32.
22. Guimaraes MP, Nishioka RS, Bottino MA. Analysis of implant/abutment marginal fitting. *PGR - Pois - Grad Fac Pdntol Sao Jose dos Campos*. 2001;4(2):12-19.
23. Gigandet M, Bigolin G, Faoro F, Bürgin W, Bragger U. Implants with original and non-original abutment connections. *Clin Implant Dent Rel Res* 2012;01-10.
24. Kano SC, Binon PP, Curtis DA. A classification system to measure the implant-abutment microgap. *Int J Oral Maxillofac Implants*. 2007;22:879-885.
25. Kikuchi K, Akiba N, Sadr A, Sumi Y, Tagami J, Minakuchi S. Evaluation of the marginal fit at implant-abutment interface by optical coherence tomography. *J Biomedical Optics*. 2014;19(5):001-007.
26. Lorenzoni FC, Coelho PG, Bonfante G, Carvalho RM, Silva NRFA, Suzuki M, Silva TL, Bonfante EA. Sealing Capability and SEM observation of the implant-abutment interface. *Int J Dent*. 2011; 01-06
27. Sola-Ruiz MF, Otaolaurruchi ES, Vicente GS, Cossio IG, Borras VA. Accuracy combining different brands of implants and abutments. *Med Oral Patol Oral Cir Bucal*. 2013;18(2):332-


Received: 15 January 2019 | Revised: 8 April 2019 | Accepted: 29 April 2019

DOI: 10.1111/jcpe.13125

IMPLANT DENTISTRY

WILEY **Journal of Clinical  
Periodontology**

## The effect of immediate implant placement on alveolar ridge preservation compared to spontaneous healing after tooth extraction: Radiographic results of a randomized controlled clinical trial

Marco Clementini<sup>1</sup>  | Agnese Agostinelli<sup>1</sup> | Walter Castelluzzo<sup>1</sup> | Federica Cugnata<sup>2</sup> | Fabio Vignoletti<sup>1</sup> | Massimo De Sanctis<sup>1</sup>

<sup>1</sup>Department of Periodontology, Università Vita-Salute San Raffaele, Milan, Italy

<sup>2</sup>University Centre of Statistics for Biomedical Sciences (CUSBS), Università Vita-Salute San Raffaele, Milan, Italy

### Correspondence

Marco Clementini, Department of Periodontology, Università Vita-Salute San Raffaele, Via Olgettina 48, Milano, Italy. Email: mclementini@me.com

### Funding information

The project (14-034) was supported by a grant from the Osteology Foundation, Switzerland.

### Abstract

**Aim:** To radiographically evaluate the effect of immediate implant placement plus alveolar ridge preservation (ARP) with a deproteinized bovine bone mineral and a collagen matrix (IMPL/DBBM/CM) as compared to ARP (DBBM/CM) or spontaneous healing (SH) on vertical and horizontal bone dimensional changes after 4 months of healing.

**Materials and methods:** Thirty patients requiring extraction of one single-rooted tooth or premolar were randomly assigned to IMPL/DBBM/CM, ARP DBBM/CM or SH. Cone-beam computed tomography (CBCT) scans, performed before tooth extraction and after 4 months, were superimposed in order to assess changes in ridge height at the buccal and lingual aspect and in ridge width at 1 mm, 3 mm and 5 mm apical to the bone crest. Kruskal–Wallis test was applied for comparison of differences between groups.

**Results:** No statistically significant differences between the groups were observed for the vertical bone resorption of the buccal and the lingual side, while significant differences were found between SH group ( $-3.37 \pm 1.55$  mm;  $-43.2 \pm 25.1\%$ ) and both DBBM/CM ( $-1.56 \pm 0.76$  mm;  $-19.2 \pm 9.1\%$ ) and IMPL/DBBM/CM ( $-1.29 \pm 0.38$  mm;  $-14.9 \pm 4.9\%$ ) groups in the horizontal dimension at the most coronal aspect.

**Conclusion:** Ridge preservation techniques using DBBM and CM reduce the horizontal bone morphological changes that occur, mostly in the coronal portion of the buccal bone plate following tooth extraction, when compared to spontaneous healing. This is true regardless of whether immediate implant placement is performed or not.

### KEYWORDS

alveolar ridge preservation, CBCT, immediate implant placement, radiographic changes, tooth extraction

ClinicalTrials.gov ID: NCT03422458

776 | © 2019 John Wiley & Sons A/S.  
Published by John Wiley & Sons Ltd

wileyonlinelibrary.com/journal/jcpe

J Clin Periodontol. 2019;46:776–786.



## 1 | INTRODUCTION

It is well known that following the extraction of a tooth, severe hard and soft tissue alterations may take place at the socket site (Pietrokovski & Massler, 1967; Schropp, Wenzel, Kostopoulos, & Karring, 2003), resulting in a subsequent reduction of both vertical and horizontal ridge dimensions (Araujo & Lindhe, 2005; Discepoli et al., 2013; Tan, Wong, Wong, & Lang, 2012; Van der Weijden, Dell'Acqua, & Slot, 2009). In many occasions, these bone dimensional changes do not allow either appropriate pontic fabrication or correct placement of endosseous implants.

Over the past 20 years, several surgical procedures, grouped under the term of "alveolar ridge preservation" (ARP), have been introduced, aiming to maintain the existing soft and hard tissues as well as a stable ridge volume, to simplify subsequent treatment procedures and optimize functional and aesthetic outcomes (Hämmerle, Araújo, & Simion, 2012). A recent controlled clinical study (Jung et al., 2013) with a 6-month follow-up evaluated different techniques for ARP. The authors concluded that the application of a deproteinized bovine bone mineral (DBBM) with 10% collagen into an extraction socket, covered either with a collagen matrix (CM) or an autogenous soft tissue graft, resulted in less vertical and horizontal changes compared with spontaneous healing or the use of b-tricalcium phosphate particles alone without primary closure. Moreover, a conspicuous number of systematic reviews on this topic have confirmed the efficacy of ARP in preventing postextraction dimensional changes of the alveolar ridge (Avila-Ortiz, Chambrone, & Vignoletti, 2019; Ten Heggler, Slot, & Weijden, 2011; Horvath, Mardas, Mezzomo, Needleman, & Donos, 2013; MacBeth, Trullenque-Eriksson, Donos, & Mardas, 2017; Mardas, Chadha, & Donos, 2010; Vignoletti, Discepoli, et al., 2012; Vignoletti, Matesanz, et al., 2012; Vittorini Orgeas, Clementini, Risi, & Sanctis, 2013). However, when ARP techniques are performed before implant placement, this treatment modality requires a minimum of 3–6 months before implant insertion (Avila-Ortiz et al., 2019; De Risi, Clementini, Vittorini, Mannocci, & Sanctis, 2015), prolonging treatment time and needing a second surgical procedure for implant insertion.

Immediate implant placement (IIP) in fresh extraction sockets was introduced, in order to reduce the number of surgical procedures and potentially limit physiological bone resorption (Lazzara, 1989; Schulte & Heimke, 1976). However, IIP may not always provide successful clinical outcomes (Lang, Pun, Lau, Li, & Wong, 2012; Tonetti et al., 2017) and has been documented that this surgical protocol fails to prevent the horizontal and vertical ridge alterations (Araujo, Sukekava, Wennstrom, & Lindhe, 2005; Discepoli et al., 2015; Vignoletti, Discepoli, et al., 2012; Vignoletti, Matesanz, et al., 2012; Vignoletti & Sanz, 2014). This may result in impaired aesthetics (Evans & Chen, 2008; Tonetti et al., 2017) such as marginal soft tissues recessions, especially if treating the buccal side of maxillary sites in patients with a high smile line (Cosyn, Hooghe, & Bruyn, 2012).

In order to improve the aesthetic outcomes and reduce the bone dimensional changes, several techniques have been proposed, such as flapless protocols, immediate provisionalization, connective

### Clinical Relevance

*Scientific rationale for the study:* No human study has ever compared simultaneous implant placement + ARP to ARP alone and to spontaneous healing. Hence, the question that remains unanswered is whether simultaneous implant placement + ARP may influence bone modelling and remodelling as compared to ARP or to spontaneous healing.

*Principal findings:* In the horizontal dimension at the most coronal aspect, minor dimensional changes were observed in DBBM/CM and IMPL/DBBM/CM groups, whereas a pronounced (40%) resorption was observed in the SH group.

*Practical implications:* Immediate implant placement in postextraction sites plus an ARP technique may be a viable option, to reduce hard tissue morphological changes and treatment time.

tissue grafting, GBR techniques or filling of the gap with a bone replacement graft (Chen & Buser, 2014). Although no consensus exists on the efficacy of regenerative techniques at the time of immediate implant placement (Clementini et al., 2015), results from a very recent clinical trial demonstrated that placing a bone replacement graft in the marginal gap between the implant and the buccal bone plate significantly reduced (approximately 0.5 mm) the horizontal dimensional changes of the buccal bone after IIP in fresh extraction sockets (Sanz, Lindhe, Alcaraz, Sanz-Sanchez, & Cecchinato, 2017). Whether this reduction is similar to the one provided by ARP is still unknown, since up-to-date no human study has ever compared immediate implant placement + ARP to ARP alone and to spontaneous healing. Hence, the question that remains is whether IIP + ARP renders different results in terms of radiographic bone changes as compared to ARP and spontaneous healing.

Thus, the aim of this randomized controlled clinical trial was to evaluate the effect of immediate implant placement + ARP (test treatment) as compared to ARP (control treatment) or spontaneous healing (negative control) on bone dimensional changes after 4 months of healing postextraction. The primary objective was to radiographically evaluate the horizontal dimensional changes in millimetre, whereas the secondary objective was to evaluate the horizontal dimensional changes in percentage and the vertical dimensional changes in millimetre and percentage.

## 2 | MATERIALS AND METHODS

### 2.1 | Study design

This study was a prospective controlled, randomized, clinical investigation according to the CONSORT statement (<http://www.consort-statement.org/>). All procedures and materials were approved by the local ethical committee (REF: 14-034, 24/07/2015) and monitored



following the Good Clinical Practice. The trial was registered at <http://www.clinicaltrials.gov/> (REF: NCT03422458).

## 2.2 | Sample size

To calculate the number of patients to be treated, summary statistics (mean and standard deviation) reported by Jung et al. (2013) were used for the variable HW-1C, respectively, for the spontaneous healing group ( $-3.3 \pm 2$ ) and DBBM-C/CM group ( $-1.2 \pm 0.8$ ). The effect size was equal to 1.4, and this value was used to determine the sample size based on a two-independent sample Mann-Whitney test (two-tailed) with a significance level alpha set equal to 5% and power equal to 80%. GPower software, v. 3.1, was used. This resulted in 10 subjects for each group.

## 2.3 | Population

Participants were selected on a consecutive basis among patients of the Dental Clinic at University Vita Salute San Raffaele, Milan, Italy, between January 2016 and January 2018. Patients agreed to participate in the study by signing a written informed consent, in full accordance with the ethical principal of Declaration of Helsinki on experimentation involving human subjects, as revised in 2008.

## 2.4 | Inclusion criteria

- Adult patients (>18 years old) requiring extraction (for caries, fracture, prosthetic reasons) of one upper or lower single rooted tooth (incisor, canine) or premolar.
- Presence of adjacent (mesial and/or distal) natural teeth.
- The presence of an intact extraction socket (evaluated after a flapped tooth extraction), with a coronal margin of the buccal bone crest that deviated  $\leq 1$  mm from the coronal margin of the lingual bone crest and  $\leq 3$  mm from the mesial and/or distal interproximal bone crest (evaluated on the preoperative CBCT).
- Systemically healthy patients not smoking more than 10 cigarettes/day.
- Patients with adequate oral hygiene (FMPS < 25%) and periodontal health (FMBS < 10% and absence of PPD > 4 mm with BoP) (Lang & Bartold, 2018).

## 2.5 | Exclusion criteria

- Uncontrolled diabetes (HbA1c > 7), osteoporosis or any other systemic or local disease or condition that would compromise post-operative healing.
- Patients with a history of malignancy, radiotherapy or chemotherapy for treatment of malignancy.
- Pregnant patient or intending to become pregnant or nursing at the time of study inclusion.
- Patients taking medications or having treatments with an effect on healing in general (e.g., steroids, large doses of anti-inflammatory drugs, bisphosphonates).

## 2.6 | Randomization process and allocation concealment

Randomization was performed using a computer-generated list by someone not involved in other aspects of the study. Allocation concealment was performed by opaque continuously numbered sealed envelopes that were opened after tooth extraction and assessment of the integrity of the bone plates.

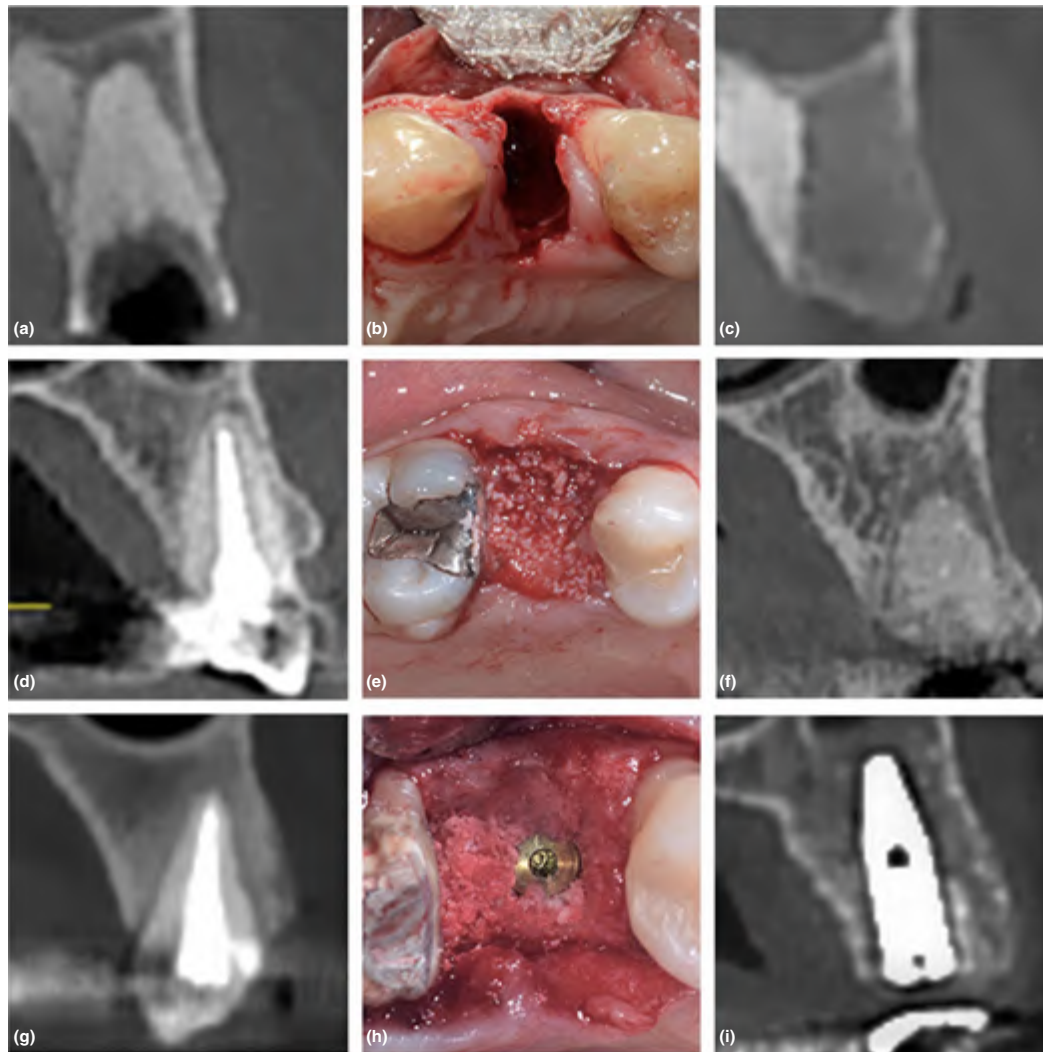
## 2.7 | Treatment procedures

A full-thickness envelope flap including the mesial and distal tooth was performed, and the tooth was extracted with great care to preserve the buccal bone plate and the surrounding hard tissue. Granulation tissue was carefully removed with hand instruments, and sterile saline rinses were performed. After assessment of the integrity of the bone plates, patients were randomly assigned to (Figure 1):

- Test group (IMPL/DBBM/CM): immediate implant placement, plus a collagenated bovine bone mineral grafted into the gap up to the buccal bone crest, sealed with a collagen porcine matrix.
- Control group (DBBM/CM): collagenated bovine bone mineral grafted into the socket up to the buccal bone crest, sealed with a collagen porcine matrix.
- Negative control group (SH): spontaneous healing.

In detail, in the test group, an immediate implant (TTi WINSIX®, Biosafin, Ancona, Italy) was placed in the correct prosthetically driven position, positioning the interface between the rough and smooth surface of the implant 1 mm apical respect to the buccal bone crest. The drilling of the osteotomies was performed following the standard surgical procedure as suggested by the implant manufacturer. After securing the closure cap, a bone substitute material (Geistlich Bio-Oss Collagen; Geistlich Pharma AG, 6110 Wolhusen, Switzerland) was placed in the gap that was formed between the implant surface and the hard tissue walls of the extraction socket. The graft was applied to fill the defect until the level of a line connecting the buccal and palatal/lingual bone crest. Subsequently, after flap replacement, the soft tissue borders were de-epithelialized and a collagen porcine matrix (Geistlich Mucograft Seal; Geistlich Pharma AG) was adapted to seal the graft and the implant using single interrupted resorbable sutures (Polysorb; Covidien, Segrate, Italy).

In the control group, a bone substitute material (Geistlich Bio-Oss Collagen; Geistlich Pharma AG) was placed in the extraction socket to the level of a line connecting the buccal and palatal/lingual bone crest. Subsequently, after flap replacement, the soft tissue borders were de-epithelialized and a collagen matrix (Geistlich Mucograft Seal; Geistlich Pharma AG) was adapted to seal the graft using single interrupted resorbable sutures (Polysorb; Covidien).



**FIGURE 1** Baseline cone-beam computed tomography (CBCT), intra-operative view and 4 months postsurgery CBCT representative of the three treatment modalities. (1) spontaneous healing: (a) baseline, (b) intra-operative, (c) 4 months. (2) DBBM-CM site: (d) baseline, (e) intra-operative, (f) 4 months. (3) IMPL/DBBM-CM site: (g) baseline, (h) intra-operative, (i) 4 months

In SH group, flap was repositioned with interrupted resorbable sutures (Polysorb; Covidien) and the coagulum within the socket was left for spontaneous healing.

Patients were instructed to rinse twice a day (starting the day after surgery) with 0.2% chlorhexidine and received antibiotics (Augmentin 1g) twice a day for 6 days and analgesic medication (Ibuprofen 600 mg) if needed. All patients were recalled at 7 days for suture removal. Patients then followed their individual maintenance programme according to the individual periodontal and caries risk assessment. Four months postextraction, all patients were recalled for a follow-up.

## 2.8 | Clinical measurements

Full-mouth plaque score (FMPS) (O'Leary, Drake, & Naylor, 1972), full-mouth bleeding score (FMBS) (Muhlemann & Son, 1971) and keratinized tissue height (KTH), measured from the most coronal extension of gingival margin to the mucogingival line, were recorded with a periodontal probe (PCP UNC 15, Hu-Friedy) at baseline and 4 months. Moreover, gingival thickness (GT) was assessed at baseline and 4 months, as described in Clementini, Discepoli, Danesi, & Sanctis, 2018. All clinical measurements were made by a single blinded calibrated examiner (A.A.).

## 2.9 | Radiographic measurements

Before treatment procedures, a cone-beam computed tomography (CBCT) scan was performed using a 3D examination (NewTom VGi evo, QR S.r.l., Verona), following the producer's prescriptions: resolution of 0.2 mm, scan time: 15 s and exposure time: 1.8 s. After four months postextraction, all selected patients underwent to a second CBCT scan with the same settings as described above.

To calculate CBCT measurements, a method similar to the one proposed by Jung et al. (2013) was adopted. Firstly, in the baseline data set, the distance from the mesial and/or distal bone crest was calculated in the axial section, and subsequently, the cross section was selected passing through the pulp canal of the involved tooth. The CBCT performed after 4 months was analysed using the same procedure, considering the distance from the mesial and/or distal bone crest previously calculated. Then, a computer-assisted (GeoGebra GmbH, Wolfauer Str 90, 4040 Linz, Austria) superimposition of the original Digital Imaging and Communications in Medicine (DICOM) data of the two CBCT scans was done in areas where no changes had taken place during the 4 months (e.g., the cranial base in the maxilla or the lower border and angle in the mandible, respectively). Varying the degree of transparency of the sections, DICOM data of the two CBCT scans were manually checked in order to assure a perfect match. Finally, the measurements were computed on the selected scans at baseline and at 4 months, by means of the following reference points and lines defined and drawn in the baseline image (Figure 2):

- Four reference points: the point representing the radiographic apex of the tooth (apical central point, ACP) and the point representing the cusp of the tooth (coronal central point, CCP). In cases where the crown of the tooth was missing or in cases of bicuspid, a segment was traced using 2 points (the most coronal and buccal point and the most coronal and lingual point of the tooth) and the

centre of this segment was taken as the coronal reference point; two points representing respectively the most coronal buccal (coronal buccal point, CBP) and the most coronal lingual (coronal lingual point, CLP) portion of the buccal and lingual bone plates.

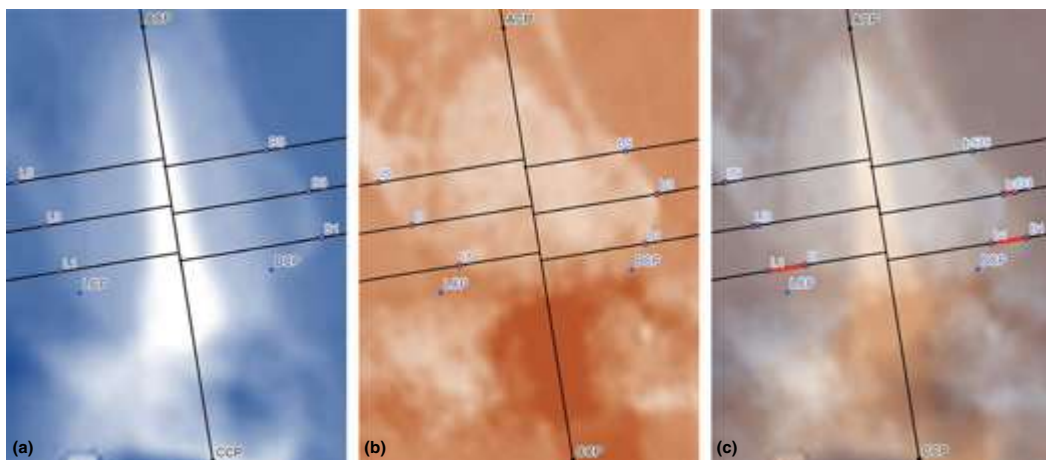
- Eleven reference lines, subsequently drawn, as follows: a vertical central line (VCL), in the centre of the socket, which crosses the apical (ACP) and coronal (CCP) central reference points; a vertical buccal line (VBL) and a vertical lingual line (VLL), parallel to the VCL and crossing respectively the most coronal point of the buccal (CBP) and lingual (CLP) bone crest; the buccal bone crest line (BCL\_B) and the lingual bone crest line (BCL\_L) connecting respectively the most coronal point of the buccal (CBP) and lingual (CLP) bone crest and perpendicular to VCL; the horizontal lines, perpendicular to the VCL drawn in precedence at 1, 3 and 5 mm and parallel to the straight lines passing through CBP (BCL\_B) and CLP (BCL\_L).

Hence, the following measurements were performed in millimetre:

- Thickness of the buccal and lingual bone plate at three levels (1, 3 and 5 mm), only at baseline.
- Vertical ridge height, measured at the buccal and lingual site, at baseline and 4 months.
- Mid-buccal and mid-lingual horizontal ridge width, measured at 1, 3 and 5 mm below respectively the CBP and CLP, at baseline and 4 months.

In addition, the following dimensional changes over time, based on the measurements performed at baseline and at 4 months, were assessed and expressed both in percentages and in millimetre:

- changes in ridge height at the buccal and lingual aspect;
- changes in ridge width at three levels (1, 3, 5 mm) respectively of



**FIGURE 2** Bone changes measurements. ACP: apical central point. CCP: coronal central point. BCP: buccal coronal point. LCP: lingual central point

the whole ridge, from the middle of the ridge to the buccal bone crest and from the middle of the ridge to the lingual bone crest.

All superimpositions of CBCT images and measurements of morphological changes were made by a single calibrated examiner (W.C.), who superimposed and measured, 24 hr apart, baseline and 4 months CBCT images of three different cases not included in the study. Intra-class coefficient correlation (Bliese, 2000) was 0.9891839.

### 2.10 | Data analysis

Descriptive statistics were provided for all the measures collected in the study. To test whether treatment groups were different, Kruskal-Wallis test, that is, the nonparametric counterpart to standard ANOVA, followed by post hoc analysis (Dunn's pairwise test and Bonferroni's adjustment of p-values), has been applied for comparison of differences between groups.

All the analyses were performed using R statistical software (R Development Core Team, 2016). In all the analyses, the significance threshold was set at 0.05.

## 3 | RESULTS

The study population consisted of 32 subjects that were screened for participating in this clinical trial from 2015 to 2018. Of these patients, two were excluded due to a loss of buccal bone plate after tooth extraction. A total of 30 subjects were finally recruited, randomized and included in the clinical trial: 10 allocated to the SH

group (negative control), 10 allocated to DBBM-CM group (control), and 10 allocated to IMPL/DBBM-CM group (test), respectively. Hence, a total of 30 subjects were included in the analysis (Figure 3).

No significant differences between treatment groups were found at the baseline (Table 1) regarding age, gender, smoking status, tooth position, presence of both mesial and distal tooth, reason for extraction, FMPS, FMBS, KTH, GT and thickness of the crest.

### 3.1 | Clinical outcomes

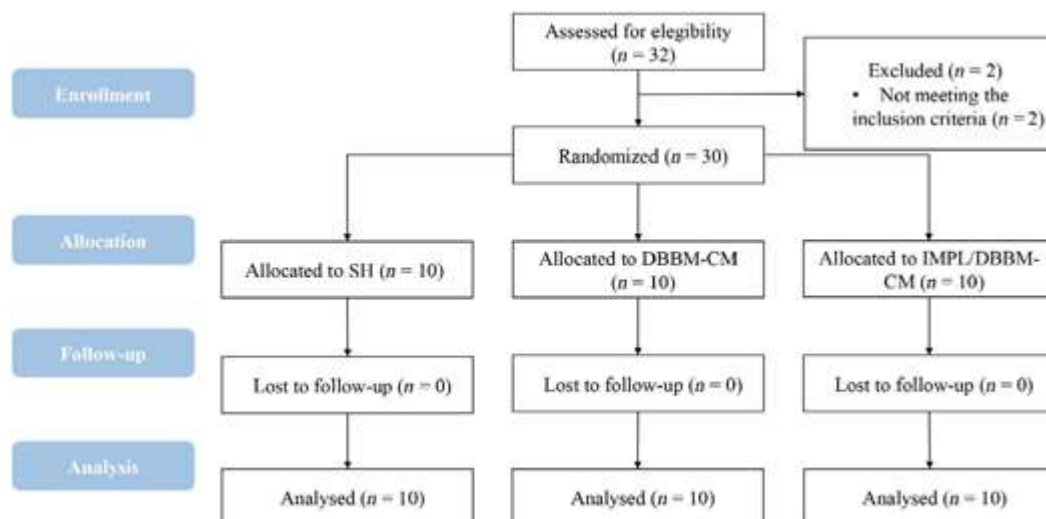
All treated sites healed uneventfully, and no postoperative complications were recorded. No significant differences were assessed from baseline to 4-month follow up for FMPS, FMBS, KTH and GT in the three study groups. Slight but not significant differences were observed for KTH (-0.4 mm) and GT (+0.35 mm) for SH group, while no differences were observed for DBBM/CM group and IMPL/DBBM/CM group.

### 3.2 | Radiographic outcomes

Dimensional alterations in millimetre and percentage that occurred during healing for all sites are reported in Table 2.

#### 3.2.1 | Horizontal dimensional changes

One millimetre apical to the most coronal bone crest, the ridge width decreased  $3.37 \pm 1.55$  mm (43.2  $\pm$  25.1%),  $1.56 \pm 0.76$  mm (19.2  $\pm$  9.1%) and  $1.29 \pm 0.38$  mm (14.9  $\pm$  4.9%) in the SH, DBBM/CM and IMPL/DBBM/CM groups, respectively (Figure 4). No statistically



**FIGURE 3** Consort diagram showing the study design.

Baseline characteristics	SH	DBBM-CM	IMPL/DBBM-CM
Age (years)	50.5 (12.2)	55.5 (11.6)	52.5 (7.5)
Male/female	7/3	4/6	3/7
Smokers	3	4	3
Maxilla/mandible	8/2	6/4	8/2
Anterior/premolars	5/5	5/5	6/4
Presence of both mesial/distal tooth	9	9	9
Reason for extraction (endo/fracture/prosthetic/root resorption)	5/1/4	5/2/2/1	4/3/2/1
FMPS (%)	15.3 (1.3)	15.1 (1.9)	14.9 (1.5)
FMBS (%)	8.9 (0.4)	8.3 (0.6)	8.6 (0.5)
KTH (mm)	2.70 (1.25)	3.70 (0.95)	4.00 (1.41)
GT (mm)	1.40 (0.57)	1.30 (0.59)	1.30 (0.42)
Thickness 1 mm buccal (mm)	1.17 (0.39)	1.33 (0.25)	1.34 (0.45)
Thickness 3 mm buccal (mm)	1.21 (0.55)	1.35 (0.48)	1.37 (0.94)
Thickness 5 mm buccal (mm)	1.59 (0.41)	1.71 (1.30)	1.64 (0.90)
Thickness 1 mm lingual (mm)	1.99 (1.054)	2.43 (1.64)	2.05 (1.30)
Thickness 3 mm lingual (mm)	2.38 (0.91)	2.89 (1.78)	3.08 (1.81)
Thickness 5 mm lingual (mm)	3.02 (1.58)	4.12 (2.16)	4.34 (2.32)

**TABLE 1** Baseline demographic, clinical and radiographic data of included patients

significant differences were observed between test and control groups, while significant differences were observed between SH group and both DBBM/CM and IMPL/DBBM/CM group.

No statistically significant differences between groups were observed for the ridge width changes 3 mm and 5 mm apical to the most coronal bone crest.

Mid-buccal ridge width 1 mm apical to the most coronal bone crest decreased  $2.45 \pm 1.29$  mm (54.9  $\pm$  20.9%),  $0.91 \pm 0.43$  mm (25.9  $\pm$  11%) and  $0.99 \pm 0.21$  mm (26  $\pm$  7%) in the SH, DBBM/CM and IMPL/DBBM/CM groups, respectively. No statistically significant differences were observed between test and control groups, while significant differences were observed between SH group and both DBBM/CM and IMPL/DBBM/CM group. Mid-lingual ridge width 1 mm apical to the most coronal bone crest decreased  $0.98 \pm 0.93$  mm (24.3  $\pm$  22%),  $0.64 \pm 0.4$  mm (14.4  $\pm$  9%) and  $0.29 \pm 0.29$  mm (5  $\pm$  9%) in the SH, DBBM/CM and IMPL/DBBM/CM groups, respectively. No statistically significant differences were observed between groups, except changes in percentages between SH group and IMPL/DBBM/CM group.

Mid-buccal ridge width 3 mm apical to the most coronal bone crest decreased  $1.92 \pm 1.99$  mm (41.5  $\pm$  26.4%)  $0.53 \pm 0.44$  mm (15.7  $\pm$  13.8%) and  $0.70 \pm 0.33$  mm (19.2  $\pm$  9.4%) in the SH, DBBM/CM and IMPL/DBBM/CM groups, respectively. No statistically significant differences were observed between test and control groups, while significant differences were observed between SH group and both DBBM/CM and IMPL/DBBM/CM group. No statistically differences between groups were observed for the mid-lingual ridge width changes 3 mm apical to the most coronal bone crest.

No statistically significant differences between groups were observed 5 mm apical to the most coronal bone crest for mid-buccal and mid-lingual ridge width changes.

### 3.2.2 | Vertical changes

No statistically significant differences between the groups were observed at the buccal and the lingual bone crest (Figure 5).

## 4 | DISCUSSION

The present study investigated the effect of immediate implant placement on alveolar ridge preservation when compared to alveolar ridge preservation alone or spontaneous healing of the socket. Radiographic linear measurements using DICOM data demonstrated the effectiveness of the alveolar ridge preservation technique, independently of the insertion of the implant, since these surgical protocols reduced the hard tissue dimensional changes that occurred after spontaneous healing of a flapped tooth extraction.

### 4.1 | Spontaneous healing

In this study, a marked resorption of the alveolar ridge was observed at 4 months when the socket was left to heal spontaneously after a flapped procedure, revealing a horizontal ridge width change of  $3.37 \pm 1.55$  mm (43.2  $\pm$  25.1%) and a vertical change of  $0.8 \pm 1.1$  mm (12  $\pm$  17%) at the buccal aspect. These data are in agreement with those of a very recent similar radiographic study by Jung et al. (2013), in which a flapless procedure was performed.

The scientific literature has amply demonstrated in humans that after the extraction of a tooth, significant changes occur in ridge dimension both horizontally and vertically (Petrokovski & Massler,

**TABLE 2** Calculated statistical differences for changes in ridge height and width over 4 months among the three treatment modalities

Dimensional changes	SH	DBBM-CM	IMPL/ DBBM-CM	Kruskal- Wallis (p-value)	Pairwise comparisons		
					SH vs. DBBM-CM	SH vs. IMPL/ DBBM-CM	DBBM-CM vs. IMPL/ DBBM-CM
Vertical buccal (mm)	-0.83 (1.14)	-0.31 (0.33)	-0.56 (0.38)	0.3444			
Vertical lingual (mm)	-0.21 (0.31)	-0.32 (0.47)	-0.50 (0.58)	0.4658			
Vertical buccal (%)	-10.60 (14.00)	-3.94 (4.79)	-6.26 (4.64)	0.4181			
Vertical lingual (%)	-2.15 (3.23)	-3.58 (4.72)	-4.98 (5.83)	0.4586			
Horizontal 1 mm (mm)	-3.37 (1.55)	-1.56 (0.71)	-1.29 (0.38)	<b>0.0008</b>	<b>0.0133</b>	<b>0.0011</b>	<b>1</b>
Horizontal 3 mm (mm)	-2.41 (1.97)	-1.07 (0.69)	-0.99 (0.48)	0.0534			
Horizontal 5 mm (mm)	-1.88 (1.55)	-0.96 (0.61)	-0.92 (0.59)	0.1858			
Horizontal 1 mm (%)	-43.23 (25.05)	-19.21 (9.18)	-14.92 (4.85)	<b>0.001</b>	<b>0.0213</b>	<b>0.0011</b>	<b>1</b>
Horizontal 3 mm (%)	-30.62 (28.60)	-12.27 (8.56)	-10.78 (5.64)	0.0738			
Horizontal 5 mm (%)	-23.12 (20.69)	-10.44 (7.13)	-9.51 (6.44)	0.1349			
Mid-buccal 1 mm (mm)	-2.45 (1.29)	-0.91 (0.43)	-0.99 (0.21)	<b>0.0001</b>	<b>0.0003</b>	<b>0.0014</b>	<b>1</b>
Mid-buccal 3 mm (mm)	-1.92 (1.99)	-0.53 (0.44)	-0.70 (0.33)	<b>0.0292</b>	<b>0.0342</b>	<b>0.1461</b>	<b>1</b>
Mid-buccal 5 mm (mm)	-1.43 (1.35)	-0.56 (0.44)	-0.53 (0.31)	0.0833			
Mid-buccal 1 mm (%)	-54.96 (20.99)	-25.96 (11.01)	-26.80 (7.07)	<b>0.0004</b>	<b>0.0009</b>	<b>0.0034</b>	<b>1</b>
Mid-buccal 3 mm (%)	-41.51 (26.45)	-15.76 (13.86)	-19.22 (9.44)	<b>0.0335</b>	<b>0.056</b>	<b>0.095</b>	<b>1</b>
Mid-buccal 5 mm (%)	-38.771 (28.16)	-16.90 (15.21)	-14.87 (8.78)	0.047	0.1262	0.076	<b>1</b>
Mid-lingual 1 mm (mm)	-0.98 (0.93)	-0.64 (0.40)	-0.29 (0.29)	0.0825			
Mid-lingual 3 mm (mm)	-0.55 (0.59)	-0.53 (0.29)	-0.29 (0.26)	0.1061			
Mid-lingual 5 mm (mm)	-0.45 (0.45)	-0.40 (0.25)	-0.38 (0.39)	0.9741			
Mid-lingual 1 mm (%)	-24.03 (22.07)	-14.47 (9.65)	-5.99 (6.18)	<b>0.0308</b>	<b>1</b>	<b>0.031</b>	<b>0.2061</b>
Mid-lingual 3 mm (%)	-14.30 (15.87)	-10.29 (6.51)	-5.20 (4.74)	0.1163			
Mid-lingual 5 mm (%)	-10.88 (12.61)	-7.00 (4.60)	-6.44 (7.08)	0.7421			

In bold: statistically significant differences

1967; Schropp et al., 2003). A very recent systematic review demonstrated a horizontal dimensional reduction of  $3.79 \pm 0.23$  mm (29%–63%) and a vertical bone loss at the buccal aspect of  $1.24 \pm 0.11$  mm (11%–22%) at 6 months (Tan et al., 2012).

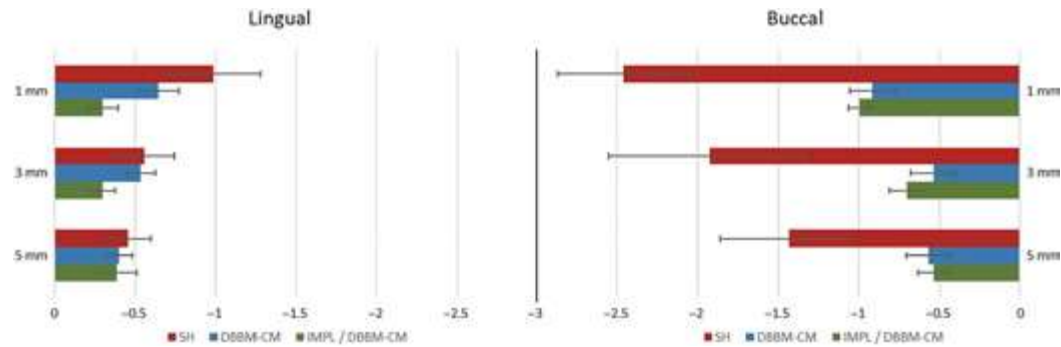
In this study, further analysis of mid-buccal and mid-lingual bone crest revealed that vertical and horizontal bone dimensional changes were more pronounced at the buccal (vertical:  $0.8 \pm 1.1$  mm; horizontal:  $2.45 \pm 1.29$  mm) than at the lingual (vertical:  $0.2 \pm 0.3$  mm; horizontal:  $0.98 \pm 0.93$  mm) aspect, thus shifting the centre of the crest towards a more palatal position. This observation is in agreement with preclinical studies by Araújo and Lindhe (2005), Fickl et al. (2008) and Discepoli et al. (2013) in which the observed morphological changes were more significant at the buccal than the palatal/lingual aspects.

On the other hand, similar to results from clinical trials in which radiographic analysis was performed at different levels below the alveolar crest (Jung et al., 2013; Kerr et al., 2008), this study demonstrated less horizontal ridge reduction as the distance from the alveolar crest increased, despite differences in the surgical method (flapped in this study, flapless in Jung et al., 2013, and Kerr et al., 2008). Different changes between the two cortices (buccal and

palatal/lingual aspects) and at different heights (1, 3 and 5 mm) below the crest may be explained by differences in thickness of the alveolar crest at baseline. This resorption pattern may be due to the presence of bundle bone, in which the periodontal ligament fibres of a tooth invest, and which is lost following tooth extraction as it is a tooth-dependent structure. In preclinical studies from Araújo and Lindhe (2005) and Discepoli et al. (2013), it was observed that thin crestal regions (high resorption rate) were made up exclusively of bundle bone while the thick regions (low resorption rate) were comprised of a combination of bundle bone and lamellar bone.

Relatively large thickness of the marginal crest at baseline (buccal:  $1.17 \pm 0.39$  mm; lingual:  $1.99 \pm 1.05$  mm) and site selection (mostly premolars) may explain the discrepancy with respect to the amount of crestal resorption between this study and results from Araújo, da Silva, de Mendonça, & Lindhe (2015), in which a vertical change of 3.6 mm (35.8%) at the buccal site and 1.4 mm (13.4%) at the palatal site were reported. In that article, the study sample comprised mostly anterior teeth, and further analysis of their data revealed that the reduction in the buccal bone plate was more pronounced in the anterior than in the premolar regions. As demonstrated by Januario et al. (2011) from a radiographic study, about 50% of the coronal





**FIGURE 4** Changes in ridge width (mm) at buccal and lingual aspects over 4 months based on cone-beam computed tomography measurements

(5 mm) portion of the buccal bone wall in maxillary incisors and canines is < 0.5 mm wide, with an average of 0.6 mm wide.

**4.2 | ARP**

The observations in the present study established that the placement of a bone substitute material (DBBM) in the fresh extraction socket, covered by a collagen matrix, reduced vertical and horizontal ridge resorption. This is in agreement with data reported by Jung et al. (2013), in which both vertical and horizontal resorption were limited by the placement of DBBM, covered by a collagen matrix, in the fresh extraction socket, despite the fact that in that study a flapless approach was performed.

This is also in agreement with a number of recently published systematic reviews on ARP procedures (Ten Heggeler et al., 2011; Horvath et al., 2013; MacBeth et al., 2017; Mardas et al., 2010; Vignoletti, Discepoli, et al., 2012; Vignoletti, Matesanz, et al., 2012; Vittorini Orgeas et al., 2013) which conclude how no bone substitute material and/or membrane is able to completely preserve the alveolar ridge after tooth extraction, but may limit buccal plate resorption to a certain extent.

Findings from the present study revealed that mid-buccal horizontal changes 1 mm ( $0.91 \pm 0.43$  mm), and 3 mm ( $0.53 \pm 0.44$  mm) below the marginal crest have been the ones which statistically benefited the most from ARP procedure when compared to spontaneous healing. This means, in agreement with Araújo, Linder, Wennström, and Lindhe (2008), that graft material apparently promoted de novo hard tissue formation showing a radiographic appearance different from that of a cortical plate but maintaining the dimensions of the hard tissue wall. This is particularly true for sites made up exclusively of bundle bone, therefore regions with a very thin bone crest.

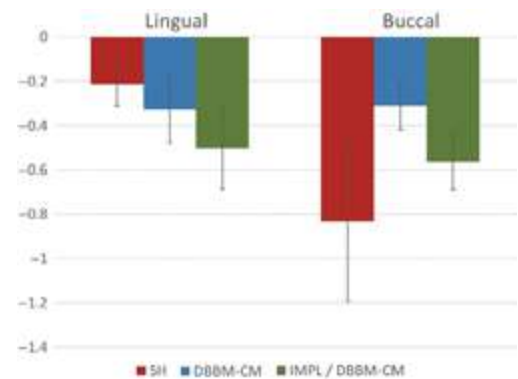
**4.3 | ARP + Immediate implant placement**

In the present work, no statistically significant difference resulted from the comparison between test group (IMPL/DBBM/CM) and control group (DBBM/CM), indicating that the preservation of bone

volumes is quite similar in sites where the implant was inserted and in the sites where only ARP was performed.

When an implant was inserted simultaneously to an ARP procedure after flapped tooth extraction, horizontal mean changes at 1 mm below the marginal crest were  $1.29 \pm 0.38$  mm ( $14.9 \pm 4.9\%$ ) with changes at buccal aspect of  $0.99 \pm 0.21$  mm ( $26.80 \pm 7.07\%$ ). These data are completely in agreement with a recent work by Sanz et al. (2017), aimed at evaluating differences in dimensional alterations of the ridge after 4 months between immediate implants and immediate implants associated with regenerative procedures. Reporting a bucco-lingual dimensional change (1 mm below the crest) in grafted sites of 1.3 (11%) and a reduction of the buccal cortical bone of 1.1 mm (29%), they demonstrated that placement of DBBM in the void between the implant and the walls of the fresh extraction socket somewhat counteracted the contraction of the buccal hard tissue plate that normally occurs during healing.

Similar data were also presented in a radiographic study by Degidi, Daprile, Nardi, and Piattelli (2012), in which the mean reduction in the distance between implant surface and outer surface



**FIGURE 5** Changes in ridge height (mm) over 4 months based on cone-beam computed tomography measurements

of buccal bone crest was  $0.88 \pm 0.51$  mm (29.3%) after 1 year of a flapless immediate implant placement with simultaneous grafting of the buccal gap with DBBM and immediate restoration. Analysing the height of the marginal buccal crest, the authors reported a mean reduction of  $0.76 \pm 0.96$  mm, that is, similar to  $0.6 \pm 0.4$  mm of vertical dimensional alteration obtained in this study at the buccal site when an immediate implant and an ARP procedure were simultaneously performed.

These data seem to confirm the trend towards better outcomes achieved by means of the combined use of regenerative techniques observed in a clinical trial by Chen, Darby, and Reynolds (2007) and by a recent systematic review (Clementini et al., 2015) on dimensional changes after immediate implant placement with or without simultaneous regenerative procedures. In IMPL/DBBM/CM group of the present study, a flapped procedure was performed and the inserted implant was not immediately restored. The use of a flapless procedure or an immediate restoration, as the placement of a soft-tissue graft or the use of a platform-switching implant-abutment connection should further be investigated in well-designed clinical trials, since there are indications of their potential benefit in maintaining ridge volume after tooth extraction.

Due to the small sample size, this randomized controlled clinical trial was not able to identify correlations between some prognostic factors (i.e., thickness of the buccal bone plate at baseline, tooth location) and the radiographic outcomes (Ferrus et al., 2010; Tomasi et al., 2010). The short follow-up period (4 months) of a radiographic analysis is another limit of this study since it does not allow an evaluation of the real benefits for patients of limiting morphological changes after tooth extraction. In this study, a number of outcomes could not be evaluated, as the necessity and the amount of a ridge augmentation procedure necessary for implant placement, the occurrence of soft tissue dehiscence and patient reported outcomes (overall treatment time, number of surgical procedures, aesthetic satisfaction). However, regardless of its limitations, the present study reveals interesting data which translates into clinically relevant information.

## 5 | CONCLUSION

The present study demonstrates that after a flapped extraction of a tooth, vertical and horizontal changes of the alveolar ridge occur, regardless of whether alveolar ridge preservation is performed. This happens despite the placement of an implant simultaneously with the ridge preservation procedure. However, a preservation technique, with or without immediate implant placement, reduces the horizontal bone morphological changes that occur, mostly in the coronal portion of the buccal bone plate, when compared to spontaneous healing. For this reason, immediate implant placement in postextraction sites plus an ARP technique may be a viable option to reduce hard tissue morphological changes and treatment time.

## ACKNOWLEDGEMENTS

The authors would like to thank Dr. Lucrezia Paterno' Holtzman for review of the English language.

## CONFLICT OF INTEREST

The authors report no conflict of interests related to the study.

## ORCID

Marco Clementini  <https://orcid.org/0000-0002-1827-5200>

## REFERENCES

- Araújo, M. G., da Silva, J. C. C., de Mendonça, A. F., & Lindhe, J. (2015). Ridge alterations following grafting of fresh extraction sockets in man. A randomized clinical trial. *Clinical Oral Implants Research*, 26, 407–412. <https://doi.org/10.1111/clr.12366>
- Araújo, M. G., Linder, E., Wennström, J. L., & Lindhe, J. (2008). The influence of Bio-Oss collagen on healing of an extraction socket: An experimental study in the dog. *International Journal of Periodontics and Restorative Dentistry*, 28, 123–135. <https://doi.org/10.1111/clr.12366>
- Araújo, M. G., & Lindhe, J. (2005). Dimensional ridge alterations following tooth extraction. An experimental study in the dog. *Journal of Clinical Periodontology*, 32, 212–218. <https://doi.org/10.1111/j.1600-051X.2005.00642.x>
- Araujo, M. G., Sukekava, F., Wennstrom, J. L., & Lindhe, J. (2005). Ridge alterations following implant placement in fresh extraction sockets: An experimental study in the dog. *Journal of Clinical Periodontology*, 32, 645–652. <https://doi.org/10.1111/j.1600-051X.2005.00726.x>
- Avila-Ortiz, G., Chambrone, L., & Vignoletti, F. (2019). Effect of alveolar ridge preservation interventions following tooth extraction: a systematic review and meta-analysis. *Journal of Clinical Periodontology*. [Epub ahead of print]. <https://doi.org/10.1111/jcpe.13057>
- Bliese, P. D. (2000). Within-group agreement, non-independence, and reliability: Implications for data aggregation and Analysis. In K. J. Klein, & S. W. Kozlowski (Eds.), *Multilevel theory, research, and methods in organizations* (pp. 349–381). San Francisco, CA: Jossey-Bass Inc.
- Chen, S. T., & Buser, D. (2014). Esthetic outcomes following immediate and early implant placement in the anterior maxilla – a systematic review. *International Journal of Oral & Maxillofacial Implants*, 29, 186–215. <https://doi.org/10.11607/jomi.2014suppl.g3.3>
- Chen, S. T., Darby, I. B., & Reynolds, E. C. (2007). A prospective clinical study of non-submerged immediate implants: Clinical outcomes and esthetic results. *Clinical Oral Implants Research*, 18, 552–562. <https://doi.org/10.1111/j.1600-0501.2007.01388.x>
- Clementini, M., Discepoli, N., Danesi, C., & de Sanctis, M. (2018). Biologically guided flap stability: The role of flap thickness including periosteum retention on the performance of the coronally advanced flap—A double-blind randomized clinical trial. *Journal of Clinical Periodontology*, 45, 1238–1246. <https://doi.org/10.1111/jcpe.12998>
- Clementini, M., Tiravia, L., De Risi, V., Vittorini Orgeas, G., Mannocci, A., & de Sanctis, M. (2015). Dimensional changes after immediate implant placement with or without simultaneous regenerative procedures: A systematic review and meta-analysis. *Journal of Clinical Periodontology*, 42, 666–677. <https://doi.org/10.1111/jcpe.12423>
- Cosyn, J., Hooghe, N., & De Bruyn, H. (2012). A systematic review on the frequency of advanced recession following single immediate implant treatment. *Journal of Clinical Periodontology*, 39, 582–589. <https://doi.org/10.1111/j.1600-051X.2012.01888.x>

- De Risi, V., Clementini, M., Vittorini, G., Mannocci, A., & de Sanctis, M. (2015). Alveolar ridge preservation techniques: A systematic review and meta-analysis of histological and histomorphometrical data. *Clinical Oral Implants Research*, 26, 50–68. <https://doi.org/10.1111/clr.12288>
- Degidi, M., Daprile, G., Nardi, D., & Piattelli, A. (2012). Buccal bone plate in immediately placed and restored implant with Bio-Oss collagen graft: A 1-year follow-up study. *Clinical Oral Implants Research*, 24(11), 1201–1205. <https://doi.org/10.1111/j.1600-0501.2012.02561.x>
- Discepoli, N., Vignoletti, F., Laino, L., de Sanctis, M., Munoz, F., & Sanz, M. (2013). Early healing of the alveolar process after tooth extraction. An experimental study in the beagle dog. *Journal of Clinical Periodontology*, 40, 638–644. <https://doi.org/10.1111/jcpe.12074>
- Discepoli, N., Vignoletti, F., Laino, L., de Sanctis, M., Munoz, F., & Sanz, M. (2015). Fresh extraction socket: Spontaneous healing vs. immediate implant placement. *Clinical Oral Implants Research*, 26, 1250–1255. <https://doi.org/10.1111/clr.12447>
- Evans, C. D., & Chen, S. T. (2008). Esthetic outcomes of immediate implant placements. *Clinical Oral Implants Research*, 19(1), 73–80.
- Ferrus, J., Cecchinato, D., Pjetursson, E. B., Lang, N. P., Sanz, M., & Lindhe, J. (2010). Factors influencing ridge alterations following immediate implant placement into extraction sockets. *Clinical Oral Implants Research*, 21, 22–29. <https://doi.org/10.1111/j.1600-0501.2009.01825.x>
- Fickl, S., Zühr, O., Wachtel, H., Stappert, C. F. J., Stein, J. M., & Hürzeler, M. B. (2008). Dimensional changes of the alveolar ridge contour after different socket preservation techniques. *Journal of Clinical Periodontology*, 35, 906–913. <https://doi.org/10.1111/j.1600-051X.2008.01305.x>
- Hämmerle, C. H. F., Araujo, M. G., & Simion, M. (2012). Evidence-based knowledge on the biology and treatment of extraction sockets. *Clinical Oral Implants Research*, 23(5), 80–82. <https://doi.org/10.1111/j.1600-0501.2011.02370.x>
- Horvath, A., Mardas, N., Mezzomo, L. A., Needleman, I. G., & Donos, N. (2013). Alveolar ridge preservation. A systematic review. *Clinical Oral Investigations*, 17, 341–363. <https://doi.org/10.1007/s00784-012-0758-5>
- Januario, A. L., Duarte, W. R., Barriviera, M., Mesti, J. C., Araujo, M. G., & Lindhe, J. (2011). Dimension of the facial bone wall in the anterior maxilla: A cone-beam computed tomography study. *Clinical Oral Implants Research*, 10, 1168–1171. <https://doi.org/10.1111/j.1600-0501.2010.02086.x>
- Jung, R. E., Philipp, A., Annen, B. M., Signorelli, L., Thoma, D. S., Hämmerle, C. H., ... Schmidlin, P. (2013). Radiographic evaluation of different techniques for ridge preservation after tooth extraction: A randomized controlled clinical trial. *Journal of Clinical Periodontology*, 1, 90–98. <https://doi.org/10.1111/jcpe.12027>
- Kerr, E. N., Mealey, B. L., Noujeim, M. E., Lasho, D. J., Nummikoski, P. V., & Mellonig, J. T. (2008). The effect of ultrasound on bone dimensional changes following extraction: A pilot study. *Journal of Periodontology*, 79(2), 283–290. <https://doi.org/10.1902/jop.2008.070289>
- Lang, N. P., & Bartold, P. M. (2018). Periodontal health. *Journal of Clinical Periodontology*, 45(20), S9–S16. <https://doi.org/10.1111/jcpe.12936>
- Lang, N. P., Pun, L., Lau, K. Y., Li, K. Y., & Wong, M. C. (2012). A systematic review on survival and success rates of implants placed immediately into fresh extraction sockets after at least 1 year. *Clinical Oral Implants Research*, 23(5), 39–66. <https://doi.org/10.1111/j.1600-0501.2011.02372.x>
- Lazzara, R. G. (1989). Immediate implant placement into extraction sites: Surgical and restorative advantages. *International Journal of Periodontics and Restorative Dentistry*, 9(5), 332–343.
- MacBeth, N., Trullenque-Eriksson, A., Donos, N., & Mardas, N. (2017). Hard and soft tissue changes following alveolar ridge preservation: A systematic review. *Clinical Oral Implants Research*, 28, 982–1004. <https://doi.org/10.1111/clr.12911>
- Mardas, N., Chadha, V., & Donos, N. (2010). Alveolar ridge preservation with guided bone regeneration and a synthetic bone substitute or a bovine-derived xenograft: A randomized, controlled clinical trial. *Clinical Oral Implants Research*, 21(7), 688–698. <https://doi.org/10.1111/j.1600-0501.2010.01918.x>
- Muhlemann, H. R., & Son, S. (1971). Gingival sulcus bleeding – a leading symptom in initial gingivitis. *Helvetica Odontologica Acta*, 15, 107–113.
- O'Leary, T. J., Drake, R. B., & Naylor, J. E. (1972). The plaque control record. *Journal of Periodontology*, 43, 38. <https://doi.org/10.1902/jop.1972.43.1.38>
- Pietrokovski, J., & Massler, M. (1967). Alveolar ridge resorption following tooth extraction. *Journal of Prosthetic Dentistry*, 17, 21–27. [https://doi.org/10.1016/0022-3913\(67\)90046-7](https://doi.org/10.1016/0022-3913(67)90046-7)
- Sanz, M., Lindhe, J., Alcaraz, J., Sanz-Sanchez, I., & Cecchinato, D. (2017). The effect of placing a bone replacement graft in the gap at immediately placed implants: A randomized clinical trial. *Clinical Oral Implants Research*, 28(8), 902–910. <https://doi.org/10.1111/clr.12896>
- Schropp, L., Wenzel, A., Kostopoulos, L., & Karring, T. (2003). Bone healing and soft tissue contour changes following single-tooth extraction: A clinical and radiographic 12-month prospective study. *The International Journal of Periodontics & Restorative Dentistry*, 23, 313–323.
- Schulte, W., & Heimke, G. (1976). The Tübingen immediate implant. *Die Quintessenz*, 27(6), 17–23.
- Tan, W. L., Wong, T. L., Wong, M. C., & Lang, N. P. (2012). A systematic review of post-extraction alveolar hard and soft tissue dimensional changes in humans. *Clinical Oral Implants Research*, 23(Suppl 5), 1–21. <https://doi.org/10.1111/j.1600-0501.2011.02375.x>
- Ten Heggeler, J. M. A. G., Slot, D. E., & Van der Weijden, G. A. (2011). Effect of socket preservation therapies following tooth extraction in non-molar regions in humans: A systematic review. *Clinical Oral Implants Research*, 22(8), 779–788. <https://doi.org/10.1111/j.1600-0501.2010.02064.x>
- Tomasi, C., Sanz, M., Cecchinato, D., Pjetursson, B., Ferrus, J., Lang, N. P., & Lindhe, J. (2010). Bone dimensional variations at implants placed in fresh extraction sockets: A multilevel multivariate analysis. *Clinical Oral Implants Research*, 21, 30–36. <https://doi.org/10.1111/j.1600-0501.2009.01848.x>
- Tonetti, M. S., Cortellini, P., Graziani, F., Cairo, F., Lang, N. P., Abundo, R., ... Wetzal, A. (2017). Immediate versus delayed implant placement after anterior single tooth extraction: The timing randomised controlled clinical trial. *Journal of Clinical Periodontology*, 44, 215–224. <https://doi.org/10.1111/jcpe.12666>
- Van der Weijden, F., Dell'Acqua, F., & Slot, D. E. (2009). Alveolar bone dimensional changes of post-extraction sockets in humans: A systematic review. *Journal of Clinical Periodontology*, 36, 1048–1058. <https://doi.org/10.1111/j.1600-051X.2009.01482.x>
- Vignoletti, F., Discepoli, N., Muller, A., de Sanctis, M., Munoz, F., & Sanz, M. (2012). Bone modelling at fresh extraction sockets: Immediate implant placement versus spontaneous healing: An experimental study in the beagle dog. *Journal of Clinical Periodontology*, 39, 91–97. <https://doi.org/10.1111/j.1600-051X.2011.01803.x>
- Vignoletti, F., Matesanz, P., Rodrigo, D., Figuero, E., Martin, C., & Sanz, M. (2012). Surgical protocols for ridge preservation after tooth extraction. A systematic review. *Clinical Oral Implants Research*, 23(Suppl 5), 22–38. <https://doi.org/10.1111/j.1600-0501.2011.02331.x>
- Vignoletti, F., & Sanz, M. (2014). Immediate implants at fresh extraction sockets: From myth to reality. *Periodontology*, 2000(66), 132–152. <https://doi.org/10.1111/prd.12044>
- Vittorini Orgeas, G., Clementini, M., De Risi, V., & de Sanctis, M. (2013). Surgical techniques for alveolar socket preservation: A systematic review. *International Journal of Oral and Maxillofacial Implants*, 28(4), 1049–1061. <https://doi.org/10.11607/jomi.2670>

**How to cite this article:** Clementini M, Agostinelli A, Castelluzzo W, Cugnata F, Vignoletti F, De Sanctis M. The effect of immediate implant placement on alveolar ridge preservation compared to spontaneous healing after tooth extraction: Radiographic results of a randomized controlled clinical trial. *J Clin Periodontol*. 2019;46:776–786. <https://doi.org/10.1111/jcpe.13125>



## Case Report

## Immediate Loading Mandibular Rehabilitation with Reduced Number of Implants

Angelo Cardarelli<sup>1\*</sup>, Michele Grechi<sup>1</sup>, Pietro Montemezzi<sup>1</sup>, Mario Piro<sup>1</sup> and Paolo Cappare<sup>1</sup>

<sup>1</sup>Department of Dentistry University "Vita-Salute" San Raffaele Milano, Dean Professor E.F. Gherlone, IRCCS San Raffaele Hospital, Milan, Italy

## Introduction

Implant-prosthetic rehabilitations of immediate jaws represent a therapeutic possibility with a high success rate and satisfaction for the operator and the patient. However, the anatomy of the jaws, periodontal and iatrogenic damages represent limitations to the conventional rehabilitations of edentulous patients and with serious impairment of the residual dental elements that would require pre-implant bone regeneration treatments. These methods are to be considered for patients with a high biological and economic cost, with high morbidity and operator employees. For these reasons, the current implant guidelines focus on clinical protocols that exploit the residual basal bone without the need for any kind of regeneration. These methods, well supported by scientific data, provide for an immediate restoration of the function by positioning implants with immediate loading. The "All on Four" protocol requires the placement of four implants, two anterior "straight" and two tilted posterior ones placed in the basal bone of the jaws. The reduced number of implant rehabilitations, whether they are inclined or not, are proven by numerous scientific studies showing that four implants are sufficient to support full-arch prosthesis. Since the immediate loading of inclined and axial implants with placement of an immediate provisional prosthesis is proposed as a predictable, fast and cheap method to treat maxillary atrophy, the purpose of this article is to illustrate the mandibular rehabilitation with immediate loading of a patient with severe impairment of residual dental elements [1-2-3-4-5].

## Materials and Methods

In this case it is described a woman patient of 65 years, in good health, with a negative history, not a smoker. The clinical and radiographic examination (OPT and Cone Beam) (Figure 1-2). shows a serious impairment, with widespread mobility of the remaining dental elements (Figures.3-4-5-6-7). In agreement with the patient is therefore decided to carry out the reclamation of the dental elements Residues, and to insert 4 implants with immediate loading according to the "All on 4" method.

## Surgical and Prosthetic Procedures

One hour before the operation, 1 g of amoxicillin is given to the patient, to be taken twice a day for the following 6 days. Surgical procedures are performed under local anesthesia, 20 mg / mL optocaine with 1: 80,000 adrenalines. At the mandibular level the remaining dental elements are emulsified, then a crestal incision is made from the area of the first right molar to the first left molar with two distal discharges and the mucoperiosteal detachment aimed at highlighting the emergence of the chin guard holes. {Figures.8-9-10} the posterior implants, with a diameter of 3.8 mm and a length of 15 mm, are positioned above the mentally foramen and inclined mesially by 30-45 degrees to the occlusal plane. The posterior implants generally emerge in the position of the second premolar. Subsequently, the axial implants are positioned 3.8 mm in diameter and 13 in length (Winsix Biosafin) (Figure.11-12). For the front implants are positioned Extreme Abutments straight, while for those posterior to 30 degrees to compensate for the lack of parallelism between the fixtures. These degrees of angulations are chosen to allow the access hole of the prosthetic screw an occlusal or lingual position with respect to the teeth mounted on the provisional prosthesis. The suture is made with 4/0 silk thread. At the end of the operation the previously made temporary

**\*Corresponding Author:** Angelo Cardarelli, Department of Dentistry University "Vita-Salute" San Raffaele Milano, Dean Professor E.F. Gherlone, IRCCS San Raffaele Hospital, Milan, Italy, E-mail: angelo\_cardarelli@libero.it

**Sub Date:** January 07<sup>th</sup>, 2019, **Acc Date:** January 12<sup>th</sup>, 2019, **Pub Date:** January 16<sup>th</sup>, 2019

**Citation:** Cardarelli A, Michele G, Pietro M, et al. (2019) Immediate Loading Mandibular Rehabilitation with Reduced Number of Implants. BAOJ Dentistry 5: 050.

**Copyright:** © 2019 Cardarelli A. This is an open access article distributed under the terms of the Creative Commons Attribution License, which permits unrestricted use, distribution, and reproduction in any medium, provided the original author and source are credited.

**Citation:** Cardarelli A, Michele G, Pietro M, et al. (2019) Immediate Loading Mandibular Rehabilitation with Reduced Number of Implants. Page 2 of 6 BAOJ Dentistry 5: 050.

prosthesis is re-ribbed and screwed according to the diagnostic set up, whose vertical dimension is established and corrected by the study fingerprints and the cephalometric study (Figure. 13-14-15). The

patient is given a semi-solid diet for 2 months following the operation. At 4 months from the osseointegration and stabilization of the soft tissues the impressions are detected, and a composite screwed Toronto is made (Figures.16-17-18-19-20-21-22-23).

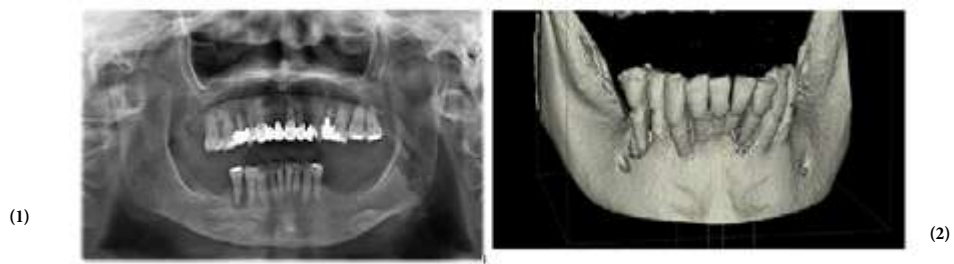

Figure:

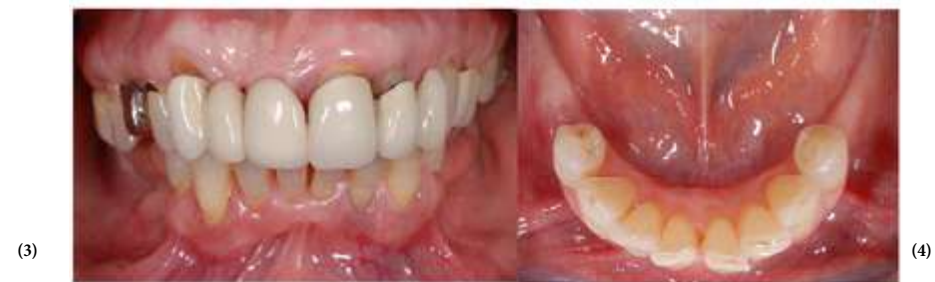

Figure:

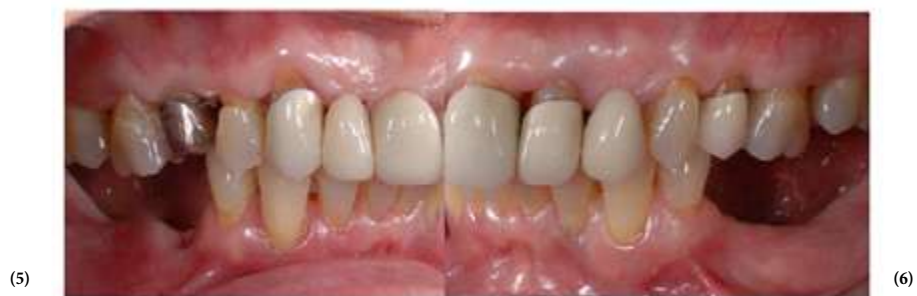

Figure:



**Citation:** Cardarelli A, Michele G, Pietro M, et al. (2019) Immediate Loading Mandibular Rehabilitation with Reduced Number of Implants. Page 3 of 6  
BAOJ Dentistry 5: 050.

---

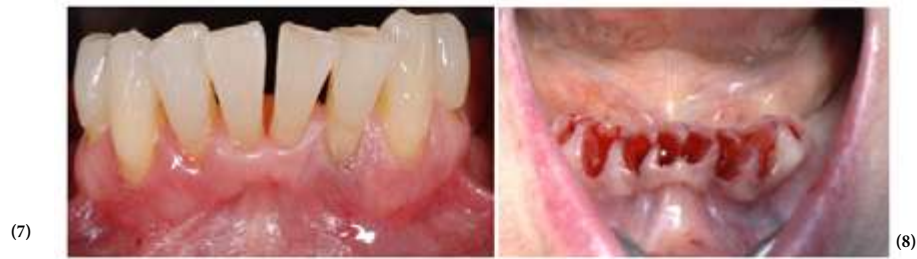

Figure:

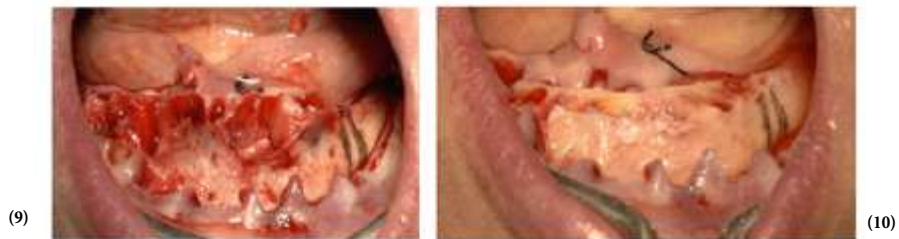

Figure:

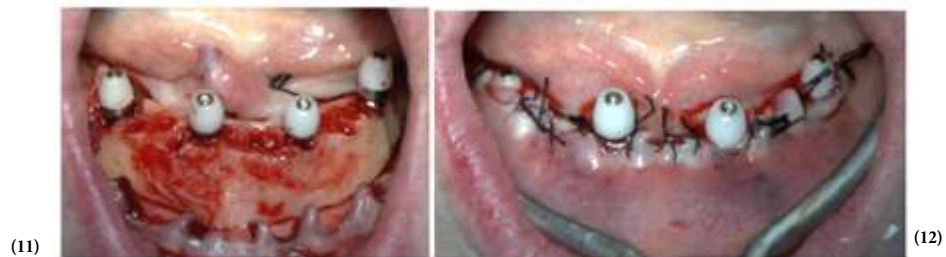

Figure:



**Citation:** Cardarelli A, Michele G, Pietro M, et al. (2019) Immediate Loading Mandibular Rehabilitation with Reduced Number of Implants. Page 4 of 6 BAOJ Dentistry 5: 050.

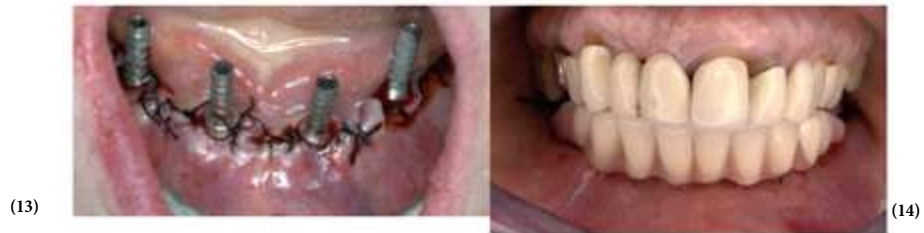

Figure:

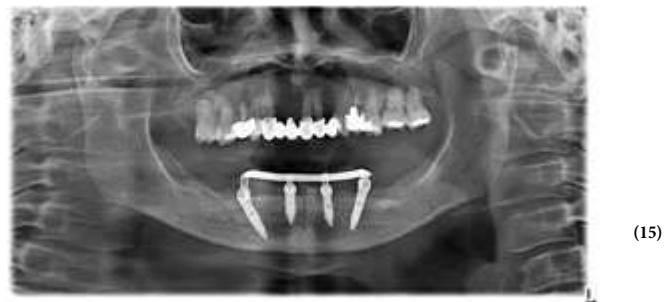

Figure:

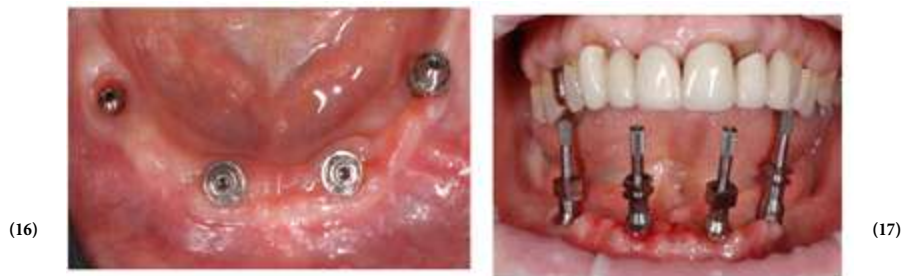

Figure:

**Citation:** Cardarelli A, Michele G, Pietro M, et al. (2019) Immediate Loading Mandibular Rehabilitation with Reduced Number of Implants. Page 5 of 6 BAOJ Dentistry 5: 050.

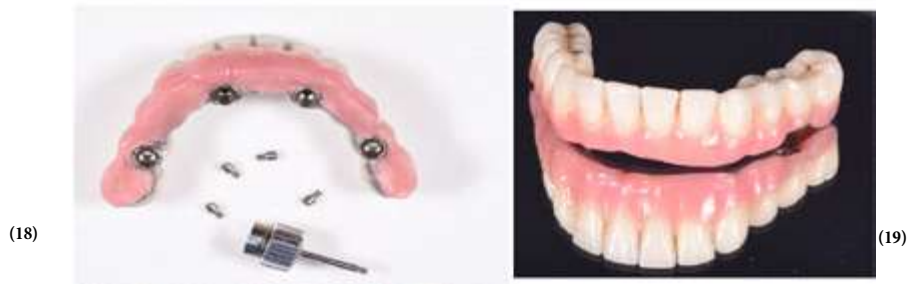

Figure:

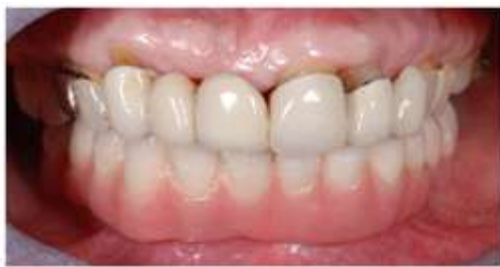

Figure 20

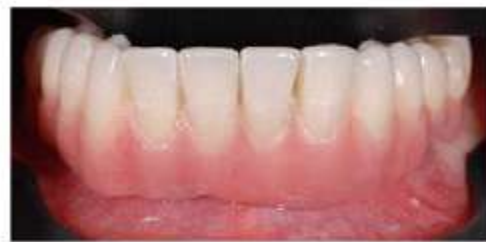

Figure 21.

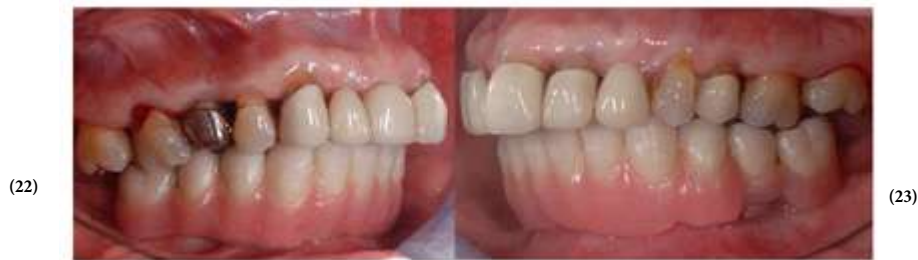
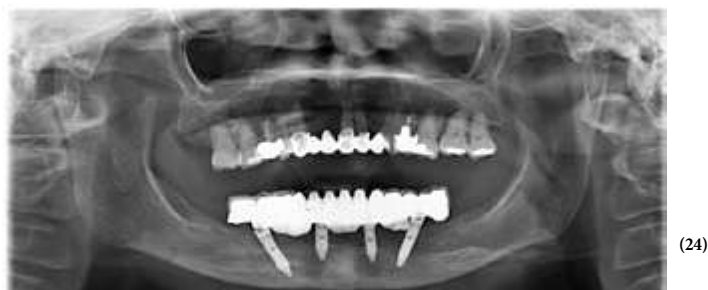
Figure:



(24)

Figure:

**Citation:** Cardarelli A, Michele G, Pietro M, et al. (2019) Immediate Loading Mandibular Rehabilitation with Reduced Number of Implants. Page 6 of 6 BAOJ Dentistry 5: 050.

### Results and Conclusions

At the 24-month follow-up the clinical and radiological appearance of soft and hard tissues is optimal and no pathological signs or prosthetic complications were recorded (Figure.24). This surgical technique, therefore, represents a valid and predictable therapeutic alternative to the techniques of bone augmentation and regeneration. The biomechanical aspect on which the use of angled implants is based is the reduction of the cantilever and therefore a better and homogeneous distribution of the loads at the prosthetic level. Numerous studies have reported a high survival rate; others have assessed the amount of stress in the peri-implant bone, and these studies showed that the single angled implant [6-7-8-9-10].

Subjected to axial loads presents greater per implant bone stress than the single axial implant; however, when the angled implants is joined to other implants with an educed cantilever, it presents a minor mechanical stress at the per implant level compared to solidarizza implants but with a greater cantilever [11-12-13-14].

### References

1. Aparicio C, Perales P, Rangert B (2001) Tilted implants as an alternative to maxillary sinus grafting. *Clin Implant Dent Relat Res* 3: 39-49.
2. Krekmanov L, Kahn M, Rangert B, Lindstrom H (2000) Tilting of posterior mandibular and maxillary implants of improved prosthesis support. *Int J Oral Maxillofac Implants* 15(3): 405-414.
3. Malo P, Nobre Mde A, Petersson U, Wigren S (2006) A pilot study of complete edentulous rehabilitation with immediate function using a new implant design: Case series. *Clin Implant Dent Relat Res* 8(4): 223-232.
4. Stegaroiu R, Khraisat A, Nomura S, Miyakawa O (2004) Influence of super-structure materials on strain around an implant underloading conditions: a technical investigation 19(5): 735-742.
5. Tealdo T, Bevilacqua M, Pera F, Menini M, Ravera G, et al. (2008) Immediate function with fixed implant-supported maxillary dentures: A 12-month pilot study. *J Prosthet Dent* 99(5): 351-360.
6. Aparicio C, Perales P, Rangert B (2001) Tilted implants as an alternative to maxillary sinus grafting. *Clin Implant Dent Relat Res* 3: 39-49.
7. Krekmanov L, Kahn M, Rangert B, Lindstrom H (2000) Tilting of posterior mandibular and maxillary implants of improved prosthesis support. *Int J Oral Maxillofac Implants* 15(3): 405-414.
8. Malo P, Nobre Mde A, Petersson U, Wigren S (2006) A pilot study of complete edentulous rehabilitation with immediate function using a new implant design: Case series. *Clin Implant Dent Relat Res* 8(4): 223-232.
9. Stegaroiu R, Khraisat A, Nomura S, Miyakawa O (2004) Influence of super-structure materials on strain around an implant underloading conditions: a technical investigation 19(5): 735-742.
10. Tealdo T, Bevilacqua M, Pera F, Menini M, Ravera G, et al. (2008) Immediate function with fixed implant-supported maxillary dentures: A 12-month pilot study. *J Prosthet Dent* 99(5): 351-360.
11. Grunder U (2001) Immediate functional loading of immediate implants in edentulous arches: Two-year results. *Int J Periodontics Restorative Dent* 21(6): 545-551.
12. Skalak R (1983) Biomechanical considerations in osseointegrated prostheses. *J Prosthet Dent* 49(6): 843-848.
13. Juodzbaly G, Kubilius R, Eidukynas V, Raustia AM (2005) Stress distribution in bone: Single-unit implant prostheses veneered with porcelain or a new composite material. *Implant Dent* 14(2): 166-175.
14. Crespi R, Vinci R, Cappare P, Romanos GE, Gherlone E (2012) A clinical study of edentulous patients rehabilitated according to the "all on four" immediate function protocol 27(2): 428-434.

## CLINICAL

# Relationship Between Crestal Bone Levels and Crown-to-Implant Ratio of Ultra-Short Implants With a Microrough Surface: A Prospective Study With 48 Months of Follow-Up

Luciano Malchiodi, MD, DDS<sup>1</sup>  
 Erika Giacomazzi, DDS<sup>2</sup>  
 Alessandro Cucchi, PhD, MSc, DDS<sup>3</sup>  
 Giulia Ricciotti, DDS<sup>1\*</sup>  
 Riccardo Caricasulo, MSc, DDS<sup>1</sup>  
 Dario Bertossi, MD<sup>1</sup>  
 Enrico Gherlone, MD, DMD<sup>4</sup>

The aim of this cohort study was to investigate the relationship between crestal bone levels and crown-to-implant ratio of ultra-short implants, after functional loading. Sixty patients with single or partial edentulism and alveolar bone atrophy were enrolled and treated between December 2009 and January 2016. Without using bone-grafting procedures, patients were rehabilitated with ultra-short implants characterized by a microrough surface and a 6-mm length. Clinical and anatomical crown-to-implant (C/I) ratios and crestal bone levels (CBL) were measured after a follow-up period ranging from 12 to 72 months; all peri-implant and prosthetic parameters were recorded. The data collected were statistically analyzed ( $P = .05$ ). A total of 47 patients with 66 ultra-short implants were completely followed up according to described protocol. The mean follow-up was  $48.5 \pm 19.1$  months. The mean anatomical C/I ratio was 2.2, while the mean clinical C/I ratio was  $2.6 \pm 0.6$  at baseline and  $2.8 \pm 0.6$  at the last follow-up appointment. Mean CBL as calculated at the baseline was  $0.7 \pm 0.5$  mm, while at the last appointment it measured  $1.0 \pm 0.5$  mm. The overall implant-based success rate was 96.9%, and the mean peri-implant bone loss (PBL) was  $0.3 \pm 0.3$  mm. No statistically significant relationship was found between anatomical or clinical C/I ratio and PBL. Ultra-short implants appear to offer a predictable solution for implant-prosthetic rehabilitation in patients with edentulism and bone atrophy. A high percentage of implants were successful, with minimal crestal bone loss. The high C/I ratio did not appear to influence either peri-implant bone loss or prosthetic complication rates.

**Key Words:** dental implants, ultra short implants, micro roughed surface, biomechanical evaluation

## INTRODUCTION

Edentulism typically results in progressive resorption of the alveolar bone.<sup>1,2</sup> When advanced maxillary or mandibular bone atrophy has occurred, prosthetic rehabilitation with standard implants can be difficult or even impossible.<sup>3</sup> As a result, different strategies have been developed to enable implant placement when limited bone is available. Surgical interventions include bone grafts, guided bone regeneration, distraction osteogenesis, sinus floor elevation, and alveolar nerve transposition; tilted, pterygoid, and zygomatic implants have also been developed.<sup>4,5</sup>

Ten Bruggenkate et al<sup>6</sup> introduced the term “short implant” in a study involving 6mm-long osseointegrated implants that were placed and followed for 1 to 7 years.

However, the definition of short and ultra-short implant remains inconsistent in the literature. Classification of any implant as “short” or “ultra-short” requires consideration of the implant’s intra-bone length.<sup>7</sup> In one recent meta-analysis, implants with an intra-bone length between 6 and 9 mm were defined as short, while implants with an intra-bone length less than or equal to 6 mm were defined as ultra-short.<sup>8</sup> Recently, short implants (<8–10 mm long) have been considered a therapeutic alternative for the implant-prosthetic rehabilitation of edentulous jaws that may provide surgical advantages including reduced morbidity, treatment time, and costs.<sup>9,10</sup>

Although the first studies of short implants showed lower success rates than those for standard implants,<sup>11,12</sup> later studies demonstrated success rates similar to those of longer devices,<sup>3,13</sup> as technical innovations in the implant surface and design helped to compensate for the unfavorable crown-to-implant ratio and lower surface available for osseointegration.<sup>14</sup> In recent years, short implants have also been used for

<sup>1</sup> Section of Oral and Maxillofacial Surgery, Department of Surgical Sciences, Dentistry, Gynaecology and Paediatrics, University of Verona, Verona, Italy.

<sup>2</sup> Private practice, Marmirolo, Mantova, Italy.

<sup>3</sup> Department of Biomedical and Neuromotorial Science, University of Bologna, Bologna, Italy.

<sup>4</sup> Department of Dentistry, Vita Salute University, San Raffaele Hospital, Milan, Italy.

\* Corresponding author, e-mail: giuliaricciotti5@gmail.com  
<https://doi.org/10.1563/aaid-joi-D-17-00204>

the rehabilitation of extremely atrophic jaws, with predictable long-term results shown for both short and ultra-short implants.<sup>8,15-18</sup>

The aim of the present study was to investigate the relationship between peri-implant bone loss and crown-implant ratio when ultra-short implants with a micro-rough surface were placed and followed for up to 72 months.

#### MATERIALS AND METHODS

##### Subjects

Inclusion criteria consisted of single, partial, or total edentulism, with a residual bone height of  $\geq 5$  mm in the upper jaw and  $\geq 7$  mm in the lower jaw. Bone width of  $\geq 6$  mm was required, along with a need for rehabilitation with a fixed implant-supported prosthesis. All patients had to accept treatment based on use of ultra-short implants.

Exclusion criteria were poor oral hygiene, heavy smoking ( $>20$  cigarettes/day), alcohol or drug abuse, acute oral infection, American Society of Anesthesiologists physical status classification of IV or V, any history of radiotherapy in the oral maxillofacial area, recent chemotherapy, or pregnancy.

Other situations such as bruxism and clenching; smoking less than 20 cigarettes/day; diabetes; type IV bone (according to Lekholm and Zarb's classification<sup>19</sup>); class IV or V atrophy (according to Cawood and Howell's classification<sup>1</sup>); human immunodeficiency virus; hepatitis C virus; hepatitis B virus; osteoporosis; autoimmune diseases; benign or malign neoplasia; hematologic, hepatic, or kidney diseases; and corticosteroid therapies were not considered as exclusion criteria to evaluate the implant function under these unfavorable conditions.

Following these criteria, patients were enrolled in the study between December 2009 and December 2015. The patients were clearly informed about the nature and aim of the study, and all participants provided written informed consent for the scientific use of their anonymous data. The study was conducted in accordance with ethical guidelines for research on human beings.

All enrolled patients were treated between January 2009 and January 2016 using ultra-short (6 mm long) implants with a microroughened (sandblasted and etched) surface, following standardized surgical procedures.

##### Materials

Two types of implants were used. The first were cylindrical (K implants, WINSIX, BioSAFin, Ancona, Italy) with a sandblasted and etched surface, 6 mm length, and 1 of 2 diameters (4.5 and 5.2 mm). The second type was tapered (TTx implants, WINSIX, BioSAFin, Ancona, Italy), with a sandblasted and etched surface, 6 mm length, and 1 of 3 diameters (3.8, 4.5, and 5.2 mm). All implants had an external hexagon connection and a smooth machined collar of 0.7 mm. All were purchased from the manufacturer by the clinician.

##### Preoperative evaluation

Each patient was clinically and radiographically evaluated. Panoramic or periapical radiographs were taken as a prelimi-

nary measure. In some cases, a cone-beam computerized tomography (CBCT) scan was obtained to facilitate more accurate evaluation of the degree of atrophy and proximity to other anatomical structures. Clinical evaluation consisted of a complete analysis of the oral hygiene and soft-tissue conditions, residual teeth, and other factors that might be relevant for treatment planning.

##### Procedures

Antibiotic prophylaxis was amoxicillin and clavulanic acid, 1 g, 2 times/day for 5 days or azithromycin 600 mg/day for 3 days for patients who were allergic to penicillin. Anti-inflammatory therapy was also administered and consisted of 600 mg of ibuprofen 2 times/day for 3 days, beginning with 1 dose before surgery. Local anesthesia with mepivacaine 2% with epinephrine 1:50 000 was performed at the surgical site, then each patient rinsed with chlorhexidine 0.2% for 2 minutes. Implant insertion was performed in healed sites following a 4-step procedure: elevation of a mucoperiosteal flap, preparation of the implant site, low-speed implant placement, and surgical flap suturing (Figures 1a through c, 2a and b).

The site preparation and implant placement varied depending on the bone density and volume and nearby anatomical structures. An osteotomic technique<sup>20</sup> was employed whenever a sinus lift or augmentation of bone density was needed. When the bone width was insufficient, a combination of standard preparation with drills and the alternative osteotomic technique was adopted. A standard technique described in a previous study<sup>21</sup> was used at sites where the bone volume was adequate, and bone density was Type 1 or 2.

In high-density bone, the site was tapped with drills if K implants were inserted, while drills with progressive diameters were used to insert tapered design (TTx) implants passively. Otherwise, the site was prepared according to the sequence of drills, as per the manufacturer's instructions.

Once the implants were inserted, they were torqued to 25–60 Ncm, cover screws were positioned, and the flaps were passively sutured to favor first intention healing. Patients were instructed to consume a liquid diet in the postsurgical period, maintain good oral hygiene to avoid infections, and rinse twice a day with chlorhexidine 0.2% for 10 days.

To achieve osseointegration, the implants were allowed to heal submerged for 3 to 4 months in the maxilla and 2 to 3 months in the mandible. They were then restored with fixed cemented single crowns or partial prostheses.

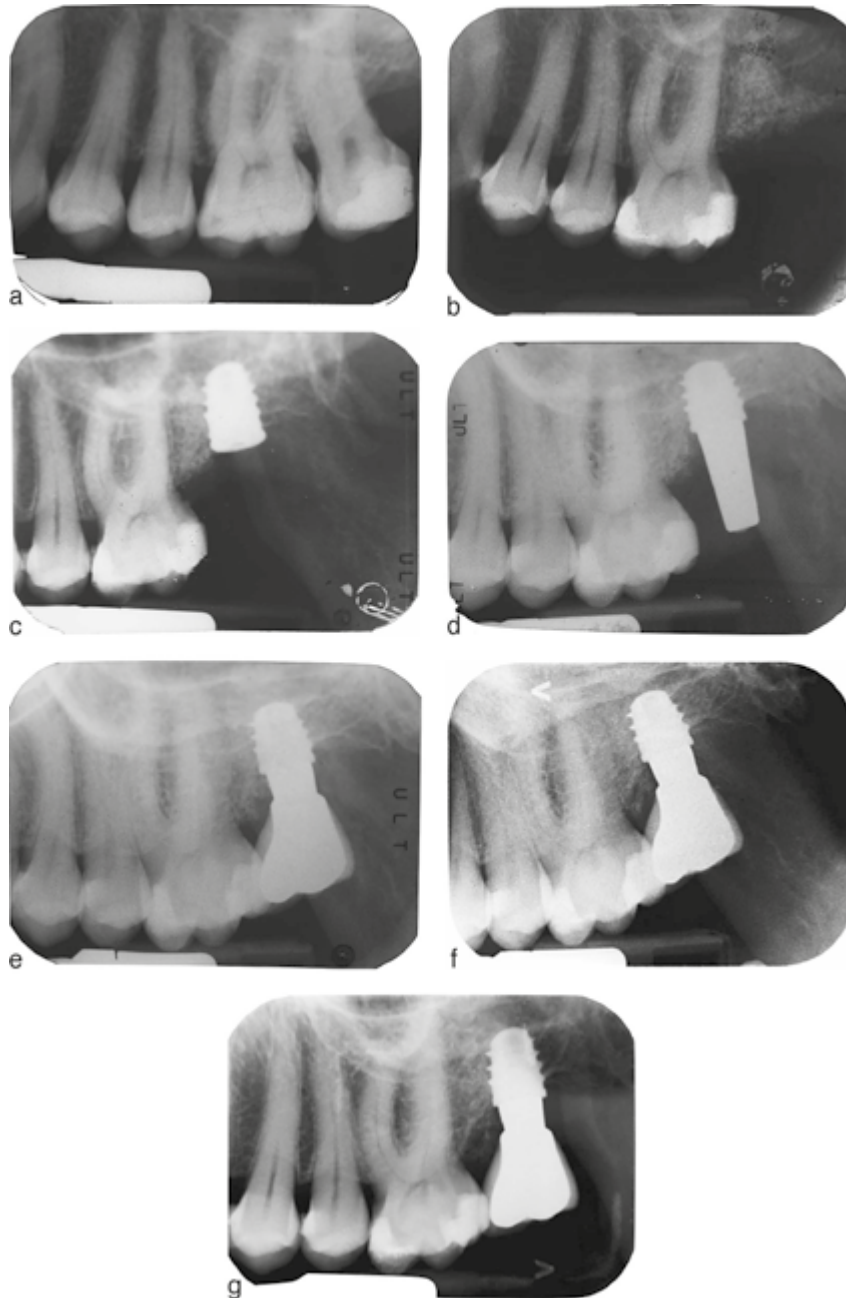
All patients were enrolled in a follow-up program that included professional oral hygiene every 6 months and regular visits during which implants were clinically and radiographically evaluated.

After the 2 to 4 months of healing, the implants were surgically uncovered, and healing screws were positioned, saving as much keratinized tissue as possible.

One week later, functional load was applied (Figures 1d, 2c and d), using the abutment- duplication technique described by Cocchetto et al.<sup>22</sup> This consisted of duplicating the implant portion of a working cast prepared using double-pour or plastic base die systems for single or multiple crowns.

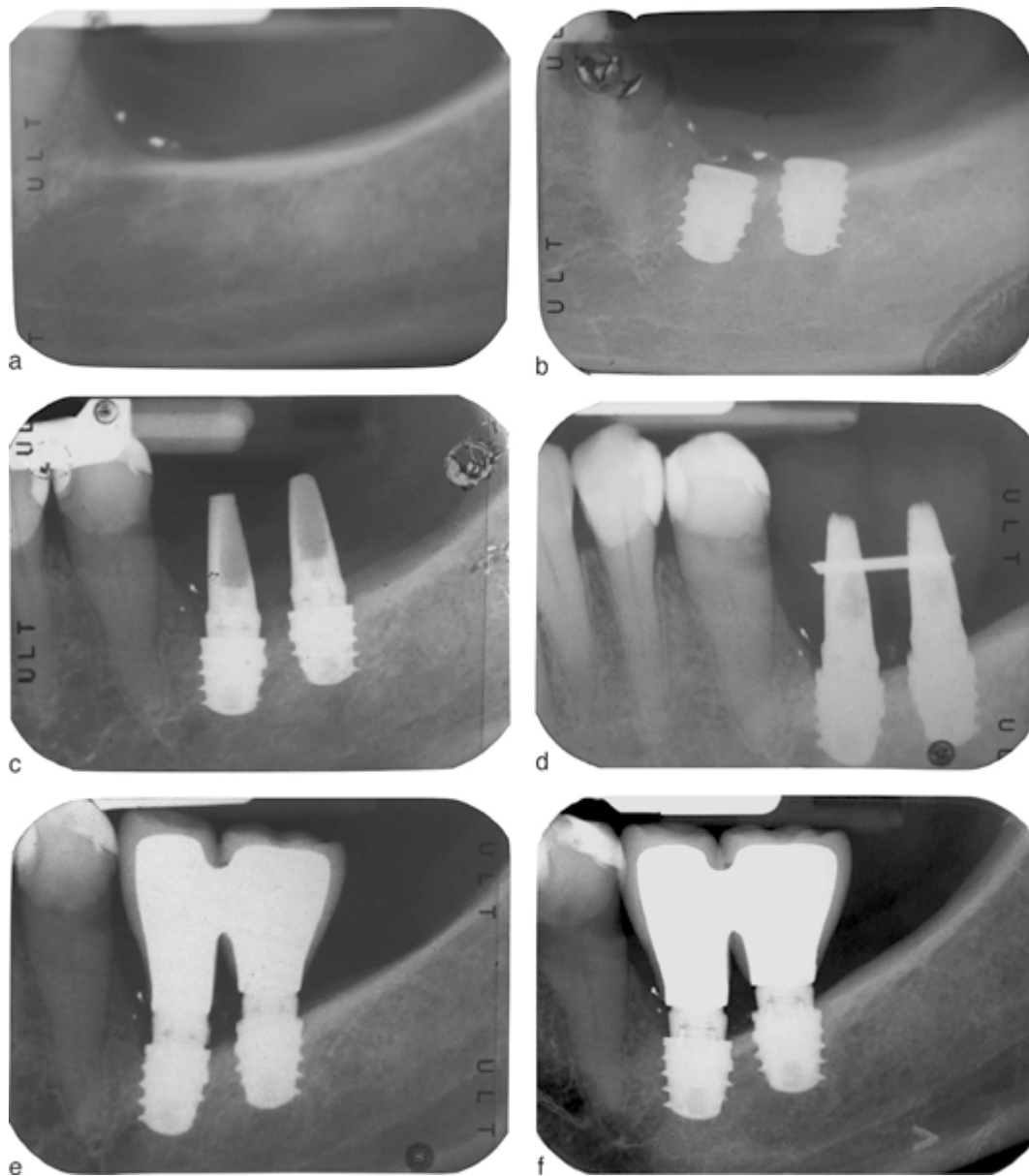
First, an impression of the implant(s) was taken with a

## Biomechanical Evaluation of Ultra-Short Implants: A Prospective Study



**FIGURE 1.** (a) Element #15 has to be extracted for periodontal problems. (b) Preoperative implant site #15. (c) Radiograph after implant surgery. (d) Radiograph after abutment connection. (e) Radiograph at delivery of definitive prosthesis. (f) Radiograph at 3-year follow-up. (g) Radiograph at 4-year follow-up.





**FIGURE 2. CONTINUED.** (a) Preoperative radiograph. (b) Postoperative periapical radiograph. (c) Radiographic examination after abutments connection. (d) Radiographic examination after provisional prosthesis. (e) Periapical radiograph taken at delivery of the definitive fixed dental prosthesis. (f) Radiograph after 3 years of functional load.

pickup technique, to enable fabrication of a master model that precisely captured the implant position(s).

Duplication was achieved using a high-precision addition silicon material and a low-shrinkage polyurethane resin. The duplicated implant abutment was used to finalize the fixed

partial denture restorations after the originals were delivered to the patients, thus reducing time of clinical sessions and avoiding the stress caused by repeated dis- and reconnection of the healing caps. Use of a provisional resin prosthesis helped to condition the tissue adequately and achieve an optimal

## Biomechanical Evaluation of Ultra-Short Implants: A Prospective Study

TABLE 1  
Anatomic distribution according to implant types\*

Jaws	Site	N° K	Freq. (%)	Cum. Freq. (%)	N° TTx	Freq. (%)	Cum. Freq. (%)	Tot. Imp.	Freq. (%)	Cum. Freq. (%)
Maxilla	Up	4	10.3	89.7	2	7.4	92.6	6	9.1	90.9
	Um	21	53.8	53.8	11	40.7	40.7	32	48.5	48.5
Mandible	Lp	4	10.3	100	2	3.7	96.3	5	7.6	98.5
	Lm	10	25.6	79.4	12	44.5	85.2	22	33.3	81.8
	total	39	100	100	27	100	100	66	100	100

\*Um indicates upper molar; Lm, lower molar; Up, upper premolar; Lp, lower premolar; K, cylindrical design; TTx, tapered design.

definitive prosthesis,<sup>23</sup> realized in gold-ceramic, zirconium-ceramic, or chrome-cobalt-ceramic. One to 6 months after delivery of the provisional prosthesis, a cement-retained definitive prosthesis was delivered (Figures 1e, 2e).

All implants were rehabilitated with fixed single crowns or partial bridges. The strict follow-up protocol required each patient to receive professional hygiene care, as well as clinical and radiographic examination 6 months after prosthetic loading and annually thereafter (Figures 1f and g, 2f).

#### Instrumentation/measurement

A database that included all the patients treated in the study was created, and the results were updated in April 2017.

From the radiographs taken at the time of implant insertion (crestal bone level insertion or CBL-ins), implant loading (CBL-bl), and the final follow-up visit (CBL-ctr), CBLs were calculated as the mean value between the mesial and distal CBLs. These were considered to be the distance between the implant shoulder and the first bone-implant contact on the radiograph, using imaging analysis software (ImageJ, National Institutes of Health, NIH, Bethesda, Maryland). Peri-implant bone loss (PBL) was calculated as the difference between the CBL at implant loading (CBL-bl) and the level after the maximum follow-up (CBL-ctr).

Peri-implant soft tissues also were clinically evaluated to detect the presence of mucositis or peri-implantitis. Modified gingival inflammation (mGI), probing pocket depth (PPD), bleeding on probing (BOP), and suppuration (pus) were registered. Any biological or prosthetic complications were recorded in the database.

For all implants, the crown/implant ratio (C/I ratio) was calculated from the radiographs.

This parameter allows us to evaluate the possible relationship between types of prosthetic restoration, PBL, and implant success, as shown in several studies.<sup>15,24-27</sup> Both anatomical and clinical C/I ratios were measured. The former was calculated as the ratio between the prosthetic manufacture length (from the implant shoulder to the top of the crown) and the implant length (6 mm). To obtain the clinical C/I ratio, the first bone-implant contact was considered the separation point between the crown and implant lengths.

Also recorded were the sex and age of all patients at the time of implant insertion, smoking habits (number of cigarettes/day), systemic diseases (diabetes in particular), number of implants inserted and placement site(s), type of antagonist elements (implant prosthesis or natural teeth), implant macro-morphology (K or TTx), implant diameter (3.8, 4.5, or 5.2 mm),

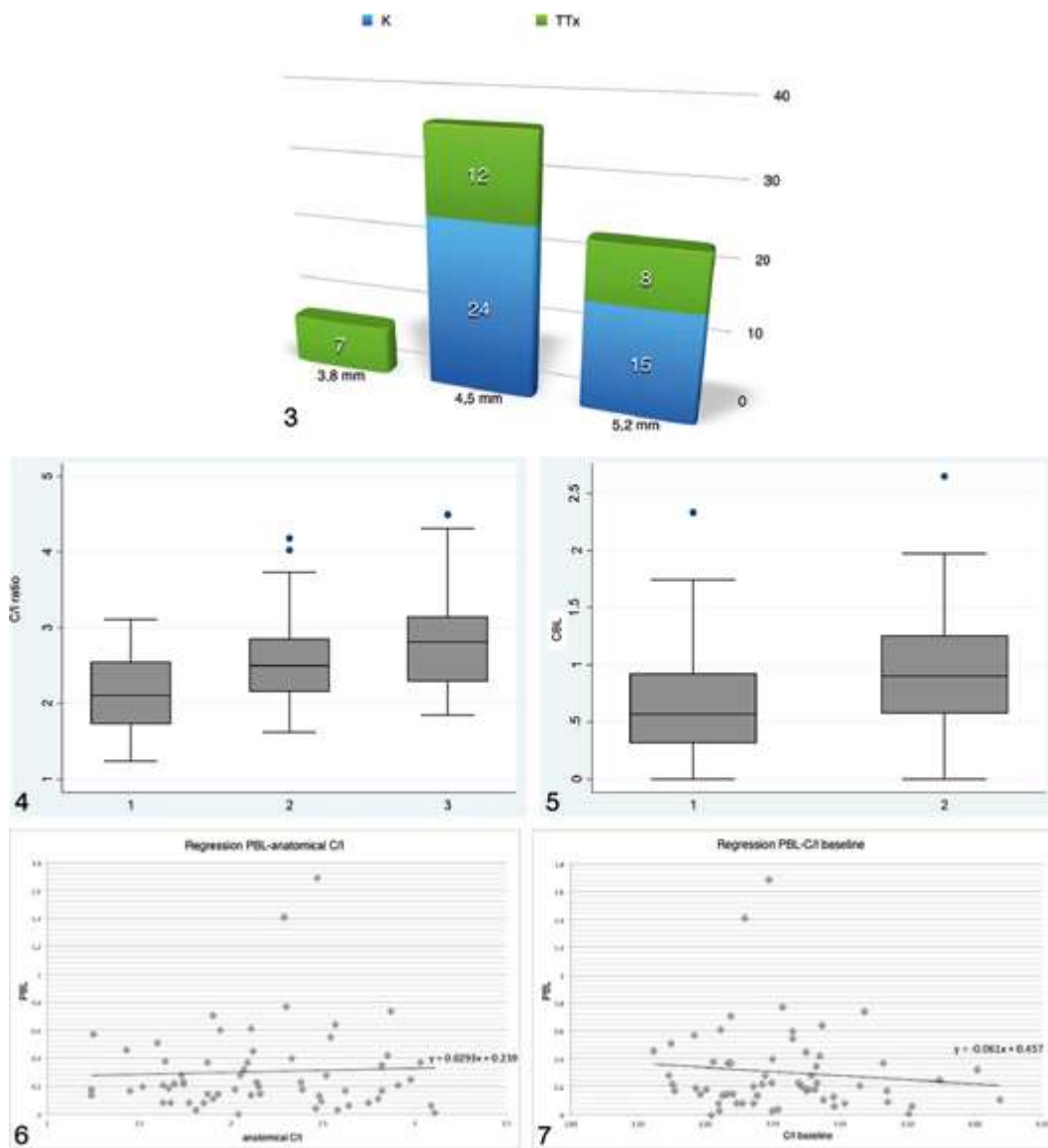
insertion modality, date of insertion and functional loading, time of follow-up, date of any implant failures, prosthesis type (single crown, fixed partial, or full prosthesis), CBL at insertion time (CBL-ins), CBL at baseline (CBL-bl), CBL at the last follow-up control (CBL-ctr), anatomical C/I ratio, clinical C/I ratio at baseline and at the last control, and any prosthetic problems.

Implants that satisfied all criteria enumerated by Buser et al and later modified by Albrektsson and Zarb, were considered successful.<sup>28,29</sup> The criteria were absence of pain, disesthesia, or paresthesia at the implant site; absence of peri-implant infection, with or without suppuration; absence of implant mobility; and absence of more than 1.5 mm of bone loss in the first loading year and 1.2 mm/y after that. The implant survival rate was considered as the percentage of implants still in function at the final follow-up visit, even if not all success criteria were satisfied. It must be noted that when considering short and ultra-short implants, the concepts of survival and success can be correlated; peri-implant bone loss may result in a significant decrease in the osseointegrated portion of the implant, unlike what happens in longer implants.<sup>30,31</sup>

#### Statistical analysis

One blinded statistician was informed about the study design to decide the most adequate statistical analysis. Once data were collected, the same statistician independently performed the following tests. Since more than 1 implant was inserted in some patients, the data collected cannot be considered independent. The authors decided to use nonparametric tests and a generalized estimating equation (GEE) for bivariate and multiple analysis. Statistical tests performed were as follows:

- Wilcoxon-Mann-Whitney nonparametric test to evaluate possible relationships between PBL and other parameters such as sex, upper/lower jaw, diabetes, smoking habits, prosthesis type, antagonistic element, osteotomic technique, and macromorphology
- Wilcoxon nonparametric test to compare peri-implant bone level at baseline (CBL-bl) to CBL at the last visit (CBL-ctr) (paired samples)
- Spearman nonparametric test to analyze the correlation between PBL and different quantitative parameters (anatomical C/I, baseline C/I, age, months of follow-up)
- Kruskal-Wallis test to evaluate the influence of implant diameter and site on PBL
- Bivariate regression analysis with generalized estimating equations to investigate the relationship between anatomical



**FIGURES 3–7.** **FIGURE 3.** Implant diameter distribution. **FIGURE 4.** Box and whiskers plot of crown-to-implant (C/I) ratio (1 = anatomical, 2 = clinical at baseline, 3 = clinical at latest follow-up). **FIGURE 5.** Box and whiskers plot of crestal bone levels (CBL) at baseline (1) and at latest follow-up visit (2). **FIGURE 6.** Bivariate regression analysis with generalized estimating equations to explore the possibility of a relationship between anatomical C/I ratio and peri-implant bone loss (PBL). **FIGURE 7.** Bivariate regression analysis with generalized estimating equations to explore the possibility of a relationship between clinical C/I ratio at loading time (C/I-bl) and PBL.

- ical C/I ratio and PBL or clinical C/I ratio at the time of loading (C/I-bl) and PBL
- Multiple regression analysis with generalized estimating equations to evaluate the correlation between different variables (site, diameter, C/I-bl, anatomical C/I, design) and PBL
- The results were analyzed with the following *P* values: *P* value <.10: 90% significance; *P* value <.05: 95% significance; *P* value

## Biomechanical Evaluation of Ultra-Short Implants: A Prospective Study

TABLE 2

Characteristics of failed implants (design type, diameter, sites, type of prosthesis, clinical C/I ratio, failure time, other information)\*

Implants	Design	Ø (mm)	Site	Prosthesis	Clinical C/I BL	Failure Time	Other Information
1	K	4.5	2.5	—	—	Failure of integration	Heavy smoker
2	TTx	5.2	1.6	—	—	Failure of integration	Same patient of implant n°4, heavy smoker
3	K	5.2	2.6	Partial bridge	2.08	16 mo after loading	—
4	TTx	4.5	3.6	Overdenture	4.48	6 mo after loading	Poor oral hygiene

\*C/I indicates crown-to-implant; BL, bone loss; K, cylindrical design; TTx, tapered design.

<.01; 99% significance. Significance level was fixed at  $P=.05$  for the results of this study.

The statistical tests were performed with Stata 12 software (StataCorp LP, College Station, Tex).<sup>15</sup>

### RESULTS

A total of 47 patients (31 female and 16 male) were included in the study. The mean age at insertion time was  $60 \pm 9$  years (median 63; range 39–81 years). Five patients were affected by diabetes and ten were smokers, 5 of whom smoked more than 10 cigarettes/day.

The 47 patients were treated with a total of 66 implants: 31 subjects received only 1 implant, 13 patients received 2, and 3 patients each received 3 implants. Of the 66 implants, 27 were TTx implants, while 39 were K implants. Thirty-nine implants (59.1%; 14 TTx and 25 K) were placed in the upper jaw, while 27 (40.9%; 13 TTx and 14 K) were placed in the mandible. Table 1 shows the anatomical location of the implants.

Implant diameters ranged from 3.8 mm to 5.2 mm: 7 were 3.8 mm in diameter, 36 were 4.5 mm, and 23 were 5.2 mm (Figure 3). Two implants failed to osseointegrate and were removed before prosthesis delivery, resulting in an osseointegration rate of 96.97%. A total of 64 implants were thus loaded and followed up, according to the pre-established protocol.

During the follow-up period, 2 implants were removed (Table 2), one 6 months after the prosthesis delivery and one during the second year of the follow-up period. Both of these implants showed clinical signs of peri-implantitis. The survival rate for the period between functional loading and the final follow-up appointment was 96.9%.

All 62 implants surviving to the final follow-up visit met the success criteria, resulting in a success rate of 96.9% (equal to the survival rate). The survival and success rates were

respectively 97.3% and 97.3% for maxilla, and 96.3% and 96.3% for mandible.

Mean follow-up for the 62 implants was  $48.5 \pm 19.1$  months (median: 48; range 12–72 months). The distribution of implants according to follow-up time is shown in Table 3.

The mean CBL at different time points is shown in Table 4. The PBL between the baseline (prosthesis delivery) and the last follow-up appointment was  $0.3 \pm 0.3$  mm.

The mean anatomical C/I ratio was  $2.2 \pm 0.5$ . The mean clinical C/I ratio at baseline was  $2.6 \pm 0.6$ , while at the last follow-up, it was  $2.8 \pm 0.6$  (Figure 4).

Regarding the type of prosthesis, the 62 implants were rehabilitated with 37 partial fixed bridges, 11 single crowns, and 1 complete overdenture. In the opposing jaw, the antagonist of the implants most frequently was an implant-supported prosthesis (54.8%); in 45.5% of the cases, it was a natural tooth. No patient had a removable prosthesis.

During the follow-up period, only 2 cases of prosthetic complication (3.1%) were observed (loosening of 2 abutment-implant connection screws).

Statistically significant differences were found between mean CBL measured at baseline and CBL at the latest visit of follow-up ( $P$  value < .0001) (Figure 5).

As reported in Tables 5 and 6, PBL was not influenced by any patient or implant parameters, such as sex, smoking habits, diabetes, type of prosthetic rehabilitation, site, or implant design. No statistically significant influence of other parameters on PBL was observed.

The statistical analysis also did not reveal any significant relationship between anatomical C/I ratio and PBL or between clinical C/I ratio at baseline (C/I-bl) and PBL (Table 6, Figure 6, Figure 7). Correlations between different variables (site, diameter, C/I-bl, anatomical C/I, design) and CBL also were not statistically significant (Table 6).

### DISCUSSION

Different studies have asserted that short implants may represent a possible solution for the rehabilitation of edentulous patients.<sup>32–38</sup> Some randomized controlled trials also have demonstrated that short implants have the same efficacy as longer devices when they are inserted in augmented bone.<sup>32,33</sup> In recent literature, however, only a few studies<sup>39–43</sup> have included ultra-short implants, that is, those with  $\leq 6$  mm length.<sup>8</sup> Moreover, some of the latter studies have had a short follow-up period.<sup>39,42</sup> In contrast, the present study followed a total of 66 ultra-short implants for a mean of 4 years, a more meaningful period for evaluation of survival and success rates

TABLE 3

Distribution of implants according to yearly follow-up time from 12 to 72 months\*

Follow-up (mo)	Implants in Situ	Failed Implants	Failure (%)	CSR %
12–23.9	63	1	1.6	96.8
24–35.9	46	0	0	96.8
36–47.9	41	0	0	96.8
48–59.9	36	0	0	96.8
$\geq 60$	17	0	0	96.8

\*CSR indicates cumulative success rate.

TABLE 4  
Crown-to-implant (C/I) ratio, bone level, bone loss\*

	Anatomical C/I	Clinical C/I (Baseline)	Clinical C/I (Follow-up)	CBL (Surgery)	CBL (Baseline)	CBL (Follow-up)	PBL
Mean ± SD	2.16 ± 0.50	2.57 ± 0.56	2.78 ± 0.62	0.34 ± 0.46	0.68 ± 0.53	0.98 ± 0.54	0.30 ± 0.30
Median (range)	2.11 (1.24-3.11)	2.50 (1.62-4.18)	2.81 (1.85-4.49)	0.10 (0.00-1.91)	0.57 (0.00-2.33)	0.90 (0.00-2.65)	0.21 (0.00-1.69)

\*CBL indicates crestal bone loss; PBL, peri-implant bone loss.

of this kind of implant-prosthetic rehabilitation. Some authors have asserted that major bone loss is observed in the first 12 months after prosthetic loading,<sup>44,45</sup> since during this period the bone-implant interface is more sensitive to stresses.<sup>46</sup>

The success rate in the present study was 96.9%, the same as the survival rate, as calculated from the time of prosthetic delivery to the final follow-up appointment. These values are comparable to those reported in published studies of ultra-short implants, in which the survival rate ranges from 86.7%<sup>47</sup> to 98.0%<sup>43</sup> and the success rate from 93.8%<sup>6</sup> to 97.5%,<sup>18</sup> with variable follow-up (1-10 years) (Table 7).

Some studies have reported a survival rate of less than 80.0%, but almost all included short or ultra-short implants with a machined surface and low roughness.<sup>48-51</sup> The great importance of the micromorphology of these implants for obtaining success and survival rates comparable to those of longer ones is thus evident. The surface of the implants used in the present study has a moderate roughness (Sa = 1.4), which leads to an acceptable risk of peri-implantitis.<sup>52</sup>

In the systematic review of Srinivasan et al of 12 studies published from 1998 and 2011,<sup>53</sup> 6 mm-long implants with a similar surface showed survival rates between 93.7% and 97.6%. Rossi et al<sup>54</sup> published a cohort prospective study in 2015 with 5 years' follow-up in which 40 implants with a sand-blasted surface and 6 mm length were inserted. A survival rate of 95.0% was calculated from insertion to the end of follow-up, while the survival rate was 100.0% from the time of prosthetic loading through follow-up.

Regarding peri-implant bone loss, measured from prosthetic delivery to the last follow-up control visit, values for implants similar to those used in the present study vary considerably, ranging from 0.1 mm after 5 years of follow-up<sup>47</sup>

to 0.2 mm after 3 years of follow-up<sup>43</sup> to up to 0.7 mm at 5 years after prosthetic loading.<sup>54</sup> The results of the present study (mean PBL between surgery and the final follow-up appointment 0.6 ± 0.4 mm; PBL between the baseline or prosthesis delivery and the final follow-up 0.3 ± 0.3 mm) are consistent with the values reported in the literature.

Two implants were lost during the reopening surgery, before prosthetic loading, while 2 others were removed after 6 and 16 months of load respectively. The first two probably failed to osseointegrate, while the failure of the last two was probably due to a lack of osseointegration and peri-implantitis, respectively. Early failure is common when short and ultra-short implants are used, with many authors reporting similar results.<sup>7,25,53</sup>

In some studies, a higher failure percentage is reported for implants placed in the posterior upper jaw, because of the low bone density and high chewing forces in this area.<sup>20,53,55,56</sup> Renouard and Nisand suggested that surgical preparation, which conforms to bone quality and rough implant surfaces, and careful patient selection were necessary to obtain comparable survival rates for short or longer implants.<sup>3</sup> The importance of site preparation for short implants that takes into

TABLE 5  
Statistical analysis of the relation between peri-implant bone loss and other parameters

Variable	P Value
Sex	.5275
Smoking habits	.4925
Diabetes	.5285
Opposite elements	.3115
Splint/single crown	.0847
Alternative osteotomic technique	.6034
Implant design	.7466
Site (upper/lower jaw)	.4666
Diameter	.1542
Site	.3659
Diameter	.1542
Site	.3659

TABLE 6  
Statistical analysis of the relationship between peri-implant bone loss (PBL) and other parameters (implant diameter, patient age, months of follow-up, and anatomical and clinical crown-to-implant [C/I] ratio). Moreover, correlation between anatomical C/I ratio and PBL and between clinical C/I ratio at loading time (C/I-bl) and PBL; finally, correlation between crestal bone levels and anatomical and clinical C/I ratio, implant diameter, and sites\*

	Spearman's Coefficient	P Value
PBL : diameter	0.187	.146
PBL : age	0.098	.450
PBL : months of follow-up	-0.025	.846
PBL : anatomical C/I	-0.027	.837
PBL : clinical C/I (BL)	-0.102	.429
PBL : anatomical C/I	0.029	.666
PBL : clinical C/I (BL)	-0.061	.195
PBL : Anatomical C/I	0.197	.083
PBL : Clinical BL C/I	-0.173	.144
PBL : Diameter	-0.005	.953
PBL : Up	0.263	.238
PBL : Lp	0.125	.190
PBL : Um	0.074	.446
PBL : Lm	0.137	.182

\*BL indicates bone loss; Up, upper premolar; Lp, lower premolar; Um indicates upper molar; Lm, lower molar.

## Biomechanical Evaluation of Ultra-Short Implants: A Prospective Study

TABLE 7  
Literature about short and ultra-short implants, regarding follow-up, peri-implant bone loss (PBL), survival rates (SSR), and success rates (SR)

Studies	Length (mm)	Follow-up (y)	PBL (mm)	SSR (Load)	SSR (Surgery)	SR
Ten Bruggenkate et al <sup>6</sup>	6	6	-	-	97%	93.8%
Friberg et al <sup>34</sup>	6-7	10	0.9 ± 0.6	-	92.3%	-
Renouard and Nisand <sup>35</sup>	6-8.5	2-3	0.44 ± 0.52	-	94.6%	-
Arlin <sup>39</sup>	6	2	-	-	-	94.3% (surgery)
Misch et al <sup>63</sup>	7-9	1-5	-	100%	98.9%	100% (load)
Malò et al <sup>36</sup>	7-8.5	1-9	1.8 ± 0.8 (7 mm)	-	96.2% (7 mm)	98.1% (7 mm)
Deporter et al <sup>41</sup>	5	1-8	-	-	92.3%	-
Fugazzotto <sup>37</sup>	6-9	6-7	-	-	-	98%
Lai et al <sup>38</sup>	≤8	5-10	0.63 ± 0.68	-	97% (6 mm)	-
Rossi et al <sup>47</sup>	6	5	0.7 ± 0.6	100%	95%	-
Rossi et al <sup>54</sup>	6-10	5	0.14	90%	86.7%	-
Malchiodi et al <sup>15,64</sup>	5-7	3	0.48 ± 0.29	98.1%	-	98.1%
Malchiodi et al <sup>21</sup>	6	2-3	0.44 ± 0.72	100%	97%	97.1% (load) 94.1% (surgery)
Anitua et al <sup>16</sup>	≤8.5	10	1 ± 0.7 M 0.9 ± 0.6 D	98.9%	98.9%	98.9%
Slotte et al <sup>40</sup>	4	5	0.53 ± 0.08	92.2%	-	-
Calvo-Guirardo et al <sup>42</sup>	4-10	1	0.71 ± 0.11 (4 mm)	-	97.5%	97.5% (surgery)
Sahrman et al <sup>43</sup>	6-10	3	0.0.62 (6 mm)	98% (6 mm)	98% (6 mm)	-
Present study	6	1-6	0.30 ± 0.30	93.9%	96.9%	96.9%

consideration the bone density also was stressed by Annibali et al in another systematic review.<sup>14</sup>

In the present study, an alternative osteotomic technique<sup>20</sup> was adopted when the bone density was low, while sites were tapped when bone showed greater density, to limit the complications connected to inadequate primary stability. This surgical approach permitted placement of both types of implants, with different macro-morphologies, in the upper and lower jaws. The two different designs yielded similar results for crestal bone levels and peri-implant bone loss.

The authors did pay great attention to guaranteeing the presence of at least 1-1.5 mm of bone thickness around each implant, both at the vestibular and lingual/palatal aspects. This was obtained by the choice of implant diameter, adaptation of the site preparation, and decision regarding implant placement depth.

An important consideration when using short and ultra short implants in atrophic jaws is the unfavorable C/I ratio. An increase of prosthetic complications, such as loosening of the abutment-implant screw, has been associated with such ratios.<sup>57</sup>

In the present study, however, only 2 cases of screw loosening were recorded throughout the follow-up period. Screw loosening typically is due to the progressive increase in stress at the implant-abutment interface, which induces a decrease of the preloading torque. This mechanism leads to the creation of a gap between the implant and abutment interface and detrimental rotational movement.<sup>58</sup> In the present study, the prosthetic protocol (strictly controlled torque when tightening the abutment-implant screws and use of the abutment-duplication technique<sup>17</sup>) optimized the implant-abutment connection and resulted in a very low number of complications.

Another consequence of an increase in the C/I ratio is the risk of overloading and consequent loss of crestal bone. The

presence of a correlation between peri-implant bone loss and C/I ratio is still a controversial question in literature. A study published by Malchiodi et al<sup>15</sup> investigated the possible relationship between C/I ratio, implant success rate, and bone loss. One hundred fifty-one patients received 280 implants with a sintered porous surface. In 27% of cases, 5 mm-length implants were inserted and monitored for 36 months. The mean anatomical C/I ratio was  $1.8 \pm 0.7$  (range: 0.9-4.3), while the mean clinical C/I ratio at baseline measured  $2.1 \pm 0.8$  (range: 1.0-4.8). The results showed a positive correlation between C/I ratio and bone loss ( $P < .001$ ).

Tawil et al<sup>59</sup> analyzed 262 short implants, divided into different groups according to C/I ratios (ranging from  $<1$  to  $>2$ ). Peri-implant bone loss was measured in the different groups to identify any potential influence of this prosthetic parameter on the implants' survival rate. No significant difference could be found among the various groups with respect to peri-implant bone loss ( $P = .150$ ). The authors concluded that increased C/I values do not seem to be a major risk factor in cases of favorable loading.

A recent systematic review analyzed 13 scientific articles and found an inverse correlation between C/I ratio and crestal bone loss, with a possible protective effect of high C/I ratios on bone levels.<sup>27</sup> According to Blanes et al,<sup>24</sup> there is not sufficient data in the literature to prove a positive or negative effect of C/I ratio on the rates of success and prosthetic complications. In a cohort retrospective study, Birdi et al examined 309 ultra-short implants with a mean follow-up of about 21 months. They concluded that C/I ratio does not influence peri-implant bone loss or implant success.<sup>26</sup>

Ghariani et al obtained similar results 1 year after prosthetic loading.<sup>60</sup> The results of the present study agree with these publications, since a statistically significant correlation between C/I ratio and crestal bone loss was not found. The lack of statistical significance may be a result of the low number of



implants analyzed in the present study. Nevertheless, for realization of a long-term successful implant-supported rehabilitation, it is important to avoid overloading during function. Crown length thus should be limited.<sup>61</sup>

As for the biomechanical behavior of osseointegrated implants, different studies have demonstrated that the use of splinted implants can be an advantage for the success of implant rehabilitation, because the splinting better distributes chewing forces.<sup>62,63</sup>

High success rates have been reported after 3 to 5 years of follow-up for short implant rehabilitations with single crowns by many publications in recent years.<sup>38,43,54</sup>

In one systematic review, the authors reported a high cumulative success rate for short implants supporting both single crowns and partial fixed bridges.<sup>14</sup> Similarly, in the present study, no statistical differences were observed in peri-implant bone loss between ultra-short implants supporting single crowns and those supporting partial fixed bridges.

Although the results reached in the present study are encouraging, additional studies that include more implants should be undertaken to draw more reliable conclusions. Moreover, longer follow-up (more than 5 years) is preferable to analyze the biomechanical and biological behavior of ultra-short implants over the long term. More comparative studies that investigate the efficacy of shorts and ultra-shorts implants with different C/I ratios are needed.<sup>15,21,64,65</sup>; only 1 study is published about the role of C/I ratio with different implant length.<sup>66</sup>

#### CONCLUSIONS

This study confirmed that ultra-short implants with a micro-roughened surface can be a viable solution for rehabilitating single or partial edentulism in posterior atrophic areas. Stable crestal bone levels and a high implant success rate confirm the predictability of this kind of implant-prosthetic rehabilitation. A high C/I ratio did not appear to influence either peri-implant bone loss or prosthetic complication rates.

#### ABBREVIATIONS

BOP: bleeding on probing  
C/I: crown-to-implant  
CBCT: cone-beam computed tomographic  
CBL: crestal bone levels  
CBL-bl: crestal bone levels at implant loading  
CBL-ctr: crestal bone levels at the final follow-up visit  
CBL-ins: crestal bone levels at the time of implant insertion  
GEE: generalized estimating equation  
mGI: modified gingival inflammation  
PBL: peri-implant bone loss  
PPD: probing pocket depth

#### NOTE

The authors have no financial interest in any company or in any of the products mentioned in this article.

#### REFERENCES

1. Cawood JI, Howell RA. A classification of the edentulous jaw. *Int J Oral Maxillofac Surg.* 1988;17:232–236.
2. Frost HM. A 2003 update of bone physiology and Wolff's Law for Clinicians. *Angle Orthod.* 2004;74:3–15.
3. Renouard F, Nisand D. Impact of implant length and diameter on survival rates. *Clin Oral Imp Res.* 2006;17:35–51.
4. Ali SA, Karthigeyan S, Deivanai M, Kumar A. Implant rehabilitation for atrophic maxilla: a review. *J Indian Prosthodont Society* 2014;14:196–207.
5. Nocini PF, D'Agostino A, Chiarini L, Trevisiol L, Procacci P. Simultaneous Le Fort I osteotomy and zygomatic implants placement with delayed prosthetic rehabilitation. *J Craniofac Surg.* 2014;25:1021.
6. Ten Bruggenkate C, Asikainen P, Foitzik C, Krekeler G, Sutter F. Short (6-mm) non-submerged dental implants. Results of a multicenter clinical trial of 1 to 7 years. *Int J Oral Maxillofac Implants.* 1998;13:791–798.
7. Neldam CA, Pinholt EM. State of the art of short dental implants: a systematic review of the literature. *Clin Implant Dent Relat Res.* 2012;14:622–632.
8. Monje A, Fu JH, Chan HL, et al. Do implant length and width matter for short dental implants (6–9 mm)? A meta-analysis of prospective studies. *J Periodontol.* 2013;84:1–15.
9. Esposito M, Pellegrino G, Pistilli R, Felice P. Rehabilitation of posterior atrophic edentulous jaws: prostheses supported by 5 mm short implants or by longer implants in augmented bone? One-year results from a pilot randomised clinical trial. *Eur J Oral Implantol.* 2011;4:21–30.
10. Nisand D, Renouard F. Short implant in limited bone volume. *Periodontol.* 2000 2014;66:72–96.
11. Bahat O. Treatment planning and placement of implants in the posterior maxillae: report of 732 consecutive Nobel-pharma implants. *Int J Oral Maxillofac Implants.* 1993;8:151–161.
12. Wyatt CCL, Zarb GA. Treatment outcomes of patients with implant-supported fixed partial prostheses. *Int J Oral Maxillofac Implants.* 1998;13:204–211.
13. Misch CE. Short dental implants: a literature review and rationale for use. *Dent Today.* 2005;24:64–68.
14. Annibaldi S, Cristalli MP, Dell'Aquila D, Bignozzi I, La Monaca G, Pilloni A. Short dental implants: a systematic review. *J Dent Res.* 2012;91:25–32.
15. Malchiodi L, Cucchi A, Ghensi P, Consonni D, Nocini PF. Influence of crown-implant ratio on implant success rates and crestal bone levels: a 36-month follow-up prospective study. *Clin Oral Implants Res.* 2014;25:240–251.
16. Anitua E, Piñas L, Begoña L, Orive G. Long-term retrospective evaluation of short implants in the posterior areas: clinical results after 10-12 years. *J Clin Periodontol.* 2014;41:404–411.
17. Deporter D, Ogiso B, Sohn DS, Ruljancich K, Pharoah M. Ultrashort sintered porous-surfaced dental implants used to replace posterior teeth. *J Periodontol.* 2008;79:1280–1286.
18. Calvo-Guirado JL, López Torres JA, Dard M, et al. Evaluation of extrashort 4-mm implants in mandibular edentulous patients with reduced bone height in comparison with standard implants: a 12-month results. *Clin Oral Implants Res.* 2016;27:867–874.
19. Lekholm U, Zarb GA. Patient selection and preparation. In: Branemark PI, Zarb GA, Albrektsson T, eds. *Tissue Integrated Prostheses: Osseointegration in Clinical Dentistry.* Chicago: Quintessence Publishing Company; 1985:199–209.
20. Malchiodi L, Cucchi A, Ghensi P, Caricasulo R, Nocini PF. The 'Alternating Osteotome Technique': a surgical approach for combined ridge expansion and sinus floor elevation. A multicentre prospective study with a three-year follow-up. *Biotechnol Biotechnol Equip.* 2016;30:762–769.
21. Malchiodi L, Caricasulo R, Cucchi A, Vinci R, Agliardi E, Gherlone E. Evaluation of ultrashort and longer implants with microrough surfaces: results of a 24- to 36-month prospective study. *Int J Oral Maxillofac Implants.* 2017;32:171–179.
22. Cocchetto R, Resch I, Castagna M, Vincenzi G, Celletti R. The abutment duplication technique: a novel protocol for cementable implant-supported restoration. *Int J Periodontics Restorative Dent.* 2010;30:415–424.
23. Fradeani M, Bottachiarri MS, Tracey T, Parma-Benfenati S, Stein JM, De Paoli S. The restoration of functional occlusion and esthetics. *Int J Periodontics Restorative Dent.* 1992;12:63–71.
24. Blanes RJ. To what extent does the crown-implant ratio affect the survival and complications of implant-supported reconstructions? A systematic review. *Clin Oral Implants Res.* 2009;20:67–72.
25. Rossi F, Ricci E, Marchetti C, Lang NP, Botticelli D. Early loading of

## Biomechanical Evaluation of Ultra-Short Implants: A Prospective Study

- single crowns supported by 6-mm-long implants with a moderately rough surface: a prospective 2-year follow-up cohort study. *Clin Oral Implants Res.* 2010;21:937–943.
26. Birdi H, Kovacs J, Schulte A, Weed M, Chuang S-K. Crown-to-implant ratios of short-length implants. *J Oral Implantol.* 2010;36:425–433.
27. Garaicoa-Pazmiño C, Suárez-López del Amo F, Monje A, et al. Influence of crown/implant ratio on marginal bone loss: a systematic review. *J Periodontol.* 2014;85:1214–1221.
28. Buser D, Weber HP, Bragger U, Baisiger C. Tissue integration of one-stage implants: 3-year results of a prospective longitudinal study with hollow cylinder and hollow screw implants. *Quintessence Int.* 1994;25:679–686.
29. Albrektsson T, Zarb GA. Determinants of correct clinical reporting. *Int J Prosthodont.* 1998;11:517–521.
30. Neldam CA, Pinholt EM. State of the art of short dental implants: a systematic review of the literature. *Clin Implant Dent Relat Res.* 2012;14:622–632.
31. Chiapasco M. *Manuale Illustrato di Chirurgia Orale.* Edra Masson; 2013.
32. Esposito M, Barausse C, Pistilli R, Sammartino G, Grandi G, Felice P. Short implants versus bone augmentation for placing longer implants in atrophic maxillae: one-year post-loading results of a pilot randomised controlled trial. *Eur J Oral Implantol.* 2015;8:257–268.
33. Felice P, Cannizzaro G, Barausse C, Pistilli R, Esposito M. Short implants versus longer implants in vertically augmented posterior mandibles: a randomised controlled trial with 5-year after loading follow-up. *Eur J Oral Implantol.* 2014;7:359–369.
34. Friberg B, Grondahl K, Lekholm U, Branemark PI. Long-term follow-up of severely atrophic edentulous mandibles reconstructed with short Branemark implants. *Clin Implant Dent Relat Res.* 2000;2:184–189.
35. Renouard F, Nisand D. Short implants in the severely resorbed maxilla: a 2-year retrospective clinical study. *Clin Implant Dent Relat Res.* 2005;7:104–110.
36. Maló P, de Araújo Nobre M, Rangert B. Short implants placed one-stage in maxillae and mandibles: a retrospective clinical study with 1 to 9 years of follow-up. *Clin Implant Dent Relat Res.* 2007;9:15–21.
37. Fugazzotto PA. Shorter implants in clinical practice: rationale and treatment results. *Int J Oral Maxillofac Implants.* 2008;23:487–496.
38. Lai H-C, Si M-S, Zhuang L-F, Shen H, Liu Y, Wismeijer D. Long-term outcomes of short dental implants supporting single crowns in posterior region: a clinical retrospective study of 5-10 years. *Clin Oral Implants Res.* 2013;24:230–237.
39. Arlin ML. Short dental implants as a treatment option: results from an observational study in a single private practice. *In J Oral Maxillofac Implants.* 2006;21:769–776.
40. Slotte C, Grønningaeter A, Halmøy AM, et al. Four-millimeter-long posterior-mandible implants: 5-year outcomes of a prospective multicenter study. *Clin Implant Dent Relat Res.* 2015;17:385–395.
41. Deporter D, Ogiso B, Sohn DS, Ruljancich K, Pharoah M. Ultrashort sintered porous-surfaced dental implants used to replace posterior teeth. *J Periodontol.* 2008;79:1280–1286.
42. Felice P, Checchi L, Barausse C, et al. Posterior jaws rehabilitated with partial prostheses supported by 4.0 × 4.0 mm or by longer implants: one year post-loading results from a multicenter randomised controlled trial. *Eur J Oral Implantol.* 2016;9:35–45.
43. Sahrman P, Naenni N, Jung RE, et al. Success of 6-mm implants with single-tooth restorations: a 3-year randomized controlled clinical trial. *J Dent Res.* 2016;95:623–628.
44. Lindquist LW, Carlsson GE, Jemt T. A prospective 15-year follow-up study of mandibular fixed prostheses supported by osseointegrated implants. Clinical results and marginal bone loss. *Clin Oral Implants Res.* 1996;7:329–336.
45. Manz MC. Factors associated with radiographic vertical bone loss around implants placed in a clinical study. *Ann Periodontol.* 2000;5:137–151.
46. Raghavendra S, Wood MC, Taylor DT. Early wound healing around endosseous implants: a review of the literature. *Int J Oral Maxillofac Implants.* 2005;20:425–431.
47. Rossi F, Botticelli D, Cesaretti G, De Santis E, Storelli S, Lang NP. Use of short implants (6 mm) in a single-tooth replacement: a 5-year follow-up prospective randomized controlled multicenter clinical study. *Clin Oral Implants Res.* 2016;27:458–464.
48. Jemt T, Lekholm U. Implant treatment in edentulous maxillae: a 5-years follow-up report on patients with different degrees of jaw resorption. *Int J Oral Maxillofac Implants.* 1995;10:303–311.
49. Hermann I, Lekholm U, Holm S, Kultje C. Evaluation of patient and implant characteristics as potential prognostic factor for oral implant failures. *Int J Oral Maxillofac Implants.* 2005;20:220–230.
50. Weng D, Jacobson Z, Tarnow D. A prospective multicenter clinical trial of 3i machined-surfaced implants: results after 6 years of follow-up. *Int J Oral Maxillofac Implants.* 2003;18:417–423.
51. Winkler S, Morris HF, Ochi S. Implant survival to 36 months as related to length and diameter. *Ann Periodontol.* 2000;5:22–31.
52. Wennerberg A, Albrektsson T. Effects of titanium surface topography on bone integration: a systematic review. *Clin Oral Implants Res.* 2009;20:172–184.
53. Srinivasan M, Vazquez L, Riede P, Moraguez O, Bernard J-P, Belsler UC. Survival rates of short (6mm) micro-rough surface implants: a review of literature and meta-analysis. *Clin Oral Implants Res.* 2014;25:1–7.
54. Rossi F, Lang NP, Ricci E, Ferraioli L, Marchetti C, Botticelli D. Early loading of 6-mm-short implants with a moderately rough surface supporting single crowns—a prospective 5-year cohort study. *Clin Oral Implants Res.* 2015;26:471–477.
55. Cochran DL. A comparison of endosseous dental implant surfaces. *J Periodontol.* 1999;70:1523–1539.
56. Rocuzzo M, Bunini M, Prioglio F, Bianchi SD. Early loading of sandblasted and acid-etched (SLA) implants: a prospective slit-mouth comparative study. *Clin Oral Implants Res.* 2001;12:572–578.
57. Gracis S, Michalakis K, Vigolo P, Vult von Steyern P, Zwahlen M, Sailer I. Internal vs. external connections for abutments/reconstructions: a systematic review. *Clin Oral Implants Res.* 2012;23:202–216.
58. Bedini R, Ippolito P, Pecci R, Rizzo F, Quaranta M. Studio in vitro sulla connessione di sistemi implantari dentali. *Rapporti ISTISAN 07/7 2007;* 26:1–26.
59. Tawil G, Aboujaoude N, Younan R. Influence of prosthetic parameters on the survival and complication rates of short implants. *Int J Oral Maxillofac Implants.* 2006;21:275–282.
60. Ghariani L, Segaan L, Rayyan MM, Galli S, Jimbo R, Ibrahim A. Does crown/implant ratio influence the survival and marginal bone level of short single implants in the mandibular molar? A preliminary investigation consisting of 12 patients. *J Oral Rehabil.* 2016;43:127–135.
61. Anitua E, Alkhraist MH, Piñas L, Begoña L, Orive G. Implant survival and crestal bone loss around extra-short implants supporting a fixed denture: the effect of crown height space, crown-to-implant ratio, and offset placement of the prosthesis. *Int J Oral Maxillofac Implants.* 2014;29:682–689.
62. Pellizzer EP, de Mello CC, Santiago Junior JF, de Souza Batista VE, de Faria Almeida DA, Verri FR. Analysis of the biomechanical behavior of short implants: the photo-elasticity method. *Mater Sci Eng C Mater Biol Appl.* 2015; 55:187–192.
63. Misch CE, Steigegna J, Barboza E, Misch-Dietsh F, Cianciola LJ, Kazor C. Short dental implants in posterior partial edentulism: a multicenter retrospective 6-year case series study. *J Periodontol.* 2006;77:1340–1347.
64. Malchioldi L, Ghensi P, Cucchi A, Pieroni S, Bertossi D. Peri-implant conditions around sintered porous-surfaced (SPS) implants. A 36-month prospective cohort study. *Clin Oral Implants Res.* 2015;26:212–219.
65. Rokni S, Todescan R, Watson P, Pharoah M, Adegbenbo AO, Deporter D. An assessment of crown-to-root ratios with short sintered porous-surfaced implants supporting prostheses in partially edentulous patients. *Int J Oral Maxillofac Implants.* 2005;20:69–76.
66. Felice P, Checchi L, Barausse C, et al. Posterior jaws rehabilitated with partial prostheses supported by 4.0 × 4.0 mm or by longer implants: one-year post-loading results from a multicenter randomised controlled trial. *Eur J Oral Implantol.* 2016;9:35–45.

Pellegrino et al. *BMC Oral Health* (2019) 19:158  
<https://doi.org/10.1186/s12903-019-0853-y>

BMC Oral Health

CASE REPORT

Open Access

# Augmented reality for dental implantology: a pilot clinical report of two cases



Gerardo Pellegrino<sup>1\*</sup>, Carlo Mangano<sup>2</sup>, Roberto Mangano<sup>3</sup>, Agnese Ferri<sup>1</sup>, Valerio Taraschi<sup>4</sup> and Claudio Marchetti<sup>5</sup>

## Abstract

**Background:** Despite the limited number of articles dedicated to its use, augmented reality (AR) is an emerging technology that has shown to have increasing applications in multiple different medical sectors. These include, but are not limited to, the Maxillo-facial and Dentistry disciplines of medicine. In these medical specialties, the focus of AR technology is to achieve a more visible surgical field during an operation. Currently, this goal is brought about by an accurate display of either static or dynamic diagnostic images via the use of a visor or specific glasses. The objective of this study is to evaluate the feasibility of using a virtual display for dynamic navigation via AR. The secondary outcome is to evaluate if the use of this technology could affect the accuracy of dynamic navigation.

**Case presentation:** Two patients, both needing implant rehabilitation in the upper premolar area, were treated with flapless surgery. Prior to the procedure itself, the position of the implant was virtually planned and placed for each of the patients using their previous scans. This placement preparation contributed to a dynamic navigation system that was displayed on AR glasses. This, in turn, allowed for the use of a computer-aided/image-guided procedure to occur. Dedicated software for surface superimposition was then used to match the planned position of the implant and the real one obtained from the postoperative scan. Accuracies, using this procedure were evaluated by way of measuring the deviation between real and planned positions of the implants. For both surgeries it was possible to proceed using the AR technology as planned. The deviations for the first implant were 0.53 mm at the entry point and 0.50 mm at the apical point and for the second implant were 0.46 mm at the entry point and 0.48 mm at the apical point. The angular deviations were respectively 3.05° and 2.19°.

**Conclusions:** From the results of this pilot study, it seems that AR can be useful in dental implantology for displaying dynamic navigation systems. While this technology did not seem to noticeably affect the accuracy of the procedure, specific software applications should further optimize the results.

**Keywords:** Computer-assisted surgery, Image-guided surgery, Implantology, Navigation system, Real-time tracking, Implant placement accuracy

## Background

Computer-assisted procedures are becoming more and more integrated into different fields of dentistry [1]. This is particularly evident in the increasing use of processes such as 3D printing and CAD-CAM methods in the manufacturing of dental implantology. This has not only allowed for a more accurate and diverse manufacturing capability but also dramatically expands on the production surgical templates often made in-house.

Currently, the examination of static guided surgery as a means of creating surgical templates to accurately position implants is ample. The conclusion drawn from this research is that should the implant be inserted with a margin of error of approximately 1 mm, the implant rehabilitation process will be mostly successful [2]. However, the working time for planning and producing the surgical template do not encourage or justify an ordinary use of this method [3]. Another method for computer-assisted surgery in dental implantology is image-guided surgery through dynamic navigation. Such surgical techniques are already largely used in major Neurosurgery, Maxillo-facial surgery, ORL, and Orthopedic surgeries and is quickly becoming popular in Implantology. Some

\* Correspondence: [gerardo.pellegrino2@unibo.it](mailto:gerardo.pellegrino2@unibo.it)

<sup>1</sup>Oral and Maxillofacial Surgery Unit, DIBINEM, University of Bologna, 125, Via San Vitale 59, 40125 Bologna, Italy  
Full list of author information is available at the end of the article



© The Author(s). 2019 **Open Access** This article is distributed under the terms of the Creative Commons Attribution 4.0 International License (<http://creativecommons.org/licenses/by/4.0/>), which permits unrestricted use, distribution, and reproduction in any medium, provided you give appropriate credit to the original author(s) and the source, provide a link to the Creative Commons license, and indicate if changes were made. The Creative Commons Public Domain Dedication waiver (<http://creativecommons.org/publicdomain/zero/1.0/>) applies to the data made available in this article, unless otherwise stated.

papers published in past years report on the comparable accuracy between dynamic and static surgical navigation [4–6]. It was shown that dynamic navigation could overcome some of the disadvantages associated with static guided surgery. These included reducing costs and time needed for the impression and laboratory procedures of a static guided system. Another advantage of a dynamic guided system could be the ability to have a direct view of the surgical field as well as the possibility to use standard drills which is optimal in a case of mouth opening reduction [7]. In addition to this, dynamic navigation allows for changes in implant planning to be made at the time of surgery. This level of flexibility is not offered by statically derived surgical guides as they are fixed and cannot be altered once they are planned and manufactured. Also, tight single-tooth edentulous ridge areas can be fully guided using dynamic guidance as a dynamic guide is not restricted by drill tube size (i.e. in the anterior mandibular incisor sites). Furthermore, implant size is not limited with dynamically guided systems, as they are with static guides and CBCT; planning and surgery can be achieved in a single day [1, 8, 9].

However, a possibly problematic disadvantage of a dynamic guided system is the need to simultaneously pay attention to the patient as well as the output from the navigation system display. This unfavourable feature is exacerbated in systems where the tracking device is positioned on the same mobile carriage as the navigation system display. This could cause difficulties in following the virtual procedure while also keeping sight of the surgical site itself [10]. Systems that use a mobile screen fixed near the patient's head on the dental chair may address this issue as they limit the movement of the surgeon's head and, therefore, their loss of sight of the surgical site [11].

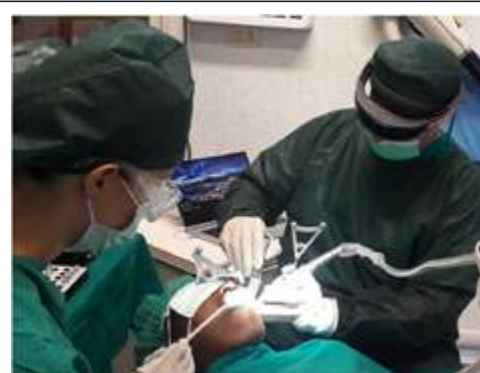The use of AR through specific glasses and an integrated screen is a fairly new trend in the field of medicine. This technology can allow the surgeon to visualize, in real-time, patient parameters, relevant x-rays, 3D reconstruction or a navigation system screen [12, 13]. This last item could significantly increase the use of dynamic navigation a process that has already been readily adopted in other major surgical disciplines. The use of these devices is currently under validation and only few publications are present in literature to date and even fewer papers investigate this technology in dentistry [10, 14]. The aim of our pilot study is to evaluate the feasibility of adopting AR as a means of facilitating the use of dynamic navigation for dental implantology. The secondary objective was to evaluate if the accuracy obtained with this innovative display device was maintained in the range already described in literature regarding dynamic navigation.

### Case presentation

Two patients were referred to the Oral and Maxillo-facial Unit of the Department of Biomedical and Neuromotor Sciences for implant supported prosthetic rehabilitation. Both patients were to be treated in the upper premolar area and were in good general health conditions and had no contra-indications to the implant surgery. The clinical procedures were carried out in accordance with national guidelines as well as with the Declaration of Helsinki.

### Navigation system setting

After the filling of the appropriate consent documentation, both patients undertook a CBCT scan with the markers plate from the navigation system. These markers were positioned in situ as per protocol of using the navigation system ImplaNav (BresMedical, Sydney, Australia) which requires that the markers plate is fixed with a hard impression material (Ramitec, 3 M Espe, USA). After the scan, the markers plate was removed and replaced in the same position on the day of the surgery. The CBCT data was analyzed through the navigation system planning software and the position of two implants were virtually planned. At the time of the surgery the patient reference tool for the navigation system was fixed on the same support of the markers plate. Another reference tool was positioned and rigidly fixed on the implant drill handle. Then the calibration tool was connected to the handle and the drill axis was identified by the navigation system. The first lance drill was successively used to touch the fiducial markers on the markers plate to verify the patient position. After the calibration procedures, the navigation system was directly interfaced with the virtual reality glasses (Hololens, Microsoft, USA) through a wifi connection using a dedicated software created by Fifthingenium (Milan, Italy) (Fig. 1).



**Fig. 1** Overview of the Hololens glasses and navigation system reference tools during the surgery



### Augmented reality glasses setting

Microsoft HoloLens is an augmented reality headset which can be used to expand the limits of interaction between the virtual and the physical world. HoloLens runs a custom Windows 10 version as its operating system. It also features Bluetooth and Wi-Fi connectivity and is powered by a Holographic Processing Unit HPU 1.0, 2GB RAM and 64GB of Solid State storage. It is also equipped with an Inertial Measurement Unit, four environment understanding cameras, mixed reality capture, four microphones, an ambient light sensor and two HD displays capable of automatic pupillary distance calibration.

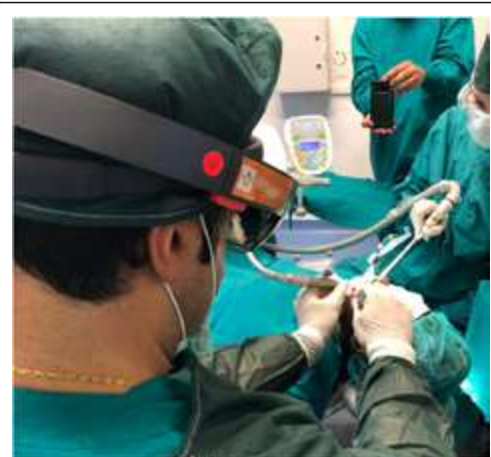The plethora of applications of the HoloLens in industry is mainly attributed to its ability to create, manipulate and display holograms or virtual objects in the field of the user. Combined with the ability to recognize objects, rooms and environments through the use of AI and markers, the capabilities of the HoloLens allows it to be useful in many industries including the Healthcare and Dental sector.

An application to use HoloLens in the dental field was developed in order to visualize 2D/3D data (CBCTs, face scans, oral scans) while at the dental chair without forcing the practitioner to look at a specific monitor/computer. By controlling the device via only voice commands or simple gestures, the surgeon is able to maintain visual of the physical surgical site and avoiding contamination.

A system capable of mirroring the desktop of a computer on the HoloLens was developed and coupled with the navigation system used for the surgery. Such system allows the doctor to avoid looking at the computer screen to receive guidance for the surgery. Instead, the doctor can visualize the system data, info, targets and positions by placing a virtual desktop near the patient's face without being forced to look away from the patient's mouth.

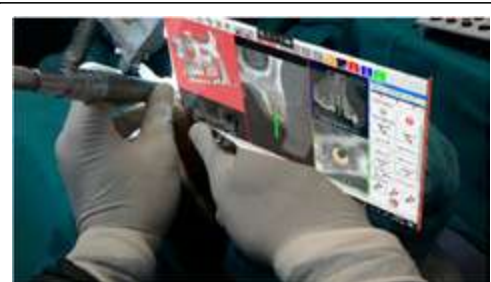### Clinical procedure

Using the HoloLens glasses, the surgeon can contemporarily visualize the surgical field (Fig. 2) and the output of the navigation system screen. The virtual position and the trajectory of the drill into the bone, the implant planned position and the bone anatomy around the implant site were checked in real-time during the whole surgical procedure (Fig. 3). The navigation system software input can also be managed with HoloLens through hand movements. Two implants were placed, one for each patient following the drill sequences provided by the implant company protocol. In one case a 3.8 × 9 mm (TTi, WinSix, Ancona, Italy) was positioned. In the other case a 4.1 × 11 mm (BL, Straumann, Switzerland). In both cases, a flapless surgery was carried out (Fig. 4). A postoperative radiograph was taken to evaluate the correct positioning of the implants (Fig. 5a, b). The

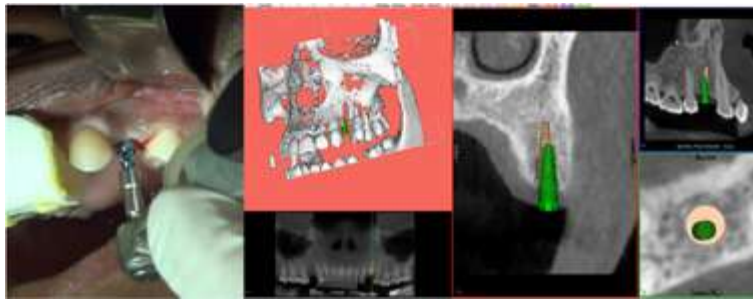


**Fig. 2** The external view of the surgeon during the surgical procedure

healing abutments were fixed without any suture. In one case the implant position had been planned to be close to the maxillary sinus (Fig. 6) and postoperative CBCT was taken to verify if the goal had been reached (Fig. 7). After about 3 months, the contra-torque test was manually performed to verify the osseointegration status of the implants. Then through a scan of the abutment and the use of the intra-oral scanner, the implant position was digitally recorded concurrently with the bordering teeth. The virtual planned position of the implant and the adjacent teeth were exported from the planning module in the ImplaNavig software. The two surfaces comprehending the teeth and the implants were compared via an N-point surface alignment of the teeth using Materialise 3-Matic (Materialise, Leuven, Belgium) (Fig. 8). The deviation between the planned implant position and the real one obtained by the scan were evaluated (Fig. 9). Both patients were rehabilitated with screw-retained crowns (Fig. 10).



**Fig. 3** The view of the surgeon during the surgery wearing HoloLens glasses



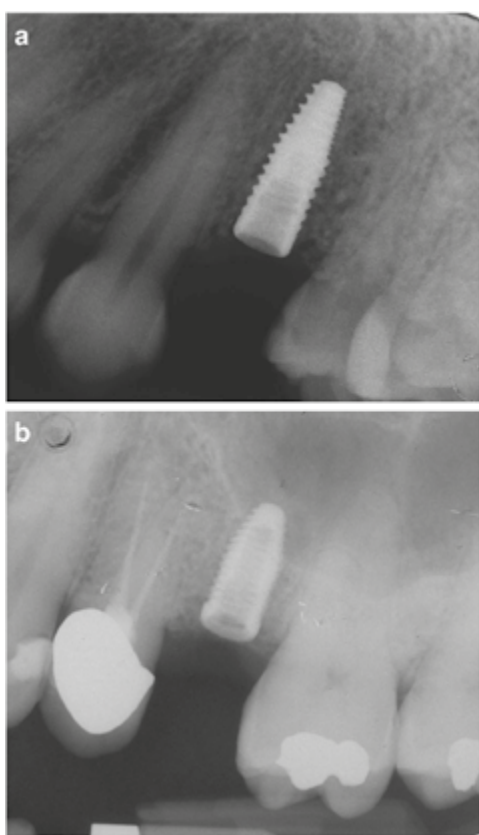
**Fig. 4** The real and the virtual implant position on the navigation system screen

### Results

In both cases it was possible to proceed with the navigation-aided implant placement with the Augmented Reality (AR) displaying in real-time a combination of surgical planning, real anatomy and the output from the navigation system (Fig. 3). The deviation between the planned and the real position of the implants resulted 0.53 mm at the entry point and 0.50 mm at the apical point for the first implant and 0.46 mm at the entry point and 0.48 mm at the apical point for the second one. The angular deviations were respectively 3.05° and 2.19° and the depth deviations were 0.26 mm and 0.37 mm.

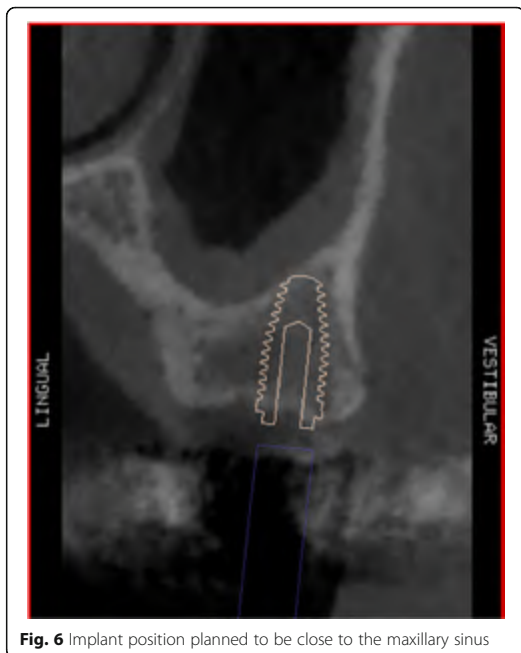
### Discussion

Dynamic navigation is one of the two computer-guided surgery techniques used in implantology. Many authors reported relatively good results in terms of implant placement accuracy using different navigation systems [1, 15–17]. Block et al. [16] reported on the implant placement accuracy obtained by 3 surgeons using dynamic navigation to treat 100 partially edentulous patients. They reported a mean error of  $0.87 \pm 0.42$  mm at the entry point,  $1.56 \pm 0.69$  mm at the apex and  $3.62^\circ \pm 2.73^\circ$  for angle deviations using dynamic navigation. Non-dynamically guided entry point deviations, apex deviations and angle discrepancies had corresponding mean values of  $1.15 \pm 0.59$  mm,  $2.51 \pm 0.86$  mm and  $7.69^\circ \pm 4.92^\circ$ . Stefanelli et al. [17], in a retrospective study on 231 implants reported an error of  $0.71 \pm 0.40$  mm at coronal point,  $1 \pm 0.49$  mm at apex and a mean angular error of  $2.26 \pm 1.62^\circ$ . Although there are reported advantages using dynamic navigation, this method requires the surgeon to coordinate his view of the screen with the movements of his hands. The look out of the implant site with the rotation of the head for looking at the navigation system screen could represent a risk in case of accidental surgical instrument shifting or unexpected patient movement, especially in advanced implantology. The use of the augmented reality

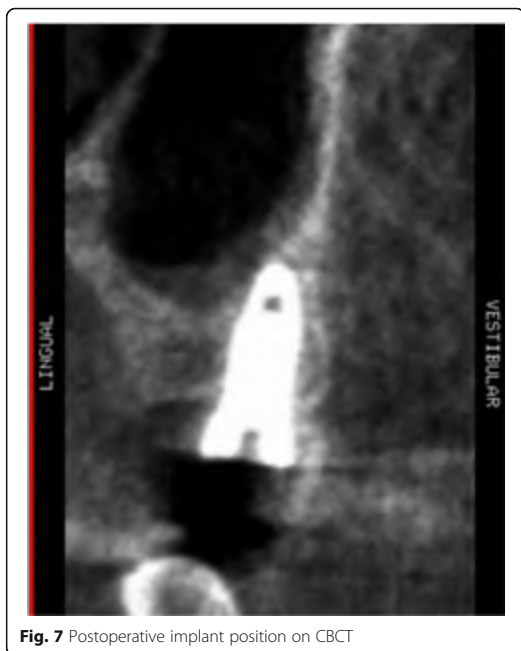

**Fig. 5 a, b:** Postoperative radiographs

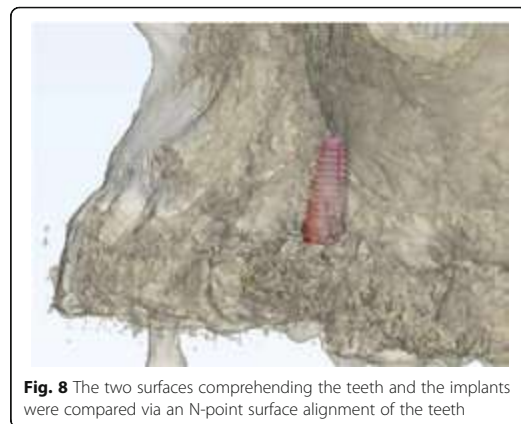




**Fig. 6** Implant position planned to be close to the maxillary sinus



**Fig. 7** Postoperative implant position on CBCT

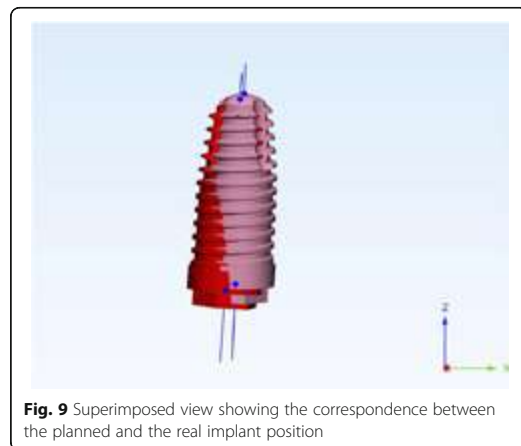


**Fig. 8** The two surfaces comprehending the teeth and the implants were compared via an N-point surface alignment of the teeth

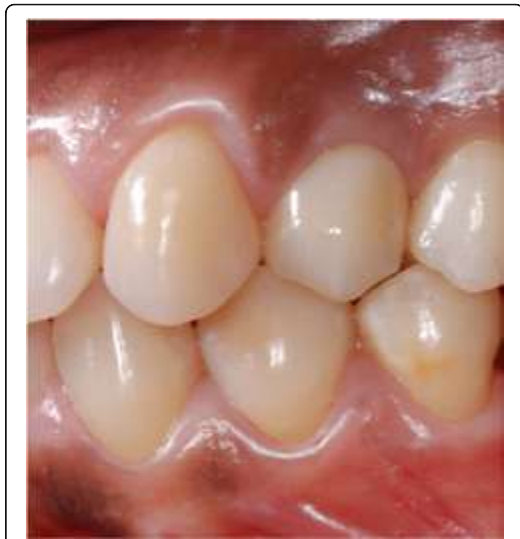can overcome this drawback and also reduce operating time [10].

The categories of AR-guided surgery are grouped as follows: type I, involving the use of glasses or head-sets [12, 13]; type II, with digital data being projected on a half-silvered mirror [18]; type III, where the images are shown directly onto the patients; type IV, with the use of an external monitor [11]. In this study glasses have been used, allowing the contemporary projection of the patient's anatomy and the virtual instruments near the surgical field. However, when a 3D virtual layer is displayed and laid over the real environment, there is often a discrepancy between the real image and the virtual image due to an overlay or positional error.

Augmented reality is employed in neurosurgery, laparoscopic digestive, laparoscopic thoracic, vascular, urological and gynecological laparoscopic and cardiac surgery. As per its application in maxillofacial surgery, most of the publications refer to its use in orthognathic surgery [13, 19, 20],



**Fig. 9** Superimposed view showing the correspondence between the planned and the real implant position



**Fig. 10** The prosthetic rehabilitation of one implant with a screw-retained crown

traumatic surgery and reconstructive surgery [21–23]. In dentistry, AR is applied in orthodontics for guided bracket placement [24]. In endodontics it is applied to detect root canals and for educational and training purposes [25–27].

In implantology, few studies regarding the use of dynamic navigation, especially in vitro, have been published. Ewers et al. [14] reported a significant medical benefit for the patients when navigation and AR are used for implant placement. In an in-vitro study, Jiang et al. [10] demonstrated a smaller error in incisor and canine regions implant placement using AR associated with dynamic navigation as opposed to the use of 2D navigation methods. The surgery time was significantly shorter by using a combination of the two technologies. In the present study, a dynamic navigation system associated with the augmented reality was deployed. This technique allowed the surgeon to simultaneously have a view of the surgical field as well as the navigation system monitor displaying implant planning and virtual burs. By wearing glasses where the virtual image is projected near the surgical field, the surgeon could see the implant site without interference and without the risk of overlay errors.

The main limit of this technology, currently, is emanated by the sometimes inconvenient virtual window positioning and orientation together with the working distance of the glasses which could force the surgeon to operate in an uncomfortable position. Nevertheless, the cases reported were simple and these limitations did not affect the results. Despite this, a comfortable work position might become mandatory in advanced clinical cases

[28, 29] in which this technology would prove to be beneficial. Other disadvantages could be considered the cost of the device, the time spent to set-up and the need to manage additional software for the AR. Possible setbacks could also occur from the device wireless connection and the battery charge although there were not reported in the present study. These problems could be solved by developing a dedicated software application for implantology and by upgrading the associated hardware.

As per the application in maxillofacial surgery of an AR technique displaying 3D images without the use of glasses, Suenaga et al. [30] reported a positional error of  $0.77 \pm 0.19$  mm (range 0,45–1,34) and an angular error of  $2^\circ$ . Zhu et al. [12], however, reported a discrepancy of  $0.96 \pm 0.51$  mm (range 0,55–2 mm). Most of the maximum overlay errors reported in literature are lower than 3 mm [11] with an exception for the research performed by Lin et al. [31], who reported a maximum error of 6.56 mm. The increase of accuracy, in addition to the lack of depth perception, is a problem the authors of these studies are working to address [32].

An in-vitro study by Lin et al. [31] showed good results in terms of implant placement accuracy using the drill-guides technique combined to AR. Katić et al. [33], by using an AR system in a pig cadaver experiment, reported a deviation of 1.1 mm and  $2^\circ$  between the planned implant and the positioned one. In the present case report, a less than 1 mm accuracy was achieved, comparable with the one reported in literature by only using the navigation system [1, 34]. This seems to indicate that AR does not affect the accuracy of the navigation procedure.

A touch-less interface for the navigation system software could also promote the use of this technology in the surgical theatre. By simplifying the procedures and reducing operative time, AR can prove to be an exceptional resource in dental implantology. This kind of technology could increase the use of dynamic navigation as it solves the problem of monitoring the screen and the patient simultaneously. The further development of AR could allow matching of the virtual with the real anatomy of the patient, a concept that is already under investigation for major surgery. At the moment, this is made difficult due to the need to follow the patient movement during the intervention usually carried out under local anesthesia.

### Conclusions

AR resulted to be quite useful in displaying dynamic navigation despite some software and hardware limits. The presence of the two environments in the AR does not seem to affect the accuracy of the surgical procedure. Specific software applications for navigation systems can further contribute to optimizing the results. Additional in vitro and clinical trials are required to validate the use of this new promising technology for dental implantology.

**Abbreviations**

AI: Artificial Intelligence; AR: Augmented Reality; CBCT: Cone-beam computerized tomography; mm: Millimeters

**Acknowledgements**

We thank BresMedical (Sydney, Australia) for the collaboration, Fithingenium (Milan, Italy) for providing HoloLens glasses and the Dental Radiology Division (Prof. Paolo Pisi), University of Bologna, Italy for assisting with the tomographic scanning facilities.

**Authors' contributions**

GP was the surgeon, conceived the ideas and wrote the manuscript; CM (author 2) conceived the ideas, RM managed the augmented reality glasses procedures, AF was the accuracy outcome assessor and wrote the manuscript, VT gave the support for the navigation system, CM (author 6) supervised the protocol. All Authors read and approved the manuscript.

**Funding**

No funding was obtained for this study.

**Availability of data and materials**

All data generated or analyzed during this study are included in this published article.

**Ethics approval and consent to participate**

This pilot case report was performed in accordance with the Declaration of Helsinki.

The present study was carried out following standard clinical procedures and the Authors confirm that this complies with national guidelines. (reference: [http://www.salute.gov.it/imgs/C\\_17\\_pubblicazioni\\_2128\\_allegato.pdf](http://www.salute.gov.it/imgs/C_17_pubblicazioni_2128_allegato.pdf)) Every patient gave his consent to the treatment.

**Consent for publication**

The identifying images and other personal or clinical details of participants are presented without compromise anonymity. The patients signed the consent form for publication.

**Competing interests**

The authors declare that they have no competing interests. The Author RM and VT, which have a relationship with the Companies providing the devices, gave only technical support in the device use.

**Author details**

<sup>1</sup>Oral and Maxillofacial Surgery Unit, DIBINEM, University of Bologna, 125, Via San Vitale 59, 40125 Bologna, Italy. <sup>2</sup>Digital Dentistry Section, University San Raffaele, Milan, Italy. <sup>3</sup>Fithingenium, Milan, Italy. <sup>4</sup>University of Technology - Sydney, School of Life Sciences, Sydney, Australia. <sup>5</sup>Chief of Oral and Maxillofacial Surgery Unit, DIBINEM, University of Bologna, Bologna, Italy.

Received: 18 April 2019 Accepted: 11 July 2019

© Pellegrino et al. 2019

**References**

- Block MS, Emery RW. Static or dynamic navigation for implant placement—choosing the method of guidance. *J Oral Maxillofac Surg.* 2016;74:269–77. <https://doi.org/10.1016/j.joms.2015.09.022>.
- Bover-Ramos F, Viña-Almunia J, Cervera-Ballester J, Peñarocha-Diogo M, García-Mira B. Accuracy of implant placement with computer-guided surgery: a systematic review and meta-analysis comparing cadaver, clinical, and in vitro studies. *Int J Oral Maxillofac Implants.* 2018;33(1):101–15. <https://doi.org/10.11607/jomi.5556>.
- D'haese J, Van De Velde T, Komiya A, Hultin M, De Bruyn H. Accuracy and complications using computer designed stereolithographic surgical guides for oral rehabilitation by means of dental implants: a review of the literature. *Clin Implant Dent Relat Res.* 2012;14(3):321–35. <https://doi.org/10.1111/j.1708-8208.2010.00275.x>.
- Ruppini J, Popovic A, Strauss M, Spüntrup E, Steiner A, Stoll C. Evaluation of the accuracy of three different computer-aided surgery systems in dental implantology: optical tracking vs. stereolithographic splint systems. *Clin Oral Implants Res.* 2008;19(7):709–16. <https://doi.org/10.1111/j.1600-0501.2007.01430.x>.
- Somogyi-Ganss E, Holmes HI, Jokstad A. Accuracy of a novel prototype dynamic computer-assisted surgery system. *Clin Oral Implants Res.* 2015; 26(8):882–90. <https://doi.org/10.1111/clr.12414>.
- Kang SH, Lee JW, Lim SH, Kim YH, Kim MK. Verification of the usability of a navigation method in dental implant surgery: in vitro comparison with the stereolithographic surgical guide template method. *J Craniomaxillofac Surg.* 2014;42(7):1530–5. <https://doi.org/10.1016/j.jcms.2014>.
- Cassetta M, Stefanelli LV, Giansanti M, Di Mambro A, Calasso S. Depth deviation and occurrence of early surgical complications or unexpected events using a single stereolithographic surgi-guide. *Int J Oral Maxillofac Surg.* 2011;40(12):1377–87. <https://doi.org/10.1016/j.ijom.2011.09.009>.
- D'haese J, Ackhurst J, Wismeijer D, De Bruyn H, Tahmaseb A. Current state of the art of computer-guided implant surgery. *Periodontol* 2000. 2017; 73(1):121–33. <https://doi.org/10.1111/prd.12175>.
- Mandelaris GA, Stefanelli LV, DeGroot BS. Dynamic navigation for surgical implant placement: overview of technology, key concepts, and a case ReportDynamic navigation for surgical implant placement: overview of technology, key concepts, and a case report. *Compend Contin Educ Dent.* 2018;39(9):614–21.
- Jiang W, Ma L, Zhang B, Fan Y, Qu X, Zhang X, Liao H. Evaluation of the 3D Augmented Reality-Guided Intraoperative Positioning of Dental Implants in Edentulous Mandibular Models. *Int J Oral Maxillofac Implants.* 2018;33(6): 1219–28. <https://doi.org/10.11607/jomi.6638>.
- Bosc R, Fitoussi A, Hersant B, Dao TH, Meningaud JP. Intraoperative augmented reality with heads-up displays in maxillofacial surgery: a systematic review of the literature and a classification of relevant technologies. *Int J Oral Maxillofac Surg.* 2019;48(1):132–9. <https://doi.org/10.1016/j.ijom.2018.09.010>.
- Zhu M, Liu F, Chai G, Pan JJ, Jiang T, Lin L, Xin Y, Zhang Y, Li Q. A novel augmented reality system for displaying inferior alveolar nerve bundles in maxillofacial surgery. *Sci Rep.* 2017;15(7):42365. <https://doi.org/10.1038/srep42365>.
- Badiali G, Ferrari V, Cutolo F, Freschi C, Caramella D, Bianchi A, Marchetti C. Augmented reality as an aid in maxillofacial surgery: validation of a wearable system allowing maxillary repositioning. *J Craniomaxillofac Surg.* 2014;42(8):1970–6. <https://doi.org/10.1016/j.jcms.2014.09.001>.
- Ewers R, Schicho K, Undt G, Wanschitz F, Truppe M, Seemann R, Wagner A. Basic research and 12 years of clinical experience in computer-assisted navigation technology: a review. *Int J Oral Maxillofac Surg.* 2005;34(1):1–8. <https://doi.org/10.1016/j.ijom.2004.03.018>.
- Wittwer G, Adeyemo WL, Schicho K, Birkfellner W, Enislidis G. Prospective randomized clinical comparison of 2 dental implant navigation systems. *Int J Oral Maxillofac Implants.* 2007;22(5):785–90.
- Block MS, Emery RW, Lank K, Ryan J. Implant placement accuracy using dynamic navigation. *Int J Oral Maxillofac Implants.* 2017;32(1):92–9. <https://doi.org/10.11607/jomi.5004>.
- Stefanelli LV, DeGroot BS, Lipton DI, Mandelaris GA. Accuracy of a dynamic dental implant navigation system in a private practice. *Int J Oral Maxillofac Implants.* 2019;34(1):205–13. <https://doi.org/10.11607/jomi.6966>.
- Wang J, Suenaga H, Hoshi K, Yang L, Kobayashi E, Sakuma I, Liao H. Augmented reality navigation with automatic marker-free image registration using 3-D image overlay for dental surgery. *IEEE Trans Biomed Eng.* 2014;61(4):1295–304. <https://doi.org/10.1109/TBME.2014.2301191>.
- Pulijala Y, Ma M, Pears M, Peebles D, Ayoub A. Effectiveness of Immersive Virtual Reality in Surgical Training-A Randomized Control Trial. *J Oral Maxillofac Surg.* 2018;76(5):1065–72. <https://doi.org/10.1016/j.joms.2017.10.002>.
- Mischkowski RA, Zinser MJ, Kübler AC, Krug B, Seifert U, Zöllner JE. Application of an augmented reality tool for maxillary positioning in orthognathic surgery - a feasibility study. *J Craniomaxillofac Surg.* 2006;34(8): 478–83. <https://doi.org/10.1016/j.jcms.2006.07.862>.
- Nijmeh AD, Goodger NM, Hawkes D, Edwards PJ, McGurk M. Image-guided navigation in oral and maxillofacial surgery. *Br J Oral Maxillofac Surg.* 2005;43(4):294–302. <https://doi.org/10.1016/j.bjoms.2004.11.018>.
- Marmulla R, Hoppe H, Mühling J, Eggers G. An augmented reality system for image-guided surgery. *Int J Oral Maxillofac Surg.* 2005;34(6):594–6. <https://doi.org/10.1016/j.ijom.2005.05.004>.
- Qu M, Hou Y, Xu Y, Shen C, Zhu M, Xie L, Wang H, Zhang Y, Chai G. Precise positioning of an intraoral distractor using augmented reality in patients with hemifacial microsomia. *J Craniomaxillofac Surg.* 2015;43(1):106–12. <https://doi.org/10.1016/j.jcms.2014.10.019>.
- Aichert A, Wein W, Ladikos A, Reichl T, Navab N. Image-based tracking of the teeth for orthodontic augmented reality. *Med Image Comput Comput Assist Interv.* 2012;15(Pt 2):601–8.

25. Llena C, Folguera S, Forner L, Rodríguez-Lozano FJ. Implementation of augmented reality in operative dentistry learning. *Eur J Dent Educ*. 2018; 22(1):e122–30. <https://doi.org/10.1111/eje.12269>.
26. Huang TK, Yang CH, Hsieh YH, Wang JC, Hung CC. Augmented reality (AR) and virtual reality (VR) applied in dentistry. *Kaohsiung J Med Sci*. 2018;34(4): 243–8. <https://doi.org/10.1016/j.kjms.2018.01.009>.
27. Yu H, Shen SG, Wang X, Zhang L, Zhang S. The indication and application of computer-assisted navigation in oral and maxillofacial surgery-Shanghai's experience based on 104 cases. *J Craniomaxillofac Surg*. 2013;41(8):770–4. <https://doi.org/10.1016/j.jcms.2013.01.016>.
28. Pellegrino G, Tarsitano A, Taraschi V, Vercellotti T, Marchetti C. Simplifying Zygomatic Implant Site Preparation Using Ultrasonic Navigation: A Technical Note. *Int J Oral Maxillofac Implants*. 2018;33(3): e67–71. <https://doi.org/10.11607/jomi.6270>.
29. Wang F, Bornstein MM, Hung K, Fan S, Chen X, Huang W, Wu Y. Application of Real-Time Surgical Navigation for Zygomatic Implant Insertion in Patients With Severely Atrophic Maxilla. *J Oral Maxillofac Surg*. 2018;76(1):80–7. <https://doi.org/10.1016/j.joms.2017.08.021>.
30. Suenaga H, Hoang Tran H, Liao H, Masamune K, Dohi T, Hoshi K, Mori Y, Takato T. Real-time in situ three-dimensional integral videography and surgical navigation using augmented reality: a pilot study. *Int J Oral Sci*. 2013;5(2):98–102. <https://doi.org/10.1038/ijos.2013.26>.
31. Lin YK, Yau HT, Wang IC, Zheng C, Chung KH. A novel dental implant guided surgery based on integration of surgical template and augmented reality. *Clin Implant Dent Relat Res*. 2015;17(3):543–53. <https://doi.org/10.1111/cid.12119>.
32. Murugesan YP, Alsadoon A, Manoranjan P, Prasad PWC. A novel rotational matrix and translation vector algorithm: geometric accuracy for augmented reality in oral and maxillofacial surgeries. *Int J Med Robot*. 2018;14(3):e1889. <https://doi.org/10.1002/rcs.1889>.
33. Katić D, Spengler P, Bodenstedt S, Castrillon-Oberndorfer G, Seeberger R, Hoffmann J, Dillmann R, Speidel S. A system for context-aware intraoperative augmented reality in dental implant surgery. *Int J Comput Assist Radiol Surg*. 2015;10(1):101–8. <https://doi.org/10.1007/s11548-014-1005-0>.
34. Pellegrino G, Taraschi V, Vercellotti T, Ben-Nissan B, Marchetti C. Three-Dimensional Implant Positioning with a Piezosurgery Implant Site Preparation Technique and an Intraoral Surgical Navigation System: Case Report. *Int J Oral Maxillofac Implants*. 2017;32(3):e163–5. <https://doi.org/10.11607/jomi.5800>.

#### Publisher's Note

Springer Nature remains neutral with regard to jurisdictional claims in published maps and institutional affiliations.

Ready to submit your research? Choose BMC and benefit from:

- fast, convenient online submission
- thorough peer review by experienced researchers in your field
- rapid publication on acceptance
- support for research data, including large and complex data types
- gold Open Access which fosters wider collaboration and increased citations
- maximum visibility for your research: over 100M website views per year

At BMC, research is always in progress.

Learn more [biomedcentral.com/submissions](https://biomedcentral.com/submissions)





- 1 All-on-four rehabilitation in patient with type II diabetes mellitus: case report and literature review**  
G.Orlando, I.Cusenza, S.Ferri,C.Ferraro,M.Nagni  
Annali di Stomatologia 2018; IX (4): 176-183

---

- 2 Functional Implant Prosthodontic Score di uno studio prospettico a un anno su tre diverse connessioni per restauri su impianto singolo**  
E.Ferrari Cagiadiaco, F.Carboncini, S.Parrini, T.Doldo, M.Nagni,N.Nuti, M.Ferrari  
Journal of Osseointegration Dicembre 2018; 10(4)

---

- 3 Sealing effectiveness against Staphylococcus aureus of five different implant-abutment connections**  
N.Discepoli, E.F.Cagiadiaco, G.Landini, L.Pallecchi, F.Garcia-Godoy, M.Ferrari  
American Journal of Dentistry, Vol.31,No.3 June 2018

---

- 4 Sopravvivenza implantare nei pazienti diabetici: studio preliminare con follow-up di 1 anno**  
F. Pirani, P. Montemezzi, P.Capparè, R.Vinci  
Scientific Poster presented at Collegio dei Docenti 12-14 April 2018

---

- 5 Utilizzo di innesti di osso autologo nelle gravi atrofie dei mascellari: analisi morfologica e immunoistochimica a lungo termine**  
G. Tetè. C. Manenti, F. Quasso, F. Mottola, M.Nagni  
Doctor OS Marzo 2018 XXIX 03

---

- 6 Strategie chirurgiche alternative nel trattamento dei terzi molari in inclusione ossea**  
F.Quasso, G. Tetè. F. Mottola, F. Amodio  
Doctor OS Febbraio 2018 XXIX 02

---

- 7 Prefabricated Bar System for Immediate Loading in Edentulous Patients: A 5-Year Follow -Up Prospective Longitudinal Study**  
E.Gherlone, G.Sannino, A.Rapanelli, R.Crespi, G.Gastaldi, P.Capparè  
BioMed Research International – Published 27 Febbraio 2018



## All-on-four rehabilitation in patient with type II diabetes mellitus: case report and literature review

Francesco Orlando<sup>1</sup>  
Irene Cusenza<sup>\*</sup>  
Serena Ferri<sup>\*</sup>  
Costanza Ferraro<sup>\*</sup>  
Matteo Nagni<sup>2</sup>

<sup>\*</sup> Dental School, Vita-Salute San Raffaele University, Milan, Italy and Department of Dentistry, IRCCS San Raffaele Hospital, Milan, Italy

<sup>1</sup> Fellow MSc, Dental School, Vita-Salute San Raffaele University, Milan, Italy and Department of Dentistry, IRCCS San Raffaele Hospital, Milan, Italy

<sup>2</sup> MSc, Dental School, Vita-Salute San Raffaele University, Milan, Italy and Department of Dentistry, IRCCS San Raffaele Hospital, Milan, Italy

### Corresponding author:

Matteo Nagni  
nagnimatteo@hotmail.it

### Abstract

**AIM:** The increase in the average age of the population leads to an increasing incidence of many different systemic diseases, often associated with partial or total edentulism. In particular, diabetes plays a significant role in patients' implant-prosthetic rehabilitation, as it has a direct effect on the oral cavity. The aim of this case report is to illustrate the rate of implant survival, marginal bone loss and any intra- and post-operative complications in patients with type II diabetes, undergoing fixed prosthetic rehabilitation according to the All-on-Four method, in a two-years of follow-up.

**Keywords:** All-on-Four, systemic diseases, immediate loading, diabetes, hyperglycemia.

### Materials and methods

The patient, suffering from type II diabetes, presented edentulous regions and compromised residual teeth in both arches. Considering the need for a fixed rehabilitation and, on the other hand, a severe bone loss in the posterior maxillary and mandibular sectors, we opted for a rehabilitation based on a reduced number of implants, according to the "All-on-Four" method. Follow-up examinations, aiming at assessing implant survival and marginal bone loss, were performed one week after surgery, after six months and then once a year for the following 24 months. Any intra- and postoperative complications were noted to evaluate and monitor the patient. Professional hygiene was performed every four months after surgery.

### Results

No implants were lost during the follow-up period. The marginal bone loss was comparable to literature results related to implant-retained prosthetic rehabilitations in healthy patients. No intra- and postoperative complications were reported.

### Conclusion

Maintaining a good glycemic control, able to favor the compensation of diabetes, the insertion of implants can be considered a safe procedure. The constant monitoring of the patient and his adherence to a strict hygiene protocol are fundamental to promote implant survival and early identification of complications.

### Introduction

The increase in the average age of the population leads to an increase in the incidence of various systemic diseases such as diabetes. At the same time fixed rehabilitation of partial or total edentulous patients with systemic diseases, associated with the increase in the average age, could be increasingly required (1, 2).

Diabetes mellitus is a complex metabolic disease, defined by the ADA (American Diabetes Association) as a group of metabolic diseases characterized by elevated blood glucose levels (hyperglycemia) that result from the body's inability to produce or use insulin (3). There are four types of diabetes: type I diabetes, an autoimmune disease characterized by an absolute deficiency of insulin, caused by destruction of pancreatic  $\beta$ -cells, that affects approximately 5-10% of the population and tends to occur at a young age; type II diabetes, caused by the association between a peripheral resistance to the action of insulin and an inadequate secretory response of pancreatic  $\beta$ -cells ("relative insulin deficiency"), represents the majority of cases of late-onset diabetes; drug- or chemical-induced diabetes; and gestational diabetes (4). Diabetes has a direct effect on the oral cavity, manifesting itself through microangiopathy, altered immune response and changes in salivary composition (5). In cases of implant rehabilitations, diabetes, could interfere with the normal processes of osseointegration, as the state of hyperglycemia has a negative effect on osteoblastic regulation and BIC (Bone Implant Contact) values (6, 7).

The diabetic patient's treatment may exhibit two different types of complications: the intra operative and the post-operative ones. The former group includes hypoglycemic crisis, while the latter includes mucositis, peri-implantitis, lack of implant osseointegration and poor wound healing (8). Hypoglycemic crisis is defined as an acute consequence of diabetic disease and usually occurs when the patient had not taken their medi-

*All-on-four rehabilitation in patient with type II diabetes mellitus: case report and literature review*

cations regularly and had not adequately eaten before the appointment (9). Mucositis and peri-implantitis are defined as inflammatory lesions of the tissues surrounding an implant. Peri-implant mucositis is defined as an inflammatory lesion limited to the surrounding mucosa of an implant, whereas peri-implantitis is defined as an inflammatory lesion of the mucosa affecting the supporting bone resulting in a loss of osseointegration, thus causing a likely decrease in implant success (10). The failure to osseointegrate the implant is another occurring post-operative complication. Osseointegration implies a firm, direct, and lasting connection between the vital bone and the titanium implants (11). In conclusion, we recall the incomplete soft tissue healing, caused by high blood glucose levels and non-enzymatic protein glycation, leading to AGE formation (12) which alters the permeability of the endothelium, releases inflammatory cytokines and growth factors, and increases the expression of adhesion molecules and chemokines, thus leading to delayed wound healing (13,14).

The aim of this case report was to illustrate implant survival rate, marginal bone loss and possible intra- and post-operative complications in patients with type II diabetes undergoing fixed prosthetic rehabilitation, according to the All-on-Four method, at two years follow-up.

### Case report

A 60-year-old woman came to the Department of Dentistry of the IRCCS San Raffaele Hospital with the wish to have an implant-prosthetic rehabilitation of the lower arch. The patient was submitted to an anamnestic questionnaire which showed that she suffered from type II diabetic pathology. To assess the state of the disease, it was decided to perform laboratory tests in which the values of Hba1c 7% (glycosylated haemoglobin) and glycaemic levels <180 mg/dl were analysed. The tests' results were normal and her diabetes resulted to be under control, making the patient an excellent candidate for implant therapy. The frontal view of the patient's smile can be observed in Figure 1. Intraoral examination revealed the presence of an incongruous prosthesis anchored to dental elements that functioned as prosthetic abutments (Fig. 2). Among the various treatment options, given the presence of edentulous areas, the placement of implants according to the "All-on-Four" method was considered the most valid. After the signing of the informed consent and the implant-prosthetic treatment, the patient was made aware of the possible intra- and post-oper-

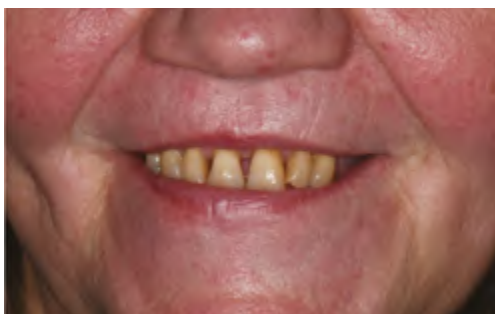

Figure 1. Extraoral photo.

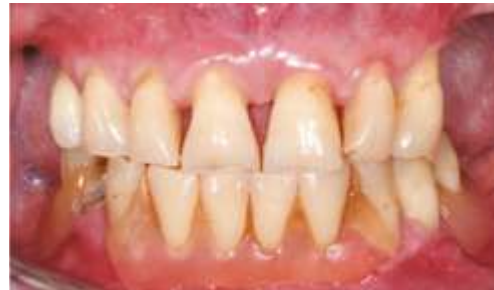

Figure 2. Intraoral photo: presence in the mandible of an incongruous prosthesis anchored to dental elements.

ative complications, determined by her general state of health. A professional oral hygiene session was carried out during the preoperative phase; subsequently, conventional impressions were taken for the study models; these were also used for the prosthetic component of the treatment. This was followed by radiographic investigations including an OPT (orthopantomography, a first level examination) which allowed an overall assessment of the jaws (Fig. 3). But, only after performing a CBCT (Cone Beam Computed Tomography, second level examination), it was possible to evaluate the bone volume of the maxilla. After carefully classifying the patient's bone density, defined as D3, and attentively performing all preoperative procedures, surgery could be scheduled. One hour before surgery, 2g of Amoxicillin and Clavulanic Acid (Augmentin, GlaxoSmithKline, Brussels, Belgium) were administered as a preventive measure. The surgical phase was performed under local anaesthesia (Optocaine 20 mg/ml with adrenaline 1:80,000; Molteni Dental, Florence, Italy). Some dental elements considered hopeless were avulsed (Fig. 4).

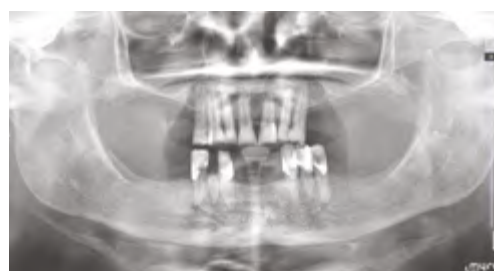


Figure 3. Orthopantomography that shows the condition of the jaw bones and residual elements.

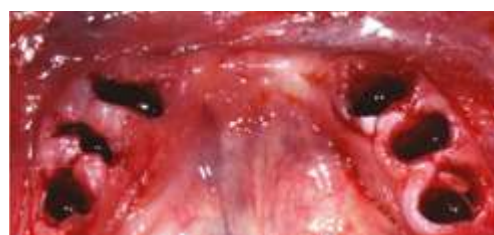
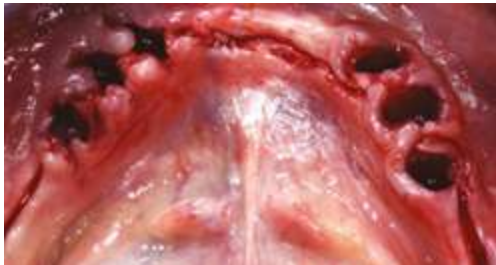
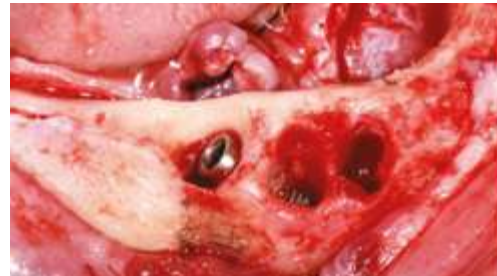Figure 4. Post-extractive socket.

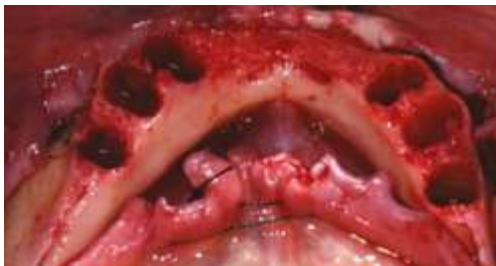*F. Orlando et al.*



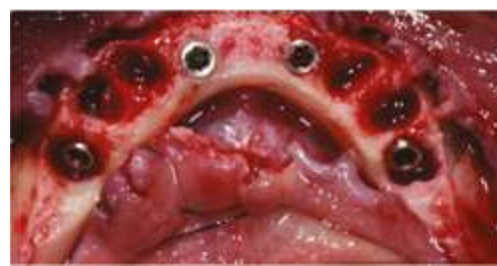**Figure 5.** Crestal incision and bilateral release incisions.



**Figure 7.** Tilted implant.



**Figure 6.** Full-thickness buccal flap.



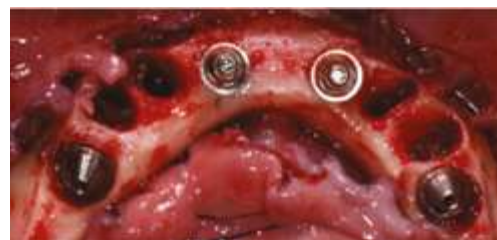**Figure 8.** Axial and tilted implants.

The mandibular edentulous ridge was incised with a crestal incision and bilateral release incisions from the first molar region to the contralateral side and a subperiosteal dissection was performed on the lingual and buccal surfaces (Fig. 5). A full-thickness buccal flap was then lifted to expose the buccal bone wall and to get an optimal view of the mental foramen (Fig. 6).

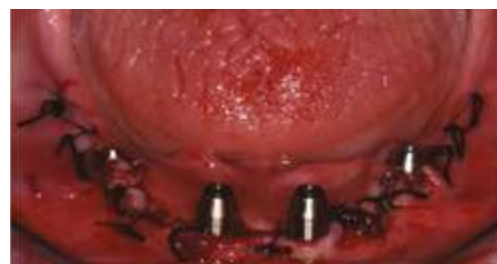Once the incisions had been made and the flaps lifted, implant placement was possible. In the mandible, the two posterior implants (dimensions length and diameter) (TTx, Winsix, Biosafin, Ancona, Italy) were placed bilaterally immediately anteriorly to the mental foramen (Fig. 7). It is important to underline that, following the All-on-Four protocol, the posterior implants are inserted following an inclined trajectory of about 25-30 degrees with respect to the occlusal plane. In fact, they emerge at the level of the second premolar, in order to decrease the length of the cantilever and maintain a large distance between the implants. The central implants, on the other hand, are inserted following a trajectory perpendicular to the occlusal plane (Fig. 8).

The insertion torque was between 30 and 40 Ncm before final implant placement, thus achieving high primary stability and immediate functionality.

To compensate for the lack of parallelism between the posterior implants and the prosthetic screw, angled abutments (Extreme Abutment, EA Winsix, Biosafin) were placed at 30°. The anterior implants, on the other hand, were fixed at 17° to allow optimal access for the prosthetic screw ((Fig. 9). After these steps, which were essential for the prosthetic part, the previously lifted flap was repositioned and adjusted with 4-0 nonabsorbable suture (Vicryl; Ethicon, Johnson & Johnson, New Brunswick, NJ, USA), ((Fig. 10). Immediately after surgery, an OPT was performed to verify the correct placement of the implants ((Fig. 11).



**Figure 9.** Placement of abutments.



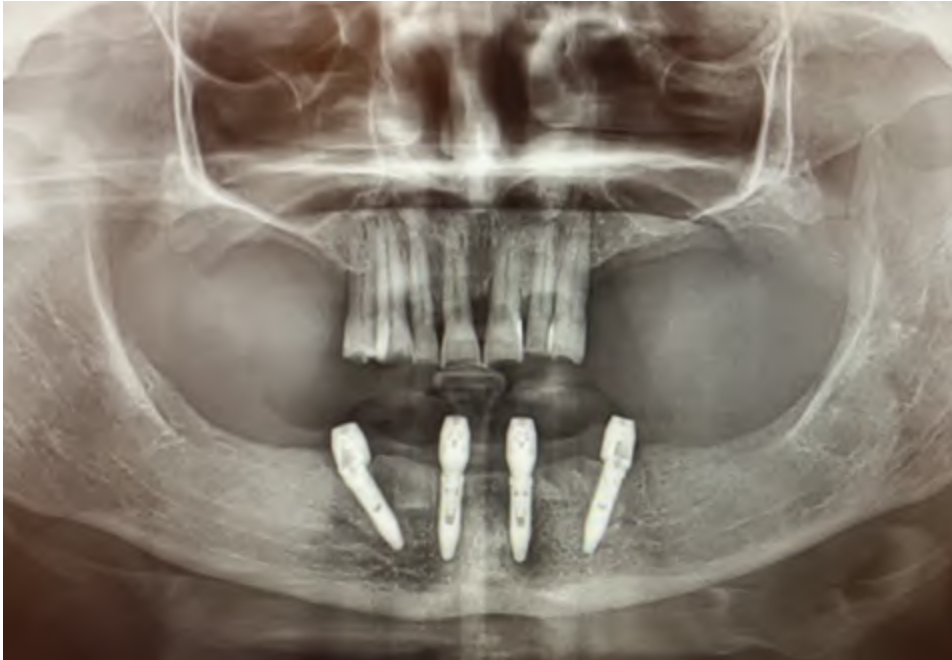**Figure 10.** Flap repositioning and suture.

Then the prosthetic phase started, which included the delivery of a provisional prosthesis and the taking of impressions for the fabrication of the definitive one: a few hours after surgery, a screw-reinforced, metal-reinforced, acrylic provisional prosthesis with ten teeth was delivered (no cantilevers were used in the provisional prostheses).

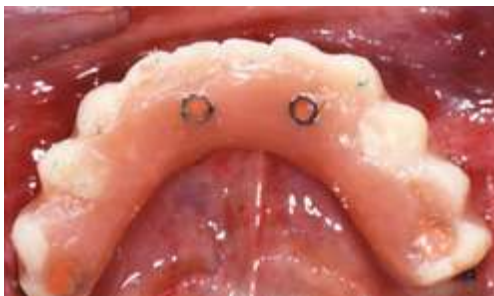The torque for the tightening the prosthetic screws was 20 N. Eventually the screw access holes were covered with temporary resin (Fermit, Ivoclar Vivadent, Naturno, Bolzano, Italy) ((Fig. 12).



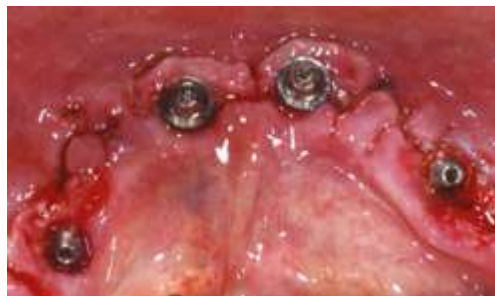*All-on-four rehabilitation in patient with type II diabetes mellitus: case report and literature review*



**Figure 11.** OPT to check implants placement.



**Figure 12.** Provisional prosthesis.



**Figure 13.** Mucosa after suture removal.

Approximately four months after surgery, the definitive prosthesis will be delivered and, unlike the provisional prosthesis, the latter will have an occlusion reproducing the patient's natural dentition, i.e. it will have a cantilever distal to the first molar.

Post-surgical indications included the use of a post-surgical dressing and rinsing with a solution containing chlorhexidine digluconate (0.12% or 0.2%), twice a day for 10 days. In addition, the use of 1 g Amoxicillin and Clavulanic Acid (Augmentin, GlaxoSmithKline) twice daily for 7 days after surgery and non-steroidal anti-inflammatory drugs (Ibuprofen 600 mg, Brufen, Abbott Laboratories, Chicago, IL, USA) was recommended should it be deemed necessary. Lastly, the patient was advised to eat a liquid diet and to avoid any brushing trauma to the surgical site, as well as smoking. The patient underwent a follow-up visit after one week and the sutures were removed at the same time (Fig. 13).

### Follow-up

Follow-up visits, aimed at clinical and radiographic examination, were performed one week after implant placement. Subsequently, at three months, six months and then annually until a two-year follow-up was attained. The patient was instructed, by a dental hygienist, in mechanical plaque control using an electric or manual toothbrush, interproximal brushes and Super Floss (Oral B, Procter & Gamble, Cincinnati, OH, USA). While, professional oral hygiene procedures were performed every three months, after implant placement.

### Parameters evaluated

**Implants survival rate.** Implant survival rate is based on the number of implants that were not lost or removed, during the follow-up period (15).

*F. Orlando et al.*

**Marginal bone loss.** Intra oral radiographs, using the parallel cone technique, were taken after implant placement, at three, six, twelve months and once a year for the following two years of follow-up. To evaluate marginal bone progression, the measurements were performed using Digora 2.5 software (Soredex, Tuusula, Finland). First, the instrument was calibrated (pixel/mm), using the diameter of the implants as the unit. Then, changes in the height of the peri-implant marginal bone with respect to the most coronal part of the implant fixture and the contact point between the implant fixture and the marginal crest were measured. To evaluate bone, a line passing over the shoulder of the implant was considered as a reference point for measurement from which a straight line was drawn parallel to the long axis of the implant to the most coronal point where the bone made contact with the fixture, both mesially and distally. The software automatically provided the distance between the two points measured in millimeters. To reduce human error, this measurement was made by different operators, and the mean of the three measurements was considered.

Then, to calculate the marginal bone level, a mesial measurement was taken, a distal measurement was taken and then the average of the mesial, distal and the average between the two values of a single implant site was calculated.

**Intra-operative and post-operative complications.**

Intra-operative complications	Post-operative complications
Hypoglycaemic crisis	Mucositis and peri-implantitis
	Lack of osseointegration
	Insufficient wound healing

**Results**

**Implant survival rate.** In the clinical case presented, the diabetic patient who received implant rehabilitation, presented laboratory tests appropriate for implant insertion. No implants were lost during the follow-up period. It is stated that the survival rate, two years after surgery, was 100% (16,17).

**Marginal bone loss.** Both axial and tilted implants showed marginal bone loss comparable to that of the healthy patient (17-19).

MARGINAL BONE LOSS	Axial implants	Tilted implants
6 months (mm)	0.61 ± 0.75	0.66 ± 0.58
1 year (mm)	0.85 ± 0.83	0.86 ± 0.91
2 years (mm)	0.86 ± 0.78	0.88 ± 0.64

**Intra- and post-operative complications.** The patient, thanks to adequate glycemic control (20), did not suffer from hypoglycemic crisis during the surgical procedure. No clinical signs of mucositis and peri-implantitis were observed during the two-year follow-up. This was made possible by the patient's inclusion in a maintenance program of professional oral hygiene and control of the diabetic pathology (21). The literature suggests that mucositis is caused by the accumulation of biofilm that interrupts host-microbe homeostasis at the implant-mucosal interface, resulting in an inflammatory lesion. Mucositis is a reversible condition, so the clinical implication is that optimal biofilm removal is a prerequisite for the prevention and management of mucositis (22). Based on these considerations, it was agreed that periodic clinical and radiographic controls should always be performed after implant placement to allow for the possible diagnosis of mucositis and peri-implantitis. Intra-oral radiographs, taken during the follow-up period, confirmed that osseointegration had taken place. They showed intimate contact between bone and implant, with an apparent absence of interposed fibrous tissue. The osseointegration of the patient's implants was promoted by the correct implant placement, based on the primary stability, which was obtained by an insertion torque of 30 N (23).

**Discussion**

According with the clinical considerations examined, it will be necessary to follow an adequate diagnostic pathway, to obtain a predictable result of the implant-prosthetic therapy of the diabetic patient. During the first visit, in fact, the general medical and dental history plays a crucial role and allows the clinician to reach an adequate knowledge of the patient's general and dental health status (24). An anamnesis is followed by an extra- and intra-oral examination; the latter paying particular attention not only to the dental elements present in the oral cavity but also to the soft tissues surrounding the tooth or located on the edentulous ridges (25, 26).

Before a diabetic patient undergoes oral surgery, it is necessary to establish the type of diabetes and the degree of glycaemic control. Robertson C et al., in a review of the literature, describe the criteria to establishing the diagnosis of diabetes and to identifying individuals at high risk of developing the disease. They suggest that if patients with controlled diabetes maintain a Hba1c value of <7%, then it will be possible to proceed with surgery (27). In the literature review, by Ramu C. et al., the indications for antibiotic prophylaxis in dental practice are stated. For patients with uncontrolled diabetes, antibiotic prophylaxis is considered mandatory as they are more susceptible to oral infections. On the other hand, antibiotic prophylaxis is recommended for patients with controlled diabetes, both in the case of minor and major surgery (28). For these reasons, in agreement with the authors, the patient was given 2g of Amoxicillin and Clavulanic acid one hour before surgery, as a preventive measure. The most serious complication, that a diabetic patient can experience during oral surgery, is a hypoglycemic crisis. To prevent this fact, it is important to make sure that the patient has taken their usual medication and eaten regularly before the appointment (29). If the patient has lost consciousness due to hypoglycemic crisis,

*All-on-four rehabilitation in patient with type II diabetes mellitus: case report and literature review*

medical assistance should be sought; a solution of 25-30 ml 50% dextrose or 1 mg glucagon should be injected intravenously; glucagon can also be administered intramuscularly or subcutaneously (30). According to Kidambi S. et al., patients receiving oral antidiabetics have a lower risk of developing hypoglycemic crises than those receiving insulin therapy (31).

Holmstrup P. et al. state that, since diabetes mellitus is a systemic inflammatory state, often associated with periodontitis, in case of implant rehabilitation, the patient may have an increased risk of developing mucositis and peri-implantitis (32). In the literature, the correlation between hyperglycemia and the risk of peri-implantitis is still a matter of discussion. Alberti A. et al., in their retrospective study, evaluated the influence of diabetes on peri-implantitis and implant failure. They considered 204 patients, treated with 929 implants. Of these, 19 were diabetic patients and most of them showed good control of their diabetic disease at the time of implant surgery. Among the diabetic patients only one showed peri-implantitis and another one showed increased implant failures. The results of these authors showed no association between peri-implantitis, diabetes mellitus and implant failure (33). In contrast, Rekawek P. et al, in their retrospective cohort study, examined 286 patients treated with 748 implants and found that diabetic patients had an increased risk of peri-implantitis. However, this risk can be counteracted by placing patients on a maintenance regimen with regular visits and professional oral hygiene sessions (34).

Another clinical aspect affected by diabetes is implant osseointegration. In the retrospective case-control study by Sghaireen MG et al. 257 subjects were included, 121 with and 136 without diabetes; diabetes was defined as well controlled with a HbA1c of less than 8%. Implant failure in the osseointegration process was observed in 17 cases in the diabetes group (4.5%) and in 16 cases in the control group (4.4%), so that a non-significant difference ( $p = 0.365$ ) was concluded (35). Schwarz F. et al., in their retrospective cohort study, evaluated immediate loading in a patient with type II diabetes. In 108 diabetic patients, immediately loaded implants showed identical survival to those placed after 3 months (100% each) (36). In diabetic individuals, persistent hyperglycaemia suppresses osteoblastic activity and alters the response of parathyroid hormone which regulates calcium and phosphorus metabolism (37), decreases collagen formation, induces apoptosis in bone lining cells and increases osteoclastic activity resulting in bone loss (38). The reduction in bone-implant contact confirms that diabetes inhibits osseointegration, unless hyperglycemia is therapeutically treated, and normal glucose levels are maintained (39). In the article by Khan N et al. it appears that the authors were not in favour of dental implant placement in patients with diabetes mellitus because of the high failure rate due to poor wound healing and impaired bone metabolism (40). High blood glucose levels and non-enzymatic glycation of proteins lead to the formation of AGEs (advanced glycation end products) (40). AGE alters the permeability of the endothelium, releases inflammatory cytokines and growth factors, increases the expression of adhesion molecules and chemokines, thus leading

to micro-vascular complications and delayed wound healing (41).

In the retrospective study by Alberti et al., no difference in implant survival (survival rate) after 10 years was shown in patients with diabetes (survival rate 96.5%), compared to patients without diabetes mellitus (survival rate 94.8%) (42). According to the literature review, by Naujokat H. et al., in the first years after implant placement, the survival rate of implants in patients with controlled diabetes does not differ from that of non-diabetics. However, when observed in the long term, about twenty years, the implant survival rate is reduced in patients with controlled diabetes compared to non-diabetic patients (43).

Lorean A et al., in their retrospective study, reported that patients with high HbA1c values (8.1% to 10.0%) had greater marginal bone loss than those with lower HbA1c values (44). In agreement with this, Souto-Maior JR et al., through a systematic review of the literature, state that it is possible to observe marginal bone loss that affects osseointegration (45). The factors that can contribute to implant failure, as already described, are many. However, according to the scientific review by Mombelli et al., bacterial plaque has a negative role in the health of peri-implant oral tissues; in fact, the basis of a correct management of the bacterial flora is home oral hygiene supported by professional services (46). It is necessary to underline how fundamentally important the synergy between the dental professional and the dental hygienist is in the context of successful implant rehabilitation, which, even more so in the treatment and monitoring of patients with systemic pathologies, must be expressed because of the potential risks of any preoperative, intraoperative, and postoperative complications (47, 48).

## Conclusion

This case report could demonstrate that implant-prosthetic rehabilitations in the totally edentulous patient with compensated diabetes could be safely applied. Clinical studies should be performed to confirm this result.

## References

1. Tetè G, Polizzi E, D'orto B, Carinci G, Capparè P. How to consider implant-prosthetic rehabilitation in elderly patients: a narrative review. *J Biol Regul Homeost Agents*. 2021 Jul-Aug;35(4 Suppl. 1):119-126. doi: 10.23812/21-4suppl1-11. PMID: 34425667.
2. D'Orto B, Tetè G, Polizzi E. Osseointegrated dental implants supporting fixed prostheses in patients affected by Sjögren's Syndrome: A narrative review. *J Biol Regul Homeost Agents*. 2020 Nov-Dec;34(6 Suppl. 3):91-93. PMID: 33412784.
3. Sannino G, Bollero P, Barlattani A, Gherlone E. A Retrospective 2-Year Clinical Study of Immediate Prosthetic Rehabilitation of Edentulous Jaws with Four Implants and Prefabricated Bars. *J Prosthodont*. 2017 Jul;26(5):387-394. doi: 10.1111/jopr.12406. Epub 2015 Nov 30. PMID: 26619306.
4. American Diabetes Association. 2. Classification and Diagnosis of Diabetes: Standards of Medical Care in Diabetes-2021. *Diabetes Care*. 2021 Jan;44(Suppl 1):S15-S33. doi: 10.2337/dc21-S002. Erratum in: *Diabetes Care*. 2021 Sep;44(9):2182. PMID: 33298413.



*F. Orlando et al.*

5. American Diabetes Association. 2. Classification and Diagnosis of Diabetes: Standards of Medical Care in Diabetes-2020. *Diabetes Care*. 2020 Jan;43(Suppl 1):S14-S31. doi: 10.2337/dc20-S002. PMID: 31862745.
6. Ternois M. La bouche : un miroir du diabète [The oral cavity: A mirror of diabetes]. *Presse Med*. 2017 Sep;46(9):822-830. French. doi: 10.1016/j.lpm.2017.04.001. Epub 2017 May 10. PMID: 28502373.
7. Retzeppi M, Donos N. The effect of diabetes mellitus on osseous healing. *Clin Oral Implants Res*. 2010 Jul;21(7):673-81. doi: 10.1111/j.1600-0501.2010.01923.x. Epub 2010 May 3. PMID: 20465554.
8. Mellado-Valero A, Ferrer García JC, Herrera Ballester A, Labaig Rueda C. Effects of diabetes on the osseointegration of dental implants. *Med Oral Patol Oral Cir Bucal*. 2007 Jan 1;12(1):E38-43. PMID: 17195826.
9. Jiang X, Zhu Y, Liu Z, Tian Z, Zhu S. Association between diabetes and dental implant complications: a systematic review and meta-analysis. *Acta Odontol Scand*. 2021 Jan;79(1):9-18. doi: 10.1080/00016357.2020.1761031. Epub 2020 May 13. PMID: 32401121.
10. Umpierrez G, Korytkowski M. Diabetic emergencies - ketoacidosis, hyperglycaemic hyperosmolar state and hypoglycaemia. *Nat Rev Endocrinol*. 2016 Apr;12(4):222-32. doi: 10.1038/nrendo.2016.15. Epub 2016 Feb 19. PMID: 26893262.
11. Figuero E, Graziani F, Sanz I, Herrera D, Sanz M. Management of peri-implant mucositis and peri-implantitis. *Periodontol* 2000. 2014 Oct;66(1):255-73. doi: 10.1111/prd.12049. PMID: 25123773.
12. Brånemark PI, Hansson BO, Adell R, Breine U, Lindström J, Hallén O, Ohman A. Osseointegrated implants in the treatment of the edentulous jaw. Experience from a 10-year period. *Scand J Plast Reconstr Surg Suppl*. 1977;16:1-132. PMID: 356184.
13. Tetè G, D'orto B, Ferrante L, Polizzi E, Cattoni F. Role of mast cells in oral inflammation. *J Biol Regul Homeost Agents*. 2021 Jul-Aug;35(4 Suppl. 1):65-70. doi: 10.23812/21-4suppl-6. PMID: 34425662.
14. Tetè G, D'Orto B, Nagni M, Agostinacchio M, Polizzi E, Agliardi E. Role of induced pluripotent stem cells (iPSCs) in bone tissue regeneration in dentistry: a narrative review. *J Biol Regul Homeost Agents*. 2020 Nov-Dec;34(6 Suppl. 3):1-10. PMID: 33386051.
15. Misch CE. Bone classification, training keys to implant success. *Dent Today*. 1989 May;8(4):39-44. PMID: 2597401.
16. Andrade CAS, Paz JLC, de Melo GS, Mahrouseh N, Januário AL, Capeletti LR. Survival rate and peri-implant evaluation of immediately loaded dental implants in individuals with type 2 diabetes mellitus: a systematic review and meta-analysis. *Clin Oral Invest*. 2022 Feb;26(2):1797-1810. doi: 10.1007/s00784-021-04154-6. Epub 2021 Sep 29. PMID: 34586502; PMCID: PMC8479496.
17. Chrcanovic BR, Albrektsson T, Wennerberg A. Diabetes and oral implant failure: a systematic review. *J Dent Res*. 2014 Sep;93(9):859-67. doi: 10.1177/0022034514538820. Epub 2014 Jun 13. PMID: 24928096; PMCID: PMC4541101.
18. Souto-Maior JR, Pellizzer EP, de Luna Gomes JM, Dds CAAL, Dds JFSJ, Vasconcelos BCDE, de Moraes SLD. Influence of Diabetes on the Survival Rate and Marginal Bone Loss of Dental Implants: An Overview of Systematic Reviews. *J Oral Implantol*. 2019 Aug;45(4):334-340. doi: 10.1563/aaid-joi-D-19-00087. Epub 2019 May 1. PMID: 31042455.
19. Lorean A, Ziv-On H, Perlis V, Ormianer Z. Marginal Bone Loss of Dental Implants in Patients with Type 2 Diabetes Mellitus with Poorly Controlled HbA1c Values: A Long-Term Retrospective Study. *Int J Oral Maxillofac Implants*. 2021 Mar-Apr;36(2):355-360. doi: 10.11607/jomi.8476. PMID: 33909727.
20. de Araújo Nobre M, Maló P, Gonçalves Y, Sabas A, Salgado F. Dental implants in diabetic patients: retrospective cohort study reporting on implant survival and risk indicators for excessive marginal bone loss at 5 years. *J Oral Rehabil*. 2016 Nov;43(11):863-870. doi: 10.1111/joor.12435. Epub 2016 Sep 27. PMID: 27611605.
21. Robertson C, Drexler AJ, Vernillo AT. Update on diabetes diagnosis and management. *J Am Dent Assoc*. 2003 Oct;134 Spec No:16S-23S. doi: 10.14219/jada.archive.2003.0368. PMID: 18196669.
22. Smeets R, Henningsen A, Jung O, Heiland M, Hammächer C, Stein JM. Definition, etiology, prevention and treatment of peri-implantitis--a review. *Head Face Med*. 2014 Sep 3;10:34. doi: 10.1186/1746-160X-10-34. PMID: 25185675; PMCID: PMC4164121.
23. Heitz-Mayfield LJA, Salvi GE. Peri-implant mucositis. *J Clin Periodontol*. 2018 Jun;45 Suppl 20:S237-S245. doi: 10.1111/jcpe.12953. PMID: 29926488.
24. Villa R, Polimeni G, Wikesjö UM. Implant osseointegration in the absence of primary bone anchorage: a clinical report. *J Prosthet Dent*. 2010 Nov;104(5):282-7. doi: 10.1016/S0022-3913(10)00146-0. PMID: 20970533.
25. American Diabetes Association. 2. Classification and Diagnosis of Diabetes: Standards of Medical Care in Diabetes-2021. *Diabetes Care*. 2021 Jan;44(Suppl 1):S15-S33. doi: 10.2337/dc21-S002. Erratum in: *Diabetes Care*. 2021 Sep;44(9):2182. PMID: 33298413.
26. Song YL, Zhang SJ. [Clinical features, diagnosis and treatment key points of dental implant prostheses for diabetic patients]. *Zhonghua Kou Qiang Yi Xue Za Zhi*. 2021 Dec 9;56(12):1172-1178. Chinese. doi: 10.3760/cma.j.cn112144-20210926-00437. PMID: 34915649.
27. Halpern LR, Adams DR. Medically Complex Dental Implant Patients: Controversies About Systemic Disease and Dental Implant Success/Survival. *Dent Clin North Am*. 2021 Jan;65(1):1-19. doi: 10.1016/j.cden.2020.08.001. Epub 2020 Oct 9. PMID: 33213704.
28. Robertson C, Drexler AJ, Vernillo AT. Update on diabetes diagnosis and management. *J Am Dent Assoc*. 2003 Oct;134 Spec No:16S-23S. doi: 10.14219/jada.archive.2003.0368. PMID: 18196669.
29. Ramu C, Padmanabhan TV. Indications of antibiotic prophylaxis in dental practice- review. *Asian Pac J Trop Biomed*. 2012 Sep;2(9):749-54. doi: 10.1016/S2221-1691(12)60222-6. PMID: 23570007; PMCID: PMC3609373.
30. Turchin A, Matheny ME, Shubina M, Scanlon JV, Greenwood B, Pendergrass ML. Hypoglycemia and clinical outcomes in patients with diabetes hospitalized in the general ward. *Diabetes Care*. 2009 Jul;32(7):1153-7. doi: 10.2337/dc08-2127. PMID: 19564471; PMCID: PMC2699723.
31. Mealey BL. Impact of advances in diabetes care on dental treatment of the diabetic patient. *Compend Contin Educ Dent*. 1998 Jan;19(1):41-4, 46-8, 50 passim; quiz 60. PMID: 9533351.
32. Kidambi S, Patel SB. Diabetes mellitus: considerations for dentistry. *J Am Dent Assoc*. 2008 Oct;139 Suppl:8S-18S. doi: 10.14219/jada.archive.2008.0364. PMID: 18809649.
33. Holmstrup P, Damgaard C, Olsen I, Klinge B, Flyvbjerg A, Nielsen CH, Hansen PR. Comorbidity of periodontal disease: two sides of the same coin? An introduction for the clinician. *J Oral Microbiol*. 2017 Jun 14;9(1):1332710. doi: 10.1080/20002297.2017.1332710. PMID: 28748036; PMCID: PMC5508374.
34. Alberti A, Morandi P, Zotti B, Tironi F, Francetti L, Taschieri S, Corbella S. Influence of Diabetes on Implant Failure and Peri-Implant Diseases: A Retrospective Study. *Dent J (Basel)*. 2020 Jul 4;8(3):70. doi: 10.3390/dj8030070. PMID: 32635449; PMCID: PMC7559512.
35. Rekawek P, Carr BR, Boggess WJ, Coburn JF, Chuang SK, Panchal N, Ford BP. Hygiene Recall in Diabetic and Nondiabetic Patients: A Periodic Prognostic Factor in the Protection Against Peri-Implantitis? *J Oral Maxillofac Surg*. 2021 May;79(5):1038-1043. doi: 10.1016/j.joms.2020.12.032. Epub 2020 Dec 29. PMID: 33497648.
36. Sghaireen MG, Alduraywish AA, Srivastava KC, Shrivastava D, Patil SR, Al Habib S, Hamza M, Ab Rahman S, Lynch E, Alam MK. Comparative Evaluation of Dental Implant Failure among Healthy and Well-Controlled Diabetic Patients-A 3-Year Retrospective Study. *Int J Environ Res Public Health*. 2020 Jul 21;17(14):5253. doi: 10.3390/ijerph17145253. PMID: 32708165; PMCID: PMC7400304.

*All-on-four rehabilitation in patient with type II diabetes mellitus: case report and literature review*

37. Schwarz F, Derks J, Monje A, Wang HL. Peri-implantitis. *J Clin Periodontol*. 2018 Jun;45 Suppl 20:S246-S266. doi: 10.1111/jcpe.12954. PMID: 29926484.
38. Santana RB, Xu L, Chase HB, Amar S, Graves DT, Trackman PC. A role for advanced glycation end products in diminished bone healing in type 1 diabetes. *Diabetes*. 2003 Jun;52(6):1502-10. doi: 10.2337/diabetes.52.6.1502. PMID: 12765963.
39. Kayal RA, Tsatsas D, Bauer MA, Allen B, Al-Sebaei MO, Kakar S, Leone CW, Morgan EF, Gerstenfeld LC, Einhorn TA, Graves DT. Diminished bone formation during diabetic fracture healing is related to the premature resorption of cartilage associated with increased osteoclast activity. *J Bone Miner Res*. 2007 Apr;22(4):560-8. doi: 10.1359/jbmr.070115. PMID: 17243865; PMCID: PMC3109431.
40. Kopman JA, Kim DM, Rahman SS, Arandia JA, Karimbux NY, Fiorellini JP. Modulating the effects of diabetes on osseointegration with aminoguanidine and doxycycline. *J Periodontol*. 2005 Apr;76(4):614-20. doi: 10.1902/jop.2005.76.4.614. PMID: 15857103.
41. Khan N, Bakshi KS, Jaggi AS, Singh N. Ameliorative potential of spironolactone in diabetes induced hyperalgesia in mice. *Yakugaku Zasshi*. 2009 May;129(5):593-9. doi: 10.1248/yakushi.129.593. PMID: 19420890.
42. Basta G, Schmidt AM, De Caterina R. Advanced glycation end products and vascular inflammation: implications for accelerated atherosclerosis in diabetes. *Cardiovasc Res*. 2004 Sep 1;63(4):582-92. doi: 10.1016/j.cardiores.2004.05.001. PMID: 15306213.
43. Alberti A, Morandi P, Zotti B, Tironi F, Francetti L, Taschieri S, Corbella S. Influence of Diabetes on Implant Failure and Peri-Implant Diseases: A Retrospective Study. *Dent J* (Basel). 2020 Jul 4;8(3):70. doi: 10.3390/dj8030070. PMID: 32635449; PMCID: PMC7559512.
44. Naujokat H, Kunzendorf B, Wiltfang J. Dental implants and diabetes mellitus-a systematic review. *Int J Implant Dent*. 2016 Dec;2(1):5. doi: 10.1186/s40729-016-0038-2. Epub 2016 Feb 11. PMID: 27747697; PMCID: PMC5005734
45. Lorean A, Ziv-On H, Perlis V, Ormianer Z. Marginal Bone Loss of Dental Implants in Patients with Type 2 Diabetes Mellitus with Poorly Controlled HbA1c Values: A Long-Term Retrospective Study. *Int J Oral Maxillofac Implants*. 2021 Mar-Apr;36(2):355-360. doi: 10.11607/jomi.8476. PMID: 33909727.
46. Souto-Maior JR, Pellizzer EP, de Luna Gomes JM, Dds CAAL, Dds JFSJ, Vasconcelos BCDE, de Moraes SLD. Influence of Diabetes on the Survival Rate and Marginal Bone Loss of Dental Implants: An Overview of Systematic Reviews. *J Oral Implantol*. 2019 Aug;45(4):334-340. doi: 10.1563/aa-id-joi-D-19-00087. Epub 2019 May 1. PMID: 31042455.
47. Mombelli A, Lang NP. The diagnosis and treatment of peri-implantitis. *Periodontol* 2000. 1998 Jun;17:63-76. doi: 10.1111/j.1600-0757.1998.tb00124.x. PMID: 10337314.
48. Cattoni F, Tetè G, D'orto B, Bergamaschi A, Polizzi E, Gastaldi G. Comparison of hygiene levels in metal-ceramic and stratified zirconia in prosthetic rehabilitation on teeth and implants: a retrospective clinical study of a three-year follow-up. *J Biol Regul Homeost Agents*. 2021 Jul-Aug;35(4 Suppl. 1):41-49. doi: 10.23812/21-4suppl1-4.
49. Polizzi E, D'orto B, Tomasi S, Tetè G. A micromorphological/microbiological pilot study assessing three methods for the maintenance of the implant patient. *Clin Exp Dent Res*. 2021 Apr;7(2):156-162. doi: 10.1002/cre2.345. Epub 2020 Nov 19. PMID: 33211411; PMCID: PMC8019768.

## Functional Implant Prosthodontic Score di uno studio prospettico a un anno su tre diverse connessioni per restauri su impianto singolo

► E. FERRARI CAGIDIACO<sup>1,2</sup>, F. CARBONCINI<sup>1</sup>, S. PARRINI<sup>1</sup>, T. DOLDO<sup>1</sup>, M. NAGNI<sup>3</sup>, N. NUTI<sup>1</sup>, M. FERRARI<sup>1,4</sup>

<sup>1</sup> Dipartimento di Biotecnologie Mediche, Università di Siena, Italy

<sup>2</sup> Dipartimento di Parodontologia, Universidad Complutense, Madrid, Spain

<sup>3</sup> Dipartimento di Odontostomatologia, Università Vita e Salute, S. Raffaele, Milano, Italy

<sup>4</sup> Dipartimento di Restorative Dentistry, University of Leeds, UK

### TO CITE THIS ARTICLE

Ferrari Cagidiaco E, Carboncini F, Parrini S, Doldo T, Nagni M, Nuti N, Ferrari M. Functional Implant Prosthodontic Score of a one-year prospective study on three different connections for single-implant restorations. *J Osseointegr* 2018;10(4):130-135.

DOI 10.23805 /JO.2018.10.04.04

### RIASSUNTO

**Scopo** Lo scopo di questo studio clinico prospettico è stato di analizzare, utilizzando un nuovo score clinico, cioè il Functional Prosthodontic Implant Score (FIPS), i risultati di tre diversi tipi di protesi implantari con due tipi di connessioni (1 tipo esagonale vs 2 tipi conici) a distanza di un anno.

**Materiali e metodi** Trenta pazienti sono stati trattati con corone cementate su impianti soft tissue level (10 TTc Winsix, 10 TTK Winsix e 10 Aadv GC) in siti posteriori e monitorati per 1 anno. Il FIPS è stato applicato per la valutazione del risultato obiettivo finale insieme agli esami clinici e radiografici. Sono state definite cinque variabili per la valutazione, risultando in un punteggio massimo di 10 per ogni ricostruzione implanto-protesica. Il livello di soddisfazione dei pazienti è stato registrato e correlato con il FIPS.

**Risultati** Tutti gli impianti, le connessioni e le corone hanno rivelato percentuali di sopravvivenza del 100% senza complicanze biologiche o tecniche dopo un anno di carico. Il FIPS totale registrato per il gruppo 1 era 44, 43 nel gruppo 2 e 42 nel gruppo 3. Il punteggio medio FIPS totale per campione era di  $8,6 \pm 1,1$  sempre comunque compreso tra 6 e 10. La variabile "osso" ha rivelato i punteggi più alti (2,0, range: 2-2), così come "occlusione" (2,0, range: 2-2). I punteggi medi sono stati per "design" ( $1,7 \pm 0,4$ ; range: 1-2), "mucosa" ( $1,6 \pm 0,5$ ; range: 1-2) e "interprossimale" ( $1,5 \pm 0,6$ ; range: 1-2). I pazienti hanno espresso un alto livello di soddisfazione funzionale ( $80,5 \pm 2,5$ , range: 65-100). Nessun tipo di connessione ha dimostrato di essere superiore alle altre due. Nessuna differenza statisticamente significativa è stata trovata tra i tre gruppi testati. Una correlazione significativa è stata trovata tra il FIPS e la percezione soggettiva dei pazienti con un coefficiente di 0,80 ( $P < 0,0001$ ).

**Conclusioni** I risultati di questo studio clinico hanno indicato il grande potenziale delle connessioni sia coniche che esago-

nali e le loro buone prestazioni dopo 1 anno di uso. Il FIPS ha dimostrato di essere uno strumento di valutazione clinica oggettivo e affidabile per valutare il successo dell'impianto.

**KEYWORDS** Functional Implant Prosthodontic Score (FIPS), Connessione esagonale; Connessione conica; impianto singolo.

### INTRODUZIONE

Al giorno d'oggi è stato riportato un tasso di sopravvivenza e successo molto elevato di impianti e restauri (1). Tuttavia, l'aumento delle aspettative dei pazienti riguardo ai risultati estetici e alla longevità del trattamento obbliga a cercare un aspetto naturale come risultato finale del trattamento implantoprotesico (2,3).

I punteggi e gli indici clinici sono stati sviluppati per valutare le corone su impianto singolo nella zona estetica (4-8), ma principalmente per valutare il successo delle corone poste sugli impianti anteriori (4-8). Queste metodologie hanno voluto indirizzare i punteggi clinici sugli aspetti sia protesici che parodontali delle corone complete anteriori e consentire ai dentisti di eseguire una valutazione clinica (4-8). Sfortunatamente, nessun sistema di valutazione clinica simile per corone posteriori su impianti è stato mai realizzato, fino a quando non è stato proposto il Functional Implants Prosthodontic Score (FIPS) (9). Il FIPS è stato recentemente introdotto per convalidare corone cliniche su impianti. Si deve considerare che, secondo l'AAID (<http://www.aaid.com>), la distribuzione nelle regioni posteriore e anteriore dell'arco delle ricostruzioni di unità singole supportate da impianto mostra un rapporto di 2:1.

È stata anche analizzata la valutazione della riproducibilità e della variabilità dell'osservatore del FIPS (10) confermandone l'ottima applicabilità. Inoltre, il FIPS è stato utilizzato in uno studio clinico prospettico su corone monolitiche in disilicato di litio supportate da impianto con

► Ferrari Cagdiaco E. et al.

workflow digitale completo (11), che mostra la sua elevata potenzialità da applicare nella pratica quotidiana e in studi clinici randomizzati. Quindi il FIPS può anche essere utile ad analizzare i criteri di successo per la stabilità biologica e tecnica a lungo termine.

Sono state proposte diverse connessioni implantoprotetiche e le due più popolari sono quella esagonale e quella conica (12-15).

Il FIPS può anche essere usato per confrontare diverse connessioni di restauri su impianti singoli durante studi clinici randomizzati in base a criteri standardizzati e obiettivi, utilizzando dati clinici e radiografici e per correlare questi risultati alle percezioni soggettive dei pazienti (9).

Lo scopo di questo studio clinico randomizzato è stato di valutare con il FIPS tre tipi di corone su impianto singolo nell'area posteriore utilizzando due connessioni coniche e una esagonale a un anno dalla loro realizzazione.

Le ipotesi nulle testate erano che, valutando i restauri di singoli impianti con FIPS, ci sarebbero state: 1. differenze tra le connessioni esagonale e coniche e 2. differenze tra le tre connessioni testate.

## MATERIALI E METODI

### Impostazione dello studio clinico

Un campione di 30 restauri su impianti singoli in 30 pazienti (17 F e 13 M, età media  $52 \pm 6,5$  anni) è stato selezionato tra gennaio e aprile 2017 dal pool di pazienti che hanno avuto accesso al Dipartimento di protesi dentale e materiali dentali dell'Università di Siena, Italia. Tutti i pazienti richiedevano un restauro su impianto singolo nell'area posteriore (siti premolari e molari superiori e inferiori).

Tutte le procedure eseguite in questo studio che coinvolgono pazienti sono state conformi agli standard etici del comitato di ricerca istituzionale e/o nazionale e alla

dichiarazione di Helsinki del 1964 e alle sue successive modifiche o standard etici comparabili.

### Criteri di inclusione ed esclusione

Tutti i pazienti erano parodontalmente sani. La presenza di uno dei seguenti fattori ha determinato l'esclusione del paziente dalla sperimentazione clinica: 1) minorenni (<18 anni); 2) gravidanza; 3) disabilità; 4) parodontite (cronica); 5) contatti occlusali pesanti o storia di bruxismo; 6) malattia sistemica o gravi complicanze mediche; 7) storia allergica riguardante metacrilati; 8) carie dilagante; 9) xerostomia; 10) mancanza di conformità; 11) barriere linguistiche; 12) indice di placca superiore a 20.

### Randomizzazione e selezione dei pazienti

Dopo il reclutamento, sono state fornite ai pazienti istruzioni di igiene orale ed è stata eseguita la profilassi per stabilire il controllo ottimale della placca e la salute gengivale. Sono state eseguite e registrate le valutazioni cliniche dei parametri parodontali quali profondità di sondaggio delle tasche (PPD, Löe and Silness) (16), sanguinamento al sondaggio (BoP, Ainamo e Bay) (17), e indice di placca (PI, Löe e Silness) (16).

Tutte le procedure protesiche sono state eseguite in anestesia locale (articaina con epinefrina 1:100.000) da un singolo operatore esperto.

Rx intraorali sono state eseguite prima di iniziare il trattamento.

### Randomizzazione, occultamento delle assegnazioni e mascheramento degli esaminatori

Ogni soggetto è stato diviso casualmente nei tre gruppi sperimentali di 10 ciascuno ( $3 \times n = 10$ ) e assegnati a uno dei tre gruppi in base al sistema implantare utilizzato.

- Gruppo A: impianto Aadvia (GC) con connessione conica;
- Gruppo B: Winsix (Biosafin) con connessione conica (TTC);

## INTRODUCTION

A very high survival and success rate of implants and restorations is reported (1). However, increase of patients' expectations regarding esthetic results and longevity of the treatment, obliges to search a natural appearance as final result of the implant-prosthetic treatment (2,3).

Clinical scores and indices have been developed to assess single-implant crowns in the esthetic zone (4-8), but mainly to evaluate success of anterior crowns placed on implants (4-8). These methodologies wanted to address clinical scores on both prosthodontic and periodontal aspects of anterior full crowns and permit dentists to perform a clinical evaluation (4-8). Unfortunately, no similar clinical evaluation system for posterior crowns on implants has been available for a

long time, until the Functional Implants Prosthodontic System (FIPS) was proposed (9). The FIPS was recently introduced in order to validate clinical crowns on implants. It must be considered that, according to the AAID (<http://www.aaid.com>), the distribution in the posterior and the anterior regions of the arch of implant-supported single-unit reconstructions shows a ratio of 2:1.

Assessment of reproducibility and observer variability of FIPS was evaluated (10). Also, FIPS was used in a prospective clinical trial on Monolithic implant-supported lithium disilicate crowns in a complete digital workflow (11), showing its high potentiality to be applied in daily practice and randomized clinical trials. FIPS can help to analyze success criteria for long term biological and technical stability. Different implant-prosthetic connections were proposed

and the two most popular connections are hexagon and conical (12-15).

FIPS can also be used to compare different connections of single-implant restorations during randomized clinical trials under standardized and objective criteria using clinical and radiographic outcomes and to correlate these results to the subjective perceptions of the patients (9).

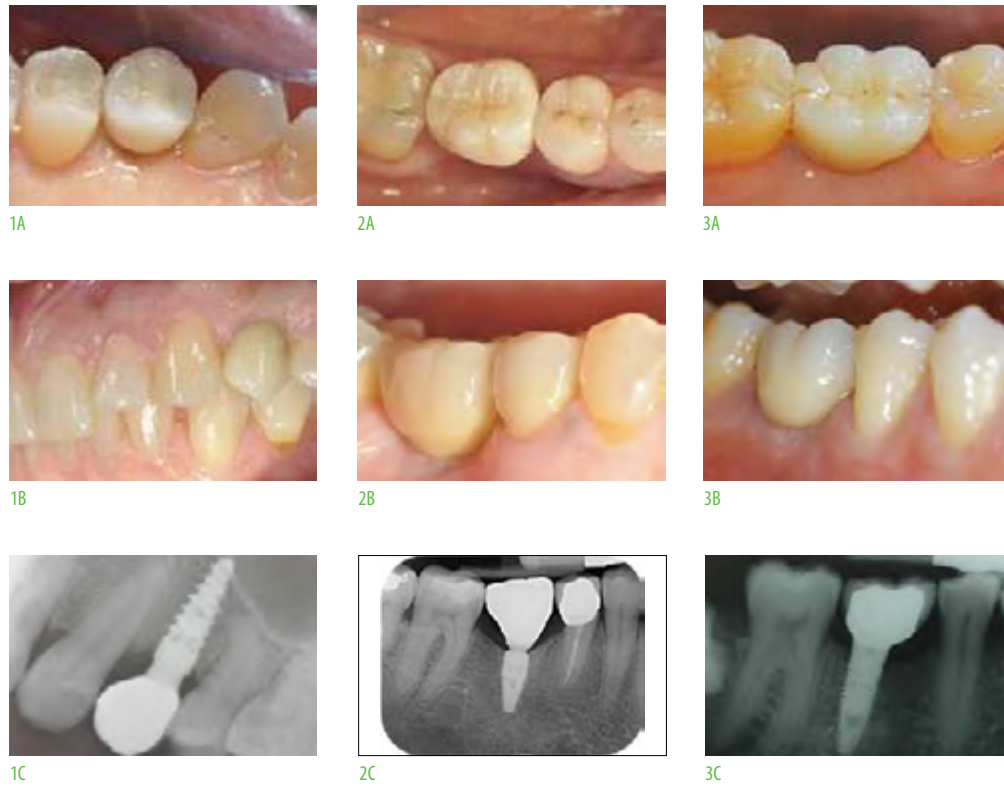The aim of this randomized clinical study was to evaluate with FIPS three types of single-implant crowns in the posterior area using two conical and one hexagon connections after 1 year of clinical service.

The null hypotheses tested were that, scoring the single-implant restorations with FIPS, there are

1. Differences between hexagon and conical connections;
2. Differences among the three tested connections.

JO

Functional Implant Prosthodontic Score nella valutazione dei risultati di riabilitazioni su impianto singolo



Variables	0	1	2
Contatti interprossimali e papille			2
Occlusione statica e dinamica			2
Contoni e colore		1	
Qualità e quantità della mucosa			2
Radiografia osso			2
Score massimo			9

FIG. 1 Gruppo 1: premolare superiore restaurato (FDI 24) dopo 1 anno di carico; visioni occlusale (A) e laterale (B) e immagine radiografica (C). L'applicazione del FIPS ha rivelato un punteggio totale di 9.

Variables	0	1	2
Contatti interprossimali e papille			2
Occlusione statica e dinamica			2
Contoni e colore			2
Qualità e quantità della mucosa		1	
Radiografia osso			2
Score massimo			9

FIG. 2 Gruppo 2: premolare superiore restaurato (FDI 46) dopo 1 anno di carico; visioni occlusale (A) e laterale (B) e immagine radiografica (C). L'applicazione del FIPS ha rivelato un punteggio totale di 9.

Variables	0	1	2
Contatti interprossimali e papille			2
Occlusione statica e dinamica			2
Contoni e colore		1	
Qualità e quantità della mucosa			2
Radiografia osso			2
Score massimo			9

FIG. 3 Gruppo 3: premolare superiore restaurato (FDI 46) dopo un anno di carico; visioni occlusale (A) e laterale (B) e immagine radiografica (C). L'applicazione del FIPS ha rivelato un punteggio totale di 9.

► Ferrari Cagidiaco E. et al.

• Gruppo C: Winsix (Biosafin) con connessione esagonale (TTK). L'assegnazione del trattamento è stata annotata nel modulo di registrazione e trattamento assegnato dallo studio. L'occultamento delle assegnazioni è stato eseguito con buste sigillate opache, numerate in sequenza. Lo statistico ha fatto la sequenza di allocazione per mezzo di una lista casuale generata dal computer e ha incaricato un soggetto diverso di assegnare una busta sigillata contenente il tipo di IOS. L'involucro opaco è stato aperto prima della selezione del sistema implantare e comunicato all'operatore. Al richiamo a un anno è stato applicato il blinding dell'esaminatore. Tutte le corone sono state prodotte in un misto tradizio-

nale, le impronte sono state realizzate utilizzando il materiale per impronta Vinyl Polyether Silicone (EXA'lence, GC), quindi sono state versate in gesso (FujiRock, GC) - e lavoro in laboratorio con digitale, i calchi sono stati scansionati con uno scanner da laboratorio (Aadva Lab Scan, GC), elaborato tramite CAD/CAM con abutment in titanio individualizzati, cappette in zirconio (Aadva zirconia, GC), oltre a sovrastrutture in ossido di zirconio impiallacciate manualmente (Initial, GC). Ogni singolo abutment in titanio è stato avvitato con un torque massimo di 35 Ncm secondo le istruzioni del produttore e le corone definitive sono state cementate con cemento provvisorio (TempBond NE, Kerr Dental, Rastatt, Germania).

Variabili	Gruppo 1	Gruppo 2	Gruppo 3	Score totale ciascun gruppo
Contatti interprossimali e papille	8	7	6	21
Occlusione statica e dinamica	10	10	10	30
Contoni e colore	8	9	8	25
Qualità e quantità della mucosa	8	7	8	23
Radiografia osso	10	10	10	30
Score totale ciascun gruppo	44	43	42	

TAB. 1 Punteggi radiografici e clinici basati sul FIPS per ciascun gruppo.

N= 20 pazienti	Mediana	Q25-Q75	Media	SD	Min-Max
Contatti interprossimali e papille	1.5	1-2	1.5	0.6	1-2
Occlusione statica e dinamica	2	2-2	2	0	1-2
Contoni e colore	1.5	1-2	1.7	0.4	0-2
Qualità e quantità della mucosa	1.5	1-2	1.6	0.5	0-2
Radiografia osso	2	2-2	2	0	2-2
Score totale ciascun gruppo	8.5	6-9	8.8	1.2	6-10

TAB. 2 Mediana e quartili Q25-Q75 riassunti e punteggi FIPS medi inclusi i valori di deviazione standard (SD) e minimo-massimo (min-max) per ciascuna variabile.

#### MATERIAL AND METHODS

##### Clinical study setting

A sample of 30 consecutive single-implant restorations in 30 patients (17 F and 13 M, mean age 52 ± 6.5 years) was selected between January and April 2017 from the pool of patients accessing the Department of Prosthodontics and Dental Materials of the University of Siena, Italy. All patients required a single-implant restoration in the posterior area (upper and lower premolar and molar sites).

All procedures performed in this study involving human participants were in accordance with the ethical standards of the institutional and/or national research committee and with the 1964 Helsinki declaration and its later amendments or comparable ethical standards.

##### Inclusion and exclusion criteria

All patients were periodontally healthy.

Patients with the following factors were excluded from the clinical trial: 1) underage (<18 years); 2) pregnancy; 3) disabilities; 4) (profound, chronic) periodontitis; 5) heavy occlusal contacts or history of bruxism; 6) systemic disease or severe medical complications; 7) allergic history concerning methacrylates; 8) rampant caries; 9) xerostomia; 10) lack of compliance; 11) language barriers; 12) plaque index higher than 20.

##### Randomization and selection of the patients

After recruitment, oral hygiene instructions were given to the patients and prophylaxis was performed to establish optimal plaque control and gingival health.

Clinical assessments of periodontal parameters such as

probing pocket depths (PPD) Löe and Silness (16), bleeding on probing (BoP) Ainamo and Bay (17), and a full-mouth plaque index (PI), Löe and Silness (16) were performed and recorded. All restorative procedures were performed under local anaesthesia (Articaine with 1:100.000 epinephrine) by a single experienced operator.

Intraoral X-rays were made before starting the treatment.

Randomization, allocation concealment and masking of examiners

Each experimental subject was randomly divided in three test groups of 10 each (3 × n = 10) and assigned to one of three groups according to the implant system used:

- Group A: Aadva implant (GC) with conical connection;
- Group B: Winsix (Biosafin) with conical connection (TTC)
- Group C: Winsix (Biosafin) with hexagon connection (TTK)



Q1 (come sono state soddisfatte le aspettative generali dei pazienti)	
Gruppo 1	85, 80, 65, 75, 90, 100, 85, 70, 70, 75 (79.5 mean)
Gruppo 2	80, 70, 65, 100, 100, 75, 65, 80, 80, 75 (79.0 mean)
Gruppo 3	65, 70, 100, 95, 90, 70, 80, 70, 75, 65 (78.0 mean)
Q2 (soddisfazione generale dei pazienti dal punto di vista funzionale)	
Gruppo 1	80, 95, 90, 65, 70, 75, 100, 65, 85, 90 (81.5 mean)
Gruppo 2	75, 80, 100, 65, 65, 90, 75, 75, 95, 70 (79.0 mean)
Gruppo 3	100, 90, 65, 70, 75, 80, 85, 70, 90, 80 (80.5 mean)

TAB. 3 Entrambe le domande includevano una scala analogica visiva (VAS) che andava da "insoddisfatti" a "completamente soddisfatti" (0-100).

### Follow-up

Tutti i pazienti sono stati arruolati in un programma di richiamo di igiene dentale semestrale e follow-up annuale. Gli esami radiografici clinici e intraorali sono stati eseguiti dopo un anno di carico (follow-up).

La valutazione del FIPS è stata completata da un protesista esperto per tutti i pazienti al baseline e al follow-up di 1 anno. Inoltre, la soddisfazione del paziente è stata valutata con un questionario che copre due questioni centrali relative alla ricostruzione dell'impianto. La domanda 1 (Q1) si è concentrata sui risultati del trattamento e cioè su come le aspettative generali dei pazienti fossero state soddisfatte. La seconda domanda (Q2) riguardava specificamente la soddisfazione dei pazienti da un punto di vista funzionale. Entrambe le domande includevano una scala analogica visiva (VAS) che andava da "insoddisfatti" a "completamente soddisfatti" (0-100). Qui, i pazienti potevano segnare separatamente il loro grado personale di soddisfazione per Q1 e Q2.

### Analisi statistica

Le statistiche descrittive del FIPS sono state calcolate per mediane e quartili Q25-Q75 e punteggi medi compresi le deviazioni standard (SD), i valori minimo e massimo

(min-max). È stata eseguita un'analisi di regressione lineare per rilevare eventuali correlazioni significative tra i punteggi FIPS totali e i risultati soggettivi delle risposte VAS dei pazienti a Q1 e Q2.

Un livello di significatività è stato fissato a  $P < 0,05$ . I calcoli statistici sono stati effettuati con il programma open source "GraphPad Software" (<http://www.Graphpad.com>) (Tabella 1, 2, 3).

### RISULTATI

I tassi di sopravvivenza per tutti gli impianti e le ricostruzioni protesiche sono stati del 100%. Nessuna complicanza tecnica o biologica è stata osservata durante il follow-up.

Gli esami clinici hanno mostrato punteggi medi full-mouth per PI di  $20,4 \pm 2,5$  (range: 16-22) a baseline e  $19,5 \pm 1,2$  (range: 16-22) al follow-up a 1 anno, PPD di  $3,6 \pm 0,4$  mm (range: 1-4) e  $3,4 \pm 0,4$  mm (range: 1-4), e un punteggio medio per BoP di  $21,2 \pm 2,5$  (range: 17-24) e  $19,8 \pm 1,2$  (range: 16-23), rispettivamente.

Il punteggio medio FIPS totale era di  $8,6 \pm 1,1$  (range: 6-10). In dettaglio, tutti gli impianti hanno mostrato un

Treatment assignment was noted in the registration and treatment assignment form that was kept by the study. Allocation concealment was performed by opaque sealed, sequentially numbered envelopes. The statistician made the allocation sequence by means of a computer-generated random list and instructed a different subject to assign a sealed envelope containing the type of IOS. The opaque envelope was opened before implant system selection and communicated to the operator. At the one-year recall blinding of the examiner was applied.

All crowns were produced in a mixed traditional - impressions were made using Vinyl Polyether Silicone impression material (EXA'lence, GC), and then were poured on dental die stone (FujiRock, GC) - and digital lab workflow, the casts were scanned with a lab scanner (Aadva Lab Scan, GC), CAD/CAM-

processed with individualized titanium abutments, zirconia copings (Aadva zirconia, GC), plus manually veneered zirconia suprastructures (Initial, GC). Each single titanium abutment was screwed with a maximum torque of 35 Ncm according to the manufacturer's instructions and the final crowns were luted with temporary cement (TempBond NE, Kerr Dental, Rastatt, Germany).

#### Follow-up

All patients were enrolled in a dental hygiene recall program every 6 months and annual follow-up. Clinical and intraoral radiographic examinations were performed immediately after one year of loading (follow-up).

The FIPS evaluation was completed by an experienced prosthodontist for all patients at baseline and 1-year

follow-up. Also, patient satisfaction was evaluated with a questionnaire covering two central issues related to the implant reconstruction. Question 1 (Q1) focused on the treatment result on how the patients' general expectations had been fulfilled. The second question (Q2) addressed specifically the patients' satisfaction from a functional point of view. Both questions included a visual analogue scale (VAS) ranging from "unsatisfied" to "fully satisfied" (0-100). Here, the patients could separately mark their personal degree of satisfaction for Q1 and Q2.

#### Statistical analysis

Descriptive statistics of FIPS were calculated for medians and quartiles Q25-Q75 as well as mean scores including standard deviations (SD), minimum and maximum (min-max) values.

Ferrari Cagdiaco E. et al.

livello stabile della cresta alveolare senza segni di perdita ossea all'analisi radiografica. Pertanto, la variabile "osso" ha dimostrato i risultati più coerenti e i punteggi più alti con un valore medio di  $2 \pm 0$ . Allo stesso modo il punteggio medio è stato registrato per la variabile "occlusione"  $2.0 \pm 0$ .

Al contrario, i punteggi medi per "design"  $1,9 \pm 0,7$  (range: 0-2), "mucosa"  $1,8 \pm 0,4$  (range: 1-2) e "interprossimale"  $1,7 \pm 0,4$  (range: 1-2) sono stati più impegnativi da soddisfare (Tabella 2).

I calcoli delle mediane e del quantile Q25-Q75 nonché il punteggio FIPS medio per ciascuna delle cinque variabili, comprese le deviazioni standard e i valori minimo e massimo, sono riepilogati nella Tabella 3.

I due questionari hanno riguardato la soddisfazione dei pazienti in base al risultato del trattamento. Il primo si concentrava sull'adempimento delle aspettative generali dei pazienti. Q2 ha chiesto esplicitamente la soddisfazione complessiva dei pazienti in base alla funzionalità delle corone implantari.

Tutti i pazienti hanno segnato un livello di soddisfazione pari o superiore al 65% sulla VAS per entrambe le domande. Il punteggio medio di Q1 era  $79,0 \pm 1,5$  (mediana: 78,8; Q25-Q75: 70-92; intervallo: 65-100) e  $80,5 \pm 2,5$  per Q2 (mediana: 80,3; Q25-Q75: 73-95; intervallo: 65-100).

L'analisi di regressione lineare ha mostrato una correlazione statisticamente significativa tra il punteggio FIPS totale e la risposta VAS di Q1 e Q2. È stata trovata una moderata correlazione tra FIPS e Q1 e FIPS e Q2, con un coefficiente di 0,82 e 0,80 ( $P < 0,0001$ ) rispettivamente.

## DISCUSSIONE

È stata recentemente proposta la possibilità di valutare in modo selettivo l'integrazione funzionale dei restauri su impianto singolo con un punteggio oggettivo, affidabile

e rapidamente applicabile e che consente di razionalizzare la soddisfazione del paziente, identificare potenziali rischi di insuccesso in una fase precoce del trattamento e confrontare la manutenzione (9-11).

Il FIPS sembra essere più facile e più affidabile da applicare rispetto ad altri criteri che sono stati proposti in passato (18-20). Alcuni di essi mescolano diversi parametri, come la mobilità dell'impianto, la radiotrasparenza e la sostanziale perdita di tessuto osseo, il sanguinamento e la suppurazione, l'insorgenza di fallimenti meccanici e l'estetica. Tuttavia, il successo di un restauro su impianto singolo dovrebbe idealmente considerare l'esito a lungo termine dell'intero complesso implantoprotesico nel suo insieme.

Il FIPS può essere generalmente accettato e considerato ben consolidato come strumento di valutazione affidabile attraverso la formulazione di un punteggio fondendo i risultati clinici e radiografici per la valutazione dei restauri implantari (nei siti posteriori) (9-11). Infatti, il FIPS è uno strumento di valutazione diagnostica che può essere utile, facile da usare, rapido e riproducibile e implica una rilevanza clinica per il dentista.

Il presente studio ha confermato l'applicabilità clinica del FIPS. Questo nuovo punteggio funzionale è definito da sole cinque variabili. Al contrario, gli indici estetici utilizzano schemi di punteggio molto più complessi con 10 fino a 15 sottocategorie di valutazione diverse (4-8, 21-23). L'applicabilità semplice del FIPS è utile per studi clinici randomizzati a lungo termine ed è usato anche da un ampio numero di clinici.

Questo studio clinico prospettico ha valutato i risultati funzionali di un lavoro tradizionale e digitale misto per fabbricare corone su impianto singolo su tre diversi impianti dopo un anno di carico utilizzando il FIPS. Si può considerare che la reazione del tessuto gengivale agli insulti infiammatori come il posizionamento di un restauro di una singola unità, può determinare entro un anno alcune reazioni sfavorevoli; la presenza di un leggero mi-

A linear regression analysis was performed for the detection of any significant correlations between the total FIPS scores and the subjective results of the patients' VAS responses to Q1 and Q2.

A level of significance was set at  $P < 0.05$ . Statistic calculations were made with the open-source program "GraphPad Software" (<http://www.graphpad.com>) (Table 1, 2, 3).

## RESULTS

Survival rates for all implants and connected prosthodontic reconstructions were 100%. No technical or biological complications were observed during follow-up.

Clinical examinations exhibited mean full-mouth scores for PI of  $20.4 \pm 2.5$  (range: 16-22) at baseline and  $19.5 \pm 1.2$  (range: 16-22) at 1-year follow-up, PPD of  $3.6 \pm 0.4$  mm (range: 1-4) and  $3.4 \pm 0.4$  mm (range: 1-4), and a mean score for BoP of  $21.2 \pm 2.5$  (range: 17-24) and  $19.8 \pm 1.2$  (range: 16-23), respectively.

The mean total FIPS score was  $8.6 \pm 1.1$  (range: 6-10). In detail, all implants showed a stable level of the alveolar crest without any signs of bone loss in the radiographic analysis. Therefore, the variable "bone" demonstrated the most consistent results and highest scores with a mean value of  $2 \pm 0$ .

Similarly mean score was recorded for the variable "occlusion"  $2.0 \pm 0$ .

In contrast, mean scores for "design"  $1.9 \pm 0.7$  (range: 0-2),

"mucosa"  $1.8 \pm 0.4$  (range: 1-2), and "interproximal"  $1.7 \pm 0.4$  (range: 1-2) were the most challenging to satisfy (Table 2).

Calculations of medians and quantil Q25-Q75 as well as mean total FIPS scoring for each of the five variables, including standard deviations and minimum and maximum values, are summarized in Table 3.

The two questionnaires addressed the patients' satisfaction according to the treatment outcome. Q1 focused on the fulfillment of the patients' general expectations. Q2 asked explicitly for the overall patients' satisfaction according to the functionality of the implant crowns.

All patients marked their level of satisfaction at or above 65% on the VAS for both questions. The mean score of Q1 was  $79.0 \pm 1.5$  (median: 78.8; Q25-Q75: 70-92; range: 65-100), and  $80.5 \pm 2.5$  for Q2 (median: 80.3; Q25-Q75: 73-95; range:

## JO

Functional Implant Prosthodontic Score nella valutazione dei risultati di riabilitazioni su impianto singolo

gioramento degli indici parodontali in combinazione con qualsiasi perdita ossea può essere un segno favorevole di una buona integrazione dei restauri al singolo impianto. Le ipotesi nulle testate erano che, valutando i restauri a singolo impianto con il FIPS, ci sarebbero state differenze tra connessioni esagonali e coniche; e tra le tre connessioni testate; entrambe le ipotesi sono state respinte: non sono state riscontrate differenze tra il tipo di connessioni dell'abutment e tra i tre sistemi implantari testati. Ciò può essere dovuto alle elevate prestazioni riportate per entrambi i tipi di connessioni (24), alla corretta selezione dei casi, alle procedure chirurgiche e protesiche ben eseguite e al corretto mantenimento dell'igiene orale domiciliare (25-26); le due ipotesi nulle saranno rivalutate e riportate a medio e lungo termine. Sebbene l'osservazione a breve termine e il numero limitato di campioni di ciascun gruppo possano essere considerati limiti importanti di questo studio, dopo il follow-up annuale è prevista un'osservazione più lunga in un numero più ampio di pazienti.

L'analisi riassuntiva delle variabili "interprossimale", "occlusione", "design", "mucosa" e "osso" ha rivelato un punteggio medio alto di 8,6 su 10, con un intervallo relativamente ristretto (SD: 1,1), che indica una valutazione precisa e affidabile del FIPS all'interno di questi gruppi. Sebbene, in condizioni ottimali, le variabili definite del FIPS risultino in un punteggio inferiore a 10, tutti i restauri con singolo impianto esaminati hanno sempre mostrato un punteggio medio di  $\geq 6$ , che può essere interpretato come esito del trattamento (funzionale) di successo.

Un altro aspetto importante era che la soddisfazione dei pazienti è stata soggettivamente elevata rispetto al risultato del trattamento previsto in generale. La soddisfazione dei pazienti riflette le loro aspettative, confermando che la loro percezione può corrispondere alla FIPS. Certamente, il metodo utilizzato per valutare la percezione dei pazienti (VAS) potrebbe essere migliora-

to, sebbene in questa forma sia molto facile da applicare, ripetibile e affidabile (9).

## CONCLUSIONI

I risultati di questo studio clinico randomizzato hanno indicato il potenziale di entrambe le connessioni coniche ed esagonali nel funzionare molto bene dopo 1 anno. Il FIPS ha dimostrato di essere uno strumento oggettivo e affidabile nella valutazione del successo del restauro su un singolo impianto.

## BIBLIOGRAFIA

1. Pjetursson BE, Asgeirsson AG, Zwahlen M, Sailer I. Improvements in implant dentistry over the last decade: comparison of survival and complication rates in older and newer publications. *Int J Oral Maxillofacial Implants* 2014; 29(Suppl.): 308–324.
2. Papaspyridakos P, Chen CJ, Singh M, Weber HP, Gallucci GO. Success criteria in implant dentistry: a systematic review. *J Dental Res* 2012; 91: 242–248.
3. Sadid-Zadeh R, Kutkut A, Kim H. Prosthetic failure in implant dentistry. *Dent Clin North Am* 2015; 59: 195–214.
4. Furhauser R, Florescu D, Benesch T, Haas R, Mailath G, Watzek G. Evaluation of soft tissue around single-tooth implant crowns: the pink esthetic score. *Clin Oral Implants Res* 2005; 16: 639–644.
5. Meijer HJ, Stellingsma K, Meijndert L, Raghoobar GM. A new index for rating aesthetics of implant-supported single crowns and adjacent soft tissues—the implant crown aesthetic index. *Clin Oral Implants Res* 2005; 16: 645–649.
6. Belser UC, Grutter L, Vailati F, Bornstein MM, Weber HP, Buser D. Outcome evaluation of early placed maxillary anterior single-tooth implants using objective esthetic criteria: a cross-sectional, retrospective study in 45 patients with a 2- to 4-year follow-up using pink and white esthetic scores. *J Periodontol* 2009; 80: 140–151.
7. Juodzbalys G, Wang HL. Esthetic index for anterior maxillary implant-supported restorations. *J Periodontology* 2010; 81: 34–42.
8. Tettamanti S, Millen C, Gavric J, Buser D, Belser UC, Bragger U, Wittneben JG. Esthetic evaluation of implant crowns and peri-implant soft tissue in the anterior maxilla: comparison and reproducibility of three different indices. *Clin Implant Dent Related Research* 2016; 18: 517–526.

65–100).

The linear regression analysis showed a statistically significant correlation between the total FIPS score and the VAS response of Q1 and Q2. A moderately correlation was found between FIPS and Q1 and FIPS and Q2, with a coefficient of 0.82 and 0.80 ( $P < 0.0001$ ) respectively.

## DISCUSSION

The possibility to selectively assess the functional integration of single-implant restorations with an objective, reliable, and quickly applicable score was recently proposed and permits to rationalize patient's satisfaction, to identify potential failure risks at an early stage of the treatment and to compare

follow-up maintenance (9-11).

FIPS seems to be easier and more reliable to be applied than other criteria that have been proposed in the past (18-20). Some of them were mixing different parameters, such as mobility of the implant, radiolucency and substantial bone loss, bleeding and suppuration, the occurrence of technical failures, and esthetics. However, success of a single-implant restoration should ideally consider the long-term outcome of the entire implant-prosthodontic complex as a whole. FIPS can be now generally accepted and well-established as a reliable assessment tool estimating a score by merging clinical and radiographic findings for the evaluation of implant restorations (in posterior sites) (9-11). In fact, FIPS is an outcome assessment tool that can be helpful, is easy to use, quickly and reproducibly applicable, and implies a

clinical relevance for the dentist. The present trial confirmed the applicability of FIPS. This novel functional score is defined by only five variables. In contrast, esthetic indices use much more complex scoring schemes with 10 up to 15 different subcategories of assessment (4-8, 21-23). The ease applicability of FIPS is useful for long term randomized clinical trials and its use also by a wide number of clinicians. This prospective clinical study evaluated the functional outcomes of a mixed traditional and digital workflow to fabricate single-implant crowns on three different implants after one year of loading using FIPS. It can be considered that the reaction of gingival tissue at inflammatory insults such as a placement of a single-unit restoration, can determine within one year of clinical service some unfavorable reactions; the presence of a slight improvement of periodontal indices

9. Joda T, Ferrari M, Bragger U. A prospective clinical cohort study analyzing single-unit implant crowns after three years of loading: introduction of a novel Functional Implant Prosthodontic Score (FIPS). *Clin Oral Implants Res* 2017 Oct;28(10):1291-1295.
10. Joda T, Zarone F, Zitzmann NU, Ferrari M. The Functional Implant Prosthodontic Score (FIPS): assessment of reproducibility and observer variability *Clinical Oral Investig* 2018 Jul;22(6):2319-2324.
11. Joda T, Ferrari M, Bragger U. Monolithic implant-supported lithium disilicate (LS2) crowns in a complete digital workflow: A prospective clinical trial with a 2-year follow-up. *Clin Implant Dent Relat Res* 2017; 1-7.
12. Pinheiro Feitosa PC, Barbosa de Lima AP, Silva-Concilio LR, Brandt WC. Stability of external and internal implant connections after a fatigue test *Eur J Dent* 2013;7: 267-271.
13. Machado LS, Bonfante EA, Anchieta RB, Yamaguchi S, Coelho PG. Implant-abutment connection designs for anterior crowns: reliability and failure modes. *Implant Dent* 2013;22:540-5.
14. Mokhtar MA, Elnagar G, Saleh M, Radwan MM. The biological complication of implant abutment materials. A systematic review and meta-analysis. *J Osseointegr* 2018; 10 (1): 23-30 .
15. Fujiwara CA, Magro Filho O, Oliveira NT, Pereira Queiroz T, Sabagg Abila M, Luiz Pardini C. Assessment of the interface between implant and abutments of five systems by scanning electronic microscopy. *J Osseointegr* 2009; 1(2): 60-66.
16. Loe H, Silness J. Periodontal disease in pregnancy. I Prevalence and severity. *Acta Odont Scand* 1963;21:533-551.
17. Ainamo J, Bay I. Problems and proposals for recording gingivitis and plaque. *Int Dent J* 1975; 25: 229-235.
18. Chen ST, Buser D. Clinical and esthetic outcomes of implants placed in post extraction sites. *Int J Oral Maxillofacial Implants* 2009; 24(Suppl.): 186-217.
19. Fuentealba R, Jofre J. Esthetic failure in implant dentistry. *Dent Clin North Am* 2015; 59: 227-246.
20. Le M, Papia E, Larsson C. The clinical success of tooth- and implant-supported zirconia-based fixed dental prostheses. A systematic review. *J Oral Rehabilitation* 2015; 42: 467- 480.
21. Gehrke P, Degidi M, Lulay-Saad Z, Dhom G. Reproducibility of the implant crown aesthetic index-rating aesthetics of single- implant crowns and adjacent soft tissues with regard to observer dental specialization. *Clin Implant Dent Relat Res* 2009; 11: 201- 213.
22. Vaidya S, Ho YL, Hao J, Lang NP, Mattheos N. Evaluation of the influence exerted by different dental specialty backgrounds and measuring instrument reproducibility on esthetic aspects of maxillary implant-supported single crown. *Clin Oral Implants Res* 2015; 26: 250-256.
23. Levine RA, Nack G. Team treatment planning for the replacement of esthetic zone teeth with dental implants. *Compendium Continuing Education in Dentistry* 2011; 32: 44-50.
24. Gracis S, Michalakis K, Vigolo P, Vult von Steyern P, Zwahlen M, Sailer I. Internal vs. external connections for abutments/reconstructions: a systematic review. *Clin Oral Implants Res* 2012 Oct;23 Suppl 6:202-16
25. Ciancio SG, Lauciello F, Shibly O, Vitello M, Mather M. The effect of an antiseptic mouthrinse on implant maintenance: plaque and peri-implant gingival tissues. *J Periodontol* 1995; 66, 11: 962-5.
26. Kracher CM, Smith WS. Oral health maintenance dental implants. *Dent Assist* 2010;79:27-35.

in combination with any bone loss can be a favorable sign of good integration of single-implant restorations. The null hypotheses tested were that, scoring the single-implant restorations with FIPS, there were differences between hexagon and conical connections and among the three tested connections; both were rejected: no differences were found between the type of abutment connections and among the three tested implant systems. That can be due to the high performances reported for both types of connections (24), the proper selection of the cases, the well performed surgical and prosthodontic procedures as well as the proper maintenance of home oral hygiene (25-26); the two null hypotheses will be reevaluated and reported along further recalls. Although the short-term observation and the limited number

of samples of each group can be considered important limitations of this study, a longer observation in a wider number of patients is planned after the three-year follow up. The summarized analysis of the variables "inter-proximal," "occlusion," "design," "mucosa," and "bone" revealed a high mean total score of 8.6 of 10 with a relatively narrow range (SD: 1.1), indicating a precise and reliable assessment of FIPS within these groups. Although under optimal conditions, the defined variables of FIPS result in a top score of 10, all examined single-implant restorations always showed a mean score of  $\geq 6$ , which can be interpreted as a successful (functional) treatment outcome. Another important aspect was that the patients' satisfaction was subjectively high with respect to the expected treatment outcome in general. The patients' satisfaction reflected

their expectations, confirming that their perception can correspond to the FIPS. Certainly, the method used to evaluate patients' perception (VAS) might be improved although in this form it is very easy to be applied, repeatable and reliable (9).

#### CONCLUSIONS

The findings of this randomized clinical trial indicated the potential of both conical and hexagon connections to perform very well after 1 year of clinical service. FIPS showed to be an objective and reliable instrument in assessing single-implant restoration success.

## Sealing effectiveness against *Staphylococcus aureus* of five different implant-abutment connections

NICOLA DISCEPOLI, DDS, MS, PHD, EDOARDO FERRARI CAGIDIACO, DDS, GIULIA LANDINI, DDS, LUCIA PALLECCHI, DDS, FRANKLIN GARCIA-GODOY, DDS, MS, PHD, PHD & MARCO FERRARI, MD, DDS, PHD

**ABSTRACT: Purpose:** To compare the sealing effectiveness of four different implant-abutment connections against *Staphylococcus aureus* (*S. aureus*). The null hypotheses stated that there was no difference on sealing ability among the implant-abutment connections tested. **Methods:** Five diverse commercially available dental implants were used to investigate the degree of microleakage at the implant-abutment junction (IAJ): Group 1: Torque Type conical implant with double conic connection - TTc (Winsix); Group 2: Torque Type conical implant with Cone Morse connection - TTcm (Winsix); Group 3: Free Lock connection - K type implant (Winsix); Group 4: Internal double hexagon - OsseoSpeed; Group 5: Internal hexagon - Aadv Implant. Nine implants were tested in each group and one group was used as the negative control (Group 4). The abutments were connected to implants according to manufacturers' recommendations. All procedures involving connection and disconnection of implants were performed in sterile conditions in a laminar flow biological safety cabinet. *S. aureus* ATCC 6538, a methicillin susceptible reference strain, was chosen for the experiments to test the degree of microleakage. Statistical analysis was performed in order to find significant differences among the five groups regarding sealing capability of the implant-abutment connections tested. The recorded data were statistically analyzed. **Results:** One implant from Group 4 was excluded from the study because of the growth of a contaminant after 48 hours of incubation in all three wells (i.e. *Paenibacillus pabuli*, environmental Gram-positive bacteria). Wells A and B (i.e. wells where the samples were passed before being located in the final well C) of all other samples (n = 46) remained sterile over the 72 hours of incubation, indicating the lack of external contamination during implant-abutment connection. Similarly, no bacterial growth was observed in the five negative controls (i.e. one implant for each type), which had been inoculated with sterile saline and processed as the others. Bacterial microleakage was demonstrated with three samples, including one sample of Group 1, one of Group 3 and one of Group 5, in which growth of *S. aureus* in wells C after 48 hours of incubation was demonstrated (Table 1). No statistically significant difference between groups was noticed ( $P > 0.05$ ). (*Am J Dent* 2018;31:141-143).

**CLINICAL SIGNIFICANCE:** Within the limitations of the present in vitro model, the results obtained suggest a tendency toward a better sealing capability for conical connections and internal hexagon.

✉: Prof. Dr. Marco Ferrari, Research Center for Dentistry, Piazza Attias, 19, Livorno 57125, Italy. E-✉: ferrarimar@unisi.it

### Introduction

Over the past decades, the placement of dental implants has become a routine procedure in the oral rehabilitation of fully and partially edentulous patients. However, biological complications "biofilm promoted" (i.e. mucositis and peri-implantitis) are an increasing clinical scenario. Biofilms can develop successfully around several components/surface of titanium implants. Bacteria and calculus are able to challenge the soft tissue around the implant and so provoke a connective tissue inflammatory infiltrate, potentially producing bone resorption of the surrounding peri-crestal hard tissue. Evidence exists<sup>1</sup> that microorganisms can harbor in the implant-abutment junction (IAJ) defined as the space between implant assemblies (i.e. microgap) and represent a potential reservoir for threatening microflora.

Several bacteria mimicking well-established periodontitis biofilm have been associated to peri-implant diseases;<sup>1</sup> thus *S. aureus*, a pathogen not commonly considered in periodontal microbiological research,<sup>2</sup> is known to have the ability to attach to almost any type of titanium surface<sup>3</sup> and consequently potentially facilitate an early adhesion of more pathogenic anaerobic bacteria (*P. gingivalis* and *P. intermedia*), leading to infection of peri-implant tissue.<sup>4,5</sup>

In vitro studies<sup>6</sup> assessed the impact of IAJ design on the amount of microbial penetration into the internal part of the

implant: the design of the IAJ can have an impact on the amount and quality of biofilm, influencing the early biological phase of the peri-implant tissue formation after implant installation. Internal Morse-taper connection has shown a minimal internal contamination both in dynamic loading<sup>7</sup> and non-loading conditions.<sup>8</sup> To our knowledge, no information is available in the literature regarding the design of a new model of IAJ (Winsix<sup>®</sup>).

Therefore, the present investigation utilized an in vitro model to assess the quantity of microbial penetration by strains of *S. aureus* of five commercially available types of implant abutment-junction. The null hypotheses was that there would be no difference on bacteria sealing capacity among the implant-abutment combinations tested.

### Materials and Methods

Five different commercially available dental implants were used to investigate the degree of microleakage at the implant-abutment junction (IAJ):

- Group 1: Torque Type conical implant with double conic connection - TTc (Winsix<sup>®</sup>);
- Group 2: Torque Type conical implant with Cone Morse connection - TTcm (Winsix<sup>®</sup>);
- Group 3: Free Lock connection - K type implant (Winsix<sup>®</sup>);
- Group 4: Cone Morse connection, double internal hexagon - (OsseoSpeed<sup>®</sup>);
- Group 5: Double internal hexagon - (Aadv Implant<sup>®</sup>).

Table. Representation of the type of implant-abutment combinations, the results of the bacteria leakage and the corresponding statistical analysis (the groups with the same alphabetic letter did not show statistically significant differences) (Group 1: TTc (BioSAFin); Group 2: TTcm (BioSAFin); Group 3: K (BioSAFin); Group 4: Osseospeed (AstraTech)).

Group	Sample (n=9)	Microleakage	Absence of microleakage + bacterial viability	Absence of microleakage + no bacterial viability	Contamination
Group 1a	9	1	8	0	0
Group 2a	9	0	7	2	0
Group 3a	9	1	7	1	0
Group 4a	9	0	9	0	0
Group 5a	9	1	8	1	0
Total	45	3	39	4	0

Nine implants were tested in each group. The abutments were connected to implants according to manufacturers' recommendations. Non-sterile materials (i.e. abutments of Winsix, Astratech, and GC Tech implants) were sterilized in an autoclave before use. All procedures involving connection and disconnection of implants were performed in sterile conditions (e.g. sterile gloves, sterile disposable labware, sterile reagents) in a laminar flow biological safety cabinet.

*Staphylococcus aureus* ATCC 6538, a methicillin susceptible reference strain, was chosen for the experiments to test the degree of microleakage at the level of IAJ. Indeed, *S. aureus* may colonize dental implants at an early stage after implant, and may be responsible for peri-implantitis.<sup>11</sup> Overnight cultures of *S. aureus* ATCC 6538 onto Tryptic Soy Agar (TSA<sup>d</sup>) were used to prepare a suspension of about  $1 \times 10^8$  colony forming units (CFU/ml) in sterile saline (i.e. by adjusting turbidity to 0.5 McFarland), and 3  $\mu$ l (corresponding to about  $3 \times 10^5$  CFU) were used for inoculating the inner part of 36 implants (nine implants of each type). Negative controls (one for each type of implant) were represented by implants inoculated with 3  $\mu$ l of sterile saline and processed as the others. After proper connection of the implants, sterile pads soaked in 1.15% sodium hypochlorite were used to carefully clean the external parts of the implants. Residual sodium hypochlorite was removed by generously rinsing the implants with sterile saline. Microleakage experiments were performed in six-well polystyrene tissue culture plates (Iwaki microplate<sup>e</sup>) dispensed with 5 ml of Tryptic Soy Broth (TSB). Each implant was subjected to immersion in three consecutive wells: first they were located in well A for 2 minutes, then transferred into well B for an additional 2 minutes, and finally they were transferred and left in well C. The plates were incubated for up to 72 hours at 37°C in static condition, and inspected every 24 hours for bacterial growth. The rationale for the passages in wells A and B was to detect a possible contamination of the external part of the implants occurring during implant-abutment connection. In this perspective, development of bacterial growth in wells A and B was considered suggestive of external contamination of implants, while bacterial growth in well C was considered suggestive of microleakage at the IAJ. Experimentally, in case of bacterial growth in any of the three test wells, an aliquot of culture broth was used to inoculate a TSA plate and proceed to bacterial identification by the MALDI-TOF MS<sup>f</sup> system. After 72 hours of incubation, implants were removed from all wells C that did not show bacterial growth, and processed to verify viability of bacterial inoculum. For this purpose, implants were disconnected and 5  $\mu$ l of sterile saline were used to recover initial bacterial inoculum, which was then plated onto TSA for bacterial viability confirmation and identification.

confirmation and identification.

The recorded data were statistically analyzed with SPSS<sup>g</sup> software (vers. 13.0). The Kolmogorov-Smirnov test was used to verify the normality of data distribution. The leakage values were analyzed with the one-way ANOVA followed by the Kruskal-Wallis on ranks test for multiple comparisons. For all the statistical tests, the level of significance was set at  $P=0.05$ .

## Results

One implant from AstraTech was excluded from the study because of the growth of a contaminant after 48 hours of incubation in all the three wells (i.e. *Paenibacillus pabuli*, environmental Gram-positive bacteria) (Table). Wells A and B of all other samples ( $n=44$ ) remained sterile over the 72 hours of incubation, indicating the lack of external contamination during implant-abutment connection (Table). Similarly, no bacterial growth was observed in the five negative controls (i.e. one implant for each type), which had been inoculated with sterile saline and processed as the others.

Bacterial microleakage was demonstrated in three samples (i.e. 3 out of 35, 9%), including one TTc, one K and one GC, which showed growth of *S. aureus* in wells C after 48 hours of incubation (Table).

After the 72-hour incubation period, all 41 implants that gave negative results for bacterial translocation (i.e. no bacterial growth in wells C) were disassembled to check for bacterial viability and *S. aureus* identification. *S. aureus* growth was obtained from 39 of them (86%) (Table). In particular, of the four implants from which viable *S. aureus* cells could not be recovered, three were from BioSAFin (2/9 TTcm, and 1/9 K) (Table).

No statistically significant difference was found among the five tested groups.

## Discussion

The rough results obtained were influenced by the type of IAJ tested: no bacterial microleakage was recovered in presence of the Cone Morse connection (TTcm BioSAFin; Conical seal Astra Tech; GC Tech).

The rationale to use colonies of *S. aureus* for the present investigation was the biological role that this aerobic bacterium has during the initial phase of biofilm development on titanium implant surface. It is an initial colonizer with a strong affinity to attach to other pathogenic bacteria as well as almost any type of titanium surface.<sup>3</sup>

The main purpose of the current experimental protocol was to assess quantitatively the presence of *S. aureus* within the implant-abutment connections. The degree of microleakage



varied between 20% of the specimens (TTC BioSAfin) and 0% (TTcm BioSAfin and Astra). The internal hexagon free lock (K, BioSAfin) displayed 10% contamination.

Jaworsky et al<sup>9</sup> compared external and internal abutment connection under non-loading conditions, in terms of microleakage by *E. coli*, after an experimental period of 3 weeks. Cone Morse connection resulted in half the microbial leakage compared to external hexagon (30% of specimens vs 60%). The magnitude of microleakage described by Jaworsky et al<sup>9</sup> is different from the results obtained in the present investigation. The difference could be due to several factors: the microleakage potential of the bacterial strains used (*S. aureus* vs *E. coli*), the different technique used to obtain the experimental chamber and the different incubation periods used (72 hours vs 14 days).

In a similar in vitro study, Tripodi et al<sup>10</sup> evaluated the degree of microleakage of Cone Morse tapered implants. After an incubation period of 13 days, in which all specimens were contaminated by a suspension of *E. faecalis*, 20% of implant-abutment assemblies resulted contaminated. This result is slightly higher in magnitude than that observed in the present investigation. The longer experimental period used by Tripodi et al<sup>10</sup> could have jeopardized the sealing ability of the IAJ tested. Actually, one could speculate that with a longer experimental period of incubation, even the results obtained in this experiment could be of greater magnitude. Selecting colonies of *S. aureus* as a benchmark for the process of microleakage allowed us to use a shorter assessment period, by virtue of *S. aureus* adhesion characteristics and its own specific role in the early stages of biofilm formation. Furst et al<sup>11</sup> analyzed the levels of microbial contamination of titanium implants immediately after implant placement and throughout the first 12 post-surgical weeks. The quantity of *S. aureus* encountered was almost the same value detected immediately after the surgery, showing that this bacterium is able to quickly colonize the implant surface.

The current in vitro experiment was carried out without any loading forces on the implant-abutment system. Actually, how much the loading process could influence the IAJ, and consequently the degree of microleakage is still debatable. Loading forces applied to the IAJ complex could mimic bending forces that characterize the implant abutment complex during function. The reason not to apply loading forces to the present in vitro model was partially based on recent published data<sup>8,10</sup> in which loading forces did not alter the quantity of bacterial microleakage irrespective of the type of IAJ connection studied. This data are in contrast with a previous investigation,<sup>12</sup> where after a 7-day period of saliva incubation, loaded and unloaded implants were tested for microleakage. The results obtained assessed that loaded implants displayed higher values of bacterial contamination.

One interesting aspect that arose from the results obtained was the viability of bacteria detected after the 72 hours of incubation. Three samples showed no viable microbial colonies inside the IAJ. Conversely, among the test groups, bacteria colonies detected were vital. This phenomenon could be related either to the entry of sodium hypochlorite into the inner part of

the implants during the procedures for external decontamination, or to the overflow and washing out of bacterial suspension during the following steps of lavages with sterile saline.

In conclusion, within the limitations of the present in vitro model, bacterial microleakage of *S. aureus* after 72 hours of contamination seemed to be independent of the type of IAJ, and all IAJ were effective in preventing bacteria penetration.

- a. BioSAFin, Ancona, Italy.
- b. Dentsply Astra Tech, Molndal, Sweden.
- c. GC Tech, Tokyo, Japan.
- d. Oxoid, Milan, Italy.
- e. Bibby Scientific Limited, Staffordshire, UK.
- f. BioMérieux Inc., Marcy l'Étoile, France.
- g. SPSS Inc., Chicago, IL, USA.

*Disclosure statement:* The authors declared no conflict of interest.

Dr. Discepoli is Assistant Professor, Department of Periodontics, University of Siena, Siena, Italy. Dr. Ferrari Cagidiaco is a Ph D Student, University of Siena, Italy. Dr. Landini, is a PhD student; Dr. Pallecchi is Associate Professor, Department of Microbiology, University of Siena, Italy. Dr. Garcia-Godoy is Professor and Chair, Department of Bioscience Research and Director, Bioscience Research Center College of Dentistry, College of Dentistry, University of Tennessee Health Science Center, Memphis, Tennessee, USA, and Senior Clinical Investigator, The Forsyth Institute, Cambridge, Massachusetts, USA. Dr. Ferrari is Dean, Professor and Chair, Department of Prosthodontics and Dental Materials, University of Siena, Siena, Italy, and Professor, School of Dentistry, University of Leeds, Leeds, UK.

## References

1. Renvert S, Lindahl C, Renvert H, Persson GR. Clinical and microbiological analysis of subjects treated with Brånemark or AstraTech implants: A 7-year follow-up study. *Clin Oral Implants Res* 2008;19:342-347.
2. Kronström M, Svenson B, Hellman M, Persson GR. Early implant failures in patients treated with Brånemark System titanium dental implants: A retrospective study. *Int J Oral Maxillofac Implants* 2001;16:201-207.
3. Harris LG, Richards RG. Staphylococcus aureus adhesion to different treated titanium surfaces. *J Mater Sci Mater Med* 2004;15:311-314.
4. Kuula H, Könönen E, Lounatmaa K, Kontinen YT, Könönen M. Attachment of oral gram-negative anaerobic rods to a smooth titanium surface: An electron microscopy study. *Int J Oral Maxillofac Implants* 19;803-809.
5. Botero JE, González AM, Mercado RA, Olave G, Contreras A. Subgingival microbiota in peri-implant mucosa lesions and adjacent teeth in partially edentulous patients. *J Periodontol* 2005;76:1490-1495.
6. Silva-Neto JP da, Prudente MS, Carneiro T de APN, Nóbilo MA de A, Penatti MPA, Neves FD das. Micro-leakage at the implant-abutment interface with different tightening torques in vitro. *J Appl Oral Sci* 20:581-587.
7. Tesmer M, Wallet S, Koutouzis T, Lundgren T. Bacterial colonization of the dental implant fixture-abutment interface: An in vitro study. *J Periodontol* 2009;80:1991-1997.
8. Koutouzis T, Mesia R, Calderon N, Wong F, Wallet S. The effect of dynamic loading on bacterial colonization of the dental implant fixture-abutment interface: An in vitro study. *J Oral Implantol* 2014;40:432-437.
9. Jaworski ME, Melo ACM, Picheth CMT, Sartori IA de M. Analysis of the bacterial seal at the implant-abutment interface in external-hexagon and Morse taper-connection implants: An in vitro study using a new methodology. *Int J Oral Maxillofac Implants* 2012;27:1091-1095.
10. Tripodi D, D'Ercole S, Iaculli F, Piattelli A, Perrotti V, Iezzi G. Degree of bacterial microleakage at the implant-abutment junction in Cone Morse tapered implants under loaded and unloaded conditions. *J Appl Biomater Funct Mater* 2015;13:e367-e371.
11. Fürst MM, Salvi GE, Lang NP, Persson GR, Persson SGR. Bacterial colonization immediately after installation on oral titanium implants. *Clin Oral Implants Res* 2007;18:501-508.
12. do Nascimento C, Miani PK, Pedrazzi V, et al. Leakage of saliva through the implant-abutment interface: In vitro evaluation of three different implant connections under unloaded and loaded conditions. *Int J Oral Maxillofac Implants* 2012;27:551-560.



Università Vita-Salute San Raffaele  
Facoltà di Medicina e Chirurgia  
Corso di Laurea in Odontoiatria e Protesi Dentaria  
Presidente Prof. Enrico F. Gherlone

I.R.C.C.S. Ospedale San Raffaele  
Dipartimento di Odontoiatria  
Direttore Prof. Enrico F. Gherlone



## SOPRAVVIVENZA IMPLANTARE NEI PAZIENTI DIABETICI : STUDIO PRELIMINARE CON FOLLOW-UP DI 1 ANNO

*Pirani F., Montemezzi P., Capparè P., Vinci R.*

### SCOPO:

L'uso di impianti dentali in pazienti con diabete mellito di tipo 1 (DM1) rimane controverso a causa del fatto che in letteratura è stata riscontrata una diminuita percentuale di sopravvivenza degli impianti stessi. Questo studio ha l'obiettivo di determinare se DM1 rappresenta un fattore di rischio significativo il successo delle riabilitazioni implantoprotesiche.

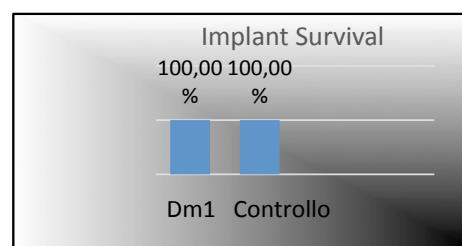
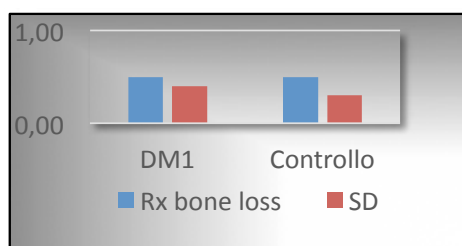
### METODI:

In questo studio sono stati selezionati pazienti adulti affetti da DM1 da oltre 20 anni, affetti da edentulia singola e richiedenti un trattamento implantare, confrontati con pazienti sani che necessitavano dello stesso tipo di riabilitazione.

Gli impianti dentali sono stati collocati in singoli siti edentuli secondo le istruzioni del produttore ed è stato impostato un protocollo di carico differito. (Sistema implantare Winsix, Biosafin, Ancona, Italia) La profilassi antibiotica è stata somministrata a pazienti DM1 1 ora prima dell'intervento e poi continuata per 6 giorni. L'osteointegrazione dell'impianto è stata valutata mediante radiografie intraorali digitali e follow-up clinici a 6 e 12 mesi dall'intervento. Le sessioni di igiene orale professionale sono state pianificate a 4, 8 e 12 mesi dall'intervento. Nello stesso appuntamento, i pazienti sono stati motivati per le abitudini di igiene orale domiciliare. Sono state consegnate a tutti i pazienti riabilitazioni protesiche implantari fisse. Le analisi statistiche sono state effettuate utilizzando la versione 5.00 del software GraphPad Prism per Windows.

### RISULTATI:

Un totale di 25 pazienti DM1 e 25 pazienti non diabetici hanno soddisfatto i criteri di inclusione e sono stati selezionati per lo studio. A 12 mesi, è stato riportato un tasso di sopravvivenza del 100% per il gruppo DM1 e del 100% per il gruppo di controllo non diabetico, senza differenze statistiche ( $p > 0,05$ ). A 12 mesi di follow-up, i risultati radiografici hanno mostrato una perdita ossea marginale media di  $0,81 \pm 0,40$  mm per il gruppo DM1, mentre  $0,75 \pm 0,30$  mm è stata registrata nel gruppo di controllo, senza differenze statistiche ( $p > 0,05$ ). La guarigione delle ferite è stata riportata senza complicazioni in tutti i 25 pazienti DM1. I tessuti molli sono andati incontro ad una buona guarigione in entrambi i gruppi. Nessuna complicanza protesica è stata riportata al follow-up di 12 mesi.



### CONCLUSIONI:

L'assenza di differenze statistiche tra i due gruppi ha suggerito che l'uso di una procedura implantare minimamente invasiva, la somministrazione di antibiotici prima e dopo l'intervento chirurgico e un rigido protocollo di igiene orale post-operatorio sono efficaci nel controllo della sopravvivenza dell'impianto in pazienti DM1. Questi risultati devono essere confermati da un follow-up più lungo e con una dimensione del campione più ampia.

### Bibliografia

- Kudiyirickal MG, Pappachan JM. Diabetes mellitus and oral health. *Endocrine*. 2015; 49:27-34.  
 Retzepi M, Donos N. The effect of diabetes mellitus on osseous healing. *Clin.Oral.Impl.Res.* 2010; 2 1:673-681.  
 Javed F, Romanos GE. Impact of diabetes mellitus and glycemic control on the osseointegration of dental implants: a systematic literature review. *J.Periodontol.* 2009; 80:1719-1730.  
 Nevins ML, Karimbux NY, Weber HP, Giannobile WV, Fiorellini JP. Wound healing around endosseous implants in experimental diabetes. *Int.J.Oral.Maxillofac.Implants.* 1998;13:620-629  
 Prakash PSG, Victor DJ. Influence of diabetes on dental implants: a retrospective study. *Journal of Dental Implants.* 2012; 2:83-87.



## RICERCA CLINICA

## Utilizzo di innesti di osso autologo nelle gravi atrofie dei mascellari: analisi morfologica e immunohistochimica a lungo termine

*Use of autologous bone grafts in the serious atrophies of the maxillars: morphological and immunohistochemical analysis at long-term*



tetegiulia92@gmail.com

### SCOPO DEL LAVORO

Basandosi su evidenze riportate in precedenza, lo scopo di questo studio era di valutare i meccanismi morfologici e molecolari che caratterizzano l'integrazione dell'autologo con innesti di calvaria dopo 4 mesi (T1), 6 mesi (T2) e 15 anni (T3) e il rimodellamento del sito impiantare.

### MATERIALI E METODI

Sono stati inclusi tre pazienti (45/65 anni): due che necessitano di riabilitazione impiantare previo innesto osseo di calvaria e protesi supportate da impianti, mentre l'altro paziente ha effettuato un inserimento di un impianto nell'area adiacente al sito rigenerato con innesto di calvaria 15 anni prima. Nei primi due pazienti, i campioni ossei sono stati ottenuti dal sito donatore (T0), dall'area rigenerata 4 mesi dopo l'innesto (T1) e 6 mesi dopo l'inserimento dell'impianto (T2). Inoltre, un campione di osso è stato ottenuto da un terzo paziente, 15 anni dopo l'innesto (T3). È stata effettuata un'analisi macrostrutturale e un'analisi immunohistochimica, verificando l'espressione di BSP2, marker osteogenico, collagene I, organizzatore della matrice ossea, VEGF regolatore angiogenico, ERK 1/2, che regola sia l'attività osteogenica che angiogenica, e la proteina infiammatoria iNOS.

### RISULTATI

I campioni T1 e T2 mostrano la presenza d'importanti fenomeni di rimodellamento, con area di riassorbimento e neoapposizione ossea, unitamente alla formazione di nuovi vasi sanguigni. Mentre nel campione T3 si osservano caratteristiche morfologiche molto vicine all'osso nativo, come dimostrato dalla scomparsa delle linee di saldatura. Tuttavia, le piccole cellule poligonali che assomigliano agli osteoblasti, chiuse nei canali di Havers, denotano che ci sia ancora neoapposizione ossea. Le analisi immunohistochimiche

mostrano una drastica diminuzione dell'espressione del collagene, in T1 e T2, stabilizzata in T3, in parallelo all'aumento di BSP2, che tuttavia è considerevolmente ridotto in T3. Inoltre, il fattore di angiogenesi VEGF è aumentato in T2, rispetto a T0, T1 e T3 che sono abbastanza simili. Il livello più alto di ERK 1/2 è evidenziato nel campione T2; ed infine i livelli basali di iNOS, correlati a eventi infiammatori sono evidenziati in T0 e T3, rispetto a T1.

### CONCLUSIONI

Questi dati, combinati con osservazioni cliniche, suggeriscono che l'innesto di origine extraorale, in particolare da calvaria, è perfettamente integrato dopo 15 anni. Inoltre, ciò è confermato dalla presenza di cellule poligonali attorno ai canali di Havers e dalla tendenza negli anni di BSP2, parallelamente all'espressione di VEGF e ERK 1/2, suggerendo che esiste una nuova formazione ossea residua. Pertanto, gli innesti di osso autologo extraorale, in particolare quelli di calvaria, sembrano particolarmente adatti come biomateriali per la rigenerazione ossea di difetti estesi prima di una successiva terapia protesica supportata da impianto. (1) (Tetè et al., 2013 Eur.J.Histochem, 57,60-65).

La ricostruzione dei grandi difetti ossei mascellari e mandibolari causata da incidenti, tumori o atrofie da edentulismo rappresenta un'importante sfida clinica per i chirurghi; quindi per riparare tali difetti è importante avere una conoscenza delle proprietà biologiche del tessuto osseo nativo e dei sostituti ossei, i quali devono essere biocompatibili, ben tollerati, non teratogeni, non cancerogeni, bioattivi, sterilizzabili e con buone proprietà meccaniche e chimiche. L'evidenza scientifica attesta che l'osso autologo può es-



Innesti, osso autologo, atrofia, calvaria, pattern molecolare

Grafts, autologous bone, atrophy, calvaria, molecular pattern



Giulia Tetè

\*

Chiara Manenti

Federico Quasso

\*

Francesca Mottola

\*\*

Matteo Nagni

\*

D.D.S.

\*\*

Specializzando

Reparto di Chirurgia Orale, Università Vita-Salute San Raffaele, Milano, IRCCS Università Ospedale San Raffaele, Milano, Dental School, Dipartimento di Odontoiatria

## RICERCA CLINICA

sere considerato il gold standard tra i materiali da innesto in quanto garantisce l'avvio di tre processi biologici fondamentali su cui poggiano le basi concettuali per le procedure di innesto osseo: osteogenesi, osteoinduzione e osteoconduzione. Pertanto oggetto di questa tesi sperimentale è stato investigare gli aspetti morfologici e i meccanismi molecolari che caratterizzano l'integrazione dell'osso autologo e il rimodellamento della sede dell'implanto.

In particolare è stata presa in considerazione l'espressione di BSP2, marker osteogenico, di collagene, organizzatore della matrice ossea, di VEGF, regolatore angiogenico, e delle vie di segnale MAPK/ERK, che inducono sia l'attività osteogenica che angiogenica nonché l'espressione della iNOS, che può mediare l'eventuale instaurarsi di un processo infiammatorio nel tessuto osseo ospite in presenza di innesti di osso autologo extra-orale da calvaria in siti edentuli del mascellare superiore posteriore in due pazienti a T1 (4mesi), T2 (6mesi) e T3 (15 anni).

### MATERIALI E METODI

Sono stati esaminati tre pazienti, comprese tra i 45 e i 65 anni, di sesso femminile e un paziente di anni 65 che ha effettuato un rientro dopo 15 anni, per inserimento implantare in sede adiacente. I suddetti pazienti avevano bisogno di una riabilitazione orale nel mascellare superiore e presentavano un volume osseo inadeguato, per permettere l'inserimento implantare; precisamente definite classe 5 (classificazione di Cawood e Howell). Quindi presentando una cresta alveolare residua minore di 4 mm, uno spessore di almeno 5 mm e un'aumentata distanza intermascellare, sono stati trattati con rialzo di seno mascellare ed innesto di osso autologo, prelevato da teca cranica, d'apposizione verticale e orizzontale. Tutti i pazienti sono stati previamente informati dello scopo di questa ricerca ed hanno espresso il loro consenso in forma scritta, in accordo con la commissione etica locale, con la legislazione italiana, e con il codice dei principi etici della ricerca scientifica inerenti agli esseri umani della World Medical Association (Dichiarazione di Helsinki).

### Procedura chirurgica

Prima dell'intervento i pazienti sono stati sottoposti ad anamnesi medica completa, esame obiettivo clinico e radiografico. Tutti i pazienti hanno mostrato (condizione necessaria per il loro reclutamento nello studio) buone condizioni sistemiche, inclusa l'assenza di patologie che controindicassero la chirurgia o che costituissero un fattore di rischio per il futuro successo della terapia riabilitativa implanto-protetica. In particolare sono stati adottati come criteri di inclusione: assenza di compliance per le procedure di igiene orale domiciliare, malattia parodontale incontrollata, patologie infiammatorie acute dei mascellari, malattie delle mucose orali, storia recente di irradiazione della regione testa-collo, chemioterapia, fumo, diabete mellito scompensato, uso di sostanze stupefacenti, assunzione di bisfosfonati, immunodepressione, parafunzioni. La valutazione radiografica preoperatoria ha incluso l'esecuzione di ortopantomografia e tomografia computerizzata cone beam (CBCT). Prima di qualsiasi intervento chirurgico è stata somministrata l'antibiotico-profilassi. Gli interventi di prelievo di osso autologo dalla teca cranica sono stati effettuati presso l'ospedale Vita e Salute San Raffaele dal professor Raffaele Vinci. I blocchi di osso autologo, di dimensione corrispondente al difetto osseo da ricostruire, sono stati prelevati in anestesia generale dalla regione parietale della teca cranica, utilizzando la tecnica splitting-in-situ proposta da Paul Tessier nel 1982. Il vantaggio di essa, differentemente dalla tecnica splitting-on-table, è di permettere il distacco unicamente della corticale esterna: in questa maniera si ottiene certamente una minor quantità di osso, ma in compenso le procedure chirurgiche risultano più semplici, di durata inferiore, e soprattutto meno invasive, riducendo al minimo i possibili incidenti di esposizione o lacerazione della dura madre, quindi non rende necessaria la presenza del neurochirurgo.

Dopo l'incisione della cute non rasata (Vinci R et al, 2006) e la riflessione del lembo, il contorno del blocco è stato delimitato con uno strumento piezoelettrico (Easy Surgery, BioSAF IN S.r.l., Ancona, Italia). Una volta osteotomizzati completamente i margini, il frammento è stato mobilizzato e staccato

mediante scalpelli di differente angolazione. Il sito ricevente è stato esposto tramite un'incisione a tutto spessore e ribaltamento di un lembo mucoperiosteale, e i blocchi di osso sono stati sagomati secondo la morfologia e le dimensioni del difetto. L'osso corticale dei siti riceventi è stato perforato con una fresa rotante di 1 mm di diametro per aumentare l'apporto sanguigno dai vasi endosseali e i blocchi d'osso sono stati fissati con viti da osteosintesi di 1,5-2 mm di diametro per ricostruire la cresta alveolare.

Tutte le intercapedini tra i blocchetti d'osso e il sito ricevente sono state riempite con osso autologo particolato.

La chiusura dell'accesso chirurgico è stata ottenuta dopo un'incisione di rilascio periostale di entrambi i lembi mucoperiosteali, buccale e linguale, con suture 3-0. Il protocollo farmacologico post-operatorio prevedeva per tutti i pazienti, la somministrazione di un antibiotico (ceftriaxone, 2g/die per 10 giorni), un antiinfiammatorio non steroideo (ketoprofene, 400 mg/die per 10 giorni), un glucocorticoide (betametasona, 4mg/die per i primi due giorni, 2mg il terzo giorno) ed un antisettico locale (clorexidina 0,20% collutorio 3 volte al giorno). Inoltre è stata prescritta a tutti i pazienti dieta morbida ed igiene orale scrupolosa.

Terminata la prima fase chirurgica e rimosse le suture dopo circa 10 giorni, i pazienti sono stati seguiti mensilmente con esami clinici e radiologici effettuati con radiografie periapicali della sede trattata.

L'inserimento delle fixture è stato rimandato in tutti i pazienti; circa 4 mesi dopo l'intervento di prelievo, infatti, tutti i pazienti sono stati sottoposti ad una seconda fase chirurgica per il posizionamento degli impianti. In occasione del rientro chirurgico, dall'osso rigenerato e interessato dall'inserimento degli impianti sono stati prelevati dei campioni biotipi mediante una fresa trephine di 3 mm di diametro e 8 mm di altezza, in modo da avere campioni significativi di osso rigenerato per tutti i pazienti. Mentre come precedentemente citato con il medesimo strumento è stata prelevata una carota ossea nel rientro a 15 anni, dovendosi sottoporre la paziente a inserimento implantare in una sede adiacente.

## RICERCA CLINICA

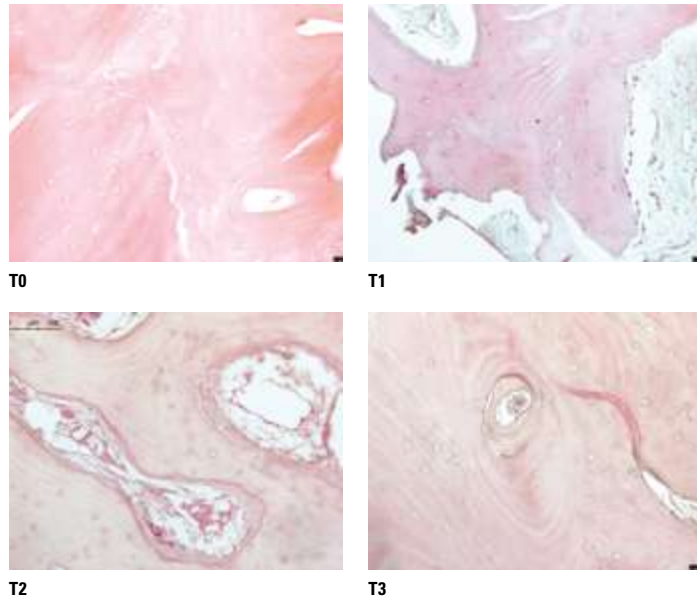
**Analisi morfologica in microscopia ottica ed immunostochimica**

I campioni di tessuto osseo, fissati in una soluzione tamponata con fosfato di formalina 10% per 72 h, sono stati decalcificati in una soluzione di EDTA (MIELODEC kit, Bio-Optica, Milano), disidratati in soluzioni a concentrazione crescente di alcool e xilene e successivamente inclusi in paraffina. Sono state poi tagliate sezioni di 5  $\mu$ m di spessore, deparaffinate in xilene e successivamente in concentrazioni decrescenti di alcoli e processate per la colorazione con ematossilina-eosina e per l'analisi immunostochimica. Al fine di mettere in evidenza le proteine, BSP2, Collagene I, VEGF, MAPK/ERK, iNOS, oggetto dello studio, le analisi immunostochimiche sono state eseguite su 5 sezioni di tessuto per ciascun campione sperimentale, utilizzando il kit Ultravision LP Detection System HRP Polymer & DAB Plus Chromogen (Lab Vision Thermo, CA, USA) seguendo le istruzioni fornite dalla casa produttrice.

Le sezioni sono state incubate con anticorpi monoclonali di topo anti BSP2, collagene I, VEGF (Santa Cruz Biotechnology, Santa Cruz, CA, USA) con anticorpo policlonale di coniglio anti iNOS (Santa Cruz Biotechnology, Santa Cruz, CA, USA) e anticorpo policlonale di coniglio anti MAPK/ERK (Cell Signalling Technology Inc., CA, USA). Il cromogeno utilizzato per lo sviluppo della reazione è stato il tetracloruro di 3,3-diaminobenzidina (DAB), che ha fornito il prodotto di ossidazione insolubile, colorato in bruno-arancio e precipitante sul luogo di reazione. I nuclei sono stati contrastati con ematossilina, e i preparati sono stati osservati al microscopio ottico sia per l'esame morfologico che immunostochimico. I controlli negativi sono stati ottenuti omettendo l'utilizzo degli anticorpi primari. Le sezioni sono state osservate per mezzo di microscopio ottico Leica DN 4000 (Leica Cambridge Ltd, Cambridge, UK) dotato di una videocamera Leica DFC 320 (Leica Cambridge Ltd, Cambridge, UK) per l'ottenimento di immagini computerizzate.

**Misurazione morfometrica computerizzata ed analisi di immagine**

Dopo la digitalizzazione delle immagini derivanti dalle analisi immunostochimiche,



**Fig. 1** Osservazione al microscopio ottico di campioni di tessuto osseo in sede di innesto (T0) e ottenuti dopo 4 (T1), 6 mesi (T2) e 15 anni (T3) dall'inserimento dell'innesto da siti rigenerati con osso autologo prelevato da calvaria. Colorazione: ematossilina-eosina. Ingrandimento: 20x - 40x.

è stato utilizzato il software di analisi d'immagine QWin Plus 3.5 (Leica Cambridge Ltd, Cambridge, UK) per valutare l'espressione di TGF 1, OPG, RANKL, VEGF, Bmp2, collagene, MAPK/ERK, iNOS. L'analisi dell'espressione proteica è stata effettuata attraverso la quantificazione delle aree colorate in marrone in dieci campi acquisiti casualmente per ciascuna sezione di ciascun punto sperimentale. I dati ottenuti mediante il software QWin sono stati registrati in fogli dati Microsoft Excel e trattati per le deviazioni standard e gli istogrammi. La significatività statistica dei risultati è stata valutata mediante il Wilcoxon, Mann-Whitney Test, usando il software di analisi statistica R Software, versione 2.12.1 per Mac, ed impostando come livello di significatività con  $p = 0,05$ .

**RISULTATI**

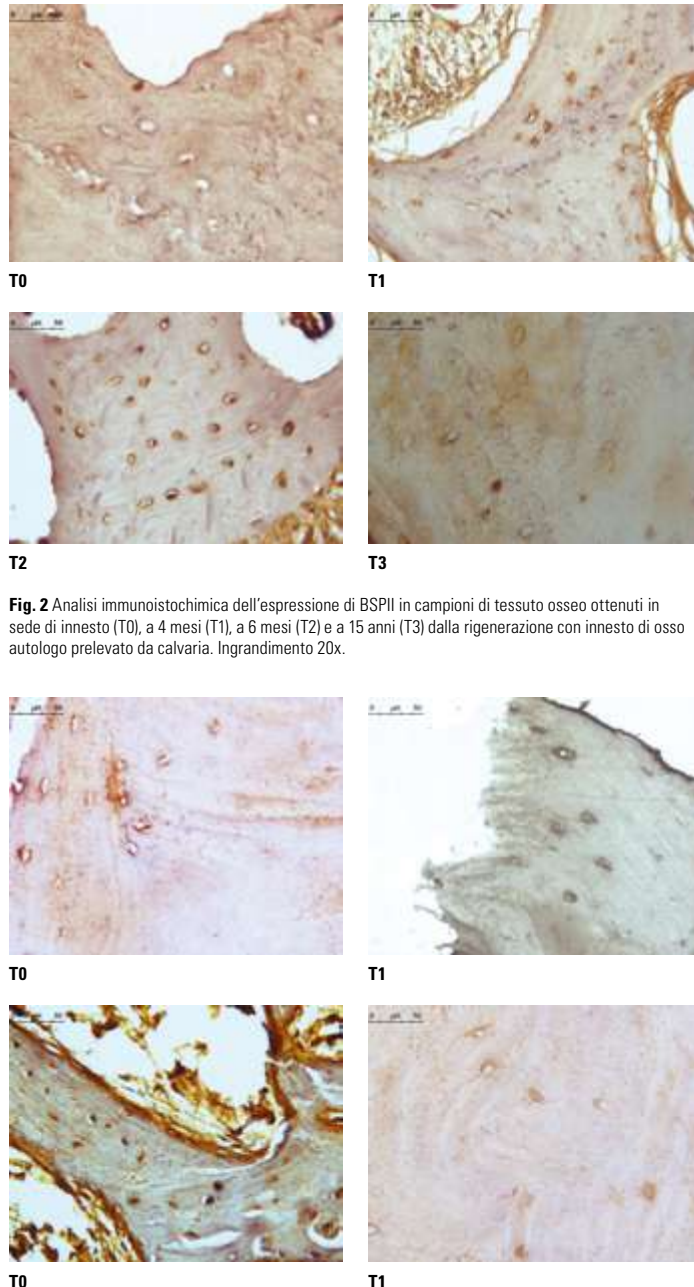
Il posizionamento di un innesto di tessuto osseo, volto ad incrementare il volume della cresta residua, induce una reazione nel si-

to ricevente. Tale risposta, indipendente dalla natura del sito donatore, presenta alcuni caratteri comuni al processo infiammatorio (iperemia, vasodilatazione). In breve tempo, si assiste all'incorporazione dell'innesto, mediante il processo di angiogenesi e di colonizzazione ad opera di cellule mesenchimali e mediatori chimici. Successivamente queste cellule multipotenti iniziano a differenziarsi in senso osteogenico ed a proliferare. A circa 4 settimane dall'intervento, da parte degli osteoblasti rimasti vitali nell'innesto e da quelli derivati dalla differenziazione delle cellule multipotenti, appongono nuovo tessuto osseo. Questo osso primario va incontro a maturazione, con formazione di tessuto osteoide e sistemi haversiani che ne determinano una struttura lamellare. Alla base di questi processi si instaurano dei meccanismi molecolari che ne regolano l'andamento. A tale proposito in questo studio sono stati analizzati i livelli di espressione di molecole strettamente coinvolte nel processo d'integrazione dell'innesto, quali BSP2, Collagene I, VEGF, MAPK/ERK, iNOS. Le ana-



## RICERCA CLINICA

lisi sono state eseguite su campioni biotici di tessuto osseo prelevato dai pazienti in occasione del rientro chirurgico nel sito rigenerato avvenuto circa 4 mesi dopo il primo intervento, ossia al momento dell'inserimento degli impianti, a 6 mesi cioè al momento dell'esposizione delle viti, ed infine un caso a 15 anni per inserimento implantare in sede adiacente. L'analisi morfologica è stata eseguita al microscopio ottico dopo colorazione con ematossilina-eosina, mette in evidenza nei campioni appartenenti al gruppo T1 (4 mesi), la presenza del tessuto osseo nativo e delle nuove fibre di tessuto connettivo può essere facilmente identificata; infatti nei campioni T2 (6 mesi) si osserva una struttura per lo più compatta con vaste aree di rimodellamento in cui è possibile evidenziare la presenza di neoformazioni vasali. Inoltre sono presenti linee di saldatura con margini di riassorbimento e neoapposizione ossea tra il tessuto osseo preesistente e l'innesto. Nei campioni ottenuti invece a 15 anni circa dal momento dell'innesto (T3), l'osservazione microscopica mette in luce un aspetto morfologico molto simile a quello dell'osso nativo, indice della formazione di osso corticale con le stesse caratteristiche strutturali e biomolecolari di quello innestato. Infatti l'analisi microscopica ha evidenziato che l'innesto ha assunto delle caratteristiche morfologiche molto simili all'osso nativo, come si evince dalla scomparsa delle linee di saldatura. Tuttavia la cosa più interessante è che intorno al canale di Havers, sono posizionate piccole cellule poligonali che ricordano la morfologia degli osteoblasti, lasciando ipotizzare che non solo il campione risulta perfettamente integrato ma si potrebbe pensare che ci sia ancora apposizione ossea. L'analisi immunostochimica conferma i precedenti risultati. La BSP2 mostra un picco in T2 parallelamente all'espressione del VEGF, indice di attività di rimodellamento osseo e del potenziale neoangiogenico del tessuto ospite. I livelli sono infatti più elevati in T1 e T2 rispetto al T0 e T3, tutto ciò è confermato dall'immagine dove vediamo la positività (colorazione marrone) in corrispondenza del tessuto connettivo immaturo disposto tra le lamelle ossee. Ricordando che il collagene anche dai risultati è emerso che ha un picco fisiologico a T0 per poi stabilizz-

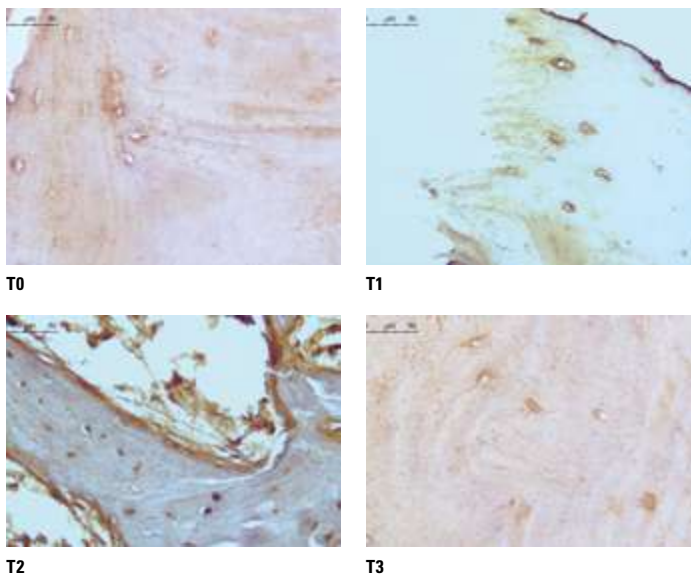


**Fig. 2** Analisi immunostochimica dell'espressione di BSP1I in campioni di tessuto osseo ottenuti in sede di innesto (T0), a 4 mesi (T1), a 6 mesi (T2) e a 15 anni (T3) dalla rigenerazione con innesto di osso autologo prelevato da calvaria. Ingrandimento 20x.

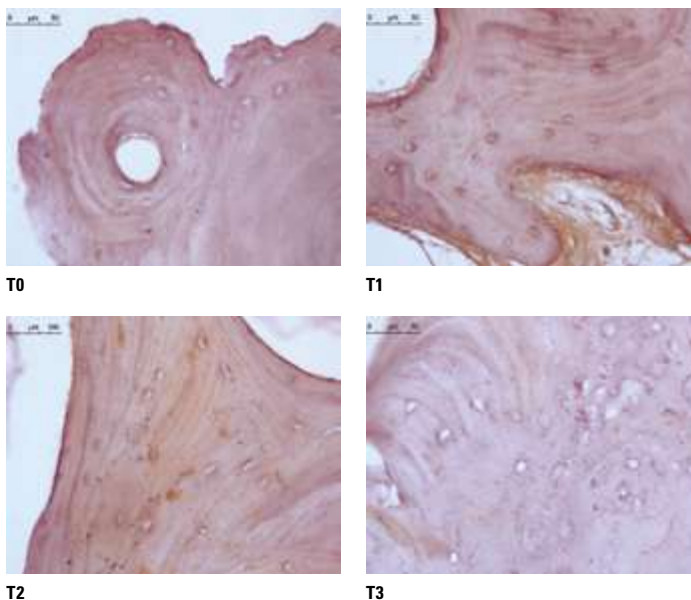
**Fig. 3** Analisi immunostochimica dell'espressione di VEGF in campioni di tessuto osseo ottenuti in sede di innesto (T0), a 4 mesi (T1), a 6 mesi (T2) e a 15 anni (T3) dalla rigenerazione con innesto di osso autologo prelevato da calvaria. Ingrandimento 20x.



## RICERCA CLINICA



**Fig. 4** Analisi immunohistochimica di Erk1/2 in campioni di tessuto osseo ottenuti in sede di innesto (T0), a 4 mesi (T1), a 6 mesi (T2) e a 15 anni (T3) dalla rigenerazione con innesto di osso autologo prelevato da calvaria. Ingrandimento 20x.



**Fig. 5** Analisi immunohistochimica dell'espressione di VEGF in campioni di tessuto osseo ottenuti in sede di innesto (T0), a 4 mesi (T1), 6 mesi (T2) e a 15 anni (T3) dalla rigenerazione con innesto di osso autologo prelevato da calvaria. Ingrandimento 20x.

zarsi completamente. Questi dati molecolari supportano la tecnica di carico a 6 mesi di Branemark, infatti l'espressione di tali molecole stimola sotto carico la corretta disposizione dell'osso lamellare. Mentre l'ERK che abbiamo detto che il coordinatore tra l'osteogenesi e la neoangiogenesi quindi di vegf e BSP2 mostra anch'esso livelli più alti in T1 e soprattutto in T2 supportando appunto questa ipotesi. La risposta infiammatoria risulta un processo fondamentale per il processo d'integrazione e attecchimento del tessuto osseo innestato, infatti nelle fasi iniziali macrofagi e cellule infiammatorie vengono richiamate in sede per contribuire in maniera indiretta con la produzione di citochine e cellule proinfiammatorie e direttamente al riassorbimento della matrice del tessuto innestato al fine di creare lo spazio fisico entro cui possono svilupparsi nuove gemme vascolari, proliferare e quindi permettere la differenziazione in cellule mesenchimali. L'iNOS è la protagonista della fase infiammatoria ed è più alta in T1 proprio perché dimostra il picco di attività infiammatoria, che richiama in sede non solo macrofagi ma anche osteoblasti che la contrastano per dare il via alle fasi successive. (Figg. 1-5)

## DISCUSSIONE

Quindi alla luce di questi risultati possiamo dire che considerando i risultati dei campioni soprattutto considerando quelli a 15 anni, l'osso si presenta simile alla struttura dell'osso innestato quindi corticale, e possiamo permetterci di affermare che l'osso a 15 anni è perfettamente integrato e non solo parzialmente quindi all'interfaccia tra osso innestato e osso nativo, e non presenta quei fenomeni tipici dell'infiammazione: quindi la struttura ossea ha raggiunto il suo perfetto equilibrio come se l'intervento non ci fosse mai stato, inoltre è un osso vitale perché nella sua struttura sono presenti ancora osteoblasti, dotati di una minima attività di neoapposizione ossea, intorno ai canali haversiani.

## CONCLUSIONE

I dati clinici insieme a quelli morfologici e molecolari permettono di affermare che gli

## RICERCA CLINICA

innesti di osso autologo, ed in particolare di calvaria, rappresentano il gold standard dei biomateriali utilizzabili per ottenere una predicibile rigenerazione nelle severe atrofie ossee. Si può affermare, infine, che questo studio rappresenti un esempio di translational research, nella quale evidenze scientifiche obiettive costituiscono un ausilio per il clinico nella scelta della terapia più congrua per una determinata alterazione patologica.

### AIM OF THE WORK

Thus, basing on previously reported evidences the aim of this study was to evaluate the morphological and molecular mechanisms characterizing the integration of autologous with calvaria bone grafts after 4 months (T1), 6 months (T2) and 15 years (T3) and the remodeling of the implant site.

### MATERIALS AND METHODS

Three patients (45/65 yrs) were included: two needing oral bone rehabilitation through calvaria graft and implantsupported prosthesis, one needing implant insertion in the adjacent area to a site regenerated with calvaria graft 15 yrs before. In the first two patients, bone samples were obtained from donor site (T0), from regenerated area 4 months after grafting (T1), and 6 months after implant insertion (T2). Moreover, a bone sample was obtained from a third patient, 15 yrs after grafting (T3). Morphostructural analysis and immunohistochemical analyses of BSP2, osteogenic marker, Collagen I, organizer bone matrix, VEGF, angiogenic regulator, ERK 1/2, regulating both osteogenic and angiogenic activity, and iNOS inflammatory protein, expression were carried out.

### RESULTS

T1 and T2 samples show the presence of important remodeling phenomena, with area of bone resorption and apposition, together with new blood vessels formation. T3 sample shows morphological features very close to native bone, as shown by the disappearance of welding lines. However, small polygonal cells resembling osteoblasts are close to Havers channels. Immunohistochemical analyses show a drastic decrease of Collagen expression, in T1 and T2, stabilized in T3, in parallel to BSP2 expression increase, which however is considerably reduced in T3. Moreover VEGF angio-

genic factor is increased in T2, with respect to T0, T1 and T3 which are quite similar. The highest level of ERK 1/2 is evidenced in T2 sample, basal levels of iNOS, related to inflammatory events is evidenced in T0 and T3, with respect to T1.

### CONCLUSIONS

This data, combined with clinical observations, suggest that the graft of extraoral source, is perfectly integrated after 15 years. Moreover, this is confirmed by the presence of polygonal cells around the Havers channels and by the trend through the years of BSP2, paralleled by VEGF and ERK 1/2 expression, suggesting that there is a residual new bone formation. Thus, autologous extraoral bone grafts, in particular calvaria ones, seem particularly suitable as biomaterial for bone regeneration of extensive defects prior to a subsequent implant-supported prosthetic therapy. (1) (Tetè et al. 2013 Eur.J.Histochem. 57,60-65).

### BIBLIOGRAFIA

1. Jensen OT, Shulman LB, Block MS, Iaconi VJ. Report of the sinus consensus con27, doi: 10.1111/j.1600-0501.2011.02300.x, 2011ference of 1996. *Int J Oral Maxillofac Implants*, 13: 11-45, 1998
2. Tong DC et al. A review of survival rates for implants placed in grafted maxillary sinuses using meta-analysis. *Int J Oral Maxillofac Implants*, 13:175-182, 1998
3. Tetè S, Vinci R et al. Atrophic jaw reconstruction by means of calvarial bone graft: long-term results. *J Craniofac Surg*, 21: 1147-1152, 2010
4. Tetè S, Vinci R et al. Immunohistochemical analysis of matrix metalloproteinase-9, vascular endothelial growth factor, bone sialoprotein and i-nitric oxide synthase in calvaria vs. iliac crest bone grafts. *Clin Oral Implants Research*
5. Barker TH, Baneyx G, Cardó-Vila M, Workman GA, Weaver M, Menon PM, Dedhar S, Rempel SA, Arap W, Pasqualini R, Vogel V, Sage EH. SPARC regulates extracellular matrix organization through its modulation of integrin-linked kinase activity. *J Biol Chem*. Oct 28;280(43):36483-93. 2005.
6. Brown JM, Corey E, Lee ZD, et al. Osteoprotegerin and rank ligand expression in prostate cancer. *Urology*, 57: 611-6. 2001.
7. Coleman R, Brown J, Terpos E, et al. Bone markers and their prognostic value in metastatic bone disease: clinical evidence and future directions. *Cancer Treat Rev*. 34: 629-39. 2008.
8. Dunder U, Kavuncu V, Ciftci IH, et al. The effect of risedronate treatment on serum cytokines in postmenopausal osteoporosis: a 6-month randomized and controlled study. *J Bone Miner Metab*, 27(4): 464-470. 2009.
9. Fahrleitner-Pammer A, Dobnig H, Dimai HP, et al. The effect of RANKL and OPG on bone mineral density in pre-dialysis chronic renal failure. *Clin Nephrol*, 71(6): 652-659, 2009.
10. Glycoproteomic analysis of two mouse mammary cell lines during transforming growth factor (TGF)-beta induced epithelial to mesenchymal transition". 7thspace.com. 2009.
11. Li EK, Tam LS, Griffith JF, et al. High prevalence of asymptomatic vertebral fractures in Chinese women with systemic lupus erythematosus. *J Rheumatol*, 36(8): 1646-1652, 2009.



## RICERCA CLINICA

## Strategie chirurgiche alternative nel trattamento dei terzi molari in inclusione ossea

*Alternative surgery strategies in the treatment of the third molars impacted*



federico.quasso@gmail.com

### SCOPO DEL LAVORO

Lo scopo di questo lavoro è stato valutare e confrontare i due possibili strumenti utilizzabili per le estrazioni di ottavi inclusi sia superiori che inferiori, confrontando il dolore, numero di compresse di ibuprofene assunte, trisma post operatorio ed il tempo impiegato.

### MATERIALI E METODI

Sono stati selezionati casi di difficoltà simile e seguiti dei rigidi criteri di inclusione ed esclusione è stato poi confrontato il dolore, trisma, numero di compresse di ibuprofene assunte, e tempo impiegato con strumento rotante o piezoelettrico differenziando arcata superiore ed inferiore.

### RISULTATI

Attraverso l'uso dello strumento piezoelettrico i valori raccolti per quanto riguarda trisma, dolore post operatorio e numero di compresse di ibuprofene assunte sono decisamente a favore dello strumento ultrasonico piezoelettrico. Solo per quanto riguarda la tempistica di intervento lo strumento rotante si è dimostrato nettamente più veloce.

### CONCLUSIONI

Lo strumento piezoelettrico ormai in commercio da diversi anni ma sempre più efficiente si dimostra un valido ed ottimo strumento alternativo al classico strumento rotante, assicurando un intervento più confortevole al paziente e con un decorso migliore. Da valutare l'uso dello strumento rotante in base al tipo di paziente al fine di ridurre quando possibile ed in sicurezza il tempo operativo.

In odontoiatria l'estrazione di ottavi inclusi è un intervento molto frequente. La conoscenza del corretto approccio chirurgico all'avulsione di un dente del giudizio è di fondamentale importanza; è sempre necessaria una scrupolosa pianificazione dell'intervento, unita alla valutazione di costi e benefici e alla scelta del tipo di lembo da scolpire per accedere all'area anatomica interessata.

Oltre alla parte clinica e chirurgica è bene ricordare l'aspetto psicologico e doloroso del paziente, per il quale l'intervento si presenta strettamente correlato alla paura e alla preoccupazione per il dolore intra e post intervento. Per questo motivo abbiamo provveduto a valutare e confrontare due possibili strumenti utilizzabili per le estrazioni di ottavi inclusi sia superiori che inferiori: strumenti rotanti classici come il manipolo dritto e strumento ultrasonico piezoelettrico. (Fig. 1-4)

### MATERIALI E METODI

Gli strumenti utilizzati sono stati i seguenti.

Manipolo dritto Kavo INTRAmatic 10 CN:

- velocità di azionamento max. 40.000 giri/minuto
- trasmissione numero di giri 1:1
- marcatura 1 anello blu
- morsetto a pulsante Ø 1,6.

Possono essere utilizzate frese conformi alla norma DIN EN ISO 1797-1 tipo 3.

Piezoelettrico Biosafin Easy Surgery:

- tensione alimentazione 230V -50/60hz



estrazioni terzi molari, strumento rotante, strumento piezoelettrico, dolore, ibuprofene

third molar extraction, rotating instrument, piezoelectric instrument, pain, ibuprofen



\*  
**Federico Quasso**

\*\*  
**Giulia Tetè**

\*\*  
**Francesca Mottola**

\*\*\*  
**Francesco Amodio**

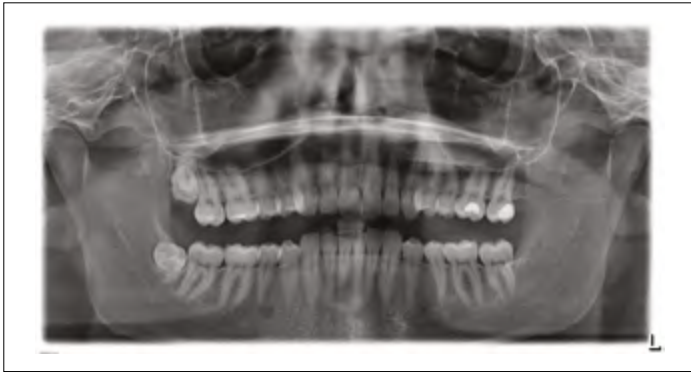\*  
Odontoiatra libero professionista

\*\*  
Studentessa

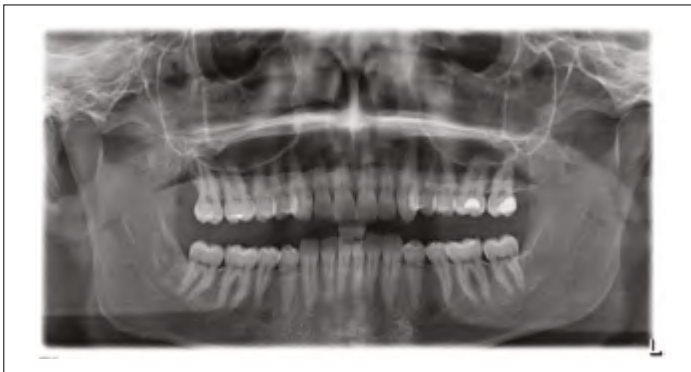\*\*\*  
Specializzando

Università Vita-Salute San Raffaele  
Facoltà di Medicina e Chirurgia Corso di Laurea Magistrale in Odontoiatria e Protesi Dentaria  
Direttore:  
Prof. E. Gherlone

## RICERCA CLINICA



**Fig. 1** OPT pre intervento di avulsione elemento 48 (valido ai fini dello studio) con strumento piezoelettrico.



**Fig. 2** OPT di controllo e guarigione post avulsione a 3 mesi.

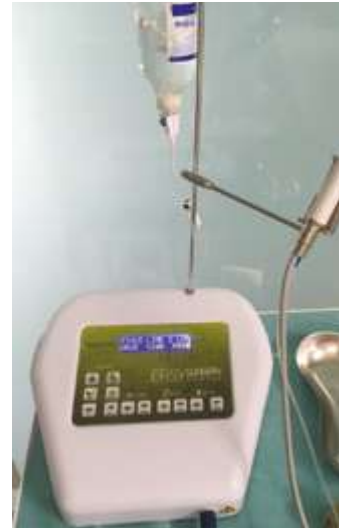- potenza nominale 170VA
- vibrazione massima 200 micron
- frequenza di lavoro 22-38 Khz.

Il principio di funzionamento dello strumento piezoelettrico è la trasduzione della corrente alternata prodotta da un generatore e in seguito trasmessa al manipolo generando, per l'effetto piezoelettrico inverso, vibrazioni longitudinali e verticali la cui ampiezza varia secondo la frequenza e la potenza utilizzate. (Fig. 5)

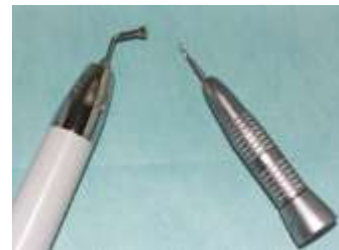Nelle situazioni anatomiche in cui si debba eseguire un'osteotomia partendo dalla corticale, utilizzando strumenti rotanti, risulta evidente che la forza necessaria per sfruttare il "torque" nella struttura ossea più mineralizzata risulta improvvisamen-

te eccessiva nel passaggio alla spongiosa. In questa situazione, infatti, la notevole pressione produce un'istantanea perdita di controllo dello strumento chirurgico, che può essere pericolosa in contiguità con strutture anatomiche delicate quali fasci vascolari o tessuto nervoso. Gli strumenti motorizzati tradizionali, nel produrre l'azione di taglio, generano macrovibrazioni che a loro volta riducono la sicurezza chirurgica.

L'azione del taglio piezoelettrico è invece il risultato di microvibrazioni lineari di natura ultrasonica, dell'ampiezza di soli 20-60µm in senso longitudinale che consentono il controllo del campo chirurgico in tutte le situazioni anatomiche.



**Fig. 3** Strumento piezoelettrico utilizzato.



**Fig. 4** Terminale Piezoelettrico Biosafin Easy Surgery - Manipolo dritto Kavo INTRAMatic 10 CN.



**Fig. 5** Set terminali piezoelettrici.

## RICERCA CLINICA

Dividiamo le caratteristiche del taglio piezoelettrico in caratteristiche fisiche e cliniche.

Le caratteristiche fisiche del taglio sono:

- microvibrazione
- hammering action (effetto martello)
- effetto cavitazione
- taglio selettivo

Le microvibrazioni sviluppate dall'apparecchio piezoelettrico si trovano nel range di vibrazione tra 27.000/29.500 Hz, ed a seconda del tipo d'inserto impiegato varia l'ampiezza di vibrazione sia sul piano orizzontale 60/200µm sia sul piano verticale 20/60 µm dell'inserto stesso.

Nello studio sono stati inclusi 20 pazienti con terzi molari inferiori inclusi e 20 con terzi molari superiori inclusi, i quali presentavano le seguenti caratteristiche:

- pazienti con età compresa tra 18 e 35 anni
- pazienti in buona salute
- pazienti sia di sesso maschile che femminile
- paziente senza stati infiammatori orali importanti in atto
- terzi molari inclusi o ad inclusione parziale ossea in disodontiasi.

Inoltre sono stati presi in considerazione solo interventi di exeresi di terzo molare inferiore incluso o parzialmente, di simile difficoltà, comprendenti osteotomia e odontotomia, quando necessaria e con un tempo di intervento per ciascuna avulsione che non differisse di più di 10 minuti in eccesso o in difetto dalla durata media di tutti gli interventi (25 minuti). La posizione del terzo molare inferiore doveva essere mesioverso e di simile difficoltà, in generale tutta la corona dell'ottavo si doveva trovare anteriormente al ramo mandibolare e presentare un piano occlusale compreso tra quello del settimo e la linea di giunzione amelo-cementizia del secondo molare.

I criteri di esclusione dei pazienti sono stati invece i seguenti:

- pazienti con problematiche patologiche sistemiche
- pazienti in terapia con farmaci anticoagulanti e antiaggreganti
- pazienti in terapia con farmaci per ipertensione

**PROTOCOLLO PER IL CONTROLLO DEL DOLORE NEL POST-OPERATORIO NELLE ESTRAZIONI DEI TERZI MOLARI INCLUSI**

- Analgesico:** AUGMENTIN 1 (p.e. ogni 12 ore per 6 gg). L'assunzione è iniziata preoperatorio il 2° giorno di terapia antibiotica.
- Glucosio:** applicato al glucosio subito dopo l'intervento e continuato. L'applicazione nelle 12 ore successive all'intervento a fasce alterne.
- Analgesico:** FANS (se non stitico): **Ibuprofene 400 mg** nel post-operatorio (prima della fine dell'effetto dell'anestesia) somministrato al termine dell'intervento e successivamente **Ibuprofene 400 mg** all'occorrenza a seconda del paziente.  
Da seguire indicare il numero di compresse di ibuprofene 400mg assunte ogni giorno successivo.

Giorno 1	
Giorno 2	
Giorno 3	
Giorno 4	
Giorno 5	
Giorno 6	
Giorno 7	

- Autovisualizzazione del dolore a casa:**  
Da seguire indicare il livello di dolore associato alla scala del dolore nel post-operatorio.

<p>Dolore medio nelle 72 ore successive all'intervento:</p>	0-10

**SCALA VAS**

Note particolari da parte del paziente riguardanti il dolore:

**N.B. il contenuto modulo varia da riconoscere al momento della visita di controllo e/o rivasazione post operatoria.**

**Fig. 6** Schede di protocollo comune consegnate ai pazienti dello studio.

- pazienti trapiantati
- pazienti con controindicazioni alla chirurgia
- pazienti con controindicazioni alla somministrazione di ibuprofene
- pazienti che presentavano pericoronariti acute al momento dell'intervento
- pazienti che avevano assunto di recente antinfiammatori.

Tutti i pazienti sono stati informati della natura dello studio e il consenso informato è stato ottenuto prima dello svolgersi dell'intervento.

Lo stesso protocollo terapeutico è stato ap-

plicato a entrambi i gruppi. (Tab. 1)

Ventiquattro ore dopo l'intervento chirurgico sono stati valutati in entrambi i gruppi tre parametri diversi: dolore soggettivo, la tumefazione facciale e il serramento. Tuttavia a causa della poca precisione riscontrata nella misurazione della tumefazione il parametro è stato poi escluso dallo studio (dalla somma delle distanze trago-pogonion, trago-commessura labiale, gonion commessura palpebrale).

- Trisma o serramento: il serramento postoperatorio è stato ottenuto calcolando la differenza tra la massima apertura



## RICERCA CLINICA

della bocca prima e dopo l'atto chirurgico. I punti di reperi sono stati i margini incisali degli incisivi centrali superiori ed inferiori. Son state misurate le aperture massime prima dell'intervento e dopo 24 ore.

- Valutazione del dolore attraverso la scala VAS precedentemente evidenziata. (Fig. 6)

## RISULTATI

I risultati sono mostrati nelle tabelle 1 e 2 e nelle figure 7 e 8.

Il tempo impiegato in media per l'intervento chirurgico è stato:

Gruppo A

- superiore 27+/- 5 minuti
- inferiore 32+/- 5 minuti

Gruppo B

- superiore 18+/- 5 minuti
- inferiore 23+/- 5 minuti

La massima apertura della bocca prima dell'intervento chirurgico è stata in media di 44,4 mm nel gruppo A (osteotomia piezoelettrica) e di 41,7 mm nel gruppo B (tecnica osteotomica rotante ad alta velocità). Dopo 24 ore l'escursione mandibolare si è

Paziente	Media dolore VAS	N. Compresse nei 7 gg
1 gruppo A Superiore	3	2
2 gruppo A Superiore	2	2
3 gruppo A Superiore	2	2
4 gruppo A Superiore	2	0
5 gruppo A Superiore	1	0
6 gruppo A Superiore	1	0
7 gruppo A Superiore	2	0
8 gruppo A Superiore	1	2
9 gruppo A Superiore	2	1
10 gruppo A Superiore	1	1
11 gruppo A Inferiore	2	1
12 gruppo A Inferiore	2	2
13 gruppo A Inferiore	2	1
14 gruppo A Inferiore	1	2
15 gruppo A Inferiore	3	2
16 gruppo A Inferiore	2	2
17 gruppo A Inferiore	2	1
18 gruppo A Inferiore	1	1
19 gruppo A Inferiore	2	1
20 gruppo A Inferiore	2	2

Tab. 1 Media dolori VAS e assunzione compresse Gruppo A.

Paziente	Media dolore VAS	N. Compresse nei 7 gg
1 gruppo A Superiore	2	3
2 gruppo A Superiore	3	4
3 gruppo A Superiore	2	4
4 gruppo A Superiore	2	4
5 gruppo A Superiore	3	3
6 gruppo A Superiore	3	2
7 gruppo A Superiore	4	2
8 gruppo A Superiore	4	2
9 gruppo A Superiore	3	0
10 gruppo A Superiore	2	1
11 gruppo A Inferiore	4	1
12 gruppo A Inferiore	4	2
13 gruppo A Inferiore	1	3
14 gruppo A Inferiore	3	4
15 gruppo A Inferiore	3	2
16 gruppo A Inferiore	3	4
17 gruppo A Inferiore	2	4
18 gruppo A Inferiore	3	3
19 gruppo A Inferiore	2	3
20 gruppo A Inferiore	5	4

Tab. 2 Media dolori VAS e assunzione compresse Gruppo B. NB: compresse conteggiate esclusa la prima da 600mg somministrata dopo l'intervento.

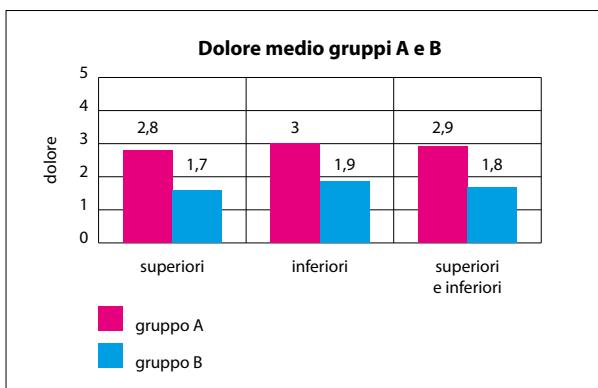


Fig. 7 Grafico con dolore medio riferito dei gruppi A e B in rapporto ad arcata inferiore o superiore.

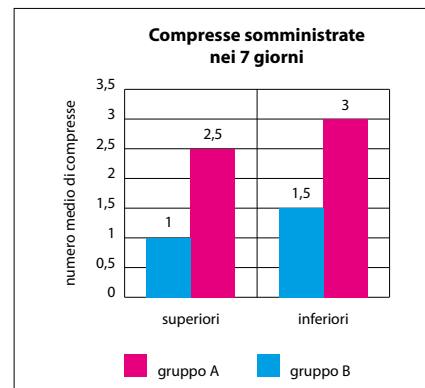


Fig. 8 Raccolta media di compresse assunte nei 7 giorni successivi all'intervento in rapporto ai due gruppi e nelle due sedi anatomiche.



RICERCA CLINICA

ridotta in media a 31,7 mm nel gruppo A e a 24,4 mm nel gruppo B. (Fig. 9-10, tab. 3)

**Indagini diagnostiche**

Per la valutazione dell'area da trattare e l'identificazione della posizione dei terzi molari inferiore si è fatto ricorso all'ortopantomografia (OPT) e al dental scan (TAC), tramite le quali sono stati quindi selezionati interventi si simili entità.

**DISCUSSIONE**

La chirurgia piezoelettrica fu introdotta in odontoiatria nel corso del 1970, quando Horton et al. [17 Horton JE, Tarpley Jr TM, Wood LD. The healing of surgical defects in alveolar bone produced with ultrasonic instrumentation, chisel, and rotary bur. Oral Surg Oral Med Oral Pathol 1975;39(4):536-46.] indagarono il processo di guarigione di siti chirurgici su animali, esaminando gli aspetti clinici e istologici di tre tecniche osteotomiche: scalpello, strumenti a ultrasuoni e fresa montata su manipolo a bassa velocità. L'obiettivo era analizzare istologicamente i siti operati durante il decorso postoperatorio a 1, 3, 7, 14, 28, 56 e 90 giorni. Questi autori osservarono che il processo di guarigione può essere considerato simile per le tecniche osteotomiche con strumenti a ultrasuoni o con scalpello; tuttavia, fu riscontrata una guarigione peggiore del tessuto osseo nei siti trattati con la fresa, ove si apprezzavano degenerazione degli elementi cellulari lungo i bordi dell'osteotomia, persistenza di tessuto fibrovascolare e ridotta reattività di osteoblasti e osteoclasti. La chirurgia piezoelettrica è stata rivalutata definitivamente alla fine degli anni ottanta e oggi è considerata una valida tecnica alternativa per la chirurgia ossea orale e maxillo-facciale, in quanto produce minori complicanze post operatorie. Pochi, e contrastanti nei risultati, sono gli studi presenti in letteratura che hanno ricercato una relazione tra le sequele post operatorie e il tipo di tecnica osteotomica utilizzata nella chirurgia di terzi molari inferiori inclusi. Gonzalez-Garcia et al. hanno riscontrato un aumento delle complicazioni post operatorie, e una riduzione della percentuale totale di successo, dopo inter-

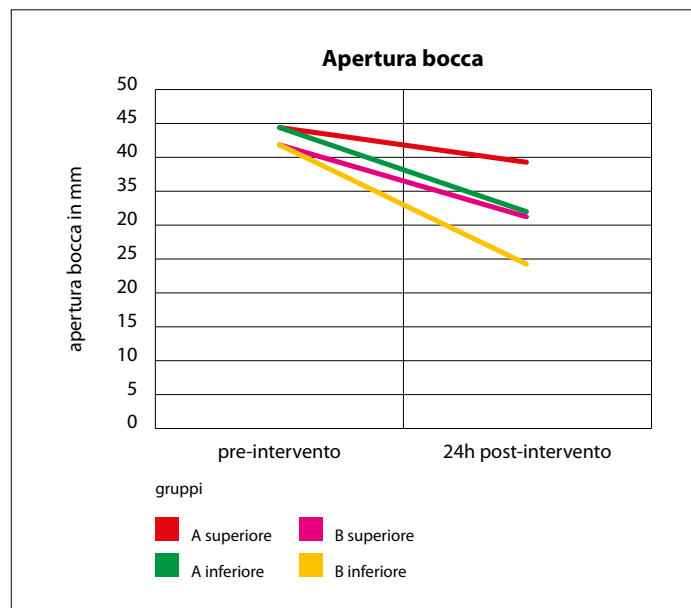


Fig. 9 Analisi del trisma post intervento tramite misura intercispale nei vari gruppi.

Gruppo	Pre intervento	Dopo 24h	Differenza
Gruppo A inferiore	44,4mm	31,7mm	12,7mm
Gruppo A superiore	44,4mm	39,2mm	5,2mm
Gruppo B inferiore	41,7mm	24,4mm	17,3 mm
Gruppo B superiore	41,7mm	31,2mm	10,5mm

Tab. 3 Valori medi.

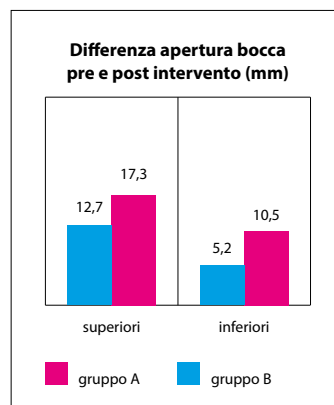


Fig. 10 Differenza apertura bocca pre e post intervento.

venti di distrazione ossea eseguiti con tecnica osteotomia piezoelettrica, rispetto a quelli in cui l'osteotomia era stata eseguita con tecnica rotante tradizionale. Al contrario Sortino et al., in uno studio prospettico Sortino F, Pedulla E, Masoli V. The piezoelectric and rotatory osteotomy technique in impacted third molar surgery: comparison of postoperative recovery. J Oral Maxillofac Surg 2008;66 (12):2444-8.], hanno mostrato una riduzione del serramento e della tumefazione facciale dopo estrazione di terzi molari inferiori inclusi, trattati con tecnica osteotomia piezoelettrica, piuttosto che con osteotomia mediante tecnica rotante. Anche Crippa et al. hanno riportato minore dolore postoperatorio, specie dopo 1 e 3 giorni, a seguito di mastoidectomie

## RICERCA CLINICA

eseguite mediante piezochirurgia, rispetto a quelle effettuate con tecnica rotante con microfrese. Istologicamente, in uno studio su maiali, Romeo et al. hanno mostrato che l'osteotomia eseguita con tecnica piezoelettrica produce minori segni d'insulto termico ai margini delle biopsie ossee, rispetto a quelle eseguite con tecnica rotante ad alta o anche a bassa velocità. In questo studio sono state confrontate le sequele postoperatorie dopo chirurgia di terzi molari inferiori inclusi, eseguita con tecnica piezoelettrica oppure osteotomica rotante con fresea e manipolo ad alta velocità, applicando i medesimi protocolli chirurgici e metodi di misurazione in entrambi i gruppi esaminati. L'estrazione di terzi molari inferiori inclusi è un intervento frequente in chirurgia orale, tuttavia spesso comporta fastidiose complicanze post operatorie per il paziente, quali la tumefazione facciale e il serramento mandibolare. I risultati di questo studio prospettico mostrano che l'osteotomia piezoelettrica riduce la tumefazione facciale e il serramento postoperatori, anche se aumenta la durata dell'intervento chirurgico. Tuttavia, quest'ultimo effetto può essere considerato meno rilevante se confrontato con la riduzione delle complicanze postoperatorie.

## CONCLUSIONI

La chirurgia piezoelettrica, rispetto alla tecnica osteotomica rotante ad alta velocità, riduce le complicanze post operatorie nella chirurgia dei terzi molari inclusi, nello specifico rende più sicuro l'intervento per quanto riguarda gli ottavi inferiori preservando il nervo mandibolare ed evitando possibili lesioni. Inoltre il minor traumatismo consente al paziente un periodo post operatorio più confortevole con assunzioni ridotte di farmaci antidolorifici. Per la valutazione della tumefazione facciale è stato complesso e difficile da misurare nonostante i punti di repere, per questo motivo al fine di avere dati reali e precisi si è preferito dopo i primi casi di non tenere in considerazione questo dato di misurazione. Il serramento quindi il trisma invece è stato un semplice ed efficace metodo di valutazione per lo studio. In conclusione da questa analisi è possibile evincere che il trattamento con strumento piezoelettrico migliora il decorso post operatorio del paziente in termini di dolore e trisma, inoltre si ha sempre la sicurezza di operare con una selettività precisa ed affidabile dello strumento.

## AIM OF WORK

## Aim of the work

Aim of this study is to evaluate the differences between rotating and piezoelectric instruments used for upper and lower third molars extraction, in terms of pain, pills of ibuprofene, post surgical lockjaw and time.

## MATERIALS AND METHODS

Same cases of impacted third molars, in terms of difficulty, have been selected for upper and lower jaw. After the extraction have been compared pain, number of ibuprofene pills and time spent on surgery using rotating instruments or piezoelectric ones.

## RESULTS

According with the data analyzed in this study, we had great improvements in terms of pain, number of pills and lockjaw using piezoelectric instruments. The only one improvement using rotating instruments is time spent on surgery.

## CONCLUSIONS

Piezoelectric instruments are the better choice for the surgeon because they result less aggressive and more comfortable than rotating instruments, which are to choose when clinical conditions allow surgeon to spend less time.

## BIBLIOGRAFIA

- Osborn TP, Frederickson G Jr, Small IA, et al. A prospective study of complications related to mandibular third molar surgery. *J Oral Maxillofac Surg* 1985;43:767.
- Pogrel MA. Complications of third molar surgery. In: Kaban LB, Pogrel MA, Perrot DH, editors. *Complications of oral and maxillofacial surgery*. Philadelphia: WB Saunders Co., 1997; 59-68.
- Mehrabi M, Allen JM, Roser SM. Therapeutic agents in perioperative third molar surgical procedures. *Oral Maxillofac Surg Clin North Am* 2007;19:69-84.
- Susarla S, Blaesus B, Magalnick D. Third molar surgery and associated complications. *Oral Maxillofac Surg Clin North Am* 2003;15:177.
- Tomaso Vercellotti. La chirurgia ossea piezoelettrica "Una nuova era". 2016;Pag 30-95
- Piersanti L, Di Lorenzo M, Monaco G, Marchetti C. Piezosurgery or conventional rotatory instruments for inferior third molar extractions? *J Oral Maxillofac Surg*. 2014 Sep;72(9) : 1647 -52. doi: 10.1016/j.joms.2014.04.032. Epub 2014 May 6
- Barone A, Marconcini S, Giacomelli L, Rispoli L, Calvo JL, Covani U. A randomized clinical evaluation of ultrasound bone surgery versus traditional rotary instruments in lower third molar extraction. *J Oral Maxillofac Surg*. 2010; 68(2): 330-336.
- Crippa B, Salzano FA, Mora R, Dellepiane M, Salami A, Guastini L. Comparison of postoperative pain: piezoelectric device versus microdrill. *Eur Arch Otorhinolaryngol* 2011 Feb 16;. [Epub ahead of print].
- Gonzalez-Garcia A, Diniz-Freitas M, Somoza-Martin M, Garcia-Garcia A. Piezoelectric and conventional osteotomy in alveolar distraction osteogenesis in a series of 17 patients. *Int J Oral Maxillofac Implants* 2008;23(5):891-6.
- Steubinger S, Kuttenberger J, Filippi A, Sader R, Zeilhofer HF. Intraoral piezosurgery: preliminary results of a new technique. *J Oral Maxillofac Surg* 2005;63(9):1283-7.
- Chiapasco M, De Cicco L, Marrone G. Side effects and complications associated with third molar surgery. *Oral Surg Oral Med Oral Pathol* 1993; 76:412-20.
- Neupert 3rd EA, Lee JW, Philput CB, Gordon JR. Evaluation of dexamethasone for reduction of postsurgical sequelae of third molar removal. *J Oral Maxillofac Surg* 1992;50(11):1177-82.
- Voegelien TC, Suter VG, Bornstein MM. Complications during and after surgical removal of mandibular third molars. Impact of patient related and anatomical factors. *Schweiz Monatsschr Zahnmed* 2008;118:192-8.
- Chiapasco M, Crescentini M, Romanono G. Germectomy or delayed removal of mandibular third molars: the relationship between age and incidence of complication. *J Oral Maxillofac Surg* 1995;53:418-442.
- Benediktsdóttir IS, Wenzel A, Petersen JK, Hintze H. Mandibular third molar removal: risk indicators for extended operation time, postoperative pain, and complications. *Oral Surg Oral Med Oral Pathol Oral Radiol Endod* 2004;97(4):438-46.
- Tay AB, Go WS. Effect of exposed inferior alveolar neurovascular bundle during surgical removal of impacted lower third molars. *J Oral Maxillofac Surg* 2004;62(5):592-600.

Hindawi  
BioMed Research International  
Volume 2018, Article ID 7352125, 7 pages  
<https://doi.org/10.1155/2018/7352125>

## Clinical Study

# Prefabricated Bar System for Immediate Loading in Edentulous Patients: A 5-Year Follow-Up Prospective Longitudinal Study

Enrico F. Gherlone,<sup>1</sup> Gianpaolo Sannino<sup>1</sup>,<sup>1</sup> Andrea Rapanelli,<sup>1</sup> Roberto Crespi,<sup>1</sup> Giorgio Gastaldi,<sup>1,2</sup> and Paolo Cappare<sup>1</sup>

<sup>1</sup>Department of Dentistry, IRCCS San Raffaele Hospital and Dental School, Vita Salute University, Via Olgettina, No. 48, 20123 Milan, Italy

<sup>2</sup>San Rocco Clinical Institute, Via dei Sabbioni, No. 24, Ome, 25050 Brescia, Italy

Correspondence should be addressed to Gianpaolo Sannino; [gianpaolosannino@gmail.com](mailto:gianpaolosannino@gmail.com)

Received 27 September 2017; Accepted 31 January 2018; Published 27 February 2018

Academic Editor: Gasparini Giulio

Copyright © 2018 Enrico F. Gherlone et al. This is an open access article distributed under the Creative Commons Attribution License, which permits unrestricted use, distribution, and reproduction in any medium, provided the original work is properly cited.

**Objectives.** The aim of this clinical study was to evaluate a new type of prefabricated bar system, supported by axial and tilted implants at 5-year follow-up. **Materials and Methods.** Twenty-nine consecutive participants (19 females, 10 males) (mean age 61.4 years), edentulous in one or both jaws, with severe atrophy of the posterior regions, were treated according to the All-on-four® protocol with immediately loaded axial (64) and tilted (64) implants supporting complete-arch screw-retained prostheses (12 maxillary, 20 mandibular) featuring a prefabricated bar as framework. Follow-up visits were performed at 3, 6, 12, 24, 48, and 60 months after implant insertion. Radiographic assessments were made using panoramic radiographs obtained immediately after surgery and at each follow-up visit. Bone level measurements around the axial and tilted implants were compared by means of the Student's *t*-test. **Results.** One axial implant failed in the lower jaw and did not compromise prosthetic function. The 60-month overall implant survival rate was 100% for axially positioned implants and 98.44% for tilted implants. The implant survival rates were 100% in the maxilla and 98.75% in the mandible. None of the 32 fixed prostheses were lost during the observation period, representing a prosthetic survival rate of 100%. No statistically significant differences ( $P > 0.05$ ) in marginal bone loss between tilted and axial implants were detected in either jaw over time. **Conclusions.** The use of the evaluated prefabricated bar for immediately loaded implants placed according to the All-on-four concept may significantly reduce implant failures; however, more long-term prospective clinical trials are needed to affirm the effectiveness of the surgical-prosthetic protocol.

## 1. Introduction

Clinical implant dentistry is oriented to low cost treatments using simple protocols that are well supported by scientific data, while providing immediate function through immediate restoration and loading of dental implants [1–4].

The All-on-four concept that employs tilted implants to restore edentulous patients has been proposed as an alternative to bone augmentation procedures [5].

The placement of four implants, two implants tilted posteriorly and two vertical implants in the anterior region, allows for avoiding bone augmentation procedures when rehabilitating a completely edentulous jaw with minimal bone volume [6]. The development to tilting of fewer implants

has been encouraged by the results from implant load analyses, demonstrating that four implants are enough for complete-arch prosthesis [7, 8].

Longer implants may be optimally placed in areas with good cortical anchorage to increase prosthetic support and reduce the length of the cantilever. This procedure supported a simpler, less expensive, and less time-consuming treatment compared to maxillary sinus lift or bone grafts [9, 10].

Krekmanov et al. treated forty-seven consecutive patients with implants placed in tilted positions: the cumulative success rates in the maxilla at 5 years were 98% for tilted implants and 93% for nontilted implants [11].

Analysis of the load distribution in one mandibular case showed no significant difference between tilted and the

nontilted implants, and the improved prosthesis support was confirmed. The immediate loading of tilted implants with a provisional restoration has been proposed as a simpler, more predictable, less expensive, and less time-consuming treatment of the atrophic maxilla [12]. However a passive fit of the framework plays a key role in splinting and loading non-parallel implants. Tensile, compressive, and bending forces may be dangerous for the osseointegration process and/or result in failure of the components [13].

Soldering or laser welding procedures are often needed to compensate loss of accuracy due to clinical/laboratory errors and achieve the appropriate adaptation of the framework. Using prefabricated parts to assemble prosthetic frameworks, such as bars, could be useful in reducing material distortion, chair time, and the high costs of fabrication. Therefore the aim of this clinical study was to evaluate the use of a prefabricated bar system for immediately loaded implants in patients rehabilitated according to the All-on-four concept with up to 5 years' follow-up.

## 2. Materials and Methods

**2.1. Patient Selection.** This prospective longitudinal study was performed at the Department of Dentistry, San Raffaele Hospital, Milan, Italy. Between March 2011 and March 2012, 29 participants (19 women, 10 men), aged between 41 and 72 years (mean age 61.4) were consecutively treated according to the All-on-four protocol with immediately loaded axial (64) and tilted (64) implants supporting complete-arch screw-retained prostheses (12 maxillary, 20 mandibular). Four patients were treated with both maxilla and mandibular prosthetic rehabilitation.

The investigation was conducted according to the tenets of the Helsinki Declaration and followed STROBE (Strengthening the Reporting of Observational Studies in Epidemiology) guidelines (<https://www.strobe-statement.org>). The study was approved by the appropriate ethics committees related to the institution in which it was performed and written informed consent was obtained from each participant. The following inclusion criteria were adopted: all patients were in good health, patients had to be edentulous (in one or both jaws) or they had to have a few hopeless teeth, severe atrophy of the mandible or maxilla in posterior regions. Exclusion criteria were the presence of any active infection or severe inflammation in the areas intended for implant placement, presence of chronic systemic disease, any interfering medication such as steroid therapy or bisphosphonate therapy, radiation therapy to head or neck region within 5 years, smoking more than 15 cigarettes, bruxism habits, and poor oral hygiene.

The diagnosis was made clinically and radiographically (preoperative panoramic radiograph and CT scan) (Figure 1). Study casts were obtained from jaw impressions of the patients and mounted on articulators. For edentulous patients, new removable prostheses were fabricated in order to restore optimal occlusal vertical dimension, mandibular position, and occlusal planes. The new prostheses were duplicated and used as radiographic templates during the

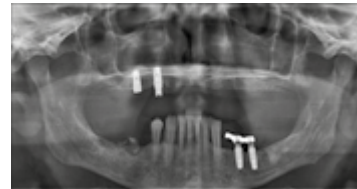

FIGURE 1: A preoperative panoramic radiograph.

TABLE 1: Implant diameters and lengths for maxilla and mandible (maxilla  $n = \text{implant} = 48$ ; mandible  $n = \text{implant} = 80$ ).

		Length 13 mm	Length 15 mm
Maxilla $n = 48$			
Upright $n = 24$	Diameter 4.5 mm	10	0
	Diameter 3.8 mm	14	0
Tilted $n = 24$	Diameter 4.5 mm	12	12
	Diameter 3.8 mm	0	0
Mandible $n = 80$			
Upright $n = 40$	Diameter 4.5 mm	4	10
	Diameter 3.8 mm	8	18
Tilted $n = 40$	Diameter 4.5 mm	18	14
	Diameter 3.8 mm	4	4

CT exams. The bone volume was accurately assessed for a safe and prosthetically driven implant placement. All patients gave their written informed consent for immediate implant loading.

**2.2. Surgical Procedure.** One hour prior to surgery the patients received 2 g amoxicillin (Zimox, Pfizer Italia, Latina, Italy) and 1 g twice a day for a week after surgical procedure. Surgery was performed under anesthesia induced by local infiltrations of optocain solution with adrenaline 1:80.000 (AstraZeneca, Milan, Italy).

In edentulous mandibles, incisions were made on top of the alveolar crest, from the first molar on one side to the first molar on the contralateral side with bilateral releasing incisions. Subperiosteal dissection on the lingual and vestibular surfaces was carried out and mental foramina were sited. The most posterior implants were placed close to the anterior wall of the mental loop and were tilted distally about 25–30 degrees relative to the occlusal plane. The posterior implants, which were 4.5 mm in diameter and 15 or 13 mm in length, typically emerged at the second premolar position. Anterior implants were either 4.5 or 3.8 mm in diameter and 13 mm in length (Winsix, Biosafin, Ancona, Italy) (Table 1). After placement of the posterior implants bilaterally, additional implants were placed in the anterior space.

In some cases tooth extractions were carried out and, when necessary, bone shaping was performed with a round

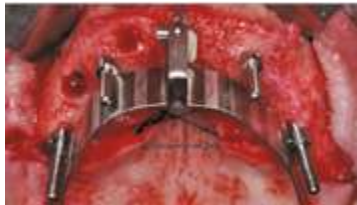

FIGURE 2: Implant site preparations assisted by a customized surgical guide.

bur to level the bone crest and, to achieve crestal positioning, bone recontouring was performed distal to the angled implants.

In edentulous maxillary patients, incisions were made on the alveolar crest from the first molar on one side to the first molar on the contralateral side with bilateral releasing incisions. Subperiosteal dissection was carried out. The most posterior implant was placed close to and parallel with the anterior sinus wall. Thus, this implant was tilted distally approximately 25 to 30 degrees. The lower corner of the implant neck was positioned at bone level (Figure 2).

Then the placement of implants in the anterior part of the maxilla was performed, and the implant neck was positioned at bone level. The posterior implants were 4.5 mm in diameter and 15 or 13 mm in length, and the anterior implants were either 4.5 or 3.8 mm in diameter and 13 mm in length (Winsix, Biosafin, Ancona, Italy) (Table 1).

Underpreparation was performed in soft bone to obtain high primary stability. The implant in immediate function had a final insertion torque ranging between 30 and 40 N/cm. Angulated abutments (Extreme Abutment, EA® Winsix, Biosafin, Ancona, Italy) for anterior implants were set at 17° and those for posterior implants at 30° to compensate for the lack of parallelism between implants as well as to place the prosthetic screw-access holes in an occlusal or lingual location. The angulated abutments were tightened with 25 N/cm of torque. Flap adaptation and suturing were performed in the usual manner with 4–0 nonresorbable suture (Vicryl; Ethicon, Johnson & Johnson, New Brunswick, NJ, USA).

Nonsteroidal anti-inflammatory drugs (Brufen 600 mg, Abbott Laboratories, Chicago, IL, USA) and chlorhexidine digluconate 0.2% mouthwash during the first 2 weeks after surgery were prescribed as postoperative care for all participants.

**2.3. Prosthetic Protocol.** After surgery straight cylinders (AT, WINSIX; Biosafin) were screwed onto the angulated abutment. The interimplant distance was measured (Figure 3(a)). Three bar tubes were shortened to the optimal lengths using the specific cutter bar device and a splitter disk [14]. Two bar joints (CF and CM, WINSIX; Biosafin) were inserted into the end of each tube in order to connect the whole structure to the cylinders (Figure 3(b)). The height of the cylinders was chosen to make the bar parallel to the occlusal plane. All the joints were connected to the cylinders and fixed by

means of resin cements. No soldering was performed; the universal nature of the ball joint allows the tube bar to be located in the horizontal plane in a truly stress free alignment [15]. The prostheses were provided with four large openings according to planned cylinder emergence. The passive seating and the occlusal relationship of the removable prostheses were checked (Figure 4). The bar system was attached to the denture with self-curing acrylic resin.

After polymerization, the prostheses with the incorporated bar system were removed from the implants and retention, marginal precision, and stability were improved by resin addition around the collar of the cylinders (Figures 5(a) and 5(b)). Screw-retained full-arch temporary prostheses were placed (Figure 6).

Cantilevers were extended to the first molar regions and in three cases only to second premolar. Articulating paper (Bausch Articulating Paper, Nashua, NH, USA) was used to check the occlusion and adjust it, if necessary. Static occlusion consisted of central contacts established on all masticatory units. Dynamic occlusion included canine/premolar guidance, regardless of the opposite arch settings. Screw-access holes were covered with provisional resin (Fermit, Ivoclar Vivadent, Naturno, Bolzano, Italy). Fifteen days after prosthesis delivery, a final occlusal adjustment was performed.

All patients followed a soft/liquid diet for 2 months (the bread consistency varied).

After 4 months from implant positioning, 32 definitive prostheses were placed (Figure 7).

**2.4. Follow-Up.** Follow-up visits were performed by a dental hygienist, trained for clinical studies, and calibrated at 3, 6, 12, 24, 36, 48, and 60 months after implant insertion. Success criteria for implant survival were presence of implant stability, absence of radiolucent zone around the implants, no mucosal suppuration, and no pain. Restoration success was defined as the absence of fractures of the acrylic resin superstructure. Implant survival was defined as the absence of implant mobility, swelling, or pain in the surgical site at the time of examination.

Implant success was defined as implant survival plus marginal bone loss of less than 1.5 mm after 1 year of loading and no more than 0.2 mm of loss between each follow-up appointment after the first year of function.

**2.5. Radiographic Examination.** Radiographic assessments were made using panoramic radiographs obtained immediately after surgery and at each follow-up visit (Figure 8). Bone level measurements were performed on the mesial and distal aspect of each implant, using the implant-abutment junction as a reference point.

To adjust for dimensional distortion and enlargement on the radiographs, the actual sizes of the implants were compared to the measured implant dimensions on the radiograph [1, 15]. A radiologist twice measured the changes in marginal bone height over time: the reference points were marked and the lines were measured on the screen interactively (the numeric value of measurements was reported by software) (CDR, Schick Technologies, Long Island City, NY, USA). The



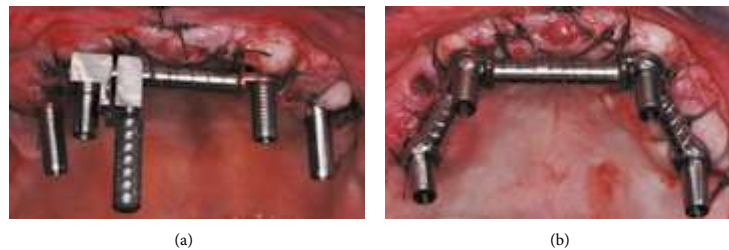

FIGURE 3: Each tube was shortened at the correct implant distance (a) and connected to adapters by using two dedicated bar joints in order to develop the whole bar structure (b).

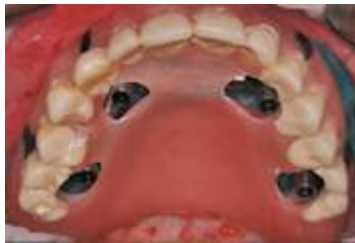

FIGURE 4: Passive seating and occlusal relationship of the removable prostheses were checked. Removable prostheses were released in correspondence with the expected bar volume. The contacts between the prostheses and the mucosal regions, which were not involved in the surgical procedures, were used as anatomical pre- and postsurgical landmarks to avoid variations in the occlusal relationships previously achieved. Four large openings were made according to planned cylinder emergence.

implant length (a known dimension) was used for calibration. The radiographic measurements were compared to the values obtained immediately after surgery.

**2.6. Statistical Analysis.** A dedicated software (SPSS 11.5.0, SPSS, Chicago, IL, USA) was used for all statistical analyses. Sample size calculation was performed before patients recruitment. Bone level measurements were reported as means  $\pm$  standard deviations at 6, 12, and 60 months. Bone loss around the upright and tilted implants was compared by means of the Student's *t*-test at a significance level of  $P = 0.05$ .

### 3. Results

In the first four months after implant placement, one implant failed (one mandibular), as a result of painfulness (Table 2). The failed implant was axial and did not compromise prosthetic function. An implant of the same length and larger diameter was immediately placed and left unloaded until a new definitive prosthesis was completed and inserted.

The 5-year overall implant survival rate was 100% for axially positioned implants and 98.44% for tilted implants.

TABLE 2: Failure table for upright and tilted implants (maxilla  $n =$  implant = 48; mandible  $n =$  implant = 80).

	Placed	Failed	Survival (%)
Maxilla $n = 48$			
Upright	24	0	100
Tilted	24	0	100
Mandible $n = 80$			
Upright	40	1	97.50
Tilted	40	0	100

The implant survival rates were 100% in the maxilla and 98.75% in the mandible.

None of the 32 fixed prostheses were lost during the observation period, representing a prosthetic survival rate of 100%. Occlusal screw loosening, was observed in 3.03% of cases (4 implants) within 6 months of follow-up.

Radiographic results are reported in Table 3. At the 60-month evaluation, peri-implant crestal bone loss averaged  $1.08 \pm 0.45$  mm for upright maxillary implants ( $n = 24$  implants) and  $1.02 \pm 0.67$  mm for tilted maxillary implants ( $n = 24$  implants) (Table 3). In the mandible, a mean peri-implant crestal bone loss of  $1.04 \pm 0.61$  mm for upright implants ( $n = 40$ ) and  $1.09 \pm 0.56$  mm for tilted implants ( $n = 40$ ) was found (Table 3).

No statistically significant differences ( $P > 0.05$ ) in crestal bone loss between tilted and upright implants were detected at 6-, 12-, and 60-month follow-up evaluation in either jaw.

### 4. Discussion

The data from the present prospective study have shown encouraging clinical results as a means of restoring edentulous jaws with immediately loaded full-arch fixed prostheses supported by a prefabricated bar system and screwed onto two anterior axial implants and two distal tilted implants.

One loaded implant was lost, and the prosthesis survived on the remaining three implants until the replacement implant was loaded. The use of three loaded implants allows for the failure of one implant without failure of the prosthesis. The failed implant was inserted with a torque of at least 40 Ncm.



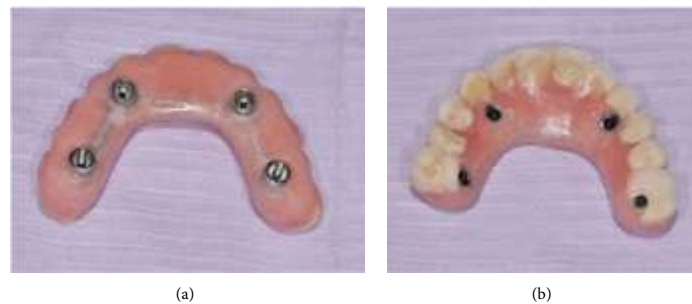

FIGURE 5: The bar was attached to the denture with self-curing acrylic resin and marginal precision was improved by resin addition around the collar of the adapters ((a) crestal view, (b) occlusal view).

TABLE 3: Crestal bone loss values (mean ± SD) for maxillary and mandibular tilted and upright implants (maxilla *n* = implant = 48; mandible *n* = implant = 80).

Bone Loss	Upright		Tilted	
	Maxilla <i>n</i> = 24	Mandible <i>n</i> = 40	Maxilla <i>n</i> = 24	Mandible <i>n</i> = 40
6 months (mm)	0.99 ± 0.23	0.97 ± 0.31	1.00 ± 0.32	1.01 ± 0.27
12 months (mm)	1.03 ± 0.33	1.05 ± 0.44	1.06 ± 0.50	1.08 ± 0.41
60 months (mm)	1.08 ± 0.45	1.04 ± 0.61	1.02 ± 0.67	1.09 ± 0.56

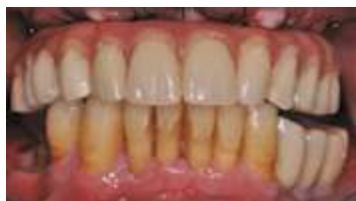

FIGURE 6: Provisional screw-retained bar-reinforced acrylic resin prosthesis delivery. Frontal view.

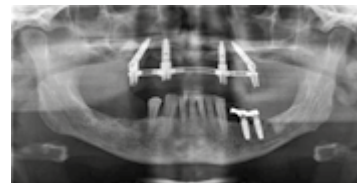


FIGURE 8: Panoramic radiograph at 60-month follow-up.

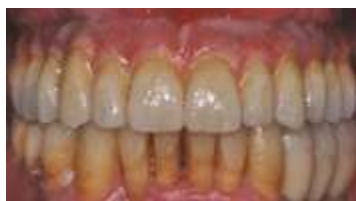

FIGURE 7: Definitive screw-retained full-arch restoration at 60-month follow-up.

In the current study, radiographs demonstrated that the bone resorption pattern for posterior, angulated implants was similar on the mesial and distal surfaces. This was in agreement with the findings of other studies [8–10, 16–18].

No statistically significant differences ( $P > 0.05$ ) in crestal bone loss between tilted and upright implants were

detected at 6- and 12-month follow-up evaluation in either jaw, and this is also consistent with other data found in the literature, confirming that tilted implants may achieve the same outcome as implants placed in an upright position [6, 16]. This positive result is associated with biomechanical advantages, since in this protocol implants are placed in strategic positions from a load-sharing point of view. Placement of the 2 well-anchored posterior tilted implants together with the anterior upright implants can provide a predictable foundation for an implant-supported prosthesis. This surgical-prosthetic procedure also seems to validate the reduced length of the prostheses cantilevered segments. Implant placement and orientation provided effective cross-arch stabilization without the need for bone grafting procedures. Excluding maxillary sinus bone grafts resulted in significantly less morbidity and dramatically decreased the financial costs associated with those procedures.

This treatment protocol allows the implant rehabilitation to be simplified and shortened for both the patient and the clinical team. The postsurgical period is more comfortable for

patients since they have been utilizing their fixed prosthesis from the first day [9].

The immediate creation of the temporary restoration with a simple and repeatable prosthetic protocol represents a major advantage for patients, providing less expensive and less time-consuming treatments [10].

Traditional laboratory procedures such as soldering and welding may give rise to errors and increase in cost; furthermore, several bar framework material, such as gold alloy, silver-palladium alloy, commercially pure titanium, and cobalt-chromium alloy transfer significant stress to the supporting peri-implant tissues [19].

The key of prefabricated precision-milled components is that the framework is assembled without the use of soldering, laser welding, or conventional bonding techniques, thus reducing stress transmission to bone around the implants.

There is no casting, soldering, laser welding, or bonding of components when fabricating the definitive bar. This, combined with the universal ball joint nature of the components, ensures a true passive fit when the bar is assembled and seated.

No laboratory time is required to fabricate the bar and there are no gold-alloy charges. Clinically, there is no need for the bar sections to be soldered in an attempt to achieve passive fit—a step that may need repeating—as with the conventional method. The prefabricated bar is relatively inexpensive compared with conventional gold castings and CAD/CAM options.

Precision-milled components provide an improved quality of fit. The physical and mechanical properties of the component materials can be controlled accurately, which is difficult to achieve with conventional casting methods [14]. The passive-fit bar assembly can result in greatly reduced stress transmission to the supporting implants [14]. Studies have demonstrated that this is also a viable treatment option for immediate-loading situations in the mandible, provided that the implants achieved insertion torques exceeding 50 Ncm approximately [20].

A clinical study [21] evaluated initial, 4-month, and 1-year stability of immediately loaded dental implants inserted according to a protocol of lower rehabilitation with prefabricated bars. Immediately after implant installation, resonance frequency analysis (RFA) for each implant was registered as well as after 4 months and 1 year with the prosthetic bar removed as it is a screwed system. The analysis of variance showed a statistically significant result ( $P = 0.015$ ) among implant stability quotient values for the different periods evaluated. Tukey test results showed statistically significant differences between 1-year results and the initial periods but there was no statistically significant difference between initial and 4-month results ( $P > 0.05$ ).

Prefabricated bars were compared to custom-made bars used for implant-retained mandibular complete overdentures [22]. All patients were evaluated clinically and radiographically immediately after overdenture delivery and after 6, 12, and 18 months.

There was more pronounced bone resorption in cast bar group more than the prefabricated bar group and minimal marginal bone loss in the group treated with prefabricated

bar. The prefabricated bar overdentures showed less bone resorption distal to the implants in comparison with the cast bar implant-retained overdentures. The prefabricated bar implant-retained overdenture showed low significant reduction in the bone height after 1 year, and a very highly significant reduction after 18 months.

## 5. Conclusions

Data and results of this clinical study demonstrated high success rates and a low number of complications.

The use of the evaluated prefabricated bar for immediately loaded implants placed according to the All-on-four concept may significantly reduce implant failures; however, more long-term prospective clinical trials are needed to affirm the effectiveness of the surgical-prosthetic protocol especially performed in various clinical centers from different clinicians.

## Ethical Approval

Italian Ministry of Health approved the study, Protocol no. RF-FSR-2007-646412, Italian National Registry Office of Research, no. L1660026.

## Conflicts of Interest

All the authors declare that there are no conflicts of interest regarding the publication of this paper.

## References

- [1] M. Hinze, T. Thalmair, W. Bolz, and H. Wachtel, "Immediate loading of fixed provisional prostheses using four implants for the rehabilitation of the edentulous arch: a prospective clinical study," *The International Journal of Oral & Maxillofacial Implants*, vol. 25, no. 5, pp. 1011–1018, 2010.
- [2] M. Chiapasco, "Early and immediate restoration and loading of implants in completely edentulous patients," *The International Journal of Oral & Maxillofacial Implants*, vol. 19, pp. 76–91, 2004.
- [3] M. Del Fabbro, T. Testori, L. Francetti, S. Taschieri, and R. Weinstein, "Systematic review of survival rates for immediately loaded dental implants," *International Journal of Periodontics and Restorative Dentistry*, vol. 26, no. 3, pp. 249–263, 2006.
- [4] R. Crespi, P. Capparè, G. Gastaldi, and E. F. E. Gherlone, "Immediate occlusal loading of full-arch rehabilitations: screw-retained versus cement-retained prosthesis. An 8-year clinical evaluation," *The International journal of oral & maxillofacial implants*, vol. 29, no. 6, pp. 1406–1411, 2014.
- [5] P. Maló, B. Rangert, and M. Nobre, "'All-on-four' immediate-function concept with Brånemark system implants for completely edentulous mandibles: a retrospective clinical study," *Clinical Implant Dentistry and Related Research*, vol. 5, supplement 1, pp. 2–9, 2003.
- [6] P. Maló, B. Rangert, and M. Nobre, "All-on-4 immediate-function concept with Brånemark System implants for completely edentulous maxillae: a 1-year retrospective clinical study," *Clinical Implant Dentistry and Related Research*, vol. 7, supplement 1, pp. S88–S94, 2005.

- [7] J. Duyck, H. Van Oosterwyck, J. V. Sloten, M. De Cooman, R. Puers, and I. Naert, "Magnitude and distribution of occlusal forces on oral implants supporting fixed prostheses: An in vivo study," *Clinical Oral Implants Research*, vol. 11, no. 5, pp. 465–475, 2000.
- [8] G. Sannino, "All-on-4 concept: a 3-dimensional finite element analysis," *Journal of Oral Implantology*, vol. 41, no. 2, pp. 163–171, 2015.
- [9] E. L. Agliardi, A. Pozzi, C. F. J. Stappert, R. Benzi, D. Romeo, and E. Gherlone, "Immediate fixed rehabilitation of the edentulous maxilla: A prospective clinical and radiological study after 3 years of loading," *Clinical Implant Dentistry and Related Research*, vol. 16, no. 2, pp. 292–302, 2014.
- [10] E. Gherlone, P. Capparé, R. Vinci, F. Ferrini, G. Gastaldi, and R. Crespi, "Conventional versus digital impressions for "All-on-Four" restorations," *The International Journal of Oral & Maxillofacial Implants*, vol. 31, no. 2, pp. 324–330, 2016.
- [11] L. Krekmanov, M. Kahn, B. Rangert, and H. Lindström, "Tilting of posterior mandibular and maxillary implants for improved prosthesis support," *The International Journal of Oral & Maxillofacial Implants*, vol. 15, no. 3, pp. 405–414, 2000.
- [12] R. Calandriello and M. Tomatis, "Simplified treatment of the atrophic posterior maxilla via immediate/early function and tilted implants: a prospective 1-year clinical study," *Clinical Implant Dentistry and Related Research*, vol. 7, no. 1, pp. S1–S12, 2005.
- [13] C. Kunavisarut, L. A. Lang, B. R. Stoner, and D. A. Felton, "Finite element analysis on dental implant-supported prostheses without passive fit," *Journal of Prosthodontics*, vol. 11, no. 1, pp. 30–40, 2002.
- [14] G. Sannino, P. Bollero, A. Barlattani, and E. Gherlone, "A retrospective 2-year clinical study of immediate prosthetic rehabilitation of edentulous jaws with four implants and prefabricated bars," *Journal of Prosthodontics*, vol. 26, no. 5, pp. 387–394, 2017.
- [15] M. B. Hurzeler, A. Kirsch, K. L. Ackermann, and C. R. Quinones, "Reconstruction of the severely resorbed maxilla with dental implants in the augmented maxillary sinus: a 5-year clinical investigation," *The International Journal of Oral & Maxillofacial Implants*, vol. 11, pp. 466–475, 1996.
- [16] J. I. Smedberg, E. Lothigius, I. Bodin, A. Frykholm, and K. Nilner, "A clinical and radiological two-year follow-up study of maxillary overdentures on osseointegrated implants," *Clinical Oral Implants Research*, vol. 4, no. 1, pp. 39–46, 1993.
- [17] Y. Fortin, R. M. Sullivan, and B. R. Rangert, "The Marius implant bridge: Surgical and prosthetic rehabilitation for the completely edentulous upper jaw with moderate to severe resorption: A 5-year retrospective clinical study," *Clinical Implant Dentistry and Related Research*, vol. 4, no. 2, pp. 69–77, 2002.
- [18] G. Sannino and A. Barlattani, "Straight versus angulated abutments on tilted implants in immediate fixed rehabilitation of the edentulous mandible: A 3-year retrospective comparative study," *International Journal of Prosthodontics*, vol. 29, no. 3, pp. 219–226, 2016.
- [19] A. O. Spazzin, M. B. F. dos Santos, L. C. Sobrinho, R. L. X. Consani, and M. F. Mesquita, "Effects of horizontal misfit and bar framework material on the stress distribution of an overdenture-retaining bar system: A 3D finite element analysis," *Journal of Prosthodontics*, vol. 20, no. 7, pp. 517–522, 2011.
- [20] S.-R. Ha, S.-H. Kim, S.-I. Song, S.-T. Hong, and G.-Y. Kim, "Implant-supported overdenture with prefabricated bar attachment system in mandibular edentulous patient," *The Journal of Advanced Prosthodontics*, vol. 4, no. 4, pp. 254–258, 2012.
- [21] A. C. M. Melo, M. C. De Freitas, S. R. Bernardes, I. A. De Mattias Sartori, A. P. F. Bassi, and G. Thomé, "A prospective follow-up study of 44 mandibular immediately loaded implants using resonance frequency analysis: Preliminary 1-Year results," *Implant Dentistry*, vol. 18, no. 6, pp. 530–538, 2009.
- [22] M. A. Abd El-Dayem, A. S. Assad, M. E. Eldin Sanad, and S. A. A.-H. Mahmoud Mogahed, "Comparison of prefabricated and custom-made bars used for implant-retained mandibular complete overdentures," *Implant Dentistry*, vol. 18, no. 6, pp. 501–511, 2009.

**1 Three-Dimensional Implant Positioning with a Piezosurgery Implant Site Preparation Technique and an Intraoral Surgical Navigation System: Case Report**

G.Pellegrino,V.Taraschi,T.Vercellotti,C.Marchetti

The International Journal of Oral & Maxillofacial Implants Volume 32, number 3 - 2017

---

**2 Immediate fixed rehabilitation supported by axial and tilted implants of edentulous jaws: a prospective longitudinal study in HIV – positive patients**

G. Gastaldi, R. Vinci, M.C.Francia, F. Bova, P.Cappare'

Journal of Osseointegration –May – August 2017; 9 (2)

---

**3 Alternative terapeutiche al grande rialzo di seno mascellare: impianti tiltati**

A. Cardarelli, F. Cardarelli, M. Grechi, R. Vinci, E. F. Gherlone

Quintessenza implantologia Luglio 2017

---

**4 Evaluation of Ultrashort and Longer Implants with Microrough Surfaces: Results of a 24-to-36-Month Prospective Study**

L. Malchiodi, R. Caricasulo, A. Cucchi, R.Vinci, E. Agliardi, E.Gherlone

The International Journal of Oral & Maxillofacial Implant 2017

---

**5 The association between three attitude-related indexes of oral hygiene and secondary implant failures: A retrospective longitudinal study.**

S.Tecco , M.G. Grusovin , S. Sciara , F. Bova , G.Pantaleo ,P. Cappare' .

Int J Dent Hyg. 2017 Jul 11. doi: 10.1111/idh.12300.

**6 Prosthetic rehabilitation after total resection of the nose and premaxilla for adenosquamous carcinoma**

G. Marzorati ,L. Palumbo , P. Capparè , G. Gastaldi , E.F. Gherlone .  
Journal of Osseointegration 2017; 9(1): 24

---

**7 Dental implant rehabilitation at the Dental Clinic, Department of Dentistry, San Raffaele Hospital, Milan: a report of 2015/2016**

N. Cantile , G.P. Patianna , A. Cardarelli , M. Nagni , M. Grechi  
Journal of Osseointegration 2017; 9(1): 31

---

**8 Comparative study between sinus floor elevation and tilted implant in the atrophic posterior maxilla**

C. Manenti , F. Mottola , G. Tetè , R. Vinci  
Journal of Osseointegration 2017; 9(1): 47

---

**9 Split crest technique in the atrophic maxilla: indication for the treatment**

F. Mottola , C. Manenti , G. Tetè , R. Vinci  
Journal of Osseointegration 2017; 9(1): 49

---

**10 Aesthetic issues about the implant-prosthetic rehabilitation of the hard and soft tissues in case of agenesis of anterior teeth**

L. Pittari , Raimondi, F. Lucchetti , M. Tucci, A. Gualandris , R. Vinci  
Journal of Osseointegration 2017; 9(1): 51

**11 Implant prosthetic rehabilitation in HIV-positive patients: a comparison of two different implant surface roughness**

M. C Francia , S. Galli , F. Bova, S. Ferrari Parabita , P. Capparè , E.F. Gherlone  
Journal of Osseointegration 2017; 9(1): 77

---

**12 Survival rate of "all-on-four" rehabilitations in HIV-positive patients**

S. Galli , M.C. Francia , A. Rapanelli , S. Bianchi , P Capparè  
Journal of Osseointegration 2017; 9(1): 78

---

**13 Oral rehabilitation of fully edentulous patients according to the "all on four" protocol at the Dental Clinic, Department of Dentistry, San Raffaele Hospital, Milan**

G.P Patianna, A. Cardarelli , P. Capparè , R. Vinci , E.F. Gherlone  
Journal of Osseointegration 2017; 9(1): 81

---

**14 Grande rialzo di seno mascellare con l'utilizzo di Hypro-Oss e contestuale inserimento di impianti in una severa atrofia**

A.Cardarelli, F. Cardarelli, R. Vinci, E. Gherlone  
Implant Tribune Italian Edition – Novembre 2017

---

**15 Implant therapy in patient with severe periodontal disease**

A.Cardarelli, F. Cardarelli, R. Vinci, E. Gherlone  
Implant Tribune Italian Edition – Novembre 2017



## Three-Dimensional Implant Positioning with a Piezosurgery Implant Site Preparation Technique and an Intraoral Surgical Navigation System: Case Report

Gerardo Pellegrino, DDS, PhD<sup>1</sup>/Valerio Taraschi, BPhil, PhD<sup>2</sup>/Tomaso Vercellotti, MD, DDS<sup>3</sup>/  
Besim Ben-Nissan, BSc, PhD<sup>4</sup>/Claudio Marchetti, MD, DDS<sup>5</sup>

*This case report describes new implant site preparation techniques joining the benefits of using an intraoral navigation system to optimize three-dimensional implant site positioning in combination with an ultrasonic osteotomy. A report of five patients is presented, and the implant positions as planned in the navigation software with the postoperative scan image were compared. The preliminary results are useful, although further clinical studies with larger populations are needed to confirm these findings. INT J ORAL MAXILLOFAC IMPLANTS 2017;32:e163–e165. doi: 10.11607/jim.5800*

**Keywords:** anatomical preservation, image-guided surgery, oral implantology, osseointegration, piezoelectric surgery, 3D implant positioning

**P**iezoelectric bone surgery procedures have commonly been used for osteotomies for alveolar bone crest expansion, maxillary sinus elevation, and dental implant removal, which can be performed accurately and safely, providing excellent clinical and biologic results.

A recent application of Piezosurgery (Mectron Srl) in dental implantology has been the preparation of implant sites<sup>1</sup> for a large number of implants. The outcome of this clinical study showed 97.7% success in all anatomical situations (ridge expansion, sinus elevation, bony block, and guided bone regeneration). The advantage of preparing crestal cortical bone separately from the underlining cancellous bone (differential implant site preparation) is to optimize the primary stability in a difficult anatomical situation. In particular, such differential preparation allows widening of a socket

wall by a three-dimensional (3D) cutting action that includes lateral movements. Studies<sup>2,3</sup> showed the maintenance of primary stability due to early osteogenesis, promoted by ultrasonic stimulation of stem cells, as demonstrated by an increase in growth factors.

Multiple factors contribute to this result. Among them, there is reduced mechanical and thermal trauma, improved washing of smaller bone debris, and improved efficacy of debridement by cavitation versus the regular irrigation action using normal drill bits.

As a consequence, both primary and secondary stability are improved, and the risk of postoperative necrosis is reduced.<sup>4,5</sup>

Other studies have examined how ultrasonic drilling can be more accurate than conventional rotary instruments in terms of uniformity of the osteotomy cut.<sup>4,6</sup> Mixed traditional and ultrasonic techniques for implant site osteotomies have been evaluated clinically for implant placement, revealing that implant stability might develop more rapidly.<sup>7,8</sup>

Because of the nonaxial cutting action, it is ideal if the implant socket is prepared through live tracking of the Piezosurgery tip. However, since it is based on ultrasonic vibrations, the piezoelectric surgical technique avoids the macrovibrations generated by conventional drilling, allowing greater intraoperative control with higher safety when cutting in difficult anatomical regions.<sup>9,10</sup> In this context of reduced vibrations, if applied, a tracking system could facilitate access to deeper cortical areas of the surgical site, guiding the cutting action, for example, in thin bony crests, near the mandibular nerve, or close to the maxillary sinus.

<sup>1</sup>Research Fellow and Visiting Professor at Master in Oral Surgery and Implantology, Oral and Maxillofacial Surgery Division, DIBINEM, University of Bologna, Italy.

<sup>2</sup>Honorary Fellow, University of Technology - Sydney, School of Mathematical and Physical Sciences, Australia.

<sup>3</sup>Founder and International Chairman, International Piezosurgery Academy (IPA); Visiting Professor, Queen Mary University of London, United Kingdom.

<sup>4</sup>Visiting Professor, University of Technology - Sydney, School of Mathematical and Physical Sciences, Australia.

<sup>5</sup>Professor of Maxillofacial Surgery and Chief of Oral and Maxillo-facial Division, DIBINEM, University of Bologna, Italy.

**Correspondence to:** Gerardo Pellegrino, 125, Via San Vitale 59, 40125, Bologna, Italy. Email: gerardo.pellegrino2@unibo.it

©2017 by Quintessence Publishing Co Inc.



Pellogrino et al

The ImplaNav Navigation System consists of a software interface running in Microsoft Windows (Microsoft), which processes positional data obtained from a stereoscopic camera. In each frame, the firmware of the camera (NDI Polaris Vicra; Northern Digital) identifies the 3D coordinates of a predefined geometric pattern of reflective spheres, which are segmented on-the-fly in the two-dimensional (2D) image obtained from the frame. The software-hardware system is modular, so that the assembly of the main components—the camera, reflective tools with relative supports, and the processing unit—can be customized to facilitate operations in a dental facility.

Surgical planning is performed with the ImplaNav software on a 3D model reconstructed from a cone beam computed tomography (CBCT) scan. Image-to-world registration is performed using radiopaque markers embedded in a calibration plate manufactured in biocompatible plastic, which can be tooth-supported for partially edentulous patients or bone-supported via a provisional mini-fixture for full-arch reconstructions. Both the patient and the surgical handpiece are equipped with a minimally invasive optical reference frame supporting markers that reflect infrared light from the stereoscopic camera.

Given the multiple axes of symmetry of the Piezosurgery inserts, in contrast to the straight tips used for contra-angle handpieces, a specialized tool has been designed to allow the calibration, and thus, correct virtualization of the tips in the 3D-rendering environment. Because of its complex internal design, a prototype of the calibration tool was manufactured via selective laser sintering using an EOS P380 machine (Advanced Manufacturing Services).

Following the calibration procedure, the position of the implant site is registered with the 3D model that the surgeon used to plan the surgery virtually. During the surgical planning stage, the optimal position for the implants is evaluated according to the virtual representation of the prosthetic restoration, which can be scanned with an optical laser or as a radiographic template via CT data. Alternatively, the prostheses are loaded from an internal software library and superimposed on the CT data. The registration procedure consists of touching three points with the tip mounted on the handpiece. Because of the curved nature of the tips, axis calibration is performed by identifying the axis of the distal end of the ultrasonic tip. This set-up allows the surgeon to follow in real-time, via an LCD display, the increasing depth of the cutting action of the tip.

## MATERIALS AND METHODS

In this preliminary clinical study, five patients referred to the Oral and Maxillofacial Department, University of

Bologna, Italy, in need of implant-born prosthetic rehabilitation were included. The patients were all in good health and between 25 and 60 years of age. No patient had contraindications for implant surgery. After being briefed about the surgical treatment plan, all patients signed an informed consent for the procedure.

Two maxillae and three mandibles were treated; five implant sites were considered. The patient cases were chosen for their complexity and difficulty due to reduced bone support in the horizontal or vertical direction during preparation of the implant site.

For two patients, a full ultrasonic implant site preparation was performed, and in one case, flapless surgery was performed. In the remaining cases, implant preparation was performed using ultrasonic tips and completed using progressively larger standard drills up to the planned implant diameter. The mandible cases included the selective preparation of the lingual cortical wall in the thin-crest posterior mandible, performed using both a full piezoelectric procedure and a combination of Piezosurgery and traditional drilling. It is known that, in this anatomical region, “traditional” socketing procedures often result in a shifting of the implant due to contact between the drill tip and the lingual wall (Fig 1a).

### Technique One: Combined Piezo-drill-Navigated Implant Site Preparation

In these cases, using the piezo-navigated technique, the surgeon could perform a combined differential preparation (Fig 1b), consisting primarily of the selective preparation of the lingual cortical wall using IMS1 and IM2P inserts, with a real-time monitoring of the tip position (Fig 2a). With the ultrasonic tip, the surgeon could keep the right trajectory and better instrument control. This procedure proved to be more accurate and safer than using rotary instruments, which were instead only used as part of the final step to refine the implant socket (Fig 2b). The same method was also used in a maxillary case with flapless surgery.

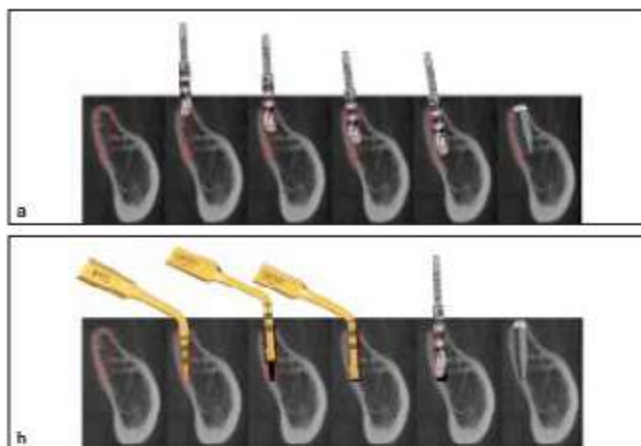
### Technique Two: 3D Piezo-Navigated Implant Site Preparation

In one mandibular case, flapless surgery was performed, following a full piezo-navigated preparation (Fig 3). Using only two Piezosurgery inserts, IMS1 and OT4 (Fig 4), the socketing procedure was completed via a 3D approach, visualizing the live tracked position of the ultrasonic tip and the virtual volume of the planned implant on a digital display. While using an insert with a 3D cutting edge, the software guides the progressive circumferential border preparation to the desired depth. The surgeon shapes the socket to the virtual volume that will be occupied by the planned implant by way of radial extensions according to feedback from the navigation system.

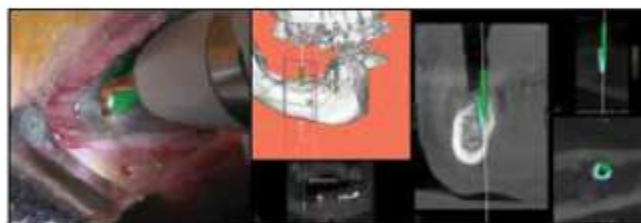
e162 Volume 32, Number 3, 2017

© 2017 BY QUINTESSENCE PUBLISHING CO, INC. PRINTING OF THIS DOCUMENT IS RESTRICTED TO PERSONAL USE ONLY. NO PART MAY BE REPRODUCED OR TRANSMITTED IN ANY FORM WITHOUT WRITTEN PERMISSION FROM THE PUBLISHER.


**Fig 1** (a) Conventional implant shift due to contact between the tip and the lingual cortical wall. (b) Different preparation using a combined piezoelectric and traditional drilling process.



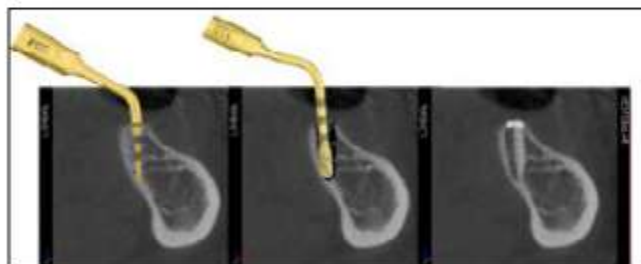**Fig 2a** Selective preparation of the lingual cortical wall using IMS1 and IM2P inserts.



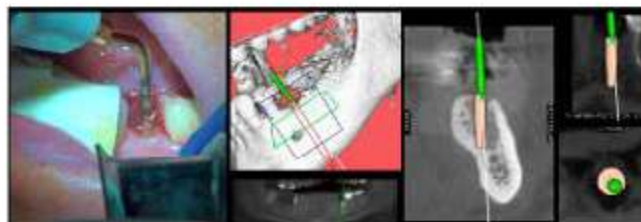
**Fig 2b** Rotary instruments, which are only used to refine the implant socket.



**Fig 3** Different steps of a full piezo-navigated implant site preparation using only two Piezosurgery inserts, IMS1 and OT4, and a 3D approach.



**Fig 4** Contextual visualization on a digital display of the live tracked position of the OT4 Piezosurgery tip and the virtually planned implant.

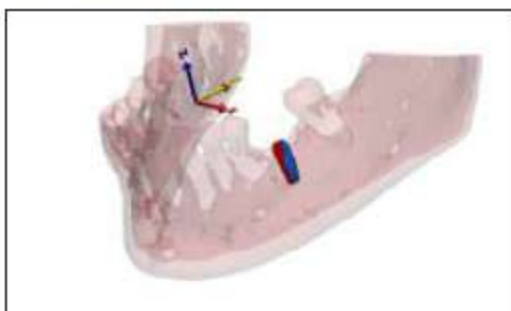



Pollegriño et al



**Fig 5** Vertical ultrasonic implant site preparation hooking in real time, on the navigation system display, the tip depth.



**Fig 6** Superposition of preoperative surgical plan with postoperative segmentation of the inserted implant.

### Technique Three: Full Piezo-Navigated Implant Site Preparation

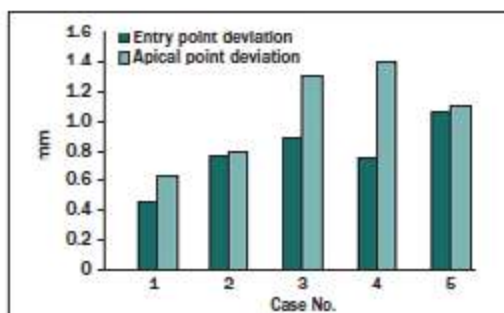
In a left first molar area of the maxilla, a short implant had to be placed avoiding the maxillary sinus in which a thickening of the membrane appeared. Following the standard procedure for a vertical ultrasonic implant site preparation, the tip depth was checked in real-time, on the navigation system display, allowing the surgeon to keep the sinus floor intact (Fig 5). This method could be considered suitable in similar cases in which there is the need of a highly sensitive implant site preparation, due to close anatomical structures.

After socket preparation, the implants (three, Southern Implants and two, BioSafin) were positioned with a contra-angle handpiece at 40 rpm with 40-Ncm maximum torque. The depth of the Implant insertion could also be tracked on the software against the final virtually planned implant position.

### Accuracy Evaluation

For all patients, a postoperative CBCT scan was taken within 3 months after the implant surgery, according to the research protocol approved by the S. Ursola-Malpighi Hospital Ethical Committee, University of Bologna, Italy.

The accuracy of the procedure was evaluated by comparing the software-based surgical plan with postoperative information. The inserted implants were segmented from the tomographic scan using the OpenMAF platform,<sup>11,12</sup> and the volumes from the preoperative and postoperative models were aligned using a three-point registration module within the ImplNav software



**Fig 7** Results of the displacement vector module for entry and apical points for the five clinical cases.

(Fig 6). At this point, the deviation of each planned implant with respect to the segmented postoperative implant profiles was evaluated in two ways. First, the authors used a dedicated function within Geomagic Studio 12.0 (Geomagic), which computes all point-to-point distances and, from them, calculates a mean deviation quantity. The other method was identifying the Euclidean distance between the 3D coordinates of the entry position and the apical point for each pair of implants.

Analysis of the point-to-point distances for the five implant insertions in the five patients showed a mean deviation of  $0.87 \pm 0.04$  mm. The results, summarized in Fig 7, also showed a mean deviation of  $0.78 \pm 0.20$  mm for the insertion point and  $1.04 \pm 0.29$  mm for the apical point.

### DISCUSSION

No studies are reported, at the moment, about the combined use of a navigation system and ultrasonic instruments.

Although few significant clinical studies on navigated implant surgery have been reported to date, the performance of the ImplNav system<sup>13</sup> seems to be similar to that of the Treon navigation system (Medtronic) and the VISIT navigation system (University of Vienna) for navigated implant insertion.<sup>14,15</sup>

The application of the piezo-navigation technology<sup>16</sup> seems to facilitate the use of a smaller-diameter insert for the lateral and vertical preparation of an implant socket, possibly leading to more abundant and



deeper irrigation of the osteotomy area. Implant site preparation using a navigated piezosurgery approach may be key to improving the primary stability of the implant. In fact, the ability to access lower trabecular regions of the bone would strengthen deeper implant anchorage while keeping the pressure acting on the upper implant-cortical bone interface low (and where, generally, reabsorption phenomena related to implant buccal-lingual inclination occur<sup>17</sup>). If tracked in real-time over the tomographic scan, the surgeon can selectively prepare deeper regions of the cortical walls, such as the mandibular lingual wall or the oblique walls of the maxillary sinus floor, while damage to the surrounding soft and neurovascular tissues is reduced markedly using the Piezosurgery system.<sup>9,18</sup>

As described in this study, when navigation is combined with ultrasonic drilling and, in particular, a 3D differential preparation, the number of inserts used for socketing can be reduced readily. Indeed, if specifically designed, it is likely that one insert could be used for the entire piezosurgery procedure. Moreover, the possibility of horizontal movement during a lateral preparation allows more control over the socket's geometry in the case of narrow bone crests, according to the morphology of the vestibulo-lingual walls. Additionally, being able to use an insert that is considerably smaller than the socket in both lateral and vertical movements allows more generous irrigation of the socket itself, up to its floor. With the advantages related to the use of an image-guided surgery system that is specialized for oral implantology, it is reasonable to conclude that navigation allows deeper preparation of an implant site, performed according to preoperative virtual surgery planning.

Unlike the use of surgical drill guides, and because of the live feedback from the tracking procedure, the diameter and orientation of the socket can be changed dynamically during the surgery—with respect to the virtual planning—if, for example, poor bone quality or pathologic or anatomical anomalies become evident.

Because this technique can be used with standard drill tips, it becomes more useful for posterior areas, where limited mouth opening may limit access for the extended drill tips, achieved by socketing through drill guides. Finally, because the surgical planning and the live tracking are performed within the same software, the surgeon can decide to modify the optimal position for the implant(s) at any time or even use a free-navigation module that allows inspection of the morphology and density of the surgical site below the tracked surgical instrument.

As a result, the surgeon could perform implant surgery more safely and with the reduced invasiveness that a flapless technique can offer. Clinical studies are underway to further evaluate the efficacy of this procedure.

## ACKNOWLEDGMENTS

The authors thank DresMedical Pty Ltd (Sydney, Australia) for providing the surgical navigation system, Mectron Srl (Carasco, Italy) for supplying the piezoelectric surgery equipment, Southern Implants (Irene, South Africa) and BioSAF IN (Ancona, Italy) for their provision of the dental implants used, and Castlereagh Imaging (Westmead, Australia) and Dental Radiology Division, University of Bologna, Italy for assisting with tomographic scanning facilities. The authors reported no conflicts of interest related to this study.

## REFERENCES

- Vercellotti T, Stacchi C, Russo C, et al. Ultrasonic implant site preparation using piezosurgery: A multicenter case series study analyzing 3,579 implants with a 1- to 3-year follow-up. *Int J Periodontics Restorative Dent* 2014;34:11–18.
- Stacchi C, Vercellotti T, Torelli L, Furlan F, Di Lenarda R. Changes in implant stability using different site preparation techniques: twist drills versus piezosurgery. A single-blinded, randomized, controlled clinical trial. *Clin Implant Dent Relat Res* 2013;15:188–197.
- Preti G, Martinasso G, Pelrone B, et al. Cytokines and growth factors involved in the osseointegration of oral titanium implants positioned using piezoelectric bone surgery versus a drill technique: A pilot study in minipigs. *J Periodontol* 2007;78:716–722.
- Jo KH, Yoon KH, Park KS, et al. Thermally induced bone necrosis during implant surgery: 3 case reports. *J Korean Assoc Oral Maxillofac Surg* 2011;37:406–414.
- Tehehar SH. Factors affecting heat generation during implant site preparation: A review of biologic observations and future considerations. *Int J Oral Maxillofac Implants* 1999;14:127–136.
- Scarano A, Iezzi G, Perrotti V, et al. Ultrasonic versus drills implant site preparation: A histologic analysis in bovine ribs. *J Craniofac Surg* 2014;25:814–817.
- Vercellotti T. *Essentials in Piezosurgery: Clinical Advantages in Dentistry*. Milan: Quintessence, 2009:97.
- Canullo L, Peñarocha D, Peñarocha M, Rocio AG, Peñarocha Diago M. Piezoelectric vs. conventional drilling in implant site preparation: Pilot controlled randomized clinical trial with crossover design. *Clin Oral Implants Res* 2014;25:1336–1343.
- Schaeren S, Jaquéry C, Heberer M, Tolnay M, Vercellotti T, Martin L. Assessment of nerve damage using a novel ultrasonic device for bone cutting. *J Oral Maxillofac Surg* 2008;66:593–596.
- Bertossi U, Lucchese A, Albanese M, et al. Piezosurgery versus conventional osteotomy in orthognathic surgery: A paradigm shift in treatment. *J Craniofac Surg* 2013;24:1763–1766.
- Taddai F, Ansaloni M, Teeti D, Viceconti M. Virtual palpation of skeletal landmarks with multimodal display interfaces. *Med Inform Internet Med* 2007;32:191–198.
- Lattanzi R, Viceconti M, Zannoni C, Quadroni P, Toni A. Hip-Op: An innovative software to plan total hip replacement surgery. *Med Inform Internet Med* 2002;27:71–83.
- Pollegirino G, Taraschi V, Marchetti C. A new navigation system for dental implantology. *Clin Oral Implants Res* 2014;25(suppl):s297.
- Wittwer G, Adeyemo WL, Schicho K, Glogovic N, Turhani D, Enslin G. Computer-guided flapless transmucosal implant placement in the mandible—A new combination of two innovative techniques. *Oral Surg Oral Med Oral Pathol Oral Radiol Endod* 2006;101:718–723.
- Wagner A, Wanschitz F, Birkfellner W, et al. Computer-aided placement of endosseous oral implants in patients after ablative tumour surgery: Assessment of accuracy. *Clin Oral Implants Res* 2003;14:340–348.
- Pollegirino G, Taraschi V, Milana P, Marchetti C. 3D Piezo-navigated implant site preparation. *Clin Oral Implants Res* 2015;26(suppl):236.
- Ramaglia L, Tuti P, Sbordone C, Guidetti F, Marzucelli R, Sbordone L. Implant angulation: 2-year retrospective analysis on the influence of dental implant angle insertion on marginal bone resorption in maxillary and mandibular osseous onlay grafts. *Clin Oral Investig* 2015;19:769–779.
- Perreira CC, Gealli WC, Meurini-Nogueira L, Garcia-Júnior BR, Okamoto R. Piezosurgery applied to implant dentistry: Clinical and biological aspects. *J Oral Implantol* 2014;40(suppl):s401–s408.

## Immediate fixed rehabilitation supported by axial and tilted implants of edentulous jaws: a prospective longitudinal study in HIV-positive patients

▶ **GIORGIO GASTALDI<sup>1</sup>, RAFFELE VINCI<sup>2</sup>, MARIA CHIARA FRANCIA<sup>3</sup>, FRANCESCO BOVA<sup>4</sup>, PAOLO CAPPARÉ<sup>5</sup>**

<sup>1</sup> MD, DMD, Associate Professor, Dental School, Vita-Salute San Raffaele University, Milan, Italy and Unit of Oral and Maxillofacial Surgery, San Rocco Clinical Institute, Ome, Brescia, Italy

<sup>2</sup> Associate Professor, Dental School, Vita-Salute University, Milan, Italy and Department of Dentistry, IRCCS San Raffaele Hospital, Milan, Italy

<sup>3</sup> Fellow DDS, Dental School, Vita-Salute San Raffaele University, Milan, Italy

<sup>4</sup> DH, Adjunct Professor, Bachelor's Degree in Dental Hygiene, Vita-Salute San Raffaele University, Milan, Italy  
Department of Dentistry, IRCCS San Raffaele Hospital, Milan, Italy

<sup>5</sup> Researcher, Dental School, Vita-Salute University, Milan, Italy and Department of Dentistry, IRCCS San Raffaele Hospital, Milan, Italy

### TO CITE THIS ARTICLE

Gastaldi G, Vinci R, Francia MC, Bova F, Capparé P. Immediate fixed rehabilitation supported by axial and tilted implants of edentulous jaws: a prospective longitudinal study in HIV-positive patients. *J Osseointegr* 2017;9(2):239-44.

DOI 10.23806/JO.2017.09.02.01

**KEYWORDS** Dental implant, HIV Seropositivity; Implant prosthetic rehabilitations; Tilted implants.

### ABSTRACT

**Aim** The purpose of this study is to evaluate the success of implant prosthetic rehabilitation "All on four" in HIV positive patients.

**Materials and Methods** HIV-positive patients under a strict medical control with edentulous mandible and/or maxilla, were enrolled for the present study. The "all on four" protocol was applied with immediate fixed rehabilitations. Marginal bone loss, implant and prosthetic failure, biological and mechanical complications, serological levels (CD4 cell count, CD4/CD8 ratio and HIV-RNA) were recorded at 6, 12 and 24-month follow-up.

**Results** A total of 108 implant were placed in 21 patients, and 27 rehabilitations were delivered. Five implants were lost (survival rate = 95.37%). At the 24-months radiographic evaluation, perimplant crestal bone loss averaged  $0.98 \pm 0.21$  mm for upright maxillary implants ( $n = 30$  implants) and  $0.87 \pm 0.18$  mm for tilted maxillary implants ( $n = 30$  implants). In the mandible, a mean peri-implant crestal bone loss of  $0.88 \pm 0.32$  mm for upright implants ( $n = 24$ ) and  $0.91 \pm 0.30$  mm for tilted implants ( $n = 24$ ) was found. No statistically significant difference in the marginal bone loss between tilted and axially placed implants, and between jaws at 6, 12 and 24-month follow-up evaluation ( $P > 0.05$ ). Moreover, not statistically significant linear correlations were found between serological levels and marginal bone loss.

**Conclusions** Within its limitations, the present study reported that the "all on four" protocol can be a suitable treatment option in immunocompromised but immunologically stable HIV positive patients.

### INTRODUCTION

HIV infection is a global pandemic, especially in developing countries, massively impacting on world public health. HIV is the virus responsible for a progressive immunodeficiency that weakens the body's defense against pathogens and can be detected by a decreasing CD4+ cell count, indicator of the state of the disease. HIV-positive patients tend to develop more easily opportunistic infections and other HIV-associated oral lesions such as oral candidiasis, hairy leukoplakia, HIV associated gingivitis and periodontitis, Kaposi Sarcoma, non Hodgkin lymphoma, xerostomia and destructive carious disease (1), mostly due to poor oral hygiene and potentially also to alterations in the salivary flow. Atypical periodontal necrotic ulcerations and an increased incidence of herpetic infections have also been documented (2). Recently, thanks to highly active antiretroviral therapies, the life expectancy of HIV-positive patients has increased, their systemic health has improved and implant-supported prosthesis has become a valid alternative to removable prostheses in restoring dental aesthetics and function.

In a prospective cohort study (3) conducted at the IRCCS San Raffaele Hospital, Milan, it has been reported that implant prosthetic rehabilitation in HIV positive patients, showing strict adherence to antiretroviral drug regimen and good oral hygiene, is a reasonable treatment option with results slightly worse compared



to the healthy population.

In order to improve the quality of life and to encourage also a social rehabilitation of those patients, the "All on four" treatment concept represents a predictable procedure for the rehabilitation of completely edentulous jaws, showing the advantages of both the immediate loading, which allows immediate function, and full arch fixed prosthetic restoration, with a higher degree of patient satisfaction compared to removable prostheses (4). Low incidence of complications and high long-term survival rates with excellent Marginal Bone Level (MBL) outcome have been reported for this protocol by Paulo Maló et al. (2014) (5).

Early loss of the natural dentition due to oral complications and poor oral hygiene, often leads to a severe atrophy of the alveolar ridge (6). As a consequence, to achieve implant stability and support when rehabilitating atrophic edentulous jaws, an extensive surgical bone augmentation procedure, such as bone grafts or maxillary sinus elevation, would be required, resulting in higher risk of patient morbidity and complications, higher costs, longer time intervals and poor patient acceptance (7, 8). As HIV positive patients seem to have higher risk for both early and late postoperative complications, such as septicemia and poor wound healing (9), they may benefit from a simpler and shorter treatment. Therefore a suitable option is the placement of four tilted implants – two most anterior placed axially and two posterior distally angled – according to "all on four" treatment protocol (10).

No significant differences in crestal bone loss and implant prosthetic failure rate have been found between tilted and axial implants (8, 11, 12). Tilted implants may achieve the same success rate as implants axially placed (13), showing both clinical and biological advantages, and cause no detrimental effect on the osseointegration process (14).

The purpose of this study is to evaluate the success of implant prosthetic rehabilitation "All on four" in HIV positive patients.

## MATERIALS AND METHODS

### Patient selection

This prospective longitudinal study was performed in the San Luigi Center for Infectious Diseases, IRCCS San Raffaele Hospital, Milan, Italy.

HIV-positive patients under a strict medical control and with severely resorbed mandible or maxilla, were enrolled from December 2013 to June 2014.

The main inclusion criteria were patients with either edentulous jaws or jaws with teeth with a poor long-term prognosis treatment planned for extraction.

The inclusion criteria were: age >18 years, total or partially edentulous in one or both jaws, adequate

bone volume (divisions A, B, or C according to Misch classification of bone available) (15) and appropriate bone density (classes D1, D2, or D3 Misch) (16).

Exclusion criteria were: severely immunocompromised patients with a high recurrence of opportunistic infections, tuberculosis, or malignancy, decompensated diabetes, severe malocclusion, severe parafunctions (bruxism), inadequate bone volume (Division D of Misch), inadequate bone density (density D4 Misch), disorders that contraindicate surgical procedures, lack of collaboration, lack of oral hygiene (plaque index higher than 1).

Diagnosis was made clinically and radiographically. All patients gave written informed consent, and underwent oral hygiene, conventional impression for study model for the fabrication of temporary prosthesis, panoramic radiographs and CT-scans before surgery.

### Surgical procedure

One hour before the surgery patients were administered 2 g amoxicillin + clavulanic acid (Augmentin, GlaxoSmithKline, Belgium), which they continued (1 g twice a day) for 1 week after surgery. Implant surgery was performed under local anaesthesia (optocaine 20 mg/ml with adrenaline 1:80000, Molteni Dental, Firenze, Italy).

In edentulous mandibles, incisions were made on top of the alveolar crest, from the first molar on one side to the first molar on the contralateral side with bilateral releasing incisions. Subperiosteal dissection on the lingual and vestibular surfaces was carried out and mental foramina were located. Soon before implant placement, all compromised teeth with a poor prognosis were atraumatically extracted, when present, and sockets were carefully debrided. The four implants and abutments were placed starting with the posterior ones. Bilaterally the most posterior implants were placed close to the anterior wall of the mental loop and were tilted distally about 25-30 degrees in relation to the occlusal plane. The lower corner of the implant neck was positioned at bone level.

Posterior implants were placed emerging at the second premolar position.

In edentulous maxillae, incisions were made on the alveolar crest from the first molar to the contralateral side with bilateral releasing incisions. Subperiosteal dissection was carried out. The most posterior implants were placed distally tilted approximately 25 to 30 degrees.

The diameter of the final drill was chosen based on the bone quality in order to optimize implant stability.

Implant placement was performed following the manufacturer's instructions (Tx system, Winsix, Biosafin, Ancona, Italy), except that under preparation was used to achieve an insertion torque at least 35 Nm before final seating of the implant. Underpreparation was performed in soft bone to obtain high primary



stability. The implant neck was aimed to be positioned at bone level and bicortical anchorage was established whenever possible. The posterior implants were 3.8 or 3.3 mm in diameter and 15 or 13 mm in length, and the anterior implants were either 3.8 or 3.3 mm in diameter and 11 or 13 mm in length (TTx system, Winsix, Biosafin, Ancona, Italy).

Angulated abutments (Extreme Abutment, EA® Winsix, Biosafin, Ancona, Italy) for anterior implants were set at either 17° and those for posterior implants at 30° to compensate for the lack of parallelism between implants as well as to place the prosthetic screw-access holes in an occlusal or lingual location.

Flap adaptation and suturing were performed in the usual manner with 4–0 nonresorbable suture (Vicryl; Ethicon, Johnson & Johnson, New Brunswick, NJ, USA). After surgery were prescribed as postoperative care for all participants, non-steroidal anti-inflammatory drugs (Brufen 600 mg, Abbott Laboratories, Chicago, IL, USA), and chlorhexidine digluconate 0.2% mouthwash during the first 2 weeks. All patients were instructed to avoid brushing and any trauma to the surgical site and were recommended to follow a soft diet (avoiding bread and meat) for 2 months.

#### Prosthetic protocol

Provisional full-arch all-acrylic prostheses were delivered on the day of surgery, thanks to former impression taking. Pickup impressions (Permadyne, ESPE, Seefeld, Germany) of the implants were made at the conclusion of the surgery, after suturing, to manufacture a high-density all-acrylic prosthesis with titanium cylinders. No later than 3 h after the surgery an acrylic provisional prosthesis was delivered.

Articulating paper (Bausch Articulating Paper, Nashua, NH, USA) was used to check the occlusion and adjust it, if necessary. Static occlusion consisted of central contacts established on all masticatory units. Dynamic occlusion included canine/premolar guidance during lateral movements, regardless of the opposite arch settings. Screw access holes were covered with provisional resin (Fermit, Ivoclar Vivadent, Naturno, Bolzano, Italy). Final prostheses were delivered 4 months postsurgery. They were made of acrylic resin masticatory surfaces, and metal frameworks for increased strength and rigidity.

#### Follow-up

Follow-up visits were performed at 3, 6, 12 and 24 months after implant insertion with radiographic assessments to evaluate the marginal bone loss and the overall bone level.

According to the Infectious Disease Unit, Serological parameters (CD4 cell count, CD4/CD8 ratio and HIV RNA viral load) were assessed every 6 months.

Each 6 months from implant placement, a dental hygienist performed oral hygiene procedures and clinical parameters regarding (15).

The surgical criteria used to evaluate the outcomes were the failure of the implant, absence of perimplantitis, absence of implant mobility, absence of mucosal suppuration and absence of pain at the time of examination. Restoration success was defined as the absence of fractures of the acrylic resin superstructure.

#### Radiographic examination

Intraoral digital radiographic assessments were made immediately after surgery and at each follow-up visit. Bone level measurements were performed on the mesial and distal aspect of each implant, using the implant-abutment junction as a reference point (15).

They were made perpendicular to the long axis of the implant with long cone parallel technique, using an occlusal custom template to measure the marginal bone level. A dedicated dentist measured the changes in crestal bone height over time. The difference in bone level was measured radiographically through specific software (DIGORA 2.5, Soredex, Tuusula, Finland). The software was calibrated for every single image using the known implant diameter at the most coronal portion of the neck of the implant. The linear distance between most coronal point of bone-to-implant contact and the coronal margin of the implant collar was measured to the nearest 0.01 mm, at both mesial and distal sides, and averaged. Bone level changes at single implants were averaged at patients level and then at group level.

#### Outcome measures

The outcomes were considered as follows: prosthesis failure, implants failure which led to implant removal (due to mobility, progressive marginal bone loss due to peri-implantitis, any mechanical complication rendering the implant not usable), biological and prosthetic complications (number and type were recorded as single episodes for each implant), peri-implant marginal bone level changes (MBLCs).

#### Statistical analysis

A dedicated software (SPSS 11.5.0, SPSS, Chicago, IL, USA) was used for all statistical analyses.

Data were analyzed at patient level and were reported and summarized as mean and standard deviations. For the outcome measures, the number of implant failures, prosthetic failures, peri-implantitis, occurrence of pus, pain, paresthesia, and fracture of fixtures were reported as absolute values and/or percentages in the whole sample (108 implants in 21 patients). In order to investigate the correlation between marginal bone levels and serological levels of CD4 cell count, CD4/CD8 ratio and HIV RNA at different time points (6, 12 and 24 months), a linear regression analysis was performed. The Pearson R coefficient was calculated and significance was set at  $p < .05$ . All results are provided as mean  $\pm$ SD. To compare marginal bone levels at 6, 12 and 24 months between axial and tilted implants in maxilla and

Gastaldi G. et al.

mandible, a Student t test was applied at a significance level of P = 0.05.

**RESULTS**

A total of 108 implants were placed in 21 patients (Table 1). Among them, 11 were smokers (52,3%). Six patients received rehabilitation of both jaws, 9 patients received a maxillary rehabilitation and 6 received a mandibular rehabilitation (Table 1). All prostheses were supported by four implants. In total, 27 rehabilitations were delivered (Table 1).

**Implant failure**

Implant failure was registered in two patients (5 fixtures out of 108). Both patients were not smokers. One had suffered the loss of all implants due to late perimplantitis occurred 1 year after implant placement. The other patient lost one tilted implant as a consequence of a primary infection, at 2 months from placement. The survival rate was 95.37% (96.30% for axial implants and 94.45% for tilted implants). Four implants out of 108 (3.70%) were lost for peri-implantitis in one patient and one implants out of 108 (0.93%) was lost for primary infection in another patient. No fixture fracture occurred.

**Biological and prosthetic complications**

biological and prosthetic complications were reported in Table 2. Peri-implantitis occurred in 4 implants in the same patient (3.70%), and resulted in the loss of the fixture and led to the removal of the implants (Table 2) and fixed prosthesis was lost (Table 2). Fracture of provisional prosthesis occurred in 2 patients (1 maxilla and 1 mandibular rehabilitations). No paresthesia and no prosthetic complications in definitive prostheses were registered in the whole sample.

**Peri-implant MBLs**

Marginal Bone Level (MBL) was followed up for 2 years (Table 3).

At the 24-month radiographic evaluation, peri-implant crestal bone loss averaged  $0.98 \pm 0.21$  mm for axial maxillary implants (n = 30 implants) and  $0.87 \pm 0.18$  mm for tilted maxillary implants (n = 30 implants). In the mandible, a mean peri-implant crestal bone loss of

		diameter	length		
			13 mm	15 mm	11 mm
Maxilla n=60	UPRIGHT n=30	3.3 mm	15	0	3
		3.8 mm	10	0	2
	TILTED n=30	3.3 mm	3	15	0
		3.8 mm	2	10	0
Maxilla n=48	UPRIGHT n=24	3.3 mm	11	0	2
		3.8 mm	7	0	4
	TILTED n=24	3.3 mm	2	11	0
		3.8 mm	4	7	0

TABLE 1 Implants dimensions and position

	Number	Rate
Implant failure	5	4.63%
Prosthetic failure	1	3.70%
Fixture fracture	0	0
Perimplantitis	4	3.70%
Provisional prosthesis fracture	2	7.41%
Episode of Pus	0	0
Pain	0	0
Paresthesia	0	0

TABLE 2 Implant failure, prosthetic failure, biological and mechanical complications.

$0.88 \pm 0.32$  mm for axial implants (n = 24) and  $0.91 \pm 0.30$  mm for tilted implants (n = 24) was found. No statistically significant difference in the marginal bone loss between tilted and axially placed implants, and between jaws at 6, 12 and 24-month follow-up evaluation (P>0.05) were recorded.

**Prosthetic failure**

One of the 27 fixed prostheses was lost during the observation period, representing a prosthetic survival rate of 96.3%. In definitive prostheses, no fractures of the acrylic resin superstructure occurred.

Bone loss	UPRIGHT		TILTED	
	maxilla n=30	mandible n=24	maxilla n=30	mandible n=24
6 months (mm)	$0.84 \pm 0.21$	$0.80 \pm 0.32$	$0.85 \pm 0.30$	$0.92 \pm 0.22$
12 months (mm)	$0.92 \pm 0.36$	$0.85 \pm 0.36$	$0.88 \pm 0.23$	$0.94 \pm 0.33$
24 months (mm)	$0.98 \pm 0.21$	$0.88 \pm 0.32$	$0.87 \pm 0.18$	$0.91 \pm 0.30$

TABLE 3 Marginal bone loss at 6, 12 and 24 months from implant placement.

	CD4 cell count	CD4/CD8 ratio	HIV RNA
6 months (mm)	536.33 ± 327.34	0.88 ± 0.37	3.28 ± 9.52
12 months (mm)	508.50 ± 288.03	1.05 ± 0.68	14.62 ± 22.06
24 months (mm)	531.17 ± 253.17	0.88 ± 0.76	19.21 ± 16.73

TABLE 4 Serological levels at different time points (6, 12 and 24 months).

### Serological parameters

Serological parameters are reported in Table 4.

A not statistically significant linear correlation was found between:

- CD4 cell count and marginal bone levels at 6, 12 and 24 months ( $R=0.11$ , explained variance  $R^2=0.01$ );
- CD4/CD8 ratio and marginal bone levels at 6, 12 and 24 months ( $R=0.21$ , explained variance  $R^2=0.04$ );
- HIV RNA and marginal bone levels at 6, 12 and 24 months ( $R=0.13$ , explained variance  $R^2=0.02$ ).

All linear correlations were not significant ( $p>0.05$ ).

### DISCUSSION

The aim of this study is to investigate the survival rate of implants in "All on four" rehabilitations, performed on controlled HIV-positive patients with good oral hygiene. The recent switch of HIV infection from terminal to chronic disease has allowed HIV-positive patients to benefit from implant prosthetic rehabilitations, as their general health conditions and longevity improved. This explains why the current literature on this topic is considerably scarce and long-term clinical data are still lacking.

In 1998, Rajnay and colleagues (16) attempted the placement of one endosseous implant in a HIV-positive patient under strict medical control, obtaining good aesthetic and functional results after an observation period of 18 months. These findings have been supported by Strietzel et al. (17) who placed 10 implants in three HIV-positive patients with CD4+ cell counts  $>250/\mu\text{L}$  and viral load below the lower detectable limit. Their outcomes corroborate the hypothesis that implant-prosthetic rehabilitation of immunocompromised but immunologically stable patients can be a predictable treatment option.

In a prospective non-randomized clinical trial involving HIV-positive and negative patients requiring implant-supported mandibular overdenture, Stevenson et al. (18) reported osseointegration of all the implants, despite the high number of smokers included.

More recently Gherlone and colleagues (3) in a clinical trial, beside a cumulative implant survival rate of 92,11%, have showed a relatively high incidence of peri-implant infections in HIV-positive patients, occurred in the first 6 months after implant placement and probably due to individual susceptibility and immunological status. Therefore a strict protocol of infection control is needed when dealing with HIV-positive patients and the close

collaboration with the Infectious Disease Department is essential for successful treatment outcomes, since the immune status and blood clotting parameters play a crucial role in patient selection.

Whether HIV-infected patients are more predisposed to experience postoperative complications from dental treatment is controversial. In a case report, Baron et al. (9) documented osseointegration in all implants placed in a HIV-positive patient: no signs of inflammation and uneventful healing of both the soft and the hard tissues were observed, supporting the hypothesis that minor surgery does not represent an increased risk for a controlled HIV-infected population. Same outcomes have been reported by Achong et al. (19) in a report on 3 cases. The authors assess also as the low CD4+ count levels at the time of implant insertion do not correlate with the outcome of the implants.

Other authors investigated the role of CD4+ cell count and its relation with implants survival.

Oliviera et al. (20) in a pilot study, including 25 HIV-positive and 15 HIV-negative volunteers, showed high success rates without clinical complications for all implants placed in the study participants, and no statistically significant relationship between bone resorption and CD4+ cell count, viral load and type of ART.

In a recent study Gherlone et al. (21) evaluated the associations between implant survival and patient-related aspects such as smoking habits, oral hygiene, CD4+ level in patients with HIV infection. No significant associations were found between the considered variables, except for heavy smokers ( $>10$  cigarettes/day) who showed to experience implant failures, perimplantitis, episodes of pus and pain more frequently compared with nonsmokers and light smokers ( $\leq 10$  cigarettes/day).

Long-term success rates for implant prosthetic rehabilitations in HIV-positive patients have been reported by two studies (27, 28). Gay-Escoda and colleagues (27) registered implant survival and success rates of 98,3% and 68,4% respectively after 5 to 9 years of follow-up. Similarly, any evidence of an increased risk of implant failure after up to 10 years was found by Rania et al. (28), showing no significant difference in success rates between HIV-positive and HIV-negative patients.

According to the mentioned literature and the results obtained in the present study, successful implant survival rates in HIV-infected patients seem to be more related to proper patient selection, appropriate surgical

technique, meticulous follow up and strict antimicrobial protocol, rather than values of specific markers for HIV-positive individuals such as CD4+ cell count or viral load. Kolhatkar et al. (23) documented the successful placement of immediate implants into fresh extraction sockets in two HIV-positive individuals. The immediate placement reduces the total treatment time and allows to preserve the alveolar bone level from the collapse of healing events (24).

Immediate loading protocol was achieved in order to obtain immediate function, improving aesthetic outcomes and patient satisfaction.

There are very few reports that show the clinical evidence of immediately loaded implants placed in HIV-infected patients. One of those (25) (Romanos et al.) presents a fixed implant-supported immediate loading protocol in an edentulous asymptomatic HIV-positive patient, documenting the validity of this type of oral rehabilitation also in immunocompromised patients.

## CONCLUSIONS

To our knowledge, the present study represents the only report on "All on four" implant prosthetic rehabilitation in HIV-positive population. Within its limitations, it shows as this protocol can be a suitable treatment option in immunocompromised but immunologically stable patients.

However in the literature there is a lack of further long-term data and additional studies are needed.

## REFERENCES

- Patton L, Glick M. Clinician's guide to treatment of HIV-infected patients. 3rd ed. Baltimore, MD: American Academy of Oral Medicine, 2001.
- Melnick S, Engel D, Truelove E. Oral mucosal lesions: Association with the presence of antibodies to the human immunodeficiency virus. *Oral Surg Oral Med Oral Pathol* 1989;68:37-43.
- Gherlone E, Cappare P, Tecco S, et al. Implant prosthetic rehabilitation in controlled HIV-positive patients: a prospective longitudinal study with one-year follow-up. *Clin Implant Dent Relat Res* 2015; 7:doi: 10.1111/cid.12353.
- Att W, Stappert C. Implant therapy to improve quality of life. *Quintessence Int* 2003; 34:573-581.
- Maló P, de Araújo Nobre M, Lopes A, Ferro A, Gravito I. All-on-4 treatment concept for the rehabilitation of the completely edentulous mandible: A 7-year clinical and 5-year radiographic retrospective case series with risk assessment for implant failure and marginal bone level. *Clin Implant Dent Relat Res* 2014. Doi: 10.1111/cid.12068.
- Patzelt S, Bahat O, Reynolds M, Strub J. The all-on-four treatment concept: a systematic review. *Clin Implant Dent Relat Res* 2014; 16:836-855.
- Del Fabbro M, Testori T, Francetti L, Weinstein R. Systematic review of survival rates for implants placed in the grafted maxillary sinus. *Int J Periodontics Restorative Dent* 2004; 24:565-577.
- Crespi R, Vinci R, Cappare P, Romanos GE, Gherlone E. A clinical study of edentulous patients rehabilitated according to the "all on four" immediate function protocol. *Int J Oral Maxillofac Implants* 2012; 27:428-434.
- Baron M, Gritsch F, Hansy AM, Haas R. Implants in an HIV-positive patient: a case report. *Int J Oral Maxillofac Implants* 2004;19:425-430.
- Maló P, Rangert B, Nobre M. "All-on-Four" immediate function concept with Brånemark system implants for completely edentulous mandibles: a retrospective clinical study. *Clin Implant Dent Res* 2003; 5(suppl 1):2-9.
- Menini M, Signori A, Tealdo T, Bevilacqua M, Pera F, Ravera G, Pera P. Tilted implants in the immediate loading rehabilitation of the maxilla: a systematic review. *J Dent Res* 2012; 91:821-827.
- Agliardi E, Clerico M, Villa C, Maló P. Immediate rehabilitation of the edentulous jaws with full fixed prostheses supported by four implants: interim results of a single cohort prospective study. *Clin Oral Implants Res* 2010; 21:459-465.
- Del Fabbro M, Bellini CM, Romeo D, Francetti L. Tilted implants for the rehabilitation of edentulous jaws: a systematic review. *Clin Implant Dent Relat Res* 2012; 14:612-621.
- Krekmanov L, Kahn M, Rangert B, Lindstrom H. Tilting of posterior mandibular and maxillary implants of improbe prosthesis support. *Int J Oral Maxillofac Implants* 2000;15:405-414.
- Crespi R, Cappare P, Gherlone E. Immediate loading of dental implants placed in periodontally infected and non-infected sites: a 4-year follow-up clinical study. *J Periodontol*. 2010 Aug;81(8):1140-6.
- Rajnay ZW, Hochstetter RL. Immediate placement of an endosseous root-form implant in an HIV-positive patient: Report of a case. *J Periodontol* 1998;69:1167-1171.
- Strietzel FP, Rothe S, Reichart PA, Schmidt-Westhausen AM. Implant-prosthetic treatment in HIV-infected patients receiving highly active antiretroviral therapy: Report of cases. *Int J Oral Maxillofac Implants* 2006;21:951-956.
- Stevenson GC, Riano PC, Moretti AJ, Nichols CM, Engelmeier RL, Flaitz CM. Short-term success of osseointegrated dental implants in HIV-positive individuals: A prospective study. *J Contemp Dent Pract* 2007;8:1-10.
- Oliviera MA, Gallottini M, Pallos D, Maluf PS, Jablonka F, Ortega KL. The success of endosseous implants in human immunodeficiency virus-positive patients receiving antiretroviral therapy: a pilot study. *J Am Dent Assoc* 2011; 142:1010-1016.
- Achong RM, Shetty K, Arribas A, Block MS. Implants in HIV-positive patients: 3 case reports. *J Oral Maxillofac Surg* 2006; 64:1199-1203.
- Gherlone E, Cappare P, Tecco S, et al. A prospective longitudinal study on implant prosthetic rehabilitation in controlled HIV-positive patients with 1-year follow-up: the role of CD4+ level, smoking habits and oral hygiene. *Clin Implant Dent Relat Res* 2015; doi:10.1111/cid.12370.
- U.S. Department of Health and Human Services. *AIDS.gov: HIV and smoking* [last revised 2013 Jul 5; accessed 2014 Apr 17].
- Kolhatkar S, Khalid S, Rolecki A, Bhola M, Winkler JR. Immediate dental implant placement in HIV-positive patients receiving highly active antiretroviral therapy: a report of two cases and a review of the literature of implants placed in HIV-positive individuals. *J Periodontol* 2011; 82:505-511.
- Becker W, Goldstein M. Immediate implant placement: Treatment planning and surgical steps for successful outcome. *Periodontol* 2000 2008;47:79-89.
- Romanos GE, Goldin E, Marotta L, Froum S, Tarnow DP. Immediate loading with fixed implant-supported restorations in an edentulous patient with an HIV infection: a case report. *Implant Dent* 2014 ;23:8-12.
- Patton L. Current strategies for prevention of oral manifestations of human immunodeficiency virus. *Oral Surg Oral Med Oral Pathol Oral Radiol* 2016;121:29-38.
- Gay-Escoda C, Pérez-Alvarez D, Camps-Font O, Figueiredo R. Long-term outcomes of oral rehabilitation with dental implants in HIV-positive patients: A retrospective case series. *Med Oral Patol Oral Cir Bucal*. 2016 May 1;21(3):e385-91.
- Rania V, Pellegrino P, Donati G, Ghezzi M, Clementi E, Sparaco A. Long-term Efficacy of Dental Implants in HIV-Positive Patients. *Clin Infect Dis*. 2015;61(7):1208.



Angelo Cardarelli, Filippo Cardarelli, Michele Grechi, Raffaele Vinci, Enrico F. Gherlone

## Alternative terapeutiche al grande rialzo di seno mascellare: impianti tiltati

**Scopo:** nei pazienti parzialmente o totalmente edentuli, il mascellare può presentare gravi limitazioni per la realizzazione del trattamento implantare convenzionale. Il riassorbimento delle ossa mascellari e la pneumatizzazione del seno riducono in molti casi la quantità di osso disponibile sia in spessore che in altezza, inoltre nel mascellare posteriore la qualità dell'osso è meno densa, più midollare e più sottile rispetto alla premaxilla. Scopo di questo lavoro pertanto è presentare una tecnica alternativa alle normali procedure di rialzo del seno mascellare, valutandone la predicibilità, la minore invasività e la possibilità di eseguire il carico immediato, in pazienti che presentano controindicazioni alle procedure classiche di rialzo. **Materiali e metodi:** nei tre casi clinici descritti la pneumatizzazione dei seni mascellari ha ridotto notevolmente l'altezza ossea in posizione dei primi molari, tale da non permettere l'inserimento degli impianti se non con una terapia rigenerativa. L'anamnesi positiva per una patologia sinusite cronica e un'abitudine viziata di forti fumatori ha escluso l'intervento di elevazione della membrana sinusale, pertanto angolando gli impianti distali si è riusciti ad ottenere una riabilitazione protesica fissa, senza cantiliver, ed in due casi su tre si è potuto realizzare anche una provvisionalizzazione immediata, aumentando il comfort dei pazienti. **Risultati e conclusioni:** al follow-up di un anno l'aspetto clinico e radiologico dei tessuti molli e duri risulta ottimale e non sono stati registrati segni patologici. Tale tecnica chirurgica, per la riabilitazione di siti edentuli mascellari, rappresenta una valida e predicibile alternativa terapeutica alle tecniche di sollevamento della membrana sinusale.

**PAROLE CHIAVE:** Atrofia, Seno mascellare, Carico immediato, Impianti angolati.

### INTRODUZIONE

Nelle riabilitazioni implanto-protesiche del mascellare atrofico esistono delle alternative alla chirurgia di elevazione del seno mascellare che devono essere prese in considerazione qualora siano presenti controindicazioni assolute (pazienti ad alto rischio, classe 4 ASA, displasie e neoplasie del seno, uso di stupefacenti, patologie sinusali acute in atto) o

controindicazioni relative (ipertrofia della mucosa sinusale, fumo, controindicazioni relative di carattere generale comuni alla chirurgia orale). In Letteratura sono descritte varie alternative terapeutiche al rialzo sinusale, come gli impianti di dimensioni ridotte, impianti pre e postsinusal, impianti protesizzati con un cantilever distale e infine impianti con inclinazione mesio-distale. Nel seguente articolo viene illustrato a scopo esemplificativo l'utilizzo degli impianti inclinati

per la riabilitazione dei mascellari atrofici di pazienti non candidati alla chirurgia di grande rialzo del seno mascellare.<sup>1-4</sup>

### MATERIALI E METODI

Nei casi descritti la pneumatizzazione dei seni mascellari ha ridotto notevolmente l'altezza ossea in posizione dei primi molari, tale da non permettere l'inserimento degli impianti se non con una te-

#### | Angelo Cardarelli

DDS, Specialista in Chirurgia Odontostomatologica, Professore a Contratto e Consulente Scientifico, Unità di Chirurgia Orale Reparto di Odontoiatria, Università Vita Salute, IRCCS Ospedale San Raffaele, Milano

#### | Filippo Cardarelli

DDS, Specialista in Ortogantodonzia, Libero professionista, Isernia

#### | Michele Grechi

Professore a contratto e Consulente Scientifico Unità di Chirurgia Orale Reparto di Odontoiatria, Università Vita Salute, IRCCS Ospedale San Raffaele, Milano

#### | Raffaele Vinci

MD, DMD, MS, Professore Associato, Unità di Chirurgia Orale, Reparto di Odontoiatria, Università Vita Salute, IRCCS Ospedale San Raffaele, Milano

#### | Enrico F. Gherlone

MD, DMD, PhD, Professore Ordinario e Direttore, Reparto di Odontoiatria, Università Vita Salute, IRCCS Ospedale San Raffaele, Milano

#### Corrispondenza:

Angelo Cardarelli  
Ospedale San Raffaele Dental Clinic  
Via Olgettina, 48 - Milano  
angelo\_cardarelli@libero.it

Cardarelli A | Cardarelli F | Grechi M | Vinci R | Gherlone E F

rapia rigenerativa. L'anamnesi positiva per una sinusite cronica e un'abitudine viziata di forti fumatori ha escluso l'intervento di elevazione della membrana sinusale.

L'alternativa chirurgica adottata prevede il posizionamento di impianti inclinati mesiali alla parete anteriore del seno con emergenza protesica in corrispondenza del primo molare per permettere una riabilitazione senza cantilever distali.<sup>5</sup>

### Procedure chirurgiche e protesiche

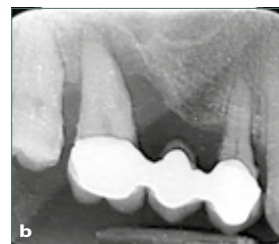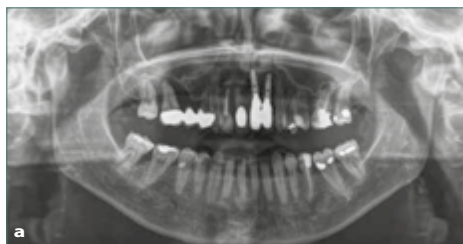#### Caso clinico 1

Alla paziente è stata somministrata una profilassi antibiotica di 2 g di amoxicillina e acido clavulanico 1 ora prima della seduta operatoria.

Previa infiltrazione plessica di soluzione anestetica contenente articaina 1:100.000 del primo quadrante si procede all'avulsione degli elementi di ponte 1.4-1.6, (Figg. 1-3) si esegue un'incisione crestale con svincolo verticale di rilascio distale per ottenere un lembo a tutto spessore esteso per visualizzare la proiezione del seno mascellare sulla superficie ossea vestibolare (Fig. 4). In sede post-estrattiva di 1.6 si evidenzia una severa perdita ossea in senso verticale con continuità dell'alveolo con la membrana sinusale. L'osteotomia distale ha un andamento tangenziale alla parete anteriore del seno mascellare: questa inclinazione permette di ottenere un'emergenza della piattaforma implantare a livello del primo molare. Verificata

la correttezza delle preparazioni implantari si procede all'inserimento degli impianti TTX Biosafin Winsix in sede 1.4 (3,8 x 13) e in sede 1.5 tiltato (3,8 x 13). Sull'impianto in sede 1.4 viene avvitato un EA dritto, su quello in sede 1.5 (tiltato) viene avvitato un EA da 30°, quindi vengono inseriti i monconi provvisori, ribasato il provvisorio precedentemente confezionato e si esegue una protesizzazione immediata (Figg. 5-10). Il lembo viene suturato con punti staccati in seta 4/0.

Dopo 4 mesi dalla fase chirurgica, stabilizzati i tessuti e avvenuta l'osteointegrazione vengono prese le impronte e si procede al confezionamento di un ponte definitivo in metallo - ceramica avvitato (Figg. 11-15).



Figg. 1a,b RX preoperatoria.

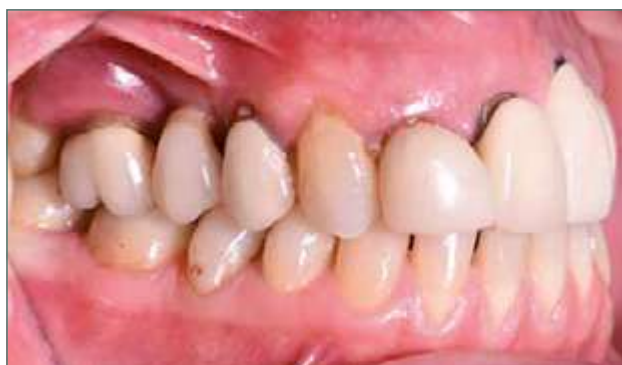
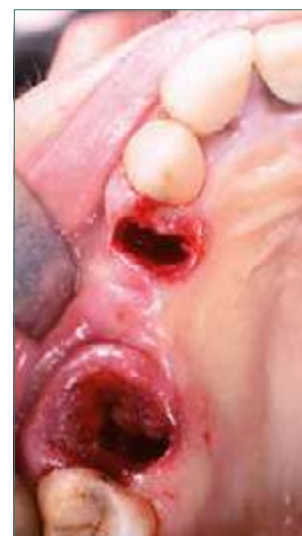
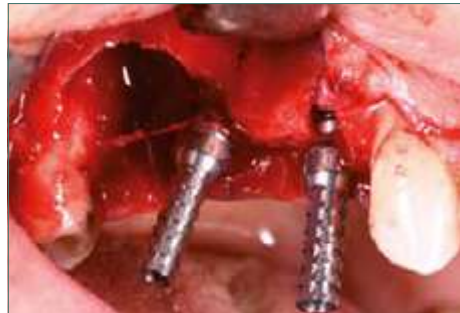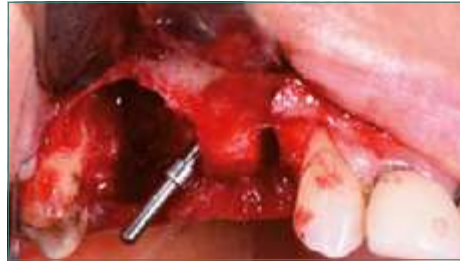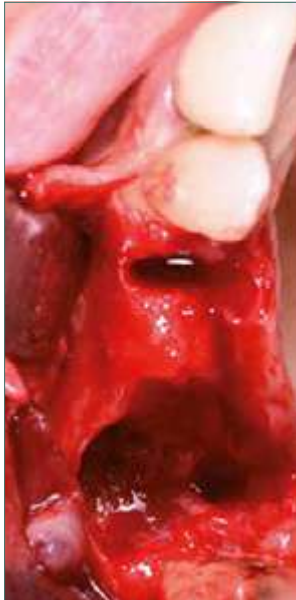Fig. 2 Situazione clinica iniziale.

Fig. 3 Avulsione degli elementi dentari 1.4-1.6.



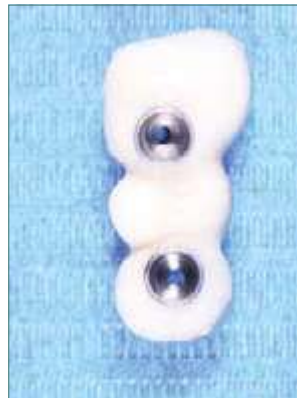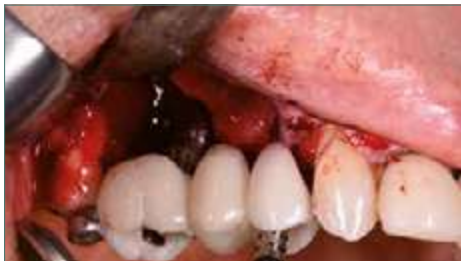Cardarelli A | Cardarelli F | Grechi M | Vinci R | Gherlone E F



**Fig. 4** Scheletrizzazione ossea.

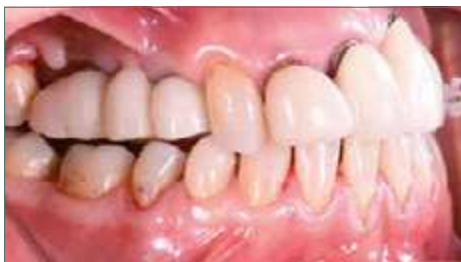**Fig. 5** Preparazione sedi implantari, impianto tiltato in sede 1,5.

**Fig. 6** Impianti inseriti e Monconi provvisori.



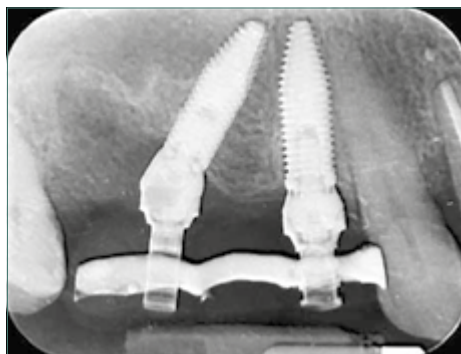
**Fig. 7** Ribasatura provvisoria.

**Fig. 8** Provvvisorio ribasato.



**Fig. 9** Provvvisorializzazione immediata.

**Fig. 10** RX post-operatoria.



Cardarelli A | Cardarelli F | Grechi M | Vinci R | Gherlone E F

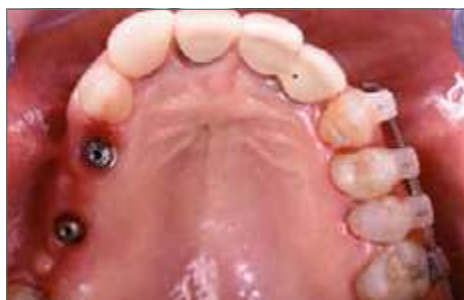

Fig. 11 Guarigione a 4 mesi.

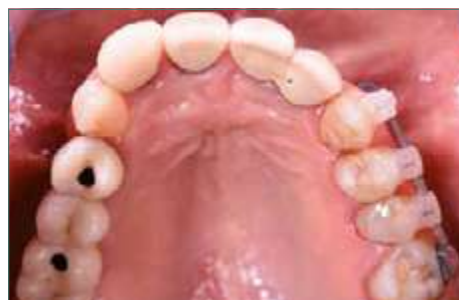

Fig. 12 Protesi definitiva avvitata, visione oclusale.

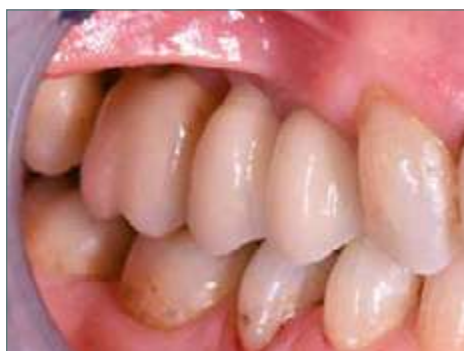

Fig. 13 Protesi definitiva -visione laterale.

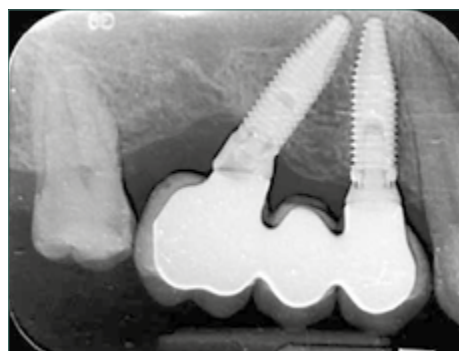


Fig. 14 Controllo radiografico a 12 mesi.

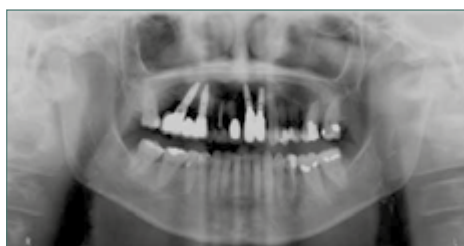


Fig. 15 Ortopanoramica a 12 mesi.

### Caso clinico 2

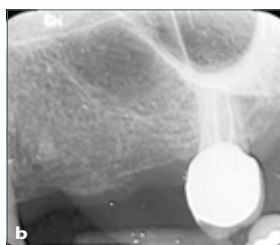
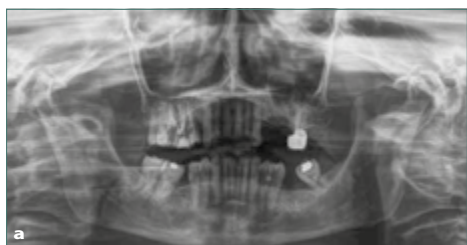Al paziente è stata somministrata una profilassi antibiotica di 2 g di amoxicillina e acido clavulanico 1 ora prima della seduta operatoria. Previa infiltrazione plessica di soluzione anestetica contenente articaina 1:100.000 del secondo quadrante si procede all'avulsione dell'elemento 2.6, parodontalmente compromesso, si esegue un'incisione cre-stale con svincolo verticale di rilascio distale per ottenere un lembo a tut-

to spessore esteso per visualizzare la proiezione del seno mascellare sulla superficie ossea vestibolare. La presenza di una patologia sinusita cronica, evidenziata dall'esame con TC cone beam, esclude la possibilità di eseguire un grande rialzo di seno. Si procede quindi alla preparazione delle sedi implantari ed all'inserimento degli impianti TTX Biosasin Winsix in sede 2.4 (3,8 x 13) e 2.5 (3,8 x 15) (tiltato). Sull'impianto in sede 2.4 viene avvitato un EA dritto, su

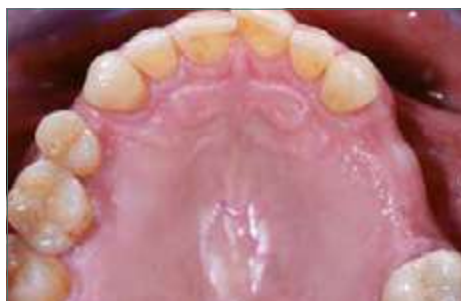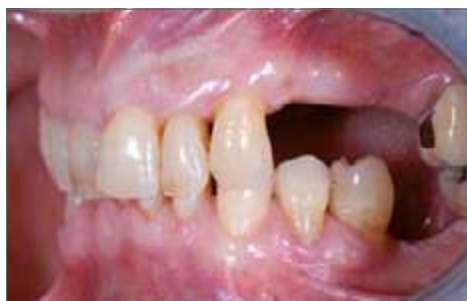quello in sede 2.5 (tiltato) viene avvitato un EA da 30° e realizzata una protesizzazione immediata ribasando il provvisorio precedentemente confezionato (Figg. 16-23). Il lembo viene suturato con punti staccati in seta 4/0. Dopo 4 mesi dalla fase chirurgica, stabilizzati i tessuti e avvenuta l'osteointegrazione vengono prese le impronte e si procede al confezionamento di un ponte definitivo in metallo-ceramica avvitato (Figg. 24-25).



Cardarelli A | Cardarelli F | Grechi M | Vinci R | Gherlone E F

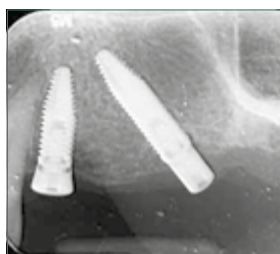
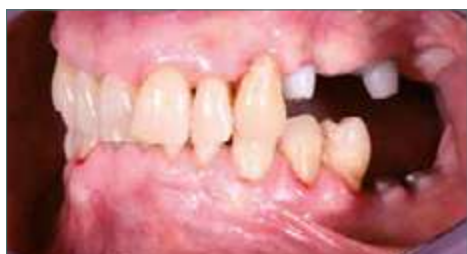
**Fig. 16a,b** RX preoperatoria.



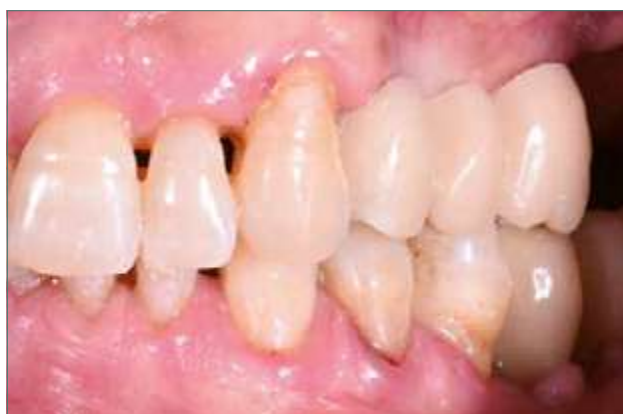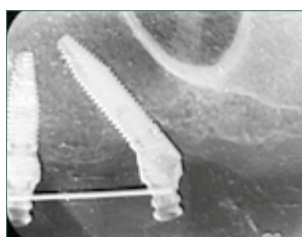
**Fig. 17** Situazione clinica iniziale visione laterale.

**Fig. 18** Situazione clinica iniziale visione occlusale.



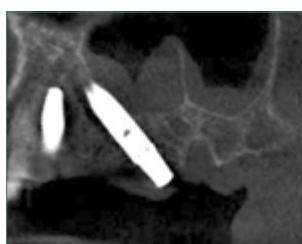
**Fig. 19** Impianti inseriti.

**Fig. 20** Rx post operatoria.



**Fig. 21** Rx post-operatoria con provvisorio immediato.

**Fig. 22** TAC cone beam post-operatoria.



**Fig. 23** Provvisorio.



Cardarelli A | Cardarelli F | Grechi M | Vinci R | Gherlone E F

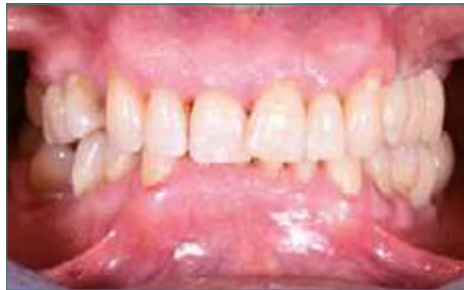

Fig. 24 Finalizzazione protesica.

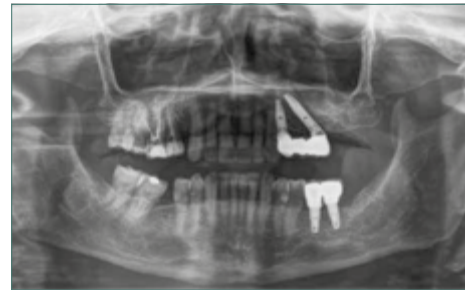

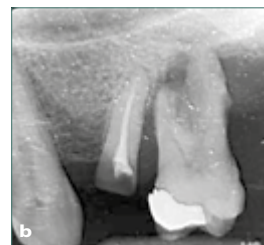
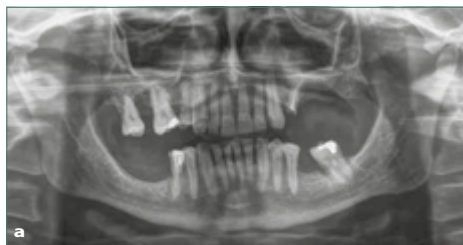Fig. 25 Controllo radiografico a 12 mesi.

**Caso clinico 3**

Al paziente è stata somministrata una profilassi antibiotica di 2 g di amoxicillina e acido clavulanico 1 ora prima della seduta operatoria. Previa infiltrazione plessica di soluzione anestetica contenente articaína 1:100.000 del secondo quadrante si procede all'avulsione degli elementi 2.5 e 2.6, quest'ultimo con grave perdita ossea verticale ed in

continuità con la membrana sinusale. Si procede pertanto all'inserimento di un impianto Biosafin Winsix 3,8 x 13 TTI tiltato in sede 2.5 tangenziale alla parete anteriore del seno mascellare ed un impianto in sede 2.4 (3,8 x 11 TTI). Il lembo viene suturato con punti staccati in seta 4/0 (Figg. 26-30). Dopo 4 mesi dalla fase chirurgica, stabilizzati i tessuti e avvenuta l'osteointegra-

zione si procede alla seconda fase chirurgica e riapertura degli impianti, vengono avvitati gli EA, da 30° in sede 2.5 e da 17° in sede 2.4, quindi vengono prese le impronte e si procede al confezionamento prima di un provvisorio e successivamente stabilizzati i tessuti molli al confezionamento di un ponte definitivo in metallo-ceramica avvitato da 2.4 a 2.6 (Figg. 31-35).

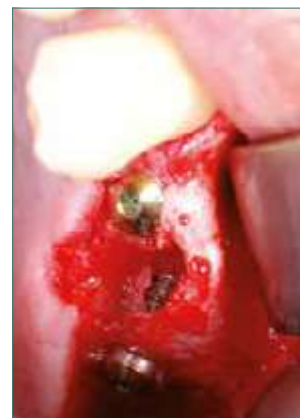
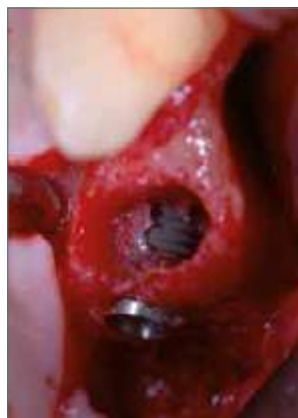
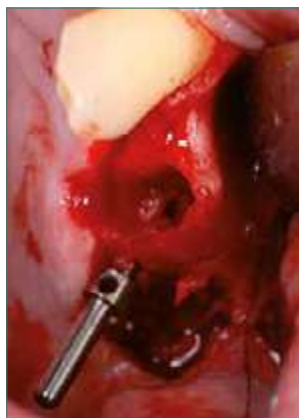Figg. 26a,b RX preoperatoria.

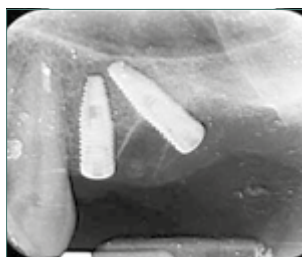Fig. 27 Avulsione degli elementi dentari ed inserimento impianti.

Fig. 28 Impianto tiltato in sede 1.5 tangenziale alla parete anteriore del seno mascellare visione oclusale.

Fig. 29 Impianti inseriti.

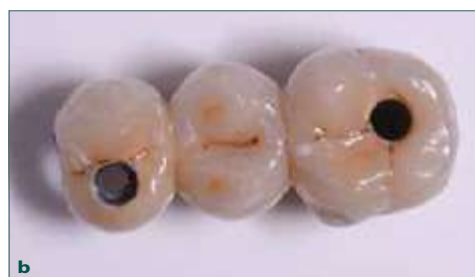
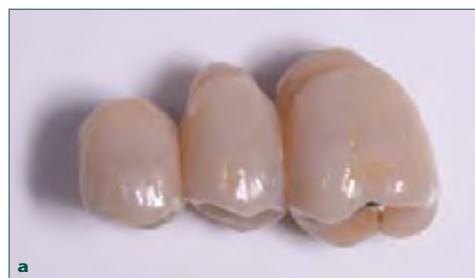
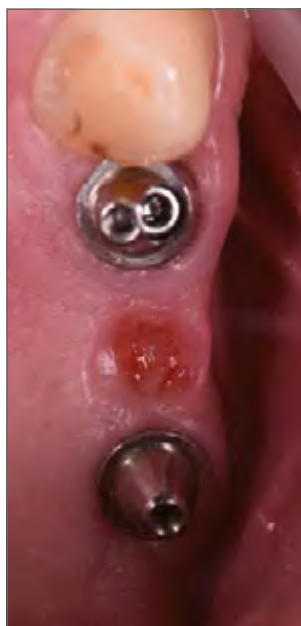Cardarelli A | Cardarelli F | Grechi M | Vinci R | Gherlone E F

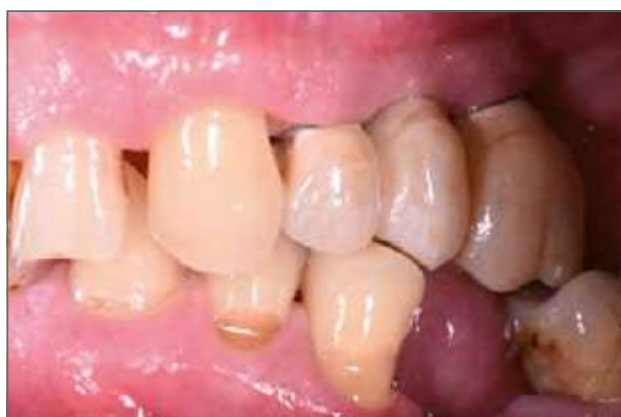
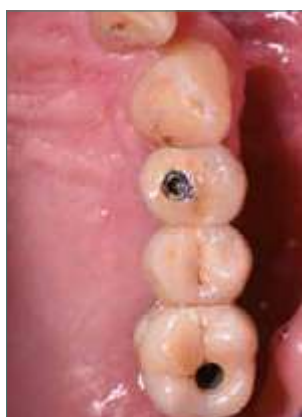
**Fig. 30** Rx postoperatoria.

**Fig. 31** Guarigione a 6 mesi con provvisorio.



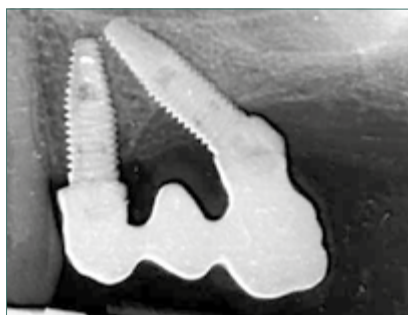
**Figg. 32a,b** Protesi definitiva.



**Fig. 33** Protesi definitiva avvitata visione oclusale.

**Fig. 34** Protesi definitiva visione laterale.

**Fig. 35** Controllo radiografico a 12 mesi.



## DISCUSSIONE

L'aspetto biomeccanico su cui si basa l'impiego di impianti angolati è la riduzione del cantilever e quindi una distribuzione migliore ed omogenea dei carichi a livello protesico, migliorando l'ancoraggio corticale, a livello della parete anteriore del seno e della fossa nasale, a vantaggio di una maggiore stabilità primaria e consentendo di usare impianti più lunghi. L'apice di questi impianti ed il fulcro di rotazione sono localizzati nella regione canina e la piattaforma implantare emerge in corrispondenza del secondo premolare o addirittura in corrispondenza del primo molare. Numerosi studi hanno riportato un elevato tasso di sopravvivenza, altri hanno valutato la quantità di stress a livello del tessuto osseo perimplantare<sup>6,7</sup>; da tali studi è emerso che il singolo impianto angolato sottoposto a carichi assiali presenta un maggiore stress osseo periimplantare rispetto al singolo impianto assiale; tuttavia quando l'impianto angolato viene solidarizzato ad altri impianti con un cantilever ridotto presenta uno stress meccanico minore a livello perimplantare rispetto ad impianti assiali solidarizzati ma con un cantilever maggiore. Tale tecnica quindi si è rivelata predicibile e facile da applicare anche per operatori meno esperti in tecniche rigenerative più o meno avanzate come il grande rialzo di seno mascellare; tale tecnica, è stata descritta per la prima volta nel 1974 e da allora è considerata predicibile, ma non priva di

complicanze quali: sinusiti acute, perforazione della membrana di Schneider, deiscenza della ferita e dispersione del materiale da innesto all'interno della cavità sinusale. Traducendo questi dati nella pratica clinica quotidiana possiamo affermare che l'utilizzo di impianti angolati ci consente con una minore invasività chirurgica, sfruttando l'osso basale residuo del paziente, la possibilità di ridurre i tempi delle riabilitazioni, permettendo di eseguire una protesizzazione immediata, con una maggiore compliance da parte del paziente.

## CONCLUSIONI

Questa procedura, sebbene rappresenti un'alternativa a tecniche più invasive, richiede una selezione e pianificazione del caso molto accurata associata a:

- conoscenza dell'anatomia sinusale, onde evitare il posizionamento dell'impianto distal nel seno mascellare con conseguente rischio di aumento di complicanze postoperatorie;
- componentistica chirurgica e protesica adeguata alla tecnica utilizzata;
- attenta valutazione dei carichi occlusali masticatori.

I vantaggi risultano essere oltre che la ridotta invasività rispetto al grande rialzo di seno anche la possibilità di poter eseguire una protesizzazione immediata offrendo al paziente il vantaggio di poter avere denti fissi subito aumentando il comfort e la compliance.

## BIBLIOGRAFIA

1. Schiegnitz E, Kämmerer PW, Sagheb K, Wendt AJ, Pabst A, Al-Nawas B, Klein MO3. Impact of maxillary sinus augmentation on oral health-related quality of life. *Int J Implant Dent.* 2017 Dec;3(1):10.
2. Zaniol T, Zaniol A. A Rational Approach to Sinus Augmentation: The Low Window Sinus Lift. *Case Rep Dent.* 2017;2017:7610607.
3. Timmenga NM, Raghoobar GM, van Weissenbruch R, Vissink A. Maxillary sinus floor elevation surgery. A clinical, radiographic and endoscopic evaluation. *Clin Oral Implants Res.* 2003 Jun;14(3):322-8.
4. Timmenga NM, Raghoobar GM, Boering G, van Weissenbruch R. Maxillary sinus function after sinus lifts for the insertion of dental implants. *J Oral Maxillofac Surg.* 1997 Sep;55(9):936-9;discussion 940.
5. Küçük Kurt S, Alpaslan G, Kurt A. Biomechanical comparison of sinus floor elevation and alternative treatment methods for dental implant placement. *Comput Methods Biomech Biomed Engin.* 2017 Feb;20(3):284-293.
6. Andreasi Bassi M, Andrisani C, Lopez MA, Gaudio RM, Lombardo L, Lauritano D. Maxillary sinus by-pass with tilted implants via tapered-screw bone expanders in low density bone: one year follow-up of a case series. *J Biol Regul Homeost Agents.* 2016 Apr-Jun;30(2 Suppl 1):13-20.
7. Chrcanovic BR, de Carvalho Machado V, Gjelvold B. Immediate implant placement in the posterior mandible: A cone beam computed tomography study. *Quintessence Int.* 2016;47(6):505-14.

Cardarelli A | Cardarelli F | Grechi M | Vinci R | Gherlone E F

Angelo Cardarelli, Filippo Cardarelli, Michele Grechi, Raffaele Vinci, Enrico F. Gherlone

## Therapeutic alternatives to maxillary sinus: tilted implants

**Aim:** In partially or totally edentulous patients, maxillary can have severe limitations for conventional implant treatment. Resorption of jaw bones and breast pneumothorax reduce in many cases the amount of bone available both in thickness and height, and in the lower jaw bone quality is less dense, more bone marrow and thinner than the forehead. The purpose of this work is therefore to present an alternative technique to normal maxillary sinus lifting procedures, assessing predictability, reduced invasiveness, and the possibility of immediate loading, in patients who have contraindications to maxillary sinus. **Material and Methods:** In the three clinical cases described, maxillary sinus pneumonitis has considerably reduced the bone height in the position of the first molars, so as not to allow the insertion of the implants except for regenerative therapy. Positive history for a chronic sinusitis pathology and a the defective habit of strong smokers excluded the sinus membrane elevation, so angled prosthetic rehabilitation, without cantiliver, was achieved by unplugging the distal systems, and in two out of three cases it was possible to achieve immediate loading, increasing the comfort of the patients themselves. **Results and Conclusions:** At one year's follow-up, the clinical and radiological appearance of soft and hard tissues is optimal and no pathological signs have been reported. This surgical technique for the rehabilitation of edentulous jaw sites is a valid and predictable therapeutic alternative to sinus lifting techniques.

**KEY WORDS:** Atrophy, Maxillary sinus, Immediate loading, Tilted implants.

## Evaluation of Ultrashort and Longer Implants with Microrough Surfaces: Results of a 24- to 36-Month Prospective Study

Luciano Malchiodi, MD, DDS<sup>1</sup>/Riccardo Caricasulo, MSc, DDS<sup>2</sup>/Alessandro Cucchi, PhD, MSc, DDS<sup>3</sup>/  
Raffaele Vinci, MD, DDS<sup>4</sup>/Enrico Agliardi, MD, DDS<sup>4</sup>/Enrico Gherlone, MD, DMD<sup>5</sup>

**Purpose:** The aim of this prospective study was to establish if ultrashort implants are a reliable therapeutic solution by evaluating their effect on mean crestal bone loss and assessing their survival and success rates.

**Materials and Methods:** Patients were treated using 6-, 9-, and 11-mm-long implants with sandblasted and acid-etched surfaces and fitted with fixed partial prostheses. Clinical and radiographic examinations were scheduled yearly. Data collected included the implant positioning site, implant length and diameter, peri-implant bone loss (PBL), and clinical and anatomical C/I ratios. **Results:** One hundred eleven implants (6-mm-long, 30.6%) were positioned; two implants were lost before loading. During the 36-month follow-up, no other implants were lost (98.2% survival rate, 100% from loading), but four implants did not meet the criteria for success, due to excessive crestal bone loss, resulting in a 94.6% success rate, 96.3% from loading. Success rates and peri-implant bone loss were not significantly different among implants with different lengths. No correlation was observed between implant length and bone resorption. **Conclusion:** Six-millimeter-long implants did not show different results in comparison with 9- and 11-mm-long implants. They can be considered a reliable solution for implant prosthetic rehabilitation and a dependable and minimally invasive therapeutic option in areas showing severe bone resorption. INT J ORAL MAXILLOFAC IMPLANTS 2017;32:171–179. doi: 10.11607/jomi.4648

**Keywords:** crown-implant ratio, implant length, implant success rate, prospective study, ultrashort implants

Osseointegrated dental implants can achieve high long-term success rates.<sup>1</sup> However, a common problem that hinders restoration of edentulous sites with implant-supported prostheses is bone resorption, which may be more pronounced if the patient has been wearing a removable prosthesis. A study that involved more than 400 skulls demonstrated that 62% of the posterior partially edentulous maxillae and 50% of the partially edentulous mandibles had insufficient bone height to receive implants shorter than 6 mm.<sup>2</sup>

As moderately rough-surfaced short implants have become available, investigators have found that they may be useful, as they show lower failure rates than machine-turned surface implants of < 10 mm length.<sup>3,4</sup> A recent definition of “short implant” is that of Renouard and Nisand,<sup>5</sup> who defined a short implant as one with an intrabony length of  $\leq 8$  mm.<sup>5</sup> Moderately rough-surface threaded implants offer the advantage of increased bone-to-implant surface contact; coupled with a slightly modified surgical technique, the likelihood of success with short implant lengths is increased.<sup>6,7</sup>

Inevitably, the use of shorter implants results in increased crown-to-implant ratios (C/I). Originally, appropriate suggested C/I for dental implants was considered—as with natural teeth—to be in the 1:1 range.<sup>8,9</sup> More recently, however, a number of investigators have demonstrated that it is possible to use implants with a C/I ratio of 2:1 or greater without compromising long-term implant survival/success, provided that certain threshold values are respected.<sup>10–12</sup>

The present study compares the performance of moderately rough-surfaced, ultrashort (ie, 6-mm-long) implants with longer, standard ones (9 or 11 mm).

<sup>1</sup>Professor, Department of Surgery, University of Verona, Verona, Italy.

<sup>2</sup>Graduate Student, Department of Surgery, University of Verona, Verona, Italy.

<sup>3</sup>Researcher, Department of Biomedical and Neuromotorial Science, University of Bologna, Bologna, Italy.

<sup>4</sup>Visiting Professor, Department of Dentistry, Vita Salute University, San Raffaele Hospital, Milan, Italy.

<sup>5</sup>Full Professor and Chairman, Department of Dentistry, Vita Salute University, San Raffaele Hospital, Milan, Italy.

**Correspondence to:** Riccardo Caricasulo, University of Verona, Verona, Italy. Email: riccardo.caricasulo@gmail.com

©2017 by Quintessence Publishing Co Inc.



Malchiodi et al

## MATERIALS AND METHODS

### Study Design

Patients enrolled in this prospective study were selected from among those who were referred to the authors seeking implant-prosthetic restoration according to the following criteria:

- Inclusion criteria: partial or total edentulism; bone height  $\geq 5$  mm in the maxilla and  $\geq 7$  mm in the mandible; bone width  $> 5$  mm; choosing to be rehabilitated by means of an implant-supported fixed prosthesis; accepting a treatment plan based on the use of short and/or ultrashort implants; and showing sufficient compliance to participate in the follow-up.
- Exclusion criteria: showing very poor oral hygiene; showing aggressive and/or untreated periodontal disease; smoking more than 20 cigarettes/day; abuse of alcohol or drugs; showing acute oral infections; ASA 4 or 5; having undergone remote or recent radiation therapy in the oral maxillofacial district; being subjected to recent chemotherapy; or pregnant.

All patients were consecutively treated with 6-, 9-, and/or 11-mm-long implants with sandblasted and acid-etched surfaces, and subsequently fitted with single crowns or implant-supported fixed prostheses. Implants were all inserted according to surgical and prosthetic protocols that had been preestablished at the beginning of the prospective study.

### Surgical Protocol

Each patient was evaluated clinically and radiographically to plan the appropriate treatment. Initial patient evaluation was performed on the basis of periapical and panoramic radiographs (Fig 1a), while cone beam computed tomography (CBCT) was requested in all cases of alveolar atrophy, ie, if the bone height was  $< 7$  mm in the maxilla or  $< 9$  mm in the mandible, to accurately evaluate residual bone volumes. A clinical examination was carried out to evaluate overall periodontal conditions, the amount of keratinized tissue at intended implant sites, the residual stability of the remaining dentition, and the status of oral hygiene. If a patient was diagnosed with either a generalized or localized chronic periodontal disease, he/she was subjected (before implant surgery) to a complete periodontal therapy cycle comprising a nonsurgical first phase, a surgical second phase, a restorative third phase, and a maintenance fourth phase.

Patients were administered 2 g amoxicillin 1 hour before surgery, which was continued with 2 g/day for another 6 days. Those who had an allergy to penicillin

were given azithromycin, 600 mg/day for 3 days, starting 1 hour before surgery.

Surgery was performed under local anesthesia (mepivacain with epinephrine 1:50,000 in the site of intervention and mepivacain with epinephrine 1:100,000 in other sites).

Implants used in this prospective study (WINSIX, BioSAFin. S.r.l.) had a semispherical apex and thread geometry that varied, widening from the apex to the neck. The 0.3-mm-long neck had a machine-turned surface, while the remainder of the designed intrabony implant length was sandblasted and acid-etched (microrough surface). Implants were purchased from the manufacturer. Implant lengths were 6, 9, or 11 mm. The 6-mm-long implants were wide-diameter (4.5 and 5.2 mm), while the longer implants were also used in diameters of 3.3 mm (narrow-diameter) or 3.8 mm (standard-diameter).

Implants were placed only in healed extraction sites, their length chosen according to the bone height available at the intended implantation site. After elevating full-thickness flaps, the implant site preparation was adapted to the local bone conditions.

In dense bone, sites were prepared using undersized burs, whose diameter was 0.6 mm narrower than the one of the neck of the implant being placed. In these cases, pretapping was performed to reduce bone compression.

In maxillae, where bone density was low or the sinus floor needed elevation of  $\leq 2$  mm, osteotomies were performed using primarily, although not exclusively, hand osteotomes. If sinus floor elevation of up to 2 mm was needed, implant sites were included and the floor elevated using indirect osteotome sinus elevation without added graft material as reported by Calvo-Guirado et al.<sup>13</sup>

When implants were placed in the posterior mandible, 0.5 to 1 mm was considered a safe distance from the mandibular neurovascular bundle. When necessary, implant site depth was monitored intraoperatively with periapical radiographs (Figs 1a to 1c).


All implants were left submerged for 5 months, irrespective of implant length or bone quality.

During the first 15 days, patients were instructed to observe a fluid diet, while for the next 15 days, patients were instructed to observe a soft diet and good oral hygiene. Chlorhexidine, 0.2% three times daily, was recommended until suture removal. Patients used no removable prostheses with mucosal support in the operation site.

### Prosthetic Protocol

At the time of stage-two surgery, an impression was made with polyether material using transfer copings and a customized tray. The impression was sent

**Fig 1** Measurement of (a) anatomical and (b) clinical C/I ratio.



directly to the dental laboratory to obtain the master model, which incorporated implant analogs.

The prosthetic protocol described by Cocchetto et al<sup>14</sup> was adopted for all of the cement-retained prostheses. The technique consisted of the duplication of the implant portion of a working cast prepared using double-pour or plastic base die systems for single or multiple crowns. For this purpose, a flask previously intended for the production of ceramic inlays and onlays was used. Duplication was obtained using a high-precision addition silicon material and a low-shrinkage polyurethane resin. The duplicated implant abutment was used to finalize the fixed partial denture restorations after the originals were delivered to the patients, thus reducing the time of the clinical sessions and avoiding repeated dis/reconnections.

Provisional prostheses were made in the laboratory and rebased directly in the mouth, using flowable acrylic resin. The occlusion was also checked to eliminate pre-contact and interference during centric and eccentric movements. After the patients had worn the provisional prostheses for 1 to 3 months, the definitive prostheses were prepared and delivered in a 1- to 2-week period. The latter were primarily cement-retained. To reduce the risk of occlusal overload, no cantilevers were created with ultrashort implants, as suggested by Misch et al.<sup>15</sup> For the same purpose, occlusal surfaces were reduced in the buccolingual direction, and the cusp height/inclination was kept to a minimum. Implants were splinted together when possible.

#### Follow-up and Data Collection

Patients were questioned orally and in writing regarding name, age, sex, dental history, smoking habits (number of cigarettes/day), and number of professional oral hygiene procedures in the last 3 years (number of hygiene procedures/year).

For each implant, the authors recorded the following parameters at the time of the surgery: implant length (6, 9, or 11 mm); implant diameter (3.3, 3.8, 4.5, or 5.2 mm); implant site (anterior, premolar, or molar); maxilla or mandible; and implant primary stability. After the

definitive restoration of the implants, the anatomical C/I ratio and clinical C/I ratio were radiographically assessed, as suggested by Blanes et al<sup>16</sup> (Fig 1).

Patients followed a maintenance program aimed to achieve optimal hard and soft tissue healing, which included professional oral hygiene every 6 months. Clinical evaluations were performed weekly during the first month after provisional restoration, and then monthly during the first 6 months after definitive restoration. Standardized intraoral radiographs, using an individual template, were obtained at the 1-, 2-, and 3-year follow-ups (Fig 2).

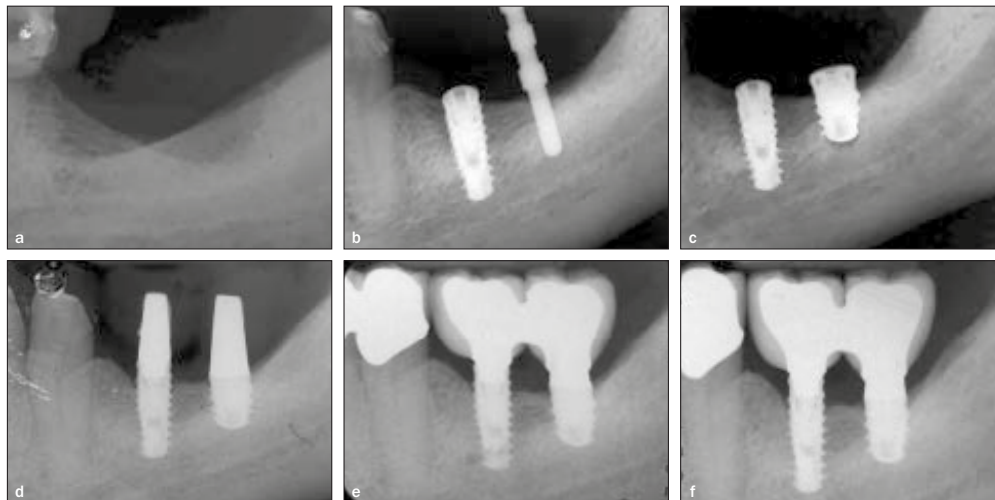
At the yearly control, implant survival and complications were evaluated. The soft tissue monitored parameters included bleeding scores (bleeding on probing [BoP]), pocket probing depth (PPD), and recession (REC) at all four surfaces of all implants (mesial, distal, buccal, and lingual/palatal).

PBL was measured at baseline and at the 12-month, 24-month, and 36-month follow-ups for each implant, considering the first contact point at the bone-implant interface.

Radiographs were scanned, digitized in JPG, converted to the TIFF format with a resolution of 600 dpi, and stored in a personal computer. Peri-implant marginal bone levels were measured using analysis software (ImageJ, National Institutes of Health), calibrated for every single image using the known implant diameter at the most coronal portion of the neck of the implant. The peri-implant bone levels were measured from the implant-abutment interface to the highest interproximal crestal bone level (CBL), to the nearest 0.01 mm, at both the mesial and distal sides, and then averaged.

Implant success was defined according to the criteria suggested by Buser et al<sup>17</sup> and modified according to Albrektsson and Zarb,<sup>18</sup> including: absence of persistent pain, dysesthesia, or paresthesia in the implant area; absence of peri-implant infection with/without suppuration; absence of perceptible implant mobility; and absence of persistent peri-implant bone resorption greater than 1.5 mm during the first year of loading and 0.2 mm per year during the following years.

Malchiodi et al



**Fig 2** Radiographs (a) before surgery, (b) with paralleling pin, (c) after surgery, (d) at baseline with provisional restoration, (e) at 1-year follow-up, and (f) at 3-year follow-up.

Overall success and survival rates were recorded at three different times:  $t_i$  = time of insertion;  $t_0$  = time of loading; and ctrl = maximum follow-up time.

### Statistical Analysis

All variables evaluated at different periods were included in the analyses.

The primary outcome variable was peri-implant bone-level changes, related to the implant length. Differences regarding radiographic bone-level changes at the various reexaminations and implant length were analyzed using the Student *t* test for paired observations. A Pearson correlation coefficient was calculated to test significant correlations among bone levels, implant diameter and length, clinical and anatomical C/I ratio, position of the implant, and kind of prosthesis. Simple linear regression models with a single explanatory variable were calculated to evaluate the relationship between the PBL and each other variable collected. Multivariate linear regression analysis was applied to test the combined influence of all variables together. The level of significance was set at  $\alpha = .05$ .

### RESULTS

One hundred eleven implants were placed in 43 subjects (ages: 41 to 79; 24 women and 19 men), who were followed for 24 to 36 months (mean follow-up of 31 months). Based on medical history, five patients were affected by diabetes and seven were smokers, four of whom smoked between 10 and 20 cigarettes/day.

Finally, 10 patients were treated for chronic periodontal disease.

Ultrashort implants were used in 30.6% ( $n = 34$ ) of the cases; implant distributions according to length, diameter, and site are reported in Tables 1 and 2.

There were no deviations from the study protocols, and no patients dropped out during the follow-up period. All patients regularly attended follow-up visits and maintained a good level of oral hygiene.

Two implants failed to integrate and were removed, so functional loading was applied on 109 implants. During the 36-month follow-up, no other implants were lost (98.2% survival rate, 100% from loading), but four implants did not meet the criteria for success, due to excessive crestal bone loss, resulting in a 94.6% success rate, 96.3% from loading; similar success rates were found among different groups of implants and between maxillae and mandibles (Tables 3 to 5; Fig 3).

Mean marginal bone loss during functional loading was  $0.56 \pm 0.69$  mm (median: 0.31 mm; range: 0.01 to 4.20 mm), considering all implants;  $0.44 \pm 0.72$  mm (median: 0.24 mm; range: 0.04 to 4.20 mm) for ultrashort implants,  $0.46 \pm 0.37$  mm (median: 0.33 mm; range: 0.05 to 2.53 mm) for 9-mm implants, and  $0.75 \pm 0.86$  mm (median: 0.54 mm; range: 0.01 to 3.86 mm) for 11-mm-long implants (Table 6). Most of the implants ( $n = 65$ ; 59.6%) showed PBL ranging from 0.1 to 0.5 mm (Fig 4). A comparison between CBL and PBL values of 6 mm and longer implants is shown in Fig 5.

The mean anatomical C/I ratio for 6-mm implants was  $2.26 \pm 0.52$  (median: 2.19 mm; range: 1.08 to 3.16), while the mean clinical C/I ratio at baseline was  $2.31 \pm$

**Table 1 Implant Distribution According to Length and Diameter**

Diameters	Lengths		
	6 mm	9 mm	11 mm
3.3 mm	0	10	12
3.8 mm	0	18	18
4.5 mm	23	9	10
5.2 mm	11	2	0
Total	34	39	38

**Table 3 Overall Success and Survival Rates in Relation to Length and Position**

	SR (from t <sub>i</sub> )	SR (from t <sub>0</sub> )	SSR (from t <sub>i</sub> )	SSR (from t <sub>0</sub> )
<b>Length</b>				
6 mm	94.1%	97.1%	97.0%	100%
9 mm	94.9%	97.4%	97.4%	100%
11 mm	94.7%	94.7%	100.0%	100%
<b>Position</b>				
Maxilla	93.9%	95.4%	98.5%	100%
Mandible	95.6%	97.7%	97.8%	100%
Total	94.6%	96.3%	98.2%	100%

SR = success rate; SSR = survival rate; t<sub>i</sub> = time of insertion; t<sub>0</sub> = time of loading.

**Table 2 Implant Sites According to Implant Lengths**

Lengths	Implant sites				
	Incisors	Canines	Premolars	Molars	Total
6 mm	0	0	9	25	34
9 mm	1	0	13	25	39
11 mm	8	4	15	11	38

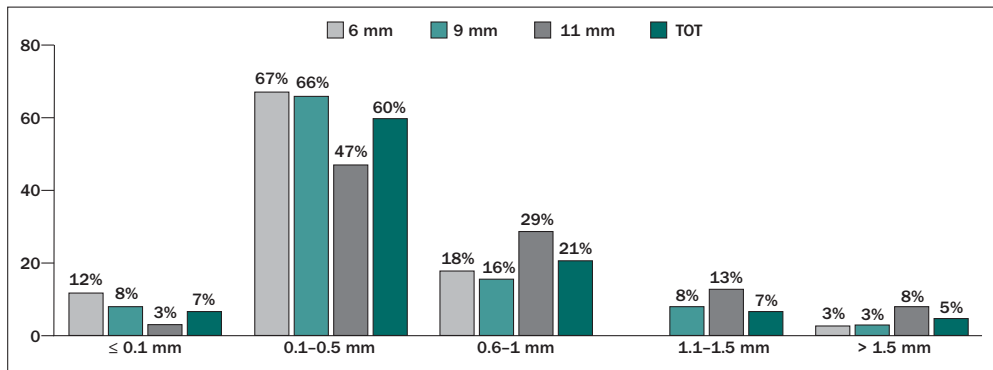
**Table 4 Cumulative Success Rates at the Follow-up Controls**

Follow-up (mo)	Implants in situ (no.)	Failed implants (no.)	Interval failure rate	Cumulative success rate
0-12	109	1	0.9%	99.1%
12, 1-24	109	1	0.9%	98.2%
24, 1-36	82	2	2.4%	95.8%

**Table 5 Failed Implants After Loading**

Implants	Dimensions (mm)	Site	Prosthesis	Clinic C/I ratio (baseline)
1	6 × 5.2	46	Single	2.25
2	9 × 3.3	14	FDP	1.05
3	11 × 3.3	24	FDP	1.83
4	11 × 3.3	23	FDP	1.62

FDP = fixed dental prosthesis.



**Fig 3** PBL distribution related to implant length.

0.49 (median: 2.25 mm; range: 1.31 to 3.16). As expected, both clinical and anatomical ratios were highly dependent on the implant length, the shorter implants having higher C/I ratios with shorter implants, as shown in Fig 6.

Concerning peri-implant soft tissues, the mean PPD at the last follow-up was 3.03 ± 1.17 mm (range: 2 to 8 mm), and the mean recession was 0.09 ± 0.36 mm (range: 0 to 4 mm). BoP was observed in 12.4% of sites, with 31.2% of implants having at least one bleeding site.

A total of 61 prosthetic devices were employed (12 single crowns and 49 multiple-element prostheses); 4.9% were screw-retained and 95.1% were cement-retained prostheses. At the time of follow-up, there were prosthetic complications in 3.3% of the implants. Additionally, a fracture of a connection screw in one implant supporting a partial prosthesis and the decementation of a fixed bridge were observed.

Malchiodi et al

Study group	PBL (mm) (median ± SD)	PBL (mm) (median, range)	Anatomical C/I ratio	Clinical C/I ratio (t <sub>0</sub> )
6 mm	0.44 ± 0.72	0.24 (0.04–4.20)	2.26 ± 0.52	2.31 ± 0.49
9 mm	0.46 ± 0.37	0.33 (0.05–2.53)	1.44 ± 0.35	1.49 ± 0.35
11 mm	0.75 ± 0.86	0.54 (0.01–3.86)	1.18 ± 0.29	1.21 ± 0.29

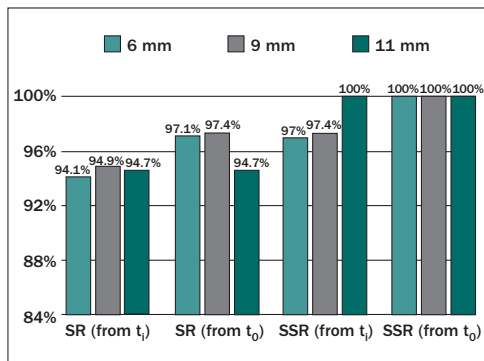


Fig 4 Overall success and survival rates in relation to length and position. SR = success rate; SSR = survival rate; t<sub>i</sub> = time of insertion; t<sub>0</sub> = time of loading.

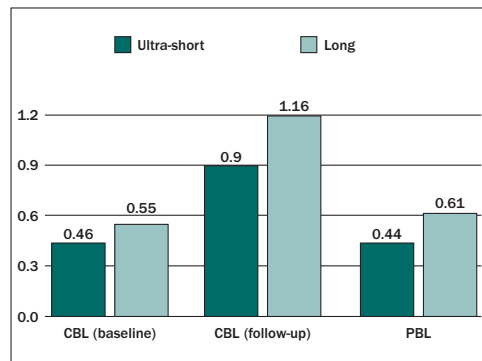


Fig 5 Mean CBL and PBL for 6-mm and longer implants.

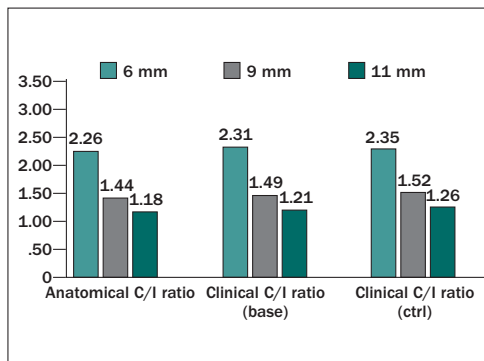


Fig 6 Anatomical and clinical C/I ratios.

Statistical analysis showed no correlation between elevated PBL and ultrashort implants; more specifically, no statistical differences were observed between the mean PBL values of the 6-mm and 9-mm ( $P = .888$ ) implant groups; differences between the mean PBL values of the 6-mm and 11-mm groups ( $P = .099$ ) and of the 9-mm and 11-mm-long groups ( $P = .063$ ) were slightly significant. No significant differences were observed when comparing implants with different diameters ( $P = .123$ ).

Higher C/I ratios for shorter implants did not seem to be relevant to determine higher PBL and to affect

success rates: no correlation was found between anatomical ( $P = .717$ ) or clinical C/I ratio and PBL ( $P = .722$ ), as can be seen in Figs 7 and 8.

## DISCUSSION

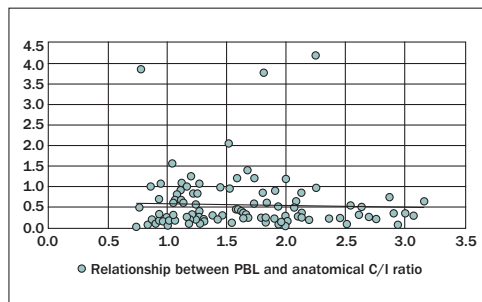
Studies published in the last 15 years appear to validate the use of short implants, ie, those having an intrabony length of  $\leq 8$  mm.<sup>5</sup> Srinivasan et al<sup>19</sup> have suggested that a better definition of what “short” means, when speaking about implant length, would be in the 6- to 7.5-mm range, while “ultrashort” implants could be those  $< 6$  mm in length.

The present prospective cohort study supports the use of 6-mm-long, wide-diameter, threaded implants with a moderately rough surface. After 2 to 3 years in function, only one of such implants was lost and only one other had to be considered as having failed on the basis of crestal bone loss.

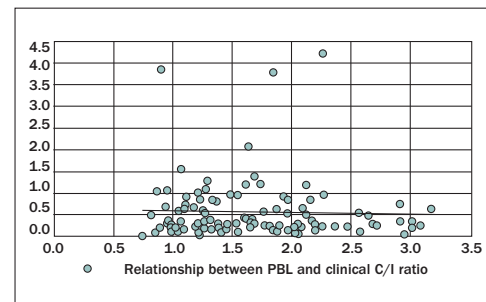
The results of this study are consistent with data from published studies on short implants with a mean follow-up longer than 2 years, which report survival and success rates ranging from 92% to 100% and from 80% to 100%, respectively, depending on the follow-up time considered<sup>20–37</sup> (Table 7).

In the present study, only two implants were lost and were reported as early failures. No implants were lost after functional loading, although four were





**Fig 7** Relationship between PBL and anatomical C/I ratio.



**Fig 8** Relationship between PBL and clinical C/I ratio.

regarded as failed on the basis of their crestal bone loss. These findings are consistent with previous investigations. A recent review<sup>28</sup> reported that late failures were observed in only one out of 12 studies on short implants. In the studies being reviewed, most implant failures (76%) were early, ie, before loading. A cohort prospective study by Rossi et al<sup>24</sup> reported a 95% survival rate for moderately rough-surface 6-mm-long implants, with either regular or wide diameters, that had been loaded 6 weeks after placement. Taken together, these findings suggest that implant surface roughness and surgical technique (eg, undersized osteotomies) may be more important than implant length. However, it should be pointed out that wide diameters may be important when using some short and ultrashort implant designs.

Some authors have reported higher failure rates for implants placed in maxillae compared with mandibles primarily because of differences in bone density in the two arches.<sup>31,33</sup> The present study detected small but statistically not significant differences for implant survival/success between the two arches (Table 3). Osteotomes were used to prepare many of the osteotomies in the maxillae, and the bone condensation associated with this method may have added to initial implant stability.

Failures did not seem to be related to diabetes or smoking status. Since evaluation of the relationship between medical history and peri-implant tissues was not the aim of the present paper, these results were based on heterogeneous data in a small cohort (10 periodontally compromised patients, 5 diabetic patients, and 7 smokers out of 43). Moreover, each patient had a personal professional maintenance protocol based on his or her medical conditions and local factors (ie, keratinized mucosa height and prostheses extension), which guaranteed good peri-implant tissue health even in patients at higher risk. Patients with a nonacceptable risk of failure were not enrolled in the study, according to inclusion/exclusion criteria.

In this study, implants with different lengths and diameters were placed both in posterior and anterior sites of the arches. Ultrashort implants were primarily used in posterior sites, while long and narrow implants, ie, 11.0 × 3.3-mm implants, were placed more often in anterior sites. This may represent an influencing bias factor of this study. As reported in Table 4, the failure rate corresponding to the 2- to 3-year interval increased significantly, due to the failure of two 11 × 3.3-mm implants (ie, not short ones). Implant success rates might be affected more by narrow diameters than by short implant lengths, yet results of the present study showed that the implant diameter was not significantly correlated with observed PBL, and narrower implants had PBL levels not significantly different from those with a regular diameter (4.5 mm). Implants that were 6 mm long with a 4.5-mm diameter had a mean bone loss of 0.35 ± 0.23 mm; the mean PBL for 9 × 4.5-mm implants was 0.50 ± 0.48 mm, and 0.65 ± 0.33 mm was recorded for 1-mm-long ones, with the three not being statistically different.

In the present study, the mean PBL for 6 mm-long, wide-diameter implants was 0.56 ± 0.69 mm. These results are consistent with those of other investigators. For example, Malchiodi et al<sup>12,27</sup> observed a mean PBL of 0.48 mm for a group of 259 implants, 5 and 7 mm long, with sintered porous surfaces, while the mean PBL observed by Rossi et al<sup>24</sup> for 6-mm-long SLActive Straumann implants was 0.43 mm. Pieri et al<sup>37</sup> reported a 0.60-mm mean PBL for implants with the same length after 2 years in function.

PBL means and ranges observed in the three groups under examination in the present study show that implants with different lengths behave similarly during functional loading. The highest values observed in the three groups were due to the four failed implants. Also, the mean PBL for 11-mm implants appears a bit higher (0.75 mm) than that of the other two groups (0.44 and 0.46 mm). This could be explained by the two late

Malchiodi et al

**Table 7 Literature Results on Short Implants**

Study	Length (mm)	Implant design and surface	Follow-up (y)	PBL (mm)	SR (from $t_i$ )	SR (from $t_0$ )	SSR (from $t_i$ )	SSR (from $t_0$ )
ten Bruggenkate et al <sup>22</sup> (1998)	6	Cylindric TPS	6	–	93.8%	–	97.0%	–
Renouard and Nisand <sup>29</sup> (2005)	6 to 8.5	Cylindric Machined/Oxidized	2–3	0.44 ± 0.52	–	–	94.6%	–
Arlin <sup>30</sup> (2006)	6	Various Various	2	–	–	–	94.3%	–
Deporter et al <sup>33</sup> (2008)	5	Cone-shaped Sintered-porous	1–8	–	92.3%	–	–	–
Rossi et al <sup>24</sup> (2010)	6	Cylindric SLActive	2	0.43 ± 0.49	–	–	95.0%	100.0%
Malchiodi et al (2014 and 2015) <sup>12,27</sup>	5 and 7	Cone-shaped Sintered-porous	3	0.48 ± 0.29	–	98.1%	–	98.8%
Esposito et al <sup>36</sup> (2014)	5 (maxilla) 5 (mandible)	Cylindric RBM	3 3	1.02 1.44	– –	– –	– –	– –
Present study	6	Cylindric Sand-blasted and acid-etched	2–3	0.44 ± 0.72	94.1%	97.0%	97.0%	100.0%

SR = success rate; SSR = survival rate;  $t_i$  = time of insertion;  $t_0$  = time of loading; RBM = resorbable blast media.

failures in this group, since the mean value calculated not considering these two implants was  $0.58 \pm 0.46$  mm.

When short or ultrashort implants are required, bone height is not the only limitation that may be present. Another significant parameter can be the ridge width, since a large diameter of short implants is usually chosen to provide implant stability. For this, the ridge width must certainly be  $> 1.5$  mm to allow short implant placement.<sup>38,39</sup> Crown-to-implant ratios also may be of some concern if they exceed recommended values. Many investigators have evaluated the relationship between C/I and PBL.<sup>12,17,40,41</sup> The current consensus appears to be that the use of implants with C/I ratios much larger than the 1:1 ratio is preferred for natural teeth. The data from the present study adds further support to this conclusion.

Few (3.3%) prosthetic complications were detected in the present study. They were possibly related to the extended period of function with provisional prostheses. The protocol followed also involved definitive abutment insertion, as also described by other authors.<sup>14</sup> This technique permits minimizing the stress at the bone-implant interface and decreasing micro-trauma to give higher stability both to hard<sup>42</sup> and soft tissues<sup>43</sup> The PPD ( $3.03 \pm 1.17$  mm) and BoP (12.4% of sites) values observed suggested that this also occurred in this study.

In this study, all implants were splinted together when possible, but no differences were observed between single crowns and multi-unit fixed dental prostheses (FDPs). This result is based on very

heterogeneous data (12 single crowns and 49 prostheses for multiple elements). The relationship between the prosthesis type and PBL when short and ultrashort implants are used should be investigated with specifically aimed studies, as current literature on the subject still provides different data; some authors recommend splinting shorter implants,<sup>22,44</sup> and others report good success rates even with single crowns.<sup>24,33</sup>

## CONCLUSIONS

This prospective cohort study revealed that moderately rough-surface, wide-diameter, 6-mm-long implants offer a predictable and minimally invasive treatment for rehabilitation of edentulous sites with advanced loss in alveolar ridge height. Clinical outcomes were not affected by C/I values, and these implants suffered no greater crestal bone loss than 9-mm or 11-mm-long implants, which included those with standard or narrow diameters. Key factors in the successful outcome may relate to the fact that initial healing intervals were long (5 months), many sites were underprepared or developed with hand osteotomes, a long period of provisionalization was used, and the majority of implants were splinted to other implants.

## ACKNOWLEDGMENTS

The authors reported no conflicts of interest related to this study.

## REFERENCES

- Adell R, Eriksson B, Lekholm U, Brånemark PI, Jemt T. Long-term follow-up study of osseointegrated implants in the treatment of totally edentulous jaws. *Int J Oral Maxillofac Implants* 1990;5:347–359.
- Oikarinen K, Raustia AM, Hartikainen M. General and local contraindications for endosteal implants, an epidemiological panoramic radiographic study in 65-year old subjects. *Community Dent Oral Epidemiol* 1995;23:114–118.
- Sun HL, Huang C, Wu YR, Shi B. Failure rates of short ( $\leq 10$  mm) dental implants and factors influencing their failure: A systematic review. *Int J Oral Maxillofac Implants* 2011;26:816–825.
- Olate S, Lyrio MC, de Moraes M, Mazzonetto R, Moreira RW. Influence of diameter and length of implant on early dental implant failure. *J Oral Maxillofac Surg* 2010;68:414–419.
- Renouard F, Nisand D. Impact of implant length and diameter on survival rates. *Clin Oral Implants Res* 2006;17(suppl):s35–s51.
- Pommer B, Frantal S, Willer J, Posch M, Watzek G, Tepper G. Impact of dental implant length on early failure rates: A meta-analysis of observational studies. *J Clin Periodontol* 2011;38:856–863.
- Balevi B. In selected sites, short, rough-surfaced dental implants are as successful as long dental implants: A critical summary of Pommer B, Frantal S, Willer J, Posch M, Watzek G, Tepper G. Impact of dental implant length on early failure rates: A meta-analysis of observational studies. *J Clin Periodontol* 2011;38:856–863. *J Am Dent Assoc* 2013;144:195–196.
- Spiekermann H. Special diagnostic methods for implant patients. In: Rateitschak KH, Wolf HF (eds). *Implantology*. Stuttgart, Germany: Thieme, 1995.
- Rangert BR, Krogh PH, Langer B, van Roekel N. Bending overload and implant fracture: A retrospective clinical analysis. *Int J Oral Maxillofac Implants* 1995;10:326–334.
- Blanes RJ. To what extent does the crown-implant ratio affect the survival and complications of implant-supported reconstructions? A systematic review. *Clin Oral Implants Res* 2009;20(suppl):s67–s72.
- Birdi H, Schulte J, Kovacs A, Weed M, Chuang SK. Crown-to-implant ratios of short-length implants. *J Oral Implantol* 2010;36:425–433.
- Malchiodi L, Cucchi A, Ghensi P, Consonni D, Nocini PF. Influence of crown-implant ratio on implant success rates and crestal bone levels: A 36-month follow-up prospective study. *Clin Oral Implants Res* 2014;25:240–251.
- Calvo-Guirado JL, Saez-Yuguero R, Pardo-Zamora G. Compressive osteotomes for expansion and maxilla sinus floor lifting. *Med Oral Patol Oral Cir Bucal* 2006;11:52–55.
- Cocchetto R, Resch I, Castagna M, Vincenzi G, Celletti R. The abutment duplication technique: A novel protocol for cementable implant-supported restorations. *Int J Periodontol Restorative Dent* 2010;30:415–424.
- Misch CE, Steigenga J, Barboza E, Misch-Dietsh F, Cianciola LJ, Kazor C. Short dental implants in posterior partial edentulism: A multicenter retrospective 6-year case series study. *J Periodontol* 2006;77:1340–1347.
- Blanes RJ, Bernard J-P, Blanes ZM, Belsler UC. A 10-year prospective study of ITI dental implants placed in the posterior region. I: Clinical and radiographic results. *Clin Oral Implants Res* 2007;18:699–706.
- Buser D, Weber HP, Brägger U, Balsiger C. Tissue integration of one-stage implants: 3-year results of a prospective longitudinal study with hollow cylinder and hollow screw implants. *Quintessence Int* 1994;25:679–686.
- Albrektsson T, Zarb GA. Determinants of correct clinical reporting. *Int J Prosthodont* 1998;11:517–521.
- Srinivasan M, Vazquez L, Rieder P, Moraguez O, Bernard JP, Belsler UC. Efficacy and predictability of short dental implants. *Int J Oral Maxillofac Implants* 2012;27:1429–1437.
- Griffin TJ, Cheung WS. The use of short, wide implants in posterior areas with reduced bone height: A retrospective investigation. *J Prosthet Dent* 2004;92:139–144.
- Fugazzotto PA. Shorter implants in clinical practice: Rationale and treatment results. *Int J Oral Maxillofac Implants* 2008;23:487–496.
- ten Bruggenkate CM, Asikainen P, Foitzik C, Krekeler G, Sutter F. Short (6-mm) nonsubmerged dental implants: Results of a multicenter clinical trial of 1 to 7 years. *Int J Oral Maxillofac Implants* 1998;13:791–798.
- Kotsovilis S, Fourmousis I, Karoussis IK, Bamia C. A systematic review and meta-analysis on the effect of implant length on the survival of rough-surface dental implants. *J Periodontol* 2009;80:1700–1718.
- Rossi F, Ricci E, Marchetti C, Lang NP, Botticelli D. Early loading of single crowns supported by 6-mm-long implants with a moderately rough surface: A prospective 2-year follow-up cohort study. *Clin Oral Implants Res* 2010;21:937–943.
- De Santis D, Cucchi A, Longhi C, Vincenzo B. Short threaded implants with an oxidized surface to restore posterior teeth: 1- to 3-year results of a prospective study. *Int J Oral Maxillofac Implants* 2011;26:393–403.
- Urdaneta RA, Daher S, Leary J, Emanuel KM, Chuang SK. The survival of ultrashort locking-taper implants. *Int J Oral Maxillofac Implants* 2012;27:644–654.
- Malchiodi L, Ghensi P, Cucchi A, Pieroni S, Bertossi D. Peri-implant conditions around sintered porous-surfaced (SPS) implants. A 36-month prospective cohort study. *Clin Oral Implants Res* 2015;26:212–219.
- Srinivasan M, Vazquez L, Rieder P, Moraguez O, Bernard JP, Belsler UC. Survival rates of short (6 mm) micro-rough surface implants: A review of literature and meta-analysis. *Clin Oral Implants Res* 2014;25:539–545.
- Renouard F, Nisand D. Short implants in the severely resorbed maxilla: A 2-year retrospective clinical study. *Clin Implant Dent Relat Res* 2005;7(suppl):s104–s110.
- Arlin ML. Short dental implants as a treatment option: Results from an observational study in a single private practice. *Int J Oral Maxillofac Implants* 2006;21:769–776.
- das Neves FD, Fones D, Bernardes SR, do Prado CJ, Neto AJ. Short implants—an analysis of longitudinal studies. *Int J Oral Maxillofac Implants* 2006;21:86–93.
- Anitua E, Orive G, Aguirre JJ, Andia I. Five-year clinical evaluation of short dental implants placed in posterior areas: A retrospective study. *J Periodontol* 2008;79:42–48.
- Deporter D, Ogiso B, Sohn DS, Ruljancich K, Pharoah M. Ultrashort sintered porous-surfaced dental implants used to replace posterior teeth. *J Periodontol* 2008;79:1280–1286.
- Annibaldi S, Cristalli MP, Dell'Aquila D, Bignozzi I, La Monaca G, Pilloni A. Short dental implants: A systematic review. *J Dent Res* 2012;91:25–32.
- Draenert FG, Sagheb K, Baumgardt K, Kämmerer PW. Retrospective analysis of survival rates and marginal bone loss on short implants in the mandible. *Clin Oral Implants Res* 2011;23:1063–1069.
- Esposito M, Pistilli R, Barausse C, Felice P. Three-year results from a randomised controlled trial comparing prostheses supported by 5-mm long implants or by longer implants in augmented bone in posterior atrophic edentulous jaws. *Eur J Oral Implantol* 2014;7:383–395.
- Pieri F, Aldini NN, Fini M, Marchetti C, Corinaldesi G. Preliminary 2-year report on treatment outcomes for 6-mm-long implants in posterior atrophic mandibles. *Int J Prosthodont* 2012;25:279–289.
- Esposito M, Murray-Curtis L, Grusovin MG, Coulthard P, Worthington HV. Interventions for replacing missing teeth: Different types of dental implants. *Cochrane Database Syst Rev* 2007;CD003815.
- Grunder U, Gracis S, Capelli M. Influence of the 3-D bone-to-implant relationship on esthetics. *Int J Periodontics Restorative Dent* 2005;25:113–119.
- Tawil G, Aboujaoude N, Younan R. Influence of prosthetic parameters on the survival and complication rates of short implants. *Int J Oral Maxillofac Implants* 2006;21:275–282.
- Schulte J, Flores AM, Weed M. Crown-to-implant ratios of single tooth implant-supported restorations. *J Prosthet Dent* 2007;98:1–5.
- Degidi M, Piattelli A, Shibli JA, Perrotti V, Iezzi G. Bone formation around immediately loaded and submerged dental implants with a modified sandblasted and acid-etched surface after 4 and 8 weeks: A human histologic and histomorphometric analysis. *Int J Oral Maxillofac Implants* 2009;24:896–901.
- Abrahamsson I, Berglundh T, Lindhe J. The mucosal barrier following abutment dis-reconnection. An experimental study in dogs. *J Clin Periodontol* 1997;24:568–572.
- Yilmaz B, Seidt JD, McGlumphy EA, Clelland NL. Comparison of strains for splinted and nonsplinted screw-retained prostheses on short implants. *Int J Oral Maxillofac Implants* 2011;26:1176–1182.

Accepted: 8 June 2017

DOI: 10.1111/idh.12300

## ORIGINAL ARTICLE

WILEY International Journal of  
Dental Hygiene 

# The association between three attitude-related indexes of oral hygiene and secondary implant failures: A retrospective longitudinal study

S Tecco<sup>1</sup> | MG Grusovin<sup>2</sup> | S Sciarra<sup>3</sup> | F Bova<sup>4</sup> | G Pantaleo<sup>3</sup> | P Capparé<sup>1</sup> <sup>1</sup>Dental School, Vita-Salute San Raffaele University and IRCCS San Raffaele, Milan, Italy<sup>2</sup>Dental School, Vita-Salute San Raffaele University, Milan, Italy<sup>3</sup>UniSR-Social Lab (Research Methods), Faculty of Psychology, Vita-Salute San Raffaele University, Milan, Italy<sup>4</sup>Center for Oral Hygiene and Prevention, Dental School, Vita-Salute San Raffaele University and IRCCS San Raffaele, Milan, Italy**Correspondence**Paolo Capparé, Dentistry Department, IRCCS San Raffaele Hospital, Milan, Italy.  
Email: paolocappare@gmail.com**Abstract**

**Objective:** This study evaluated the strength of the association between three widely used clinical indexes considered as distal behavioural indicators of attitude-related oral status (an index of oral hygiene, the plaque index [PI] and two periodontal indexes, that is the presence of bleeding on probing [BOP] and of pockets probing depth [PPD]) and secondary implant failure due to peri-implantitis in patients rehabilitated with cemented prosthesis.

**Materials and Methods:** The study included patients who underwent implant-prosthetic rehabilitation and had joined the programme of maintenance of the same hospital. Implant failures, number of months between implant insertion and implant loading, and patients' surgical protocol were monitored and recorded. Further, PI, BOP and PPD—all attitude-related indicators of oral hygiene and periodontal inflammation—were recorded and related, in terms of odds ratios (OR<sub>s</sub>) and corresponding risk factors, to secondary implant failures.

**Results:** A total of 1427 patients (2673 implants) were enrolled. The follow-up ranged from 1.5 to 9 years (mean 5.3 years±1.3). The cumulative survival rate was 98.01%. Thirty-two patients (36 implants, 1.36% of all implants) had implant failure. A statistically significant association between PI, BOP, PPD and secondary failures due to peri-implantitis was observed.

**Conclusion:** Within the limitations of this study, all three attitude-related behavioural indicators—the plaque index (PI), bleeding on probing (BOP) and abnormal probing pocket depth (PPD)—proved to be significant risk indicators for secondary implant failure due to peri-implantitis, both from a clinical and from a socio-psychological attitude-related perspective.

**KEYWORDS**

dental implant, failure, oral hygiene, retrospective

## 1 | INTRODUCTION

Despite the remarkably high survival rate of dental implants, it is important to understand factors related to implant failures so that prevention of negative events can be implemented both at the clinical and at the psychosocial level. Whereas at the clinical level, careful

consideration of oral health status may seem fairly obvious to clinicians, background psychological aspects and behavioural indexes of patients' attitude-related poor oral hygiene are often neglected, even when they actually may play a crucial role in determining desirable clinical outcomes. In line with the tenets of experimental social psychology—a relatively new life science typically proceeding by hypothesis

testing<sup>1</sup>—at the psychological level of functioning, poor oral care and hygiene may easily stem from wrong habits, beliefs and attitudes towards the dentist and oral hygiene maintenance.<sup>2,3</sup> Insufficient oral hygiene may in turn result into severe conditions of poor oral health, as part of a process leading from periodontal inflammation to irreversible implant failure.<sup>4</sup> Negative oral health-related outcomes such as teeth decay, deteriorated dental aesthetics, teeth loss and implant failure are not negligible events, as they all deeply affect patients' self-regard, self-esteem and, ultimately, patients' broader social functioning.<sup>5-7</sup> Good oral health and quality-of-life bolstering psychological conditions, by contrast, have been demonstrated to be systematically linked—among others—to successful crown therapy,<sup>3</sup> reduced dentine hypersensitivity,<sup>8,9</sup> and, more generally, proper orthodontic treatments and interventions.<sup>6</sup>

On a concrete, behavioural plan, some *distal behavioural indicators* commonly used in clinical practice, such as the plaque index (PI), presence of bleeding on probing (BOP) and of probing pockets depth (PPD), play a crucial role because they allow the clinician to directly monitor what patients do or have actually done in order to maintain proper oral conditions, rather than limiting the measurements only to the more abstract "emotional" or "cognitive" components of patients' attitude-related behaviours towards oral health.

Implant failures can be divided into early and late failures.<sup>10,11</sup> Early failure occurs before implant loading,<sup>12</sup> while late failure after occlusal loading.<sup>13,14</sup> Peri-implantitis is one of the causes of late implant failure and can be defined as the presence of bleeding and/or suppuration on probing, redness and swelling of the mucosa, deepening of the pockets adjacent to the dental implants and loss of supporting bone.<sup>15</sup> Treatment of peri-implantitis represents a challenge for clinicians. Thus, it becomes important to understand which factors can lead to the development of the disease. Plaque accumulation is a risk factor for infection. The majority of the authors recommend to routinely assess plaque, marginal bleeding, bleeding on probing and probing depth during the follow-up visits of their patients treated with implant-prosthetic rehabilitation. This is because inflammatory processes can ultimately lead to implant failure and, thus, good oral hygiene is considered as a positive predictor of implant success.<sup>16</sup> A correlation between previous periodontal disease and peri-implant status is also supported by the literature.<sup>17</sup> The presence of periodontal bacteria around failing implants could suggest a correlation between periodontitis and peri-implantitis.<sup>18</sup>

Inflammatory processes can be diagnosed through presence of bleeding on probing and of deepened probing depth.<sup>19</sup>

Dental practitioners play an important role in the diagnosis of gingival, periodontal and peri-implant diseases. It is not yet known the level at which peri-implant indexes can be used to predict the risk of implant failure, that is to say above which values the clinician should fear the possibility of implant failure and which is the role that the periodontal follow-up performed by the hygienists can have.<sup>20</sup>

The aim of this work was to assess the strength of association between three widely used indicators (the index of oral hygiene, the plaque index [PI], and two periodontal indices, that is presence of bleeding on probing [BOP] and presence of probing pocket depth

[PD]), considered as distal behavioural indicators of attitude-related oral status, and secondary implant failure due to peri-implantitis in patients following a dedicated maintenance programme.

## 2 | MATERIALS AND METHODS

The participants of this retrospective longitudinal study were selected among those who had undergone implant-prosthetic rehabilitation at the Department of Dentistry, IRCCS San Raffaele Hospital, Milan, Italy. Patient records and data recorded at the department in the digital database software (Dental Management System DMS, ET Edizioni Tecnologiche, Milan, Italy) were analysed. The STROBE Statement for improving the quality of cohort studies was followed.

Conical implants with rough surface (Micro Rough Surface—MRS<sup>®</sup>) and internal hexagon connection were used (K implants, WinSix<sup>®</sup>, BioSAFin. S.r.l.—Ancona, Italy).

Inclusion criteria were as follows:

- Adult patients (>18 years) with partial edentulous status, submitted at the Department of Dentistry, IRCCS San Raffaele Hospital, Milan, Italy, for the implant-prosthetic therapy, with the insertion of at least one fixture;
- Patients referred, at the end of their implant-prosthesis rehabilitation, to the implant maintenance programme at the Centre for Oral Hygiene and Prevention (COHP) of the same Department, and inserted in the programme to follow-up.
- No systemic contraindications to implant-prosthetic therapy;
- Complete medical records present;
- Follow-up of at least 1.5 years.

Exclusion criteria were as follows:

- Patients who had not joined the programme of maintenance and follow-up at the COHP of the same hospital;
- Patients with incomplete data about implant failures;
- Full-arch rehabilitations;
- Rehabilitations with at least one tilted implant;
- Rehabilitations with implants shorter than 9 mm;
- Screw-retained rehabilitations.

All patients signed a consent form for implant-prosthetic rehabilitations and implant surgery.

Eligible patients had undergone at the COHP the following protocol:

- An initial examination (t0) performed about 30 days before the implant/s insertion;
- A second visit performed at the time of prosthetic functionalization (t1);
- Thereafter, a series of check-ups organized periodically, every 4 months (t2, t3, ..., tn, ...), during which the PI, BOP and PD were detected.



The clinical protocol adopted during the sessions of follow-up is described in Table 1, which reports the operating sequence used for healthy implants.

Instead, when the implant site appeared to suffer from mucositis and/or peri-implantitis, the operational protocol was modified adopting the addition of the so-called cumulative interceptive supportive therapy (C.I.S.T.),<sup>21</sup> depending on the severity of the pathology observed.

According to Sanz et al.,<sup>15</sup> peri-implant mucositis and peri-implantitis were defined as:

- *Peri-implant mucositis*: Presence of redness and swelling in the peri-implant soft tissue. Bleeding on probing is currently recognized as the important feature. No appreciable peri-implant bone loss.
- *Peri-implantitis*: Presence of an inflammatory process around an implant, including both soft-tissue inflammation and progressive loss of supporting bone beyond biological bone remodelling.

A vertical distance of 2 mm from the expected crestal bone level following remodelling after implant placement was considered as the threshold level.<sup>22</sup> Moreover, the parameter used to assess soft-tissue inflammation in either mucositis or peri-implantitis was the bleeding on probing (BoP) index.<sup>22</sup>

## 2.1 | Data collection and preliminary coding

The primary outcome measure was secondary implant failure due to peri-implantitis, with "implant failure," meaning the removal or loss of an implant for progressive peri-implantitis after successful loading. For each patient, the number, the time, the reason of implant failure and the surgical protocol adopted for the insertion were recorded.

The plaque index (PI O'Leary), the presence of bleeding on probing (BOP) and of probing pockets depth (PPD) were recorded on teeth, whereas modified plaque index (mPI) and modified bleeding index (mBOP) referred to implants.<sup>23,24</sup> Each measurement was acquired at mesial, distal, palatal and vestibular sites.<sup>25</sup>

Data were considered from the first maintenance visit, at 4 months from prosthetic functionalization of implants to the end of the follow-ups. Mean values were calculated at patient level, for each of the study variables and across all follow-up visits. Thus, with respect to the PI O'Leary and mPI variables, data were coded into "low presence of plaque" (PI ≤ 25%) vs "presence of plaque" (PI > 25%). Analogously, with respect to the BOP and mBOP variables, data were coded into "low presence of bleeding on probing" (BOP ≤ 30%) vs "presence of bleeding on probing" (BOP > 30%). Finally, with respect to the PPD variable, data were coded into "absence of probing depth" (PPD ≤ 4) vs "presence of at least one site with probing depth" (PPD > 4 mm). All analyses were conducted at patient level.

## 2.2 | Statistical methods and plan for the analyses

Odds ratios (OR<sub>s</sub>) were calculated separately for PI (O'Leary)/mPI, BOP/mBOP and PPD to test their role as attitude-related risk indicators of secondary implant loss. *Confidence intervals* at 95% and *Z-tests*

of significance for OR<sub>s</sub> were also computed, to provide an estimate of range of expected results, along with a test of statistical significance, for each of the three potential risk factors. The degree of independence vs. association in the cross-tabulations of categorical variables related to each of the three OR<sub>s</sub> was established by  $\chi^2$  tests. The *P*-value for each statistical test of significance was set at .05.

## 3 | RESULTS

A total of 1751 patients (4637 implants) were rehabilitated from March 2006 to March 2013.

Thirty-eight patients (266 implants) were excluded because they were treated with full-arch rehabilitation after grafting procedures; 31 patients (296 implants) were excluded because they were treated with full-arch rehabilitation without grafting; 137 patients (742 implants) were excluded because they were treated with tilted implants for full-arch rehabilitation; 8 patients (21 implants) were excluded because they were treated with tilted implants for partial rehabilitation. Subjects excluded because treated with screw-retained rehabilitations were all part of these excluded cases. Finally, 1537 subjects (3312 implants) were considered as eligible subjects and treated between March 2006 and March 2013.

Further, 110 patients from this latter group were excluded, as they did not adhere to the maintenance programme. Indeed, the 110 patients were excluded because they were not present at least at one recall visit. So, the minimum adherence was three visits each 12 months (1 visit each 4 months). Thus, the ratio between suggested and attended visits each year was one. A total of 1427 subjects (2673 implants) were thus included in the study. Patients' clinical follow-up ranged from 1.5 to 9 years (mean 5.3 years ± 1.3), and the number of detections/visits per patient ranged from a minimum of four detections/visits (for patients with follow-up of 1.5 years) to a maximum of 22 detections/visits (for patients with follow-up of 9 years). The flow chart of the study is depicted in Figure 1.

### 3.1 | Implant failure

Preliminary descriptive analyses showed that a total of 31 patients (M: 10; F: 21) experienced implant loss. Thirty-six implants (1.35% of 2673 implants) failed. The cumulative survival rate was 98.01% (36 implants failed). Twenty patients (among 31 patients) experienced early failure of 24 implants in a range of time of 1-3 months from implant insertion (in these cases, implant failure was due to primary infection). Eleven patients (12 implants) experienced secondary implant failure, all because of peri-implantitis.

In total, 803 implants (30.04%) in 314 patients suffer from mucositis and 238 implants (8.90%) in 98 patients suffer from peri-implantitis.

Data about the location, size and type of failed implants for secondary infections are reported in Table 2. Ten of these 11 subjects were females. Among these subjects, four patients experienced implant failure before 20 months and four patients more than 3 years from insertion (Table 2).

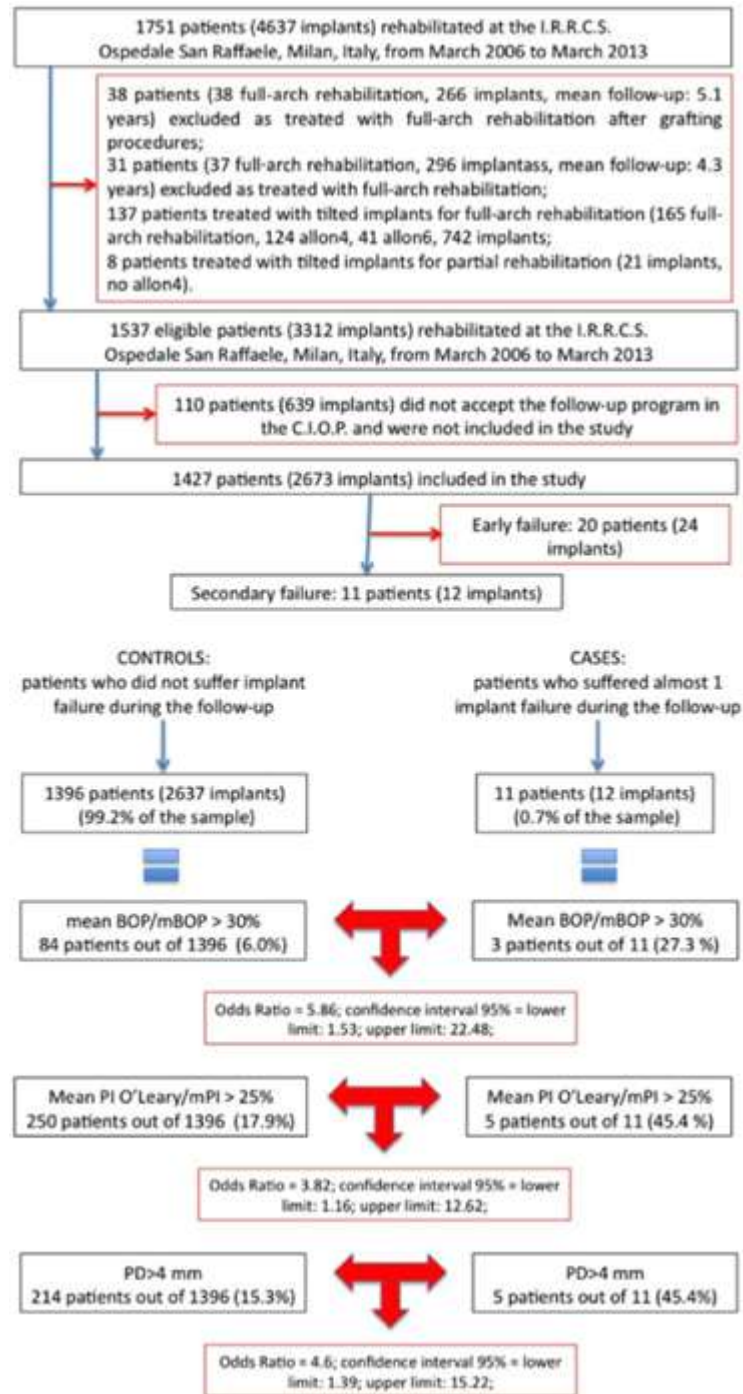


FIGURE 1 Flow chart of the study

**TABLE 1** Operating protocol at C.I.O.P. Visits and data acquisition performed every 4 months from the prosthetic functionalization of osseointegrated implants

1. Check the patient's medical history framework;
2. Assessment of exposure to risk factors for the peri-implant disease;
3. Detection of clinical parameters: PI O'Leary, PPD, BOP;
4. Education and patient motivation to correct and regular oral hygiene at home, and—where necessary—to the use of at-home hygiene aids adequate to implant-prosthesis;
5. Supragingival scaling;
6. Supragingival air-polishing with powder of glycine in average grain size;
7. Subgingival polishing with powder of glycine at a very low particle size

All the failed implants were inserted using a delayed loading protocol, with no post-extractive implants; in one patient, the insertion was made on previously regenerated alveolar bone.

Considering the entire follow-up period, further descriptive analyses of the PI, BOP and PD indexes conducted on patients with secondary implant failure revealed the following pattern of preliminary results:

- An average PI (O'Leary)/mPI [mean values between PI (O'Leary) values and mPI values] of 28.4%±14.8% (range: 11%-58.5%), with five patients of 11 showing a mean PI (O'Leary)/mPI index >25%.
- An average BOP/mBOP [mean values between BOP values and mBOP values] of 13.4%±12.7% (range: 2%-33%), with three patients showing a mean BOP/mBOP index>30%.
- An average PD >4 mm of 34%±26.1% (range: 3%-73% of sites), with five patients showing a mean PD >4 mm during the follow-up in more than 25% of sites.

Main statistical analyses revealed that, when the relationships between (i) mean PI (O'Leary)/mPI and secondary implant failure, (ii) mean BOP/mBOP and secondary failure and (iii) PD>4 mm and secondary implant failure were evaluated to test the role of these variables as potential risk factors, the following results emerged (Table 3):

- A statistically significant association between PI (O'Leary)/mPI and secondary implant failure ( $\chi^2_{(1)}=5.58$ ,  $P=.018$ , without Yates' correction), corresponding to an OR for PI (O'Leary)/mPI >25% of 3.82.
- A statistically significant association between BOP/mBOP >30% and secondary failure ( $\chi^2_{(1)}=5.23$ ,  $P=.022$ , with Yates' correction), corresponding to an OR for BOP/mBOP >30% of 5.86.
- A statistically significant association between PPD >4 mm and implant failure ( $\chi^2_{(1)}=7.54$ ,  $P=.006$ , without Yates' correction), corresponding to an OR for PD >4 mm of 4.60.

**TABLE 2** Raw data on secondary implant failures

N	Gender	Tooth site (Palmer numeration)	Months from insertion and failure	Months from loading to failure	Width (mm)	Length (mm)
Patient 1	F	3.2	38	33	3.3	13
Patient 2	F	1.6	6	1	5	10
Patient 3	F	1.5	24	24	6.5	9
Patient 4	F	1.5	33	30	3.3	11
Patient 5	F	1.6	47	44	4.5	11
Patient 6	F	1.6	20	12	5.2	9
Patient 7	M	2.7	4	1	5	10
Patient 8	F	4.6	23	20	3.8	9
Patient 9	F	3.6	15	12	4.5	11
Patient 10	F	4.5	72	69	3.8	11
Patient 11	F	4.6-3.6	59	56	4.5	11

**TABLE 3** Systematic relationships between secondary implant failure and identified risk factors

	Chi-square and P-values	Odds ratios	95% CIs	Z-test	P
PI (O'Leary)/mPI >25%	$\chi^2_{(1)}=5.58$ $P=.018$ without Yates' correction	3.82	1.16-12.62	2.20	.028
BOP/mBOP >30%	$\chi^2_{(1)}=5.23$ $P=.022$ with Yates' correction	5.86	1.53-22.48	2.58	.01
PPD >4 mm	$\chi^2_{(1)}=7.54$ $P=.006$ without Yates' correction	4.60	1.39-15.22	2.50	.012

#### 4 | DISCUSSION

This study found a statistically significant association among poor oral hygiene and related periodontal inflammation status and secondary implant failure due to peri-implantitis. More specifically, all three indicators (PI, BOP and PPD), considered through all maintenance visits, were systematically and reliably associated with secondary implant failures due to peri-implantitis. The risk of experiencing secondary implant loss was 3.8 times higher for patients with PI (O'Leary)/mPI >25% than for their counterparts. Analogously, the risk of experiencing secondary implant loss was 5.86 times higher for patients with BOP/mBOP >30% if compared with their counterparts. Finally, the risk of experiencing secondary implant loss was 4.60 times higher for patients with PPD >4 mm than for their counterparts. Taken together, this pattern of results suggests that PI, BOP and PPD should be carefully monitored as indicators of a concrete risk of experiencing secondary implant loss—a risk that we estimated, even in the case of the most favourable observed outcome (PI), of at least four times (OR=3.8) more pronounced for exposed patients than for their non-exposed counterparts.

In showing how poor oral hygiene is linked to deteriorated oral status and, in turn, to implant failure, our pattern of results also steers attention to those implicit socio-psychological factors (eg wrong attitude-related habits and beliefs towards the dentist and/or oral hygiene)<sup>2,3</sup> which should constitute the target of informed and specific interventions, aimed at monitoring and preventing their negative effects. In this respect, a clear limit of this study is that we considered only three *distal* attitude-related indexes (PI, BOP and PPD) of the *behavioural* component of oral hygiene. Further studies could thus benefit from considering also the role of more traditional "cognitive" and "emotional" components of patients' thinking and feeling about oral health.

From a methodological point of view, the identification of risk factors would be even more informative if conducted on the basis of longitudinal prospective studies. Nevertheless, retrospective studies with a considerable sample size—such as ours—can suggest clinically useful risk indicators as well, to closely monitor patients' oral status during maintenance. In this respect, in a 15-year prospective study on 46 edentulous patients poor oral hygiene was associated with bone loss, while only one secondary failure was recorded.<sup>26</sup> Other retrospective studies tried to identify risk indicators associated with implant complications, but substantial differences in the protocols used make a direct comparison with our study difficult. Roos-Jansåker et al.<sup>17</sup> presented data on 218 patients with 9- to 14-year follow-up and found a significant correlation between implant loss and periodontal bone loss at remaining teeth. At patient level, peri-implantitis was related to a previous history of periodontitis and smoking,<sup>4</sup> while no correlation was found with the frequency of visits to the hygienist/dentist and, at the implant level, with plaque.

Recently, Daubert et al.<sup>27</sup> in examining the time of implant failure in a sample of 96 patients (225 implants) with a follow-up time of 10.9–1.5 years, reported five secondary failures due to peri-implantitis, all in patients with history of periodontitis. Data on oral hygiene and maintenance visits were not considered.

Implant survival rate in non-periodontitis and periodontitis patients has been analysed in several studies. The data indicate that patients with periodontitis are more prone to peri-implantitis,<sup>4</sup> bone loss around implants and eventually implant failure.<sup>28,29</sup> Patients with chronic periodontitis had four times more chance of developing peri-implant disease than patients with healthy periodontal tissues.<sup>30</sup> A recent study states that within the same subjects, putative periodontal pathogens are common to both periodontal and peri-implant sites irrespective of health status, while the prevalence and levels of *P. gingivalis* and *F. nucleatum* are significantly associated with periodontitis, but not with peri-implantitis.<sup>31</sup>

All the patients included in the study were treated using similar rehabilitation protocols, followed an accurate maintenance programme. The low failure rate suggests that implant therapy can be successfully used in patients who undergo proper therapy and regular periodontal maintenance.<sup>32</sup>

Patients with different follow-up periods were included in the study. All patients included followed the proposed maintenance programme, and the periodicity of their visits remained more or less constant in all patients during their entire follow-up. This seems to confirm the validity of a maintenance programme organized based on the mechanism of the phone recalls.

Only cemented rehabilitations were used to examine a more homogenous sample, because the presence of cement can be one factor in the development of peri-implantitis.<sup>4,33</sup> All the patients had cemented restoration and were treated in the same way with careful removal of all remaining cement.

With the aim of obtaining indications that could be easily applied in clinical practice, we chose to correlate presence of secondary failures to dichotomized indexes. Thus, with respect to PI O'Leary/mPI, the cut-off level was set at 25%, because this is the most common cut-off value used in periodontal studies to discriminate between patients with acceptable vs. bad oral hygiene.<sup>23</sup> Analogously, a cut-off value of 30% was used for BOP/mBOP in accordance with Joss et al.<sup>34</sup> who considered as clinical indicators of disease progression or periodontal stability, respectively, mean BOP and mBOP values >30% or ≤30%. Finally, a cut-off level of PPD >4 mm was established because, in clinical practice, it has been widely used to individuate subjects with periodontitis.<sup>35</sup>

#### 5 | CONCLUSIONS

Within the limitations discussed above, all three attitude-related behavioural indicators of oral hygiene and periodontal status monitored in this study—the plaque index (PI), the presence of bleeding on probing (BOP), and abnormal probing pocket depth (PPD)—proved to be significant risk indicators for secondary implant failure due to peri-implantitis. All three monitored variables revealed significant increases in the risk of experiencing secondary implant failure due to peri-implantitis—a risk that we estimated, even in the case of the most favourable observed outcome (PI), of at least (circa) four times (OR=3.8) more pronounced for exposed patients than for their non-exposed counterparts. This pattern of results has clear and distinct

relevance for preventing implant failure, both from a clinical and from an attitude-related socio-psychological perspective.

## 6 | CLINICAL RELEVANCE

### 6.1 | Scientific rationale

In the current literature, it is not yet known how peri-implant attitude-related indexes can be used to predict the risk of implant failure; that is, above which values the clinician should fear the possibility of implant failure, and which is the role that the periodontal maintenance performed by the hygienists can have.

### 6.2 | Principal findings

Attitude-related behavioural indicators of oral hygiene—the plaque index (PI), and the periodontal indices bleeding on probing [BOP] and abnormal probing pocket depth (PPD)—proved to be significant risk indicators for secondary implant failure due to peri-implantitis.

### 6.3 | Practical implications

A correct maintenance protocol can preserve good oral hygiene in implant patients and can lower the risk of secondary implant failure, both from a clinical and from a socio-psychological attitude-related perspective.

## ACKNOWLEDGEMENTS

Authors disclosed any commercial or other relationships that could constitute a conflict of interest.

## REFERENCES

- Koller M, Lorenz W. Quality of life: a deconstruction for clinicians. *J R Soc Med*. 2002;95:481-488.
- Thomson WM. Social inequality in oral health. *Community Dent Oral Epidemiol*. 2012;40(suppl 2):28-32.
- Lundgren GP, Karsten A, Dalhoef G. Oral health-related quality of life before and after crown therapy in young patients with amelogenesis imperfecta. *Health Qual Life Outcomes*. 2015;13:197-205.
- Renvert S, Quirynen M. Risk indicators for peri-implantitis: a narrative review. *Clin Oral Implants Res*. 2015;26(suppl 11):15-44.
- Davis LG, Ashworth PD, Spriggs LS. Psychological effects of aesthetic dental treatment. *J Dent*. 1998;26:547-554.
- Healey DL, Gauld RD, Thomson WM. Treatment-associated changes in malocclusion and oral health-related quality of life: a 4-year cohort study. *Am J Orthod Dentofacial Orthop*. 2016;150:811-817.
- Crespi R, Capparé P, Gastaldi G, Gherlone EF. Immediate occlusal loading of full-arch rehabilitations: screw-retained versus cement-retained prosthesis. An 8-year clinical evaluation. *Int J Oral Maxillofac Implants*. 2014;29:1406-1411.
- Bekes K, Hirsch C. What is known about the influence of dentine hypersensitivity on oral health-related quality of life? *Clin Oral Invest*. 2013;17(suppl 1):S45-S51.
- Calderini A, Sciarra S, Semeria C, Pantaleo G, Polizzi E. Comparative clinical and psychosocial benefits of tooth bleaching: different light-activation of a 38% peroxide gel in a preliminary case-control study. *Clin Case Rep*. 2016;4:728-735.
- Romanos GE, Javed F, Delgado-Ruiz RA, Calvo-Guirado JL. Peri-implant diseases: a review of treatment interventions. *Dent Clin North Am*. 2015;59:157-178.
- Manor Y1, Oubaid S, Mardinger O, Chaushu G, Nissan J. Characteristics of early versus late implant failure: a retrospective study. *J Oral Maxillofac Surg*. 2009;67:2649-2652.
- Esposito M, Hirsch JM, Lekholm U, Thomsen P. Biological factors contributing to failures of osseointegrated oral implants. (I). Success criteria and epidemiology. *Eur J Oral Sci*. 1998;106:527-551.
- Keenan JR, Veitz-Keenan A. The impact of smoking on failure rates, postoperative infection and marginal bone loss of dental implants. *Evid Based Dent*. 2016;17:4-5.
- Lundgren AK, Åström M. Letter to the editor: effectiveness of implant therapy analyzed in a Swedish population: early and late implant loss. *J Dent Res*. 2015;94(suppl 9):2335.
- Sanz M, Chapple IL, on behalf of Working Group 4 of VIII European Workshop on Periodontology. Clinical research on peri-implant diseases: consensus report of Working Group 4. *J Clin Periodontol*. 2012;39(suppl 12):202-206.
- Ferreira SD, Silva GL, Cortelli JR, Costa JE, Costa FO. Prevalence and risk variables for peri-implant disease in Brazilian subjects. *J Clin Periodontol*. 2006;33:929-935.
- Roos-Jansäker AM, Lindahl C, Renvert H, Renvert S. Nine- to fourteen-year follow-up of implant treatment. Part II: presence of peri-implant lesions. *J Clin Periodontol*. 2006;33:290-295.
- Mombelli A, Marxer M, Gaberthüel T, Grunder U, Lang NP. The microbiota of osseointegrated implants in patients with a history of periodontal disease. *J Clin Periodontol*. 1995;22:124-130.
- Salvi GE, Lang NP. Diagnostic parameters for monitoring peri-implant conditions. *Oral Maxillofac Implants*. 2004;19(suppl 1):116-127.
- Gherlone EF, Capparé P, Tecco S, et al. Implant prosthetic rehabilitation in controlled HIV-positive patients: a prospective longitudinal study with 1-year follow-up. *Clin Implant Dent Relat Res*. 2016;18:955-964.
- Lang NP, Wilson TG, Corbet EF. Biological complications with dental implants: their prevention, diagnosis and treatment. *Clin Oral Implants Res*. 2000;11(suppl 1):146-155.
- Coli P, Christiaens V, Sennerby L, De Bruyn H. Reliability of periodontal diagnostic tools for monitoring peri-implant health and disease. *Periodontol 2000*. 2017;73:203-217.
- Mombelli A, Lang NP. The diagnosis and treatment of peri-implantitis. *Periodontol 2000*. 1998;17:63-76.
- Crespi R, Capparé P, Gherlone E. Immediate loading of dental implants placed in periodontally infected and non-infected sites: a 4-year follow-up study. *J Periodontol*. 2010;81:1140-1146.
- Gherlone EF, Capparé P, Tecco S, et al. Implant prosthetic rehabilitation in controlled HIV-positive patients: a prospective longitudinal study with 1-year follow-up. *Clin Implant Dent Relat Res*. 2016;18:725-734.
- Lindquist LW, Carlsson GE, Jemt T. A prospective 15-year follow-up study of mandibular fixed prostheses supported by osseointegrated implants. Clinical results and marginal bone loss. *Clin Oral Implants Res*. 1996;7:329-336.
- Daubert DM, Weinstein BF, Bordin S, et al. Prevalence and predictive factors for peri-implant disease and implant failure: a cross-sectional analysis. *J Periodontol*. 2015;86:337-347.
- Salcetti JM, Moriarty JD, Cooper LF, et al. The clinical, microbial, and host response characteristics of the failing implant. *Int J Oral Maxillofac Implants*. 1997;12:32-42.
- Meijndert L, van der Reijden WA, Raghoebar GM, Meijer HJ, Vissink A. Microbiota around teeth and dental implants in periodontally healthy, partially edentulous patients: is pre-implant microbiological testing relevant? *Eur J Oral Sci*. 2010;118:357-363.



30. Casado PL, Pereira MC, Duarte ME, Granjeiro JM. History of chronic periodontitis is a high risk indicator for peri-implant disease. *Braz Dent J.* 2013;24:136-141.
31. Zhuang LF, Watt RM, Mattheos N, Si MS, Lai HC, Lang NP. Periodontal and peri-implant microbiota in patients with healthy and inflamed periodontal and peri-implant tissues. *Clin Oral Implants Res.* 2016;27:13-21.
32. Zangrando MS, Damante CA, Sant'Ana AC, Rubo de Rezende ML, Greggi SL, Chambrone L. Long-term evaluation of periodontal parameters and implant outcomes in periodontally compromised patients: a systematic review. *J Periodontol.* 2015;86:201-221.
33. Pesce P, Canullo L, Grusovin MG, de Bruyn H, Cosyn J, Pera P. Systematic review of some prosthetic risk factors for periimplantitis. *J Prosthet Dent.* 2015;114:346-350.
34. Joss A, Adler R, Lang NP. Bleeding on probing. A parameter for monitoring periodontal conditions in clinical practice. *J Clin Periodontol.* 1994;21:402-408.
35. Albandar JM. Periodontal diseases in North America. *Periodontol* 2000. 2002;29:31-69.

**How to cite this article:** Tecco S, Grusovin MG, Sciara S, Bova F, Pantaleo G, Capparé P. The association between three attitude-related indexes of oral hygiene and secondary implant failures: A retrospective longitudinal study. *Int J Dent Hygiene.* 2017;00:1-8. <https://doi.org/10.1111/idh.12300>

### Prosthetic rehabilitation after total resection of the nose and premaxilla for adenosquamous carcinoma

**Marzorati Gianluca, Palumbo Luca, Capparè Paolo, Gastaldi Giorgio, Gherlone Enrico F.**

Dental School, Università Vita-Salute San Raffaele, Milan, Italy

**Aim:** Maxillofacial defect caused by cancer treatment represents a problem affecting the quality of life of patients. The prosthetic rehabilitation is a surgical alternative in functional-aesthetic facial reconstruction when the conventional reconstructive surgery cannot be applied either because of the psychophysical conditions of the patient or because of an excessive excessive loss of tissue. The aim of this study is to report an our technical approach to the rehabilitation of a complex oronasal defect by means of a implant-supported dental prosthesis combined with a nasal epithesis.

**Methods:** We present the case of a 82 years-old man, who had a maxillectomy and total rhinectomy defect because of a adeno squamous cell carcinoma of the tip of the nose. After the surgery, the patient presented a maxillary defect associated to the absence of the nasal pyramid. We hereby describe one prosthetic device rehabilitating two iatrogenic defects by means an overdenture supported to four implants with locator attack that extends throughout the oronasal communication: this offering nasal epithesi anchorage. Both dental prosthesis that epithesis are completely removable from the patient. After oncological surgery, temporary epithesis was necessary because the surrounding tissues are still in a healing process and they cannot excessively stressed. Six months later, four intraoral implants were placed in maxilla and they offer good anchorage in rehabilitating wide defects after oncological surgery and a good chance for patients to improve their quality of life.

**Results:** Since one year the patient has a prosthetic rehabilitation that allows good phonetics, proper nutrition and adequate social relationship. The patient well tolerated the prosthesis, and he was able to do a proper oral and nose hygiene. From an oncological point of view, there was no relapse of the pathology. The patient did not receive radiotherapy and was nonsmoker, two factors that are known to influence the success of implant therapy.

**Conclusion:** The prosthetic rehabilitation offers a good chance to social reintegration because the aesthetic result and facial camouflage are good and then it allows a good retention of the nasal epithesis and an esthetic result which is satisfying for the patient. Despite the accurate professional and home care required by intraoral implants, prosthetic rehabilitation could be considered an effective and suitable method for rehabilitation of extensively resected head and neck cancer patients.

### **Dental implant rehabilitation at the dental clinic, department of dentistry, San Raffaele Hospital, Milan: a report of 2015/2016**

**Cantile Nicola, Patianna Giuseppe Pio, Cardarelli Angelo, Nagni Matteo, Grechi Michele**

Dental School, Department of Dentistry (Head: Prof. E. Gherlone), IRCCS San Raffaele Hospital, Milan, Italy

**Aim:** The aim of our study was to evaluate the whole number of dental implant rehabilitations in patients referred to the Dental Clinic of San Raffaele Hospital, Milan in the academic year 2015/2016. This unit is aimed to allow vulnerable social classes to equally and easily access to dental care, ensuring quality and excellence. A key-role in this context is held by a synergic relation between students and the renowned tutors of the Department.

**Methods:** A retrospective analysis of the total number of dental implants placed in different categories of patients was performed. We considered different and heterogeneous types of oral rehabilitations: from single implant to full-arch rehabilitation of maxillary and mandibular jaws, both in healthy and compromised conditions. Patients were affected by different diseases like viral hepatitis, diabetes, acquired immunodeficiency syndrome (AIDS), myocardial or renal insufficiency, and also patients who have had or have a neoplasia. Follow-up controls were performed at 3 (T1), 6 (T2), 9 (T3) and 12 (T4) months after implant insertion and included both radiographic assessments of bone level around the implants and clinical parameters evaluation (plaque accumulation and bleeding index). The radiographic evaluation was based on the analysis of bone levels on the mesial and distal ridges around the fixtures, as shown by intraoral radiographs taken with Rinn's film holders.

**Results:** Single implants were placed in 32 patients (71 implants), while the overall number of complete-arch immediately loaded prostheses was 15 (60 implants). Low incidence of complications and long-term survival rates were recorded after twelve months of followup. Implant failure occurred in 4 patients (5 fixtures out of 131), one healthy and four with pathological systemic conditions. The implant survival rate was 96.2%, while prosthetic provisional failure occurred in only 2 patients. The most common complication was mucositis around implants, while the most negative prognostic factor was found to be plaque accumulation around implants.

**Conclusion:** In armony with the current literature, our analysis confirms the high predictability of the modern protocols in implant dentistry, even in healty compromised patients where implant rehabilitation can have a higher risk of failure. A huge percentage of patients showed confidence in complying on the service we offer.

### Comparative study between sinus floor elevation and tilted implant in the atrophic posterior maxilla

**Manenti C., Mottola F., Tetè G., Vinci R.**

Department of Dentistry, IRCCS San Raffaele Hospital, Milan Italy  
Dental School, Vita Salute San Raffaele University, Milan, Italy

**Aim:** Owing to mechanical and anatomic difficulties, implant treatment in the atrophic maxilla represents a challenge. The purpose of this study was to compare two rehabilitation techniques: the maxillary sinus and the tilted implants.

**Methods:** Have been selected 10 patients with the same inclusion and exclusion criteria which included age, the absence of systemic diseases, absence of bisphosphonate therapy, the absence of allergies, reduced minimum height of the residual edentulous ridge of 3mm. They were divided into two groups: the test group was made of the breast upward and control group were inserted tilted implants, mesial to the anterior wall of the maxillary sinus whose platform is placed at the level of the first molar, to allow a prosthetic rehabilitation fixed from 1.2 to 1.6 without cantilever distal. Information about the quantity and quality of bone, the system characteristics (shape, diameter and length), the presence of dehiscence and fenestrations and torque implant insertion were recorded on special forms at the time of surgery, both for reasons legal doctor of the final prosthetic management. The patients were followed weekly for the first month to evaluate the healing of the periimplant soft tissue and the prosthetic functionality. Subsequent check-ups are carried out on the basis of Implant maintenance protocol and when requested by the patient. During the entire observation period it was recorded the plaque index and bleeding index every six months, using a predefined scheme. Every six months for the first two years and then annually up to five years from the load must be carried out individual radiographs with individual centering technique and the long cone for accurate assessment of changes in the peri-implant bone level through computer analysis.

**Results:** Monitoring visits were found a plaque and bleeding index in the standard (20-25%) and a low percentage of implant loss. There is no statistically significant superiority between the two techniques. The tilted implant offer the possibility of an immediate aesthetic while for sinus lift you must wait a period of between 4-6 months for the bone healing and proceed to the case of the prosthesis. Also in two of

10 patients it manifested a sinus complication.  
**Conclusions:** Results indicate that the use of tilted implants is an effective and safe alternative to maxillary sinus floor augmentation procedures.



### Split crest technique in the atrophic maxilla: indication for the treatment

**Mottola F., Manenti C., Tetè G., Vinci R.**

Departement of Dentistry, IRCCS San Raffaele Hospital, Milan Italy  
Dental School, Vita Salute San Raffaele University, Milan, Italy

**Aim:** Various treatment strategies and techniques have been proposed to perform alveolar bone augmentation; the most common of all is the split crest. In this study, we describe the indication for the bone augmentation techniques in order to optimize the regenerative bone conditions in a bone augmentation technique. In order to plan an intervention with crestal expansion technique it is essential to obtain as much information as possible regarding the actual structural characteristics of the bone residue, both qualitatively and quantitatively. It becomes necessary a presurgical study for three-dimensional evaluating regarding the amount and morphology of the residual ridge, the bone quality, and the relationship with the opposing arch and the prosthesis elements programmed. Objective examination and palpation of the edentulous areas, as well as the radiological study represent the most suitable diagnostic tools for obtaining a complete diagnosis of the bone segment to be expanded.

**Methods:** Cone Beam Computed Tomography is the most appropriate exam for the analysis radiographic investigation of the edentulous alveolar ridge. Thanks to the ridge expansion techniques is possible the dislocation of the buccal bone plate in a labial direction and simultaneous implant insertion in singlestage surgery, abbreviating overall treatment time. The piezoelectric ridge expansion technique permits to obtain the expansion of very mineralized bone crests without excessive traumas or the risk of ridge fractures. The fundamental idea on which is based the piezoelectric surgery is the use of a surgical force able to cut the bone according to the needs of the case. It transmits energy in a controllable way, it minimize the surgical trauma and the reduction of ridge's fracture risk, while stimulating a favorable response of tissue healing.

**Results:** In base of the result obtaining by the measurement and anatomical variations of CBCT it is possible determine the degree of surgical difficulty in each case and choose the most appropriate surgical technique. Through the analysis of cross-sectional images and their three-dimensional processing, is possible an accurate picture of the actual thickness of the atrophic ridge.

**Conclusion:** The split crest technique appears to be a promising and effective one to gain bone width. When the pre-surgical study by Cone Beam images shows a triangular shaped ridge, with vestibular cortical thin and poor cancellous bone density, surgical difficulty will be modest. It is not possible having predictable results by using the conventional mechanical method of expansion in front of the present of a very mineralized bone crest that is seen in the edentulous jaws of old date.

### **Aesthetic issues about the implant-prosthetic rehabilitation of the hard and soft tissues in case of agenesis of anterior teeth**

**Pittari L., Raimondi Lucchetti F., Tucci M., Gualandris A., Vinci R.**

Department of Dentistry, IRCCS San Raffaele Hospital, Milan Italy  
Dental School, Vita-Salute University, Milan, Italy  
Head: Prof. E. Gherlone

**Aim:** The post implant surgery evaluation of hard and soft tissues healing in patients with agenesis in maxillary aesthetic areas.

**Methods:** For this study were identified three patients with agenesis of the maxillary lateral incisors between the ages of 18 and 24 years in whom the correct useful space for an implant-prosthetic rehabilitation was kept or obtained orthodontically. In these patients an expansion of alveolar ridge technique was performed because of the vestibule-palatal deficits that often recurs in cases of agenesis. So, after a careful radiographic evaluation of the available mesio-distal and buccal-palatal spaces, the surgical approach has involved the design of a paracrestal flap with a primary palatal incision and a total thickness dissection. With a beaver and a firing pin it is provided to create a bone incision in order to insert scalpels of increasing thickness, until it had recreated a correct expansion of the alveolar process of the edentulous site. Then the surgical site was created using dedicated burs at low speed to avoid any fractures of the vestibular cortical bone. The site preparation was completed with the use of an osteotome. By setting implant motor at 20 rpm and a torque of 35 N implants BioSafin Winsix were placed with a diameter of: Case 1: Two 3.3 x 13mm TTX implants - Case 2: Two 3.3 x 13mm K implants - Case 3: a 3.3 x 13mm TTX implant. Immediately after placement the fixtures were provisionally prosthodontized with PMMA single crowns. We preferred to use screwed crowns in case 2 and 3 because, despite the higher cost, it's easier to manage any complications and they have an higher biocompatibility (operator dependent); in the case 1 we chose to cement the crowns for a particular inclination of the implants, due to the anatomy of the patient (which would not be easily managed with a screw technique). The finishing of provisional prosthetic element played an important role because a careful and meticulous polishing, especially in its transmucosal portion, allowed a drastic reduction of bacterial plaque film. In this way the maturation of the

peri-implant soft tissues was facilitated. In the early stages of tissue maturation it is unavoidable notice a tissue retraction that can cause imperfections which are being reduced thanks to the modeling of the resin provisional element emergence profile by the addition of composite resin. Another key element for proper healing was the occlusion of the provisional and the patient's motivation and its compliance about it (soft diet for the first few months). The healing of hard and soft tissues was assessed radiographically and clinically. Cases 1 and 2 were evaluated with followup at 3 months and the case 3 at one year.

**Results:** The healing of hard tissues and the correct conditioning of the soft ones was highlighted at 3 months. In case 3 specifically (at one year) it was possible to establish the correct integration of both bone and aesthetics of the implant.

**Conclusion:** The expected aesthetic result was reached by a correct implant placement and a proper prosthesis. A big advantage was given by the not functionalized (out of occlusion) immediate loaded implant because, compared to delayed technique, it gave aesthetic function and phonetics, managing immediately the soft tissues and avoiding orthodontics maintenance, without forgetting of the "positive psychological impact" on the patient.

### Implant prosthetic rehabilitation in HIV-positive patients: a comparison of two different implant surface roughness

Francia M.C., Galli S., Bova F., Ferrari Parabita S., Cappare P., Gherlone E.

Department of Dentistry, IRCCS San Raffaele Hospital, Milan, Italy  
Dental School, Vita-Salute San Raffaele University, Milan, Italy

**Aim:** The aim of this study is to compare the clinical and radiological outcome of implants with different surface roughness in HIV controlled patients.

**Methods:** Partially or completely edentulous HIV patients showing adherence to antiretroviral drug regimen and good oral hygiene that could benefit from implant prosthetic restorations were enrolled in the present study. Each patient received at least one dental implant and two different types of implant surfaces were compared: one group of implants had a higher roughness surface (Microrough surface MRS) and the other one was electrochemically treated, with low roughness surface (Full Contact Covering Surface FCC). The surgeon was blinded to the type of implant surface used. Depending on patient requirements, single implants or full arch rehabilitations, immediately loaded according to the "All on four" protocol, were performed. Re-entry procedures for healing abutment placement have been carried out for single implants at least after 50 days from implant placement. Follow-up visits were scheduled at 6 (T1) and 12 (T2) months after implant insertion and included both radiographic assessments of bone level around the implants and clinical parameters evaluation (plaque accumulation and bleeding index). Survival criteria for implant were presence of implant stability, absence of radiolucent zone around the implants, no mucosal suppuration, and no pain. One year follow-up after implant insertion was considered.

**Results:** Implants were placed in 59 patients and the overall number of fixture was 208. Twenty-six "All on four" complete-arch rehabilitations (104 fixtures) and 104 single implants were achieved. For single crowns and fixed partial dentures, definitive metal-ceramic restorations were cemented onto the definitive abutments. In the rehabilitations according to the "All-on-four" protocol, a screw-retained full-arch prosthesis was positioned few hours after surgery. Low incidence of complications and good survival rates with Marginal Bone Level (MBL) outcome were recorded after one year follow up. Mean marginal bone levels measured at T1 were 0.82 □} 0.21 mm for FCC implant surface and 0.90 □} 0.42 mm for MRS implant surface and at T2 were 0.89 □} 0.32 mm for FCC implant

surface and  $0.99 \pm 0.45$  mm for MRS implant surface. Not statistically significant differences were found between the two different implant surfaces ( $P > 0.05$ ). Implant failure occurred in 3 patients (6 fixtures out of 208): one patient developed early implant failure due to primary infection, the other two lost their implants due to peri-implantitis. The implant survival rate was 100% for FCC implants and 95,3% for MRS implants. In all cases an absence of fractures of the acrylic resin superstructure was found.

**Conclusion:** Within the limitations of the present study, due to the short follow-up and the number of implants, low roughness implant surface seems to be less susceptible to primary infection and peri-implantitis, in immunocompromised but immunologically stable patients, compared to microrough surface. However, not statistically differences were found and further studies are needed to investigate the correlation between implant surface roughness and survival rate in HIV positive patients.



### Survival rate of “all-on-four” rehabilitations in hiv-positive patients

**Galli S., Francia M.C., Rapanelli A., Bianchi S., Cappare P.**  
Department of Dentistry, I.R.C.C.S. San Raffaele, Milan  
Dental School, Vita-Salute University, Milan, Dean Prof. Gherlone

**Aim:** The aim of this study is to evaluate the survival rate of “All-on-four” rehabilitations in HIV-positive patients, recruited at San Luigi Center for Infective Disease, I.R.C.C.S. San Raffaele Hospital, Milan.

**Methods:** In this study 17 immunocompromised but immunologically stable patients were included. Patients were partial or total edentulous. All of them required an implant prosthetic restoration of one or both jaws. The “All-on-four” protocol was followed; 4 implants were placed in maxilla and/or mandible, 2 mesial implants placed axially and 2 distal implants placed tilted (from 30° to 45°). Pre-operative evaluation was both clinical and radiological. Each patient underwent implant placement and immediate loading in the same day, obtaining aesthetic and function. Implant insertion was considered with one year follow-up. Follow-up visits included radiographic assessment of bone level and clinical parameters and were performed at 6 and 12 months.

**Results:** Implants were placed in 17 patients, with a total amount of 104 implants. 6 patients received rehabilitation of both jaws, 2 patients were rehabilitated only in the mandible and 9 patients were rehabilitated in the upper jaw. Mean marginal bone levels (MBL) were recorded at 6 and 12 months. At 6 months the mean MBL in axial implants was 1.01 +/- 0.81 mm while in tilted implants was 1.23 +/- 0.32 mm; at 12 months the mean MBL was 1.17 +/- 0.43 mm in axial implants and 1.31 +/- 0.21 mm in tilted implants. Not statistically significant differences were

found between axial and tilted implants over time. An high long-term survival rate was achieved. Implant survival rate was 94,24%. Implant failure occurred in three patients, six months after the immediate loading. One patient lost all four implants, while the other two patients lost only ones, with a total amount of 6 implants failed. At a later time, all implants were re-placed. In comparison with previous studies a better survival rate and better marginal level were measured.

**Conclusion:** Within its limitations, this study shows that the “All-on-four” protocol represents a predictable treatment for the rehabilitation of completely edentulous jaws in HIV-positive patients. It shows the advantages in function and aesthetic for the immediate loading. Furthermore, patients have a higher degree of satisfaction compared to removal prosthesis. However, further studies are needed to analyze medium and long-term follow-up data.

**Oral rehabilitation of fully edentulous patients according to the “all on four” protocol at the Dental Clinic, Department of Dentistry, San Raffaele Hospital, Milan**

**Patianna G.P., Cardarelli A., Capparé P., Vinci R., Gherlone E.F.**

Department of Dentistry (Head: Prof. E. Gherlone), IRCCS San Raffaele Hospital, Milan, Italy  
Specialization School in Oral Surgery (Director: Prof. E. Gherlone), Faculty of Medicine and Surgery, Vita-Salute San Raffaele University, Milan, Italy

**Aim:** The aim of our study was to evaluate the survival rate of “All on four” rehabilitations in patients referred to the Dental Clinic of San Raffaele Hospital, Milan. This unit is aimed to devolve effective and efficient care for poorer and/or unhealthy social classes, ensuring quality service and excellence. In this context, Undergraduate and Postgraduate students have the opportunity to work safely, under the supervision of highly skilled doctors and tutors.

**Methods:** Fully edentulous patients or with a severely compromised natural dentition, as a consequence of deep caries or severe periodontitis, both in compromised and healthy conditions, requiring an implant prosthetic restoration of one or both of the jaws, were included in the present study. Each patient received at least one fixed full-arch maxillary rehabilitation. Four implants were placed in each jaw according to the “All on four” treatment concept: 2 mesial implants placed axially, 2 distal tilted implants to shorten cantilever. Immediate loading protocol was achieved in order to obtain immediate function and aesthetics on the same day of surgery. Follow-up controls were performed at 3 (T1) and 6 (T2) months after implant insertion and included both radiographic assessments of bone level around the implants and clinical parameters evaluation. According to Albrektsson & Sennerby, survival criteria for implants were the presence of implant stability, absence of radiolucent zone around the implants, absence of mucosal suppuration and no pain.

**Results:** Implants were placed in 11 patients and the overall number of complete-arch immediately loaded prostheses was 15 (60 implants). Four patients received rehabilitation of both jaws, four patients received a maxillary rehabilitation and three received a mandibular rehabilitation. Low incidence of complications and medium-term survival rates were recorded after six months of follow-up. Implant failure occurred in 1 patient (1 fixtures out of 60), and the implant survival rate was 98,4% (100% for axially

positioned implants and 96,8% for tilted implants).  
Prosthetic provisional failure occurred in 2 patients.  
**Conclusions:** Within the limitations of our report, the  
“All on four” treatment concept is a viable procedure  
for the rehabilitation of fully edentulous patients,  
showing the advantages of both the immediate loading,  
which allows immediate function and aesthetics, and  
the full-arch fixed prosthetic restoration, with a  
higher patient satisfaction compared to removable  
protheses. However, there is still a lack of consensus  
and long-term data in the modern literature; further  
studies with larger samples size and longer follow-up  
should be carried out to validate and strengthen our  
conclusions.

# Grande rialzo di seno mascellare

con l'utilizzo di Hypro-Oss e contestuale inserimento di impianti in una severa atrofia

Angelo Cardarelli\*, Filippo Cardarelli\*\*, Raffaele Vinci\*\*\*, Enrico F. Gherlone\*

\* DDS, Specialista in Chirurgia Odontostomatologica, Professore a Contratto e Consulente Scientifico, Unità di Chirurgia Orale Reparto di Odontoiatria, Università Vita Salute, IRCCS Ospedale San Raffaele, Milano.

\*\* DDS, Specialista in Ortogantodonzia, libero professionista, Isermia.

\*\*\* MD, DMD, MS, Professore Associato, Unità di Chirurgia Orale, Reparto di Odontoiatria, Università Vita Salute, IRCCS Ospedale San Raffaele, Milano.

\* MD, DMD, PhD, Professore Ordinario e Direttore, Reparto di Odontoiatria, Università Vita Salute, IRCCS Ospedale San Raffaele, Milano.

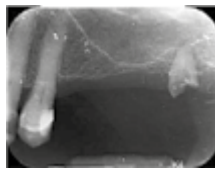


Fig. 1 - Rx endorale iniziale.

## Introduzione

Il riassorbimento osseo nel mascellare posteriore inizia con la malattia parodontale e continua con la perdita dei denti, che induce una diminuzione dell'ampiezza della cresta ossea a discapito della teca vestibolare<sup>1,2</sup>. Il seno mascellare attraversa tre fasi di espansioni fisiologiche, dal periodo prenatale fino ai 18 anni, la quarta espansione si verifica con la perdita dei denti posteriori. L'antro si espande sia lateralmente che inferiormente e la quantità di osso disponibile dal pavimento alla sommità della cresta ossea, diminuisce in altezza.

Nell'ambito della chirurgia del mascellare posteriore edentulo si colloca il sollevamento del seno mascellare, comunemente denominato rialzo del seno. Nel 1980 Boyne e James pubblicarono la tecnica del riempimento subantrale con osso autogeno. Nel 1984 Misch perfezionò questa tecnica sistematizzandone le indicazioni in rapporto all'osso disponibile in altezza al di sotto dell'antro<sup>4</sup>. Questa tecnica è ormai provata come altamente predicibile, a patto che ci sia una adeguata selezione dei pazienti, un training adeguato del chirurgo e anche una compliance del paziente<sup>5</sup>. La complicità intraoperatoria più frequente e comune è rappresentata dalla perforazione della membrana di Schneider, che può verificarsi durante l'osteotomia o durante lo scollamento della membrana. Complicanza invece a breve termine può essere la deiscenza della linea di incisione con possibilità di diffusione di infezioni all'innesto e perdita del biomateriale; le infezioni sono presenti in circa il 5% dei casi secondo Misch. Complicanze a lungo termine invece hanno una bassa incidenza, e sono circoscritte in genere a fistole oro-antrali<sup>6,7</sup>.

L'attuale classificazione (Consensus Conference 1996) identifica 4 classi in base all'altezza di osso residuo:

- Classe A: osso residuo >10 mm;
- Classe B: osso residuo 7-9 mm, rialzo per via crestale con inserimento contestuale di impianti;
- Classe C: osso residuo 4-6 mm, rialzo di seno per via laterale e

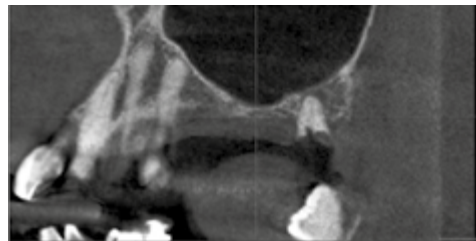


Fig. 2a - CBCT seno mascellare sinistro (Atrofia classe D).

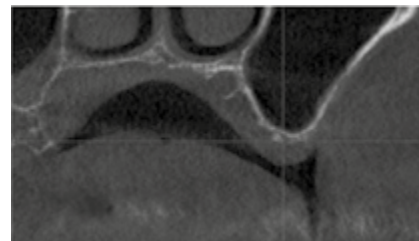


Fig. 2b - CBCT seno mascellare sinistro.

contestuale inserimento degli impianti;

- Classe D: osso residuo 1-3 mm, rialzo di seno per via laterale, posizionamento degli impianti tardivo a guarigione avvenuta.

## Case report

Nel caso descritto la pneumatizzazione del seno mascellare di sinistra ha ridotto notevolmente l'altezza ossea in posizione dei primi molari (classe D) tale da non permettere l'inserimento degli impianti se non con una terapia rigenerativa (Figg. 1-2b)

L'anamnesi negativa e l'assenza di abitudini viziate (fumo) ci ha fatto optare per il rialzo del seno per via laterale con contestuale inserimento degli impianti nonostante l'elevato grado di atrofia. Alla paziente è stata somministrata una profilassi antibiotica di 2 g di amoxicillina e acido clavulanico 1 ora prima della seduta operatoria. Previa infiltrazione plessica di soluzione anestetica contenente articaina 1:100.000 del secondo quadrante si procede all'avulsione del residuo radicolare del 2,7, si esegue un'incisione crestale con svincoli verticali di rilascio distale e mesiale per ottenere un lembo a tutto spessore esteso per visualizzare la proiezione del seno mascellare sulla superficie ossea vestibolare. Mediante terminale piezoelettrico si procede alla creazione della botola ossea, quindi si esegue lo scollamento e sollevamento della membrana sinusale, si preparano le

sedi implantari e si inseriscono due impianti in sede 2.5 (3,8x11TTI Biosafin Winsix) ed in sede 2.6 (3,8x9TTI Biosafin Winsix). La cavità sinusale pertanto viene riempita con una miscela di bone chips precedentemente prelevati dal pilastro zigomatico e biomateriale Hypross-Oss della Bioimplon Italia (osso bovino naturale costituito dal 70% di idrossiapatite e il 30% di atelocollagene di Tipo I). A protezione dell'innesto viene applicata una membrana riassorbibile di origine bovina Bioimplon Italia (Figg. 3-6).

Il lembo viene suturato con punti staccati in seta 4/0. Dopo 4 mesi dalla prima fase chirurgica, stabilizzati i tessuti e avvenuta l'osteointegrazione, si procede alla seconda

fase chirurgica con la riapertura degli impianti, quindi vengono prese le impronte e si procede alla realizzazione prima di un provvisorio, e successivamente di un ponte definitivo in metallo-ceramica cementato (Figg. 7-10).

## Conclusioni

La scelta di inserire contestualmente gli impianti, nonostante l'elevato grado di atrofia (classe D) e, quindi la scarsa disponibilità di osso residuo, ci ha permesso di ottenere una rigenerazione ossea migliore, rapida e stabile nel tempo, pertanto quando possibile e soprattutto se si ha la possibilità di ottenere la stabilità primaria degli impianti, questa scelta risulta essere la più predicibile.

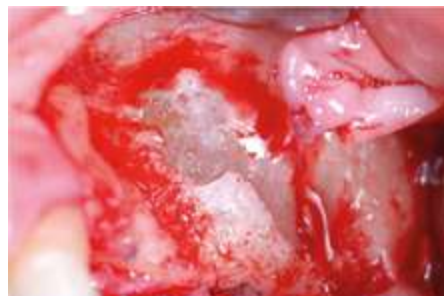

Fig. 3 - Scheletrizzazione ossea - Membrana di Schneider.

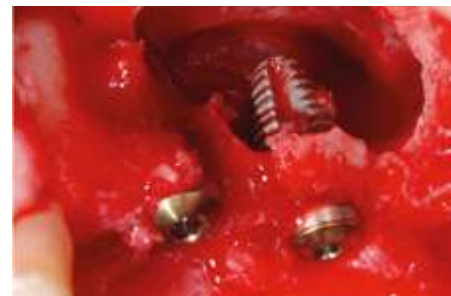

Fig. 4 - Elevazione membrana sinusale e contestuale inserimento degli impianti.

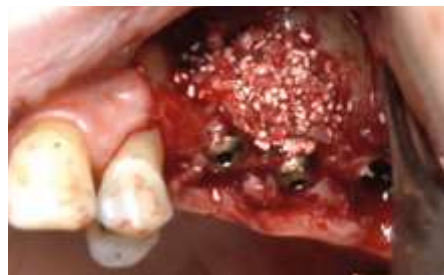

Fig. 5 - Riempimento con bone chips associato a Hypro-Oss Bioimplon Italia.




Fig. 6 - Rx post-operatoria.

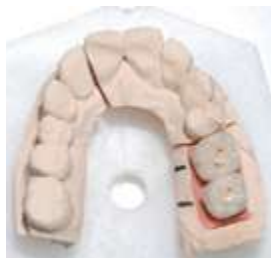

Fig. 7a - Manufatto protesico definitivo.

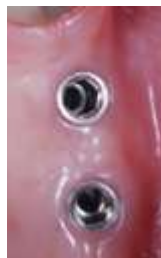

Fig. 7b - Guarigione a 4 mesi.

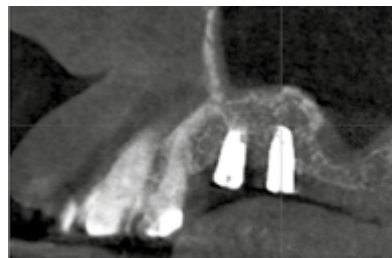


Fig. 8a, 8b - CBCT a 4 mesi dall'osteointegrazione.

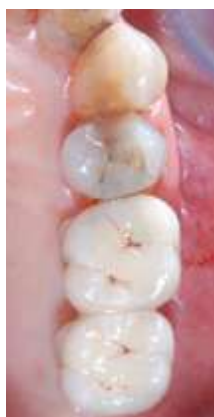

Fig. 9 - Finalizzazione protesica.

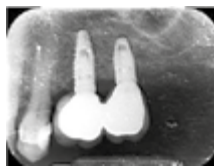

Fig. 10 - Rx finale.

**bibliografia**

- Schiegutz E, Kümmerer PW, Sigleb K, Wendt AJ, Pabst A, Al-Nawas B, Klein MO. Impact of maxillary sinus augmentation on oral health-related quality of life. *Int J Implant Dent.* 2017 Dec;3(1):0. doi: 10.1186/s40729-017-0072-8. Epub 2017 Mar 28.
- Zaniol T, Zaniol A. A Rational Approach to Sinus Augmentation: The Low Window Sinus Lift. *Case Rep Dent.* 2017;2017:610607. doi: 10.1155/2017/610607. Epub 2017 Feb 26.
- Timmenga NM, Baghoobar GM, van Weissenbruch R, Vissink A. Maxillary sinus floor elevation surgery. A clinical, radiographic and endoscopic evaluation. *Clin Oral Implants Res.* 2003 Jun;4(3):322-8.
- Timmenga NM, Baghoobar GM, Boering G, van Weissenbruch R. Maxillary sinus function after sinus lifts for the insertion of dental implants. *J Oral Maxillofac Surg.* 1997 Sep;55(9):936-9;discussion 940.
- Küçükkurt S, Alpaslan G, Kurt A. Biomechanical comparison of sinus floor elevation and alternative treatment methods for dental implant placement. *Comput Methods Biomech Biomed Eng.* 2017 Feb;20(3):284-295. doi:10.1080/10255842.2016.1218482. Epub 2016 Aug 8.
- Andreas Bassi M, Andrisani C, Lopez MA, Gaudio RM, Lombardo L, Lauritano D. Maxillary sinus by-pass with tilted implants via tapered-screw bone expanders in low density bone: one year follow-up of a case series. *J Biol Regul Homeost Agents.* 2016 Apr-Jun;50(2 Suppl 1):13-20.
- Chrcanovic BR, de Carvalho Machado V, Gjelvold B. Immediate implant placement in the posterior mandible: A cone beam computed tomography study. *Quintessence Int.* 2016;47(6):505-14. doi:10.3290/j.qia.56008.



L'obiettivo di Bioimplon è quello di sviluppare, produrre e commercializzare biomateriali di origine bovina come punta di diamante nella chirurgia dei tessuti molli e duri.

La nostra ampia gamma di prodotti copre:

il campo della rigenerazione ossea

il campo dei tessuti molli

la guarigione delle ferite per le applicazioni dentali, spinali, ortopediche e dermatologiche

I nostri prodotti sono utilizzati dagli odontoiatri e dai chirurghi maxillofacciali, in parodontologia e implantologia dentale, nonché dai chirurghi ortopedici.

**La sicurezza dei pazienti, la facilità d'uso, l'affidabilità e il risultato del trattamento sono la nostra priorità.**

I nostri prodotti hanno dimostrato il loro successo in sicurezza, efficacia, affidabilità e i risultati sono confermati dagli studi clinici e da casi documentati.

**Hipro-Oss® sostituto dell'osso di origine bovina con capacità osteoinduttive**

Recombinant human bone morphogenetic protein-2 (rhBMP-2) induces osteoblast differentiation when combined with demineralized freeze-dried bone allograft (DFDBA) or hydroxyapatite phosphor (HCP). [Biol Trace Elem Res](#) 1997; 137:1-11. [Schulze EP, Thoma V, Cantelmo LP, Hernandez BA, Miller SP. Clin Oral Implants Res](#)



**PRODOTTI BIOIMPLON**

I nostri prodotti sono utilizzati dagli odontoiatri e dai chirurghi maxillo facciali, in parodontologia e implantologia dentale, nonché dai chirurghi ortopedici.

**MALLIVENTO SRL**

IMPORTATORE IN ESCLUSIVA PER

ITALIA - SVIZZERA - FRANCIA

Via P. F. M. Grimaldi, 5 - 40122 Bologna (Italia)

Phone +39 051 524354

Mail [info@bioimplon.eu](mailto:info@bioimplon.eu)



## IMPLANT THERAPY IN PATIENT WITH SEVERE PERIODONTAL DISEASE

\* Angelo Cardarelli \*\* Filippo Cardarelli  
\*\*\* Michele Grechi \*\*\*\* Enrico Felice Gherlone

\* DDS, Specialist in Oral Surgery, Professor, Department of Dentistry, University Vita-Salute, IRCCS San Raffaele Hospital, Milan.

\*\* Private Practice, Isernia.

\*\*\* Professor, Department of Dentistry, University Vita-Salute, IRCCS San Raffaele Hospital, Milano

\*\*\*\* MD, DMD, PhD, Professor and Director, Department of Dentistry, University Vita-Salute, IRCCS San Raffaele Hospital, Milan

Address for correspondence:

Angelo Cardarelli

San Raffaele Dental Clinic Hospital Via Olgettina, 48 - Milano [angelo\\_cardarelli@libero.it](mailto:angelo_cardarelli@libero.it)

- Graduated with Lode in Dentistry and Dental Prosthetics at the University of L'Aquila in 2007.
- Specializing in Oral Surgery at the "Sapienza" University of Rome in 2010. He is a contract
- Professor and tutor at the San Raffaele University of Milan. He is a Scientific Advisor to the Dental
- Clinic at the Department of IRCCS San Raffaele in Milan (Dean Prof. E. Gherlone).
- He work in Milan and Isernia, where he practices Implantoprotesis and Oral Surgery. Author of many publications, Speaker in National Congresses on Implantology and Oral Surgery. Member of the San Raffaele Implant Implant Cultural Association, is part of the WINSIX® Pilot Center Teamwork and SIMO (Società Italiana Maxillo Odontostomatologica)



Angelo Cardarelli

### INTRODUCTION

Periodontitis is defined as an inflammatory disease of the supporting tissues of the tooth, caused especially by gram- negative bacteria, resulting in progressive destruction of the bone-supporting tissues of the tooth. The undeniable role of bacterial infection in the pathogenesis of the periodontitis is known to be accompanied by the individual's immune and inflammatory response under the influence of external, such as dental plaque, and internal factors. However, the dental plaques represent the main risk factors related to periodontitis occurrence and development.(1-2)

From the epidemiological point of view, there are an increasing proportion of adults

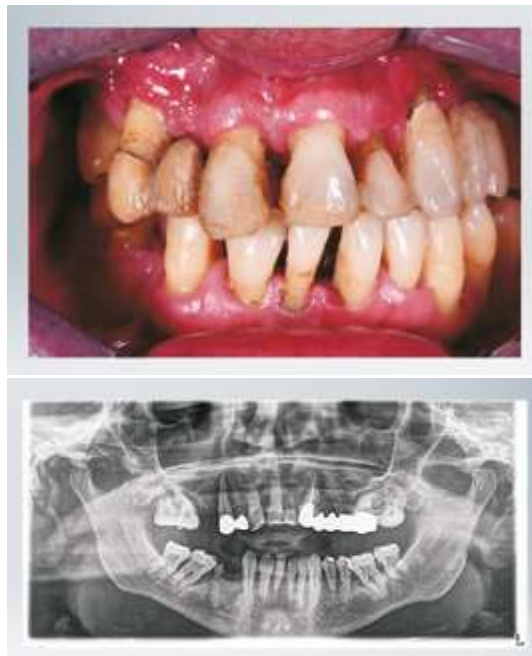
retaining their teeth until late in life, and, nowadays, periodontal disease is a serious problem in older adults. Moreover, the risk of the concomitants oral problems, such as root caries, tooth mobility, and tooth loss, can be increased by the presence of periodontal disease, which has also been associated with a growing list of chronic systemic diseases and impaired cognition .Dental implant science has rapidly moved into the mainstream of dentistry in the last 10 years with a phenomenal growth based on rapidly expanding technology, increasing public interest, and the reporting of sound scientific data. Indeed, dental implants have been widely used to retain and support cross-arch fixed dentures. However, biological complications, including peri-implant diseases (i.e., peri-implant mucositis and peri-

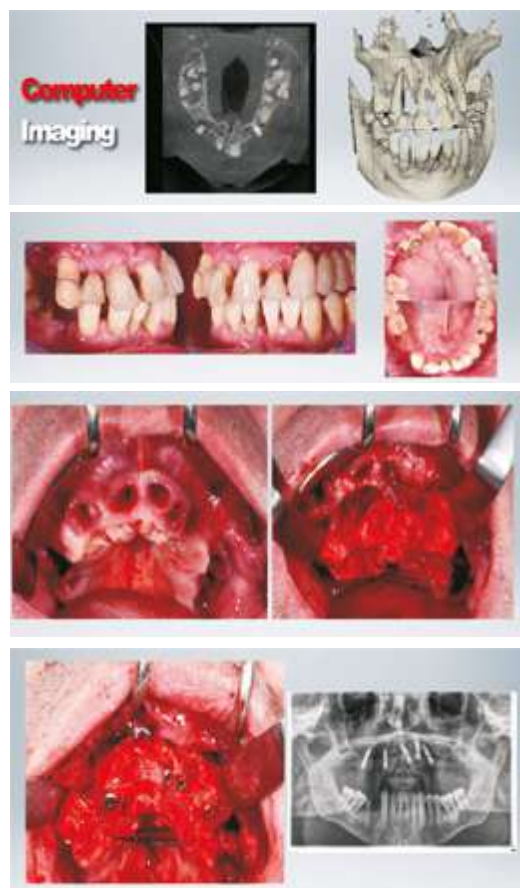


implantitis), along with technical complications, have emerged as follow-up periods have been extended.(3-4-5) Peri-implantitis was first defined as “inflammatory reactions with loss of supporting bone in the tissues surrounding a functioning implant” . The outcomes of various treatment approaches for peri-implantitis are not always successful or predictable . Moreover, alveolar bone defects around the implant destroyed by peri-implantitis cannot be regenerated in a reliable and predictable way, although various efforts to do so have been made over the last few decades . Hence, prevention of peri-mucositis, the precursor of peri-implantitis, has been suggested as the best approach to treat peri-implantitis . If an infection of supporting tissues around the implant cannot be properly controlled, it will eventually result in loss of the implant . According to another opinion, the significance of peri-implantitis is over-exaggerated. It has been suggested that most implants can function properly over long-term periods since bone loss around the implant does not continue in most cases.(6-7-8-9) In relation to population samples, ethnicity might affect the prevalence of peri-implantitis because the prevalence of periodontitis has been shown to be high in certain ethnic groups. Various risk factors for peri-implantitis have been evaluated in the literature . They are mainly categorized as implant- or patient-related factors and as systemic or local factors . Implant surface design, implant position and angulation, and prosthesis design in terms of performing plaque control have been suggested as implant-related/local factors while a history of periodontitis and smoking are the most frequently analyzed patient-related/ systemic factors associated with peri-implantitis . Like supportive periodontal therapy for the prevention of recurrent periodontal disease, regular maintenance therapy after implant placement has been emphasized as a way to prevent peri-implantitis periodontal therapy. (10-11)

### Case report

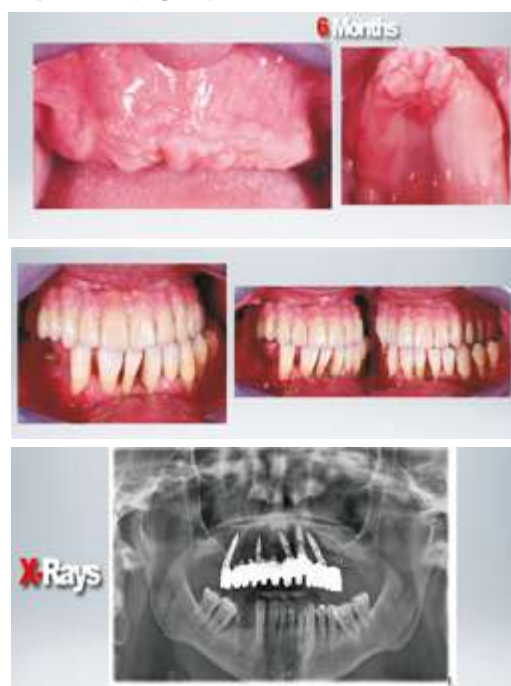A 57 year old man affected by severe periodontitis ,no smoker with no contra indication for dental implants Anatomic conditions and pathology of the jaws were evaluated by panoramic radiograph and cone beam CT which highlighted the serious impairment of all maxillary teeth with high mobility(Fig 1,2,3). So we decided to extract them all and insert 6 implants (Biosafin Winsix) that will support a fixed prosthesis placement. In the jaw ,however all teeth are kept after periodontal therapy and surgery was performed under local anesthesia after premedication with diazepam (0.2mg/kg) given orally 30 minutes before surgery.After crestal incision we reflected a full thickness flap. We extracted all teeth. removed necrotic tissues and all inflammatory residues. Then, the bone cavity was extended gradually, according to the intended implant diameter. Immediate loading was not done , but a temporary removable prosthesis was designed.





All the implants had a satisfactory primary stability.(Fig.4-5-6) The flap was sutured with suture points in 4/0 silk. Postoperative medications included antibiotics (1000mg amoxicillin and clavulanic acid twice daily for 7 days, starting on the day of surgery); an analgesic (600 mg ibuprofen as required every 6 hours); and 0.2% chlorhexidine mouthwash twice daily for 2 weeks, starting on the day after surgery. After 6 months to the healing of hard and soft tissues, a temporary followed by definitive fixed prosthesis was done . The patient was subjected to periodic controls and maintenance therapy every 3 months. At 12 months of follow-up, all the implants were considered to be successful, and it

does not show any sign of mucositis and peri-implantitis.(Fig7-8)



### CONCLUSIONS

Implant therapy in the periodontally compromised patient has a good predictability, The antibiotic therapy and the deletion of all inflammatory sites during open surgery could represent a fundamental step for bone regeneration and the implant stability. It is important for the long-term success to subject the patient to periodic and meticulous checks. every 3 months.

### BIBLIOGRAPHY

1. Dahlin C, Linde A, Gottlow J, Nymans :Healing of bone defects by guided tissue regeneration.Plast Reconstr Surg 1988;81:672-676
2. Dahlin C, GottlowJ, linde A, Nyman S. Healing of maxillary and mandibular bone defects

- using a membrane technique .An experimental study in monkeys. Stand J Plast Reconstr Surg 1990;24:13-19
3. Melcher AH, Dreyer CY. Protection of the blood clot in healing circumscribed bone defects J Bone Joint Surg 1962; 44B:424-430.
  4. Nevins M, Mellonig JT The advantages of localized ridge augmentation prior to implant placement: a staged event Int J Periodont Rest Dent 1994; 14:97-111
  5. Parma Benfenati S, Tinti C, Albreksson T, Johansson C. Histologic evaluation of guided vertical ridge augmentation around implants in humans Int J Periodontics Restorative Dent 1999;19:425-437
  6. Simion M, Trisi P, Piattelli A. Vertical ridge augmentation using a membrane technique associated with osseointegrated implants. Int J Periodontics Restorative Dent 1994;14:496-511
  7. Tinti C, Parma Benfenati S, Vertical Ridge augmentation: surgical protocol and retrospective evaluation of 48 consecutively inserted implants. Int J Periodontics Restorative Dent 1998;18:435-443
  8. Vanden Bogaerde L. A proposal for the classification of bony defects adjacent to dental implants, Int J Periodontics Restorative Dent 2004;24:26:264-271
  9. Nocini P.F, De Santis D. Nuove prospettive in Implanto-protesi e in chirurgia rigenerativa Quintessenza Edizioni
  10. Prevalence and risk indicators of peri-implantitis in Korean patients with a history of periodontal disease: a cross-sectional study Mi-Seon Goh, Eun-Jin Hong, Moontaek Chang J Periodontal Implant Sci. 2017 Aug;47(4):240-250
  11. Mandibular regeneration after immediate load dental implant in a periodontitis patient A clinical and ultrastructural case report Maurizio Catinari, MD, Manuel Scimeca, PhD, Massimo Amorosino, MD, Mario Marini, Doctor, Elena Bonanno, MD, PhD, Virginia Tancredi, MD Medicine (2017) 96:15(e6600)

## EVENTS

- **39<sup>th</sup> Asia-Pacific Dental and Oral Care Congress October 26-28, 2017 Osaka, Japan**
- **American World Dentistry November 13-14, 2017 San Antonio, USA**
- **27<sup>th</sup> Global Summit and Expo on Dental Marketing December 07-08, 2017 Madrid, Spain**
- **3<sup>rd</sup> Annual meeting of the International Academy for Digital Dental Medicine December 8-9, 2017, Marriott Hotel Berlin, Germany**

- 1 Pianificazione Implantoprotesica digitale.  
Progettazione e realizzazione di riabilitazioni "full arch" a carico immediato**  
M. Manacorda, R. Vinci, F. Bova, E. Gherlone  
Doctors Os Gennaio 2016 XXVII 01

---
- 2 Riabilitazione a carico immediato con numero ridotto di impianti**  
A. Cardarelli, F. Cardarelli, R. Vinci  
Doctor OS Marzo 2016 - XXVII 03

---
- 3 Sealing ability to Staphylococcus aureus of 4 different  
implant-abutment connections**  
E. F. Cagidiaco, G. Landini, L. Pallecchi, E. Gherlone, M. Ferrari  
Poster Collegio Dei Docenti - Aprile 2016

---
- 4 Combined microcomputer tomography, biomechanical and histomorphometric  
analysis of the peri-implant bone: a pilot study in minipig model**  
M. Gramanzini, S. Gargiulo, F. Zarone, R. Megna, A. Apicella, R. Aversa, M. Salvatore, M. Mancini, R. Sorrentino, A. Brunetti  
Dental Materials 32 ( 2016) 794-806

---
- 5 Riabilitazioni estetiche complesse: case report**  
A. Cardarelli, F. Cardarelli, R. Vinci, E. Gherlone  
Quintessenza Implantologia 2016 / numero 2

---
- 6 Studio clinico sulle riabilitazioni a ridotto numero di impianti solidarizzati  
a carico immediato**  
A. Cardarelli  
Doctors Os Settembre 2016 - XXVII 07

---
- 7 The "Alternating Osteotome Technique": a surgical approach for combined  
ridge expansion and sinus floor elevation. A multicentre prospective study  
with a three-year follow-up**  
L.Malchiodi, A.Cucchi, P. Ghensi, R.Caricasulo, P.F.Nocini  
Biotechnology & Biotechnological Equipment 09 June 2016, At: 09:16

---
- 8 A Prospective Longitudinal Study on Implant Prosthetic Rehabilitation in  
Controlled HIV-Positive Patients with 1-Year Follow-Up: The Role of CD4+  
Level, Smoking Habits, and Oral Hygiene.**  
E.F. Gherlone , P. Capparé , S. Tecco , E. Polizzi , G. Pantaleo , G. Gastaldi M.G. Grusovin.  
Clinical Implant Dentistry and Related Research, Volume 18, Number 5 -2016

---
- 9 Implant Prosthetic Rehabilitation in Controlled HIV-Positive Patients:  
A Prospective Longitudinal Study with 1-Year Follow-Up.**  
E.F. Gherlone , P. Capparé , S. Tecco , E. Polizzi , G. Pantaleo , G. Gastaldi , M.G. Grusovin .  
Clinical Implant Dentistry and Related Research, Volume 18, Number 4 -2016



## AGGIORNAMENTO PROFESSIONALE

## Pianificazione implantoprotesica digitale. Progettazione e realizzazione di riabilitazioni “full arch” a carico immediato

*Digital implant and prosthetic planning. An innovative procedure for immediate load, full arch rehabilitations*



micmanacorda@gmail.com



Pianificazione digitale, riabilitazione computer assistita, carico immediato, chirurgia protesicamente guidata, estetica facciale.

Digital planning, computer aided rehabilitation, immediate loading, prosthetic guided surgery face beautification.

## RIASSUNTO

In odontoiatria, la grande diffusione dell'esame CBCT rispetto alla TAC convenzionale nella diagnosi 3D della maggior parte dei pazienti è dovuta alla minore quantità di radiazioni cui viene sottoposto il paziente e alla maggiore semplicità di utilizzo. L'esame CBCT, inoltre, dà al medico l'opportunità di integrare la diagnosi bidimensionale standard con una ricostruzione digitale in 3D su cui pianificare gli impianti.

La progettazione implantoprotesica computer assistita permette contemporaneamente lo studio morfologico, funzionale ed estetico dei denti e delle ossa maxillofacciali, al fine di pianificare una protesizzazione dentoalveolare implantosupportata.

Nella letteratura scientifica si riscontrano differenti metodologie e software sviluppati per pianificare e realizzare guide chirurgiche e protesi provvisorie. Molti studi sono stati dedicati all'accuratezza delle diverse tecniche applicate alla chirurgia computer assistita.

La maggioranza delle tecniche per la progettazione digitale delle protesi si basa su tecnologie di alto livello, generalmente di proprietà delle aziende del settore. In questo modo, chirurgo e laboratorio hanno soltanto un controllo parziale sulla procedura completa.

Questo articolo descrive una procedura innovativa. Una metodologia basata sulle più avanzate tecnologie, sia per la progettazione che per la manifattura, ma che, a differenza di tutte le altre, può essere gestita in un flusso di lavoro ininterrotto tra il medico e il laboratorio. Nei paragrafi a seguire viene illustrata questa tecnica, con le sue applicazioni in casi chirurgici reali.

La realizzazione di estese riabilitazioni implantosupportate nel paziente edentulo richiede un approfondito iter diagnostico che comprende la tempistica d'intervento, la valutazione chirurgica

ca implantare e il progetto protesico, e che consideri anche il risultato estetico che spesso coinvolge tutto il distretto medio e inferiore del volto. Soprattutto nel protocollo riabilitativo a carico immediato, le fasi diagnostiche e di impostazione del piano di trattamento rivestono grande importanza. Per questo un'accurata analisi progettuale assistita da software diagnostici rappresenta oggi la soluzione più corretta e completa per la formulazione del progetto riabilitativo. Da tempo la pianificazione implantare può essere trasferita con precisione al piano terapeutico reale con l'implantologia computer assistita e oggi, grazie alla tecnologia CAD/CAM integrata nei software diagnostici, è possibile associare al progetto chirurgico anche la progettazione e la costruzione della protesi per il carico immediato delle fixture.

La grande diffusione degli esami tomografici volumetrici a fascio conico del distretto facciale (CBCT) è dovuta alla migliore completezza diagnostica che essi offrono rispetto agli esami radiografici bidimensionali. Grazie alla minore emissione di radiazioni rispetto alla tomografia assiale (MSCT), l'impiego della tecnologia CBCT offre all'odontoiatra l'opportunità di accedere più frequentemente a una visione tridimensionale del segmento scheletrico analizzato in fase prechirurgica (1). I dati DICOM ottenuti dalla CBCT vengono elaborati dai numerosi software diagnostici dedicati alla simulazione dell'intervento implantare (2). La pianificazione chirurgica virtuale viene trasferita “in vivo” grazie alla costruzione della dima chirurgica che guida fedelmente il posizionamento degli impianti, come da progetto, mediante l'intervento guidato con tecnica “flapless” mininvasiva (3). I moderni software di diagnostica e progettazione implantare possono inoltre sovrapporre le immagini DICOM alle scansio-



Michele Manacorda

Raffaele Vinci  
Francesco Bova  
Enrico Felice Gherlone

Università Vita-Salute  
San Raffaele, Milano  
Corso di Laurea  
Magistrale  
in Odontoiatria  
e Protesi Dentaria  
Presidente:  
professor E.F. Gherlone

IRCCS Ospedale  
San Raffaele, Milano  
Dipartimento di  
Odontoiatria  
San Raffaele  
Dental Clinic  
Direttore:  
professor E.F. Gherlone



## AGGIORNAMENTO PROFESSIONALE

ni ottiche dei modelli e delle protesi diagnostiche, integrando la programmazione chirurgica con il layout protesico. L'obiettivo è quindi l'integrazione del progetto implantare con il mock-up della protesi, al fine di definire non soltanto gli aspetti chirurgici, ma anche quelli funzionali ed estetici, propri delle riabilitazioni protesiche implantosupportate. Con la tecnologia CAD/CAM è possibile infine costruire il manufatto protesico identico al progetto digitale, comprensivo delle connessioni implantari: sul modello ottenuto dal progetto digitale si realizza il provvisorio per il carico immediato. Nel presente lavoro descriviamo un'innovativa procedura operativa che grazie alle opportunità offerte dalle tecnologie digitali e a un protocollo diagnostico terapeutico digitalizzato, integra l'implantologia computer assistita con la realizzazione di protesi precostruite per il carico implantare immediato.

### MATERIALI E METODI

Il metodo di lavoro proposto si prefigge come obiettivo di fornire un workflow diagnostico e terapeutico che utilizzi tecnologie digitali avanzate al fine di realizzare riabilitazioni protesiche a supporto implantare al contempo funzionali ed estetiche. Il protocollo è stato definito e denominato CAR (Computer Aided Rehabilitation) perché integra e completa il percorso progettuale caratteristico dell'implantologia computer assistita (CAI). La progettazione implantare virtuale è preceduta da un iter diagnostico esteso allo studio morfologico, funzionale ed estetico del terzo medio ed inferiore del volto, finalizzato alla corretta realizzazione di protesi ortopediche dento-alveolari a supporto implantare, necessarie soprattutto nei casi di edentulia atrofica associata a dismorfismo indotto. La CAR è in sintesi un protocollo integrato di elaborazione digitale della diagnostica radiologica e clinica finalizzata alla verifica di una corretta progettazione protesica nel rispetto delle funzioni orali e dell'estetica facciale (4).

In tabella 1 sono schematicamente riassunte le indagini cliniche e strumentali impiegate per la formulazione del progetto riabilitativo.

<b>Diagnostica clinica ed esame obiettivo</b>	Visita, anamnesi, esame obiettivo e facciale
<b>Diagnostica strumentale dell'occlusione</b>	Montaggio dei modelli in articolatore, valli di prova, protesi diagnostiche
<b>Diagnostica per immagini</b>	Ortopantomografia e tomografia computerizzata, teleradiografia latero-laterale (esame cefalometrico), fotografia clinica (esame cefalometrico delle parti mobili)
<b>Studio prechirurgico</b>	Dime radiologiche, dime chirurgiche, analisi della TC con software dedicati, programmazione degli impianti e della guida chirurgica tramite software (CAI), oggettivazione del risultato estetico e funzionale delle protesi diagnostiche (cefalometria 3D)
<b>Protesi</b>	Progettazione e realizzazione CAD/CAM della protesi a carico immediato

**Tab. 1**  
Schema procedurale delle fasi cliniche e strumentali.

La raccolta dei dati clinici e strumentali si arricchisce anche della diagnostica per immagini, finalizzata all'elaborazione digitale dei dati ottenuti. Una maggiore completezza diagnostica e la programmazione dell'intervento riabilitativo con le nuove tecnologie garantiscono la previsualizzazione del risultato clinico.

### Diagnostica e progettazione digitale

Il workflow proposto per il paziente edentulo o che necessita di una bonifica totale degli elementi dentari residui prevede come prima fase lo sviluppo di modelli studio tradizionali, montati in articolatore. Essi fungono da base per la costruzione di una protesi totale provvisoria diagnostica, che il paziente porterà fino al momento della chirurgia implantare. Il manufatto rimovibile deve contenere tutte le informazioni, funzionali ed estetiche, da trasferire alla protesi fissa implantosupportata, ed essere funzionalizzato. La congruità della protesi totale diagnostica deve essere verificata periodicamente, prima dell'esame CBCT. Deve essere stabile e se necessario ribasata per adattarsi all'atrofia dei tessuti ossei e al rimodellamento della mucosa nei casi di bonifica degli elementi naturali. In questa fase uno studio cefalometrico dei tessuti molli e scheletrici sulla teleradiografia latero-laterale permette di ricontrollare oggettivamente la correttezza di parametri fondamentali funzionali ed estetici, quali il riassetto delle dimensioni verticali, l'inclinazione del piano oc-

clusale, il montaggio dei denti e la risposta dei tessuti molli al nuovo sostegno del labbro (5, 6, 7) (figg. 1 e 2).

La protesi diagnostica, secondo la procedura RealGuide (3Diemme, Cantù, Italia) che di seguito andiamo a descrivere, serve inoltre da dima radiologica durante il successivo esame radiografico con apparecchiatura CBCT. La guida radiologica non necessita di elementi radiopachi, ma viene munita di un apposito repere extraorale (3DMarker) da includere nel volume durante la scansione tomografica (fig. 3). La presenza del 3DMarker è necessaria per il corretto posizionamento del layout protesico durante la successiva progettazione implantare virtuale (8).

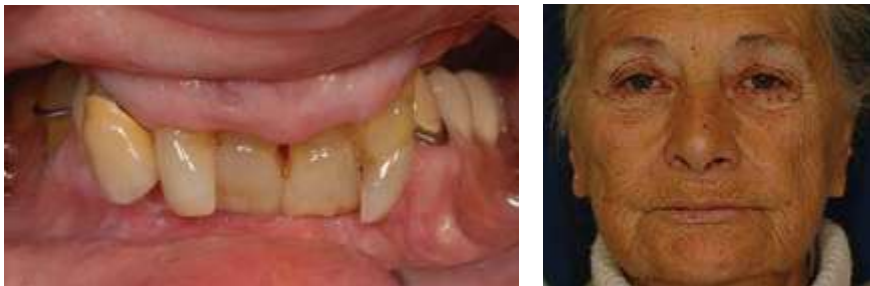Ottenuti i dati dalla TC a fascio conico in formato DICOM, questi vengono accoppiati con una procedura di best fit matching con la scansione ottica del modello e con la scansione della protesi diagnostica, effettuate con scanner da laboratorio (fig. 4). L'integrazione dei dati provenienti dall'esame radiografico e dalle scansioni ottiche fornisce una completa e accurata ricostruzione tridimensionale dell'anatomia del paziente visualizzabile attraverso il software di Imaging e progettazione implantare dedicato (3Diagnosis v4.1, 3Diemme, Cantù, Italia).

In ambiente virtuale, chirurgo e protesista completano la fase diagnostica e pianificano il posizionamento delle fixture.

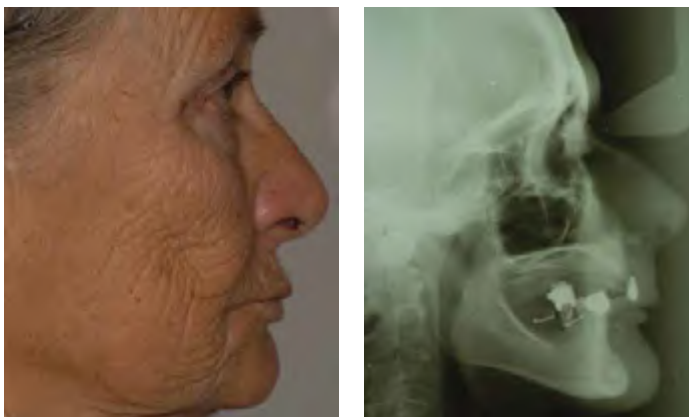Nel caso clinico descritto la scarsa quantità ossea residua ha indirizzato il chirur-



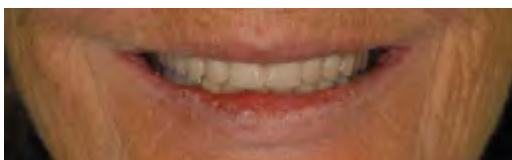## AGGIORNAMENTO PROFESSIONALE

**Figg. 1**

Nel caso esaminato, ove si rende necessaria la bonifica delle due arcate, si nota come lo studio prechirurgico sia indispensabile per ristabilire dimensione verticale, occlusione ed estetica estesa al terzo medio e inferiore del volto.

**Figg. 2**

Dopo la costruzione di due protesi totali diagnostiche postestrattive, e in attesa della guarigione dei tessuti, si valuta la congruità del nuovo piano occlusale, dell'estetica e dei parametri funzionali del progetto protesico programmato.

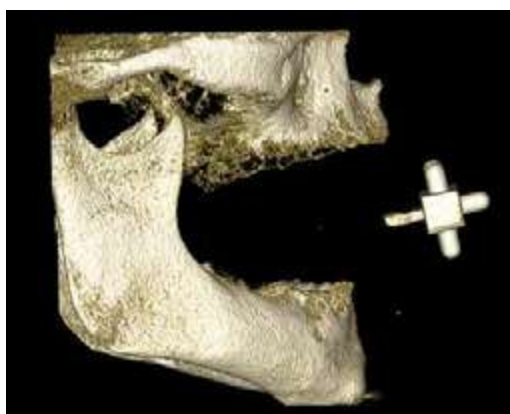

## AGGIORNAMENTO PROFESSIONALE

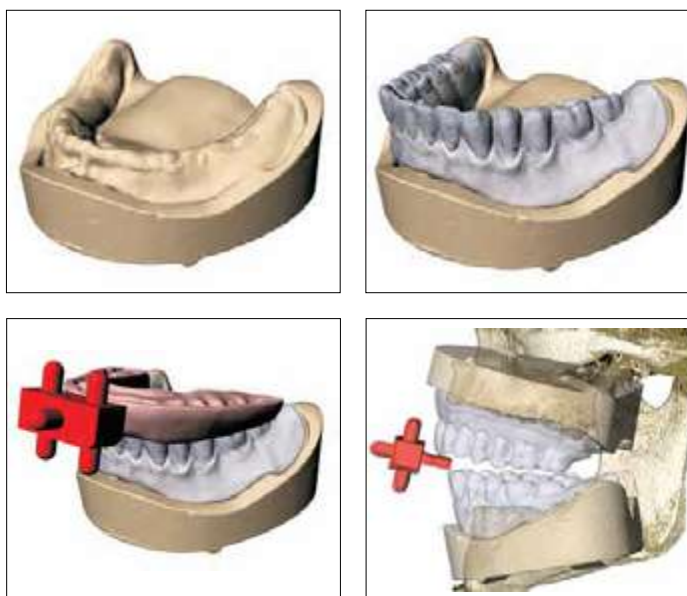go verso la scelta di un intervento implantare a numero ridotto di impianti, secondo la tecnica Just On Four mandibolare (Biosafin, Milano, Italia). Sono stati utilizzati quattro impianti Winsix TTx in posizione intraforaminale, dei quali i due distali inclinati di 30 gradi, per ridurre il cantilever protesico in zona molare, secondo una tecnica ormai consolidata (9). La presenza nelle librerie del programma dei modelli virtuali degli impianti e dei monconi protesici facilita ulteriormente il posizionamento delle connessioni protesiche. Il progetto non si limita al posizionamento spaziale degli impianti, ma si completa con la pianificazione delle connessioni protesiche e dei loro rapporti con la mucosa e la gengiva aderente. Tutta la progettazione è conseguente alla visualizzazione della futura struttura protesica sovrastante, per una pianificazione chirurgica realmente protesicamente guidata (fig. 5). Il progetto risultante viene quindi utilizzato per la modellazione virtuale automatica della guida chirurgica (PlastyCAD v1.5, 3Diemme, Cantù, Italia), realizzata con tecnologie CAD/CAM o di prototipazione rapida. Contemporaneamente è possibile importare il progetto digitale degli impianti, con l'aggiunta degli abutment prescelti virtualmente, in qualsiasi software aperto di progettazione protesica per la realizzazione della protesi provvisoria postchirurgica a carico immediato (fig. 6).

### Fase chirurgica

La fase chirurgica si realizza con il classico protocollo dell'implantologia mininvasiva, quindi con intervento flapless guidato dalla dima chirurgica. Il momento del posizionamento della dima è cruciale per il corretto posizionamento delle fixture, soprattutto nei casi di dime ad esclusivo appoggio mucoso. Come evidenziato in figura 7, la dima è inserita ad appoggio mucoso sull'arcata edentula e viene mantenuta in posizione dal paziente attraverso un vallo in silicone, denominato indice chirurgico, che riproduce fedelmente l'occlusione abituale. Questo metodo garantisce un appoggio mucoso uniforme della dima e riproduce la normale compressione della protesi diagnostica sulla mucosa resiliente. La base della dima infatti ripete esattamente



**Fig. 3**  
La ricostruzione 3D del massiccio facciale edentulo evidenzia la presenza del repere extraorale applicato alla protesi durante l'esame. L'anatomia chirurgica visualizzata attraverso l'elaborazione del software 3Diagnosys v4.1 (3Diemme, Italia) permette di realizzare con precisione il progetto implantare virtuale in 3D.

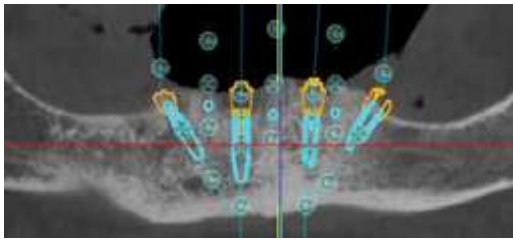


**Fig. 4**  
Le scansioni ottiche del modello e della protesi diagnostica, effettuate con il marker radiopaco, vengono inserite nel software di diagnosi e progettazione implantare, facilitando la progettazione e la scelta delle fixture e delle connessioni protesiche.

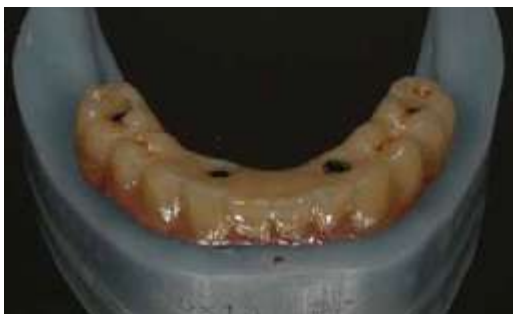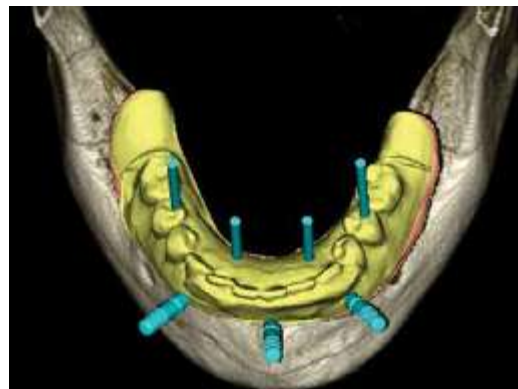
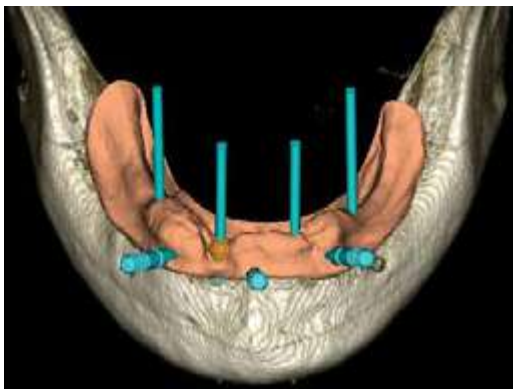
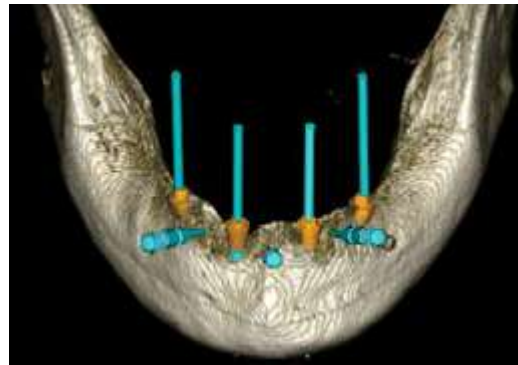
l'appoggio della protesi totale diagnostica, il suo posizionamento risulta essere corretto se la chiusura in abituale del paziente ne stabilisce posizione e compressione. In figura 8 è visibile un momento della fase chirurgica in cui il mounter guida con precisione l'inserimento implantare scorrendo all'interno del cilindro guida fissa-

to alla dima. Al termine della fase chirurgica si procede all'avvitamento dei cilindri per protesi avvitate sugli abutment. La fissazione del provvisorio pre-costruito sulle connessioni cilindriche avviene con cemento composito duale. Si ottiene così una connessione diretta e passiva del provvisorio agli abutment implantari, compensan-

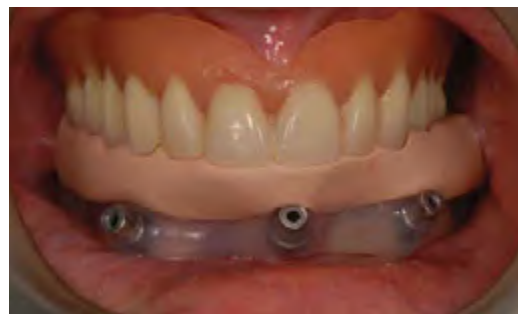## AGGIORNAMENTO PROFESSIONALE

**Fig. 5**

La pianificazione implantare vista in pseudopanoramica evidenzia la scelta chirurgica di una riabilitazione tipo Just On Four mandibolare. I due impianti "tiltati" distali e la loro emergenza in corrispondenza dei secondi premolari è visualizzabile in anteprima sul software di pianificazione che integra l'anatomia con il progetto protesico.

**Fig. 6**

Il provvisorio per il carico immediato realizzato sul modello stereolitografico è prodotto per fresatura dal pieno in CAD/CAM e poi rifinito e caratterizzato.

**Fig. 7**

Il posizionamento della dima chirurgica attraverso l'indice chirurgico in silicone. Prima di inserire i pin di fissazione progettati, il paziente tiene la dima in posizione con l'ausilio del vallo, facilitandone il posizionamento e la sua stabilizzazione corretta sulla mucosa resiliente.

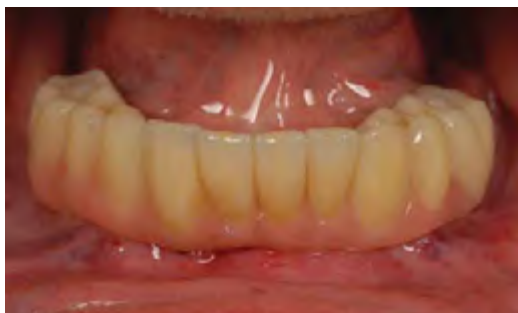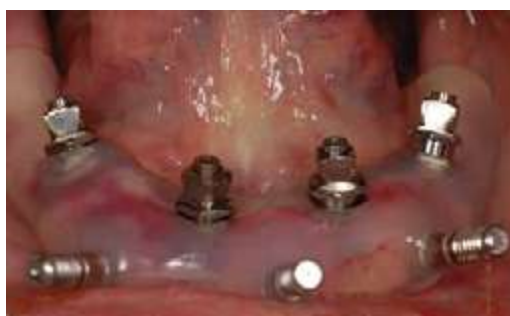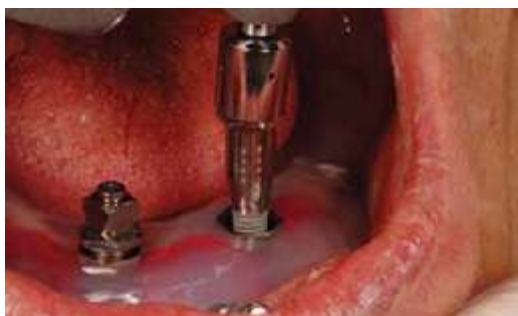do le discrepanze esistenti tra la posizione reale degli impianti e il loro posizionamento digitale (fig. 9).

**RISULTATI**

La corretta applicazione della metodica in

ogni sua fase, è fondamentale per ottenere risultati che siano predicibili e ripetibili. In ambito protesico è la correttezza della co-

## AGGIORNAMENTO PROFESSIONALE



**Figg. 8 e 9**

L'inserimento guidato degli impianti si effettua attraverso mounter dedicati. A fondo corsa i profili esagonali del mounter e del cilindro guida devono coincidere. In questo modo il montaggio degli abutment sull'esagono esterno degli impianti corrisponde a quanto progettato sul software di pianificazione. Al termine dell'intervento il posizionamento degli elementi protesici passivati e avvitati.

struzione della protesi diagnostica a garantire l'efficacia del provvisorio avvitato a carico immediato. Quest'ultimo infatti è costruito dal pieno via CAD/CAM dai dati della scansione ottica della diagnostica, non può quindi essere modificato dopo la sua fresatura. Un errore nella costruzione della protesi radiologica/diagnostica viene quindi trasferito in toto alla protesi postchirurgica creando un difetto di posizione, morfologico o estetico di non facile risoluzione. È per questo che spesso non si utilizzano le protesi preesistenti del paziente, se già portatore di protesi totale, spesso incongrue (10).

Il corretto posizionamento degli impianti attraverso la dima chirurgica è stata oggetto di molti studi e lavori scientifici che negli anni hanno valutato la fedeltà del posizionamento implantare al layout digitale e di conseguenza la validità della tecnica computer assistita (11, 12, 13, 14). Grazie all'evoluzione della tecnica costruttiva della dima, interamente digitale, e alla sua stabilizzazione, oltre alla riduzione delle tolleranze della componentistica per la chirurgia guidata e alla fedeltà delle immagini tridimensionali delle scan-

sioni ottenute dalla CBTC, siamo in grado oggi di garantire elevati livelli di accuratezza. Lo scostamento del posizionamento implantare rispetto al progetto è quasi sempre submillimetrico, sia la deviazione angolare che lo scostamento lineare degli impianti ci permettono di operare con tranquillità anche con tecnica flapless. Già in fase progettuale consideriamo l'eventuale margine medio di errore, operando in sicurezza. In tabella 2 sono riportati i dati di accuratezza del caso presentato raccolti mediante sovrapposizione digitale della CBTC del progetto e di uno stesso esame effettuato postchirurgico per il controllo radiologico delle fixture. I risultati sono molto confortanti e ripetuti in tutti i casi trattati (tab. 2).

### DISCUSSIONE

Il metodo proposto ha lo scopo di dimostrare come in odontoiatria un flusso di lavoro altamente informatizzato possa essere impiegato per la progettazione e la realizzazione delle riabilitazioni protesiche fisse a supporto implantare. Il protocollo CAR è inno-

vativo dal punto di vista diagnostico e della funzionalità chirurgica, sfrutta al massimo la reale disponibilità ossea tenendo presenti le necessità protesiche, funzionali ed estetiche. Un ulteriore vantaggio della metodica risiede nella velocità di intervento, poiché dopo la fase chirurgica non occorre rilevare le impronte avendo già a disposizione la protesi provvisoria realizzata con tecnica di fresaggio da scansione della protesi diagnostica e adattata alle connessioni implantari sul modello stereolitografico (15). L'utilizzo di un sistema digitale "aperto" consente inoltre l'interazione tra diversi software e la realizzazione dei manufatti con qualsiasi piattaforma CAD/CAM o macchina RP (prototipazione rapida).

L'implantologia computer assistita si serve di programmi non solo dedicati alla progettazione delle fixture, ma anche della protesi post chirurgica. Il progetto protesico, oltre a guidare la posizione implantare, viene inviato ad apparecchiature CAD/CAM per la sua realizzazione stereolitografica. Con l'impiego di un solo software si possono quindi progettare sia la dima chirurgi-

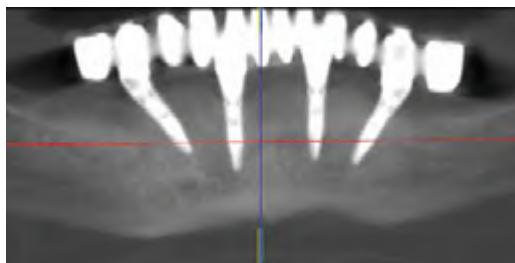


## AGGIORNAMENTO PROFESSIONALE

ARCATA	IMPIANTO	DIFFERENZA APICE mm				DIFFERENZA TESTA mm				DIFFERENZA ANGOLO °
		Xs	Ys	Zs	S	Xv	Yv	Zv	V	
inferiore/ appoggio mucoso	32	0,16	-0,25	1,44	1,47	0,050	-0,320	1,130	1,18	3,36
	34	0,89	-0,11	0,55	1,05	-0,070	-0,170	0,200	0,27	3,72
	42	-0,73	0,5	0,26	0,92	-0,090	-0,050	0,060	0,12	2,29
	44	-0,23	-0,01	0,26	0,35	-0,520	-0,050	0,180	0,58	1,44

**Tab. 2**

Misurazione dell'accuratezza nel posizionamento delle fixture. Il matching delle due TC permette di valutare il misfitting degli impianti inseriti con la ditta chirurgica rispetto alla posizione programmata nel software. Scostamenti angolari al di sotto dei 4 gradi e deviazioni lineari non superiori al millimetro sono da considerarsi risultati molto incoraggianti.

**Fig.10**

CBCT di controllo dopo sei mesi dal carico e dopo la realizzazione del manufatto protesico definitivo, cui sono stati aggiunti due elementi in estensione distali.

ca per l'intervento flapless mininvasivo, sia la struttura protesica provvisoria, che viene realizzata prima dell'intervento chirurgico. L'efficacia a distanza del carico immediato è riportata da studi retrospettivi che riportano dati di efficacia molto confortanti (18). Per verificare l'accuratezza della procedura sono stati proposti differenti metodi di valutazione (16, 19). L'indagine radiografica tomografica di controllo, necessaria dopo l'inserimento implantare, può essere utilizzata per calcolare il grado di precisione della sistemazione. Viene eseguita perciò una CBCT di controllo con la quale si valutano tridimensionalmente il posizionamento implantare e la guarigione dei tessuti (fig. 10). Sovrapponendo il file dell'indagine volumetrica di controllo a quello del progetto implantare digitale è quindi possibile misurare con precisione la discrepanza di posizione di ogni singolo impianto. Vengono normalmente misurati lo scostamento angolare lungo l'asse maggiore delle fixture e le distanze lineari sia all'apice che al colletto degli impianti. La media dei risultati ottenuti indica il grado di precisione della metodica. Il livello medio di accuratezza del posizionamento degli impianti rispetto al progetto nel caso trattato è più

che soddisfacente, se la si confronta con i valori riportati nelle revisioni sistematiche in letteratura (17). Ciò significa che la procedura clinica, la componentistica hardware e il software, se utilizzati secondo precisi protocolli, portano a risultati più che soddisfacenti.

**CONCLUSIONI**

Il protocollo CAR può rappresentare un approccio clinico alla soluzione dell'edentulia di una o entrambe le arcate nel paziente edentulo anche in presenza di importanti atrofie ossee. Esso consente la previsualizzazione in digitale della riabilitazione implantoprotetica che si intende eseguire e del rapporto tra le posizioni spaziali di fixture e sovrastrutture protesiche, con un livello di precisione nelle tre dimensioni clinicamente accettabile e comunque tale da permettere al clinico di giungere, a conclusione del percorso diagnostico iniziale, ad un progetto riabilitativo che tenga conto delle quote ossee utilizzabili, e delle proprietà del manufatto protesico a carico immediato quale mezzo per il ripristino funzionale ed estetico dell'apparato masticatorio. ●

**ABSTRACT**

Lower radiation exposure and simpler application of CBCT exam versus conventional CT for 3D diagnosis resulted in its great diffusion in dentistry. Moreover, CBCT exam offers the possibility to integrate standard bidimensional diagnosis with digital 3D reconstructions on which an implant planning is based.

Computer-assisted implant prosthetic planning allows the morphological, functional and aesthetic study of teeth and maxillofacial bones, necessary for the planning of implant-supported dentoalveolar prosthesis. Literature reports many different methods and softwares developed for planning and manufacturing surgical guides and provisional prosthesis. Many studies also focus on the accuracy of different techniques for computer guided surgery.

Most digital techniques for prosthetic planning are based on computer programs generally owned by manufacturers, and surgeons and laboratories have just a partial control over the full process.

This article describes an innovative procedure, a method based on the most advanced technologies both for planning and manufacturing, but that unlike other ones can be fully managed as a workflow between the surgeon and the laboratory. In this article this technique is illustrated, together with its application on real surgical cases.

## AGGIORNAMENTO PROFESSIONALE

### BIBLIOGRAFIA

- Ludlow JB, Ivanovic M. Comparative dosimetry of dental CBCT devices and 64 slices CT for oral and maxillofacial radiology. *Oral Surgery, Oral Medicine, Oral Pathology, Oral Radiology and Endodontology* 106:106-114 (2008)
- Neugebauer J, Stachulla G, Ritter L, Dreiseidler T, Mischkowsky RA, Keeve E., Zoller JE. Computer-aided manufacturing technologies for guided implant placement. *Expert Review of Medical Devices* 7:113-129 (2010)
- Gherlone E.: Riabilitazioni implantoprotesiche e Chirurgia minimamente invasiva. 2013 Ariesdue Ed. (CO) Italy. Cap 9. 189-213.
- Manacorda M, Vinci R, Bova F, Nagni M, Gherlone E.: Riabilitazione dei mascellari edentuli: presentazione di una nuova tecnica software assistita. *Doctor Os*, Vol. XXIV - maggio 2013
- Arnett G.W.: Mc Laughlin R.P. Facial and Dentofacial Planning for Orthodontists and Oral Surgeons. St Louis (Mo): Mosby, Elsevier 2004
- G. Perrotti, L. De Vecchi, T.Weinstein. A. Motroni, T. Testori, M. Del Fabbro: La teleradiografia latero-laterale in implantologia e riabilitazione orale: dall'analisi bidimensionale alla diagnostica 3D. *Dental Cadmos* Giugno 2010. (78-88)
- Sutton DN, Lewis BR, Patel M, Cawood JI.: Changes in facial form relative to progressive atrophy of the edentulous jaws. *Int J Oral Maxillofac Surg.* 2004 Oct; vol. 33 pp. 676-82.
- Russig LL, Schultze R.K.W.: Effects of minute misregistrations of prefabricated markers for image-guided dental implant surgery: an analytical evaluation. *Clin. Oral Impl.m Res.* 24,2013, 1339-1346
- Maio P, De Araujo,Nobre M, Lopes A. The use of computer-guided flapless implant surgery and four implants placed in immediate function to support a fixed denture: preliminary results after a mean follow-up period of thirteen months. *J Prosthet Dent.* 2007 Jun;97(6 Suppl):S26-34.
- Yalçın Çiftçi, İken Kocadereli, enay Canay, Pınar enyılmaz.: Cephalometric Evaluation of Maxillomandibular Relationships in Patients Wearing Complete Dentures: The Angle Orthodontist: September 2005, Vol. 75, No. 5, pp. 821-825
- Van Assche N, Van Steenberghe D, Quirynen M, Jacobs R.: Accuracy assessment of computer-assisted flapless implant placement in partial edentulism. *J ClinPeriodontol* 2010 Apr; 37(4):398-403.
- Neugebauer J, Stachulla G, Ritter L, Dreiseidler T, Mischkowsky R.A., Keeve E., Zoller J.E.: Computer-aided manufacturing technologies for guided implant placement. *Expert Review of Medical Devices* 7:113-129 (2010)
- Al Harbi SA, Sun AY. Implant placement accuracy when using stereolithographic template as a surgical guide: preliminary results. *Implant Dent.* 2009 Feb;18(1):46-56.
- Ozan O, Turkyilmaz I, Ersoy AE, McGlumphy EA, Rosenstiel SF.:Clinical accuracy of 3 different types of computed tomography-derived stereolithographic surgical guides in implant placement. *J Oral Maxillofac Surg.* 2009 Feb;67(2):394-401
- Sanna AM, Molly L, Van Steenberghe D.: Immediately loaded CAD-CAM manufactured fixed complete dentures using flapless implant placement procedures: a cohort study of consecutive patients.. *J Prosthet Dent.* 2007 Jun; 97(6):331-9.
- Jung RE, Schneider D, Ganeles J, Wismeijer D, Zwahlen M, Hämmerle CH, Tahmaseb A. Computer technology applications in surgical implant dentistry: a systematic review. *Int J Oral Maxillofac Implants.* 2009;24 Suppl:92-109.
- Schneider D, Marquardt P, Zwahlen M, Jung RE.:A systematic review on the accuracy and the clinical outcome of computer-guided template-based implant dentistry. *Clin Oral Implants Res.* 2009 Sep;20 Suppl 4:73-86.
- S. M. Meloni, G. de Riu, M. Pisano, G. Cattina, and A. Tullio, "Implant treatment software planning and guided flapless surgery with immediate provisional prosthesis delivery in the fully edentulous maxilla. A retrospective analysis of 15 consecutively treated patients," *European Journal of Oral Implantology*, vol. 3, no. 3, pp. 245-251, 2010.
- S. Platzer, G. Bertha, A. Heschl, W. A. Wegscheider, and M. Lorenzoni, "Three-dimensional accuracy of guided implant placement: indirect assessment of clinical outcomes," *Journal of Oral andMaxillofacial Surgery*, vol. 67, no. 2, pp. 394-401, 2009.





CASO CLINICO DEL MESE

# Riabilitazione a carico immediato con numero ridotto di impianti

✉ angelo\_cardarelli@libero.it

Angelo Cardarelli  
Filippo Cardarelli  
Raffaele Vinci

Università Vita-Salute San Raffaele, Milano; Corso di Laurea Magistrale in Odontoiatria e Protesi Dentaria  
Presidente: Prof. E.F. Gherlone  
IRCCS Ospedale San Raffaele, Milano Dipartimento di Odontoiatria  
Direttore: Prof. E.F. Gherlone



**FIG. 1**  
Ortopanoramica iniziale.

**FIG. 2**  
Situazione clinica iniziale: visione extraorale.

**FIG. 3**  
Situazione clinica iniziale: visione occlusale.

**FIG. 4**  
Situazione clinica iniziale: visione frontale.

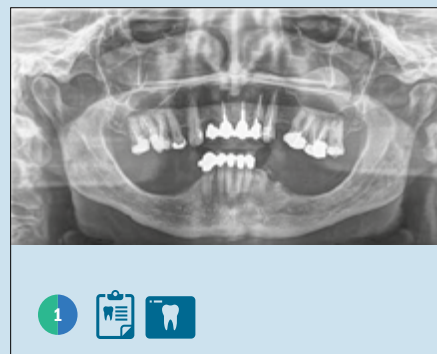


**FIG. 5**  
Avulsione degli elementi dentari e scheletrizzazione ossea.

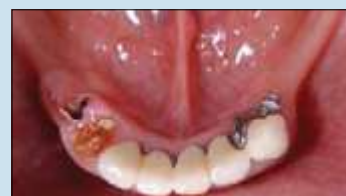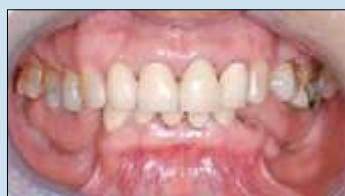**FIG. 6**  
Isolamento dei nervi mentonieri.

**FIG. 7**  
Osteotomia ed applicazione della Just-Guide.

Il presente caso clinico descrive la riabilitazione implantoprotesica a carico immediato secondo la metodica "Just On 4" che ha permesso alla paziente di ottenere sin da subito una protesi provvisoria avvitata garantendo funzionalità ed estetica immediata. In considerazione delle attuali condizioni socio-economiche, è oggi importante potere offrire ai pazienti completamente o parzialmente edentuli delle possibilità di trattamento che siano sostenibili dal punto di vista economico e biologico.



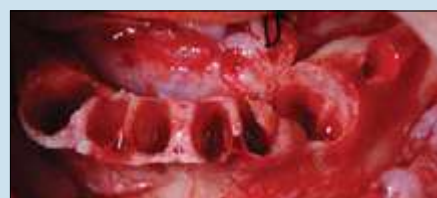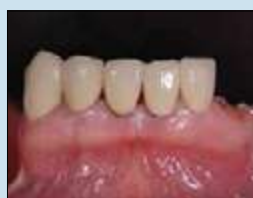diagnosi  
%  
**IMG**  
14%



studio  
%  
**IMG**  
14%

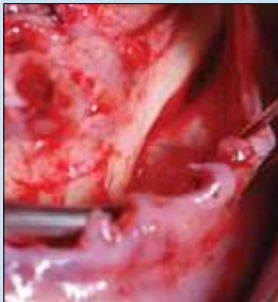

trattamento  
%  
**IMG**  
59%

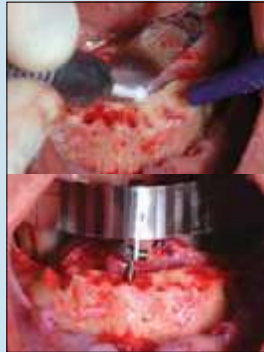

controllo  
%  
**IMG**  
14%

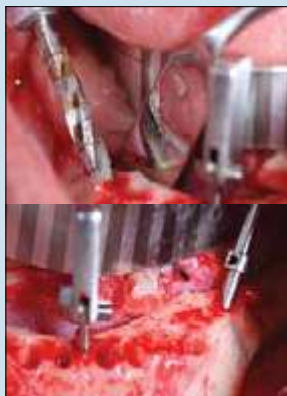
CASO CLINICO DEL MESE



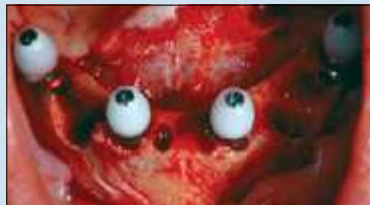6



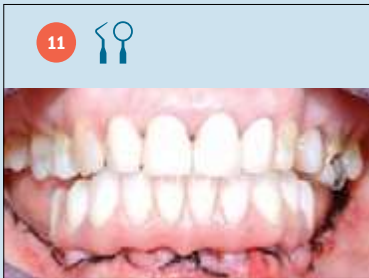
7



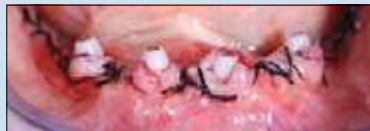8



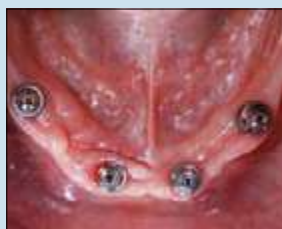9



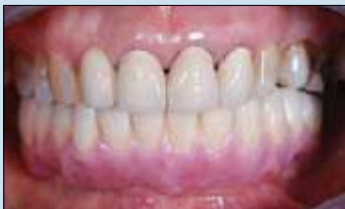11



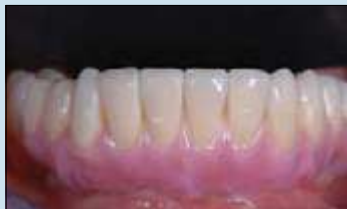10



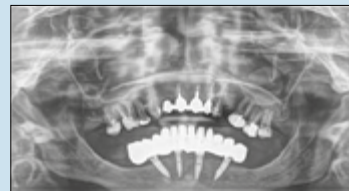12



13



14



15

**FIG. 8**  
Inserimento degli impianti distali con un angolazione di 30°.

**FIG. 9**  
Impianti inseriti secondo la metodica Just On 4.

**FIG. 10**  
Sutura dei lembi.

**FIG. 11**  
Provvisorio con carico immediato.

**FIG. 12**  
Guarigione dei tessuti a quattro mesi dal carico.

**FIG. 13**  
Finalizzazione protesica.



**FIG. 14**  
Situazione clinica finale.

**FIG. 15**  
Ortopanoramica finale.

## Sealing ability to *Staphylococcus aureus* of 4 different implant-abutment connections

Edoardo Ferrari Cagidiaco<sup>1</sup>, Giulia Landini<sup>2</sup>, Lucia Pallecchi<sup>2</sup>, Enrico Felice Gherlone<sup>1</sup> Marco Ferrari<sup>2</sup>

<sup>1</sup> Università Vita-Salute San Raffaele  
Corso di Laurea in Odontoiatria e Protesi Dentaria  
Presidente Prof. E. Gherlone



<sup>2</sup> Università di Siena  
Corso di Laurea in Odontoiatria e Protesi Dentaria  
Coordinatore Prof. Marco Ferrari

**SCOPI:** Il presente studio ha avuto come scopo del lavoro di testare la capacità di sigillo allo *Staphylococcus aureus* di 4 differenti tipi di connessione impianto-moncone.

L'ipotesi nulla testata era che vi sarebbe differenza riguardo la capacità di sigillo della connessione tra i 4 gruppi testati.

### MATERIALI E METODI:

Quattro diversi tipi di impianti disponibili sul mercato sono stati utilizzati per indagare il grado di micro-infiltrazione della connessione impianto-monconi (CIA)(Fig.1): Gruppo 1: Torque Type conical implant a doppia connessione conica – TTc (Winsix, BioSAFin, Ancona, Italy); Gruppo 2: Torque Type conical implant con connessione cone morse – TTcm (Winsix, BioSAFin); Gruppo 3: K type implant con connessione esagonale interna (Winsix, BioSAFin); Gruppo 4: OsseoSpeed, quale controllo, a connessione conica interna (Astra Tech, Molndal, Sweden). Dieci impianti per gruppo sono stati testati. I monconi sono stati connessi agli impianti seguendo le indicazioni della casa. Tutte le procedure di connessione e/o disconnessione dei monconi dagli impianti sono state eseguite in condizioni di sterilità, in una cappa laminare a flusso biologico.

*Staphylococcus aureus* ATCC 6538, è stato scelto per testare il grado di micro-infiltrazione biologica. Infatti, lo *S. aureus* può colonizzare gli impianti in fase precoce può essere responsabile di peri-implantite. system (bioMeriëux Inc., Marcy l'Étoile, France). Dopo 72 ore di incubazione, gli impianti sono



Fig. 1 I quattro tipi di impianti testati

stati rimossi dall'ultimo terreno di cultura e processati riguardo il passaggio dei batteri che erano stati inoculati nel loro interno prima che la connessione fosse serrata. A questo scopo dopo aver rimosso la connessione dagli impianti, attraverso una soluzione salina sterile di 5 µl were i batteri inoculati sono stati recuperati e portati in un altro terreno di cultura per confermarne la vitalità ed identificarli.

I risultati sono stati quindi valutati statisticamente. L'analisi statistica è stata eseguita per identificare eventuali differenze statisticamente significative tra i quattro gruppi riguardo la capacità di sigillo delle connessioni impianto-moncone testate

Type of implant (brand)	Total N.	Microleakage	Absence of microleakage + bacterial viability	Contamination
TTc (BioSAFin)	9	2	7	0
TTcm (BioSAFin)	9	0	7	0
K (BioSAFin)	9	1	7	0
Osseospeed (AstraTech)	9	0	1	1
Total	36	3	22	1

### RISULTATI:

**Risultati** - Un impianto del gruppo controllo (Astra Tech) è stato escluso dallo studio in quanto vi era stato uno sviluppo batterico di contaminante nei tre terreni di cultura dopo 48 ore (i.e. *Paenibacillus pabuli*, environmental Gram-positive bacteria) (Table 1). I terreni cultura 1 e 2 (i.e. i terreni di cultura 1 e 2 erano dove i campioni erano passati prima di essere collocati nel terreno finale C) di tutti gli altri campioni (n = 35) sono rimasti sterili fino a 72 ore dall'inoculazione, indicando l'assenza di contaminazione esterna a livello della connessione impianto-moncone (Tavola 1). Similmente, nessuna crescita batterica è stata osservata nei 4 controlli negativi (1 impianto per ogni tipo di impianto), che erano stati inoculati con soluzione salina sterile.

Infiltrazione batterica è stata dimostrata in tre campioni (i.e. 3 di 35, 9%), comprendendo due TTc ed 1 K, che hanno mostrato crescita di *S. aureus* nel terreno di cultura C dopo 48 ore di incubazione (Tavola 1). Nessuna differenza statisticamente significativa è stata riscontrata ( $p > 0.05$ ). L'ipotesi nulla è quindi stata rigettata.

### CONCLUSIONI:

I quattro gruppi testati hanno mostrato una alta capacità di sigillo a livello della connessione impianto-moncone; sicuramente il livello di ermetici a livello della connessione impianto-moncone può essere considerata accettabile clinicamente. I tre impianti testati si sono mostrati a livello dell'impianto controllo riguardo al gradi di ermeticità della connessione impianto-moncone.

e-mail: edoardo.ferrari.cagidiaco@gmail.com

### BIBLIOGRAFIA

- Vandeweghe S, Vervack V, Vanhove C, Dierens M, Jimbo R, De Bruyn H. Accuracy of optical dental digitizers: an in vitro study. Int J Periodontics Restorative Dent 2015;35:115-21
- Penarrocha-Oltra D, et al., Microbial Leakage at the Implant-Abutment Connection Due to Implant Insertion Maneuvers: Cross-Sectional Study 5 Years Postloading in Healthy Patients. J Oral Implant 2015; e292-98
- Canullo L, Penarrocha-Oltra D, Soldini C, Mazzocco F, Penarrocha M, Covani U. Microbiological assessment of the implant-abutment interface in different connections: cross-sectional study after 5 years of functional loading. Clin Oral Implants Res. 2015;26:426-434.

DENTAL MATERIALS 32 (2016) 794–806

Available online at [www.sciencedirect.com](http://www.sciencedirect.com)

ScienceDirect

journal homepage: [www.intl.elsevierhealth.com/journals/dema](http://www.intl.elsevierhealth.com/journals/dema)

## Combined microcomputed tomography, biomechanical and histomorphometric analysis of the peri-implant bone: a pilot study in minipig model



Matteo Gramanzini<sup>a,b,\*</sup>, Sara Gargiulo<sup>a,b,1</sup>, Fernando Zarone<sup>c</sup>,  
Rosario Megna<sup>a</sup>, Antonio Apicella<sup>d</sup>, Raffaella Aversa<sup>d</sup>, Marco Salvatore<sup>e</sup>,  
Marcello Mancini<sup>a</sup>, Roberto Sorrentino<sup>c,d</sup>, Arturo Brunetti<sup>f,b</sup>

<sup>a</sup> Institute of Biostructure and Bioimaging, National Research Council, Via T. De Amicis 95, 80145 Naples, Italy

<sup>b</sup> CEINGE scrl, Via G. Salvatore 486, 80145 Naples, Italy

<sup>c</sup> Department of Neurosciences, Reproductive and Odontostomatological Sciences, School of Medicine, University "Federico II", Via Pansini 5, 80131 Naples, Italy

<sup>d</sup> Department of Architecture and Industrial Design, Second University of Naples, Borgo San Lorenzo, 81031 Aversa, Italy

<sup>e</sup> IRCCS SDN, Via E. Gianturco 113, 80143 Naples, Italy

<sup>f</sup> Department of Advanced Medical Sciences, University "Federico II", Via Pansini 5, 80145 Naples, Italy

### ARTICLE INFO

#### Article history:

Received 5 October 2015

Received in revised form

9 March 2016

Accepted 22 March 2016

#### Keywords:

Dental implant

Insertion torque

Resonance frequency analysis

$\mu$ CT

Histomorphometry

Minipig model

### ABSTRACT

**Objectives.** To present a practical approach that combines biomechanical tests, microcomputed tomography ( $\mu$ CT) and histomorphometry, providing quantitative results on bone structure and mechanical properties in a minipig model, in order to investigate the specific response to an innovative dental biomaterial.

**Methods.** Titanium implants with innovative three-dimensional scaffolds were inserted in the tibias of 4 minipigs. Primary stability and osseointegration were investigated by means of insertion torque (IT) values, resonance frequency analysis (RFA), bone-to-implant contact (BIC), bone mineral density (BMD) and stereological measures of trabecular bone.

**Results.** A significant positive correlation was found between IT and RFA ( $r = 0.980$ ,  $p = 0.0001$ ). BMD at the implant sites was 18% less than the reference values ( $p = 0.0156$ ). Peri-implant Tb.Th was 50% higher, while Tb.N was 50% lower than the reference zone ( $p < 0.003$ ) and they were negatively correlated ( $r = -0.897$ ,  $p = 0.006$ ).

\* Corresponding author at: Institute of Biostructure and Bioimaging, National Research Council, Via T. De Amicis 95, 80145 Naples, Italy. Tel.: +39 0812203401; fax: +39 0812203498.

E-mail addresses: [matteo.gramanzini@ibb.cnr.it](mailto:matteo.gramanzini@ibb.cnr.it) (M. Gramanzini), [sara.gargiulo@ibb.cnr.it](mailto:sara.gargiulo@ibb.cnr.it) (S. Gargiulo), [fernandozarone@mac.com](mailto:fernandozarone@mac.com) (F. Zarone), [rosario.megna@ibb.cnr.it](mailto:rosario.megna@ibb.cnr.it) (R. Megna), [antonio.apicella@unina2.it](mailto:antonio.apicella@unina2.it) (A. Apicella), [raffaella.aversa@unina2.it](mailto:raffaella.aversa@unina2.it) (R. Aversa), [marsalva@unina.it](mailto:marsalva@unina.it) (M. Salvatore), [marcello.mancini@ibb.cnr.it](mailto:marcello.mancini@ibb.cnr.it) (M. Mancini), [errestino@libero.it](mailto:errestino@libero.it) (R. Sorrentino), [brunetti@unina.it](mailto:brunetti@unina.it) (A. Brunetti).

<sup>1</sup> These authors contributed equally to this work.

<http://dx.doi.org/10.1016/j.dental.2016.03.025>

0109-5641/© 2016 Academy of Dental Materials. Published by Elsevier Ltd. All rights reserved.



*Significance.*  $\mu$ CT increases evaluation throughput and offers the possibility for qualitative three-dimensional recording of the bone–implant system as well as for non-destructive evaluation of bone architecture and mineral density, in combination with conventional analysis methods. The proposed multimodal approach allows to improve accuracy and reproducibility for peri-implant bone measurements and could support future investigations.

© 2016 Academy of Dental Materials. Published by Elsevier Ltd. All rights reserved.

## 1. Introduction

Improvements in bone–implant integration are crucial in modern dental surgery [1,2]. The processes of osseointegration involve an initial mechanical interlocking between alveolar bone and the implant body (primary implant stability) and, later on, a biological fixation through continuous bone apposition (contact osteogenesis) and remodeling toward the implant (secondary implant stability). [3].


Biofidelity is a raising topic in modern medicine; such a concept derives from the study of the biomechanic of tissues and materials and of the biomimetic approach nowadays common in tissue engineering to imitate the properties of natural tissues with bioinspired materials. The bone tissue is as a natural nanostructured biomaterial containing a collagen matrix and hydroxyapatite filler [4]. Tissue engineering using synthetic biomaterials is nowadays used in regenerative therapies and implantology, since they may act as bioactive scaffolds promoting wound healing and bone formation [5]. The physico-chemical and structural characteristics of the scaffold materials have been observed to significantly influence their *in vivo* activity; 3D scaffolds may then represent new clinical applications in bone reconstructive surgery and implantology [6]. In particular, it has been shown that scaffolds made up of porous hydroxyapatite may be colonized by osteoblasts favoring implant stability improvement [7].

Different methods were developed to objectively evaluate implant primary stability. In particular, peak insertion torque (IT) and resonance frequency analysis (RFA) are the parameters that are most globally used and a correlation between primary stability and implant insertion torque has been often suggested in dental literature [8–18]. Insertion torque values were correlated to histological bone-to-implant contact and radiological bone density [19]. RFA is another effective and reliable method to assess implant stability, which positively correlates with IT method [20,21].

The use of patients care newly developed implant materials often requires the use of preclinical models to test their biocompatibility, mechanical stability and safety. Before clinical trials in humans, minipigs are a recommended as animal model for translational research of new dental materials, since their bone structure is similar to that of humans. This species is considered to be closely representative of human bone tissue with regard to morphology [22], bone composition [23], microstructure [24] and remodeling characteristics [25,26]. Moreover, the bone of minipig shows similarities in mineral density and concentration with that of humans [27]. However, minipigs bones have a denser trabecular network: mean cavity path lengths values in the adult man are typically

1200  $\mu$ m and 350  $\mu$ m in the minipig [25], while mean trabecular path lengths in child are typically 190  $\mu$ m and 280  $\mu$ m in the minipig [28]. Bone regeneration rate in minipigs is comparable to that of humans (namely, 1.2–1.5 mm per day in minipigs and 1.0–1.5 mm per day in humans) [29], and cortical bone mineralization rate is similar to man [30], although mesenchymal stem cells in minipig showed a significantly lower ability than human ones to form differentiated and functional osteoblasts [31]. Based on the above considerations, minipig has been selected in this study as large animal model for the pivotal preclinical testing of our innovative biomaterials and implants. This model would benefit from a non-destructive imaging modality so that mechanical and morphological endpoints can more readily be examined in the same specimens. Presently, microcomputed tomography ( $\mu$ CT) may represent a promising candidate tool for bone characterization when paired to biomechanical testing and standard histology. The implant stability which is critically dependent on structural characteristics and bone quality in a relatively broad area around the implant, may be correlated to bone properties assessed by  $\mu$ CT [32,33]. This technique is fast, precise and, unlike conventional microscopic methods, does not need long time for specimen preparation and it is not impaired by the assessment of a limited number of sections. High-resolution  $\mu$ CT allows measurements of trabecular and cortical bone [34] and a three-dimensional (3D) representation of bone formation at the peri-implant region [35]. In accordance with the principles of the “refinement” and “reduction” declared by Russell and Burch in 1954,  $\mu$ CT allows less use of samples necessary for both biomechanical and morphometric studies. In the present investigation, an innovative hybrid nanocomposite working as a biomimetic scaffold was used to evaluate the performance of the novel material in improving implant primary stability in post-surgical sites.

Our innovative biomaterial appears as a nanoporous transparent glassy polymer (Fig. 1B) able to progressively swell into a hydrogel form (Fig. 1C) when in contact with water solutions (picking up to 30–50% in weight of water), with a kinetic of swelling at 37 °C of about 0.1 mm per hour [36]. The geometrical configuration of the modified implant (Fig. 1A) confines the polymeric scaffold in a niche that allows swelling deformation only in the radial implant direction. This radial guided swelling could be used to stabilize the implant in the socket while creating a biomechanically active interface for bone growth [36]. Moreover, the nanoporosity can be modulated to host cells and growth factors. In previous investigations, the material was characterized for physical, chemical and mechanical properties [37]. It showed a bioactive surface with improved osteoblastic adhesion and proliferation and it could be speculated that this feature could promote more effective



**Fig. 1 – (A) Implant prototype, (B) implant with glassy polymer scaffold, and (C) implant with swollen scaffold.**

and rapid osseointegration. Furthermore, the finite element analysis (FEA) was used to evaluate the scaffold interactions between the swollen interface and the bone [36]. The elastic modulus of the scaffolds in the swollen state was reported to range between 2 and 10 MPa, which is comparable to that of the periodontal ligament (2–50 MPa) [38–40]. The scaffold had to play two biomechanical functions: a structural one, as part of the fixture, and a bioactive one, as bone growth stimulus. Physiologically, the stresses and deformations induced by the stretching of the periodontal ligament acts as a biomechanical stimulus that favors new bone apposition in the tooth socket [36]. Since the elastic modulus of the swollen scaffold was comparable to that of the periodontal ligament, the FEA confirmed that the swelling of the nanocomposite could act as a biomechanical bone growth input [36]. According to Frost's law regarding the strain dependent adaptive properties of bone [41], the strain values recorded at the bone-scaffold interface fell within the adapted window and were compatible with an organized bone growth. The purpose of this pilot study was to examine the utility of  $\mu$ CT for evaluating bone-implant integration in a minipig model, as an adjunct to conventional histomorphometry and biomechanical testing. The presented approach can serve as a model for future investigations to study implants of different composition or shape with complementary  $\mu$ CT analysis. The null hypothesis stated that there was no association between the biomechanical, histomorphometric and  $\mu$ CT study variables of control and experimental implant sites.

## 2. Materials and methods

### 2.1. Surgical procedures


All experimental procedures have complied with the Italian D.L. no 116 of 1992 and associated guidelines in the European Communities Council Directive of the 24th of November 1986 (86/609/ECC). Titanium implants (Winsix Implant System, Biosafin, Ancona, Italy) modified with 3D scaffolds were used.

The proposed biomaterial was a hydrophilic hybrid composite made up of nanoinclusions of hydroxyapatite dipped in a ceramo-polymeric matrix composed by poly-hydroxyethylmethacrylate and fumed nanosilica.

The scaffolds were designed using a reverse engineering approach and were retained by modified implant prototypes. Standard titanium implants with a diameter of 5.2 mm, a length of 13 mm and a hexagonal internal connection were used. An implant was imported in a solid modeler and meshed to discretize its geometry. Then, a finite element modeling was used to modify the fixture and create the experimental prototype, whose shape was suitable to incorporate the scaffold (Fig. 1A). The coronal part of the screw thread was removed so as to incorporate the scaffold, that had a length of 5 mm and the shape of a truncated cone with the major base apically (major base 0.6 mm, minor base 0.4 mm). The titanium implant prototypes had a micro-rough surface that was acid etched (Fig. 1A).

A steel cylinder was used as tray for the fabrication of the modified implants. A double impression technique was performed using putty and light silicon impression materials. First, the shape of a standard unmodified implant was impressed in the silicon to obtain the external profile shape mold. Subsequently, the modified titanium implant prototypes were inserted in the silicon molds by means of an implant holder and the unpolymerized novel material liquid composite resin [36,37] was injected in the empty space between the external shape mold and the modified implant. The material was let to self-polymerize at room temperature for 15 min. Then, the implant threads were thoroughly polished by means of silicon rubbers. Although, the new biomaterial was designed as self-setting at room temperature, an additional thermal treatment at 80 °C was added to the fabrication procedures in order to favor complete polymerization and stabilization of the scaffolds in their highly rigid glassy state (with an elastic modulus comparable to that of the bone) [36,37] before the surgical insertion (Fig. 1B). The scaffolded implants were then sterilized by means of gamma-rays. The scaffolded implants were introduced uncortically into the left and right proximal tibial metaphysis of 4 male Yucatan minipigs (>18-month old, average body weight 65 kg) with an inter-implant distance of 5–9 mm. The implants were inserted flush with the cortical bone, so as the scaffolds could interface with both the cortical and the spongy bone (Fig. 2). This was made to evaluate if the different elasticity of the bony tissues could affect the swelling of the scaffolds. The animals were sedated by an intramuscular injection (10 mg/kg) of ketamine (Inoketam 1000<sup>®</sup>, Virbac S.r.l., Milan, Italy) and 0.5 mg/kg midazolam PHG (Hospira, Lake Forest, IL, USA). Anesthesia was induced by mask and, after endotracheal intubation, the minipigs were maintained in spontaneously breathing by inhalation of 3% isoflurane and oxygen. The surgical fields were shaved and disinfected with benzoxonium chloride (Citrosil<sup>®</sup>, Manetty & Roberts, Milan, Italy). The tibias were exposed by skin incisions and fascial-periosteal flaps. The implant sites were prepared using drills with increasing diameter and a torque-controlled handpiece implant unit at a rotation speed of 25–30 RPM, with continuous external sterile saline irrigation to minimize bone damage caused by overheating. Thereafter, 4 implants were





**Fig. 2 – Representative sagittal  $\mu$ CT slice showing scaffold-implants systems inserted into the tibia of minipigs after 8 weeks of healing time and the cylindrical volumetric region of interest (VOI), where measurements in peri-implant bone were made (A), at the level of the test zone and (B), at the level of reference zone.**

placed in each tibia, according to local anatomy and bone quality. A total of 28 scaffolded fixtures was inserted in 7 tibias; 1 tibia was not used because of unfavorable local anatomy. The insertion torque values were recorded using an electronic torque-control implant handpiece. The implant position was checked by means of radiographs and intensification of brilliance, in order to verify that the scaffolds were in the transition area between the cortical and the spongy bone. The skin and the fascia-periosteum were closed in separate layers with synthetic monofilament non absorbable polypropylene suture (Prolene<sup>®</sup> 2-0, Ethicon, Somerville, NJ, USA) and a single absorbable suture (Vicryl<sup>®</sup> 3-0, Ethicon, Somerville, NJ, USA), respectively. Perioperatively, the animals received enrofloxacin 2.5 mg/kg/12 h (Baytril<sup>®</sup>, Bayer, Barmen, Germany) as antibiotic for 6 days and ketorolac 1 mg/kg/24 h as anti-inflammatory medication for 3 days. The animals were inspected after the first few postoperative days for signs of wound dehiscence or infection and, thereafter, weekly to assess general health. The animals did not show signs of physical impairments and were in stable condition throughout the study. After 8 weeks, animals were sacrificed and specimens containing the implants were fixed in 10% pH 7.0-buffered formalin.

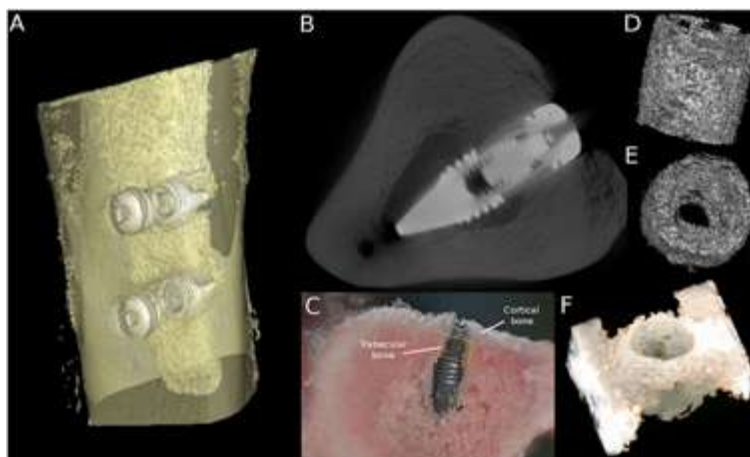
## 2.2. Biomechanical analysis

Insertion torque values (N cm) were recorded during implant placement by means of a torque-controlled implant handpiece. Moreover, once implant placement was completed, a RFA was performed using a dedicated electronic device (Osstell ISQ, Osstell AB, Göteborg, Sweden). The values of resonance frequency were recorded as an implant stability quotient (ISQ) in order to allow a comparison of primary stability between different fixtures [42–44].

## 2.3. $\mu$ CT and 3D reconstruction

The bone surrounding the implant scaffolds was examined using  $\mu$ CT (eXplore Locus, GE Healthcare, London, Canada). The detector of such  $\mu$ CT system was made up of 2 components, a scintillator and a CCD camera, which were connected

with optical fibers. The scintillator is a thin screen of cesium iodide, that luminesces when exposed to X-rays. The camera behind it records the image that is projected onto the scintillator. The projection is saved in digital format. A total of 466  $\mu$ CT slices, with a pixel size of 45  $\mu$ m, were imaged at an X-ray energy level of 80 kVp and a current of 450  $\mu$ A. Exposure time was 100 ms with a total scanning time of 11 min. Images were reconstructed using a modified Feldkamp algorithm and scaled into Hounsfield units (HU). A calibration standard, containing a compartment with 1073 mg/cm<sup>3</sup> SB3 (an epoxy based bone-mimicking material), was used for bone mineral density (BMD) calibration. All data were evaluated in MicroView, 2.1.2 (GE Healthcare, London, Canada). Datasets were resampled to reorient implants perpendicular to the cross-section plane. Before segmentation, threshold levels for bone, implant and scaffold were determined, based on visual inspection of the complete slices and on the gray-scale histogram. The upper and lower threshold levels for bone, implants and scaffold were determined in all 7 samples and did not overlap, allowing to make a clear distinction. An automatic segmentation technique, that utilizes the Otsu method, was used for calculate the value to be used as the threshold to extract the bone from the surrounding structures. The means were calculated and used for each sample. The inter- and intra-examiner variabilities within 1 standard deviation were calculated. Then, a cylindrical, volumetric region of interest (VOI) was placed in correspondence of the scaffold element of the implant circumferentially expanded 2.5 mm around the scaffold, including both cortical and cancellous bone (Fig. 2C), which was defined as the test zone (Fig. 3A). Subsequently, bone, implant and scaffold in the ROI were differentiated based on their threshold levels. Outcome variables were: BMD (mg/cm<sup>3</sup>) and bone mineral concentration (BMC, mg); bone volume fraction (BVF), being the % of the ROI which includes bone; bone volume (BV), being the mm<sup>3</sup> of bone that is present in the region of interest; the ratio of the volume of bone present (BV) to the total volume (TV) of interest (%); the ratio of the surface (BS) to the volume (BV) of bone (mm<sup>-1</sup>); the average trabecular thickness (Tb.Th, mm); the mean trabecular number (Tb.N, mm<sup>-1</sup>); the mean diameter to the marrow spaces (Tb.Sp, mm). These values were also measured in VOI at an equivalent distance between 2



**Fig. 3 – (A) High-resolution  $\mu$ CT 3-D volume rendering of minipig tibias with implants. (B) Representative axial  $\mu$ CT image of minipig tibias with implant–bone interface visualization. (C) Representative photograph of minipig tibias with implant position visualization. (D and E) High-resolution  $\mu$ CT 3-D volume rendering of scaffold. (F) High-resolution  $\mu$ CT 3-D volume rendering peri-implant bone.**

median implants, as reference zone (Fig. 3B). 3-D volume rendering images were performed on  $27\ \mu\text{m}$   $\mu$ CT dataset using Osirix Imaging Software 5.8.5 (Pixmeo, Bermex, Switzerland) (Fig. 2A, B, E, F).

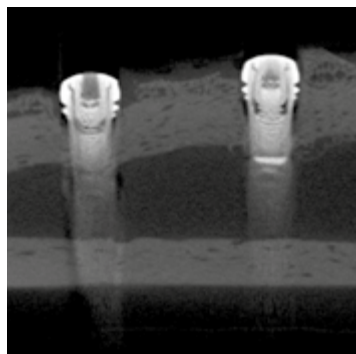
#### 2.4. Histology and histomorphometry

The formalin-fixed specimens were transferred to 70% ethanol solution, dehydrated in ascending concentration of ethanol up to 100%, and then infiltrated and embedded in a hydrophilic acrylic resin (LR White, London Resin Company, Berkshire, England). After polymerization, the specimens were sectioned along the longitudinal axis with a high-precision diamond disk at about  $100\ \mu\text{m}$ , provided with a custom-built sawing and a grinding apparatus (TT System, TMA2, Grottammare, Italy). A total of 3 sections was obtained for each implant (1 longitudinal central section and 2 sections at a cutting distance of  $600\ \mu\text{m}$ ). The sections were ground down to about  $60 \pm 10\ \mu\text{m}$  and stained with acid fuchsine and toluidine blue. The investigation was conducted in a transmitted bright-field and circularly polarized Light Microscope Axiolab (Zeiss Oberchen, Germany) connected to a high-resolution digital camera (FinePix S2 Pro, Fuji Photo Film Co. Ltd, Minato-Ku, Japan). A histomorphometric software package with image capturing capabilities (Image-Pro Plus 6.0, Media Cybernetics Inc, Bethesda, MD, USA) was used. To ensure accuracy, the software was calibrated for each experimental image using a feature named “Calibration Wizard”, which creates a linear remapping of the pixel numbers. The unit of measurement was the pixel. The analyzed parameter was the bone-to-implant contact (BIC, %), defined as the ratio between the length of the scaffold material section in contact with bone and the perimeter of the scaffold area, at  $25\times$  magnification. At each measurement, the software was calibrated

using the length of the implant as reference. Measurements were performed by a single experienced and calibrated operator. Intra-examiner variability was controlled by carrying out 2 measurements; if the difference between the 2 values was greater than 5%, the measuring was repeated.

#### 2.5. Statistical analyses

The study variables were divided into 4 groups as follows: biomechanical (IT and RFA), histomorphometric (BIC),  $\mu$ CT of implant sites (BMD, BMC, BVF, BV, BV/TV, BS/BV, TbTh, TbN, TbSp) and  $\mu$ CT of control sites (cBMD, cBMC, cBVF, cBV, cBV/TV, cBS/BV, cTb/Th, cTbN, cTbSp). Mean, standard deviation, median, minimum and maximum values were calculated for all the variables. Normality was tested using Shapiro–Wilk test and variance homogeneity using Bartlett or Levene test. When data were normally distributed and variance homogeneity was met, the variables were compared using one-way analysis of variance (ANOVA). In case of violation of normality or variance homogeneity, Kruskal–Wallis or Mann–Whitney test were performed. The mean values of 21 variables for 7 tibial samples were used for the statistical analysis. The Pearson correlation was performed for all possible pairs of variables, for a total of 210 combinations. The linear regression coefficients were calculated for the 12 pairs of variables found to be correlated. Moreover, IT, RFA, BIC, BMD, BMC, TbTh, TbN and TbSp were analyzed for comparison among implant sites. Sample size required to reach a 5% significance with a 80% power was estimated for Mann–Whitney, Shapiro–Wilk, Anova and Pearson correlation tests. Statistical analysis was performed using R statistical software (version 3.1.2, R Foundation for Statistical Computing, Vienna, Austria) and the level of significance was set at  $p < 0.05$  for all tests.



**Fig. 4** – Representative sagittal  $\mu$ CT slice showing scaffold-implants systems inserted into the tibia of minipigs after 8 weeks of healing time.

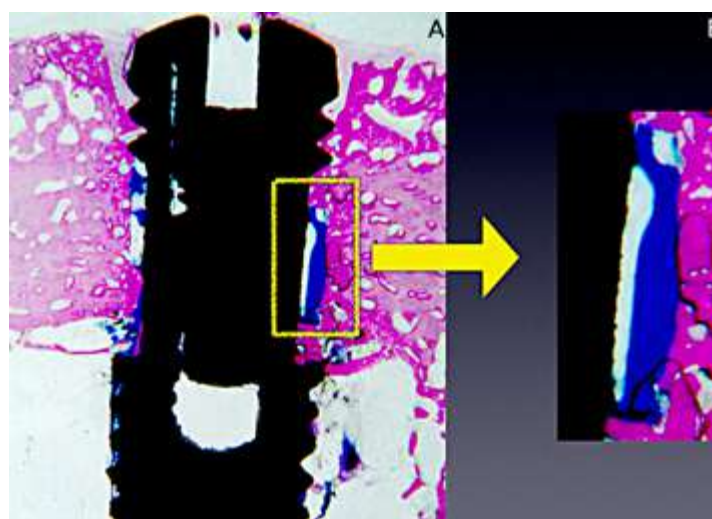
### 3. Results

The minipigs showed good general health after surgery and signs of infection were not found at clinical and  $\mu$ CT examination. No effects from X-ray scattering or ring artifacts were found in the  $\mu$ CT images in the peri-implant zone used for measurements (Fig. 4). All the implants were osseointegrated and the peri-implant bone structure consisted of lamellar bone architecture (Fig. 5). The IT and RFA values were reported in Table 1.

According to the results of the present investigation, the null hypothesis was rejected.

Descriptive statistics for biomechanical,  $\mu$ CT and histologic variables were summarized in Table 2. The mean and standard deviation of lower and upper threshold gray-levels for titanium implants, for ceramo-polymeric scaffolds and for bone made by 2 independent and calibrated operators were summarized in Table 3. The first box of Table 2 shows the values of the 3 series of repeated measures for each bone sample; the second box those of all samples for each series of measurements; the third one the global threshold value for implant, scaffold and bone. The inter- and intra-examiner variabilities were equivalent within 1 standard deviation. ANOVA did not reveal differences among the implant sites for BIC ( $F=1.76$ ,  $p=0.112$ ) and IT ( $F=2.580$ ,  $p=0.058$ ), unlike RFA (Kruskal–Wallis,  $p=0.0156$ ). For  $\mu$ CT parameters, significant differences were found among the implant sites for BMC ( $F=5.201$ ,  $p=0.003$ ) and BMD (Kruskal–Wallis,  $p=0.037$ ), unlike for TbTh ( $F=2.61$ ,  $p=0.056$ ), TbN (Kruskal–Wallis,  $p=0.037$ ) and TbSp ( $F=1.764$ ,  $p=0.167$ ). For comparisons between implant and control sites, ANOVA did not reveal differences between the  $\mu$ CT pairs of variables cBMC–BMC ( $F=1.26$ ,  $p=0.2831$ ) and cTbSp–TbSp ( $F=8.68$ ,  $p=0.0514$ ), whereas cBMD–BMD and cBV–BV were significantly different (Mann–Whitney test:  $p<0.05$ ). Fifty Pearson correlations were observed with  $p<0.05$ , both between variables of the same group that between variables of different groups. The correlation matrix of all correlation coefficients between the set of variables were reported in Table 4.

Relevant correlations were found between IT and RFA variables ( $r=0.980$ ,  $p=0.0001$ ); the  $\mu$ CT pairs of variables cBV–BMC ( $r=0.796$ ,  $p=0.0322$ ), cBV–BV ( $r=0.823$ ,  $p=0.0230$ ), cBV–BV ( $r=0.826$ ,  $p=0.0220$ ), cBV–BS/BV ( $r=-0.873$ ,  $p=0.0103$ ), cBV–TbTh ( $r=0.830$ ,  $p=0.0208$ ), cBV–TbN ( $r=-0.778$ ,  $p=0.0394$ ), cBV–TbN ( $r=0.772$ ,  $p=0.0419$ ), cBV/TV–TbN ( $r=-0.795$ ,  $p=0.0326$ ) and cBV/TV–BS/BV ( $r=-0.761$ ,  $p=0.0470$ ); and between IT–cTbSp and RFA–cTbSp ( $r=-0.859$ ,



**Fig. 5** – (A) Microphotograph of a longitudinal section of a specimen stained with fuchsin acid and toluidine blue. (B) Magnification at 25 $\times$  to show the contact between scaffold material and bone.

**Table 1 – Insertion torque (IT in N cm) and resonance frequency analysis (RFA in ISQ) values of the experimental scaffolded implants.**

Minipig	Tibia	Measurement	Implant			
			#1	#2	#3	#4
#1	Left	IT (N cm)	44.2	46.2	47.3	44.5
		RFA (ISQ)	71	73	74	71
	Right	IT (N cm)	48.1	44.6	45.1	44.4
		RFA (ISQ)	75	71	72	71
#2	Left	IT (N cm)	43.4	44.7	42.9	42.5
		RFA (ISQ)	70	71	70	69
	Right	IT (N cm)	51.1	45.2	45.8	44.7
		RFA (ISQ)	79	72	72	71
#3	Left	IT (N cm)	Excluded because of unfavorable local anatomy			
		RFA (ISQ)				
	Right	IT (N cm)	42.0	45.6	42.9	43.1
		RFA (ISQ)	69	72	70	69
#4	Left	IT (N cm)	46.2	43.7	45.2	43.8
		RFA (ISQ)	73	70	72	70
	Right	IT (N cm)	42.6	39.9	43.2	42.2
		RFA (ISQ)	69	66	70	69

**Table 2 – Descriptive statistic of sample data.**

Variable	Unit	Mean	SD	Min	Median	Max
IT	N cm	44.39	1.63	41.90	43.83	46.70
RFA	ISQ	71.11	1.71	68.50	71.25	73.50
BMD	mg/cm <sup>3</sup>	623.7	42.1	533.2	631.9	665.0
BMC	mg	46.62	5.71	36.18	47.47	54.34
BVF	%	0.7809	0.0639	0.6705	0.7925	0.8579
BV	mm <sup>3</sup>	74.04	4.42	67.47	73.98	79.39
BV/TV	%	0.8394	0.1118	0.7332	0.8164	1.0743
BS/BV	mm <sup>-1</sup>	1.641	0.182	1.451	1.634	1.891
TbTh	mm	1.244	0.140	1.058	1.228	1.405
TbN	mm <sup>-1</sup>	0.6392	0.0335	0.5846	0.6316	0.6866
TbSp	mm	0.3311	0.0744	0.2246	0.3165	0.4351
cBMD	mg/cm <sup>3</sup>	764.0	31.5	719.9	765.5	808.9
cBMC	mg	52.40	12.36	33.62	54.13	73.82
cBVF	%	0.6955	0.0983	0.4933	0.7322	0.7799
cBV	mm <sup>3</sup>	63.70	12.47	44.50	69.52	73.82
cBV/TV	%	0.7075	0.1009	0.5043	0.7467	0.7913
cBS/BV	mm <sup>-1</sup>	3.722	1.307	1.923	4.117	5.517
cTbTh	mm	0.6152	0.2675	0.3624	0.4857	1.0399
cTbN	mm <sup>-1</sup>	1.274	0.355	0.761	1.391	1.617
cTbSp	mm	0.2407	0.0817	0.1507	0.2474	0.3561
BIC	%	76.91	4.17	69.86	77.44	82.34

$p=0.0134$  and  $r=-0.834$ ,  $p=0.0196$ , respectively. A lack of statistical significance was found between the values of BIC and all other variables. Table 5 summarized the linear regression coefficients for the pairs of variables correlated.

#### 4. Discussion

Preclinical research is considered an essential step to test dental materials and implants prior to their clinical use. Minipigs are suitable models for translational validation due to their anatomical and physiological correspondences with human bone [45]. It is generally accepted that the chemical and physical properties of implant surfaces have a major influence on the structure of the peri-implant bone and thus can improve

osseointegration. The scaffolds should work as a medium that offers mechanical properties similar to the host bone, promoting cell adhesion and activity and inducing finally bone growth. The tested innovative nanocomposite material allowed to fabricate stable 3D implant scaffolds that proved to be easy handling and suitable for the surgical procedures. In a previous investigation [36], it was demonstrated that the volumetric expansion of the bioactive novel material due to the swelling of the scaffolds, significantly contributed to the primary stability of the implants. Since it is known that the development of a stable bone-implant interface depends on different factors, it is desirable to use several methods capable to evaluate different bone properties. In this perspective, the integration of biomechanical data, of 3D  $\mu$ CT information and histomorphometric parameters in the same implant/bone

Table 3 – Descriptive statistics for intra-operator and inter-operator reproducibility (mean ± standard deviation).

Bone sample	OP 1						OP 2					
	Implant		Scaffold		Bone		Implant		Scaffold		Bone	
	LTh	UTH	LTh	UTH	LTh	UTH	LTh	UTH	LTh	UTH	LTh	UTH
#1	4999.3 ± 1.2	13,873.7 ± 1.5	0.3 ± 0.6	1499.3 ± 1.2	1699.0 ± 1.0	4699.0 ± 1.0	4999.3 ± 1.2	13,873.7 ± 1.5	0.3 ± 0.6	1499.7 ± 0.6	1699.0 ± 1.0	4699.0 ± 1.0
#2	4998.6 ± 1.2	13,872.7 ± 1.2	0.0 ± 0.0	1500.0 ± 0.0	1699.3 ± 0.6	4699.3 ± 0.6	4999.3 ± 1.2	13,872.7 ± 1.2	0.3 ± 0.6	1499.0 ± 1.0	1699.3 ± 0.6	4699.3 ± 0.6
#3	5000.0 ± 0.0	13,874.7 ± 1.2	0.3 ± 0.6	1499.3 ± 0.6	1698.0 ± 0.0	4694.6 ± 0.6	5000.0 ± 0.0	13,872.7 ± 1.2	0.3 ± 0.6	1499.3 ± 0.6	1694.7 ± 0.7	4694.0 ± 1.0
#4	4999.0 ± 1.0	13,873.0 ± 1.7	0.3 ± 0.6	1499.6 ± 0.6	1698.3 ± 0.6	4693.6 ± 0.6	4999.0 ± 1.0	13,873.7 ± 1.5	0.0 ± 0.0	1499.6 ± 0.6	1695.7 ± 0.8	4694.3 ± 2.1
#5	4999.3 ± 1.2	13,873.7 ± 1.5	0.3 ± 0.6	1499.6 ± 0.6	1699.6 ± 0.6	4699.6 ± 0.6	4999.3 ± 1.2	13,873.7 ± 1.5	0.7 ± 0.6	1499.6 ± 0.6	1699.6 ± 0.6	4699.3 ± 0.6
#6	4999.3 ± 1.2	13,873.0 ± 1.7	0.3 ± 0.6	1499.0 ± 1.0	1699.0 ± 1.0	4699.3 ± 1.2	4999.3 ± 1.2	13,872.7 ± 1.2	0.3 ± 0.6	1499.0 ± 1.0	1699.0 ± 1.0	4699.0 ± 1.0
#7	4999.3 ± 1.2	13,872.0 ± 1.2	0.3 ± 0.6	1499.3 ± 0.6	1700.0 ± 0.0	4699.7 ± 0.6	4999.3 ± 1.2	13,872.0 ± 1.2	0.3 ± 0.6	1499.3 ± 0.6	1700.0 ± 0.0	4699.7 ± 0.6
Repeated measures	1° 4999.3 ± 0.9	13,874.1 ± 1.1	0.1 ± 0.4	1499.6 ± 0.8	1698.7 ± 1.0	4698.0 ± 2.5	4999.6 ± 0.8	13,873.3 ± 1.3	0.2 ± 0.4	1499.3 ± 0.7	1698.8 ± 0.8	4697.7 ± 2.6
series	2° 4999.1 ± 1.0	13,872.7 ± 1.3	0.1 ± 0.4	1499.1 ± 0.7	1698.8 ± 0.7	4698.2 ± 2.6	4999.0 ± 1.1	13,873.0 ± 1.3	0.2 ± 0.4	1499.3 ± 0.5	1697.2 ± 3.8	4697.7 ± 2.4
Global value	3° 4999.4 ± 1.0	13,873.1 ± 1.5	0.6 ± 0.5	1499.7 ± 0.5	1699.8 ± 0.8	4697.4 ± 2.9	4999.4 ± 1.0	13,873.0 ± 1.3	0.7 ± 0.5	1499.5 ± 0.8	1697.7 ± 4.9	4697.2 ± 2.9
	4999.3 ± 1.0	13,873.3 ± 1.4	0.3 ± 0.5	1499.5 ± 0.7	1699.3 ± 0.9	4697.3 ± 2.6	4999.3 ± 0.9	13,873.1 ± 1.2	0.3 ± 0.5	1499.4 ± 0.7	1698.2 ± 3.5	4698.3 ± 2.5

OP: operator; LTh: lower HU threshold; UTh: upper HU threshold.

sample enables to improve evaluation of implant stability. Primary implant stability is considered of paramount importance to achieve osseointegration and IT and RFA values are validated mechanical parameters to evaluate the strenght of the interaction between the host bone and implant surface [46]. In dental literature, minimum IT values for immediate loading ranged from 32 to 50 N cm [8,12,14,47-51], sufficient for retaining micromovements within limits [12,49]. RFA has been used at early stages of osseointegration or in monitoring over time and increases during the healing phase [52]. The acceptable range of RFA, that indicates stability, lies between 55 and 85 ISQ [53-55]. Moreover, IT and ISQ values have shown a positive correlation [33,56]. The measurements of IT and RFA recorded in this study were in the interval of values reported as adequate in literature. In agreement with the literature, a strong correlation between IT and RFA was found. Secondary stability is determined by the new bone formation and remodeling at the implant interface, and greater bone contact is generally believed to result in better implant stability [57]. In the examined samples, lamellar bone was visible in intimate contact with the scaffold surface. The BIC values in this study were found to be appropriate to warrant stability, since they were higher than 50%, the minimum value considered necessary for loading and to ensure long-term survival of implants [58]. Good primary stability may be related to better bone tissue response. However, the formula of higher biomechanical parameters translating into better osseointegration may not always be true, because the quantity and quality of bone may vary significantly among subjects. Despite IT and RFA have been considered valid tools to foresee the bone quality and primary stability of implant sites, their comparison with radiologic or histomorphometric tests gave contradictory results [59-69]. Friberg et al. [61] demonstrated that IT was correlated to histomorphometric BIC and to radiological BMD of the prepared sites [19,52]. Other authors demonstrated that IT values was correlated with BMD of the receiving bone site, obtained by measuring CT or  $\mu$ CT [9,70,71]. In contrast, it has been reported that RFA suffers from a lack of sensitivity to the quality of surrounding bone [72], and a correlation with histomorphometric BIC was not found [56,73]. The biomechanical properties of the bone seems to be related both to its mineral content and microarchitecture [74]. Moreover, bone quality parameters assessed by  $\mu$ CT in peri-implant regions did not seem linearly correlated to biomechanical variables [68]. The present study failed to find a correlation between BIC and biomechanical or  $\mu$ CT parameters. Nevertheless, a strong relationship between IT-cTbSp and RFA-cTbSp was found, where negative values of r indicate that, increasing cTbSp, IT and RFA decreased. Although histology is the most common method for analysing bone formation around implants, it also has limitations. Sample preparation is time consuming, may alter bone-implant interface and a limited number of 2D sections per sample are used for the approximation of mean values of BIC. Conversely,  $\mu$ CT is a non-destructive, fast and precise technique, that provides accurate modeling and analysis of 3D images of bone samples, and can evaluate both qualitative and quantitative morphometry of bone integration around dental implants [57,75].  $\mu$ CT produces voxels in the range of 5-50  $\mu$ m, or approximately 1.000 times smaller in volume than clinical CT voxels [76,77]. A wide range of specimens may be examined

**Table 4 – Pearson correlation matrix.**

	IT	RFA	BIC	TMD	TMC	BVF	BV	BV/TV	BS/BV	TbTh	TbN	TbSp	cTMD	cTMC	cBVF	cBV	cBV/TV	cBS/BV	cTbTh	cTbN	
RFA	0.980 <sup>*</sup>																				
BIC	-0.171	-0.286																			
BMD	0.321	0.384	0.108																		
BMC	0.226	0.281	0.123	0.928 <sup>*</sup>																	
BVF	0.310	0.352	0.199	0.899 <sup>*</sup>	0.978 <sup>*</sup>																
BV	0.036	0.094	0.206	0.772 <sup>*</sup>	0.941 <sup>*</sup>	0.937 <sup>*</sup>															
BV/TV	-0.093	-0.193	-0.052	-0.775 <sup>*</sup>	-0.535	-0.462	-0.350														
BS/BV	-0.407	-0.467	-0.054	-0.755 <sup>*</sup>	-0.857 <sup>*</sup>	-0.931 <sup>*</sup>	-0.857 <sup>*</sup>	0.290													
TbTh	0.408	0.455	0.107	0.743	0.840 <sup>*</sup>	0.925 <sup>*</sup>	0.838 <sup>*</sup>	-0.268	-0.996 <sup>*</sup>												
TbN	-0.520	-0.596	0.123	-0.527	-0.566	-0.688	-0.564	0.181	0.896 <sup>*</sup>	-0.897 <sup>*</sup>	0.567										
TbSp	-0.242	-0.244	-0.297	-0.800 <sup>*</sup>	-0.945 <sup>*</sup>	-0.965 <sup>*</sup>	-0.939 <sup>*</sup>	0.280	0.868 <sup>*</sup>	-0.870 <sup>*</sup>	0.280	0.567									
cBMD	-0.249	-0.094	-0.205	0.320	0.491	0.473	0.673	-0.215	-0.552	0.494	-0.480	-0.394									
cBMC	0.071	0.243	-0.463	0.304	0.415	0.410	0.523	-0.221	-0.560	0.492	-0.602	-0.279	0.918 <sup>*</sup>								
cBVF	0.301	0.406	-0.161	0.287	0.465	0.544	0.612	0.003	-0.736	0.695	-0.772 <sup>*</sup>	-0.474	0.794 <sup>*</sup>	0.869 <sup>*</sup>							
cBV	0.327	0.450	-0.081	0.717	0.796 <sup>*</sup>	0.823 <sup>*</sup>	0.826 <sup>*</sup>	-0.452	-0.873 <sup>*</sup>	0.830 <sup>*</sup>	-0.778 <sup>*</sup>	-0.709	0.782 <sup>*</sup>	0.823 <sup>*</sup>	0.864 <sup>*</sup>						
cBV/TV	0.320	0.426	-0.134	0.329	0.492	0.574	0.628	-0.043	-0.761 <sup>*</sup>	0.722	-0.795 <sup>*</sup>	-0.496	0.788 <sup>*</sup>	0.863 <sup>*</sup>	0.998 <sup>*</sup>	0.884 <sup>*</sup>					
cBS/BV	0.294	0.146	0.139	-0.172	-0.299	-0.336	-0.503	0.140	0.505	-0.470	0.566	0.228	-0.921 <sup>*</sup>	-0.840 <sup>*</sup>	-0.751	-0.663	-0.750				
cTbTh	-0.453	-0.292	-0.201	0.157	0.248	0.242	0.432	-0.232	-0.362	0.322	-0.403	-0.124	0.903 <sup>*</sup>	0.795 <sup>*</sup>	0.593	0.561	0.591	-0.968 <sup>*</sup>			
cTbN	0.643	0.501	0.134	-0.037	-0.068	-0.050	-0.233	0.242	0.140	-0.117	0.206	-0.064	-0.719	-0.563	-0.302	-0.294	-0.302	0.854 <sup>*</sup>	-0.941 <sup>*</sup>		
cTbSp	-0.858 <sup>*</sup>	-0.834 <sup>*</sup>	0.066	-0.210	-0.298	-0.390	-0.260	-0.173	0.502	-0.488	0.524	0.402	-0.032	-0.264	-0.587	-0.478	-0.589	-0.087	0.297	-0.585	

\* p < 0.05.



**Table 5 – Linear regression coefficients for correlated variables ( $y = \alpha \cdot x + \beta$ ).**

y	x	$\alpha$	err. st. $\alpha$	$\beta$	err. st. $\beta$
IT	RFA	0.930	0.084	-21.73	6.00
cTbSp	IT	-0.043	0.012	2.156	0.512
cTbSp	RFA	-0.040	0.012	3.070	0.837
cBV	TMC	1.739	0.591	-17.39	27.74
cBV	BVF	160.6	49.6	-61.74	38.84
cBV	BV	2.333	0.712	-109.1	52.8
cBV	BS/BV	-59.77	14.92	161.8	24.6
cBV	TbTh	73.82	22.18	-28.15	27.74
cBV	TbN	-289.7	104.6	248.9	66.9
cBVF	TbN	-2.267	0.834	2.144	0.534
cBV/TV	TbN	-2.396	0.818	2.239	0.523
cBV/TV	BS/BV	-0.422	0.161	1.399	0.265

using  $\mu$ CT, including teeth, bone and materials such as ceramics, polymers or biomaterial scaffolds [34]. Although formalin fixation may alter the mechanical properties of bone, several studies showed that it has no effect on the mineral composition of bone [78,79]. Moreover, in a recent study it was reported that formalin fixation and freezing would not adversely affect the viscoelastic and elastic mechanical properties of murine bone [80]. In the present investigation, no artifacts were found in the  $\mu$ CT images in correspondence of the zones around the scaffolds (Fig. 4). However, it is difficult to determine the precise effect of material composition on the image quality. Nevertheless, these limits do not necessarily prevent suitable analysis of peri-implant bone by  $\mu$ CT, even if extensive experimentation for appropriate set up should be performed for each equipment. Moreover, intra- and inter-examiner reproducibility and reliability of threshold levels for methodology validation were compared, with good results. Therefore, this method can be properly used as complement of the established gold standard, allowing a refinement in the planning of experiments with animal models, in accordance with the 3Rs principles, and to improve the quality of future studies. The mean density of the newly formed bone can be an indication of how the remodeling process has been successful in terms of new bone tissue density, similar to the reference areas. In the present study, the entity of osseointegration was visualized and quantified by  $\mu$ CT 3D reconstruction.  $\mu$ CT for preclinical application provides higher spatial resolution than clinical CT, then peri-implant bone measurements at 45  $\mu$ m resolution could be used as a guide to predict implant integration. In the examined samples, cBV of the reference zone was found correlated with BMC, BV, Tb.N, Tb.Th of the bone surrounding the scaffold. Peri-implant BMD was 18% less than the control value, probably due to the fact that minipigs were sacrificed 8 weeks after implants placement. An adequate healing period for osseointegration in humans is assumed to be 12 weeks [81] and bone formation and remodeling in minipigs have been estimated to be approximately comparable to those of humans [29]. In minipigs, an healing period of 4 weeks is considered short [82] and histological evaluation of bone density demonstrated an increase of mean values over time at 4, 8 and 12 weeks after receiving different types of dental implants [83]. Nevertheless, in this study an interval of reference values for mineral density of peri-implant bone was defined after the widely adopted healing period of 8 weeks in minipigs, corresponding to the desirable values

of the biomechanical properties. Bone in the vicinity of the implants showed evidence of an increase of 50% in trabecular thickness but a similar decrease of their number when compared to the bone in the control zone ( $p=0.0021$ ). It is likely that these changes in trabecular microarchitecture parameters may be a way for low density bone to respond to the stress induced by loading, since bone strength increases proportionally to the square of the trabecular radius [84]. In some studies, bone density were measured preoperatively in implant recipient site of human patients by clinical CT and were recorded in Hounsfield units (HU) or converted in  $\text{mg}/\text{cm}^3$  using a calibration phantom with known density values [19,46,66–68]. As to bone density analysis, the method using BMD calibration standard is more accurately compared with the method with Hounsfield units [85]. Bilhan et al. [86] reported in an *ex vivo* study that HU values assessed by clinical CT could be a misleading tool for the determination of bone density and could result in an overestimation of micro-architectural parameters, while  $\mu$ CT, with a spatial resolution not more than 100  $\mu$ m, was able to reasonably evaluate bone quantitatively and qualitatively with a good correlation between histomorphometric and microtomographic data [85]. The main limitation of this proof of concept study was the relatively small number of samples. Thus, caution is required in the interpretation of the results. Estimated sample sizes per group ranged from 11 for Pearson correlation tests to 26 for Anova. Further studies in a larger group of animals are needed to assess the sensitivity of this approach that combines biomechanical tests, microcomputed tomography ( $\mu$ CT) and histomorphometry to improve evaluation of implant stability.

## 5. Conclusion

In conclusion, the results from this pilot study showed the feasibility and usefulness of  $\mu$ CT imaging in the characterization of bone density and microarchitecture to predict structural changes in minipig bone undergoing new biomaterials and implants, in a complementary way to the common biomechanical testing and histomorphometry. The innovative hybrid ceramopolymeric nanocomposite was effective in fabricating three-dimensional bioactive scaffolds. Further clinical studies are needed to confirm that the experimental nanocomposite could be useful for ensuring scaffold fixation

avoiding micromotion at the tissue/biomaterial interface, promoting accelerated implant osseointegration and loading.

#### Conflict of interest

The authors declare that there is no conflict of interest.

#### Author contributions

- **Matteo Gramanzini**: conception and design of the work; acquisition, analysis and interpretation of data; imaging data reconstruction and post-processing; critical revision of data and statistics; drafting article.
- **Sara Gargiulo**: conception and design of the work; acquisition, analysis and interpretation of data; imaging data reconstruction and post-processing; critical revision of data and statistics; drafting article.
- **Roberto Sorrentino**: conception and design of the work; acquisition, analysis and interpretation of data; critical revision of article.
- **Rosario Megna**: statistics; analysis and interpretation of data; critical revision of article.
- **Antonio Apicella**: conception and design of the work; analysis and interpretation of data.
- **Raffaella Aversa**: acquisition, analysis and interpretation of data; critical revision of article.
- **Marco Salvatore**: critical revision of article and final approval; analysis and interpretation of data.
- **Marcello Mancini**: critical revision of article and final approval; analysis and interpretation of data.
- **Fernando Zarone**: conception and design of the work; critical revision of article and final approval.
- **Arturo Brunetti**: conception and design of the work; critical revision of article and final approval.

#### Acknowledgements

The authors would like to thank Prof. Enrico Felice Gherlone and his team of the University Vita Salute San Raffaele of Milan (Italy) for the support in histological and histomorphometrical analyses and Biosafin (Ancona, Italy) for the technical support providing the implant prototypes of the Winsix Implant System.

#### REFERENCES

- [1] Franchi M, Fini M, Martini D, Orsini E, Leonardi L, Ruggeri A, et al. Biological fixation of endosseous implants. *Micron* 2005;36:665–71.
- [2] Joos U, Wiesmann HP, Szuwart T, Meyer U. Mineralization at the interface of implants. *Int J Oral Maxillofac Surg* 2006;35:783–90.
- [3] Berglundh T, Abrahamsson I, Lang NP, Lindhe J. De novo alveolar bone formation adjacent to endosseous implants. *Clin Oral Implants Res* 2003;14:251–62.
- [4] Otsuka M, Nakagawa H, Otsuka K, Ito A, Higuchi WI. Effect of geometrical structure on the in vivo quality change of a three-dimensionally perforated porous bone cell scaffold made of apatite/collagen composite. *J Biomed Mater Res B Appl Biomater* 2013;101:338–45.
- [5] Panseri S, Russo A, Sartori M, Giavaresi G, Sandri M, Fini M, et al. Modifying bone scaffold architecture in vivo with permanent magnets to facilitate fixation of magnetic scaffolds. *Bone* 2013;56:432–9.
- [6] Velasquez P, Luklinska ZB, Meseguer-Olmo L, Mate-Sanchez de Val JE, Delgado-Ruiz RA, Calvo-Guirado JL, et al.  $\alpha$ -TCP ceramic doped with dicalcium silicate for bone regeneration applications prepared by powder metallurgy method: in vitro and in vivo studies. *J Biomed Mater Res A* 2013;101:1943–54.
- [7] Vozzi G, Corallo C, Carta S, Fortina M, Gattazzo F, Galletti M, et al. Collagen–gelatin–genipin–hydroxyapatite composite scaffolds colonized by human primary osteoblasts are suitable for bone tissue engineering applications: in vitro evidences. *J Biomed Mater Res Part A* 2013;00A.
- [8] Calandriello R, Tomatis M, Rangert B. Immediate functional loading of Bra<sup>®</sup>emark system implants with enhanced initial stability: a prospective 1- to 2-year clinical and radiographic study. *Clin Implant Dent Relat Res* 2003;5:10–20.
- [9] Beer A, Gahleitner A, Holm A, Tschabitscher M, Homolka P. Correlation of insertion torques with bone mineral density from dental quantitative CT in the mandible. *Clin Oral Implants Res* 2003;14:616–20.
- [10] Meredith N. Assessment of implant stability as a prognostic determinant. *Int J Prosthodont* 1998;11:491–501.
- [11] O'Sullivan D, Sennerby L, Meredith N. Measurements comparing the initial stability of five designs of dental implants: a human cadaver study. *Clin Implant Dent Relat Res* 2000;2:85–92.
- [12] Nikellis I, Levi A, Nicolopoulos C. Immediate loading of 190 endosseous dental implants: a prospective observational study of 40 patients treatments with up to 2-years data. *Int J Oral Maxillofac Implants* 2004;19:116–23.
- [13] Friberg B, Sennerby L, Gröndahl K, Bergström C, Bäck T, Lekholm U. On cutting torque measurements during implant placement: a 3 years clinical prospective study. *Clin Implant Dent Relat Res* 1999;1:75–83.
- [14] Hui E, Chow J, Li D, Liu J, Wat P, Law H. Immediate provisional single-tooth implant replacement with Bra<sup>®</sup>emark 612 system: preliminary report. *Clin Implant Dent Relat Res* 2001;3:79–86.
- [15] Johansson P, Strid KG. Assessment of bone quality from cutting placement resistance during implant surgery. *Int J Oral Maxillofac Implants* 1994;9:279–88.
- [16] Lorenzoni M, Pertl C, Zhang K, Wimmer G, Wegscheider WA. Immediate loading of single-tooth implants in the anterior maxilla. Preliminary results after one year. *Clin Oral Implants Res* 2003;14:180–7.
- [17] Shalabi MM, Wolke JGC, Jansen JA. The effects of implant surface roughness and surgical technique on implant fixation in an in vitro model. *Clin Oral Implants Res* 2006;17:172–8.
- [18] Sakoh J, Wahlmann U, Stender E, Nat R, Al-Nawas B, Wagner W. Primary stability of a conical implant and a hybrid, cylindrical screw-type implant in vitro. *Int J Oral Maxillofac Implants* 2006;21:560–6.
- [19] Friberg B, Sennerby L, Roos J, Johansson P, Strid CG, Lekholm U. Evaluation of bone density using cutting resistance measurements and microradiography. *Clin Oral Implants Res* 1995;6:164–71.
- [20] Degidi M, Perrotti V, Strocchi R, Piattelli A, Iezzi G. Is insertion torque correlated to bone-implant contact percentage in the early healing period? A histological and

- histomorphometrical evaluation of 17 human-retrieved dental implants. *Clin Oral Implants Res* 2009;20:778–81.
- [21] Degidi M, Daprile G, Piattelli A. Primary stability determination by means of insertion torque and RFA in a sample of 4,135 implants. *Clin Implant Dent Relat Res* 2010;21:213–20.
- [22] Thorwarth M, Schultze-Mosgau S, Kessler P, Wiltfang J, Schlegel KA. Bone regeneration in osseous defects using a resorbable nanoparticulate hydroxyapatite. *J Oral Maxillofac Surg* 2005;63:1626–33.
- [23] Mosekilde L, Kragstrup J, Richards A. Compressive strength, ash weight, and volume of vertebral trabecular bone in experimental fluorosis in pigs. *Calcif Tissue Int* 1987;40:318–22.
- [24] Martiniakova M, Grosskopf B, Omelka R, Vondráková M, Bauerová M. Differences among species in compact bone tissue microstructure of mammalian skeleton: use of a discriminant function analysis for species identification. *J Forensic Sci* 2006;51:1235–9.
- [25] Mosekilde L, Weisbrode SE, Safron JA, Stills HF, Jankowsky ML, Ebert DC, et al. Calcium-restricted ovariectomized Sinclair S-1 minipigs: an animal model of osteopenia and trabecular plate perforation. *Bone* 1993;14:379–82.
- [26] Martinez-Gonzalez JM, Cano-Sanchez J, Campo-Trapero J, Gonzalo-Lafuente JC, Díaz-Regañón J, Vázquez-Piñero MT. Evaluation of minipigs as an animal model for alveolar distraction. *Oral Surg Oral Med Oral Pathol Oral Radiol Endod* 2005;99:11–6.
- [27] Aerssens J, Boonen S, Lowet G, Dequeker J. Interspecies differences in bone composition, density, and quality: potential implications for in vivo bone research. *Endocrinology* 1998;139:663–70.
- [28] Beddoe HA. Quantitative study of the structure of trabecular bone in man, rhesus monkey, beagle and miniature pig. *Calcif Tissue Res* 1978;25:273–81.
- [29] Laiblin C, Jaeschke G. Clinical chemistry examinations of bone and muscle metabolism under stress in the Gottingen miniature pig—an experimental study. *Berl Munch Tierarztl Wochenschr* 1979;92:124–8.
- [30] Kragstrup J, Richards A, Fejerskov O. Effects of fluoride on cortical bone remodeling in the growing domestic pig. *Bone* 1989;10:421–4.
- [31] Heino Terhi J, Alm JJ, Moritz N, Aro HT. Comparison of the osteogenic capacity of minipig and human bone marrow-derived mesenchymal stem cells. *J Orthop Res* 2012;30:1019–25.
- [32] Homolka P, Beer A, Birkfellner W, Nowotny R, Gahleitner A, Tschabitscher M, et al. Bone mineral density measurement with dental quantitative CT prior to dental implant placement in cadaver mandibles: pilot study. *Radiology* 2002;224:247–52.
- [33] Turkyilmaz I, McGlumphy EA. Influence of bone density on implant stability parameters and implant success: a retrospective clinical study. *BMC Oral Health* 2008;8:32, <http://dx.doi.org/10.1186/1472-6831-8-32>.
- [34] Swain MV, Xue J. State of the art of micro-CT applications in dental research. *Int J Oral Sci* 2009;1:177–88.
- [35] Park YS, Yi KY, Lee IS, Yung YC. Correlation between microtomography and histomorphometry for assessment of implant osseointegration. *Clin Oral Implants Res* 2005;16:156–60.
- [36] Aversa R, Sorrentino R, Apicella A. New biomimetic hybrid nanocomposites for early fixation prostheses. *Adv Mater Res* 2015;1088:487–94.
- [37] Schiraldi C, D'agostino A, Oliva A, Flamma F, De Rosa A, Apicella A, Aversa R, De Rosa M. Development of hybrid materials based on hydroxyethylmethacrylate as supports for improving cell adhesion and proliferation. *Biomaterials* 2004;25:3645–53.
- [38] Natali AN, Pavan PG, Scarpa C. Numerical analysis of tooth mobility: formulation of a non-linear constitutive law for the periodontal ligament. *Dent Mater* 2004;22:3–22, 9.
- [39] Colin SS, Wiskott HWA, Justiz J, Botsis J, Belser UC. In vitro time-dependent response of periodontal ligament to meachanical loading. *J Appl Physiol* 2005;99:2369–78.
- [40] Aversa R, Apicella A, Perillo L, Sorrentino R, Zarone F, Ferrari M, Apicella A. Non-linear elastic three-dimensional finite element analysis on the effect of endocrown material rigidity on alveolar bone remodeling process. *Dent Mater* 2009;25:678–90.
- [41] Frost HM. Bone mass and the mechanostat: a proposal. *Anat Rec* 1987;219:1–9.
- [42] Calvo-Guirado JL, Gómez-Moreno G, Delgado-Ruiz RA, Maté Sánchez de Val JE, Negri B, Ramírez Fernández MP. Clinical and radiographic evaluation of osseotite-expanded platform implants related to crestal bone loss: a 10-year study. *Clin Oral Implants Res* 2014;25:352–8.
- [43] Romanos GE, Ciornei G, Jucan A, Malmstrom H, Gupta B. In vitro assessment of primary stability of straumann® implant designs. *Clin Implant Dent Relat Res* 2014;16:89–95.
- [44] Salimov F, Tatli U, Kürkçü M, Akoğlan M, Öztunc H, Kurtoglu C. Evaluation of relationship between preoperative bone density values derived from cone beam computed tomography and implant stability parameters: a clinical study. *Clin Oral Implants Res* 2014;25:1016–21.
- [45] Wang S, Liu Y, Fang D, Shi S. The miniature pig: a useful large animal model for dental and orofacial research. *Oral Dis* 2007;13:530–7.
- [46] Degidi M, Daprile G, Piattelli A, Iezzi G. Development of a new implant primary stability parameter: insertion torque revisited. *Clin Implant Dent Relat Res* 2013;15:637–44.
- [47] Hui E, Chow J, Li D, Liu J, Wat P, Law H. Immediate provisional single-tooth implant replacement with Bra'nemark system: preliminary report. *Clin Implant Dent Relat Res* 2001;3:79–86.
- [48] Malo P, Rangert B, Dvarsater L. Immediate function of Bra'nemark implants in the esthetic zone: a retrospective clinical study with 6 months to 4 years of follow-up. *Clin Implant Dent Relat Res* 2000;2:138–46.
- [49] Horiuchi K, Uchida H, Yamamoto K, Sugimura M. Immediate loading of Branemark system implants following placement in edentulous patients: a clinical report. *Int J Oral Maxillofac Implants* 2000;15:824–30.
- [50] Ottoni JM, Oliveira ZF, Mansini R, Cabral AM. Correlation between placement torque and survival of single-tooth implants. *Int J Oral Maxillofac Implants* 2005;20:769–76.
- [51] Neugebauer J, Traini T, Thams U, Piattelli A, Zöller JE. Peri-implant bone organization under immediate loading state. Circularly polarized light analyses: a minipig study. *J Periodontol* 2006;77:152–60.
- [52] Meredith N, Book K, Friberg B, Jemt T, Sennerby L. Resonance frequency measurements of implant stability in vivo. A cross-sectional and longitudinal study of resonance frequency measurements on implants in the edentulous and partially dentate maxilla. *Clin Oral Implants Res* 1997;8:226–33.
- [53] Meredith N, Rasmussen L, Sennerby L, Alleyne D. Mapping implant stability by resonance frequency analysis. *Med Sci Res* 1996;24:191–3.
- [54] Meredith N, Alleyne D, Cawley P. Quantitative determination of the stability of the implant-tissue interface using resonance frequency analysis. *Clin Oral Implants Res* 1996;7:261–7.
- [55] Sennerby L, Meredith N. Implant stability measurements using resonance frequency analysis: biological and

- biomechanical aspects and clinical implications. *Periodontology* 2000 2008;47:51–66.
- [56] Dagher M, Mokbel N, Jabbour G, Naaman N. Resonance frequency analysis, insertion torque, and bone to implant contact of 4 implant surfaces: comparison and correlation study in sheep. *Implant Dent* 2014;23:672–8.
- [57] Park YS, Yi KY, Lee IS, Jung YC. Correlation between microtomography and histomorphometry for assessment of implant osseointegration. *Clin Oral Implants Res* 2005;16:156–60.
- [58] Roberts WE. Bone tissue interface. *J Dent Educ* 1988;52:804–9.
- [59] Turkyilmaz I. A comparison between insertion torque and resonance frequency in the assessment of torque capacity and primary stability of Brånemark system implants. *J Oral Rehabil* 2006;33:754–9.
- [60] Alsaadi G, Quirynen M, Michiels K, Jacobs R, van Steenberghe D. A biomechanical assessment of the relation between the oral implant stability at insertion and subjective bone quality assessment. *J Clin Periodontol* 2007;34:359–66.
- [61] Friberg B, Sennerby L, Roos J, Lekholm U. Identification of bone quality in conjunction with insertion of titanium implants. *Clin Oral Implants Res* 1995;6:213–9.
- [62] Turkyilmaz I, Tumer C, Ozbek EN, Tözüm TF. Relations between the bone density values from computerized tomography, and implant stability parameters: a clinical study of 230 regular platform implants. *J Clin Periodontol* 2007;34:716–22.
- [63] Nkenke E, Hahn M, Weinzierl K, Radespiel-Tröger M, Neukam FW, Engelke K. Implant stability and histomorphometry: a correlation study in human cadavers using stepped cylinder implants. *Clin Oral Implants Res* 2003;14:601–9.
- [64] da Cunha HA, Francischone CE, Filho HN, de Oliveira RC. A comparison between cutting torque and resonance frequency in the assessment of primary stability and final torque capacity of standard and TiUnite single-tooth implants under immediate loading. *Int J Oral Maxillofac Implants* 2004;19:578–85.
- [65] Schliephake H, Sewing A, Aref A. Resonance frequency measurements of implant stability in the dog mandible: experimental comparison with histomorphometric data. *Int J Oral Maxillofac Surg* 2006;35:941–6.
- [66] Ito Y, Sato D, Yoneda S, Ito D, Kondo H, Kasugai S. Relevance of resonance frequency analysis to evaluate dental implant stability: simulation and histomorphometrical animal experiments. *Clin Oral Implants Res* 2008;19:9–14.
- [67] Miyamoto I, Tsuboi Y, Wada E, Suwa H, Iizuka T. Influence of cortical bone thickness and implant length on implant stability at the time of surgery – clinical, prospective, biomechanical, and imaging study. *Bone* 2005;37:776–80.
- [68] Huwiler MA, Pjetursson BE, Bosshardt DD, Salvi GE, Lang NP. Resonance frequency analysis in relation to jawbone characteristics and during early healing of implant installation. *Clin Oral Implants Res* 2007;18:275–80.
- [69] Scarano A, Degidi M, Iezzi G, Petrone G, Piattelli A. Correlation between implant stability quotient and bone–implant contact: a retrospective histological and histomorphometrical study of seven titanium implants retrieved from humans. *Clin Implant Dent Relat Res* 2006;8:218–22.
- [70] Homolka P, Beer A, Birkfellner W, Nowotny R, Gahleitner A, Tschabitscher M, Bergmann H. Bone mineral density measurement with dental quantitative CT prior to dental implant placement in cadaver mandibles: pilot study. *Radiology* 2002;224:247–52.
- [71] Rebaudi A, Laffi N, Benedicenti S, Angiero F, Romanos GE. Microcomputed tomographic analysis of bone reaction at insertion of orthodontic mini-implants in sheep. *Int J Oral Maxillofac Implants* 2011;26:1233–40.
- [72] Östman PO, Hellman M, Wendelhag I, Sennerby L. Resonance frequency analysis measurements of implants at placement surgery. *Int J Prosthodont* 2006;19:77–83.
- [73] Meredith N, Shagaldi F, Alleyne D, Sennerby L, Cawley P. The application of resonance frequency measurements to study the stability of titanium implants during healing in the rabbit tibia. *Clin Oral Implants Res* 1997;8:234–43.
- [74] Majumdar S, Kothari M, Augat P, Newitt DC, Link TM, Lin JC, et al. High-resolution magnetic resonance imaging: three-dimensional trabecular bone architecture and biomechanical properties. *Bone* 1998;22:445–54.
- [75] Müller B, Bernhardt R, Weitkamp T, Beckmann F, Bräuer R, Schurig U, et al. Morphology of bony tissues and implants uncovered by high-resolution tomographic imaging. *Int J Mater Res* 2007;98:613–21.
- [76] Feldkamp LA, Goldstein SA, Parfitt AM, Jesion G, Kleerekoper M. The direct examination of three-dimensional bone architecture in vitro by computed tomography. *J Bone Miner Res* 1989;4:3–11.
- [77] Kuhn JL, Goldstein SA, Feldkamp LA, Goulet RW, Jesion G. Evaluation of a microcomputed tomography system to study trabecular bone structure. *J Orthop Res* 1990;8:833–42.
- [78] Sedlin ED, Hirsch C. Factors affecting the determination of the physical properties of femoral cortical bone. *Acta Orthop Scand* 1966;37:29–48.
- [79] Currey JD, Brear K, Zioupos P, Reilly GC. Effect of formaldehyde fixation on some mechanical properties of bovine bone. *Biomaterials* 1995;16:1267–71.
- [80] Nazarian A, Hermannsson BJ, Muller J, Zurakowski D, Snyder BD. Effects of tissue preservation on murine bone mechanical properties. *J Biomech* 2009;42:82–6.
- [81] Roberts WE, Helm FR, Marshall KJ, Gongloff RK. Rigid endosseous implants for orthodontics and orthopaedic anchorage. *Angle Orthod* 1989;59:247–56.
- [82] Stadlinger B, Ferguson SJ, Eckels U, Mai R, Lode AT, Loukota R, et al. Biomechanical evaluation of a titanium implant surface conditioned by a hydroxide ion solution. *Br J Oral Maxillofac Surg* 2010;50:74–9.
- [83] Gahlert M, Rohling S, Sprecher CM, Eichhorn S, Steinhäuser E, Wieland M, et al. Osseointegration of zirconia dental implants with a new rough surface. A biomechanical and histological study in mini pig. *Eur Cell Mater* 2008;16:34.
- [84] Davison KS, Siminoski K, Adachi JD, Hanley DA, Goltzman D, Hodsmann AB, et al. Bone strength: the whole is greater than the sum of its parts. *Semin Arthritis Rheum* 2006;36:22–31.
- [85] Cha JY, Kil JK, Yoon TM, Hwang CJ. Miniscrew stability evaluated with computerized tomography scanning. *Am J Orthod Dentofacial Orthop* 2010;137:73–9.
- [86] Bilhan H, Arat S, Geckili O. How precise is dental volumetric tomography in the prediction of bone density? *Int J Dent* 2012;2012:348908.

Angelo Cardarelli, Filippo Cardarelli, Raffaele Vinci, Enrico F. Gherlone

## Riabilitazioni estetiche complesse: case report

**Scopo:** per quanto il concetto di salute orale, non ci sono prove sul fatto che problemi orali percepiti abbiano influenza sulla qualità della vita in generale. La maggior parte degli studi hanno affrontato il concetto di salute orale correlata quali della vita come un fenomeno multidimensionale rappresentato dalla combinazione di limitazione funzionale, le percezioni del dolore e estetica apparato boccale e il suo rapporto con la malattia e la scarsa funzionalità orale. Prove da questi studi hanno anche indicato che il numero di denti rappresenta un importante ruolo determinante della salute personale orale. **Materiali e Metodi:** riportiamo il caso di una paziente di 50 anni in cui viene eseguita una riabilitazione proteica fissa su impianti e denti naturali nel mascellare superiore. Le ceramiche dentali presentano ottime capacità di riprodurre i denti naturali in materia di estetica e di biomeccanica. Il piano di trattamento è stato ideato per offrire una riabilitazione funzionale ed estetica dell'apparato stomatognatico e il miglioramento della qualità della vita. In una riabilitazione, tutte le alternative dovrebbero sempre essere illustrate al paziente, comprese le differenze di costo, i costi biologici, la longevità del lavoro eseguito, la durata del trattamento e la predicibilità del risultato estetico. Sulla base di questi fattori, il paziente è stato informato circa le possibili opzioni di trattamento. **Risultati e Conclusioni:** il caso presentato dimostra come sia fondamentale un approccio multidisciplinare nelle riabilitazioni complesse; il rispetto delle comuni conoscenze nel campo dell'impianto-protesi, in associazione ad alcuni particolari accorgimenti specifici come il rialzo trans-crestale del seno mascellare, l'utilizzo di materiali implantari e protesici di ultima generazione, permettono oggi al clinico di ottenere risultati estetici e funzionali di ottimo livello.

**PAROLE CHIAVE:** Riabilitazione, Impianti post-estrattivi, Odontoiatria estetica, Virtual planning, Mock-up.

### INTRODUZIONE

La qualità della vita è stata definita dall'OMS come "la percezione delle persone della loro posizione nella vita nel contesto dei sistemi di cultura e dei valori in cui vivono e in relazione ai loro obiettivi, le aspettative, le norme e le preoccupazioni".

Per quanto riguarda la salute orale, non ci sono prove sul fatto che i problemi orali percepiti influenzino

la qualità della vita in generale. La maggior parte degli studi hanno affrontato il concetto della salute orale correlata alla qualità della vita intesa come un fenomeno multidimensionale rappresentato dalla combinazione di limitazione funzionale, percezione del dolore ed estetica dentale.<sup>9</sup> I risultati di questi studi hanno anche indicato che il numero di denti ha un ruolo importante per la salute orale personale.<sup>10</sup>

Negli ultimi dieci anni, la tecnologia utilizzata in ambito odon-

toiatrico ha subito una rapida evoluzione, portando all'utilizzo di nuovi materiali da restauro che possano soddisfare le aspettative sempre più alte dei pazienti non tralasciando l'importanza della biocompatibilità.<sup>4-6</sup>

Pertanto, la decisione di utilizzare un determinato tipo di restauro deve essere presa valutando una serie di fattori correlati al paziente: le aspettative estetiche, le relazioni occlusali e la presenza di parafunzioni.

#### | Angelo Cardarelli

IRCSS Ospedale San Raffaele Milano  
Dipartimento di Odontoiatria San Raffaele Dental Clinic  
Direttore Prof. E.F. Gherlone  
Università Vita-Salute San Raffaele, Milano;  
Corso di Laurea Magistrale in Odontoiatria e Protesi  
Dentaria  
Presidente: Prof. E.F. Gherlone

#### | Filippo Cardarelli

Libero Professionista  
Isernia

#### | Raffaele Vinci

IRCSS Ospedale San Raffaele Milano  
Dipartimento di Odontoiatria San Raffaele Dental Clinic  
Direttore Prof. E.F. Gherlone  
Università Vita-Salute San Raffaele, Milano;  
Corso di Laurea Magistrale in Odontoiatria e Protesi  
Dentaria  
Presidente: Prof. E.F. Gherlone

#### | Enrico F. Gherlone

IRCSS Ospedale San Raffaele Milano  
Dipartimento di Odontoiatria San Raffaele Dental Clinic  
Direttore Prof. E.F. Gherlone  
Università Vita-Salute San Raffaele, Milano;  
Corso di Laurea Magistrale in Odontoiatria e Protesi  
Dentaria  
Presidente: Prof. E.F. Gherlone

#### | Corrispondenza:

Angelo Cardarelli  
Ospedale San Raffaele Dental Clinic  
Via Olgettina, 48 - Milano  
angelo\_cardarelli@libero.it



Cardarelli A | Cardarelli F | Vinci R | Gherlone EF

La valutazione delle aspettative del paziente e la pianificazione delle possibili soluzioni terapeutiche rappresentano un momento importante prima di intraprendere qualsiasi tipo di terapia. L'analisi delle caratteristiche del viso e della dinamicità delle labbra in rapporto ai denti rappresenta il punto di partenza della riabilitazione protesica.<sup>7,8</sup> L'aspetto dentale e gengivale completano l'analisi estetica, fornendo all'odontoiatra le informazioni necessarie ad effettuare le scelte terapeutiche più appropriate per ogni singolo caso. I pazienti che si rivolgono alla nostra osservazione lamentano spesso problemi estetici spesso limitando il trattamento alla sola terapia protesica. Se la compromissione estetica è determinata da un quadro clinico più complesso, sarà compito del dentista illustrare al paziente che la risoluzione del suo problema andrà inserita in un quadro riabilitativo più ampio.<sup>1-3</sup>

In questo articolo viene illustrato un caso clinico di una riabilitazione implantare e su denti naturali con restauri in zirconia-ceramica in una paziente di 50 anni, con conseguente miglioramento

della qualità della vita negli aspetti sia funzionali che psicosociali.

## MATERIALI E METODI

### Descrizione del caso

Paziente di sesso femminile, età 50 anni, si è presentata presso la nostra struttura esprimendo la necessità di migliorare l'estetica del suo sorriso e lamentando sintomatologia algica a carico dell'elemento 1.1. All'anamnesi non si registrano patologie di rilievo.

All'esame clinico e radiografico si evidenzia nell'arcata superiore la presenza di vecchi restauri protesici incongrui con compromissione a carico dell'elemento 1.1 che presenta una frattura radicolare, nell'arcata inferiore invece assenza degli elementi 4.6-4.7-3.7 (Figg. 1-3a,b). Pertanto in accordo con la paziente si redige il seguente piano di trattamento che prevede per l'arcata superiore l'avulsione dell'elemento 1.1 che verrà sostituito con un impianto, rimozione dei vecchi restauri protesici e riabilitazione implantoprotetica con inserimento di numero 3 impianti in sede 1.4-2.4-2.5, faccette estetiche

in ceramica sugli elementi 1.2-1.3-2.1-2.2. Nell'arcata inferiore invece la paziente decide di non sottoporsi a nessun trattamento. La progettazione del caso clinico è stata eseguita mediante l'utilizzo del Digital Smile Design, con l'impiego della piattaforma Mac OS X e del programma Keynote. Le fotografie e i video raccolti sono stati scaricati e inseriti nella presentazione di Keynote, quindi si è proceduto all'analisi estetica digitale del volto e del sorriso ed all'elaborazione virtuale della riabilitazione protesica, utilizzando delle "smile library", costituite da prototipi di denti, di forma e dimensioni diverse. Il progetto virtuale viene inviato al laboratorio; rilevate le impronte delle arcate dentarie del paziente, viene fabbricato un modello in gesso dei denti sul quale viene modellata la nuova sagomatura dei denti corrispondente allo studio eseguito con lo Smile Design. Su questo modello cerato viene poi stampata una mascherina di silicone, che fungerà da stampo per fabbricare la mascherina in resina acrilica che il paziente indosserà direttamente sui propri denti, facendogli visualizzare immediatamente quello che sarà il risultato estetico finale. Sulla base del

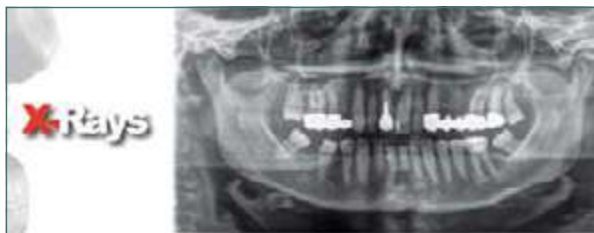


Fig. 1 Ortopanoramica Iniziale.

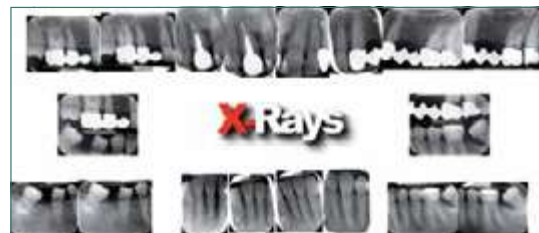
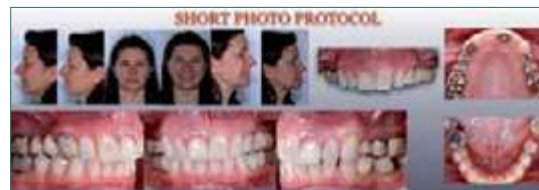
Fig. 2 Full Radiografico.



Fig. 3a,b Documentazione fotografica iniziale.





mock-up e delle modifiche ad esso apportate, vengono realizzati dapprima i provvisori ed infine il manufatto protesico definitivo (Figg. 4-7).

**Procedure chirurgiche e protesiche**

Alla paziente viene somministrata una profilassi antibiotica di 2 g di amoxicillina e acido clavulanico 1 ora prima della sedu-

ta operatoria. Previa infiltrazione plessica di soluzione anestetica contenente articaina 1:100.000 del primo e secondo quadrante, si scoliscono lembi a tutto spessore e si procede all'inserimento di numero 3 impianti WINSIX sommersi in sede 1.4 e in sede 2.4-2.5 con mini rialzo di seno secondo la tecnica di Summer. Si procede quindi all'avulsione dell'elemento 1.1 ed inserimento di un impianto nella stessa seduta con protesizzazione immediata. I lembi vengono suturati con punti staccati in seta 4/0 (Figg. 8-10). Subito dopo la fase

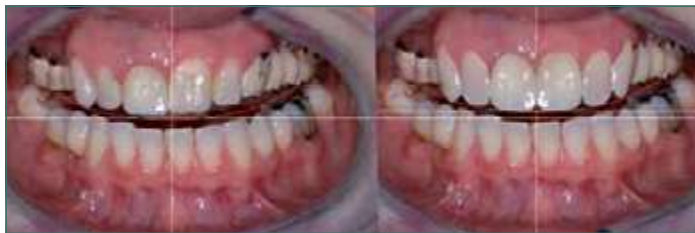
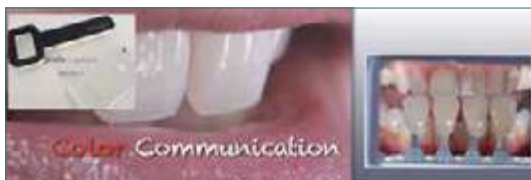
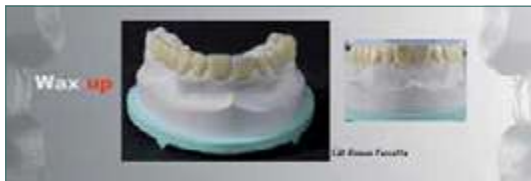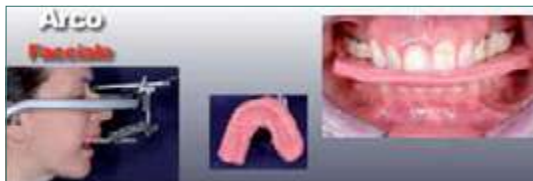Fig. 4 Digital Smile Design.



Figg. 5a-d Procedure protesiche.



Fig. 6



Fig. 7 Pre-post mock-up.

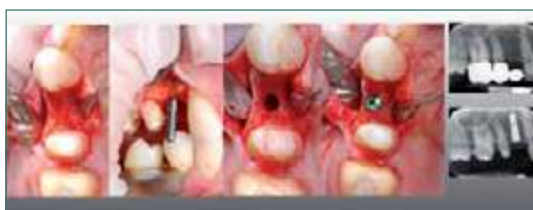

Fig. 8 Inserimento impianto in sede 1.4.

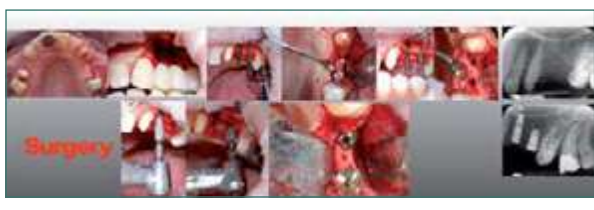

Fig. 9 Inserimento impianti in sede 2.4-2.5 con mini rialzo.

Cardarelli A | Cardarelli F | Vinci R | Gherlone EF

chirurgica, si ribasa un provvisorio armato in resina acrilica precedentemente preparato sulla base della creatura diagnostica e del progetto virtuale (DSD), che viene cementato sugli elementi dentari residui (Fig. 11).

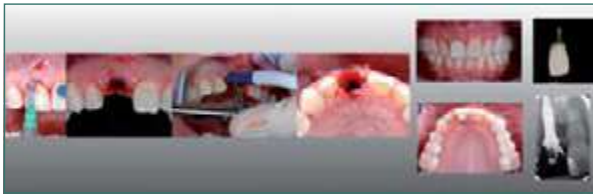La paziente viene così dimessa con terapia farmacologica di supporto antibiotica e antidolorifica e le suture rimosse in settimana giornata. Dopo 4 mesi dalla fase chirurgica, stabilizzati i tessuti ed avvenuta l'osteointe-

grazione si procede alla riapertura degli impianti, quindi vengono prese le impronte e si procede al confezionamento di un secondo provvisorio a supporto implantare (Figg. 12-14).

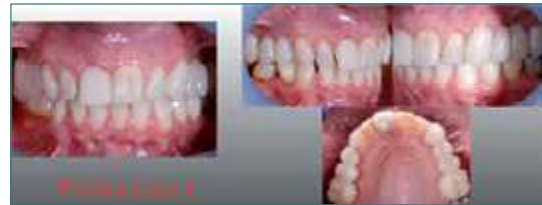A distanza di 3 mesi dal secondo provvisorio vengono prese le impronte definitive e vengono realizzate corone singole in zirconia-ceramica sugli elementi 1.1-1.4-1.5-1.6 e 2.3-2.4-2.5-2.6-2.7 e faccette sugli elementi 1.2-1.3-2.1-2.2 (Figg. 15-17).

## DISCUSSIONE

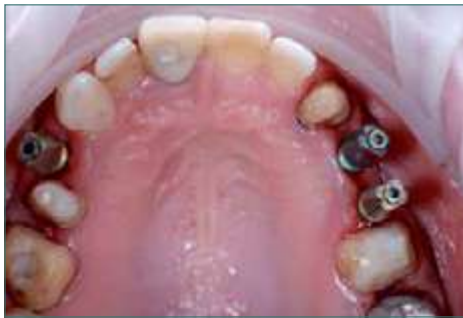Oggi l'armonia del sorriso è sempre più considerata un risultato imprescindibile e la funzione deve necessariamente essere affiancata da una sufficiente attenzione al dettaglio estetico al fine di ottenere un outcome finale naturale. La valutazione delle aspettative del paziente e la sua comprensione sono un momento cruciale prima di intraprende-



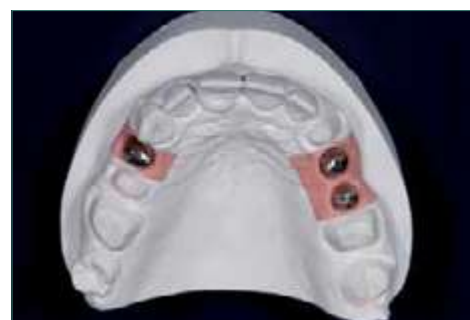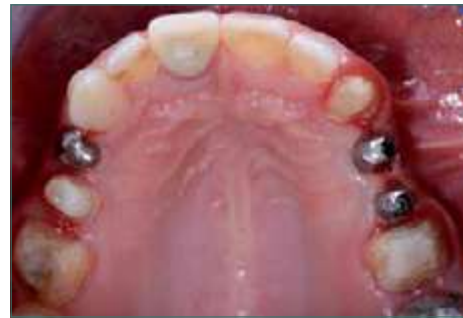**Fig. 10** Avulsione dell'elemento 1.1 ed inserimento di impianto con protesizzazione immediata.



**Fig. 11** Provvisorio post-chirurgia.

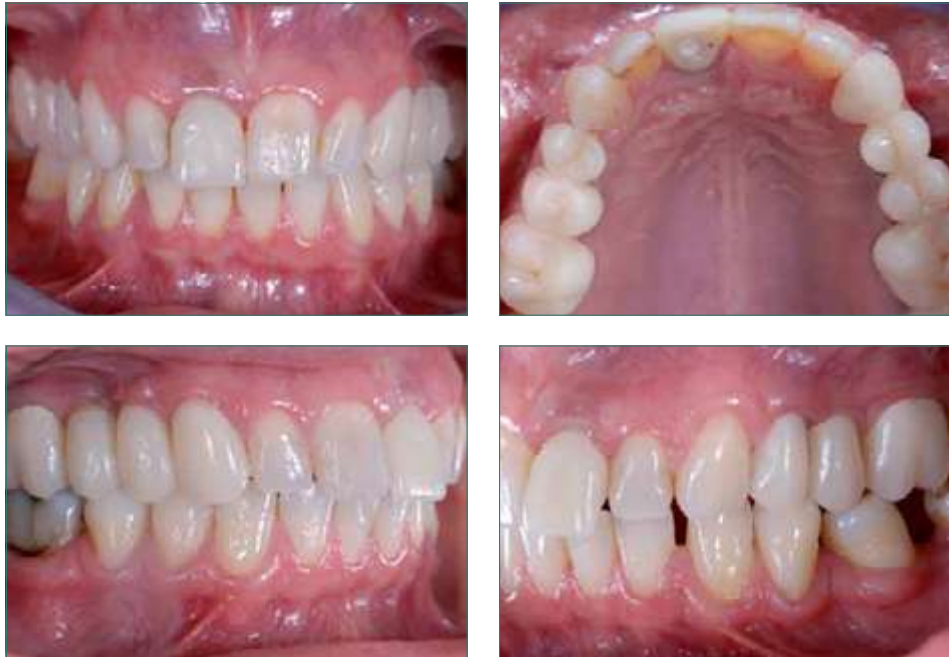

**Figg. 12a,b** Impronte degli impianti e monconi definitivi.

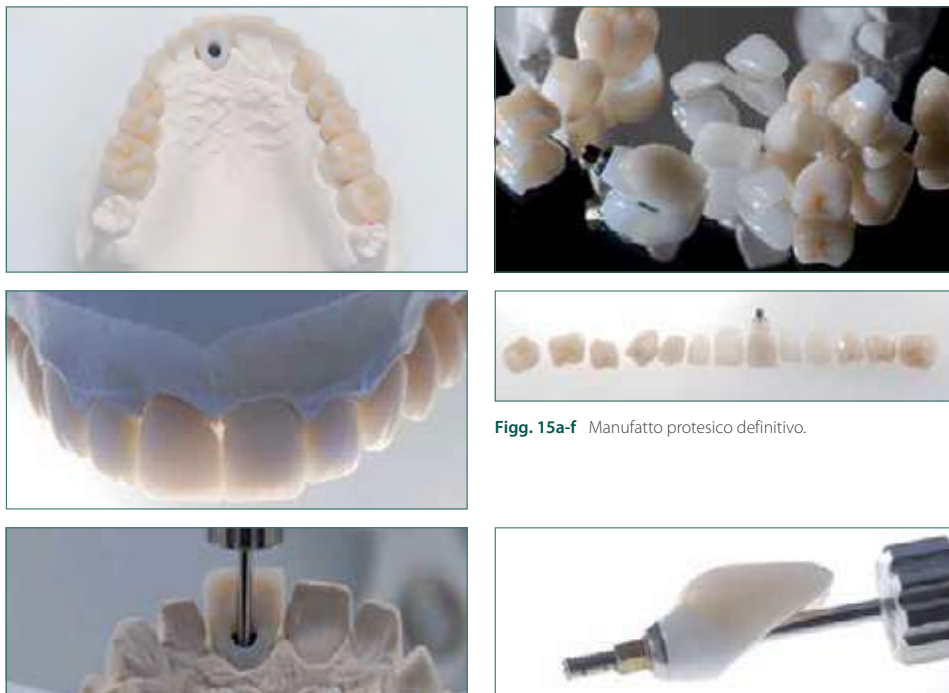


**Figg. 13a,b** Monconi definitivi e provvisori.

Cardarelli A | Cardarelli F | Vinci R | Gherlone EF

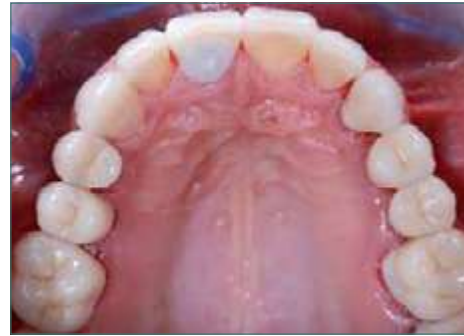
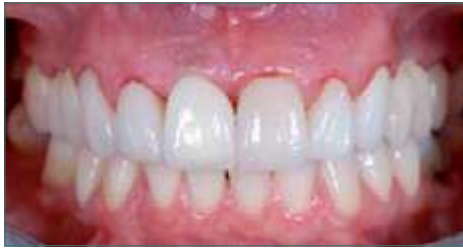
Figg. 14a-d Secondi provvisori.

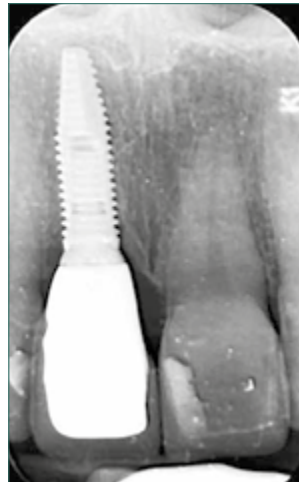
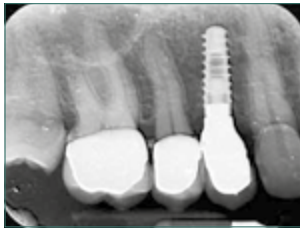
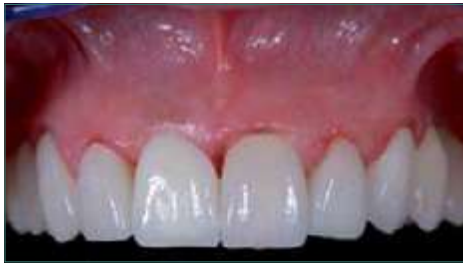Figg. 15a-f Manufatto protesico definitivo.

Cardarelli A | Cardarelli F | Vinci R | Gherlone EF



Figg. 16a-c Finalizzazione protesica.



Figg. 17a-c Rx finale.

re qualsiasi trattamento. L'analisi relativa dei fattori quali il sorriso, la composizione dentale ideale, i livelli gengivali e i materiali di ultima generazione rappresentano solo una parte del complesso di procedure necessarie alla finalizzazione estetica ottimale, costituiscono tuttavia un punto di partenza fondamentale in ogni piano di trattamento complesso.

## CONCLUSIONI

Il caso presentato dimostra come sia fondamentale un approccio multidisciplinare nelle riabilitazioni complesse; il rispetto delle comuni conoscenze nel campo dell'impianto-protesi, in associazione ad alcuni particolari accorgimenti specifici come il rialzo trans-crestale del

seno mascellare, l'utilizzo di materiali implantari e protesici di ultima generazione, permettono oggi al clinico di ottenere risultati estetici e funzionali di ottimo livello. Il criterio base per il successo implanto-protesico a lungo termine è stato e rimane il posizionamento protesicamente guidato degli impianti, che garantisce un'estetica e una biomeccanica ideale.



## BIBLIOGRAFIA

1. Tauheed S, Shaikh A, Fida M. Microaesthetics of The Smile: Extraction vs. Non-extraction. *J Coll Physicians Surg Pak*. 2012 Apr;22(4):230-4. doi: 04.2012/JCPSP230234.
2. Van Dooren E, Calamita M, Calgario M, Coachman C, Ferencz JL, Pinho C, Silva NR. Mechanical, biological and clinical aspects of zirconia implants. *Eur J Esthet Dent*. 2012 Winter;7(4):396-417.
3. Coachman C, Salama M, Garber D, Calamita M, Salama H, Cabral G. Prosthetic gingival reconstruction in fixed partial restorations. Part 3: laboratory procedures and maintenance. *Int J Periodontics Restorative Dent*. 2010 Feb;30(1):19-29.
4. Coachman C, Salama M, Garber D, Calamita M, Salama H, Cabral G. Prosthetic gingival reconstruction in fixed partial restorations. Part 3: laboratory procedures and maintenance. *Int J Periodontics Restorative Dent*. 2010 Feb;30(1):19-29.
5. Touchstone A, Nieting T, Ulmer N. Digital transition: the collaboration between dentists and laboratory technicians on CAD/CAM restorations. *J Am Dent Assoc*. 2010 Jun;141 Suppl 2:155-95.
6. McLaren EA, Cao PT. Smile Analysis and Esthetic Design: "In the Zone", *Inside Dentistry* 2009; 6,7.
7. Coachman C, Van Dooren E. An integrated cosmetic treatment plan: soft tissue management and metal-free restoration. *Pract Proced Aesthet Dent*. 2009 Jan-Feb;21(1):29-33.
8. Goldstein RE, Decker BC. *Esthetics in Dentistry*. Vol.1: Principles, Communication, Treatment, Methods. 1998
9. Rufenacht CR. *Fundamentals of Esthetics*, Chicago: Quintessence; 1990.
10. da Silva GR, Roscoe MG, Ribeiro CP, da Mota AS, Martins LR, Soares CJ. Impact of rehabilitation with metal-ceramic restorations on oral health-related quality of life. *Braz Dent J*. 2012;23(4):403-8.

Angelo Cardarelli, Filippo Cardarelli, Raffaele Vinci, Enrico F. Gherlone

## Aesthetic Complex Rehabilitations: case report

**Aim:** Regarding to oral health research, there is little evidence about whether perceived or normative oral problems influence on the quality of life generally. Most studies have addressed oral health related-quality of life as a multidimensional phenomenon represented by the combination of functional limitation, pain perceptions and aesthetics mouthparts and its relationship to disease and poor oral function. Evidence from these studies have also indicated that the number of teeth represents a major role as a determinant of subjective oral health. **Material and Methods:** We report the case of a patient of 50 years in which you run a prosthetic implant- supported fixed and a fixed prosthetic rehabilitation on natural teeth in upper jaw. Dental ceramics present excellent ability to reproduce the natural teeth regarding esthetic and biomechanics. The treatment plan was established to provide functional and aesthetic rehabilitation of the stomatognathic system and improvement of the quality of life. In a rehabilitation procedure, all alternatives should always be explained to the patient, including the cost differences, the levels of tooth tissue removal, the expected clinical longevity, the time to conclude the treatment, and the predictability of the aesthetic result. Based on these factors, the patient was informed about the possible treatments options. **Results and Conclusions:** The case presented demonstrates how fundamental a multidisciplinary approach in the complex rehabilitation ; compliance with the common knowledge in the field implant - prostheses, in combination with some special precautions such as raising specific trans - crestal sinus, the use of prosthetic implant materials and the latest generation, now allow the clinician to obtain aesthetic results and functional excellent.

**KEY WORDS:** Rehabilitation, Post-extraction implants, Aesthetic dentistry, Virtual planning, Mock-up.



## CASO CLINICO

## Studio clinico sulle riabilitazioni a ridotto numero di impianti solidarizzati a carico immediato

*Clinical study on rehabilitation a reduced number of implants solidarized with immediate loading*



Angelo\_Cardarelli@libero.it



Protesi in resina acrilica, All on Four, protesi con rinforzo in metallo, impianti inclinati.

Acrylic resin prosthesis, All on Four, prosthesis with metal framework, tilted implants.

## SCOPO DEL LAVORO

Lo scopo di questo studio è quello di comparare protesi in resina acrilica, con o senza struttura in metallo, immediatamente caricate e supportate da impianti assiali e inclinati, in pazienti totalmente edentuli, dopo 3 anni dal carico.

## MATERIALI E METODI

I pazienti selezionati per questo studio sono totalmente o parzialmente edentuli in una o entrambe le arcate e con severa atrofia delle regioni posteriori. Tutti i pazienti hanno immediatamente ricevuto una riabilitazione protesica, ognuna delle quali supportata da quattro impianti (due assiali e due inclinati). I pazienti sono stati selezionati casualmente per ricevere una protesi definitiva con una struttura in metallo o una in sola resina acrilica. Sono state effettuate visite di controllo fino a 36 mesi dopo l'inserzione degli impianti. Sono stati arruolati 54 pazienti e sono state posizionate 66 protesi a carico immediato, ognuna supportata da quattro impianti (in totale 264 impianti). In tutto sono state confezionate 31 protesi in sola resina acrilica e 35 protesi con struttura in metallo.

## RISULTATI E CONCLUSIONI

La percentuale di sopravvivenza a 3 anni degli impianti assiali è del 98,5%, del 97,76% per quelli inclinati, del 97,5% per quelli posizionati nel mascellare superiore e del 98,61% per il mascellare superiore. Non si riscontrano fallimenti protesici benché quattro protesi totalmente in resina acrilica abbiano presentato incrinature nel materiale. Non sono state riscontrate significative differenze nella perdita di osso perimplantare tra gli impianti assiali e inclinati in entrambe le arcate. Lo stesso risultato clinico è stato riscontrato per i pazienti trattati con il cosiddetto protocollo "All on Four", indipendentemente dal fatto che il ripristino della resina acrilica fosse rinforzata con metallo.

La riabilitazione implantoprotetica a carico immediato di un mascellare edentulo è una possibilità terapeutica con un elevato indice di successo e soddisfazione per l'operatore e per il paziente (1, 2). Tuttavia l'anatomia dei mascellari, i fisiologici processi di pneumatizzazione dei seni mascellari, i danni parodontali e iatrogeni rappresentano delle limitazioni alle riabilitazioni convenzionali dei pazienti edentuli che necessiterebbero di trattamenti di rigenerazione ossea preimplantare. Tali metodiche sono da considerarsi per i pazienti ad alto costo biologico ed economico, con elevata morbilità ed operatore dipendenti.

Per queste ragioni gli attuali orientamenti implantari vertono verso protocolli clinici che sfruttano l'osso basale residuo senza necessità di alcun genere di rigenerazione. Tali metodiche, ben supportate da dati scientifici, prevedono un immediato ripristino della funzione tramite il posizionamento di impianti a carico immediato (3, 4, 5).

Il protocollo "All on Four" richiede il posizionamento di quattro impianti, due anteriori "dritti" e due posteriori tiltati posti nell'osso basale dei mascellari. Tale tecnica viene utilizzata in pazienti affetti da grave atrofia senza la necessità di alcuna rigenerazione ossea. Le riabilitazioni a numero ridotto di impianti, siano essi inclinati o meno, sono comprovate da numerosi studi scientifici che dimostrano come quattro impianti siano sufficienti a supportare una protesi ad arcata completa. La validazione dell'utilizzo di impianti tiltati permette di posizionare impianti più lunghi, in regioni che presentano qualità ossee migliori con ancoraggio corticale e diminuendo il cantilever protesico (6, 7, 8).



Angelo Cardarelli

Antonio Ligabue  
Andrea Rapanelli  
Paolo Capparè  
Raffaele Vinci

Dipartimento di Odontoiatria, IRCSS Ospedale San Raffaele, Milano  
Direttore: professor E.F. Gherlone  
Corso di Laurea in Odontoiatria e Protesi Dentaria Università Vita-Salute San Raffaele, Milano  
Presidente: professor E.F. Gherlone



## CASO CLINICO

Poiché il carico immediato di impianti inclinati ed assiali con posizionamento di una protesi provvisoria immediata è proposto come metodo prevedibile, veloce ed economico per trattare le atrofie dei mascellari, lo scopo di questo studio è di comparare la riabilitazione protesica di una protesi definitiva con supporto in metallo con una protesi totalmente in resina acrilica, entrambe immediatamente caricate e supportate da due impianti mediani assiali e due impianti distali inclinati dopo tre anni dal posizionamento.

## MATERIALI E METODI

## Selezione dei pazienti

Questo studio clinico è stato eseguito nel dipartimento di Odontoiatria dell'Ospedale San Raffaele di Milano. I pazienti dovevano presentare un buono stato di salute, essere edentuli (una o entrambe le arcate) o essere resi edentuli per la presenza di elementi dentari gravemente compromessi. Tutti esibivano una severa atrofia del mascellare superiore o inferiore. I criteri di esclusione riguardavano la presenza di una qualsiasi infezione attiva o di una severa infiammazione delle aree destinate al posizionamento dell'impianto, di malattie croniche sistemiche, di consumo di 15 o più sigarette al giorno, di bruxismo e di una scarsa igiene orale.

I pazienti sono in possesso di esami radiografici di primo (OPT) e secondo livello (TAC O CBCT) e hanno sottoscritto il consenso per questo tipo di riabilitazione.

## Procedure chirurgiche

Un'ora prima dell'intervento, ai pazienti viene somministrato 1 g di amoxicillina (Zimox, Pfizer Italia), da assumere 1 g due volte al giorno, per i successivi 6 giorni. Le procedure chirurgiche vengono eseguite in anestesia locale, optocaina 20 mg/mL con adrenalina 1:80,000.

A livello mandibolare si procede ad un'incisione crestale dalla zona del primo molare destro al primo molare sinistro con due scarichi distali ed allo scollamento mucoperiosteo finalizzato a mettere in evidenza l'emergenza dei fori mentonieri. Gli impianti posteriori, di diametro 3,8 mm

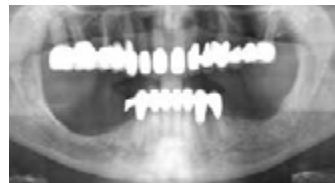

Fig. 1 Radiografia preoperatoria.

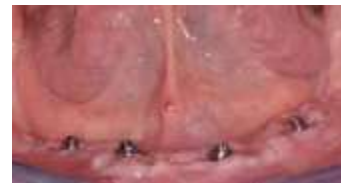

Fig. 2 Controllo dopo una settimana.

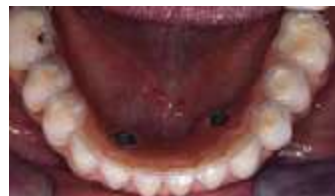

Fig. 3 La protesi avvitata: vista oclusale.

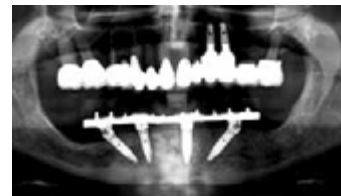


Fig. 4 Radiografia postoperatoria.

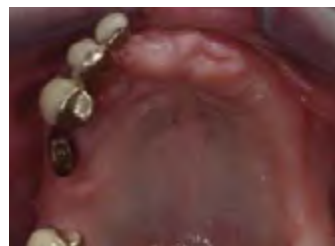

Fig. 5 Arcata mascellare superiore.

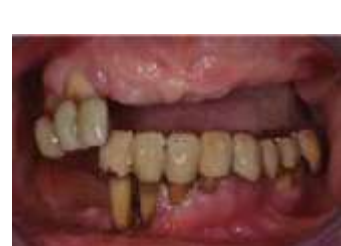

Fig. 6 Arcata superiore e inferiore da riabilitare.

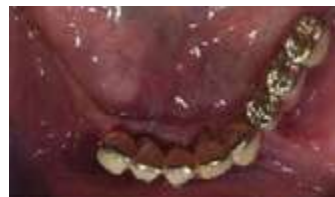

Fig. 7 Arcata mascellare inferiore.

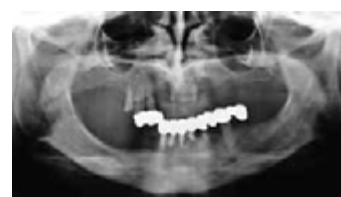

Fig. 8 Rx OPT pre intervento.

e lunghezza 15 o 13 mm, sono posizionati al di sopra del foro mentoniero ed inclinati mesialmente di 30-45 gradi rispetto al piano oclusale. Gli impianti posteriori, generalmente emergono nella posizione del secondo premolare (figg. 1, 2, 3 e 4).

A livello del mascellare superiore la tecnica prevede l'incisione dalla zona del primo molare superiore destro al primo molare superiore sinistro con scarico distale ed il sollevamento di un lembo a tutto spesso-

re. Gli impianti posteriori sono posizionati vicini e paralleli alla parete anteriore del seno mascellare; in genere questi impianti sono inclinati distalmente approssimativamente tra i 30 e i 35 gradi. Successivamente si procede ad allocare gli impianti anteriori assiali. Gli impianti posteriori erano 3,8 mm di diametro e 15 o 13 mm di lunghezza e quelli anteriori 3,8 mm di diametro e di lunghezza compresa tra gli 11 ed i 15 mm (figg. 5-11).

## CASO CLINICO

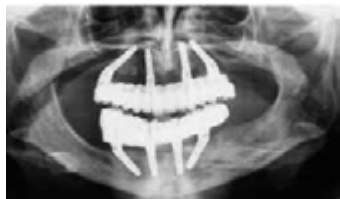

Fig. 9 Radiografia di controllo a 36 mesi.

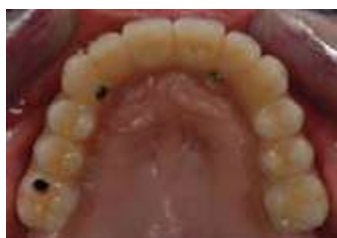

Fig. 10 Protesi arcata superiore.

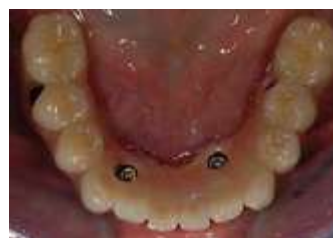

Fig. 11 Protesi arcata inferiore.

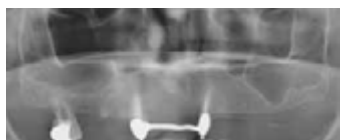

Fig. 12 Rx OPT pre intervento.

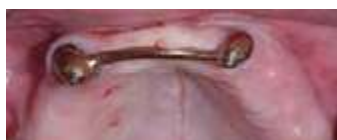

Fig. 13 Mascellare superiore, visione preoperatoria.



Fig. 14 I quattro impianti posizionati. Da notare l'inclinazione di circa 45° degli impianti distali.

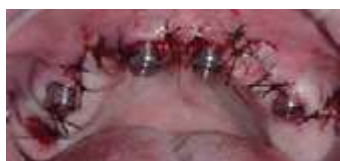

Fig. 15 Healing abutment e sutura in seta.

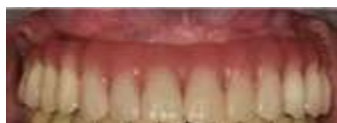

Fig. 16 La protesi acrilica posizionata a distanza di 6 mesi.

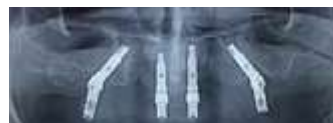

Fig. 17 Radiografia di controllo a 6 mesi.

Al fine di ottenere un adeguato torque di inserzione la cavità implantare è adeguatamente preparata e tutti gli impianti posizionati presentano un torque minimo di 25 nm.

Per gli impianti anteriori sono posizionati monconi dritti o angolati a 17 gradi, mentre per quelli posteriori a 30 gradi per compensare la mancanza di parallelismo tra le fixture. Questi gradi di angolazione sono scelti per consentire al foro di accesso della vite protesica una posizione oclusale o linguale rispetto ai denti montati sulla protesi provvisoria. La sutura è eseguita con fili 4/0 non riassorbibili (figg. 12-17).

#### Protocollo protesico

Prima dell'intervento viene realizzata una protesi totale in base al set up diagnostico, la cui dimensione verticale è stabilita e corretta dalle impronte studio e dallo studio cefalometrico. Al termi-

ne dell'intervento vengono rilevate le impronte degli impianti e la registrazione oclusale utilizzando la protesi preconfezionata. Entro le 72 ore dopo l'intervento è consegnato il manufatto protesico definitivo avvitato.

In base ad una selezione casuale i pazienti trattati hanno ricevuto protesi avvitata definitive totalmente in resina acrilica o manufatti rinforzati da una struttura metallica, entrambe le tipologie di epitesi presentano in genere cantilever fino al primo molare.

#### Follow up

Tutti i pazienti seguono una dieta semi solida per i 2 mesi successivi all'intervento (evitando pane e carne) e devono rispettare un protocollo di follow up, eseguito da una igienista dentale, a 3, 6, 9, 12, 24 e 36 mesi dopo l'intervento.

Il successo della riabilitazione è definito dal seguente criterio: assenza di fratture

della struttura in resina anche in caso di fallimento implantare di una o due fixture. Durante ogni visita di controllo è valutata la sopravvivenza implantare, definita come assenza di mobilità della fixture, di dolore e di gonfiore nella zona operata. Il successo implantare è definito come la sopravvivenza con l'aggiunta di una perdita marginale dell'osso inferiore a 1,5 mm dopo un anno di carico e di non più di 2 mm tra ogni singola visita di controllo a seguire dai primi 12 mesi dall'intervento.

Ad ogni seduta di controllo viene eseguita una radiografia OPT. Le valutazioni dell'osso perimplantare sono state eseguite mesialmente e distalmente alla fixture utilizzando le giunzioni con i monconi come punto di riferimento. Al fine di correggere la distorsione delle radiografie la reale lunghezza degli impianti è stata comparata con la lunghezza radiografica delle fixture.

## CASO CLINICO

## RISULTATI

I 54 pazienti, di cui 33 donne e 21 uomini, con un'età media di 55,9 anni (range tra 43 e 83 anni), sono stati casualmente selezionati per questo studio e trattati con 66 riabilitazioni implantoprotesiche a carico immediato, 36 mascellari e 30 mandibolari. Ogni riabilitazione è supportata da 4 impianti per un totale quindi di 264 impianti. 12 pazienti hanno richiesto protesi sia al mascellare che alla mandibola. 31 protesi in resina acrilica avvitate e 35 protesi con strutture definitive in metallo sono state consegnate ai pazienti.

Durante i primi 4 mesi, dopo il posizionamento degli impianti, 5 impianti sono stati persi, 2 mascellari e 3 mandibolari, 3 di essi inclinati e 2 assiali.

La percentuale di sopravvivenza a 3 anni degli impianti assiali è del 98,5%, del 97,76% per quelli inclinati, del 97,5% per quelli posizionati nel mascellare superiore e del 98,61% per il mascellare inferiore. Non si riscontrano fallimenti protesici benché quattro protesi totalmente in resina acrilica abbiano presentato incrinature nel materiale.

Alla valutazione dei 36 mesi, la perdita dell'osso perimplantare riscontra una media di  $1,10 \pm 0,45$  mm per gli impianti assiali mascellari e  $1,11 \pm 0,32$  per gli impianti inclinati mascellari.

## DISCUSSIONE E CONCLUSIONI

I dati del presente studio forniscono incoraggianti risultati clinici per quanto riguarda le riabilitazioni implantoprotesiche full arch a carico immediato con quattro impianti. Nonostante cinque pazienti abbiano avuto fallimenti implantari la sopravvivenza implantare media è paragonabile a quelle descritte in letteratura (6, 7, 17).

Lo studio radiografico comparativo mostra come il rimodellamento e riassorbimento osseo perimplantare sia comparabile tra le fixture assiali e quelle tiltate come già dimostrato da altri autori (9, 10, 11). Questi risultati positivi si sommano ai vantaggi biomeccanici dati dalla diminuzione del cantilever e dalla possibilità di posiziona-

re impianti più lunghi ed in aree dei mascellari caratterizzate da una buona qualità ossea. Evitare qualsiasi genere di intervento di rigenerazione ossea significa una minor morbilità ed un drastico calo dei costi. Il periodo post chirurgico risulta maggiormente confortevole per i pazienti poiché utilizzano subito dopo l'intervento le protesi a carico immediato.

In questo studio sono state realizzate 66 protesi, di cui 35 con rinforzo metallico e 31 senza, prive di alcun fallimento protesico benché 3 protesi in sola resina acrilica abbiano evidenziato delle rotture del materiale; le epitesi non hanno presentato alcuna frattura nemmeno a seguito dei fallimenti implantari.

Alcuni autori affermano che le protesi con rinforzo metallico sono significativamente più resistenti, migliorano il follow up e la sopravvivenza implantare (12, 13, 14), mentre altri autori dichiarano che l'assenza di rinforzo metallico permette un miglior assorbimento dei traumi occlusali e diminuiscono i traumi da sovraccarico degli impianti (15, 16). In letteratura sono presenti articoli che asseriscono una miglior sopravvivenza implantare di manufatti con rinforzo e altri che dichiarano un elevato successo delle fixture caricate con protesi totalmente in resina acrilica (9, 14). Nonostante non ci siano uniformi risultati clinici in letteratura questo studio dimostra che il carico immediato di protesi supportate da 4 impianti dà risultati sovrapponibili sia che i manufatti siano completamente in resina acrilica che le protesi presentino un rinforzo in resina. Studi clinici con follow up a lungo termine e con un maggior numero di pazienti arruolati potrebbero fornire nuove informazioni riguardo la necessità di rinforzi metallici o meno, comunque in accordo con la letteratura questo studio dimostra che il protocollo "all on four" presenta un elevato successo clinico. ●

## AIM OF THE WORK

The aim of this study was to compare definitive acrylic resin prostheses, with or without a cast metal framework that were immediately loaded and supported by axial and tilted implants

in completely edentulous patients after 3 years of function patients who were completely or partially edentulous in one or both arches with severe atrophy of the posterior regions were selected for this study.

## MATERIALS AND METHODS

All patients immediately received prosthetic rehabilitations, each supported by four implants (two axial and two tilted). The patients were randomized to receive a definitive prosthesis with a cast metal framework or one made of acrylic resin only. Follow-up visits were performed up to 36 months after implant insertion and included radiographic assessments of bone levels around the implants. 54 patients participated, and were placed 66 implants in immediate loading, each supported by four implants (total 264 plants). In all, 31 prostheses implants in one acrylic resin and 35 prostheses with metal frame, were packed.

## RESULTS AND CONCLUSIONS

The survival rate at three years of the axial installations is of 98.5%, of 97.76% for those inclined, 97.5% for those located in the maxilla and of 98,61% for the maxilla. There is no observed failures, although four prosthetic implants totally acrylic resin have submitted cracks in the material. No significant differences were found in the loss of peri-implant bone between axial and tilted implants in both arches. Conclusions: the same clinical result was found for patients treated with the so-called protocol "All on Four", regardless of the fact that the restoration of the acrylic resin was reinforced with metal.

## BIBLIOGRAFIA

1. Schnitman PA, Wöhrle PS, Rubenstein JE, DaSilva JD, Wang NH. Ten-year results for Brånemark implants immediately loaded with fixed prostheses at implant placement. *Int J Oral Maxillofac Implants* 1997;12:495-503.
2. Capelli M, Zuffetti F, Del Fabbro M, Testori T. Immediate rehabilitation of the completely edentulous jaw with fixed prostheses supported by either upright or tilted implants: A multicenter clinical study. *Int J Oral Maxillofac Implants* 2007;22:639-44.
3. Hinze M, Thalmair T, Bolz W, Wachtel H. Immediate loading of fixed provisional prostheses using four implants for the rehabilitation of the edentulous arch: A prospective clinical study. *Int J Oral Maxil-*

## CASO CLINICO

---

- lofac Implants 2010;25:1011-8.
4. Chiapasco M. Early and immediate restoration and loading of implants in completely edentulous patients. *Int J Oral Maxillofac Implants* 2004; 19(suppl):76-91.
  5. Del Fabbro M, Testori T, Francetti L, Taschieri S, Weinstein R. Systematic review of survival rates for immediately loaded dental implants. *Int J Periodontics Restorative Dent* 2006;26:249-63.
  6. Malo P, Rangert B, Nobre M. "All-on-Four" immediate function concept with Brånemark system implants for completely edentulous mandibles: A retrospective clinical study. *Clin Implant Dent Res* 2003; 5(suppl 1):2-9.
  7. Malo P, Rangert B, Nobre M. All-on-4 immediate function concept with Brånemark system implants for completely edentulous maxillae: A 1-year retrospective clinical study. *Clin Implant Dent Relat Res* 2005;7(suppl 1):S88-S94.
  8. Duyck J, Van Oosterwyck H, Vander Sloten J, De Cooman M, Puers R, Naert I. Magnitude and distribution of occlusal forces on oral implants supporting fixed prostheses: An in vivo study. *Clin Oral Implants Res* 2000;11:465-75.
  9. Aparicio C, Perales P, Rangert B. Tilted implants as an alternative to maxillary sinus grafting. *Clin Implant Dent Relat Res* 2001;3:39-49.
  10. Krekmanov L, Kahn M, Rangert B, Lindstrom H. Tilting of posterior mandibular and maxillary implants of imprecise prosthesis support. *Int J Oral Maxillofac Implants* 2000;15:405-14.
  11. Maló P, Nobre Mde A, Petersson U, Wigren S. A pilot study of complete edentulous rehabilitation with immediate function using a new implant design: Case series. *Clin Implant Dent Relat Res* 2006; 8:223-32.
  12. Stegaroiu R, Khraisat A, Nomura S, Miyakawa O. Influence of superstructure materials on strain around an implant under 2 loading conditions: A technical investigation. *Int J Oral Maxillofac Implants* 2004;19:735-42.
  13. Tealdo T, Bevilacqua M, Pera F, et al. Immediate function with fixed implant-supported maxillary dentures: A 12-month pilot study. *J Prosthet Dent* 2008;99:351-60.
  14. Grunder U. Immediate functional loading of immediate implants in edentulous arches: Two-year results. *Int J Periodontics Restorative Dent* 2001;21:545-551.
  15. Skalak R. Biomechanical considerations in osseointegrated prostheses. *J Prosthet Dent* 1983;49:843-848.
  16. Juodzbalys G, Kubilius R, Eidukynas V, Raustia AM. Stress distribution in bone: Single-unit implant prostheses veneered with porcelain or a new composite material. *Implant Dent* 2005;14:166-75.
  17. Crespi R, Vinci R, Capparé P, Romanos G. E, Gherlone E. A Clinical Study of Edentulous Patients Rehabilitated According to the "All on Four". *Immediate Function Protocol IJOMI* 2012; 27: 428-34.
-



## Biotechnology & Biotechnological Equipment



ISSN: 1310-2818 (Print) 1314-3530 (Online) Journal homepage: <http://www.tandfonline.com/loi/tbeq20>

### The 'Alternating Osteotome Technique': a surgical approach for combined ridge expansion and sinus floor elevation. A multicentre prospective study with a three-year follow-up

Luciano Malchiodi, Alessandro Cucchi, Paolo Ghensi, Riccardo Caricasulo & Pier Francesco Nocini

To cite this article: Luciano Malchiodi, Alessandro Cucchi, Paolo Ghensi, Riccardo Caricasulo & Pier Francesco Nocini (2016): The 'Alternating Osteotome Technique': a surgical approach for combined ridge expansion and sinus floor elevation. A multicentre prospective study with a three-year follow-up, *Biotechnology & Biotechnological Equipment*, DOI: [10.1080/13102818.2016.1171732](https://doi.org/10.1080/13102818.2016.1171732)

To link to this article: <http://dx.doi.org/10.1080/13102818.2016.1171732>



© 2016 The Author(s). Published by Taylor & Francis.



Published online: 21 Apr 2016.



Submit your article to this journal [↗](#)



Article views: 115



View related articles [↗](#)



View Crossmark data [↗](#)

Full Terms & Conditions of access and use can be found at  
<http://www.tandfonline.com/action/journalInformation?journalCode=tbeq20>

Download by: [93.145.239.31]

Date: 09 June 2016, At: 09:16

BIOTECHNOLOGY & BIOTECHNOLOGICAL EQUIPMENT, 2016  
<http://dx.doi.org/10.1080/13102818.2016.1171732>



ARTICLE; MEDICAL BIOTECHNOLOGY

OPEN ACCESS

## The 'Alternating Osteotome Technique': a surgical approach for combined ridge expansion and sinus floor elevation. A multicentre prospective study with a three-year follow-up

Luciano Malchiodi<sup>a</sup>, Alessandro Cucchi<sup>b</sup>, Paolo Ghensi<sup>c</sup>, Riccardo Caricasulo<sup>a</sup> and Pier Francesco Nocini<sup>a</sup>

<sup>a</sup>Department of Surgery, Section of Dentistry and Maxillofacial Surgery, University of Verona, Verona (VR), Italy; <sup>b</sup>Department of Biomedical and Neuromotorial Science, University of Bologna Bologna (BO), Italy; <sup>c</sup>Centre for Integrative Biology (CIBIO), University of Trento, Trento (TN), Italy

### ABSTRACT

The aim of this multicentre prospective study was to evaluate the efficacy and safety of a surgical approach based on a novel osteotome technique, in order to obtain both alveolar ridge expansion and sinus floor elevation. Partially edentulous patients requiring an implant-prosthetic rehabilitation with a fixed prosthesis in the posterior maxilla were included in this study according to pre-established inclusion and exclusion criteria. All implants were placed after site preparation with the 'Alternating Osteotome Technique', which consists of the use of alternating concave and convex osteotomes. After a 4 to 6-month healing period, all implants were restored with a definitive fixed prosthesis. Clinical and radiographic examinations were scheduled over a 36-month follow-up of functional loading according to a well-established protocol. Statistical analysis was used to detect any significant differences or correlations ( $P = 0.05$ ). Seventy-six patients were consecutively treated with a total of 120 implants in three different centres. The mean ridge expansion and sinus floor elevation were  $1.8 \pm 0.3$  and  $2.5 \pm 0.7$ , respectively. After three years of functioning, the implant success rate was 99.1% since one implant had failed and the mean marginal bone loss was  $0.6 \pm 0.3$  mm. No complications occurred during the intraoperative and postoperative periods. All parameters analysed were stable and steady throughout the three-year follow-up. The 'Alternating Osteotome Technique' enables the dental surgeon to achieve an adequate implant osteotomy with limited ridge expansion and sinus floor elevation, increasing modestly the vertical and horizontal dimensions of the alveolar crest but reducing significantly the risk of surgical complications.

### ARTICLE HISTORY

Received 31 December 2015  
 Accepted 24 March 2016

### KEYWORDS

Implant success; crestal bone loss; osteotome; ridge expansion; sinus floor elevation

### Introduction

The loss of one or more teeth has always been a cause of bone resorption, which can be influenced by many factors such as age, gender, osteoporosis, diabetes, smoking, previous lost implants, type of prosthetic rehabilitation, time elapsing before implant rehabilitation and others.[1] The more time passes before implant rehabilitation, the less bone volume will be available for insertion of implants of sufficient length and diameter to ensure a high implant success rate.[2]

On the basis of Atwood's analysis [3] and Cawood and Howell's clinical classification,[2] it appears that resorption vectors differ according to the site. Specifically, maxillae undergo a progressive volumetric reduction and centripetal contraction of the arch: the outcome of this process consists of a class IV atrophic ridge in anterior areas and a class V atrophic ridge in posterior areas.[2,3]

Expansive techniques (split-crest technique, edentulous ridge expansion (ERE) and ridge expansion osteotomy (REO)) can be used in class IV maxillae for expanding the alveolar ridge. These techniques use bone elasticity and plasticity to widen the spongy space between the two cortical plates by means of intracortical osteotomy of the alveolar crest.[4–7]

Dislocative techniques (osteotome sinus floor elevation (OSFE)) can be used in class V maxillae for elevating the sinus floor. Some techniques use osteotomes to dislocate the bone under the sinus floor, while other techniques use burs to reduce bone and dislocate only the sinus membrane in order to increase the bone height available for implant placement.[8–13]

Malchiodi et al. [13,14] proposed the technique based on the use of alternating concave/convex

CONTACT Luciano Malchiodi [research.univr@hotmail.it](mailto:research.univr@hotmail.it)

© 2016 The Author(s). Published by Taylor & Francis.

This is an Open Access article distributed under the terms of the Creative Commons Attribution-NonCommercial-NoDerivatives License (<http://creativecommons.org/licenses/by-nc-nd/4.0/>), which permits non-commercial re-use, distribution, and reproduction in any medium, provided the original work is properly cited, and is not altered, transformed, or built upon in any way.



osteotomes with variable conicity in an attempt to increase implant success rates in atrophic maxillae. This technique of manual osteotomic preparation of implant sites involves a system based on two kinds of working spikes that cause two vector compression forces apically and surrounding the implant site in order to achieve both alveolar ridge expansion and sinus floor elevation.

The aims of the present study were (1) to measure the clinical horizontal ridge expansion and radiographic vertical sinus elevation, obtained by means of this surgical approach, (2) to assess its safety, reporting intraoperative and postoperative complications and (3) to evaluate its efficacy in terms of implant success rate and marginal bone loss after a three-year follow-up.

## Materials and methods

### Study design

The patients chosen for treatment with the 'Alternating Osteotome Technique' (AOT) were referred over the period from July 2007 to July 2009 for an implant-prosthetic rehabilitation with a fixed prosthesis in the posterior maxilla in three different centres.

All patients had advanced alveolar bone resorption in the posterior areas of the maxilla, which had to be treated by implant placement. They had been advised that they were not candidates for long or wide implants without extensive preparatory implant site development, because of insufficient alveolar ridge height and width.

However, all sites had an alveolar ridge volume of at least 5.0 × 3.5 mm which is considered mandatory for performing AOT in order to have a low risk of buccal dehiscence or sinus perforation.

The decision to use a novel technique was made after discussion with the patients and after obtaining their informed written consent. The following criteria were used to select the patients in whom successful results could be achieved with this type of surgical technique:

- inclusion criteria: partial edentulism, need of an implant-supported fixed prosthesis in the posterior maxilla, residual bone volume of at least 3.5 mm in width and 5.0 mm in height, highly controlled oral hygiene, absence of acute infection in the oral cavity and willingness to participate in an oral hygiene maintenance programme;
- exclusion criteria: insufficient bone volume, bruxism, smoking more than 10 cigarettes/day, abuse of alcohol, radiotherapy in the maxillofacial district, chemotherapy, liver disease, blood disease, kidney

disease, inflammatory and autoimmune disease, immunodepression, corticosteroid therapy, pregnancy and insufficient oral hygiene.

Treatment was performed in three centres – the Department of Morphological and Biomedical Sciences, Section of Dentistry and Maxillofacial Surgery, University of Verona and two private offices. All three centres provided details of all implants placed after site preparation with AOT in partially edentulous patients.

### Osteotome surgical kit and surgical technique

The AOT is based on the use of 11 alternating osteotomes with variable conicity (Bontempi Medizintechnik GmbH, Tuttlingen, Germany), 8 initial osteotomes with a tapered design and 3 corrective osteotomes, one for 5 mm diameter implants and two for cylindrical implants. The eight initial osteotomes have alternating concave and convex spikes, with the same 2.5 mm apical diameter, but different conicity; they are between 4 and 13 mm in length, with 1.5 mm spacing from one to the next. The spikes and working bases have a constant diameter, while the difference between the devices lies in their lengths. The various lengths cause a progressive conicity of the osteotomes, with each device having greater conicity than the previous one in the sequence. Therefore, this system should be used when tapered and cylindrical 8–13 mm implants are to be placed.

Osteotome characteristics are reported in Table 1.

The operative sequence is as follows: a rose-headed bur (2 mm in diameter) is used up to its working range limit to create a generous pathway for the first osteotome. Since a 2 mm bur needs at least 1 mm of vestibular and palatal bone, the minimum thickness required for the use of this technique is 4 mm. If there is an hourglass-shaped crest with clear vestibular resorption, a progressive axial correction can be performed. The osteotomes should be used sequentially to create an adequate osteotomy according to implant size (Figure 1).

Table 1. Osteotome characteristics.

Device number	Concave spike	Convex spike	Length (mm)	Apical diameter (mm)
No. 1	x		4.0	2.5
No. 2		x	5.5	2.5
No. 3	x		7.0	2.5
No. 4		x	8.5	2.5
No. 5	x		10.0	2.5
No. 6		x	10.0	2.5
No. 7		x	11.5	2.5
No. 8		x	13.0	2.5
5 mm corrector		x	10.0	3.1
Cylindric corrector No. 1	x		13.0	3.0
Cylindric corrector No. 2		x	13.0	3.0

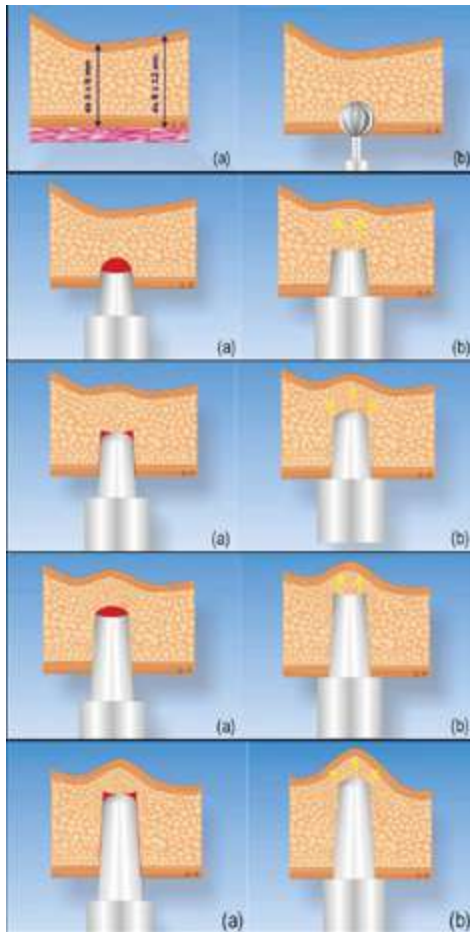


Figure 1. Alternating Osteotome Technique: (a) initial position; (b) final position.

### Surgical and prosthetic protocols

Each patient was evaluated clinically and radiographically to choose the correct treatment planning; orthopantomography and peri-apical X-rays were used as a primary radiographic examination to evaluate baseline bone height available for implant surgery, while computed tomography, in the dentascanner mode, was performed in all cases of alveolar atrophy in order to accurately evaluate bone height and width. A clinical examination was carried out aimed at evaluating oral hygiene, tissue health, keratinized mucosa, residual tooth stability and many other factors capable of influencing treatment planning.

Local anaesthesia was administered with articaine + adrenalin 1:100.000 in the site of intervention; and articaine + adrenalin 1:200.000 in other sites. A full-thickness mucoperiosteal flap was raised and implant sites were prepared using a 2 mm rotating bur and alternating osteotomes with variable conicity, as described by Malchiodi et al. [14] No graft biomaterial was used during implant site osteotomy.

Implants (Biotec BTK, Povolario di Dueville (VI), Italy; Biomet 3i, Palm Beach Gardens, FL, USA) were placed using a 'two-stage delayed function' approach, as described by the manufacturer. It is necessary to install the implant in the osteotomy site using low speed (25 rpm) and 30–45 Ncm torque, turning the implant until it is fully inserted; a cover screw is then positioned on the implant using a screwdriver; finally, the mucoperiosteal flap is re-positioned and sutured in a tension-free manner to ensure first intention healing and better osseointegration of implants.

During the first 7 days, patients were instructed to observe a fluid diet; while during the next 15 days, patients were instructed to observe a soft diet and good oral hygiene. Chlorhexidine 0.2% three times daily was recommended. Patients used no removable prostheses with mucosal support in the operation site. Occasionally, a provisional tooth-supported fixed prosthesis was used.

The initial healing period ranged from 4 to 6 months depending on the clinical circumstances and the treating clinician's preference. A temporary healing abutment is then positioned on the implant to achieve adequate peri-implant soft tissue healing. After achieving correct soft and hard tissue healing, implant-supported prostheses were created.

All definitive restorations were placed in occlusion, where the occlusal surface was thoroughly modelled so that it was in contact with reduced areas during laterality and protrusion excursions, in order to reduce the dislocating vectorial components; several contacts were maintained in maximum intercuspation.

The patient was included in a maintenance programme to achieve optimal hard and soft tissue healing, which comprised of professional oral hygiene every six months and rinsing twice daily with chlorhexidine digluconate 0.2% during the first two weeks.

Clinical evaluation was performed monthly during the first six months after definitive restoration. Further checks were performed every 6 months and consisted of analysis of soft tissue health (modified plaque index (mPI), modified gingival index (mGI) and bleeding on probing (BOP)) and evaluation of the probing pocket depth; radiographic examination with intra-oral radiographs was performed every 12 months after definitive restoration.

### Data collection

A clinical examination was carried out aimed at evaluating the presence of chronic or aggressive periodontitis; the presence of parafunctional habits (bruxism or clenching); gingival biotype (thick or thin), via visual assessment and assessment with a periodontal probe, as described by Kan et al. [15]; mPI, as described by Abraham et al. [16]; mGI, as described by Lobene et al. [17] and BOP, as described by Tagge et al. [18] For each implant, the authors recorded implant length; implant diameter and implant site (first premolar, second premolar, first molar and second molar).

During implant surgery, the width of the alveolar ridge was measured clinically prior to the osteotomy and after implant placement in order to evaluate the initial and final width; buccal–palatal ridge expansion was indicated as the difference between final and initial ridge widths. Similarly, the height of the alveolar ridge was measured radiographically prior to the osteotomy and after implant placement in order to evaluate the initial and final heights. Vertical sinus floor elevation was indicated as the difference between final and initial ridge heights. All these measurements were carried out using a Castroviejo caliper with a 1 mm graduated scale and were rounded off to the nearest 0.5 mm; similar measurements were obtained at re-opening surgery to evaluate bone stability.

Crestal bone level was measured at baseline, at the 12-month follow-up, at the 24-month follow-up and at the 36-month follow-up for each implant, considering the first contact point at the bone–implant interface.

All radiographs of implants from each subject's 36-month recall visit were reviewed independently by an oral radiologist at a magnification of 6× for the measurements of marginal bone level. This was assessed mesially and distally by identifying the lowest observed point of crestal bone intimate contact with the implant, and compared to the level at baseline to quantify marginal bone loss. Both measurements were rounded off to the nearest 0.1 mm with the aid of a seven-fold magnifying lens. A peak scale loupe with a seven-fold magnifying factor and a 0.1 mm graduated scale were used, as described by Degidi et al. [19]

Finally, both intraoperative and postoperative complications were recorded: the former included sinus perforation, cortical bone fracture, implant dehiscence, implant fenestration and incomplete osteotomy, and the latter, benign paroxysmal positional vertigo (BPPV), wound dehiscence, persistent pain, sinusitis, rhinorrhoea and nasal obstruction. Other implant–prosthetic complications, such as screw fracture, screw loosening or implant failure, were recorded postoperatively up to the 36-month follow-up examination.

### Follow-up and success evaluation

All patients were recalled every six months as a part of their routine oral hygiene programme. A clinical and radiographic examination was scheduled after the implant surgery, after four or six months of healing, at the time of prosthetic rehabilitation and every six months (radiographic examination every 12 months) until the 36-month follow-up visit, according to a well-established protocol generally used to determine implant success. Implant success was defined according to the criteria suggested by Buser et al. [20] and modified by Albrektsson and Zarb, [21] including: (1) absence of persistent pain or dysaesthesia or paraesthesia in the implant area; (2) absence of peri-implant infection with or without suppuration; (3) absence of perceptible mobility of the implant and (4) absence of persistent peri-implant bone resorption of >1.5 mm during the first year of loading and 0.2 mm/year during the following years.

The implants were considered successful in the presence of all of the above-mentioned criteria at the most recent follow-up appointment. Clinical complications such as pain, dysaesthesia or paraesthesia were assessed by interviewing the patients. Peri-implant infection with or without suppuration and implant mobility were assessed by clinical observation and pressure. Radiographic complications such as excessive peri-implant bone resorption or radiolucencies were assessed with peri-apical X-rays.

### Results and discussion

In total, records were analysed for 120 implants in 76 subjects (aged 31–68 years; 41 females and 35 males), who needed to restore a partial edentulism in the posterior maxilla. The University Center contributed 60 implants in 38 subjects (33 in molar sites and 27 in premolar sites). Private office 1 (Mantova, Italy) contributed 32 implants in 20 subjects (20 in molar sites and 12 in premolar sites), performed by an oral surgeon; and private office 2 (Brescia, Italy) contributed 28 implants in 18 subjects (16 in molar sites and 12 in premolar sites), performed by an oral surgeon. Two patients (3 implants) dropped out during the follow-up period.

According to length, 8.5, 10, 11.5 and 13 mm long implants were used in 28.3% ( $n = 34$ ), 30.9% ( $n = 37$ ), 22.5% ( $n = 27$ ) and 18.3% ( $n = 22$ ) of cases, respectively; according to the diameter, 4 and 5 mm implants were used in 65.0% ( $n = 78$ ) and 35.0% ( $n = 42$ ) of cases, respectively.

One implant had failed because of excessive crestal bone loss, during the three-year follow-up: 116 out of 117 maxillary implants fulfilled the previously established

success criteria, giving a 99.1% implant success rate. As a result, the prosthesis survival rate was 100% because the failed implant was still in function.

The mean dimensions of the alveolar ridge before surgery were  $4.6 \pm 0.8$  mm in width and  $8.5 \pm 1.9$  mm in height; after AOT, the mean width and height of the alveolar ridge were  $6.4 \pm 0.9$  and  $11.0 \pm 1.8$  mm, respectively. The mean horizontal ridge expansion and vertical sinus elevation were  $1.8 \pm 0.3$  and  $2.5 \pm 0.7$  mm, respectively, which correspond to 39.1% and 29.4% augmentation compared to the initial dimensions. The differences between alveolar ridge dimensions before and after AOT were statistically significant ( $P < 0.05$ ).

The mean crestal bone level at baseline was  $0.5 \pm 0.4$  mm, while the mean crestal bone level value at the three-year follow-up was  $1.1 \pm 0.5$  mm. Analysis of crestal bone levels revealed a mean marginal bone loss during functional loading of  $0.6 \pm 0.3$  mm. Four implants (3.4%) presented no bone resorption; most implants ( $n = 75$ ) (64.1%) showed bone resorption ranging from 0.1 to 0.5 mm; twenty-seven implants (23.1%) presented bone losses ranging from 0.6 to 1.0 mm; seven implants (6.0%) between 1.1 and 1.5 mm and only three implants (2.6%) showed bone loss up to 1.6 mm. None of the osseointegrated implants showed a marginal bone loss of more than 2.1 mm, with the exception of the failed implant.

The baseline clinical values for mPI, mGI and BOP were  $0.4 \pm 0.2$ ,  $0.5 \pm 0.2$  and  $0.4 \pm 0.2$  mm, respectively. At the 36-month follow-up evaluation, statistically significant reductions in mGI and BOP were recorded compared to baseline ( $P < 0.05$ ). The 36-month follow-up clinical values for mPI, mGI and BOP were  $0.4 \pm 0.2$ ,  $0.4 \pm 0.2$  and  $0.2 \pm 0.1$  mm, respectively.

Three cases of intraoperative complications were recorded: the first was a sinus perforation (0.9%) in a patient with a residual bone height of 5.5 mm and the other two were cortical bone fractures (1.7%) after implant placement in patients with a residual bone width of 3.5 mm. No postoperative complications, such as BPPV, wound dehiscence, acute or chronic sinusitis, were reported. Finally, only one case of screw fracture (0.9%) and two cases of screw loosening (1.7%) were observed during the 36-month follow-up.

The AOT was introduced in 2003 after analysis of implant positioning risk factors in atrophic maxillae, which are often deficient in bone width and height.[13]

All osteotomes present a wide stop at the basis of the working spike as well as progressive working spike conicity. These structural characteristics facilitate osteotome insertion in sequence: each osteotome is inserted passively via a path corresponding to the osteotomy created by the previous device and continues the osteotomic action for only 1.5 mm, i.e. the difference in length

between one osteotome and the next. It is sufficient to manually rotate the device clockwise with a slight push to allow the latter to go deeper until reaching the mechanical stop, thus, reducing the risk of maxillary sinus perforation. Additionally, the osteotome design is extremely useful for achieving the apical and buccal dislocation of alveolar bone, gradually increasing the depth and diameter of the implant site.[14]

In the present study, the use of AOT made it possible to achieve both alveolar ridge expansion and sinus floor elevation, with over a 25%–30% increase compared to original bone volume. The increase in width is rather small in comparison to ERE techniques or similar split-crest techniques, which yield a horizontal expansion of about 25%–80%.[22,23] Similarly, the increase in height is low in comparison to other OSFE techniques, which permit a vertical augmentation of about 30%–90%.[8,11,24,25]

As regards the sinus floor elevation effect of AOT, it is clear that the amount of vertical bone gain was smaller than that reported in other studies, where transcrestal sinus floor elevation was achieved by means of osteotomes and burs plus autogenous bone and graft biomaterial (6.75 mm),[26] osteotomes plus deproteinized bovine bone mineral (DBBM) (6.9 mm) [27] or osteotomes and burs plus synthetic hydroxyapatite or DBBM (7.70 and 6.50 mm, respectively).[28]

However, the majority of studies where sinus elevation was performed by means of the use of osteotomes alone or combinations of osteotomes and burs, with or without graft material, reported a mean vertical bone gain lower than 5 mm.[29–37]

AOT makes it possible to minimize the risk of intraoperative and postoperative complications, creating an adequate implant site for the placement of a conventional-sized implant. The conical conformation of the spikes, the alternation of apical concavity and convexity, the wide stop and the comfortably sized handle eliminate the need to use a hammer percussively, thus, reducing the risk of BPPV and sinus perforation.

OSFE is considered a predictable technique that makes it possible to achieve an increase in bone height and successful results similar to those of conventional implants.[25] However, sinus perforation is the most common complication of maxillary sinus surgery.[38,39] The force applied should be sufficient to fracture the sinus cortical floor but restrained enough to prevent the osteotome tip from traumatizing the Schneiderian membrane, although tapping the remaining bone of the sinus floor carries a risk of perforation of the sinus membrane.[39]

Garbacea et al. [40] conducted an *ex vivo* investigation of the occurrence of sinus membrane perforation

during surgery utilizing three different transcresal sinus floor elevation techniques; they reported high rates of sinus perforation. Although an endoscopic study has revealed that the sinus floor may be elevated by anything up to 5 mm without perforating the sinus membrane, [41] other studies have demonstrated the risk of membrane perforation while performing transalveolar sinus floor elevation of more than 4 mm.[42,43] Lai et al. [44] have published a randomized clinical trial comparing OSFE with and without graft materials, reporting membrane perforation rates of 7.8% and 2.6%, with mean residual bone heights of 4.7 and 5.6 mm, respectively.

BPPV is another common complication of OSFE. It consists of a high-prevalence, vestibular end organ disorder due to the detachment of the utricular otoconia floating in the posterior or lateral semicircular canal. Di Girolamo et al. [45] reported a BPPV rate of 2.7% as a complication of OSFE: the authors hypothesize that the surgical trauma, and specifically the pressure exerted by the osteotomes and mallet, cause the detachment of the otoliths from the utricular macula, while the patient's head position, hyper-extended and tilted to the side opposite to the one where the surgeon is working, which favours the entry of these free-floating particles into the posterior semicircular canal of the implanted side. Penarocha et al. [46–48] reported high rates of patients affected by BPPV after the use of osteotomes and mallet for sinus floor elevation and recommended that particular care be taken when using these devices in order to avoid BPPV, although this complication is a benign, self-limiting peripheral disorder that is promptly solved by means of the Epley re-positioning manoeuvre. Sammartino et al. [49] in a randomized controlled trial demonstrated that the use of osteotome and mallet for closed sinus floor elevation and implant site preparation is associated with a higher risk of BPPV compared to the use of manual or screwable osteotomes; the authors observed a BPPV rate of 3.1% for the mallet osteotome group and a BPPV rate of 0% for the screwable group. In the present study, one case of sinus perforation (0.9%) and no cases of BPPV (0%) were reported, indicating the safety of the AOT. Further randomized controlled studies are needed, however, to demonstrate its safety definitively.

As regards the ridge expansion effect of AOT, the amount of horizontal bone gain was smaller than that reported in other studies, where ERE was achieved by means of original ERE (3.5 mm),[50] the split-crest technique with ultrasonic bone surgery (2.8 mm),[22] the split-crest technique plus autogenous bone and graft biomaterial (4.8 mm),[51] the extension-crest device (3.9 mm) [52] or the two-stage split-crest technique (7.1 mm).[23,53]

However, AOT reduces the risk of intraoperative complications, such as cortical plate fractures, and makes it easier to prepare an adequate implant site without the use of split-thickness flaps, sagittal osteotomy and graft biomaterials.

Strietzel et al. [54] showed that REO was associated with 22% rate of cases with a buccal cortical plate fracture and that the risk of fracture was significantly higher in class II bone. Guided bone regeneration (GBR) with a non-resorbable membrane was used to achieve bone augmentation and implant osseointegration.

Ferrigno and Laureti [51] proposed a novel implant design in order to reduce the risk of fracture of the labial cortical plate during the last two steps of the split-crest technique: (1) implant site preparation and (2) implant insertion. Nevertheless, the authors observed that buccal plate fracture occurred in 5% of cases, in which removal of the cortical plate was required in order to perform a GBR technique with minced autogenous bone plus graft biomaterials. This complication could compromise the osseointegration of the implants, as highlighted by the same authors. In cases with total fracture of the buccal bone segment, other authors believe that careful fixation of the buccal cortex to the underlying palatal bone cortex with two bicortical micro screws may be enough to stabilize the bone segment, while allowing the preservation of a gap that should be filled with an autogenous or heterogenous bone graft.[55]

Basa et al. [56] described an alternative expansion technique for edentulous ridges, in which the buccal cortical plates were split, intentionally fractured, held *in situ* by a cortical screw and grafted with biomaterials. This procedure enables the dental surgeon to avoid the risk of unintentional fractures that may occur during ERE. In the present study, two cases of cortical bone fractures (1.7%) occurred after implant placement, but no treatment was required because of the limited extent of the fracture line, which is always less than 2 mm.

Finally, it is important to consider that also Calvo-Guirado et al. [26] evaluated the efficacy of AOT for the posterior alveolar expansion and elevation of the upper maxillary alveolar ridge, reporting a 100% implant success rate after a nine-month follow-up. Although the authors reported a mean increase in bone height of  $6.8 \pm 1.3$  mm and a mean ridge expansion of  $3.2 \pm 0.2$  mm, they provided no information regarding complication rates, such as sinus perforation or cortical bone fractures.

Considering maxillary bone and sinus membrane elasticity, the authors of the present study presume that one cannot reasonably expect to achieve 103% and 83% horizontal and vertical ridge augmentation starting from initial ridge dimensions of 3.3 and 8.2 mm, respectively,



as reported by Calvo-Guirado et al. [26] Consequently, the use of autologous bone or biomaterial was necessary to keep the bone corticals apart and to serve as scaffolding for the bone neoformation, in the cases of bone deficiencies.[26]

### Conclusion

Bone augmentation techniques are routinely required for implant placement. The AOT is capable of increasing the height and width of the ridge of atrophic maxillae by over 25%–30%, reducing the risk of complications and making implant site preparation easier. The implant success rate and crestal bone levels after AOT were comparable to those of implants placed in native bone, showing that AOT is a viable technique for preparing an increased implant site compared to the initial dimensions of the edentulous ridge.

### Acknowledgments

The authors claim to have no financial interest in any company or in any of the products mentioned in this article.

### Disclosure statement

The authors declare that there is no conflict of interests regarding the publication of this article.

### References

- [1] Felton DA. Edentulism and comorbid factors. *J Prosthodont.* 2009;18:88–96.
- [2] Jensen OT, Adams MW, Butura C, et al. Maxillary V-4: four implant treatment for maxillary atrophy with dental implants fixed apically at the vomer-nasal crest, lateral pyriform rim, and zygoma for immediate function. Report on 44 patients followed from 1 to 3 years. *J Prosthet Dent.* 2015;114:810–817.
- [3] Lautner NV, Bernauer E, Krenkel C, et al. Altered position of the medial lingual nutritional foramina at different stages of alveolar ridge atrophy. *J Oral Implantol.* 2014;40:19–24.
- [4] Khairnar MS, Khairnar D, Bakshi K. Modified ridge splitting and bone expansion osteotomy for placement of dental implant in esthetic zone. *Contemp Clin Dent.* 2014;5:110–114.
- [5] Teng F, Zhang Q, Wu M, et al. Clinical use of ridge-splitting combined with ridge expansion osteotomy, sandwich bone augmentation, and simultaneous implantation. *Br J Oral Maxillofac Surg.* 2014;52:703–708.
- [6] Beolchini M, Lang NP, Ricci E, et al. Influence on alveolar resorption of the buccal bony plate width in the edentulous ridge expansion (E.R.E.) – an experimental study in the dog. *Clin Oral Implants Res.* 2015;26:109–114.
- [7] Garcez-Filho J, Tolentino L, Sukekava F, et al. Long-term outcomes from implants installed by using split-crest technique in posterior maxillae: 10 years of follow-up. *Clin Oral Implants Res.* 2015;26:326–331.
- [8] Summers RB. A new concept in maxillary implant surgery: the osteotome technique. *Compend Contin Educ Dent.* 1994;15:152–160.
- [9] Mandelli F, Ghensi P, Vinci R, et al. Sinus floor elevation with crestal approach and immediately loaded post-extraction implants. *J Indiana Dent Assoc.* 2013;92:22–24.
- [10] Pjetursson BE, Lang NP. Sinus floor elevation utilizing the transalveolar approach. *Periodontol* 2000. 2014;66:59–71.
- [11] Cosci F, Luccioli M. A new sinus lift technique in conjunction with placement of 265 implants: a 6-year retrospective study. *Implant Dent.* 2000;9:363–368.
- [12] Esposito M, Cannizzaro G, Barausse C, et al. Cosci versus Summers technique for crestal sinus lift: 3-year results from a randomised controlled trial. *Eur J Oral Implantol.* 2014;7:129–137.
- [13] Malchiodi L. Anatomy and surgery of maxillary sinus. In: Malchiodi L, editor. *Implant surgery.* 1st ed. Bologna: Martina Ed.; 2003. p. 219–225.
- [14] Malchiodi L, D'Agostino A, Corrocher G, et al. Alternating osteotome with variable conicity technique: clinical applications in upper jaw implant surgery. *Compend Contin Educ Dent.* 2010;31:198–206.
- [15] Kan JY, Morimoto T, Rungcharassaeng K, et al. Gingival biotype assessment in the esthetic zone: visual versus direct measurement. *Int J Periodontics Restorative Dent.* 2010;30:237–243.
- [16] Abraham J, Stiles HM, Kammerman LA, et al. Assessing periodontal pathogens in children with varying levels of oral hygiene. *ASDC J Dent Child.* 1990;57:189–193.
- [17] Lobene RR, Weatherford T, Ross NM, et al. A modified gingival index for use in clinical trials. *Clin Prevent Dent.* 1986;8:3–6.
- [18] Tagge DL, O'Leary TJ, El-Kafrawy AH. The clinical and histological response of periodontal pockets to root planing and oral hygiene. *J Periodontol.* 1975;46:527–533.
- [19] Degidi M, Piattelli A, Carinci F. Immediate loaded dental implants: comparison between fixtures inserted in postextractive and healed bone sites. *J Craniofac Surg.* 2007;18:965–971.
- [20] Buser D, Weber HP, Bragger U, et al. Tissue integration of one-stage implants: 3-year results of a prospective longitudinal study with hollow cylinder and hollow screw implants. *Quintessence Int.* 1994;25:679–686.
- [21] Albrektsson T, Zarb GA. Determinants of correct clinical reporting. *Int J Prosthodont.* 1998;11:517–521.
- [22] Blus C, Szmukler-Moncler S. Split-crest and immediate implant placement with ultra-sonic bone surgery: a 3-year life-table analysis with 230 treated sites. *Clin Oral Implants Res.* 2006;17:700–707.
- [23] Anitua E, Begoña L, Orive G. Controlled ridge expansion using a two-stage split-crest technique with ultrasonic bone surgery. *Implant Dent.* 2012;21:163–170.
- [24] Nedin R, Nurdin N, Vazquez L, et al. Osteotome sinus floor elevation technique without grafting: a 5-year prospective study. *J Clin Periodontol.* 2010;37:1023–1028.
- [25] Antonaya-Mira R, Barona-Dorado C, Martínez-Rodríguez N, et al. Meta-analysis of the increase in height in maxillary sinus elevations with osteotome. *Med Oral Patol Oral Cir Bucal.* 2012;17:146–152.



- [26] Calvo-Guirado JL, Saez-Yuguero R, Pardo-Zamora G. Compressive osteotomes for expansion and maxilla sinus floor lifting. *Med Oral Patol Oral Cir Bucal*. 2006;11:52–55.
- [27] Kang T. Sinus elevation using a staged osteotomy technique for site development prior to implant placement in sites with less than 5 mm of native bone: a case report. *Int J Periodontics Restorative Dent*. 2008;28:73–81.
- [28] Trombelli L, Franceschetti G, Rizzi A, et al. Minimally invasive transcrestal sinus floor elevation with graft biomaterials. A randomized clinical trial. *Clin Oral Implants Res*. 2012;23:424–432.
- [29] Gu YX, Shi JY, Zhuang LF, et al. Transalveolar sinus floor elevation using osteotomes without grafting in severely atrophic maxilla: a 5-year prospective study. *Clin Oral Implants Res*. 2016;27:120–125.
- [30] Crespi R, Capparè P, Gherlone EF. Electrical mallet in implants placed in fresh extraction sockets with simultaneous osteotome sinus floor elevation. *Int J Oral Maxillofac Implants*. 2013;28:869–874.
- [31] Crespi R, Capparè P, Gherlone E. Sinus floor elevation by osteotome: hand mallet versus electric mallet. A prospective clinical study. *Int J Oral Maxillofac Implants*. 2012;27:1144–1150.
- [32] Si MS, Zhuang LF, Gu YX, et al. Osteotome sinus floor elevation with or without grafting: a 3-year randomized controlled clinical trial. *J Clin Periodontol*. 2013;40:396–403.
- [33] He L, Chang X, Liu Y. Sinus floor elevation using osteotome technique without grafting materials: a 2-year retrospective study. *Clin Oral Implants Res*. 2013;24(Suppl A100):63–67.
- [34] Fermergard R, Astrand P. Osteotome sinus floor elevation and simultaneous placement of implants – a 1-year retrospective study with Astra Tech implants. *Clin Implant Dent Relat Res*. 2008;10:62–69.
- [35] Nedir R, Nurdin N, Szmukler-Moncler S, et al. Placement of tapered implants using an osteotome sinus floor elevation technique without bone grafting: 1-year results. *Int J Oral Maxillofac Implants*. 2009;24:727–733.
- [36] Nedir R, Bischof M, Vazquez L, et al. Osteotome sinus floor elevation technique without grafting material: 3-year results of a prospective pilot study. *Clin Oral Implants Res*. 2009;20:701–707.
- [37] Pérez-Martínez S, Martorell-Calatayud L, Peñarrocha-Oltra D, et al. Indirect sinus lift without bone graft material: systematic review and meta-analysis. *J Clin Exp Dent*. 2015;7:e316–e319.
- [38] Wallace SS, Tarnow DP, Froum SJ, et al. Maxillary sinus elevation by lateral window approach: evolution of technology and technique. *J Evid Based Dent Pract*. 2012;12:161–171.
- [39] Schwarz L, Schiebel V, Hof M, et al. Risk factors of membrane perforation and postoperative complications in sinus floor elevation surgery: review of 407 augmentation procedures. *J Oral Maxillofac Surg*. 2015;73:1275–1282.
- [40] Garbacea A, Lozada JL, Church CA, et al. The incidence of maxillary sinus membrane perforation during endoscopically assessed crestal sinus floor elevation – a pilot study. *J Oral Implantol*. 2012;16:165–169.
- [41] Engelke W, Deckwer I. Endoscopically controlled sinus floor augmentation. A preliminary report. *Clin Oral Implants Res*. 1997;8:527–531.
- [42] Nkenke E, Schlegel A, Schultze-Mosgau S, et al. The endoscopically controlled osteotome sinus floor elevation: a preliminary prospective study. *Int J Oral Maxillofac Implants*. 2002;17:557–566.
- [43] Berengo M, Sivoletta S, Majzoub Z, et al. Endoscopic evaluation of the bone-added osteotome sinus floor elevation procedure. *Int J Oral Maxillofac Surg*. 2004;33:189–194.
- [44] Lai HC, Zhuang LF, Lv XF, et al. Osteotome sinus floor elevation with or without grafting: a preliminary clinical trial. *Clin Oral Implants Res*. 2010;21:520–526.
- [45] Di Girolamo M, Napolitano B, Arullani CA, et al. Paroxysmal positional vertigo as a complication of osteotome sinus floor elevation. *Eur Arch Oto-Rhino-Laryngol Head Neck*. 2005;262:631–633.
- [46] Peñarrocha M, Pérez H, Garcíá A, et al. Benign paroxysmal positional vertigo as a complication of osteotome expansion of the maxillary alveolar ridge. *J Oral Maxillofac Surg*. 2001;59:106–107.
- [47] Peñarrocha M, García A. Benign paroxysmal positional vertigo as a complication of interventions with osteotome and mallet. *J Oral Maxillofac Surg*. 2006;64:1324.
- [48] Peñarrocha-Diago M, Rambla-Ferrer J, Perez V, et al. Benign paroxysmal vertigo secondary to placement of maxillary implants using the alveolar expansion technique with osteotomes: a study of 4 cases. *Int J Oral Maxillofac Implants*. 2008;23:129–132.
- [49] Sammartino G, Mariniello M, Scaravilli MS. Benign paroxysmal positional vertigo following closed sinus floor elevation procedure: mallet osteotomes vs. screwable osteotomes. A triple blind randomized controlled trial. *Clin Oral Implants Res*. 2011;22:669–672.
- [50] Scipioni A, Bruschi GB, Calesini G. The edentulous ridge expansion technique: a five-year study. *Int J Periodontics Restorative Dent*. 1994;14:451–459.
- [51] Ferrigno N, Laureti M. Surgical advantages with ITI TE implants placement in conjunction with split crest technique. 18-month results of an ongoing prospective study. *Clin Oral Implants Res*. 2005;16:147–155.
- [52] Chiapasco M, Ferrini F, Casentini P, et al. Dental implants placed in expanded narrow edentulous ridges with the Extension Crest device. A 1-3-year multicenter follow-up study. *Clin Oral Implants Res*. 2006;17:265–272.
- [53] Anitua E, Begoña L, Orive G. Two-stage split-crest technique with ultrasonic bone surgery for controlled ridge expansion: a novel modified technique. *Oral Surg Oral Med Oral Pathol Oral Radiol*. 2011;112:708–710.
- [54] Strietzel FP, Nowak M, Kuchler I, et al. Peri-implant alveolar bone loss with respect to bone quality after use of the osteotome technique: results of a retrospective study. *Clin Oral Implants Res*. 2002;13:508–513.
- [55] González-García R, Monje F, Moreno C. Alveolar split osteotomy for the treatment of the severe narrow ridge maxillary atrophy: a modified technique. *Int J Oral Maxillofac Surg*. 2011;40:57–64.
- [56] Basa S, Varol A, Turker N. Alternative bone expansion technique for immediate placement of implants in the edentulous posterior mandibular ridge: a clinical report. *Int J Oral Maxillofac Implants*. 2004;19:554–558.

## A Prospective Longitudinal Study on Implant Prosthetic Rehabilitation in Controlled HIV-Positive Patients with 1-Year Follow-Up: The Role of CD4+ Level, Smoking Habits, and Oral Hygiene

Enrico F. Gherlone, MD, DMD;\* Paolo Capparé, MD, MFS;<sup>†</sup> Simona Tecco, DDS, PhD;<sup>‡</sup> Elisabetta Polizzi, BS;<sup>‡</sup> Giuseppe Pantaleo, PhD;<sup>§</sup> Giorgio Gastaldi, MD, DMD;<sup>¶</sup> Maria Gabriella Grusovin, DDS\*<sup>\*</sup>

---

### ABSTRACT

**Background:** A recent study showed that implant-prosthetic rehabilitation in well-controlled HIV patients gave slightly worse results than in an healthy population, and failures were all linked to infection.

**Purpose:** The aim of this study was to examine the associations between the success of implant-prosthetic treatment and systemic CD4+ level, smoking habits, and oral hygiene.

**Materials and Methods:** This mono-centric study included HIV patients with a stable disease and good oral hygiene requiring implant rehabilitation. Each patient received at least one dental implant. Prosthesis were delivered after 90 days in the upper jaw and 60 days in the lower jaw. Primary outcome measures were prosthetic failures, implant failures, peri-implant marginal bone level changes, and biological complications (peri-implantitis, pus, pain, paresthesia). The possible association with CD4 count, smoking habits, and oral hygiene was analyzed.

**Results:** Sixty-eight patients received 194 implants, and 66 patients (190 implants) were followed for 1 year. No significant associations were found between CD4+ count, oral hygiene-associated variables, and any of the outcome measures. If compared with nonsmoking/light smoking patients, patients who smoked >10 cigarettes/day suffered a statistically significant greater number of implant failures ( $p \leq .005$ ), presented a comparatively higher number of peri-implantitis ( $p < .001$ ), as well as a higher frequency of pus ( $p \leq .007$ ), and reported pain ( $p \leq .009$ ).

**Conclusion:** Within the limitation of the present study, placement of dental implants in HIV-positive patients with stable disease seems a reasonable treatment option, regardless of CD4+ cell count, provided that they are in a normal range. Oral hygiene variables were not influent in this group of patient following recall appointments, while HIV-positive heavy smokers (>10 cigarettes/day) demonstrated an increased risk of early implant failure, peri-implantitis, episodes of pus, and self-reported pain.

**KEY WORDS:** AIDS, HIV, implant, implant survival, implantology, osseointegration, peri-implantitis

---

\*Full professor and chairman, Dental School, Vita-Salute University and IRCCS San Raffaele, Milan, Italy; <sup>†</sup>researcher, Dental School, Vita-Salute University and IRCCS San Raffaele, Milan, Italy; <sup>‡</sup>adjunct professor, Dental School, Vita-Salute University and IRCCS San Raffaele, Milan, Italy; <sup>§</sup>associate professor, Faculty of Psychology, UniSR Social.Lab [Research Methods], Vita-Salute San Raffaele University, Milan, Italy; <sup>¶</sup>associate professor, Dental School, Vita-Salute University, Milan, Italy and head, Maxillofacial Surgery and Dentistry Unit, San Rocco Hospital, Ome, Brescia, Italy; \*\*adjunct professor, Dental School, Vita-Salute San Raffaele University, Milan, Italy

Corresponding Author: Dr. Paolo Capparé, Dentistry Department IRCCS San Raffaele Hospital, Via Olgettina n. 48, Milan 20132, Italy; e-mail: paolocappare@gmail.com  
Conflict of interest: No author had any conflict of interest. The material is original and has not been published elsewhere.

© 2015 Wiley Periodicals, Inc.

DOI 10.1111/cid.12370

## INTRODUCTION

The scientific literature about oral implants performed on HIV-positive patients is relatively scarce and consists mainly of case reports<sup>1-3</sup> or pilot study.<sup>4</sup> This is in part due to the fact that HIV-positive patients rarely were subjected to this type of treatment as their systemic disease was associated with a significant reduction of length and quality of life, and they had other medical needs, rather than implant-prosthetic rehabilitation.<sup>5</sup> The dental treatment was limited, therefore, to the management of oral lesions and dental emergencies.<sup>5</sup> With the advent of new therapies improving the quality of life of these patients, implant-prosthetic rehabilitation has become more and more common for these patients.<sup>6</sup>

Longitudinal clinical trials about implant-prosthetic rehabilitation in HIV patients are rare.<sup>6</sup> A recent prospective cohort study conducted at the IRCCS San Raffaele Hospital, Milan, showed that well-controlled HIV patients who maintained a proper oral hygiene and followed a professional maintenance protocol obtained only slight worse results in implant rehabilitation than an healthy population (survival at patient level: 57 out of 66 patients; survival at fixture level: 175 out of 190 – 92.1% after 1 year). All the failures were linked to infection and occurred before 6 months from insertion (7.9% out of 190 fixtures on nine out of 66 HIV-positive patients).<sup>7</sup>

Indeed, infection can be a serious complication in placement of dental implants and could lead to implant loss, in particular in patients infected with human immunodeficiency virus.<sup>8,9</sup> In such patients, a progressive deterioration in immunity is indicated by a fall in the T-helper (CD4) cell count, and the risk of wound infection increases as the immune status deteriorates.<sup>10,11</sup>

So, the systemic disease could cause an increase in the percentage of early failures, and the systemic level of CD4+, which is to be considered an indicator of the state of the disease, could be an indicator of the increased risk for implant failures.

Besides, other factors as cigarette smoking<sup>12</sup> and the level of oral hygiene<sup>13</sup> can affect osseointegration and infections.

The purpose of this study was therefore to investigate the associations between variables related to the survival of implant-prosthesis treatment (prosthetic failures, implant failures, biological complication, mar-

ginal bone level change [MBLC]) and systemic CD4+ values, smoking habits, and oral hygiene, in a population of HIV-positive patients followed for 1 year, undergoing implant-prosthetic treatment, described in a previous paper.

In this article, the Strobe guidelines (or Strengthening the Reporting of Observational Studies in Epidemiology) were followed.<sup>14</sup>

## MATERIALS AND METHODS

This mono-centric trial (IRCCS San Raffaele Hospital in Milan, Italy) included controlled HIV-affected patients that required implant rehabilitation. The Italian Ministry of Health approved the protocol.

### Recruitment

The patients were recruited at the San Luigi Center for Infective Diseases, IRCCS San Raffaele Hospital, Milan, in which HIV-infected patients are kept under medical control. All those who presented medical parameters of a stable disease were considered (Table 1).<sup>7</sup>

All patients received and signed a written consent form for implant procedures.

### Interventions Administered

During the first dental examination of the patients, the following procedures were done:

- General intraoral examination;
- Evaluation of the orthopantomography or any Tc Dental scans; and
- Implant planning (number of fixtures; the location, the type of prosthesis).

A few days before the surgery, periodontal health checkup (by the hygienist or dentist) was performed: This stage was the T0 for the clinical periodontal parameters. Stages T1 and T2 were considered at 6 months and 12 months, respectively, from implant placement. At these stages, a dental hygienist measured the modified bleeding index, modified plaque index, probing depth (PPD), and presence of pus (Table 2).<sup>15</sup>

Smoking habits were recorded at T0 as number of cigarettes smoked in a day. Education and motivation to oral hygiene at home, and instructions about the potential negative role of smoking were given to all the patients. Eventual debridement above/below the gingiva and one stage full-mouth disinfection in case of periodontal patients were administrated.

**TABLE 1 Inclusion and Exclusion Criteria**

The eligibility criteria	<ul style="list-style-type: none"> <li>• HIV-positive patients</li> <li>• Age &gt;18 years</li> <li>• Total or partial edentulous</li> <li>• Adequate bone volume (divisions A, B, or C according to Misch classification of bone available<sup>23</sup>) and appropriate bone density (classes D1, D2, or D3 Misch<sup>24</sup>);</li> <li>• Blood values:               <ul style="list-style-type: none"> <li>CD4+ level count &gt;400 cells/mm<sup>3</sup></li> <li>Hemoglobin &gt;8 mg/dl;</li> <li>Absolute neutrophil count &gt;750 cells/mm<sup>3</sup>;</li> <li>Platelets &gt;75.000 cells/mm<sup>3</sup>;</li> <li>AST &lt; 5 times the upper limit of normal value (ULN);</li> <li>Bilirubin &lt;2.5 times ULN;</li> <li>Alkaline phosphatase &lt;5 times ULN;</li> <li>Creatinine &lt;2.5 mg/ml</li> </ul> </li> </ul>
Exclusion criteria	<ul style="list-style-type: none"> <li>• Severely immunocompromised patients with a high recurrence of opportunistic infections, tuberculosis, or malignancy spread;</li> <li>• Diabetes decompensated;</li> <li>• Severe malocclusion;</li> <li>• Severe parafunctions (bruxism);</li> <li>• Inadequate bone volume (Division D of Misch);</li> <li>• Inadequate bone density (density D4 Misch);</li> <li>• Disorders that contraindicate surgical procedures;</li> <li>• Lack of collaboration;</li> <li>• Lack of oral hygiene: plaque index superior to 1</li> </ul>

At the day scheduled for the surgery, implants were positioned after antibiotic prophylaxis with amoxicillin and clavulanic acid, 2 g orally, 1 hour before surgery. A full-thickness flap was raised, and implant placement was conducted in accordance with the manufacturer protocol (WinSix®, BioSAFin. S.r.l., Ancona, Italy). Conical implants with rough surface (Full Contact Covering® surface) and internal hexagon connection were used (K implants, WinSix, BioSAFin. S.r.l.). Postoperative therapy consisted in amoxicillin and clavulanic acid

1 g × 2 per day for 7 days after surgery, rinse with 0.2% chlorhexidine twice a day for 15 days after surgery, and pain medication as needed. Suture removal was carried out after 7 to 10 days. Re-entry procedures for healing abutment placement were performed in each case at least after 50 days from implant placement.

After 90 days for the upper jaw and 60 days for the lower jaw, a precise impression was made, and removable prosthetic denture or fixed cemented single crowns and bridge were then delivered. For total removable

**TABLE 2 Periodontal Health Indices and Details of Methods of Measurement**

Variable	Timing	Method
Modified Bleeding index (mBI)	T1 and T2	Values were recorded at the mesial, distal, buccal, and palatal surfaces of the implants using a periodontal probe (PGF-GFS, Hu-Friedy).
Modified Plaque index (mPI)	T1 and T2	Values were recorded at the mesial, distal, buccal, and palatal surfaces of the implants using a periodontal probe (PGF-GFS, Hu-Friedy).
Probing depth (PD)	T1 and T2	Values were recorded at the mesial, distal, buccal, and palatal surfaces of the implants using a periodontal probe (PGF-GFS, Hu-Friedy).

Indices were recorded as previously reported.<sup>15</sup>

dentures, ball attachments were screwed directly onto the abutments, and two ball housings (matrices) were mounted in the overdenture.

For single crowns and fixed partial dentures, definitive metal ceramic restorations were cemented onto the definitive abutments.

#### Follow-Up Evaluation

The appointments with the dental hygienist were scheduled each 2 months. For the oral hygiene at home, patients were instructed on the proper use of aids such as interproximal brush, mono tuft toothbrush, and Super floss. Patients were recommended to brush their teeth at least three times a day.

#### Outcome Measures

The outcomes considered were as follows:

1. Prosthesis failure: when prosthesis has to be replaced due to implant failure.
2. Implant failure: implant removal dictated by mobility, progressive marginal bone loss due to peri-implantitis, and any mechanical complication rendering the implant not usable (e.g., implant fracture). The stability of each individual implants was assessed manually, 6 and 12 months from insertion by tightening the abutment screws with the removed prostheses.
3. Biological and biomechanical complications (number and type) were recorded as single episodes for each implant. Particular attention was used to assess peri-implantitis (defined as progressive bone loss with sign of infections around an osseointegrated implant), presence of pain, presence of pus, paresthesia of the lower jaw, and implant fracture.
4. Peri-implant MBLC: Periapical radiographs were taken at T0 (immediately after the insertion of the fixture) and at T2 (1-year follow-up). They were made perpendicular to the long axis of the implant with long-cone parallel technique using an occlusal custom template to measure the marginal bone level. A dedicated dentist measured the changes in crestal bone height over time. The difference in bone level was measured radiographically through specific software (DIGORA 2.5, Soredex, Tuusula, Finland). The software was calibrated for every single image using the known implant length and

diameter at the most coronal portion of the neck of the implant. The linear distance between most coronal point of bone-to-implant contact and the coronal margin of the implant collar was measured to the nearest 0.01 mm, at both mesial and distal sides and averaged. Bone level changes at single implants were averaged at patients level and then at group level.

#### Analysis of Data

Associations between CD4+ level count, smoking habits, oral hygiene (PI, BI, and PPD), and the outcome variables constituted the main target of data analyses.

For CD4+ values, the sample was divided into two subgroups ( $CD4+ \leq 749.5$  vs  $CD4+ > 749.5$ ) on the basis of a median split (median: 749.5). With respect to smoking habits, patients were divided into “nonsmokers /light smokers” (i.e., patients smoking less than 10 cigarettes a day) and “heavy smokers” (i.e., patients smoking more the 10 cigarettes a day). With respect to the assessment of oral hygiene, PI, BI, and PPD indexes were obtained and correlated with the main outcome measures considered at different points in time (T1, T2).

To inspect the relation between the level of CD4+ and outcome variables, score variations between groups of participants were compared and analyzed either with the chi-squared or the Fisher’s exact test when considering variables based on nominal data or, alternatively, with the Mann–Whitney *U* test when considering variables based on ordinal data. A multivariate analysis of variance (MANOVA) was run in order to assess simultaneous variations in failure of implants versus failure of prosthesis versus MBLC indices as a function of a subgrouping of patients into patients with  $CD4+ < 749.5$  versus  $CD4+ > 749.5$ , along with a possible statistical interaction between the three indices and patients’ assignment to one of the two CD4+ subgroups.

To inspect the relation between smoking habits and outcome variables, score variations observed between groups of participants were compared and analyzed either with the chi-squared or the Fisher’s exact test when considering variables based on nominal data (i.e., peri-implantitis, pus, pain) or, alternatively, with the Mann–Whitney *U* test, when considering variables based on ordinal data (i.e., number of implant failures).

**TABLE 3** Demographic Data of Subjects

	Whole Sample N: 68 (100%)	No Smokers n: 26 (38.2%)	Smokers ( $\leq 10$ Cigarettes/Day) n: 29 (42.6%)	Smokers ( $>10$ Cigarettes/Day) n: 13 (19.1%)
Age	55.3 $\pm$ 17.2 years (range 40–73)	50.2 $\pm$ 10.2 years (range 40–62)	56.2 $\pm$ 9.8 years (range 48–73)	58.4 $\pm$ 12.5 years (range 42–71)
Gender	46 males (67.6%) 22 females (32.4%)	16 Males (23.5%) 10 females (14.7%)	22 males (32.3%) 7 females (10.3%)	8 males (11.7%) 5 females (7.4%)
CD4+ count (cell/mm <sup>3</sup> )	CD4+ count: 726.3 $\pm$ 201.4 cell/mm <sup>3</sup> (range 400–1100 cell/mm <sup>3</sup> )	CD4+ count: 655.88 $\pm$ 208.5 cell/mm <sup>3</sup>	CD4+ count: 779.83 $\pm$ 203.6 cell/mm <sup>3</sup>	CD4+ count: 747.69 $\pm$ 145.04 cell/mm <sup>3</sup>

To detect possible associations between the level of oral hygiene and the study outcomes, a nonparametric Spearman's rank correlation analysis was run, relating the average PI score (i.e., a score obtained by averaging patients' PI index considered at T1 and T2) and the number of implant failures. Always by means of a Spearman's rank correlation analysis, we then correlated this average PI score with MBLC, and also with the number of peri-implantitis. Finally, to further illuminate possible associations with oral health, the outcomes were correlated with the mean scores of BI and PPD (i.e., with mean scores obtained by averaging separately both BI and PPD indexes, considered at T1 and T2).

All analyses were performed with a dedicated software (SPSS Inc., version 20.0). The conventional level of statistical significance was set at  $\alpha = 0.05$ .

## RESULTS

Demographic data of the sample are reported in Table 3.

Overall, 194 implants were positioned in 68 patients (22 females and 46 males). Forty-eight patients (70.6%) received total removable dentures; 11 patients (16.2%) received partial prosthesis, and nine patients (13.2%) received single elements. Because of an exacerbation of their systemic disease, two patients (each of them had two implants in the mandible with removable prosthesis) dropped out from the study between T0 and T1, thus leading to a final sample of  $N = 66$  patients at T1 (190 fixtures). The flow chart of the study is represented in Figure 1.

Failures occurred in 7.9% of the fixtures (15 fixtures out of 190). Five fixtures out of 190 (2.6%) failed due to early infection and 10 out of 190 (5.2%) due to peri-implantitis. Prosthetic failure was registered in two patients (2.9% of patients) due to the loss of all the

fixtures. Pus and pain were observed in 4/7 and 3/7 patients with peri-implantitis, respectively. No fractures of fixtures or paresthesia were registered. At T2, the mean peri-implant MBLC was  $-1.19 \pm 0.87$  mm.

### CD4+ Level

No significant difference was observed comparing patients with  $CD4+ \leq 749.5$  and patients with  $CD4+ > 749.5$  with respect to any of the outcome variables (Table 4). A MANOVA confirmed this result by assessing the significance of simultaneous variations in the measurement of "failure of implants" versus "failure of prosthesis" versus "MBLC" indices as a function of patients grouping with respect to CD4+ levels (patients with  $CD4+ \leq 749.5$  vs patients  $CD4+ > 749.5$ ). The multivariate analyses revealed a trivial main effect for measures, such that the mean values observed for MBLC were higher than the mean values of both failure of implants and failure of prosthesis measures – this effect being simply due to the different scale metrics used in assessing the three indices. Most importantly, however, the analysis confirmed the absence of a significant difference between groups of patients, and also revealed no interaction between group of patients and the three dependent variables entered in the multivariate analyses.

### Smoking Habits

The number of implant failures resulted significantly different between no/light smokers and heavy smokers (Mann–Whitney  $U = 508$ ,  $z = 2.78$ ,  $p < .005$  (Table 5). In addition, it was also observed that patients smoking  $>10$  cigarettes/day, if compared with their counterparts of patients smoking  $<10$  cigarettes/day, showed a statistically significant greater number of peri-implantitis



960 *Clinical Implant Dentistry and Related Research, Volume 18, Number 5, 2016*

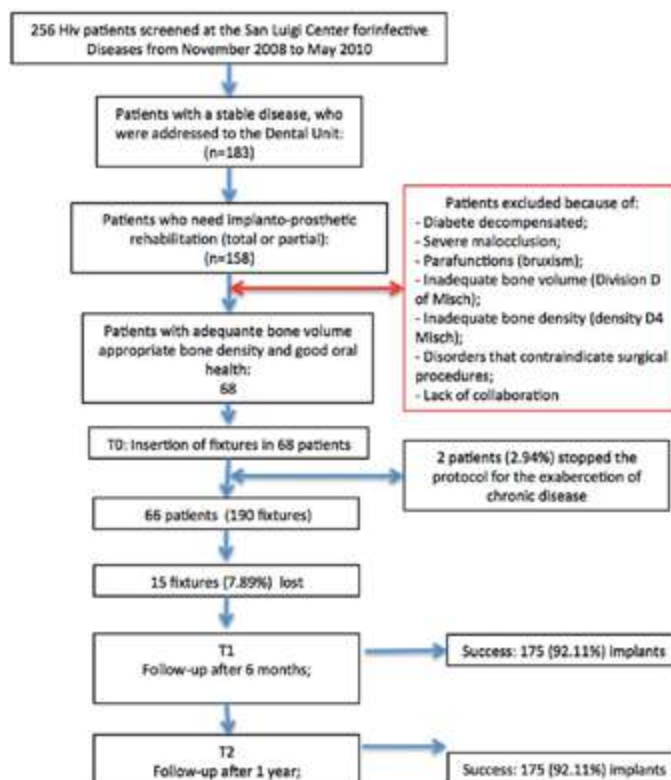


Figure 1 Flow chart of the study.

TABLE 4 Results Represented at Patient Level			
	CD4+ ≤ 749.5 (n = 33)	CD4+ > 749.5 (n = 33)	Significance
Failure of implants	6 out of 33 (18.1%)	2 out of 33 (6%)	NS
Failure of Prosthesis	2 out of 33 (6%)	0 out of 33 (0%)	NS
MBLC	1.09 ± 0.32 (mm)	1.12 ± 0.36 (mm)	NS
Peri-implantitis	5 out of 33 (15.1%)	2 out of 33 (6%)	NS
Pus	2 out of 33 (6%)	0 out of 33 (0%)	NS
Pain	2 out of 33 (6%)	0 out of 33 (0%)	NS

Patients were grouped on the basis of CD4+ level.

**TABLE 5** Results Represented at Patient Level

	No smoking patients and patients smoking <10 cigarettes/day	Patients smoking >10 cigarettes/day	Significance
Failure of implants	54 (81.9%) 4 out of 54 (7.4%)	12 (18.1%) 5 out of 12 (41.6%)	Mann–Whitney $U = 508$ , $z = 2.78$ ; $p \leq .005$
Failure of Prosthesis	1	1	NS
MBLC	$1.09 \pm 0.35$	$1.17 \text{ mm} \pm 0.31$	NS
Peri-implantitis	2 out of 54 (3.7%)	5 out of 12 (41.6%)	Mann–Whitney $U = 518$ , $z = 3.38$ $p \leq .001$
Pus	1 out of 54 (1.8%)	4 out of 12 (33.3%)	Chi-squared = 7.22 $p \leq .007$ , with Yates continuity correction; Fisher Exact test $p = .007$
Pain	0 out of 54 (0%)	3 out of 12 (25%)	Chi-squared = 6.85 $p \leq .009$ , with Yates continuity correction; Fisher Exact test $p = .009$

Patients were grouped on the basis of smoking habits.

(Mann–Whitney  $U = 518$ ,  $z = 3.38$ ,  $p < .001$ ), a comparatively higher incidence of pus (chi-squared = 7.22,  $p < .007$  with Yates continuity correction, this result being independently confirmed also by a Fisher's exact test,  $p = .007$ ), and a comparatively higher incidence of self-reported pain (Chi-squared = 6.85,  $p < .009$  with Yates continuity correction, this result being independently confirmed also by a Fisher Exact test,  $p = .009$ ).

No/light smokers and heavy smokers showed no significant differences in mean MBLC recorded on survived implants after 1 year from insertion (Mann–Whitney  $U = 439.5$ ,  $z = 0.621$ ,  $p = .53$ ). MBLC was calculated excluding all those implants affected by peri-implantitis (10 sites) or early infection (five sites) that failed before 6 months of follow-up. More specifically, MBLC of survived implants at 1 year follow-up was  $1.09 \pm 0.35$  mm in the first group of patients, and  $1.17 \pm 0.31$  mm in the second (comparison) group.

#### PI, BI, PPD

No statistically significant associations were observed between averaged PI scores (i.e., scores forming an index whose values were obtained by averaging patients' PI scores across T1 and T2) and implant failures (Spearman's  $\rho = -0.14$ ,  $p = .25$ ;  $n = 66$ ); between PI and

MBLC (Spearman's  $\rho = -0.06$ ,  $p = .67$ ;  $n = 66$ ); and between averaged PI scores and peri-implantitis (Spearman's  $\rho = -0.14$ ,  $p = .25$ ;  $n = 66$ ), respectively (Table 6). A similar pattern of results was observed also for the averaged BI scores (i.e., scores forming an index whose values were obtained by averaging patients' BI scores across T1 and T2), though no statistically significant associations were observed between averaged BI scores and implant failures (Spearman's  $\rho = 0.09$ ,  $p = .45$ ;  $n = 66$ ); between averaged PI scores and MBLC (Spearman's  $\rho = -0.04$ ,  $p = .75$ ;  $n = 66$ ); nor between averaged PI scores and peri-implantitis (Spearman's  $\rho = 0.08$ ,  $p = .52$ ;  $n = 66$ ). Also, average PPD scores (i.e., patients' PPD values averaged across T1 and T2) showed any statistically significant association with implant failure ( $n = 66$ , Spearman's  $\rho = 0.07$ ,  $p = .57$ ), nor with MBLC ( $n = 66$ , Spearman's  $\rho = -0.01$ ,  $p = .95$ ). No further statistically significant association emerged between PPD and peri-implantitis ( $n = 66$ , Spearman's  $\rho = 0.03$ ,  $p = .84$ ).

#### DISCUSSION

Limited published scientific evidence is available to guide clinicians regarding possible increased risks associated with dental implant placement in HIV-positive

**TABLE 6 Correlations with Mean PI, Mean BI, and Mean PPD (mean value between registration at T1 and T2)**

Variable 1	Variable 2	Significance
Failure of implants	Mean PI (1.33 ± 0.22)	$n = 66$ , Spearman's rho = $-0.14$ , $p = .25$
MBLC	Mean PI (1.33 ± 0.22)	$n = 66$ , Spearman's rho = $-0.06$ , $p = .67$
Peri-implantitis	Mean PI (1.33 ± 0.22)	$n = 66$ , Spearman's rho = $-0.14$ , $p = .25$
Failure of implants	Mean BI (0.64 ± 0.26)	$n = 66$ , Spearman's rho = $0.09$ , $p = .45$
MBLC	Mean BI (0.64 ± 0.26)	$n = 66$ , Spearman's rho = $-0.04$ , $p = .75$
Peri-implantitis	Mean BI (0.64 ± 0.26)	$n = 66$ , Spearman's rho = $0.08$ , $p = .52$
Failure of implants	Mean PPD (1.92 ± 0.26)	$n = 66$ , Spearman's rho = $0.07$ , $p = .57$
MBLC	Mean PPD (1.92 ± 0.26)	$n = 66$ , Spearman's rho = $-0.01$ , $p = .95$
Peri-implantitis	Mean PPD (1.92 ± 0.26)	$n = 66$ , Spearman's rho = $0.03$ , $p = .84$

patients. In this study, a group of HIV-positive patients was subjected to implant-prosthetic therapy and followed for a period of 1 year. Implant failures, prosthetic failures, complications, or MBLC were not significantly associated to the level of CD4+ in the blood. Different authors found similar results.<sup>4,8,16,17</sup> Oliveira and colleagues<sup>4</sup> followed 59 implants for 12 months after loading. Higher baseline levels of pyridinoline and deoxypyridinoline found in HIV-positive participants did not interfere with osseointegration after 12 months of follow-up. They concluded that the placement of dental implants in HIV-positive patients is a reasonable treatment, regardless of CD4+ cell count, viral load levels, and type of antiretroviral therapy.

Stevenson and colleagues,<sup>8</sup> in a prospective study including 20 HIV-positive subjects (test group) and nine HIV-negative subjects (control group) reported that the short-term (6 months) success rate was 100% for both groups, and no difference in clinical outcome was found between the groups.

Achong and colleagues<sup>16</sup> in a report of three cases indicated that implant surgery may not carry an increased risk for the HIV-positive patient, and the low CD4+ cell count levels at the time of implant placement appear to have no effect on the success of implants. The various levels of CD4+ cell counts throughout treatment for these three patients did not correlate with the outcome of the implants.

Thus, according to our results, the placement of dental implants in HIV-positive patients seems a reasonable therapy, regardless of CD4+ cell count, if patients have a stable disease.

The study of the association between smoking habits and implant failure did not reach statistical sig-

nificance when participants were grouped into three categories of patients (no smoking patients vs patients who smoked  $\leq 10$  cigarettes/day vs patients who smoked  $> 10$  cigarettes/day), because of an insufficient number of patients assigned to each category. When nonsmoking patients and patients who smoked  $\leq 10$  cigarettes/day were categorized together, however, we observed significantly more implant failures, peri-implantitis, episodes of pus, and pain in heavy smokers ( $> 10$  cigarettes/day) than nonsmokers–light smokers ( $< 10$  cigarettes/day). Considering the timing of failures, these results correlate well with the reports in the literature linking smoking to early implants failures<sup>18</sup> and to peri-implantitis.<sup>19</sup> HIV-positive smokers are more susceptible to oral infections (candidiasis and hairy leukoplakia) than HIV-positive nonsmokers.<sup>20</sup> This susceptibility plays an important role for implant failure. Implant failures are more frequent among smokers (5.6%) compared with nonsmokers (3.5%),<sup>21</sup> probably due to lowering blood flow rate, due to increased peripheral resistance and platelet aggregation, or to modifications in the level of immunoglobulines in the saliva.<sup>22</sup>

In our sample, MBLC of survived implants at 1-year follow-up was found to be  $1.09 \pm 0.35$  mm in the group of nonsmokers or light smokers ( $< 10$  cigarettes/day), and  $1.17 \pm 0.31$  mm in smokers.

In literature, the average peri-implant bone loss after 12 months is lower, about 0.47 to 0.49 mm in HIV-positive patients.<sup>4</sup> Perhaps the difference could be related the fact that bone loss was measured from implant insertion and not from implant loading.

MBLC was recorded as a difference between baseline and 1-year data and, because of the early failure (before 6 months from loading) of implants affected by

peri-implantitis, the MBLC value in the groups of implants with peri-implantitis is unknown. So, the correlation between MLBC and dependent variables cannot be excluded.

Moreover, the number of implant failures, prosthetic failures, peri-implantitis, episodes of pus, and pain did not correlate with bleeding or oral hygiene or PPD (mean values of BI, PI, or PPD between T1 and T2). However, patients were initially included only if they had a good oral hygiene and followed a strict maintenance recall system.

### CONCLUSIONS

Within the limitation of the present study, placement of dental implants in HIV-positive patients with stable disease seems a reasonable treatment option, regardless of CD4+ cell count. Oral hygiene variables did not influence the result of the treatment in a well-maintained population. HIV-positive heavy smokers (>10 cigarettes/day) demonstrated an increased risk for implant failure, for peri implantitis, episodes of pus, and self-reported pain.

### ACKNOWLEDGMENT

This study was co-funded by the Italian Ministry of Health, protocol number RF-FSR-2007-646412.

### REFERENCES

- Shetty K, Achong R. Dental implants in the HIV-positive patient—case report and review of the literature. *Gen Dent* 2005; 53:434–437.
- Kolhatkar S, Khalid S, Rolecki A, Bhola M, Winkler JR. Immediate dental implant placement in HIV-positive patients receiving highly active antiretroviral therapy: a report of two cases and a review of the literature of implants placed in HIV-positive individuals. *J Periodontol* 2011; 82:505–511.
- Romanos GE, Goldin E, Marotta L, Froum S, Tarnow DP. Immediate loading with fixed implant-supported restorations in an edentulous patient with an HIV infection: a case report. *Implant Dent* 2014; 23:8–12.
- Oliveira MA, Gallottini M, Pallos D, Maluf PS, Jablonka F, Ortega KL. The success of endosseous implants in human immunodeficiency virus-positive patients receiving antiretroviral therapy: a pilot study. *J Am Dent Assoc* 2011; 142:1010–1016.
- Bergendal B. Evidence and clinical improvement: current experiences with dental implants in individuals with rare disorders. *Int J Prosthodont* 2006; 19:132–134.
- Passaes CP, Saez-Cirion A. HIV cure research: advances and prospects. *Virology* 2014; 454–455:340–352.
- Gherlone E, Capparé P, Tecco S, et al. Implant prosthetic rehabilitation in controlled HIV-positive patients: a prospective longitudinal study with one-year follow-up. *Clin Implant Dent Relat Res* 2015; 7;doi: 10.1111/cid.12353.
- Stevenson GC, Riano PC, Moretti AJ, Nichols CM, Engelmeier RL, Flaitz CM. Short-term success of osseointegrated dental implants in hiv-positive individuals: a prospective study. *J Contemp Dent Pract* 2007; 8:1–10.
- Harrison WJ, Lewis CP. Wound healing after implant surgery in HIV-positive patients. *J Bone Joint Surg* 2002; 84:802–806.
- Tran H, Moncure M, Tarnoff M, et al. Predictors of operative outcome in patients with human immunodeficiency virus infection and acquired immunodeficiency syndrome. *Am J Surg* 2000; 180:228–233.
- Patton LL, Shugards DA, Bonito AJ. A systematic review of complication risks for HIV-positive patients undergoing invasive dental procedures. *J Am Dent Assoc* 2002; 133:195–203.
- Twito D, Sade P. The effect of cigarette smoking habits on the outcome of dental implant treatment. *PeerJ* 2014; 2:e546.
- Porter JA, von Fraunhofer JA. Success or failure of dental implants? A literature review with treatment considerations. *Gen Dent* 2005; 53:423–432, quiz 433, 446.
- von Elm E, Altman DG, Egger M, et al. The Strengthening the Reporting of Observational Studies in Epidemiology (STROBE) statement: guidelines for reporting observational studies. *J Clin Epidemiol* 2008; 61:344–349.
- Crespi R, Capparé P, Gherlone E. A 4-year evaluation of the peri-implant parameters of immediately loaded implants placed in fresh extraction sockets. *J Periodontol* 2010; 81:1629–1634.
- Achong RM, Shetty K, Arribas A, Block MS. Implant in HIV-positive patients: 3 case reports. *J Oral Maxillofac Surg* 2006; 64:1199–1203.
- Strietzel FP, Rothe S, Reichart PA, Schmidt-Westhausen AM. Implant-Prosthetic treatment in HIV-infected patients receiving highly active antiretroviral therapy: report of cases. *Int J Oral Maxillofac Implants* 2006; 21:951–956.
- De Bruyn H, Collaert B. The effect of smoking on early implant failure. *Clin Oral Implants Res* 1994; 5:260–264.
- Saaby M, Karring E, Schou S, Isidor F. Factors influencing severity of peri-implantitis. *Clin Oral Implants Res* 2014; doi: 10.1111/clr.12505.
- U.S. Department of Health and Human Services. *AIDS.gov: HIV and Smoking* [last revised 2013 Jul 5; accessed 2014 Apr 17]. 2013.
- Klokkevold PR, Han TJ. How do smoking, diabetes, and periodontitis affect outcomes of implant treatment? *Int J Oral Maxillofac Implants* 2007; 22(Suppl):173–202.

964 *Clinical Implant Dentistry and Related Research, Volume 18, Number 5, 2016*

22. Giuca MR, Pasini M, Tecco S, Giuca G, Marzo G. Levels of salivary immunoglobulins and periodontal evaluation in smoking patients. *BMC Immunol* 2014; 15:5.
23. Maini MK, Gilson RJ, Chavda N, et al. Reference ranges and sources of variability of CD4 counts in HIV-seronegative women and men. *Genitourin Med* 1996; 72:27–31.
24. Chilton D, Neuhaus J, Palfreeman A. Utility of CD4 count monitoring in patients on HAART who maintain viral load suppression – experience from the VS arm of the SMART study. 14th British HIV Association Conference, 23–25 April 2008, Belfast, Ireland. Abstract O21.

## Implant Prosthetic Rehabilitation in Controlled HIV-Positive Patients: A Prospective Longitudinal Study with 1-Year Follow-Up

Enrico F. Gherlone, MD, DMD;\* Paolo Capparé, MD, MFS;† Simona Tecco, DDS, PhD;‡  
Elisabetta Polizzi, BS;‡ Giuseppe Pantaleo, PhD;§ Giorgio Gastaldi, MD, DMD;¶  
Maria Gabriella Grusovin, DDS\*\*

### ABSTRACT

**Purpose:** The clinical trial aimed to evaluate the survival of implant-prosthetic rehabilitation in controlled HIV-positive patients.

**Materials and Methods:** This mono-centric study included HIV patients with a stable disease, requiring implant rehabilitation, with good oral hygiene. Each patient received at least one dental implant. After 90 days in the upper jaw and 60 days in the lower jaw, the appropriate prosthesis was delivered. Primary outcome measures were prosthetic failures, implant failures, peri-implant marginal bone level changes (MBLCs), and biological complications (peri-implantitis, pus, pain, paresthesia). Data were recorded before the intervention (T0), and 6 (T1) and 12 months (T2) after.

**Results:** Implants were positioned in 68 patients (22 females and 46 males; 194 implants). Two dropouts occurred for exacerbation of the disease before the sixth month of follow-up, and 66 patients (with 190 implants) completed the study. Forty-eight patients (70.6%) received total removable dentures; 11 patients (16.2%) received partial prosthesis, and nine patients (13.2%) received single elements. Implant failure occurred in nine patients (15 fixtures out of 190). These were early implant failures due to primary infection (five fixtures out of 190: 2.6%) and to peri-implantitis (10 fixtures out of 190: 5.2%). Prosthetic failure was registered in two patients (3% of patients) due to the loss of all the fixtures. Pus and pain were observed in 4/7 and 3/7 patients with peri-implantitis, respectively. No fractures of fixtures or paresthesia were registered. At T2, the mean peri-implant MBLC was  $-1.19 \pm 0.87$  mm.

**Conclusions:** Within its limitations, the study showed that in a well-controlled population of HIV patients implant rehabilitation can be a suitable options with results slightly worse to those obtained in normal population. A higher incidence of peri implant infections in the first six months was present pointing to the need of a proper protocol for infection control.

**KEY WORDS:** AIDS, HIV, implant, implant survival, implantology, osseointegration, peri-implantitis

### INTRODUCTION

AIDS is one of the most serious diseases affecting humanity. By the end of 2007, about 33 million people worldwide were living with HIV, and millions had died of AIDS.<sup>1</sup>

Today, life expectancy for HIV-infected individuals has increased due to the use of potent antiretroviral therapy.<sup>2</sup> With the sustained reduction in AIDS-related morbidity and mortality, the prospect of living with HIV as a chronic, rather than a terminal, disease has

\*Full professor and chairman, Dental School, Vita-Salute University and IRCCS San Raffaele, Milan, Italy; †researcher, Dental School, Vita-Salute University and IRCCS San Raffaele, Milan, Italy; ‡adjunct professor, Dental School, Vita-Salute University and IRCCS San Raffaele, Milan, Italy; §associate professor, Faculty of Psychology, UniSR Social Lab (Research Methods), Vita-Salute San Raffaele University, Milan, Italy; ¶associate professor, Dental School, University of Brescia, Brescia, Italy; \*\*adjunct professor, Dental School, Vita-Salute San Raffaele University, Milan, Italy

Corresponding Author: Dr. Paolo Capparé, Dentistry Department, IRCCS San Raffaele Hospital, Via Olgettina n. 48, Milan 20132, Italy; e-mail: paolocappare@gmail.com

Conflict of Interest: No author had any conflict of interest. The material is original and has not been published elsewhere.

© 2015 Wiley Periodicals, Inc.

DOI 10.1111/cid.12353



increased, and HIV-infected edentulous patients are becoming informed consumers of oral healthcare and are requesting a variety of procedures, including dental implants.<sup>3</sup>

Oral health is generally very poor for HIV-positive individuals, as about 40% to 50% of HIV-positive persons have oral fungal, bacterial or viral infections often occurring early in the course of the disease.<sup>3</sup> The most important etiopathogenetic factors are immunodeficiency states, alterations in the salivary flow (xerostomia), nutritional deficiencies, secondary occlusal trauma and the increase in plaque due to poor oral hygiene.<sup>4</sup>

Oral lesions strongly associated with HIV infection are pseudo-membranous oral candidiasis, oral hairy leukoplakia, HIV gingivitis and periodontitis, kaposi sarcoma, non-Hodgkin lymphoma, and dry mouth due to a decreased salivary flow.<sup>5</sup> Moreover, in these patients, the carious disease is often destructive, affecting large areas of enamel, especially at the cervical-vestibular, and involves painful symptoms only in very advanced stages, when it is more difficult to apply conservative intervention.<sup>5</sup> In addition, there is a high incidence of periodontal ulcerative-necrotic disease.<sup>4</sup> Many of these problems can progress to the point that result in partial or complete loss of the natural dentition.<sup>6</sup> Treatment of oral pathologies is mandatory in HIV patients to minimize and possibly eliminate all infections because they can be the starting point for more serious systemic infections able to undermine the general health.<sup>6</sup> Besides, the pathological problems of the oral cavity contribute to prevent the social rehabilitation of HIV patients, since these individuals can present functional and aesthetic situations (partially edentulous and/or total root residues, destructive caries) not compatible with a good interpersonal relationship, and their treatments contribute enormously to the self-esteem.<sup>3,4</sup> Implants can be in most cases the optimal therapeutic solution, but there is a lack of data<sup>7-9</sup> in literature about oral implant-prosthetic rehabilitations of HIV patients, except for mandibular overdenture.<sup>10</sup> Data are needed to help in properly treating these types patients and so in promoting their oral health and eventual social reintegration into society and the world of work.

This prospective longitudinal clinical trial aimed to evaluate survival of implant-prosthetic rehabilitation in controlled HIV-positive patients, with good oral

hygiene. One-year follow-up after implant insertion was considered. Survival criteria for implant were presence of implant stability, absence of radiolucent zone around the implants, no mucosal suppuration, and no pain (Buser, and Albrektsson and Isidor).<sup>11,12</sup>

In this article, the Strobe guidelines (Strengthening the Reporting of Observational Studies in Epidemiology) were followed.<sup>13</sup>

## MATERIALS AND METHODS

This longitudinal prospective mono-centric trial (IRCCS San Raffaele Hospital in Milan, Italy)<sup>14</sup> included controlled HIV-affected patients that required implant rehabilitation.

The eligibility criteria were as follows:

- HIV-positive patients
- Age >18 years
- Total or partial edentulous
- Adequate bone volume (divisions A, B, or C according to Misch classification of bone available<sup>15</sup>) and appropriate bone density (classes D1, D2, or D3 Misch<sup>16</sup>);
- Blood values:
  - CD4+ level count >400 cells/mm<sup>3</sup>
  - Hemoglobin >8 mg/dl
  - Absolute neutrophil count >750 cells/mm<sup>3</sup>
  - Platelets >75.000 cells/mm<sup>3</sup>
  - AST < 5 times the upper limit of normal value (ULN)
  - Bilirubin <2.5 times ULN
  - Alkaline phosphatase <5 times ULN
  - Creatinine <2.5 mg/ml

Exclusion criteria were as follows:

- Severely immunocompromised patients with a high recurrence of opportunistic infections, tuberculosis, or malignancy spread
- Diabetes decompensated
- Severe malocclusion
- Severe parafunctions (bruxism)
- Inadequate bone volume (Division D of Misch)
- Inadequate bone density (density D4 Misch)
- Disorders that contraindicate surgical procedures
- Lack of collaboration
- Lack of oral hygiene: plaque index superior to 1

The patients were recruited at the San Luigi Center for Infective Diseases, IRCCS San Raffaele Hospital,

Milan, in which HIV-infected patients are kept under medical control.

All those who submit the medical parameters and blood values of a stable disease were then addressed at the Department of Dentistry, IRCCS San Raffaele Hospital, Milan, Italy.

The patients with partial or total edentulism, which could benefit from an implant-prosthetic rehabilitation, were then selected according to the described inclusion/exclusion criteria.

All patients received and signed a written consent form for implant procedures, and the Italian Ministry of Health approved the protocol.

#### Interventions Administered to the Group

During the first dental examination of the patients, the following procedures were done:

- General intraoral examination
- Evaluation of the orthopantomography or any Tc Dental scans
- Implant planning (number of fixtures; the location, the type of prosthesis)

A few days before the surgery, periodontal health checkup (by the hygienist or dentist) was performed<sup>17</sup>: modified bleeding index (mBI); modified plaque index (mPI); and probing depth (PD) (Table 1). This stage was the T0 for the clinical periodontal parameters.

At the day scheduled for the surgery, implants were positioned after antibiotic prophylaxis with amoxicillin and clavulanic acid, 2 g orally, 1 hour before surgery. A full-thickness flap was raised, and implant placement was conducted in accordance with the manufacturer protocol (WinSix®, BioSAFin. S.r.l., Ancona, Italy). Conical implants with rough surface (full contact covering® surface, Biosafin, Ancona, Italy) and internal hexagon connection were used (K implants, WinSix).

Postoperative therapy consisted of amoxicillin and clavulanic acid 1 g × 2 per day for 7 days after surgery, rinse with 0.2% chlorhexidine twice a day for 15 days after surgery, and pain medication as needed. Suture removal was carried out after 7 to 10 days. Re-entry procedures for healing abutment placement were performed in each case at least after 50 days from implant placement.

After 90 days for the upper jaw and 60 days for the lower jaw, a precise impression was made.

For total removable dentures, ball attachments were screwed directly onto the abutments, and two ball housings (matrices) were mounted in the overdenture.

For single crowns and fixed partial dentures, definitive metal-ceramic restorations were cemented onto the definitive abutments.

#### Outcome Measures

The outcomes considered were as follows:

1. Prosthesis failure: when prosthesis has to be replaced due to implant failure.
2. Implants failure: implant removal dictated by mobility, progressive marginal bone loss due to peri-implantitis, any mechanical complication rendering the implant not usable (e.g., implant fracture). The stability of each individual implants was assessed manually 6 and 12 months from insertion by tightening the abutment screws with the removed prostheses.
3. Biological and prosthetic complications (number and type) were recorded as single episodes for each implant. Particular attention was used to assess peri-implantitis (defined as progressive bone loss with sign of infections around an osseointegrated implant), presence of pain, presence of pus, paresthesia in the lower jaw, implant fracture.

**TABLE 1** Periodontal Health Indices and Details of Methods of Measurement

Variable	Timing	Method
Modified bleeding index (mBI)	T0, T1, and T2	Values were recorded at the mesial, distal, buccal, and palatal surfaces of the implants using a periodontal probe (PGF-GFS, Hu-Friedy, Chicago, IL, USA).
Modified plaque index (mPI)	T0, T1, and T2	Values were recorded at the mesial, distal, buccal, and palatal surfaces of the implants using a periodontal probe (PGF-GFS, Hu-Friedy, Chicago, IL, USA).
Probing depth (PD)	T0, T1, and T2	Values were recorded at the mesial, distal, buccal, and palatal surfaces of the implants using a periodontal probe (PGF-GFS, Hu-Friedy, Chicago, IL, USA).

4. Peri-implant marginal bone level changes (MBLCs): Periapical radiographs were taken at T0 (immediately after the insertion of the fixture) and at T2 (1-year follow-up). They were made perpendicular to the long axis of the implant with long-cone parallel technique, using an occlusal custom template to measure the marginal bone level. A dedicated dentist measured the changes in crestal bone height over time. The difference in bone level was measured radiographically through specific software (DIGORA 2.5, Soredex, Tuusula, Finland). The software was calibrated for every single image using the known implant diameter at the most coronal portion of the neck of the implant. The linear distance between most coronal point of bone-to-implant contact and the coronal margin of the implant collar was measured to the nearest 0.01 mm, at both mesial and distal sides, and averaged. Bone level changes at single implants were averaged at patients level and then at group level.

#### Follow-Up Evaluation

The appointments with the dental hygienist were scheduled each 2 months. For the oral hygiene at home, patients were instructed on the proper use of aids such as interproximal brush, mono tuft toothbrush, and Super floss. Patients were recommended to brush their teeth at least three times a day.

Complete examination of the patient was done at 6 and 12 months after implant insertion.

#### Analysis of Data

Data were analyzed at patient level. Demographic data on age, gender, and CD4+ level counts at T0 were reported and summarized in form of means, standard deviations, frequencies, and range.

The height, the diameter, and the position of the inserted fixtures were specified for the whole sample, and the frequency of the types of prosthetic rehabilitation (upper total; lower total; partial or single elements) was calculated for the whole sample.

For the outcome measures, the number of implant failures, prosthetic failures, peri-implantitis, episodes of pus, pain, paresthesia, and fracture of fixtures was reported as absolute values and/or percentages in the whole sample (190 implants in 66 patients). Comparisons of MBLC levels among patients with different prosthetic rehabilitations were performed by means of a

one-way ANOVA, and a nonparametric Kruskal–Wallis test for independent samples.

Cumulative survival rate of implants was also reported.

#### RESULTS

From November 2008 to May 2010, 256 HIV-positive patients (age >18 years) were screened at the San Luigi Center for Infectious Diseases, IRCCS San Raffaele Hospital, Milan, in which HIV-infected patients are monitored and given medical assistance. Seventy-three patients were excluded from further assessment because they were severely immunocompromised (CD4+ level <400 cell/mm<sup>3</sup>), with a high recurrence of opportunistic infections, tuberculosis, or malignancy spread, and had altered values of hemoglobin, absolute neutrophil count, platelets, AST, bilirubin, alkaline phosphatase, and creatinine.

The remaining patients ( $N = 183$ ) met the medical parameters of a stable disease and were thus addressed to the Department of Dentistry, IRCCS San Raffaele Hospital, Milan, Italy.

At the Department of Dentistry, patients with partial or total edentulism (i.e., who could possibly benefit from implant-prosthetic rehabilitation) were firstly individuated ( $n = 158$ ).

Of these 158 patients, 90 were excluded for the following reasons:

- Disorders that contraindicated surgical procedures ( $n = 25$ ), among which diabetes decompensated ( $n = 13$ ), severe malocclusion ( $n = 1$ ), severe parafunctions (bruxism) ( $n = 4$ ), inadequate bone volume (division D of Misch) ( $n = 5$ )
- Inadequate bone density (density D4 Misch) ( $n = 1$ )
- Patients refusing to collaborate ( $n = 23$ )
- lack of oral hygiene ( $n = 31$ )

Thus, 68 patients (22 females and 46 males) were included in the study and treated between November 2008 and July 2011. Among them, 26 (38.2%) were no smokers; 29 (42.6%) were lightly smokers (<10 cigarettes/day), and 13 (19.1%) were heavy smokers. Because of an exacerbation of their systemic disease, two patients (each of them had two implants in the mandible with removable prosthesis) dropped out from the study between T0 and T1, thus resulting in a final sample of  $N = 66$  patients at T1 (190 fixtures) (Figure 1).

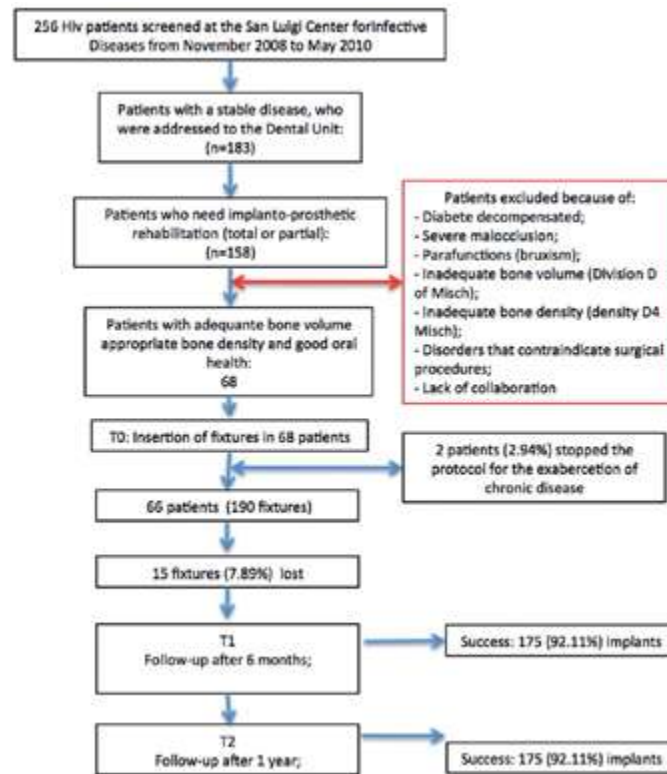


Figure 1 Flow chart of the sample included in the study.

Demographic data of patient population are reported in Table 2.

Fifty-seven patients (83.8%) received two to four fixtures, nine patients (13.2%) received a single fixture, and two patients (3%) received five and six fixtures; consequently, 48 patients (70.6%) were rehabilitated with total removable dentures (among them,

30 subjects received the upper dental arch, and 18 patients received the lower dental arch); 11 patients (16.2%) received partial prosthesis, and nine patients (13.2%) received single element rehabilitations (Figure 2 and Table 3).

The trend of periodontal health indices over time for the whole sample is showed in Figure 3. The appointments with the dental hygienist were scheduled each 2

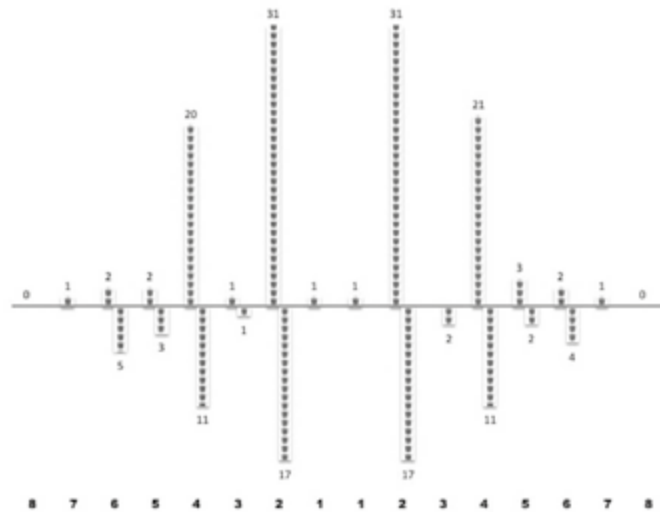
TABLE 2 Demographic Data of Patient Population

Whole Sample N: 68 (100%)	
Age	55.3 ± 17.2 Years (range 40–73)
Gender	46 Males (67.6%) 22 Females (32.4%)
CD4+ count (cell/mm <sup>3</sup> )	CD4+ count: 726.3 ± 201.4 cell/mm <sup>3</sup> (range 400–1,100 cell/mm <sup>3</sup> )
Smokers	42 (30 males; 12 females)

TABLE 3 Implant Diameter and Length

Diameter (mm)	Length of the Fixtures (mm)			
	9 (%)	11 (%)	13 (%)	Total (%)
3.3	53 (27.9)	9 (4.7)	5 (2.6)	67 (35.2)
3.8	16 (8.4)	15 (7.9)	18 (9.5)	49 (25.8)
4.5	29 (15.3)	26 (13.7)	19 (10)	74 (38.9)
Total	98 (51.6)	50 (26.3)	42 (22.1)	190

730 *Clinical Implant Dentistry and Related Research, Volume 18, Number 4, 2016*



**Figure 2** Distribution of the implants in the various sites of the mouth.

months during the follow-up. Sometimes, patients failed to visit the hygienist but they were always recalled for an another appointment.

**Prosthetic Failure**

Prosthetic failure was registered in two patients (2.9%) who had suffered the loss of all the implants positioned in their mouth; prosthetic failure occurred before T1.

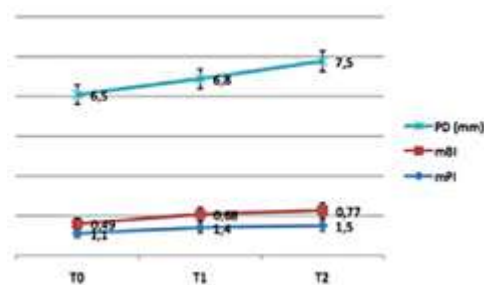
One patient was a female smoker, (CD4+ level 675 cell/mm<sup>3</sup>; PI = 1) who lost four out of four implants before T1 (two implants due to peri-implantitis and two implants due to primary infection) and had received an upper prosthesis.

The other patient was a male smoker (CD4+ level 689 cell/mm<sup>3</sup>; PI = 0) who lost two out of two implants before T1 (one implant due to peri-implantitis and one implant due to primary infection) and had received an upper prosthesis.

**Implant Failure**

Nine patients (out of 66) experienced implant failure, and a total of 15 fixtures out of 190 (7.9%) were lost (Table 4). The cumulative survival rate was 92.1%. Ten implant out of 190 (5.2%) were lost for peri-implantitis in seven patients; five implants out of 190 (2.7%) were lost for primary infection in two patients. No fixture fracture occurred.

Five patients (7.5%) suffered the failure of one implant: three of them due to peri-implantitis before T1 and the other two due to primary infection soon after the insertion of the fixture.



**Figure 3** Trend of the periodontal health indices over time for the whole sample of patients analyzed (n = 66).

TABLE 4 Cumulative Survival Rate (CSR) of Implants			
	Fixtures	Lost Fixtures	CSR (%)
Surgery–10 days	190	1 (Primary failure)	99.47
10 Days–1 month	189	3 (Primary failure)	97.89
1–3 Months	186	1 (Primary failure)	97.37
3–6 Months	185	10 (Peri-implantitis)	92.11
6–1 Year	175	0	92.11

Three subjects (4.5%) suffered the failure of two implants. Specifically, a male smoker (CD4+ count: 774 cell/mm<sup>3</sup>) lost two out of four implants due to peri-implantitis before T1; another male smoker (CD4+ count: 689 cell/mm<sup>3</sup>) lost two out of two implants, one due to peri-implantitis before T1 and the other due to primary infection; and the third subject was a female smoker (CD4+ count: 845 cell/mm<sup>3</sup>) who lost two out of two implants due to peri-implantitis before T1.

One patient lost four out of four implants: Two implants were lost for peri-implantitis before T1, and two implants were lost due to primary infection; this woman is a smoker (CD4+ count: 675 cell/mm<sup>3</sup>) and lost the totality of the implants placed in her mouth before T1.

Once established as hopeless, the operator removed all failed implants due to their serious mobility; therefore, implants were removed without additional bone tissue.

#### Biological and Prosthetic Complications

Peri-implantitis was diagnosed in seven patients (10.6%), and 10 fixtures out of 190 total fixtures were interested (5.2%).

Further, in all of these patients, peri-implantitis always resulted in the loss of the interested fixture before T1. In all 10 cases, the peri-implantitis has been diagnosed after a period of 1 to 3 months from the prosthetic loading. Treatment procedure was not possible in any case since, in all cases, the need to remove the fixture in order to allow adjustment of the prosthesis and prevent prosthetic failure was immediately evident.

Three patients (4.5% of the whole sample) suffered from peri-implantitis, which affected the totality (100%) of their fixtures and also caused the complete loss of fixtures (100%). The remaining four patients (6% of the whole sample) suffered from peri-implantitis, which, instead, affected half (50%) of the positioned fixtures and also caused the loss of the 50% of the inserted fixtures.

Pus was observed in 4/7 patients with peri-implantitis. Pain was registered in 3/7 patients with peri-implantitis. In three patients, pus and pain were observed together. These three patients were affected by serious peri-implantitis; two of them lost the totality of their fixtures and also experienced prosthesis failure.

No paresthesia and no prosthetic complications were registered in the whole sample.

#### Peri-Implant MBLCs

At T2, in 66 patients with 190 fixtures, the mean peri-implant MBLC was  $-1.19 \text{ mm} \pm 0.87 \text{ mm}$  ( $-1.18 \text{ mm} \pm 0.85 \text{ mm}$  in the mesial site and  $-1.21 \text{ mm} \pm 0.89 \text{ mm}$  in the distal site).

MBLC did not differ among patients with different prosthetic rehabilitations (one-way ANOVA:  $F = 0.53$ ,  $p = .662$ ). Estimated means for MBLC were  $-1.16 \text{ mm} \pm 0.32$  in patients with total removable denture on ball attachment (superior);  $-1.03 \text{ mm} \pm 0.30$  in patients with total removable denture on ball attachment (inferior);  $-1.11 \text{ mm} \pm 0.4$  in patients wearing partial fixed prosthetic bridges (cemented); and  $-1.07 \text{ mm} \pm 0.44$  in patients with single crowns (cemented). A nonparametric Kruskal-Wallis test for independent samples confirmed the absence of statistical differences in MBLC levels among the four groups of patients (test statistic = 1.35,  $p = .716$ ).

#### DISCUSSION

This clinical trial aimed to evaluate the survival of implant-prosthetic rehabilitation in controlled HIV-positive patients with a stable disease, requiring implant rehabilitation, with good oral hygiene. A cumulative survival rate of 92.11% was reported. Other authors<sup>7,18-20</sup> reported higher survival rates of implants placed in HIV-positive patients, similar to the healthy population.

In a pilot study by Oliveira and colleagues,<sup>18</sup> 60 dental implants were placed in the posterior mandibles of 40 volunteers, divided into three groups: the first group was composed of HIV-positive patients receiving protease inhibitor (PI)-based HAART; the second was composed of HIV-positive patients receiving non-nucleoside reverse transcriptase inhibitor-based HAART (without PI); the third control group was composed of HIV-negative participants. The authors assessed peri-implant health 6 and 12 months after implant loading. After a follow-up period of 12 months, one patient died for exacerbation of AIDS, and the remaining implants healed uneventfully, with a good osseointegration. They concluded that the placement of dental implants in HIV-positive patients is a reasonable treatment option, with no statistically significant differences with healthy population, without evidence of possible increased risks associated with dental implant placement in HIV-positive patients.

Kolhatkar and colleagues<sup>19</sup> reported two cases of immediate postextraction implants in HIV-positive



patients with 100% success and, reviewing the literature about implantology in HIV-positive patients, described a total success rate up to 98.6%.

Moreover, Stevenson and colleagues<sup>10</sup> reported a 100% success rate in overdenture supported by two implants in HIV-positive patients compared with healthy subjects.

However, in the current literature, there are no studies with implant placements in more than 20 HIV patients, and often, single case reports were published and smokers were often excluded.<sup>7-9</sup> In our study, 66 patients were followed with 190 implants; 42 of them were smokers. Fifteen implants out of 190 (7.9%) in nine patients were early lost (before 6 months from the insertion), and prosthetic failure was registered before T1 in two patients (2.9% of the patients) who had suffered early implant failures.

In healthy subjects with healthy tissues and appropriate biomechanical load, long-term success rates of 93% to 98% for the fixtures have been described,<sup>20-22</sup> and early failure is generally reported in a percentage of 3% due to lack of osseointegration.<sup>23</sup> In the present study, early implant failure was caused by primary infection (before loading) which occurred in five implants out of 190 (2.7%) in two patients. Peri-implantitis was detected in 10 implants out of 190 (5.2%) (seven patients) and led to implant loss. Two patients experienced both primary infections and peri implantitis. This higher incidence of infections could probably be linked to immunologic condition, considering that oral hygiene was maintained at a good acceptable level, in which oral indices (mPI and mBI) did not show statistically significant changes over time (Figure 3). Possible clinical suggestion is to do a meticulous follow-up and increase the antimicrobial control in HIV patients.

Clinically suggestive is the presence of deep pockets around implants (mean value  $6.5 \text{ mm} \pm 0.49$ ), and PD increased over time in the whole sample, from a mean value of  $6.5 \pm 0.49 \text{ mm}$  to  $7.5 \pm 0.51 \text{ mm}$ , although a good oral hygiene has been maintained. This trend, although not statistically significant, could suggest a possible correlation with the HIV-positive status of these patients, but this data must be better investigated by subsequent studies, recalling these patients 3 to 4 years after implant placement and re-evaluating their PD.<sup>24,25</sup>

Mean bone loss was  $1.19 \text{ mm} \pm 0.87 \text{ mm}$ , slightly higher than values found by Oliveira and colleagues

about in HIV-positive patients ( $0.47\text{--}0.49 \text{ mm}$ ).<sup>18</sup> Perhaps the difference could be related to the presence of smokers, as Oliveira and colleagues<sup>18</sup> did not include smokers, or to the fact that bone loss was measured from implant insertion and not from implant loading.

However, other studies measured bone loss from implant placement in healthy patients, including smokers of less than 10 cigarettes/day, and reported similar values.<sup>17,26,27</sup>

At 1-year follow-up, all remaining fixtures achieved good osseointegration, documented by orthopantomograph and, clinically, by stability, absence of pain on percussion, and presence of infection. A good healing of the soft tissues and absence of prosthetic complications were observed in all the patients.

However, the present study presents some limits. Significant interpatient heterogeneity was recorded for the values of periodontal health, which could affect the results and the role of patient-related aspects (smoking habits, oral hygiene, CD4+ level), which could potentially influence periodontal health, and implant survival will be analyzed in a following paper.

A specific type of micro-rough implant surface, obtained with a galvanostatic anodizing process in a phosphate-sulfate bath, was used. The surface roughness could have an influence on the onset of peri-implantitis. The eventual influence of surface roughness will be investigated in a future trial.

The patients were followed in a specialized center, with expert clinicians working in collaboration with an infection center, so the generalization of the results should be considered. Expert clinicians and specialized hospitals seem much more adequate – with respect to private medical practice – to properly select HIV patients eligible for implantology and for the strict follow-up needed by these patients. In particular, infectious disease specialists could have an important role in determining the parameters to monitor the status of the systemic immune system of HIV-positive patients and to collaborate actively in the selection of patients at lower risk for implant-prosthetic rehabilitation treatment.

The results suggest that HIV patients should be included in a strict follow-up protocol monitoring oral hygiene and peri-implant health, mostly during the early phase of implant healing (0–6 months), to manage undesired complications and early implant failure.

## CONCLUSIONS

Within its limits, the study showed that in a well-controlled population of HIV patients who maintained proper oral hygiene and accepted to follow a proper professional maintenance protocol, implant rehabilitation can be a suitable options with results slightly worse to those obtained in normal population. A higher incidence of peri implant infections in the first six months was present pointing to the need of a proper protocol of infection control.

## ACKNOWLEDGMENT

This study was co-funded by the Italian Ministry of Health, protocol number RF-FSR-2007-646412.

## REFERENCES

- Murphy R. Treatment of HIV infection. In: Crowe S, Hoy J, Mills J, eds. Management of the HIV infected patient. 2nd ed. London: Martin Dunitz Ltd., 2002:117–128.
- Passaes CP, Saez-Cirion A. HIV cure research: advances and prospects. *Virology* 2014; 454–455:340–352.
- Bergendal B. Evidence and clinical improvement: current experiences with dental implants in individuals with rare disorders. *Int J Prosthodont* 2006; 19:132–134.
- Hwang D, Wang HL. Medical contraindications to implant therapy: part II: relative contraindications. *Implant Dent* 2007; 16:13–23.
- Patton L, Glick M. Clinician's guide to treatment of HIV-infected patients. 3rd ed. Baltimore, MD: American Academy of Oral Medicine, 2001.
- Alves M, Mulligan R, Passaro D, et al. Longitudinal evaluation of loss of attachment in HIV-infected women compared to HIV-uninfected women. *J Periodontol* 2006; 77:773–779.
- Achong RM, Shetty K, Arribas A, Block MS. Implant in HIV-positive patients: 3 case reports. *J Oral Maxillofac Surg* 2006; 64:1199–1203.
- Baron M, Gritsch F, Hansy AM, Haas R. Implants in HIV-positive patient: a case report. *Int J Oral Maxillofac Implants* 2004; 19:425–430.
- Strietzel FP, Rothe S, Reichart PA, Schmidt-Westhausen AM. Implant-Prosthetic treatment in HIV-infected patients receiving highly active antiretroviral therapy: report of cases. *Int J Oral Maxillofac Implants* 2006; 21:951–956.
- Stevenson GC, Riano PC, Moretti AJ, Nichols CM, Engelmeier RL, Flaitz CM. Short-term success of osseointegrated dental implants in HIV-positive Individuals: a prospective study. *J Contemp Dent Pract* 2007; 8:1–10.
- Buser D, Mericske-Stern R, Dula K, Lang NP. Clinical experience with one-stage, non-submerged dental implants. *Adv Dent Res* 1999; 13:153–161.
- Albrektsson T, Isidor F. Consensus report in Session V. In: Lang NP, Karring T, eds. Proceedings of the 1st European workshop on periodontology. London: Quintessence, 1993:365–369.
- von Elm E, Altman DG, Egger M, et al. The Strengthening the Reporting of Observational Studies in Epidemiology (STROBE) statement: guidelines for reporting observational studies. *J Clin Epidemiol* 2008; 61:344–349.
- Hanson BP. Designing, conducting and reporting clinical research. A step by step approach. *Injury* 2006; 37: 583–594.
- Misch CE. Divisions of available bone in implant dentistry. *Int J Oral Implantol* 1990; 7:9–17.
- Misch CE. Bone classification, training keys to implant success. *Dent Today* 1989; 8:39–44.
- Crespi R, Capparé P, Gherlone E. A 4-year evaluation of the peri-implant parameters of immediately loaded implants placed in fresh extraction sockets. *J Periodontol* 2010; 81:1629–1634.
- Oliveira MA, Gallottini M, Pallos D, Maluf P, Jablonka F, Ortega KL. The success of endosseous implants in human immunodeficiency virus-positive patients receiving anti-retroviral therapy. A pilot study. *J Am Dent Assoc* 2011; 142:1010–1016.
- Kolhatkar S, Khalid S, Rolecki A, Bhola M, Winkler JR. Immediate dental implant placement in HIV-positive patients receiving highly active antiretroviral therapy: a report of two cases and a review of the literature of implants placed in HIV-positive individuals. *J Periodontol* 2011; 82:505–511.
- Shetty K, Achong R. Dental implants in the HIV-positive patient. Case report and review of the literature. *Gen Dent* 2005; 53:434–437.
- Papaspnyridakos P, Mokti M, Chen CJ, Benic GI, Gallucci GO, Chronopoulos V. Implant and prosthodontic survival rates with implant fixed complete dental prostheses in the edentulous mandible after at least 5 years: a systematic review. *Clin Implant Dent Relat Res* 2014; 16:705–717.
- Pjetursson BE, Thoma D, Jung R, Zwahlen M, Zembic A. A systematic review of the survival and complication rates of implant-supported fixed dental prostheses (FDPs) after a mean observation period of at least 5 years. *Clin Oral Implants Res* 2012; 23(Suppl 6):22–38.
- Han HU, Kim S, Han DH. Multifactorial evaluation of implant failure: a 19-year retrospective study. *Int J Oral Maxillofac Implants* 2014; 29:303–310.
- Manor Y, Oubaid S, Mardinger O, Chaushu G, Nissan J. Characteristics of early versus late implant failure: a retrospective study. *J Oral Maxillofac Surg* 2009; 67:2649–2652.
- Patton LL, Shugards DA, Bonito AJ. A systematic review of complication risks for HIV-positive patients undergoing invasive dental procedures. *J Am Dent Assoc* 2002; 133:195–203.

734 *Clinical Implant Dentistry and Related Research, Volume 18, Number 4, 2016*

26. Prosper L, Crespi R, Valenti E, Capparé P, Gherlone E. Five-year follow-up of wide-diameter implants placed in fresh molar extraction sockets in the mandible: immediate versus delayed loading. *Int J Oral Maxillofac Implants* 2010; 25:607–612.
27. Crespi R, Capparé P, Gherlone E. Immediate versus delayed loading of dental implants placed in fresh extraction sockets in the maxillary esthetic zone: a clinical comparative study. *Int J Oral Maxillofac Implants* 2008; 23:753–758.

### 1 A Retrospective 2-Year Clinical Study of Immediate Prosthetic Rehabilitation of Edentulous Jaws with Four Implants and Prefabricated Bars

G. Sannino, P. Bollero, A. Barlattani, E. Gherlone  
Journal of Prosthodontics 00 2015

### 2 A prospective longitudinal study on implant prosthetic rehabilitation in controlled HIV - positive patients with 1 - Year follow - up: the role of CD4+ level, smoking habits and oral hygiene

E. F. Gherlone, P. Capparè, S. Tecco, E. Polizzi, G. Pantaleo, G. Gastaldi, G. Grusovin Clinical Implant Dentistry and Related Research 2015 Aug 4, doi: 10.1111/cid.12370

### 3 Digital impressions for fabrication of definitive "all on four " restorations

E. F. Gherlone, F. Ferrini, R. Crespi, G. Gastaldi, P. Cappare', Implant Dentistry 2015; Vol. 24 Number 1: 125-9

### 4 Implant prosthetic rehabilitation in controlled HIV- positive patients: a prospective longitudinal study with 1-Year follow - up

E. F. Gherlone, P. Capparè, S. Tecco, E. Polizzi, G. Pantaleo, G. Gastaldi, G. Grusovin Clinical Implant Dentistry and Related Research 2015 May 7, doi: 10.1111/cid.12353

### 5 Minimally invasive Flap technique for Keratinized gingiva placement around implants

Pierluigi Pelagalli, Gian Luca Carlesi - Private practice, ROMA  
Scientific Poster presented at EAO CONGRESS - Stockholm - "Challenges in Implant Treatment" September 24-26, 2015

### 6 La previsualizzazione estetica digitale in implantologia

A.Cardarelli, R.Vinci, E.F. Gherlone - Università Vita - Salute San Raffaele di Milano, Corso di Laurea Magistrale in Odontoiatria e Protesi Dentaria, pres. Prof. Enrico Gherlone - Doctor Os, Case Report, giugno 2015 - XXVI 06

### 7 Newsletter BIOSAF IN: analisi retrospettiva a 9 anni degli esiti di trattamento implanto-protesico eseguiti con Sistema WINSIX®

Unità Operativa di Odontoiatria - Università Vita - Salute San Raffaele di Milano, dir. Prof. E. F. Gherlone

### 8 Newsletter BIOSAF IN: just on 4: 4 anni dopo - gennaio 2011 - aprile 2015

Unità Operativa di Odontoiatria - Università Vita - Salute San Raffaele di Milano, dir. Prof. E. F. Gherlone

### 9 Riabilitazione estetica complessa in paziente con esiti di fallimento implantare

A.Cardarelli, R.Vinci, F.Cardarelli, R.Pascetta, R.Vinci - Dip.di Odontoiatria e Protesi Dentaria - Università Vita - Salute San Raffaele di Milano, Pres. Prof. E. F. Gherlone - Doctor Os, Case Report, nov-dic 2015 - XXVI 09

### 10 Digital Planning and Surgery with RealGUIDETM workflow: the ultimate image based procedure for a successful immediate loading rehabilitation

M. Manacorda, A. Merlone, F. Bova, R. Pagani, G. Gastaldi, R. Vinci  
Department of Dentistry, IRCCS San Raffaele Milano and Dental School, Vita-Salute University, Milan, Italy  
Maxillofacial Unit, Carlo Poma Hospital, Mantova, Italy  
Minerva Stomatologica 2015; vol.64 (Suppl. 1 al N.2): 70

**11 Edentulous patients rehabilitated according to the "all-on-four" procedure with prefabricated bar system**

P. Capparé, M. Pasi, G. L. Di Domenico, L. Cisternino, E. Polizzi, R. Crespi - Department of Dentistry, IRCCS San Raffaele Hospital, Milan, Italy - Dental School, Vita-Salute University, Milan, Italy *Minerva Stomatologica* 2015; 64 (Suppl.1 al No2): 81

---

**12 Implant-supported prosthetic rehabilitation in a patient with infiltrating epidermoid carcinoma of the tongue**

N. D'Ovidio, N. Venza, L. S. Martinez, R. Franco, M. Miranda  
Medicina Traslazionale, Roma - *Minerva Stomatologica* 2015; 64 (Suppl.1 al No 2): 168

---

**13 Five-year retrospective analysis of implant-prosthetic treatment with Winsix® Implant System**

F. Bova, R. Iozzo - Università Vita-Salute San Raffaele, Corso di Laurea in Igiene Dentale; U.O.C. Odontoiatria, Centro di igiene Orale e Prevenzione, IRCCS Ospedale San Raffaele, Milano - *Minerva Stomatologica* 2015; 64 (Suppl.1 al No 2): 190

---

**14 Application of innovative technologies in aesthetic fixed prosthodontic**

F. Cattoni, F. Ferrini, M. Manacorda  
Department of Dentistry IRCCS San Raffaele Hospital, Milan, Italy, Dental School Vita-Salute San Raffaele University, Milan, Italy  
*Minerva Stomatologica* 2015; vol.64 (Suppl. 1 al N.2): 211

## A Retrospective 2-Year Clinical Study of Immediate Prosthetic Rehabilitation of Edentulous Jaws with Four Implants and Prefabricated Bars

Gianpaolo Sannino, DDS, PhD,<sup>1,2</sup> Patrizio Bollero, DDS, PhD,<sup>1</sup> Alberto Barlattani, MD, MSc,<sup>1</sup> & Enrico Gherlone, MD, DMD<sup>2</sup>

<sup>1</sup>Department of Clinical Sciences and Translational Medicine, School of Dentistry, University of Rome Tor Vergata, Rome, Italy

<sup>2</sup>Department of Dentistry, San Raffaele Scientific Institute, Vita Salute University, Milan, Italy

### Keywords

Acrylic resin restorations; All-on-Four; bar system; dental implants; immediate loading; screw-retained prosthesis.

### Correspondence

Gianpaolo Sannino, Department of Clinical Sciences and Translational Medicine, School of Dentistry, University of Rome Tor Vergata, Via Torri, Sabina, 14, 00199 Rome, Italy.  
E-mail: gianpaolo.sannino@uniroma2.it

*The authors deny any conflicts of interest.*

Accepted August 10, 2015

doi: 10.1111/jopr.12406

### Abstract

**Purpose:** The purpose of this retrospective investigation was to evaluate the use of a prefabricated bar system for immediately loaded implants placed and restored according to the All-on-Four concept with up to 24-month follow-up.

**Materials and Methods:** A total of 51 patients (31 males and 20 females; mean age 63.4 years) presented with edentulous or partially edentulous jaws with severe atrophy of the posterior regions. All patients were treated with full-arch fixed prostheses (28 maxillary, 34 mandibular) each supported by four implants (two vertical, two distally tilted). The implants were immediately loaded with screw-retained full-arch restorations. Each prosthesis was supported by a prefabricated metal bar combined with high-density acrylic resin. Follow-up visits were scheduled at 6, 12, and 24 months after initial prosthetic loading. Intraoral radiographs were obtained immediately after surgery and at each follow-up visit by using a custom radiograph holder and parallel technique. Marginal bone levels were assessed using digital image analysis. Implant and prosthetic survival and success rates were evaluated. Patient satisfaction was further assessed using a 100-mm visual analog scale (VAS). Data were compared by means of the Mantel-Haenszel test.

**Results:** No drop-outs occurred. The overall implant survival rates were 100% and 98.38% for the vertical and tilted implants respectively. Two of the 62 definitive fixed prostheses were lost during the observation period due to implant failure. Since restoration replacement due to implant failure was not judged a prosthodontic failure according to the survival criteria provided in this study, the overall prosthetic survival rate was 100%. No statistically significant differences in marginal bone levels between vertical and tilted implants were detected at 24-month follow-up evaluation in either jaw. All participants were functionally and esthetically satisfied with their definitive restorations after 2 years functioning, as confirmed by the average VAS scores (masticatory function: 99.7; phonetic function: 99.5, esthetics: 99.2).

**Conclusions:** The preliminary 24-month results indicate that immediate loading of vertical and tilted implants using the evaluated prefabricated bar system may be a viable solution for edentulous jaw rehabilitation; however, more long-term prospective clinical trials are needed to affirm the effectiveness of this surgical-prosthetic protocol.

One of the major challenges facing dentistry has been rehabilitation of atrophic maxillary jaws.<sup>1</sup> Complete dentures have provided patients with clinically acceptable esthetic results at a reasonable cost.<sup>2</sup> However, denture instability as well as soreness, which increases especially with severe bone resorption, have not been able to offer satisfactory function. Immediate implant-supported rehabilitation of edentulous jaws has been reported to provide a reliable alternative to conventional

dentures while significantly improving quality of life for edentulous patients.<sup>3,4</sup>

Implant dentistry has focused on therapeutic protocols that minimize the number of implants and reduce surgical invasiveness. According to the All-on-Four concept, bone augmentation procedures and/or mandibular nerve displacement may be avoided with this particular strategic placement of four implants (i.e., two vertical in the lateral incisor or canine areas



and two distally tilted implants parallel to the anterior sinus wall or anterior to the mandibular foramen).<sup>5,6</sup> Longer implants may be used secondary to tilted positioning, while improving the bone-to-implant contact as well as cortical anchorage; moreover, prosthesis support has been optimized due to shorter cantilevers.<sup>7,8</sup>

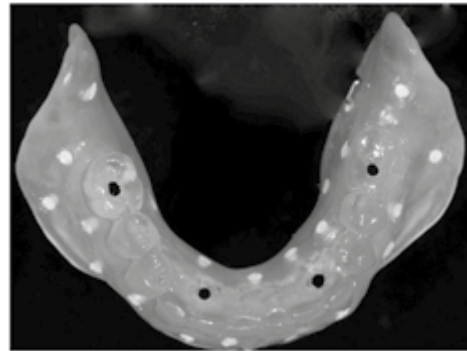
Studies on biomechanical measurements have demonstrated that tilted implants, when part of prosthetic support, do not have a negative effect on load distribution.<sup>9,10</sup> Prospective, and retrospective clinical results on the immediate-function concept by combining two vertical and two tilted implants with an acrylic resin interim full-arch fixed prosthesis reported cumulative survival rates between 92.2% and 100%.<sup>11,12</sup> Different prosthetic designs as well as multiple types of materials have been used to fabricate prosthetic frameworks.<sup>13,14</sup> A truly passive fit of screw-retained prostheses onto both vertical and tilted implants has been reported to be mandatory to avoid tensile, compressive, and bending forces, which may be dangerous for the osseointegration process and/or result in failure of the components.<sup>15-19</sup> However, some studies have found that dental implants tolerate certain levels of misfit.<sup>20,21</sup>

For an easier prosthesis adaptation, angulated abutments are needed to reduce the divergence between nonparallel implants. But, when angulated abutments are used, soldering or laser welding procedures are often required to achieve passive fit of the framework.<sup>22,23</sup> Laboratory errors are primarily due to the volumetric inconsistency and linear expansion of the fabrication materials used.<sup>22-24</sup> Using prefabricated precision milled components to assemble prosthetic frameworks, such as bars, could be a viable solution to drastically reduce material distortion, chair time, and the high costs of fabrication. Some immediate loading protocols of a fixed prosthesis supported by dental implants using prefabricated bars have been proposed in the treatment of edentulous mandibles.<sup>13,24</sup> The purpose of this short-term report was to retrospectively evaluate the use of a prefabricated bar system for immediately loaded implants placed and restored according to the All-on-Four concept with up to 24 months follow-up.

## Materials and methods

This retrospective study was performed at the Department of Clinical Sciences and Translational Medicine, Section of Dentistry, University of Rome "Tor Vergata." The investigation was conducted according to the tenets of the Helsinki Declaration, and all participants gave their written informed consent for immediate implant loading.

From September 2011 to November 2012, 51 patients (31 men, 20 women) with a mean age of 63.4 years (range: 49 to 75 years) were treated with immediately loaded complete-arch prostheses according to the All-on-Four technique. All patients met the following inclusion criteria: good health, edentulous jaws or in need of extraction of the remaining compromised teeth, atrophy of the mandible or maxilla in posterior regions, absence of any lesions in the oral cavity. The exclusion criteria were as follows: health conditions that did not permit surgical treatment; any disorders in the planned implant area such as previous tumors or chronic bone diseases; any interfering medication such as steroid therapy or bisphosphonate therapy;



**Figure 1** The new diagnostic removable prosthesis was duplicated to create an acrylic radiographic template.

alcohol or drug abuse; heavy smoking (>20 cigarettes/day); uncontrolled diabetes; radiation therapy to head or neck region within 5 years; high parafunctional activity (based on history and clinical examination).<sup>12</sup>

Panoramic radiographs were used to initially image the jaws and assess the general status of remaining teeth. Study casts with all anatomic landmarks were obtained from well-extended impressions of the patients' jaws and mounted on articulators using a facebow transfer and accurate interocclusal records.

In partially edentulous patients, the interocclusal record was recorded to assess occlusal vertical dimension (OVD) and the occlusal plane of the future screw-retained prostheses. In edentulous patients, new removable prostheses were fabricated to restore optimal OVD, mandibular position, and occlusal planes. The new prostheses were duplicated to create an acrylic resin radiographic template. Patients underwent CT scans (LightSpeed VCT; GE Healthcare, Waukesha, WI) to accurately assess the quantity of bone for prosthetically driven implant placement (Fig 1).

## Surgical procedure

A single 2 g dose of prophylactic antibiotic (amoxicillin/clavulanate potassium, Augmentin; GlaxoSmithKline, Verona, Italy) was administered 1 hour prior to surgery and then 1 g twice a day for the week following surgery.<sup>25,26</sup> Anesthesia was induced by local infiltrations of 4% articaine solution with epinephrine 1:100,000 (Ubistein; 3M Italy SpA, Milan, Italy). In some cases immediate atraumatic extractions were performed, the sockets were freed of soft tissue remnants, and cleaned to minimize infection. When necessary, bone shaping was performed to level the bone crest.

Implant placement was assisted by a specially designed surgical guide (WINSIX Just Guide; Biosafin, Ancona, Italy) that facilitated correct implant tilting and precise positioning of the implants in relation to the opposing jaw and new tooth positions. The guides were placed into 2-mm holes made at the midline of the alveolar crest; the titanium band was bent so that the occlusal centerline of the opposing jaw was followed.

Sannino *et al*

Prefabricated Bar for Immediate Restorations

In edentulous mandibles, a mucoperiosteal flap was raised to expose the crest and the mental foramina with relieving incisions on the buccal aspects in the molar areas. The most posterior implants (TTx, WINSIX, Biosafin) were placed close to the anterior wall of the mental loop and were tilted distally about 30° relative to the occlusal plane. Most of the tilted implants were 3.8 mm in diameter and typically emerged at the second premolar position. The anterior vertical implants were placed in the canine or lateral incisor area and were most often either 3.8 or 3.3 mm in diameter. In edentulous maxillae, a mucoperiosteal flap was raised to expose the crest with relieving incisions on the buccal aspects in the molar areas.

The posterior implant tilting followed the anterior sinus wall with about 30° of inclination; anterior implants were placed in lateral incisor positions. The posterior implants were either 4.5 or 3.8 mm in diameter, and the anterior implants were either 3.8 or 3.3 mm in diameter. The implant surgery was performed following the manufacturer's instructions; however, in some cases, the drilling protocol was customized by under-preparing the width of the implant sites according to the bone density to obtain primary stability with an insertion torque ranging between 35 and 45 N/cm.

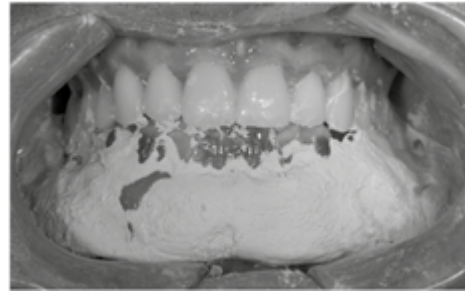
Each patient received straight anterior and angulated abutments (17° and 30°, Extreme Abutment [EA], WINSIX; Biosafin). The abutment angulations were selected to compensate for the divergence between anterior and posterior implants and to place the prosthetic screw access holes in occlusal or lingual locations.

Flaps were readapted and sutured back into position with 4-0 nonresorbable suture (Vicryl; Ethicon, Johnson & Johnson, New Brunswick, NJ). Antibiotics, nonsteroidal anti-inflammatory drugs, and chlorhexidine digluconate 0.2% mouthwash (to avoid brushing the surgical sites) during the first 2 weeks after implant placement were prescribed as post-operative care for all participants.

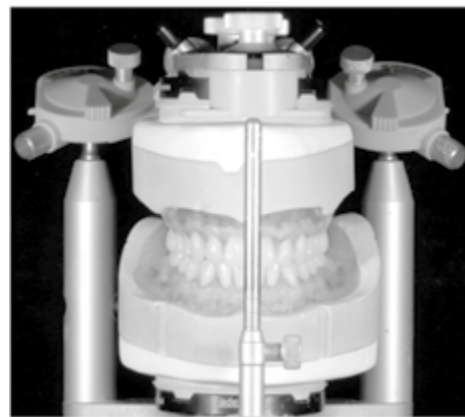
### Prosthetic protocol

After surgery, impression abutment copings (EATx, WINSIX; Biosafin) were connected and tightened to straight and angulated abutments with 15 N/cm torque. The radiographic templates were used as custom open-impression trays. The contacts between the prostheses and the mucosal regions, which were not involved in the surgical procedures, were used as anatomical pre- and postsurgical landmarks (retromolar trigone, maxillary tuberosity, palatal vault). Therefore, during setting of the impression material (SnowWhite Plaster no. 2; Kerr, Romulus, MI), patients were invited to clench in maximum intercuspalation. This allowed the prostheses to seat directly in contact with the mucosa, avoiding loss of information gained during the diagnostic phase, and simplifying laboratory procedures (Fig 2).

Abutment replicas (EAAx, WINSIX; Biosafin) were connected to the impression copings and tightened to 15 N/cm. All definitive casts were poured in low-expansion type IV stone (FujiRock® EP; GC Europe, Leuven, Belgium), and mounted on fully adjustable articulators using interocclusal records obtained by the radiographic templates. The radiographic templates were removed, and the prefabricated removable



**Figure 2** The use of the radiographic template as a custom open-tray, to allow recording of gnathological data, thanks to occluding relation.



**Figure 3** Removable prostheses were released and adapted on the master cast to transfer the occlusion and the vertical dimension of each patient onto a fully adjustable articulator.

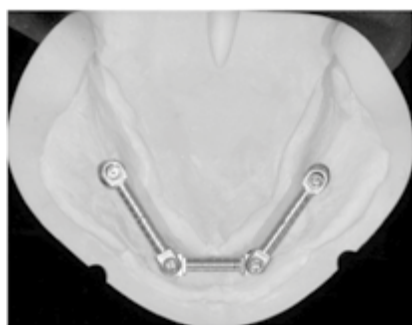prostheses were accurately adapted on the master casts according to anatomical landmarks and interocclusal records (Fig 3).

Straight cylinders (AT, WINSIX; Biosafin) were screwed onto the abutment replicas in the casts. Different cylinders were chosen in relation to margin heights to allow the bars to be parallel to the occlusal plane. The interimplant distances were measured, and 3 bar tubes were shortened to the optimal lengths using the specific cutter bar device and a splitter disk. Dedicated bar joints (CF and CM, WINSIX; Biosafin) were inserted into the tubes. Three units each composed of a tube and two joints were connected to the cylinders and fixed by means of resin cements, without soldering procedures (Fig 4).

A silicon index obtained from the preexisting removable prosthesis was used to evaluate the correct amount of resin to be removed from the prosthesis to provide a stress-free space for the bar adaptation without affecting the intermaxillary relations previously established (Fig 5). The assembled bars were moved from the master casts to the patient's mouth, and their passive nature was checked (Fig 6). Then the passive seating on

Prefabricated Bar for Immediate Restorations

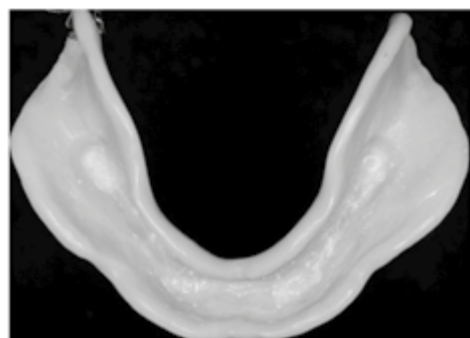
Sannino *et al*



**Figure 4** Customization of the bar: tubes were shortened at the correct implant distance and connected to adapters using dedicated bar joints.



**A**

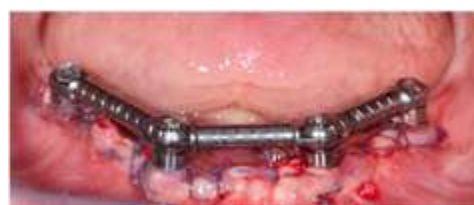

**B**

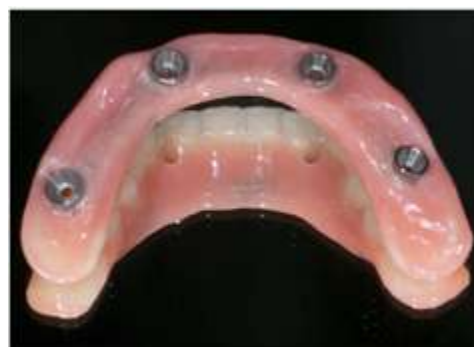**Figure 5** (A) and (B) A silicon index obtained from the preexisting removable prosthesis was used to evaluate the correct amount of resin to be removed from the prosthesis to provide a stress-free space for the bar adaptation without affecting the intermaxillary relationship previously established.

the bar and the occluding relation of the adapted prefabricated prostheses were evaluated. The removable prosthesis was provided with four openings for prosthetic screw access, according to the cylinder emergences.

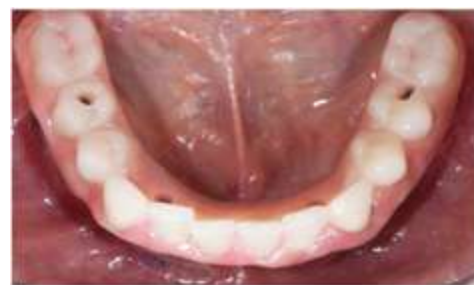The prostheses were then intraorally relined with small amounts of self-curing acrylic resin (Sintodent, Rome, Italy) just to incorporate the bars. A rubber dam was further used to



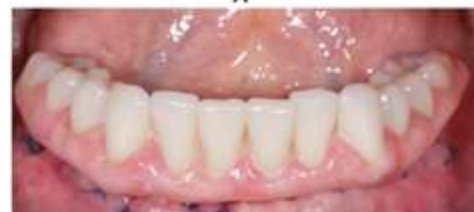**Figure 6** The assembled bar was mounted into implants, and its passive nature was checked.



**Figure 7** The bar was attached to the denture with self-curing acrylic resin and marginal precision was improved by resin addition.



**A**



**B**

**Figure 8** Screw-retained, bar-reinforced, acrylic resin prosthesis delivery. (A) Frontal view. (B) Occlusal view.

Sannino *et al*

Prefabricated Bar for Immediate Restorations

protect soft tissues. After polymerization, the prostheses connected to the bars were removed from the implants and screwed onto the master casts and retention, marginal precision, and stability were improved by resin additions (Fig 7). The prosthetic parts seated directly in contact with the mucosa were then removed using laboratory burs. Screw-retained, bar-reinforced, acrylic resin restorations were delivered immediately in all patients (Fig 8A). The emergence positions of the screw-access holes of the posterior implants were normally at the level of the second premolar. The prostheses were designed to hold a minimum of 10 teeth because of the favorable positions achieved by posterior tilting of the distal implants (Fig 8B). Most definitive prostheses included 12 teeth, with a maximum of a one-unit cantilever ( $\leq 10$  mm), which was not reinforced by a bar tube.

All centric and eccentric contacts were assessed by 40  $\mu$ m articulating paper (Bausch Articulating Paper, Köln, Germany), until light occlusal contacts, uniformly distributed on the entire prosthetic arch, were obtained. Centric occlusion was used, with group function for laterotrusive and protrusive excursions. The prosthetic screws were tightened according to manufacturer instructions, and the access holes were sealed with PTFE tape and a dual-cure, radiopaque, two-component, core build-up material supplied in an automix delivery system (Clearfil DC Core Automix; Kuraray Europe GmbH; Hattersheim am Main, German). Fifteen days after prosthesis delivery, a final occlusal adjustment was performed. Patients were advised to adhere to a soft diet for the first 2 months postsurgery and to return to a regular diet, but avoid harder food items for another 2 months.

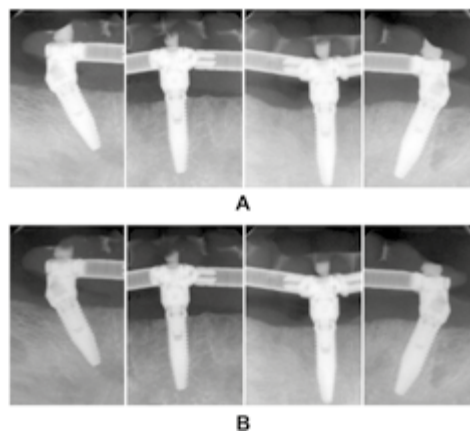
### Follow-up

Follow-up visits were scheduled each week for the first month after surgery, once a month up to the sixth month, and annually up to 2 years after implant insertion. The mean follow-up period was 29.5 months (range 24 months to 38 months). The primary outcome measures were implant and prosthetic survival and success rates.

Implant survival was defined as the absence of implant mobility, swelling, or pain in the surgical site at the time of examination. Implant success was defined as implant survival plus marginal bone loss  $<1.5$  mm after 1 year of loading and no more than 0.2 mm of loss between each follow-up appointment after the first year of function.

Restoration success was defined as the absence of fractures of the framework or the acrylic resin superstructure, even if one or more implants supporting the restoration have been removed. (Prosthesis success was evaluated using modified evaluation criteria suggested by the California Dental Association).<sup>27</sup> A "surviving prosthesis" was a prosthetic reconstruction that was stable and in good function.

The secondary outcome with respect to efficacy was the marginal bone level changes. Radiographic evaluations of marginal bone level were made using intraoral radiographs at 1 and 2 years using a custom radiograph holder and parallel technique (Fig 9). All radiographs were displayed in an image analysis program (Scion Image v4.0.2; NIH Scion Corporation 4.0.2, Frederick, MD) and evaluated under standardized conditions.



**Figure 9** (A) Intraoral radiographs after implant surgery and immediate loading. (B) After 24 months, stable marginal bone levels were shown.

The software was calibrated for every image by considering the length of the implant. Bone levels were recorded mesial and distal for each implant, using the implant/abutment junction as reference points. The first bone-to-implant contact at surgery was defined as the baseline. Marginal bone loss was calculated as the difference between the readings at the examination and the baseline value.

The third outcome, assessed at the 2-year follow-up examination, was patient satisfaction. Patients gave their overall satisfaction score regarding masticatory—phonetic function and esthetics of their definitive implant-supported restorations on a 100-mm visual analogue scale (VAS; 0 = maximal disagreeing or minimal experienced and 100 = maximal agreement or maximal experienced).

### Statistics

Statistical calculations were performed with the statistical software SPSS 14 for Windows (SPSS Inc., Chicago, IL). The marginal bone levels were reported as means  $\pm$  standard deviations at 12 and 24 months. Marginal bone remodeling around the vertical and tilted implants was recorded.

Data were subjected to statistical analysis with the Mantel-Haenszel test and the odds ratio determination, which provided all the necessary parameters to determine the significance. The Mantel-Haenszel test was applied to the contingency tables after converting the data into quantitative categorical dichotomous data. The dichotomy was based on the median value of quantitative data, thus the values less than or equal to the median were included in the zero class, while the values more than the median in the first class.

### Results

Thirty-nine patients (76.5%) were edentulous, and 12 (23.5%) were partially edentulous on the day of surgery. Eight patients (15.7%) were smokers, and five (9.8%) exhibited signs of



## Prefabricated Bar for Immediate Restorations

Sannino *et al***Table 1** Distribution of implants according to diameter and length

		Maxilla (n = 28)		
		Length 11 mm	Length 13 mm	Length 15 mm
Vertical (n = 56)	Diameter 3.3 mm	6	2	0
	Diameter 3.8 mm	8	22	2
	Diameter 4.5 mm	4	8	4
Tilted (n = 56)	Diameter 3.3 mm	0	4	2
	Diameter 3.8 mm	4	12	16
	Diameter 4.5 mm	0	8	10
		Mandible (n = 34)		
		Length 11 mm	Length 13 mm	Length 15 mm
Vertical (n = 68)	Diameter 3.3 mm	8	12	0
	Diameter 3.8 mm	10	16	4
	Diameter 4.5 mm	2	12	4
Tilted (n = 68)	Diameter 3.3 mm	0	4	4
	Diameter 3.8 mm	2	18	14
	Diameter 4.5 mm	2	12	12

occasional parafunctional activity (based on history and clinical examination). Treatment was performed in 28 maxilla (45.16%) and 34 mandibles (54.84%).

The opposing arches presented implant-supported restorations (n = 6 mandible, n = 5 maxilla), fixed prostheses on teeth (n = 5 mandible, n = 9 maxilla), removable partial dentures (n = 4 mandible, n = 4 maxilla), maxillary complete dentures (n = 8 mandible, n = 9 maxilla), and natural dentition (n = 5 mandible, n = 7 maxilla). A total of 248 implants (TTx, WIN-SIX; Biosafin) were placed and immediately loaded (Table 1). Nine implants were placed into fresh extraction sockets, and 239 were placed into healed sites.

All implants achieved primary stability at placement with a minimum torque of 35 N/cm and were immediately loaded supporting 62 fixed interim prostheses. The mean (SD) implant length was 12.61 mm (1.24 mm) for the vertical and 13.81 mm (1.22 mm) for the tilted implants. During the first 4 months after implant placement, two patients lost one tilted implant (maxillary) each due to mobility. Two implants of the same length and larger diameter were placed, and left unloaded until a new definitive prosthesis was completed and inserted. The definitive prosthesis was supported by three immediately loaded implants and one replaced implant. No additional implant failures were experienced during the study period accounting for a cumulative implant survival rate of 100% and 98.38% for the vertical and the tilted implants, respectively, and a cumulative prosthetic survival rate of 100% at 24 months. No dropouts occurred.

Four patients presented with fracture of a resin tooth of the prosthesis. The prostheses were repaired without removal from the oral cavity. No signs of excessive occlusal wear were noted at the 24-month evaluation in any patient. No other mechanical complications (such as screw loosening and/or fracture, bar fracture) occurred during the entire follow-up period.

The VAS results revealed that all participants were functionally and esthetically satisfied with their definitive prosthesis. The average VAS score was 99.7 (SD: 2.1; range: 95 to 100) for masticatory function, 99.5 ± 2.2 (range: 95 to 100) for phonetic function, and 99.2 (SD: 2.9; range: 90 to 100) for esthetics.

**Radiographic results**

At the 24-month evaluation, marginal bone loss averaged 1.07 ± 0.33 mm for vertical and 1.10 ± 0.32 mm for tilted implants in the maxilla. In the mandible a mean marginal bone loss of 1.08 ± 0.40 mm for vertical implants and 1.12 ± 0.39 mm for tilted implants was found (Table 2). No statistically significant differences in crestal bone loss between tilted and vertical implants were detected at 12- and 24-month follow-up evaluations in either jaw.

**Discussion**

The 2-year clinical and radiological results of this investigation have shown how vertical and tilted implants supporting restorations with prefabricated bar could have a favorable prognosis; however, several variables were present in this study (i.e., edentulous vs. dentate patients, type of antagonist, etc.) and might have affected the results. Two patients lost one implant each, and all prostheses survived on the remaining three implants until the replacement implants were loaded. The cumulative implant survival rate (99.19%) was comparable to results obtained with other reported immediate/early loading protocols for the same indication.<sup>5,6,12</sup>

There were no statistically significant differences in marginal bone loss between vertical and tilted implants at 24 months in either jaw. According to the findings of others, tilted implants were similar on the mesial and distal surfaces for bone resorption patterns.<sup>5-8</sup> Studies on biomechanical measurements demonstrated that tilted implants, when part of a prosthetic support, do not have a negative effect on the load distribution.<sup>9,10</sup> No postloading mechanical complications such as bar fracture or screw loosening or fracture were observed throughout the study.

Resin tooth fracture of the prosthesis did occur in four patients, but did not require replacement of the prosthesis itself, indicating a prosthetic survival rate of 100%. No correlation was found between such fractures and the type of opposing dentition; therefore, a possible explanation could be occasional parafunctional habits or poor occlusal equilibration. Restoration replacements due to implant failure have not been judged a prosthodontic failure according to the success and survival criteria provided in the study, therefore they have not been counted in the statistical calculation.

At the 24-month follow-up, bone healing was uneventful, and good soft-tissue health was maintained in all cases. No signs of adverse biological conditions were detected.

The advantages of a full-arch fixed prosthesis supported by two anterior vertical and two distal tilted implants are well known: longer implants may be placed, implant-to-bone contact area and primary implant stability may be increased, tilting the implant relative to the foramina or the anterior sinus walls

**Table 2** Radiographic results: mean marginal bone loss

Jaw	Maxilla				Mandible			
	Vertical		Tilted		Vertical		Tilted	
Placement	T-12	T-24	T-12	T-24	T-12	T-24	T-12	T-24
Time (months)	56	56	56	56	68	68	68	68
Average (mm)	-1.02	-1.07	-1.05	-1.10	-1.01	-1.08	-1.06	-1.12
SD	0.33	0.33	0.33	0.32	0.37	0.40	0.38	0.39

reduces or eliminates the need for a prosthetic cantilever, resulting in better load distribution, and the use of bone grafts may be avoided, resulting in significantly less morbidity and dramatically lower financial costs associated with those procedures. Furthermore, the immediate function concept with immediate screw-retained restoration based only on four implants represents a major advantage for patients, providing less expensive, and less time-consuming treatments.

Despite the many benefits offered by this surgical-prosthetic protocol, the prosthesis adaptation may be difficult due to different implants' orientation. These drawbacks can be overcome using angulated abutments, which correct the divergence of the tilted implants and adjust the implant platform height. Nevertheless, a perfect parallelism and the same height of the four implant platforms are never achieved, nor is a perfect passive fit between the framework and the implants, which is required for a successful restoration.<sup>16</sup> Unlike natural teeth, implants are unable to fit to the misfits, since they do not have the resiliency of the periodontal ligament.<sup>15,18</sup> A poor fit between structures introduces harmful tensile, compressive, and bending forces and may result in failure of the components as well as loss of osseointegration.<sup>15,18,19</sup>

Soldering or laser welding procedure is often required to compensate dimensional distortion, which can be introduced at any step of the fabrication process, due to the volumetric inconsistency and linear expansion of the materials used.<sup>21-23</sup> This leads to an increase in laboratory time and costs.<sup>18</sup> The system investigated in the present study could overcome these weak aspects and offer some benefits for the patient, the clinical team, and the laboratory. The prefabricated bar is composed of precision-milled cylinders, universal bar joints, bar tubes, and fixation screws.

The reproducible and constant manufacturing processes of the components also improves the physical and mechanical properties of the component materials. This ensures high accuracy and thus passive fit when the bar is assembled, as opposed to the traditional way of manual manufacture (casting or soldering), which is prone to numerous subjective errors. Passive seating is improved by the design of the bar joints, which can rotate inside the bar tubes and overcome slight undercuts of the cylinders, thanks to cylindrical and elliptical shapes. Thus no lateral stress is generated on the implants, reducing the risk of implant failure.

The real splinting of the four cylinders (i.e., the four implants) is performed by the acrylic resin; however, each tube supported by two cylinders may improve the mechanical strength of the

prosthetic span, which is subjected to compressive and bending forces during masticatory function. Each tube is stable and provides support only if it is supported by two cylinders, because there are no welding points between different parts. Therefore, the tubes have not been used as a support for the cantilever units. In the present study only one cantilever unit fracture was observed. The lack of the tube has made the repair procedure and the finishing of the prosthesis easier.

In a clinical study prefabricated bars were compared to custom-made bars used for implant-retained mandibular complete overdentures.<sup>14</sup> The authors stated that the increase in bone loss recorded (18-month follow-up) in the cast bar group was more than in the prefabricated bar group, perhaps attributable to the accuracy in fabrication of the prefabricated bar, where it has a high-polished surface, precision, and stress-free properties. These results may be attributed to the difference in the amount of load transmitted to the supporting structures by a rigid cast bar unit and a relatively flexible prefabricated bar joint used to retain the mandibular overdentures.

A finite element analysis evaluated the influence of bar framework material on the distribution of static stresses in an overdenture-retaining bar system. The authors concluded that several bar framework materials such as gold alloy, silver-palladium alloy, commercially pure titanium, and cobalt-chromium alloy transfer significant stress to the supporting peri-implant tissues.<sup>18</sup>

This system is relatively inexpensive compared with conventional gold castings and CAD/CAM options, since no laboratory time is required to fabricate the bar, and there are no costly implant components or gold-alloy charges. Furthermore customization of the bar components may be done directly at the dental chair with existing dentures or indirectly at the dental laboratory with new dentures.

When a prefabricated bar is intended to be used for a screw-retained acrylic resin prosthesis, great attention should be given to the size of the bar components. An accurate preliminary assessment of the components' volume is mandatory to enable a passive housing of the structure into the prosthesis. One of the major benefits of this system is that it can be used modifying the existing prosthesis, provided there is enough space to host the bar in the denture crestal aspect. A preliminary mounting of the stone casts in an articulator with the existing denture could be useful to evaluate the available space and the best position for each component. This advantage enables cost reduction of a new prosthesis and to keep patient esthetics and



intermaxillary relation unchanged, while improving bite force, oral function, and prosthetic stability.

The high success rate obtained with this protocol may be the result of an accurate diagnosis supported by a simple and repeatable prosthodontic protocol, which provides a transition from a diagnostic removable denture to a screw-retained implant-supported prosthesis. Versatility and biomechanical reliability of the bar components, providing a passive fit, play a key role in the uniform load distribution at the bone-implant interface.

The overall esthetic outcome of the treatment was judged excellent by the clinician and the patients. Patient comfort increased due to the reduced treatment time, morbidity, and overall costs, as confirmed by the overall satisfaction score.

### Conclusions

The results of this retrospective study demonstrated high success rates, a low number of complications, and high patient satisfaction regarding masticatory function, phonetic function, and esthetics. Prefabricated bars for screw-retained, immediately loaded, full-arch prostheses supported by two vertical and two tilted implants may be a reliable solution for the treatment of edentulous jaws. These procedures may result in improved economic benefits for patients and clinicians; however, more long-term prospective clinical trials are needed to confirm the effectiveness of this surgical-prosthetic protocol.

### References

1. Branemark PI: Osseointegration and its experimental background. *J Prosthet Dent* 1983;50:399-405
2. Bilhan H, Erdogan O, Ergin S, et al: Complication rates and patient satisfaction with removable dentures. *J Adv Prosthodont* 2012;4:109-115
3. Turkyilmaz I, Company AM, McGlumphy EA: Should edentulous patients be constrained to removable complete dentures? The use of dental implants to improve the quality of life for edentulous patients. *Gerodontology* 2010;27:3-10
4. Awad MA, Lund JP, Dufresne E, et al: Comparing the efficacy of mandibular implant-retained overdentures and conventional dentures among middle-aged edentulous patients: satisfaction and functional assessment. *Int J Prosthodont* 2003;16:117-122
5. Malo P, Rangert B, Nobre M: "All-on-Four" immediate-function concept with Branemark system implants for completely edentulous mandibles: a retrospective clinical study. *Clin Implant Dent Relat Res* 2003;5:2-9
6. Malo P, Rangert B, Nobre M: All-on-4 immediate- function concept with Branemark system implants for completely edentulous maxillae: a 1-year retrospective clinical study. *Clin Implant Dent Relat Res* 2005;7 Suppl 1:88-94
7. Pozzi A, Sannino G, Barlattani A: Minimally invasive treatment of the atrophic posterior maxilla: a proof-of-concept prospective study with a follow-up of between 36 and 54 months. *J Prosthet Dent* 2012;108:286-297.
8. Francetti L, Agliardi E, Testori T, et al: Immediate rehabilitation of the mandible with fixed full prosthesis supported by vertical and tilted implants: interim results of a single cohort prospective study. *Clin Implant Dent Relat Res* 2008;10:255-263
9. Sannino G: All-on-four concept: a 3D finite element analysis. *J Oral Implantol* 2015;41:163-171
10. Bellini CM, Romeo D, Galbusera F, et al: Comparison of tilted versus nontilted implant-supported prosthetic designs for the restoration of the edentulous mandible: a biomechanical study. *Int J Oral Maxillofac Implants* 2009;24:511-517
11. Hinze M, Thalmair T, Bolz W, et al: Immediate loading of fixed provisional prostheses using four implants for the rehabilitation of the edentulous arch: a prospective clinical study. *Int J Oral Maxillofac Implants* 2010;25:1011-1018
12. Crespi R, Vinci R, Capparé P, et al: A clinical study of edentulous patients rehabilitated according to the "all on four" immediate function protocol. *Int J Oral Maxillofac Implants* 2012;27:428-434
13. Ha SR, Kim SH, Song SI, et al: Implant-supported overdenture with prefabricated bar attachment system in mandibular edentulous patient. *J Adv Prosthodont* 2012;4:254-258
14. Abd El-Dayem MA, Assad AS, Eldin Sanad ME, et al: Comparison of prefabricated and custom-made bars used for implant-retained mandibular complete overdentures. *Implant Dent* 2009;18:501-511
15. Kunavisarut C, Lang LA, Stoner BR, et al: Finite element analysis on dental implant-supported prostheses without passive fit. *J Prosthodont* 2002;11:30-40
16. al-Turki LE, Chai J, Lautenschlager EP, et al: Changes in prosthetic screw stability because of misfit of implant-supported prostheses. *Int J Prosthodont* 2002;15:38-42
17. Baggi L, Di Girolamo M, Vairo G, et al: Comparative evaluation of osseointegrated dental implants based on platform-switching concept: influence of diameter, length, thread shape, and in-bone positioning depth on stress-based performance. *Comput Math Methods Med* 2013;2013:250929. doi: 10.1155/2013/250929. Epub 2013 Jun 19
18. Spazzin AO, Dos Santos MB, Sobrinho LC, et al: Effects of horizontal misfit and bar framework material on the stress distribution of an overdenture-retaining bar system: a 3D finite element analysis. *J Prosthodont* 2011;20:517-522
19. Gratton DG, Aquilino SA, Stanford CM: Micromotion and dynamic fatigue properties of the dental implant-abutment interface. *J Prosthet Dent* 2001;85:47-52
20. Michaels GC, Carr AB, Larsen PE: Effect of prosthetic superstructure accuracy on the osteointegrated implant bone interface. *Oral Surg Oral Med Oral Pathol Oral Radiol Endod* 1997;83:198-205
21. Carr AB, Gerard DA, Larsen PE: The response of bone in primates around unloaded dental implants supporting prostheses with different levels of fit. *J Prosthet Dent* 1996;76:500-509
22. Assif D, Marshak B, Schmidt A: Accuracy of implant impression techniques. *Int J Oral Maxillofac Implants* 1996;11:216-222
23. Rubenstein JE, Ma T: Comparison of interface relationships between implant components for laser-welded titanium frameworks and standard cast frameworks. *Int J Oral Maxillofac Implants* 1999;14:491-495
24. Parel SM, Triplett RG: Rescue procedure for the Brånemark Novum protocol. *Int J Oral Maxillofac Implants* 2004;19:421-424
25. Balevi B: Patients who have received preoperative antibiotics showed fewer early implant failures. *J Am Dent Assoc* 2014;145:1068-1070
26. Bafail AS, Alamri AM, Spivakovsky S: Effect of antibiotics on implant failure and postoperative infection. *Evid Based Dent* 2014;15:58
27. California Dental Association: Quality evaluation for dental care: guidelines for the assessment of clinical quality and professional performance. Los Angeles, California Dental Association, 1977

# A Prospective Longitudinal Study on Implant Prosthetic Rehabilitation in Controlled HIV-Positive Patients with 1-Year Follow-Up: The Role of CD4+ Level, Smoking Habits, and Oral Hygiene

Enrico F. Gherlone, MD, DMD;\* Paolo Capparé, MD, MFS;† Simona Tecco, DDS, PhD;‡  
Elisabetta Polizzi, BS;‡ Giuseppe Pantaleo, PhD;§ Giorgio Gastaldi, MD, DMD;¶  
Maria Gabriella Grusovin, DDS\*\*

---

## ABSTRACT

**Background:** A recent study showed that implant-prosthetic rehabilitation in well-controlled HIV patients gave slightly worse results than in a healthy population, and failures were all linked to infection.

**Purpose:** The aim of this study was to examine the associations between the success of implant-prosthetic treatment and systemic CD4+ level, smoking habits, and oral hygiene.

**Materials and Methods:** This mono-centric study included HIV patients with a stable disease and good oral hygiene requiring implant rehabilitation. Each patient received at least one dental implant. Prosthesis were delivered after 90 days in the upper jaw and 60 days in the lower jaw. Primary outcome measures were prosthetic failures, implant failures, peri-implant marginal bone level changes, and biological complications (peri-implantitis, pus, pain, paresthesia). The possible association with CD4 count, smoking habits, and oral hygiene was analyzed.

**Results:** Sixty-eight patients received 194 implants, and 66 patients (190 implants) were followed for 1 year. No significant associations were found between CD4+ count, oral hygiene-associated variables, and any of the outcome measures. If compared with nonsmoking/light smoking patients, patients who smoked >10 cigarettes/day suffered a statistically significant greater number of implant failures ( $p \leq .005$ ), presented a comparatively higher number of peri-implantitis ( $p < .001$ ), as well as a higher frequency of pus ( $p \leq .007$ ), and reported pain ( $p \leq .009$ ).

**Conclusion:** Within the limitation of the present study, placement of dental implants in HIV-positive patients with stable disease seems a reasonable treatment option, regardless of CD4+ cell count, provided that they are in a normal range. Oral hygiene variables were not influential in this group of patient following recall appointments, while HIV-positive heavy smokers (>10 cigarettes/day) demonstrated an increased risk of early implant failure, peri-implantitis, episodes of pus, and self-reported pain.

**KEY WORDS:** AIDS, HIV, implant, implant survival, implantology, osseointegration, peri-implantitis

---

\*Full professor and chairman, Dental School, Vita-Salute University and IRCCS San Raffaele, Milan, Italy; †researcher, Dental School, Vita-Salute University and IRCCS San Raffaele, Milan, Italy; ‡adjunct professor, Dental School, Vita-Salute University and IRCCS San Raffaele, Milan, Italy; §associate professor, Faculty of Psychology, UniSR Social.Lab [Research Methods], Vita-Salute San Raffaele University, Milan, Italy; ¶associate professor, Dental School, Vita-Salute University, Milan, Italy and head, Maxillofacial Surgery and Dentistry Unit, San Rocco Hospital, Ome, Brescia, Italy; \*\*adjunct professor, Dental School, Vita-Salute San Raffaele University, Milan, Italy

Corresponding Author: Dr. Paolo Capparé, Dentistry Department IRCCS San Raffaele Hospital, Via Olgettina n. 48, Milan 20132, Italy; e-mail: paolocappare@gmail.com

Conflict of interest: No author had any conflict of interest. The material is original and has not been published elsewhere.

© 2015 Wiley Periodicals, Inc.

DOI 10.1111/cid.12370

## INTRODUCTION

The scientific literature about oral implants performed on HIV-positive patients is relatively scarce and consists mainly of case reports<sup>1-3</sup> or pilot study.<sup>4</sup> This is in part due to the fact that HIV-positive patients rarely were subjected to this type of treatment as their systemic disease was associated with a significant reduction of length and quality of life, and they had other medical needs, rather than implant-prosthetic rehabilitation.<sup>5</sup> The dental treatment was limited, therefore, to the management of oral lesions and dental emergencies.<sup>5</sup> With the advent of new therapies improving the quality of life of these patients, implant-prosthetic rehabilitation has become more and more common for these patients.<sup>6</sup>

Longitudinal clinical trials about implant-prosthetic rehabilitation in HIV patients are rare.<sup>6</sup> A recent prospective cohort study conducted at the IRCCS San Raffaele Hospital, Milan, showed that well-controlled HIV patients who maintained a proper oral hygiene and followed a professional maintenance protocol obtained only slight worse results in implant rehabilitation than an healthy population (survival at patient level: 57 out of 66 patients; survival at fixture level: 175 out of 190 – 92.1% after 1 year). All the failures were linked to infection and occurred before 6 months from insertion (7.9% out of 190 fixtures on nine out of 66 HIV-positive patients).<sup>7</sup>

Indeed, infection can be a serious complication in placement of dental implants and could lead to implant loss, in particular in patients infected with human immunodeficiency virus.<sup>8,9</sup> In such patients, a progressive deterioration in immunity is indicated by a fall in the T-helper (CD4) cell count, and the risk of wound infection increases as the immune status deteriorates.<sup>10,11</sup>

So, the systemic disease could cause an increase in the percentage of early failures, and the systemic level of CD4+, which is to be considered an indicator of the state of the disease, could be an indicator of the increased risk for implant failures.

Besides, other factors as cigarette smoking<sup>12</sup> and the level of oral hygiene<sup>13</sup> can affect osseointegration and infections.

The purpose of this study was therefore to investigate the associations between variables related to the survival of implant-prosthesis treatment (prosthetic failures, implant failures, biological complication, mar-

ginal bone level change [MBLC]) and systemic CD4+ values, smoking habits, and oral hygiene, in a population of HIV-positive patients followed for 1 year, undergoing implant-prosthetic treatment, described in a previous paper.

In this article, the Strobe guidelines (or Strengthening the Reporting of Observational Studies in Epidemiology) were followed.<sup>14</sup>

## MATERIALS AND METHODS

This mono-centric trial (IRCCS San Raffaele Hospital in Milan, Italy) included controlled HIV-affected patients that required implant rehabilitation. The Italian Ministry of Health approved the protocol.

### Recruitment

The patients were recruited at the San Luigi Center for Infective Diseases, IRCCS San Raffaele Hospital, Milan, in which HIV-infected patients are kept under medical control. All those who presented medical parameters of a stable disease were considered (Table 1).<sup>7</sup>

All patients received and signed a written consent form for implant procedures.

### Interventions Administered

During the first dental examination of the patients, the following procedures were done:

- General intraoral examination;
- Evaluation of the orthopantomography or any Tc Dental scans; and
- Implant planning (number of fixtures; the location, the type of prosthesis).

A few days before the surgery, periodontal health checkup (by the hygienist or dentist) was performed: This stage was the T0 for the clinical periodontal parameters. Stages T1 and T2 were considered at 6 months and 12 months, respectively, from implant placement. At these stages, a dental hygienist measured the modified bleeding index, modified plaque index, probing depth (PPD), and presence of pus (Table 2).<sup>15</sup>

Smoking habits were recorded at T0 as number of cigarettes smoked in a day. Education and motivation to oral hygiene at home, and instructions about the potential negative role of smoking were given to all the patients. Eventual debridement above/below the gingiva and one stage full-mouth disinfection in case of periodontal patients were administrated.

**TABLE 1 Inclusion and Exclusion Criteria**

The eligibility criteria	<ul style="list-style-type: none"> <li>• HIV-positive patients</li> <li>• Age &gt;18 years</li> <li>• Total or partial edentulous</li> <li>• Adequate bone volume (divisions A, B, or C according to Misch classification of bone available<sup>23</sup>) and appropriate bone density (classes D1, D2, or D3 Misch<sup>24</sup>);</li> <li>• Blood values:               <ul style="list-style-type: none"> <li>CD4+ level count &gt;400 cells/mm<sup>3</sup></li> <li>Hemoglobin &gt;8 mg/dl;</li> <li>Absolute neutrophil count &gt;750 cells/mm<sup>3</sup>;</li> <li>Platelets &gt;75,000 cells/mm<sup>3</sup>;</li> <li>AST &lt; 5 times the upper limit of normal value (ULN);</li> <li>Bilirubin &lt;2.5 times ULN;</li> <li>Alkaline phosphatase &lt;5 times ULN;</li> <li>Creatinine &lt;2.5 mg/ml</li> </ul> </li> </ul>
Exclusion criteria	<ul style="list-style-type: none"> <li>• Severely immunocompromised patients with a high recurrence of opportunistic infections, tuberculosis, or malignancy spread;</li> <li>• Diabetes decompensated;</li> <li>• Severe malocclusion;</li> <li>• Severe parafunctions (bruxism);</li> <li>• Inadequate bone volume (Division D of Misch);</li> <li>• Inadequate bone density (density D4 Misch);</li> <li>• Disorders that contraindicate surgical procedures;</li> <li>• Lack of collaboration;</li> <li>• Lack of oral hygiene: plaque index superior to 1</li> </ul>

At the day scheduled for the surgery, implants were positioned after antibiotic prophylaxis with amoxicillin and clavulanic acid, 2 g orally, 1 hour before surgery. A full-thickness flap was raised, and implant placement was conducted in accordance with the manufacturer protocol (WinSix®, BioSAFin. S.r.l., Ancona, Italy). Conical implants with rough surface (Full Contact Covering® surface) and internal hexagon connection were used (K implants, WinSix, BioSAFin. S.r.l.). Postoperative therapy consisted in amoxicillin and clavulanic acid

1 g × 2 per day for 7 days after surgery, rinse with 0.2% chlorhexidine twice a day for 15 days after surgery, and pain medication as needed. Suture removal was carried out after 7 to 10 days. Re-entry procedures for healing abutment placement were performed in each case at least after 50 days from implant placement.

After 90 days for the upper jaw and 60 days for the lower jaw, a precise impression was made, and removable prosthetic denture or fixed cemented single crowns and bridge were then delivered. For total removable

**TABLE 2 Periodontal Health Indices and Details of Methods of Measurement**

Variable	Timing	Method
Modified Bleeding index (mBI)	T1 and T2	Values were recorded at the mesial, distal, buccal, and palatal surfaces of the implants using a periodontal probe (PGF-GFS, Hu-Friedy).
Modified Plaque index (mPI)	T1 and T2	Values were recorded at the mesial, distal, buccal, and palatal surfaces of the implants using a periodontal probe (PGF-GFS, Hu-Friedy).
Probing depth (PD)	T1 and T2	Values were recorded at the mesial, distal, buccal, and palatal surfaces of the implants using a periodontal probe (PGF-GFS, Hu-Friedy).

Indices were recorded as previously reported.<sup>15</sup>

dentures, ball attachments were screwed directly onto the abutments, and two ball housings (matrices) were mounted in the overdenture.

For single crowns and fixed partial dentures, definitive metal ceramic restorations were cemented onto the definitive abutments.

#### Follow-Up Evaluation

The appointments with the dental hygienist were scheduled each 2 months. For the oral hygiene at home, patients were instructed on the proper use of aids such as interproximal brush, mono tuft toothbrush, and Super floss. Patients were recommended to brush their teeth at least three times a day.

#### Outcome Measures

The outcomes considered were as follows:

1. Prosthesis failure: when prosthesis has to be replaced due to implant failure.
2. Implant failure: implant removal dictated by mobility, progressive marginal bone loss due to peri-implantitis, and any mechanical complication rendering the implant not usable (e.g., implant fracture). The stability of each individual implants was assessed manually, 6 and 12 months from insertion by tightening the abutment screws with the removed prostheses.
3. Biological and biomechanical complications (number and type) were recorded as single episodes for each implant. Particular attention was used to assess peri-implantitis (defined as progressive bone loss with sign of infections around an osseointegrated implant), presence of pain, presence of pus, paresthesia of the lower jaw, and implant fracture.
4. Peri-implant MBLC: Periapical radiographs were taken at T0 (immediately after the insertion of the fixture) and at T2 (1-year follow-up). They were made perpendicular to the long axis of the implant with long-cone parallel technique using an occlusal custom template to measure the marginal bone level. A dedicated dentist measured the changes in crestal bone height over time. The difference in bone level was measured radiographically through specific software (DIGORA 2.5, Soredex, Tuusula, Finland). The software was calibrated for every single image using the known implant length and

diameter at the most coronal portion of the neck of the implant. The linear distance between most coronal point of bone-to-implant contact and the coronal margin of the implant collar was measured to the nearest 0.01 mm, at both mesial and distal sides and averaged. Bone level changes at single implants were averaged at patients level and then at group level.

#### Analysis of Data

Associations between CD4+ level count, smoking habits, oral hygiene (PI, BI, and PPD), and the outcome variables constituted the main target of data analyses.

For CD4+ values, the sample was divided into two subgroups ( $CD4+ \leq 749.5$  vs  $CD4+ > 749.5$ ) on the basis of a median split (median: 749.5). With respect to smoking habits, patients were divided into “nonsmokers /light smokers” (i.e., patients smoking less than 10 cigarettes a day) and “heavy smokers” (i.e., patients smoking more the 10 cigarettes a day). With respect to the assessment of oral hygiene, PI, BI, and PPD indexes were obtained and correlated with the main outcome measures considered at different points in time (T1, T2).

To inspect the relation between the level of CD4+ and outcome variables, score variations between groups of participants were compared and analyzed either with the chi-squared or the Fisher’s exact test when considering variables based on nominal data or, alternatively, with the Mann–Whitney *U* test when considering variables based on ordinal data. A multivariate analysis of variance (MANOVA) was run in order to assess simultaneous variations in failure of implants versus failure of prosthesis versus MBLC indices as a function of a subgrouping of patients into patients with  $CD4+ < 749.5$  versus  $CD4+ > 749.5$ , along with a possible statistical interaction between the three indices and patients’ assignment to one of the two CD4+ subgroups.

To inspect the relation between smoking habits and outcome variables, score variations observed between groups of participants were compared and analyzed either with the chi-squared or the Fisher’s exact test when considering variables based on nominal data (i.e., peri-implantitis, pus, pain) or, alternatively, with the Mann–Whitney *U* test, when considering variables based on ordinal data (i.e., number of implant failures).

TABLE 3 Demographic Data of Subjects

	Whole Sample N: 68 (100%)	No Smokers n: 26 (38.2%)	Smokers ( $\leq 10$ Cigarettes/Day) n: 29 (42.6%)	Smokers ( $> 10$ Cigarettes/Day) n: 13 (19.1%)
Age	55.3 $\pm$ 17.2 years (range 40–73)	50.2 $\pm$ 10.2 years (range 40–62)	56.2 $\pm$ 9.8 years (range 48–73)	58.4 $\pm$ 12.5 years (range 42–71)
Gender	46 males (67.6%) 22 females (32.4%)	16 Males (23.5%) 10 females (14.7%)	22 males (32.3%) 7 females (10.3%)	8 males (11.7%) 5 females (7.4%)
CD4+ count (cell/mm <sup>3</sup> )	CD4+ count: 726.3 $\pm$ 201.4 cell/mm <sup>3</sup> (range 400–1100 cell/mm <sup>3</sup> )	CD4+ count: 655.88 $\pm$ 208.5 cell/mm <sup>3</sup>	CD4+ count: 779.83 $\pm$ 203.6 cell/mm <sup>3</sup>	CD4+ count: 747.69 $\pm$ 145.04 cell/mm <sup>3</sup>

To detect possible associations between the level of oral hygiene and the study outcomes, a nonparametric Spearman's rank correlation analysis was run, relating the average PI score (i.e., a score obtained by averaging patients' PI index considered at T1 and T2) and the number of implant failures. Always by means of a Spearman's rank correlation analysis, we then correlated this average PI score with MBLC, and also with the number of peri-implantitis. Finally, to further illuminate possible associations with oral health, the outcomes were correlated with the mean scores of BI and PPD (i.e., with mean scores obtained by averaging separately both BI and PPD indexes, considered at T1 and T2).

All analyses were performed with a dedicated software (SPSS Inc., version 20.0). The conventional level of statistical significance was set at  $\alpha = 0.05$ .

## RESULTS

Demographic data of the sample are reported in Table 3.

Overall, 194 implants were positioned in 68 patients (22 females and 46 males). Forty-eight patients (70.6%) received total removable dentures; 11 patients (16.2%) received partial prosthesis, and nine patients (13.2%) received single elements. Because of an exacerbation of their systemic disease, two patients (each of them had two implants in the mandible with removable prosthesis) dropped out from the study between T0 and T1, thus leading to a final sample of  $N = 66$  patients at T1 (190 fixtures). The flow chart of the study is represented in Figure 1.

Failures occurred in 7.9% of the fixtures (15 fixtures out of 190). Five fixtures out of 190 (2.6%) failed due to early infection and 10 out of 190 (5.2%) due to peri-implantitis. Prosthetic failure was registered in two patients (2.9% of patients) due to the loss of all the

fixtures. Pus and pain were observed in 4/7 and 3/7 patients with peri-implantitis, respectively. No fractures of fixtures or paresthesia were registered. At T2, the mean peri-implant MBLC was  $-1.19 \pm 0.87$  mm.

### CD4+ Level

No significant difference was observed comparing patients with  $CD4+ \leq 749.5$  and patients with  $CD4+ > 749.5$  with respect to any of the outcome variables (Table 4). A MANOVA confirmed this result by assessing the significance of simultaneous variations in the measurement of "failure of implants" versus "failure of prosthesis" versus "MBLC" indices as a function of patients grouping with respect to CD4+ levels (patients with  $CD4+ \leq 749.5$  vs patients  $CD4+ > 749.5$ ). The multivariate analyses revealed a trivial main effect for measures, such that the mean values observed for MBLC were higher than the mean values of both failure of implants and failure of prosthesis measures – this effect being simply due to the different scale metrics used in assessing the three indices. Most importantly, however, the analysis confirmed the absence of a significant difference between groups of patients, and also revealed no interaction between group of patients and the three dependent variables entered in the multivariate analyses.

### Smoking Habits

The number of implant failures resulted significantly different between no/light smokers and heavy smokers (Mann-Whitney  $U = 508$ ,  $z = 2.78$ ,  $p < .005$  (Table 5). In addition, it was also observed that patients smoking  $> 10$  cigarettes/day, if compared with their counterparts of patients smoking  $< 10$  cigarettes/day, showed a statistically significant greater number of peri-implantitis



6 Clinical Implant Dentistry and Related Research, Volume \*, Number \*, 2015

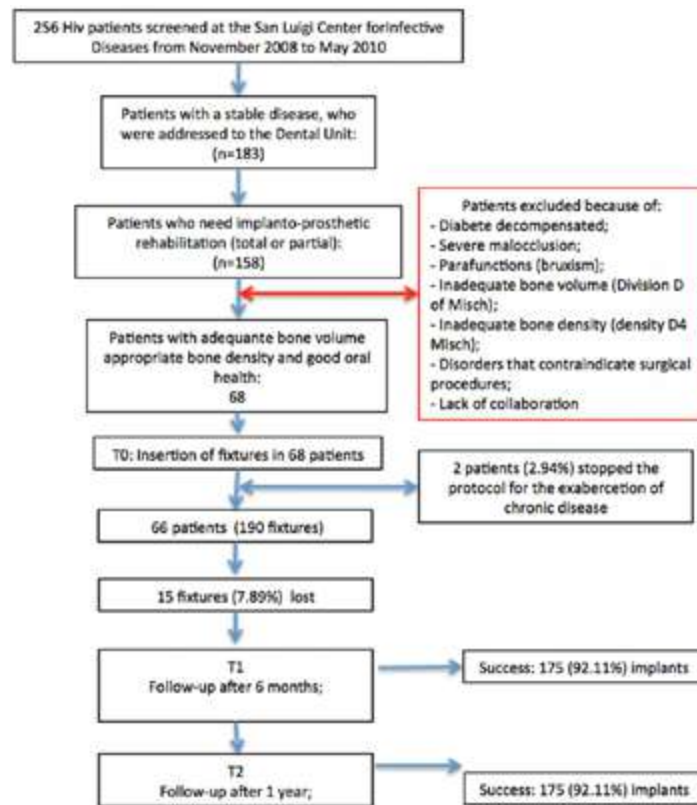


Figure 1 Flow chart of the study.

TABLE 4 Results Represented at Patient Level			
	CD4+ ≤ 749.5 (n = 33)	CD4+ > 749.5 (n = 33)	Significance
Failure of implants	6 out of 33 (18.1%)	2 out of 33 (6%)	NS
Failure of Prosthesis	2 out of 33 (6%)	0 out of 33 (0%)	NS
MBLC	1.09 ± 0.32 (mm)	1.12 ± 0.36 (mm)	NS
Peri-implantitis	5 out of 33 (15.1%)	2 out of 33 (6%)	NS
Pus	2 out of 33 (6%)	0 out of 33 (0%)	NS
Pain	2 out of 33 (6%)	0 out of 33 (0%)	NS

Patients were grouped on the basis of CD4+ level.

TABLE 5 Results Represented at Patient Level

	No smoking patients and patients smoking <10 cigarettes/day	Patients smoking >10 cigarettes/day	Significance
Failure of implants	54 (81.9%) 4 out of 54 (7.4%)	12 (18.1%) 5 out of 12 (41.6%)	Mann–Whitney $U = 508$ , $z = 2.78$ ; $p \leq .005$
Failure of Prosthesis	1	1	NS
MBLC	$1.09 \pm 0.35$	$1.17 \text{ mm} \pm 0.31$	NS
Peri-implantitis	2 out of 54 (3.7%)	5 out of 12 (41.6%)	Mann–Whitney $U = 518$ , $z = 3.38$ $p \leq .001$
Pus	1 out of 54 (1.8%)	4 out of 12 (33.3%)	Chi-squared = 7.22 $p \leq .007$ , with Yates continuity correction; Fisher Exact test $p = .007$
Pain	0 out of 54 (0%)	3 out of 12 (25%)	Chi-squared = 6.85 $p \leq .009$ , with Yates continuity correction; Fisher Exact test $p = .009$

Patients were grouped on the basis of smoking habits.

(Mann–Whitney  $U = 518$ ,  $z = 3.38$ ,  $p < .001$ ), a comparatively higher incidence of pus (chi-squared = 7.22,  $p < .007$  with Yates continuity correction, this result being independently confirmed also by a Fisher's exact test,  $p = .007$ ), and a comparatively higher incidence of self-reported pain (Chi-squared = 6.85,  $p < .009$  with Yates continuity correction, this result being independently confirmed also by a Fisher Exact test,  $p = .009$ ).

No/light smokers and heavy smokers showed no significant differences in mean MBLC recorded on survived implants after 1 year from insertion (Mann–Whitney  $U = 439.5$ ,  $z = 0.621$ ,  $p = .53$ ). MBLC was calculated excluding all those implants affected by peri-implantitis (10 sites) or early infection (five sites) that failed before 6 months of follow-up. More specifically, MBLC of survived implants at 1 year follow-up was  $1.09 \pm 0.35$  mm in the first group of patients, and  $1.17 \pm 0.31$  mm in the second (comparison) group.

#### PI, BI, PPD

No statistically significant associations were observed between averaged PI scores (i.e., scores forming an index whose values were obtained by averaging patients' PI scores across T1 and T2) and implant failures (Spearman's  $\rho = -0.14$ ,  $p = .25$ ;  $n = 66$ ); between PI and

MBLC (Spearman's  $\rho = -0.06$ ,  $p = .67$ ;  $n = 66$ ); and between averaged PI scores and peri-implantitis (Spearman's  $\rho = -0.14$ ,  $p = .25$ ;  $n = 66$ ), respectively (Table 6). A similar pattern of results was observed also for the averaged BI scores (i.e., scores forming an index whose values were obtained by averaging patients' BI scores across T1 and T2), though no statistically significant associations were observed between averaged BI scores and implant failures (Spearman's  $\rho = 0.09$ ,  $p = .45$ ;  $n = 66$ ); between averaged PI scores and MBLC (Spearman's  $\rho = -0.04$ ,  $p = .75$ ;  $n = 66$ ); nor between averaged PI scores and peri-implantitis (Spearman's  $\rho = 0.08$ ,  $p = .52$ ;  $n = 66$ ). Also, average PPD scores (i.e., patients' PPD values averaged across T1 and T2) showed any statistically significant association with implant failure ( $n = 66$ , Spearman's  $\rho = 0.07$ ,  $p = .57$ ), nor with MBLC ( $n = 66$ , Spearman's  $\rho = -0.01$ ,  $p = .95$ ). No further statistically significant association emerged between PPD and peri-implantitis ( $n = 66$ , Spearman's  $\rho = 0.03$ ,  $p = .84$ ).

#### DISCUSSION

Limited published scientific evidence is available to guide clinicians regarding possible increased risks associated with dental implant placement in HIV-positive

8 *Clinical Implant Dentistry and Related Research, Volume \*, Number \*, 2015***TABLE 6 Correlations with Mean PI, Mean BI, and Mean PPD (mean value between registration at T1 and T2)**

Variable 1	Variable 2	Significance
Failure of implants	Mean PI (1.33 ± 0.22)	$n = 66$ , Spearman's $\rho = -0.14$ , $p = .25$
MBLC	Mean PI (1.33 ± 0.22)	$n = 66$ , Spearman's $\rho = -0.06$ , $p = .67$
Peri-implantitis	Mean PI (1.33 ± 0.22)	$n = 66$ , Spearman's $\rho = -0.14$ , $p = .25$
Failure of implants	Mean BI (0.64 ± 0.26)	$n = 66$ , Spearman's $\rho = 0.09$ , $p = .45$
MBLC	Mean BI (0.64 ± 0.26)	$n = 66$ , Spearman's $\rho = -0.04$ , $p = .75$
Peri-implantitis	Mean BI (0.64 ± 0.26)	$n = 66$ , Spearman's $\rho = 0.08$ , $p = .52$
Failure of implants	Mean PPD (1.92 ± 0.26)	$n = 66$ , Spearman's $\rho = 0.07$ , $p = .57$
MBLC	Mean PPD (1.92 ± 0.26)	$n = 66$ , Spearman's $\rho = -0.01$ , $p = .95$
Peri-implantitis	Mean PPD (1.92 ± 0.26)	$n = 66$ , Spearman's $\rho = 0.03$ , $p = .84$

patients. In this study, a group of HIV-positive patients was subjected to implant-prosthetic therapy and followed for a period of 1 year. Implant failures, prosthetic failures, complications, or MBLC were not significantly associated to the level of CD4+ in the blood. Different authors found similar results.<sup>4,8,16,17</sup> Oliveira and colleagues<sup>4</sup> followed 59 implants for 12 months after loading. Higher baseline levels of pyridinoline and deoxypyridinoline found in HIV-positive participants did not interfere with osseointegration after 12 months of follow-up. They concluded that the placement of dental implants in HIV-positive patients is a reasonable treatment, regardless of CD4+ cell count, viral load levels, and type of antiretroviral therapy.

Stevenson and colleagues,<sup>8</sup> in a prospective study including 20 HIV-positive subjects (test group) and nine HIV-negative subjects (control group) reported that the short-term (6 months) success rate was 100% for both groups, and no difference in clinical outcome was found between the groups.

Achong and colleagues<sup>16</sup> in a report of three cases indicated that implant surgery may not carry an increased risk for the HIV-positive patient, and the low CD4+ cell count levels at the time of implant placement appear to have no effect on the success of implants. The various levels of CD4+ cell counts throughout treatment for these three patients did not correlate with the outcome of the implants.

Thus, according to our results, the placement of dental implants in HIV-positive patients seems a reasonable therapy, regardless of CD4+ cell count, if patients have a stable disease.

The study of the association between smoking habits and implant failure did not reach statistical sig-

nificance when participants were grouped into three categories of patients (no smoking patients vs patients who smoked  $\leq 10$  cigarettes/day vs patients who smoked  $> 10$  cigarettes/day), because of an insufficient number of patients assigned to each category. When nonsmoking patients and patients who smoked  $\leq 10$  cigarettes/day were categorized together, however, we observed significantly more implant failures, peri-implantitis, episodes of pus, and pain in heavy smokers ( $> 10$  cigarettes/day) than nonsmokers–light smokers ( $< 10$  cigarettes/day). Considering the timing of failures, these results correlate well with the reports in the literature linking smoking to early implants failures<sup>18</sup> and to peri-implantitis.<sup>19</sup> HIV-positive smokers are more susceptible to oral infections (candidiasis and hairy leukoplakia) than HIV-positive nonsmokers.<sup>20</sup> This susceptibility plays an important role for implant failure. Implant failures are more frequent among smokers (5.6%) compared with nonsmokers (3.5%),<sup>21</sup> probably due to lowering blood flow rate, due to increased peripheral resistance and platelet aggregation, or to modifications in the level of immunoglobulines in the saliva.<sup>22</sup>

In our sample, MBLC of survived implants at 1-year follow-up was found to be  $1.09 \pm 0.35$  mm in the group of nonsmokers or light smokers ( $< 10$  cigarettes/day), and  $1.17 \pm 0.31$  mm in smokers.

In literature, the average peri-implant bone loss after 12 months is lower, about 0.47 to 0.49 mm in HIV-positive patients.<sup>4</sup> Perhaps the difference could be related the fact that bone loss was measured from implant insertion and not from implant loading.

MBLC was recorded as a difference between baseline and 1-year data and, because of the early failure (before 6 months from loading) of implants affected by

peri-implantitis, the MBLC value in the groups of implants with peri-implantitis is unknown. So, the correlation between MLBC and dependent variables cannot be excluded.

Moreover, the number of implant failures, prosthetic failures, peri-implantitis, episodes of pus, and pain did not correlate with bleeding or oral hygiene or PPD (mean values of BI, PI, or PPD between T1 and T2). However, patients were initially included only if they had a good oral hygiene and followed a strict maintenance recall system.

### CONCLUSIONS

Within the limitation of the present study, placement of dental implants in HIV-positive patients with stable disease seems a reasonable treatment option, regardless of CD4+ cell count. Oral hygiene variables did not influence the result of the treatment in a well-maintained population. HIV-positive heavy smokers (>10 cigarettes/day) demonstrated an increased risk for implant failure, for peri implantitis, episodes of pus, and self-reported pain.

### ACKNOWLEDGMENT

This study was co-funded by the Italian Ministry of Health, protocol number RF-FSR-2007-646412.

### REFERENCES

- Shetty K, Achong R. Dental implants in the HIV-positive patient—case report and review of the literature. *Gen Dent* 2005; 53:434–437.
- Kolhatkar S, Khalid S, Rolecki A, Bhole M, Winkler JR. Immediate dental implant placement in HIV-positive patients receiving highly active antiretroviral therapy: a report of two cases and a review of the literature of implants placed in HIV-positive individuals. *J Periodontol* 2011; 82:505–511.
- Romanos GE, Goldin E, Marotta L, Froum S, Tarnow DP. Immediate loading with fixed implant-supported restorations in an edentulous patient with an HIV infection: a case report. *Implant Dent* 2014; 23:8–12.
- Oliveira MA, Gallottini M, Pallos D, Maluf PS, Jablonka F, Ortega KL. The success of endosseous implants in human immunodeficiency virus-positive patients receiving antiretroviral therapy: a pilot study. *J Am Dent Assoc* 2011; 142:1010–1016.
- Bergendal B. Evidence and clinical improvement: current experiences with dental implants in individuals with rare disorders. *Int J Prosthodont* 2006; 19:132–134.
- Passaes CP, Saez-Cirion A. HIV cure research: advances and prospects. *Virology* 2014; 454–455:340–352.
- Gherlone E, Capparé P, Tecco S, et al. Implant prosthetic rehabilitation in controlled HIV- positive patients: a prospective longitudinal study with one-year follow-up. *Clin Implant Dent Relat Res* 2015; 7:doi: 10.1111/cid.12353.
- Stevenson GC, Riano PC, Moretti AJ, Nichols CM, Engelmeier RL, Flaitz CM. Short-term success of osseointegrated dental implants in hiv-positive individuals: a prospective study. *J Contemp Dent Pract* 2007; 8:1–10.
- Harrison WJ, Lewis CP. Wound healing after implant surgery in HIV-positive patients. *J Bone Joint Surg* 2002; 84:802–806.
- Tran H, Moncure M, Tarnoff M, et al. Predictors of operative outcome in patients with human immunodeficiency virus infection and acquired immunodeficiency syndrome. *Am J Surg* 2000; 180:228–233.
- Patton LL, Shugards DA, Bonito AJ. A systematic review of complication risks for HIV-positive patients undergoing invasive dental procedures. *J Am Dent Assoc* 2002; 133:195–203.
- Twito D, Sade P. The effect of cigarette smoking habits on the outcome of dental implant treatment. *PeerJ* 2014; 2:e546.
- Porter JA, von Fraunhofer JA. Success or failure of dental implants? A literature review with treatment considerations. *Gen Dent* 2005; 53:423–432, quiz 433, 446.
- von Elm E, Altman DG, Egger M, et al. The Strengthening the Reporting of Observational Studies in Epidemiology (STROBE) statement: guidelines for reporting observational studies. *J Clin Epidemiol* 2008; 61:344–349.
- Crespi R, Capparé P, Gherlone E. A 4-year evaluation of the peri-implant parameters of immediately loaded implants placed in fresh extraction sockets. *J Periodontol* 2010; 81:1629–1634.
- Achong RM, Shetty K, Arribas A, Block MS. Implant in HIV-positive patients: 3 case reports. *J Oral Maxillofac Surg* 2006; 64:1199–1203.
- Strietzel FP, Rothe S, Reichart PA, Schmidt-Westhausen AM. Implant-Prosthetic treatment in HIV-infected patients receiving highly active antiretroviral therapy: report of cases. *Int J Oral Maxillofac Implants* 2006; 21:951–956.
- De Bruyn H, Collaert B. The effect of smoking on early implant failure. *Clin Oral Implants Res* 1994; 5:260–264.
- Saaby M, Karring E, Schou S, Isidor F. Factors influencing severity of peri-implantitis. *Clin Oral Implants Res* 2014; doi: 10.1111/clr.12505.
- U.S. Department of Health and Human Services. *AIDS.gov: HIV and Smoking* [last revised 2013 Jul 5; accessed 2014 Apr 17]. 2013.
- Klokkevold PR, Han TJ. How do smoking, diabetes, and periodontitis affect outcomes of implant treatment? *Int J Oral Maxillofac Implants* 2007; 22(Suppl):173–202.

10 *Clinical Implant Dentistry and Related Research, Volume \*, Number \*, 2015*

22. Giuca MR, Pasini M, Tecco S, Giuca G, Marzo G. Levels of salivary immunoglobulins and periodontal evaluation in smoking patients. *BMC Immunol* 2014; 15:5.
23. Maini MK, Gilson RJ, Chavda N, et al. Reference ranges and sources of variability of CD4 counts in HIV-seronegative women and men. *Genitourin Med* 1996; 72:27–31.
24. Chilton D, Neuhaus J, Palfreeman A Utility of CD4 count monitoring in patients on HAART who maintain viral load suppression – experience from the VS arm of the SMART study. 14th British HIV Association Conference, 23–25 April 2008, Belfast, Ireland. Abstract O21.



## Digital Impressions for Fabrication of Definitive “All-on-Four” Restorations

Enrico Felice Gherlone, MD, DMD,\* Francesco Ferrini, DDS,† Roberto Crespi, MD, MS,‡  
Giorgio Gastaldi, MD, DMD,§ and Paolo Cappare, MD, MS||

The basis for prosthetic work in implant dentistry remains an intraoral impression that is subsequently poured in dental stone. This traditional workflow has proven itself in clinical practice, although impression materials are prone to dimensional changes because of on-going chemical reactions,<sup>1</sup> and stone will show expansion because of secondary reactions while setting.<sup>2</sup> As the impression procedure is at the origin of the workflow, potential errors introduced in this phase will reverberate in the rest of the workflow. The misfit of framework will generate stress on the implants, which may have a biological effect on the bone-implant interface.<sup>3,4</sup> Also prosthetic complications as screw loosening or fracture may be related to ill-fitting framework fit.<sup>5</sup>

Although none of the techniques has proven to be a gold standard, digital implant impressions constitute a major role in the development of the full digital workflow for fixed implant prosthetic restorations.<sup>6</sup>

With a digital impression system, the data from the intraoral scanner can

**Purpose:** The aim of this study was to assess the accuracy of digital impressions for “all-on-four” implant rehabilitation.

**Materials and Methods:** Patients edentulous in one or both jaws were randomly selected for this study. Complete arch immediately loaded prostheses supported by 4 implants (2 axial and 2 tilted) were placed. Five hours after implant placement, screw-retained full-arch temporary prostheses were positioned. After 4 months, a digital scan body was used to finalize definitive prosthesis. Radiographic assessments were obtained immediately after surgery and at each follow-up visit. Bone level measurements were reported at 6 and 12 months, and bone loss between upright and tilted implants was compared.

**Results:** Fourteen definitive cast metal frameworks prosthesis were delivered to the patients. No implant dropout occurred. All prosthesis were screwed onto the dental implants, and x-ray examinations revealed a bar-implant connection accuracy. The implant survival rate was 100% for all positioned implants. No statistically significant differences ( $P > 0.05$ ) in crestal bone loss between tilted and upright implants were detected.

**Conclusions:** Digital impression creates an accurate physical model significantly improving efficiencies for the dental team and streamlining the workflow. (Implant Dent 2015;24:125–129)

**Key Words:** digital impression, all-on-four, tilted implants

be electronically transmitted to the manufacturer for the fabrication of a definitive prosthetic restoration.<sup>7,8</sup> Implants, however, will only show a range of motion of 3 to 5  $\mu\text{m}$  in axial direction and 10 to 50  $\mu\text{m}$  in lateral direction after osseointegration due to compression of the bone.<sup>9</sup> An intraoral scanner could overcome some of the errors associated with traditional impression taking<sup>10</sup> and cast production,<sup>11</sup> as digital output data can be fed directly into a digital workflow.

In the literature, there are clinical reports about digital impression technique in implant dentistry, but most of them reported to fabricate a customized

anatomic abutment and zirconia restoration.<sup>12–15</sup> Consequently, the aim of this study was to assess the accuracy of digital impressions for “all-on-four” implant rehabilitation.

### MATERIALS AND METHODS

This clinical study was performed in the Department of Dentistry, San Raffaele Hospital, Milan, Italy. From November 2011 to June 2012, 14 patients, 8 women and 6 men with a mean age of 56.3 years (range, 43–80 years) were randomly selected for this study. The following inclusion criteria were adopted: all patients were in good health, patients had to be edentulous (in 1 or

\*Full Professor and Chairman, Department of Dentistry, Vita Salute University, IRCCS San Raffaele, Milan, Italy.  
†Private Practice, Fieschi, Rome, Italy.  
‡Clinical Professor, Department of Dentistry, Vita Salute University, IRCCS San Raffaele Hospital, Milan, Italy.  
§Associate Professor, Dental School, University of Brescia, Brescia, Italy.  
||Adjunct Professor, Department of Dentistry, Vita Salute University, IRCCS San Raffaele, Milan, Italy.

Reprint requests and correspondence to: Paolo Cappare, MD, MS, Department of Dentistry, Vita Salute University, IRCCS San Raffaele, Via Olgettina N.48, 20121 Milano, Italy. Phone: 0639 6226432921. Fax: 06399226432953. E-mail: paolocappare@gmail.com

ISSN 1055-6103/15/0201-125  
Implant Dentistry  
Volume 24 • Number 1  
Copyright © 2015 by Lippincott Williams & Wilkins  
DOI: 10.1097/ID.0000000000000206



both jaws) or had a few hopeless teeth, and severe atrophy of the mandible or maxilla in posterior regions. Exclusion criteria were the absence of any active infection or severe inflammation in the areas intended for implant placement, presence of chronic systemic disease, smoking more than 15 cigarettes, bruxism habits, and poor oral hygiene.

The diagnosis was made clinically and radiographically (preoperative panoramic radiograph and computer tomography scan) (Fig. 1). All patients gave their written informed consent for immediate implant loading and digital impression procedure.

#### Surgical Procedure

One hour before surgery, the patients received 2 g amoxicillin (Zimox; Pfizer Italia, Latina, Italy) and 1 g twice a day for a week after surgical procedure. Surgery was performed under local anesthesia (optocain 20 mg/mL with adrenalin 1:80,000; Astra, Milan, Italy).

In edentulous mandible, incisions were made on top of the alveolar crest, from the first molar on one side to the first molar on the contralateral side with bilateral releasing incisions. Subperiosteal dissection on the lingual and vestibular surfaces was carried out, and mental foramina were sited. The most posterior implants were placed close to the anterior wall of the mental loop and were tilted distally about 30 to 35 degrees relative to the occlusal plane. The posterior implants, which were 4.5 mm in diameter and 15 or 13 mm in length, typically emerged at the second premolar position. Anterior implants were either 4.5 or 3.8 mm in diameter and 13 mm in length (Winsix; BioSAFin, Ancona, Italy) (Table 1). After placement of the posterior

implants bilaterally, additional implants were placed in the anterior space (Fig. 1, B). When necessary, bone shaping was performed with a round bur to level the bone crest, and to achieve crestal positioning in the posterior arches, bone recontouring was performed distal to the angled implants.

In edentulous maxillary patients, incisions were made on the alveolar crest from the first molar on one side to the first molar on the contralateral side with bilateral releasing incisions. Subperiosteal dissection was carried out. The most posterior implant was placed close to and parallel with the anterior sinus wall. Thus, this implant was tilted distally approximately 30 to 35 degrees. The lower corner of the implant neck was positioned at bone level.

Then, the placement of implants in the anterior part of the maxilla was performed, and the implant neck was positioned at bone level. The posterior implants were 4.5 mm in diameter and 15 or 13 mm in length, and the anterior implants were either 4.5 or 3.8 mm in diameter and 13 mm in length (Winsix; BioSAFin) (Table 1).

The implant in immediate function had a final insertion torque of at least 40 N·cm. Underpreparation was performed in soft bone to obtain high primary stability. In 3 patients, anterior implants were immediately positioned in postextraction sockets. In fresh sockets, granulation tissue was removed. Angulated abutments (Extreme Abutment, EA Winsix; BioSAFin) for anterior implants were set at 17 degrees and those for posterior implants at 30 degrees to compensate for the lack of parallelism between implants. These abutment angulations were chosen so that the prosthetic screw access holes were in an occlusal or

lingual location. Flap adaptation and suturing were performed in the usual manner with 4-0 nonresorbable suture.

#### Prosthetic Protocol

The vertical dimension was established and corrected using facial reference marks recorded before surgery. Immediately after implant placement, traditional impression materials (Permadyne; ESPE, Seefeld, Germany) were used to take the impressions, the implant analogs were attached to the impression copings, and a stone model was created with the analogs representing the positioning of the implant in the model. Five hours after implant placement, screw-retained full-arch temporary prosthesis by only all-acrylic resin frameworks were positioned. After 4 months, a digital scan body was used to finalize definitive prosthesis (Fig. 2). The scan body replaced the traditional impression coping and allowed the implant fixture to be captured with an intraoral digital scanning device.

The intraoral scanner used in the study was Lava COS (3M Espe, St. Paul, MN) with software version 2.1. The Lava COS uses active wavefront sampling<sup>15</sup> to obtain a 3D model of the dentition. The Lava COS is a 3D video system that captures 20 3D frames per second, which are registered real time. After the scanning procedure, a postprocessing cycle is necessary to recalculate the registration and compensate for potential errors, resulting in a high-resolution model that is uploaded to 3M. Before scanning with the Lava COS, teeth need to be dusted with Lava Powder (3M Espe), a titanium oxide powder. The latter has to do with the technology the scanner uses.

Scannable impression copings were secure to the implants with the corresponding screwdriver. The dust particles on implant abutments were used for registration of the 3D patches obtained during scanning. High-accuracy scanning protocol for scanning consists of a calibration with the aforementioned calibration block followed by a slow zig-zag scanning of the dentition. After the scan, the calibration with the calibration block is performed for a second time. The calibration measurements are used to calculate and compensate for errors that have occurred during scanning.

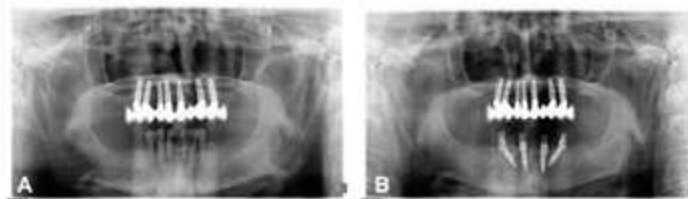


Fig. 1. Maxillary edentulous ridge (A); panoramic radiograph after implant placement (B).

**Table 1.** Implant Diameters and Lengths for Maxilla and Mandible (Maxilla, n = Implant = 24; Mandible, n = Implant = 32)

Maxilla (n = 24)	Diameter (mm)	Length 13 (mm)	Length 15 (mm)
Upright (n = 12)	4.5	8	0
	3.8	4	0
Tilted (n = 12)	4.5	4	4
	3.8	2	2
Mandible (n = 32)	Diameter (mm)	Length 13 (mm)	Length 15 (mm)
Upright (n = 16)	4.5	6	0
	3.8	10	0
Tilted (n = 16)	4.5	2	4
	3.8	8	2

Then the opposing arch was sprayed and scanned in similar fashion, followed by a scan of the buccal aspect of the patient's dentition in maximum intercuspation.

All the scans of the scanner were uploaded to the laboratory and returned after postprocessing. The virtual images were evaluated for accuracy of detail and correct occlusal relationship. Once the virtual model is created with the dental implant in position, virtual digital creation of framework and restorations can be designed through the computer-aided design (CAD) software.

The monolithic model, which includes a removable die of a replica of the CAD/computer-aided manufacturing prosthetic manufacture, was used

by the laboratory to fabricate the restoration. As the definitive frameworks are being milled titanium (Fig. 2), the rapid prototype model is simultaneously sent to the dental laboratory for use in fabricating the definitive restoration. Fourteen definitive prostheses were made by acrylic resin masticatory surfaces and metal frameworks for increased strength and rigidity (Fig. 1). All prostheses were positioned and screwed onto dental implants. The Sheffield 1-screw test<sup>16</sup> was carried out to check the precision of bar.

The marginal fit of frameworks screwed onto the implants was checked by radiographic evaluation (Fig. 2). Articulating paper (Bausch Articulating

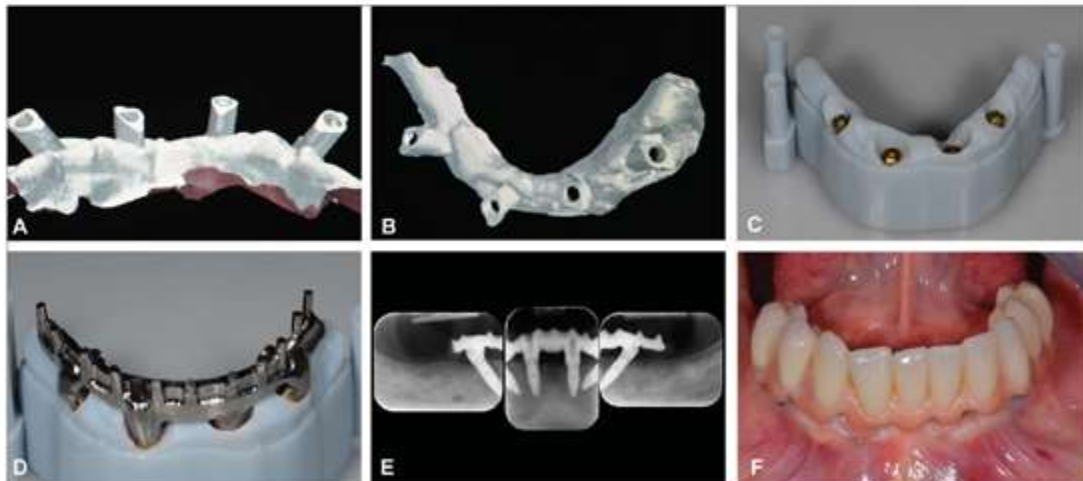
Paper, Nashua, NH) was used to check the occlusion and adjust it, if necessary. Static occlusion consisted of central contacts established on all masticatory units. Dynamic occlusion included canine/premolar guidance, regardless of the opposite arch settings. Screw access holes were covered with provisional resin (Fermit; Ivoclar Vivadent, Bolzano, Italy). All patients followed a soft diet (avoiding bread and meat) for 2 months.

#### Follow-up

Follow-up visits were performed by a dental hygienist at 3, 6, and 12 months after implant insertion. Success criteria for implant survival were the presence of implant stability, the absence of radiolucent zone around the implants, no mucosal suppuration, and no pain.

Restoration success was defined as the absence of fractures of the acrylic resin superstructure, even if one or more implants supporting the restoration have been removed. Implant survival was defined as the absence of implant mobility, swelling, or pain in the surgical site at the time of examination.

Implant success was defined as implant survival with marginal bone loss of less than 1.5 mm after 1 year of loading and no more than 0.2 mm of



**Fig. 2.** Scan bodies fit into the dental implant fixture. Image of virtual framework (A and B); occlusal view of the stereolithographic model (C); framework screwed on the stereolithographic model (D); radiographic evaluation of the marginal fit of frameworks screwed onto the implants (E); and final restoration (F).



**Table 2.** Crestal Bone Loss Values (Mean  $\pm$  SD) for Maxillary and Mandibular Tilted and Upright Implants (Maxilla  $n =$  Implant = 24; Mandible  $n =$  Implant = 32)

Bone Loss	Upright		Tilted	
	Maxilla ( $n = 24$ )	Mandible ( $n = 40$ )	Maxilla ( $n = 24$ )	Mandible ( $n = 40$ )
6 mo (mm)	1.05 $\pm$ 0.29	0.88 $\pm$ 0.46	1.04 $\pm$ 0.39	1.06 $\pm$ 0.56
12 mo (mm)	1.07 $\pm$ 0.99	1.02 $\pm$ 0.72	1.07 $\pm$ 0.81	1.10 $\pm$ 0.89

loss between each follow-up appointment after the first year of function.

#### Radiographic Examination

Radiographic assessments were made using panoramic radiographs obtained immediately after surgery and at each follow-up visit (Fig. 1). The correct assessment of marginal fit of frameworks screwed onto the implants was checked by radiographic evaluation (Fig. 2). Bone level measurements were performed on the mesial and distal aspect of each implant, using the implant-abutment junction as a reference point. To adjust for dimensional distortion and enlargement on the radiographs, the actual sizes of the implants were compared with the measured implant dimensions on the radiograph.<sup>4,17</sup> A radiologist twice measured the changes in marginal bone height over time: he marked the reference points and measured lines on the screen interactively; the numeric value of measurements was reported by software (CDR; Schick Technologies, Long Island City, NY). The implant height (a known dimension) was used for calibration. The radiographic measurements were compared with the values obtained immediately after surgery.

#### Statistical Analysis

A dedicated software (SPSS 11.5.0; SPSS, Chicago, IL) was used for all statistical analyses. Bone level measurements were reported as mean  $\pm$  SDs at 6 and 12 months. Bone loss around the upright and tilted implants was compared by means of the Student *t* test at a significance level of  $P = 0.05$ .

#### RESULTS

Fourteen patients were treated with immediately temporary loaded 14 complete-arch prostheses (6 maxillary and 8 mandibular region) supported by 4 implants (in total 56 implants). After 4

months, 14 definitive cast metal framework prostheses were delivered to the patients. No implant dropout occurred. All prostheses were screwed onto the dental implants, and x-ray examinations revealed a bar-implant connection accuracy (Fig. 2). The implant survival rate was 100% for all positioned implants. None of the 14 fixed prostheses were lost during the observation period, representing a prosthetic survival rate of 100%. No occlusal screw loosening was observed.

At the 12-month evaluation, peri-implant crestal bone loss averaged 1.07  $\pm$  0.99 mm for upright maxillary implants and 1.07  $\pm$  0.81 mm for tilted maxillary implants (Table 2). In the mandible, a mean peri-implant crestal bone loss of 1.02  $\pm$  0.72 mm for upright implants and 1.10  $\pm$  0.89 mm for tilted implants were found (Table 2). No statistically significant differences ( $P > 0.05$ ) in crestal bone loss between tilted and upright implants was detected at 6- and 12-month follow-up evaluation in either jaws.

#### DISCUSSION

All final prosthesis screwed onto the dental implants revealed a very accurate bar-implant connection. The scan bodies fit precisely into the dental implant fixture in the mouth to allow for accurate capture the position of the implant fixture, just as a traditional implant impression coping does.<sup>17</sup> The scan body has a precise geometrical shape on the surface to allow for optical capture of the fixture. Once the scan body image is captured and registered, the CAD software through alignment algorithms can accurately position the implant into the virtual model. Additionally, new developments for digital impression processing allow for the digital creation of a physical dental model with a removable repositionable implant analog so the laboratory technician can

use the digital model in a traditional fashion for restoration fabrication.

As reported in this clinical study, Lava COS had low variation in its measurements with a few angular errors and positive values.<sup>15</sup> In a vitro study, Ender and Mehl<sup>18</sup> have compared the Lava COS to the cast of an Impregum impression. In their study, the accuracy was defined by the terms "trueness": the deviation of the model about the true size of the object and "precision": the fluctuation of the different measurements. The trueness of the Lava COS was better than an Impregum impression.

The video system, as LAVA COS with a frame rate of 20 images per second, may lead to an accurate surface registration. The Lava COS uses powder particles as markers as an extra tool for the computer to join the different pieces of the 3D model. As registration errors, however minute, will always occur in registration procedures,<sup>19</sup> one expects an additive effect of these errors over the length of the arch. When comparing intraoral scanners in full-arch impression procedures, it would be interesting to involve the influence of the length of the span to assess the expected additive effect of the registration errors that may occur.

In the study of Ender and Mehl,<sup>18</sup> an increase in the deviations between the models in certain areas were noted, but these can be explained by the registration procedure. The algorithm most likely tried to register the surfaces in such a way that the overall mean deviation between the surfaces is the smallest and this may conceal an increase in deviations between the surfaces and makes interpretation of deviations difficult. A best fit algorithm on basis only of the area where the scanning was started may have shown a possible increase in deviations in their study.

Once the scan body is scanned and the structured data are captured, software is then used to process each data point to create a geometrical virtual 3-dimensional model. The CAD software applications have created the virtual geometric 3-dimensional model, computer-aided manufacturing techniques use various printing, and milling machines to create an exact replica of the virtual model in a physical form.

## CONCLUSIONS

This study advocates the use of the intraoral scanner, which virtually creates an accurate physical model that significantly improves efficiencies for the dental team and streamlines the workflow. This improved workflow should provide benefits to the dentist, the laboratory technician, and to the patient. Additional clinical studies are necessary to assess the efficiency of digital impression procedure.

## DISCLOSURE

The authors claim to have no financial interest, either directly or indirectly, in the products or information listed in the article.

## REFERENCES

1. Johnson GH, Craig RG. Accuracy of four types of rubber impression materials compared with time of pour and a repeat pour of models. *J Prosthet Dent.* 1985;53:484-490.
2. Milstein PL. Determining the accuracy of gypsum casts made from type IV dental stone. *J Oral Rehabil.* 1992;19:239-243.
3. Sahin S, Cahrel M, Yalcin E. The influence of functional forces on the biomechanics of implant-supported prostheses—A review. *J Dent.* 2002;30:271-282.
4. Wang T, Leu L, Wang J, et al. Effects of prosthesis materials and prosthesis splinting on peri-implant bone stress around implants in poor-quality bone: A numeric analysis. *Int J Oral Maxillofacial Implants.* 2002;17:231-237.
5. Sones AD. Complications with osseointegrated implants. *J Prosthet Dent.* 1989;62:581-585.
6. Christensen GJ. Impressions are changing: Deciding on conventional, digital or digital plus in-office milling. *J Am Dent Assoc.* 2009;140:1301-1304.
7. Henkel GL. A comparison of fixed prostheses generated from conventional vs digitally scanned dental impressions. *Compend Contin Educ Dent.* 2007;28:422-431.
8. Kurbad A. Impression-free production techniques. *Int J Comput Dent.* 2011;14:59-66.
9. Kim Y, Oh TJ, Misch CE, et al. Occlusal considerations in implant therapy: Clinical guidelines with biomechanical rationale. *Clin Oral Implants Res.* 2005;16:26-35.
10. Karl M, Rosch S, Graef F, et al. Strain situation after fixation of 3-unit ceramic veneered implant superstructures. *Implant Dent.* 2005;14:157-165.
11. Dell'Acqua MA, Arioli-Filho JN, Compagnoni MA, et al. Accuracy of impression and pouring techniques for an implant supported prosthesis. *Int J Oral Maxillofac Implants.* 2008;23:226-236.
12. Lin WS, Harris BT, Morton D. The use of a scannable impression coping and digital impression technique to fabricate a customized anatomic abutment and zirconia restoration in the esthetic zone. *J Prosthet Dent.* 2013;109:187-191.
13. Joda T, Wittneben JG, Bragger U. Digital implant impressions with the "Individualized Scanbody Technique" (IST) for emergence profile support. *Clin Oral Implants Res.* 2013. doi: 10.1111/ocr.12099.
14. Lin WS, Harris BT, Morton D. Use of implant-supported interim restorations to transfer perimplant soft tissue profiles to a milled polyurethane definitive cast. *J Prosthet Dent.* 2013;109:333-337.
15. Syrek A, Reich G, Ranftl D, et al. Clinical evaluation of all-ceramic crowns fabricated from intraoral digital impressions based on the principle of active wavefront sampling. *J Dent.* 2010;38:553-559.
16. McDonnell T, Houston F, et al. The effect of time lapse on the accuracy of two acrylic resins used to assemble an implant framework for soldering. *J Prosthet Dent.* 2004;91:538-540.
17. Lee SJ, Gallucci GD. Digital vs. conventional implant impressions: Efficiency outcomes. *Clin Oral Implants Res.* 2013;24:111-115.
18. Ender A, Mehl A. Full arch scans: Conventional versus digital impressions an in vitro study. *Int J Comput Dent.* 2011;14:11-21.
19. Maintz JB, Viergever MA. A survey of medical image registration. *Med Image Anal.* 1998;2:1-36.

## Implant Prosthetic Rehabilitation in Controlled HIV-Positive Patients: A Prospective Longitudinal Study with 1-Year Follow-Up

Enrico F. Gherlone, MD, DMD;\* Paolo Capparé, MD, MFS;† Simona Tecco, DDS, PhD;‡  
Elisabetta Polizzi, BS;§ Giuseppe Pantaleo, PhD;§ Giorgio Gastaldi, MD, DMD;¶  
Maria Gabriella Grusovin, DDS\*\*

### ABSTRACT

**Purpose:** The clinical trial aimed to evaluate the survival of implant-prosthetic rehabilitation in controlled HIV-positive patients.

**Materials and Methods:** This mono-centric study included HIV patients with a stable disease, requiring implant rehabilitation, with good oral hygiene. Each patient received at least one dental implant. After 90 days in the upper jaw and 60 days in the lower jaw, the appropriate prosthesis was delivered. Primary outcome measures were prosthetic failures, implant failures, peri-implant marginal bone level changes (MBLCs), and biological complications (peri-implantitis, pus, pain, paresthesia). Data were recorded before the intervention (T0), and 6 (T1) and 12 months (T2) after.

**Results:** Implants were positioned in 68 patients (22 females and 46 males; 194 implants). Two dropouts occurred for exacerbation of the disease before the sixth month of follow-up, and 66 patients (with 190 implants) completed the study. Forty-eight patients (70.6%) received total removable dentures; 11 patients (16.2%) received partial prosthesis, and nine patients (13.2%) received single elements. Implant failure occurred in nine patients (15 fixtures out of 190). These were early implant failures due to primary infection (five fixtures out of 190: 2.6%) and to peri-implantitis (10 fixtures out of 190: 5.2%). Prosthetic failure was registered in two patients (3% of patients) due to the loss of all the fixtures. Pus and pain were observed in 4/7 and 3/7 patients with peri-implantitis, respectively. No fractures of fixtures or paresthesia were registered. At T2, the mean peri-implant MBLC was  $-1.19 \pm 0.87$  mm.

**Conclusions:** Within its limitations, the study showed that in a well-controlled population of HIV patients implant rehabilitation can be a suitable options with results slightly worse to those obtained in normal population. A higher incidence of peri implant infections in the first six months was present pointing to the need of a proper protocol for infection control.

**KEY WORDS:** AIDS, HIV, implant, implant survival, implantology, osseointegration, peri-implantitis

\*Full professor and chairman, Dental School, Vita-Salute University and IRCCS San Raffaele, Milan, Italy; †researcher, Dental School, Vita-Salute University and IRCCS San Raffaele, Milan, Italy; ‡adjunct professor, Dental School, Vita-Salute University and IRCCS San Raffaele, Milan, Italy; §associate professor, Faculty of Psychology, UniSR Social Lab (Research Methods), Vita-Salute San Raffaele University, Milan, Italy; ¶associate professor, Dental School, University of Brescia, Brescia, Italy; \*\*adjunct professor, Dental School, Vita-Salute San Raffaele University, Milan, Italy

Corresponding Author: Dr. Paolo Capparé, Dentistry Department, IRCCS San Raffaele Hospital, Via Olgettina n. 48, Milan 20132, Italy; e-mail: paolocappare@gmail.com

Conflict of Interest: No author had any conflict of interest. The material is original and has not been published elsewhere.

### INTRODUCTION

AIDS is one of the most serious diseases affecting humanity. By the end of 2007, about 33 million people worldwide were living with HIV, and millions had died of AIDS.<sup>1</sup>

Today, life expectancy for HIV-infected individuals has increased due to the use of potent antiretroviral therapy.<sup>2</sup> With the sustained reduction in AIDS-related morbidity and mortality, the prospect of living with HIV as a chronic, rather than a terminal, disease has

© 2015 Wiley Periodicals, Inc.

DOI 10.1111/cid.12353

increased, and HIV-infected edentulous patients are becoming informed consumers of oral healthcare and are requesting a variety of procedures, including dental implants.<sup>3</sup>

Oral health is generally very poor for HIV-positive individuals, as about 40% to 50% of HIV-positive persons have oral fungal, bacterial or viral infections often occurring early in the course of the disease.<sup>3</sup> The most important etiopathogenetic factors are immunodeficiency states, alterations in the salivary flow (xerostomia), nutritional deficiencies, secondary occlusal trauma and the increase in plaque due to poor oral hygiene.<sup>4</sup>

Oral lesions strongly associated with HIV infection are pseudo-membranous oral candidiasis, oral hairy leukoplakia, HIV gingivitis and periodontitis, kaposi sarcoma, non-Hodgkin lymphoma, and dry mouth due to a decreased salivary flow.<sup>5</sup> Moreover, in these patients, the carious disease is often destructive, affecting large areas of enamel, especially at the cervical-vestibular, and involves painful symptoms only in very advanced stages, when it is more difficult to apply conservative intervention.<sup>5</sup> In addition, there is a high incidence of periodontal ulcerative-necrotic disease.<sup>4</sup> Many of these problems can progress to the point that result in partial or complete loss of the natural dentition.<sup>6</sup> Treatment of oral pathologies is mandatory in HIV patients to minimize and possibly eliminate all infections because they can be the starting point for more serious systemic infections able to undermine the general health.<sup>6</sup> Besides, the pathological problems of the oral cavity contribute to prevent the social rehabilitation of HIV patients, since these individuals can present functional and aesthetic situations (partially edentulous and/or total root residues, destructive caries) not compatible with a good interpersonal relationship, and their treatments contribute enormously to the self-esteem.<sup>3,4</sup> Implants can be in most cases the optimal therapeutic solution, but there is a lack of data<sup>7-9</sup> in literature about oral implant-prosthetic rehabilitations of HIV patients, except for mandibular overdenture.<sup>10</sup> Data are needed to help in properly treating these types patients and so in promoting their oral health and eventual social reintegration into society and the world of work.

This prospective longitudinal clinical trial aimed to evaluate survival of implant-prosthetic rehabilitation in controlled HIV-positive patients, with good oral

hygiene. One-year follow-up after implant insertion was considered. Survival criteria for implant were presence of implant stability, absence of radiolucent zone around the implants, no mucosal suppuration, and no pain (Buser, and Albrektsson and Isidor).<sup>11,12</sup>

In this article, the Strobe guidelines (Strengthening the Reporting of Observational Studies in Epidemiology) were followed.<sup>13</sup>

## MATERIALS AND METHODS

This longitudinal prospective mono-centric trial (IRCCS San Raffaele Hospital in Milan, Italy)<sup>14</sup> included controlled HIV-affected patients that required implant rehabilitation.

The eligibility criteria were as follows:

- HIV-positive patients
- Age >18 years
- Total or partial edentulous
- Adequate bone volume (divisions A, B, or C according to Misch classification of bone available<sup>15</sup>) and appropriate bone density (classes D1, D2, or D3 Misch<sup>16</sup>);
- Blood values:
- CD4+ level count >400 cells/mm<sup>3</sup>
- Hemoglobin >8 mg/dl
- Absolute neutrophil count >750 cells/mm<sup>3</sup>
- Platelets >75.000 cells/mm<sup>3</sup>
- AST < 5 times the upper limit of normal value (ULN)
- Bilirubin <2.5 times ULN
- Alkaline phosphatase <5 times ULN
- Creatinine <2.5 mg/ml

Exclusion criteria were as follows:

- Severely immunocompromised patients with a high recurrence of opportunistic infections, tuberculosis, or malignancy spread
- Diabetes decompensated
- Severe malocclusion
- Severe parafunctions (bruxism)
- Inadequate bone volume (Division D of Misch)
- Inadequate bone density (density D4 Misch)
- Disorders that contraindicate surgical procedures
- Lack of collaboration
- Lack of oral hygiene: plaque index superior to 1

The patients were recruited at the San Luigi Center for Infective Diseases, IRCCS San Raffaele Hospital,



Milan, in which HIV-infected patients are kept under medical control.

All those who submit the medical parameters and blood values of a stable disease were then addressed at the Department of Dentistry, IRCCS San Raffaele Hospital, Milan, Italy.

The patients with partial or total edentulism, which could benefit from an implant-prosthetic rehabilitation, were then selected according to the described inclusion/exclusion criteria.

All patients received and signed a written consent form for implant procedures, and the Italian Ministry of Health approved the protocol.

#### Interventions Administered to the Group

During the first dental examination of the patients, the following procedures were done:

- General intraoral examination
- Evaluation of the orthopantomography or any Tc Dental scans
- Implant planning (number of fixtures; the location, the type of prosthesis)

A few days before the surgery, periodontal health checkup (by the hygienist or dentist) was performed<sup>17</sup>: modified bleeding index (mBI); modified plaque index (mPI); and probing depth (PD) (Table 1). This stage was the T0 for the clinical periodontal parameters.

At the day scheduled for the surgery, implants were positioned after antibiotic prophylaxis with amoxicillin and clavulanic acid, 2 g orally, 1 hour before surgery. A full-thickness flap was raised, and implant placement was conducted in accordance with the manufacturer protocol (WinSix®, BioSAFin. S.r.l., Ancona, Italy). Conical implants with rough surface (full contact covering® surface, Biosafin, Ancona, Italy) and internal hexagon connection were used (K implants, WinSix).

Postoperative therapy consisted of amoxicillin and clavulanic acid 1 g × 2 per day for 7 days after surgery, rinse with 0.2% chlorhexidine twice a day for 15 days after surgery, and pain medication as needed. Suture removal was carried out after 7 to 10 days. Re-entry procedures for healing abutment placement were performed in each case at least after 50 days from implant placement.

After 90 days for the upper jaw and 60 days for the lower jaw, a precise impression was made.

For total removable dentures, ball attachments were screwed directly onto the abutments, and two ball housings (matrices) were mounted in the overdenture.

For single crowns and fixed partial dentures, definitive metal-ceramic restorations were cemented onto the definitive abutments.

#### Outcome Measures

The outcomes considered were as follows:

1. Prosthesis failure: when prosthesis has to be replaced due to implant failure.
2. Implants failure: implant removal dictated by mobility, progressive marginal bone loss due to peri-implantitis, any mechanical complication rendering the implant not usable (e.g., implant fracture). The stability of each individual implants was assessed manually 6 and 12 months from insertion by tightening the abutment screws with the removed prostheses.
3. Biological and prosthetic complications (number and type) were recorded as single episodes for each implant. Particular attention was used to assess peri-implantitis (defined as progressive bone loss with sign of infections around an osseointegrated implant), presence of pain, presence of pus, paresthesia in the lower jaw, implant fracture.

**TABLE 1** Periodontal Health Indices and Details of Methods of Measurement

Variable	Timing	Method
Modified bleeding index (mBI)	T0, T1, and T2	Values were recorded at the mesial, distal, buccal, and palatal surfaces of the implants using a periodontal probe (PGF-GFS, Hu-Friedy, Chicago, IL, USA).
Modified plaque index (mPI)	T0, T1, and T2	Values were recorded at the mesial, distal, buccal, and palatal surfaces of the implants using a periodontal probe (PGF-GFS, Hu-Friedy, Chicago, IL, USA).
Probing depth (PD)	T0, T1, and T2	Values were recorded at the mesial, distal, buccal, and palatal surfaces of the implants using a periodontal probe (PGF-GFS, Hu-Friedy, Chicago, IL, USA).

4 *Clinical Implant Dentistry and Related Research, Volume \*, Number \*, 2015*

4. Peri-implant marginal bone level changes (MBLCs): Periapical radiographs were taken at T0 (immediately after the insertion of the fixture) and at T2 (1-year follow-up). They were made perpendicular to the long axis of the implant with long-cone parallel technique, using an occlusal custom template to measure the marginal bone level. A dedicated dentist measured the changes in crestal bone height over time. The difference in bone level was measured radiographically through specific software (DIGORA 2.5, Soredex, Tuusula, Finland). The software was calibrated for every single image using the known implant diameter at the most coronal portion of the neck of the implant. The linear distance between most coronal point of bone-to-implant contact and the coronal margin of the implant collar was measured to the nearest 0.01 mm, at both mesial and distal sides, and averaged. Bone level changes at single implants were averaged at patients level and then at group level.

#### Follow-Up Evaluation

The appointments with the dental hygienist were scheduled each 2 months. For the oral hygiene at home, patients were instructed on the proper use of aids such as interproximal brush, mono tuft toothbrush, and Super floss. Patients were recommended to brush their teeth at least three times a day.

Complete examination of the patient was done at 6 and 12 months after implant insertion.

#### Analysis of Data

Data were analyzed at patient level. Demographic data on age, gender, and CD4+ level counts at T0 were reported and summarized in form of means, standard deviations, frequencies, and range.

The height, the diameter, and the position of the inserted fixtures were specified for the whole sample, and the frequency of the types of prosthetic rehabilitation (upper total; lower total; partial or single elements) was calculated for the whole sample.

For the outcome measures, the number of implant failures, prosthetic failures, peri-implantitis, episodes of pus, pain, paresthesia, and fracture of fixtures was reported as absolute values and/or percentages in the whole sample (190 implants in 66 patients). Comparisons of MBLC levels among patients with different prosthetic rehabilitations were performed by means of a

one-way ANOVA, and a nonparametric Kruskal-Wallis test for independent samples.

Cumulative survival rate of implants was also reported.

#### RESULTS

From November 2008 to May 2010, 256 HIV-positive patients (age >18 years) were screened at the San Luigi Center for Infectious Diseases, IRCCS San Raffaele Hospital, Milan, in which HIV-infected patients are monitored and given medical assistance. Seventy-three patients were excluded from further assessment because they were severely immunocompromised (CD4+ level <400 cell/mm<sup>3</sup>), with a high recurrence of opportunistic infections, tuberculosis, or malignancy spread, and had altered values of hemoglobin, absolute neutrophil count, platelets, AST, bilirubin, alkaline phosphatase, and creatinine.

The remaining patients ( $N = 183$ ) met the medical parameters of a stable disease and were thus addressed to the Department of Dentistry, IRCCS San Raffaele Hospital, Milan, Italy.

At the Department of Dentistry, patients with partial or total edentulism (i.e., who could possibly benefit from implant-prosthetic rehabilitation) were firstly individuated ( $n = 158$ ).

Of these 158 patients, 90 were excluded for the following reasons:

- Disorders that contraindicated surgical procedures ( $n = 25$ ), among which diabetes decompensated ( $n = 13$ ), severe malocclusion ( $n = 1$ ), severe parafunctions (bruxism) ( $n = 4$ ), inadequate bone volume (division D of Misch) ( $n = 5$ )
- Inadequate bone density (density D4 Misch) ( $n = 1$ )
- Patients refusing to collaborate ( $n = 23$ )
- lack of oral hygiene ( $n = 31$ )

Thus, 68 patients (22 females and 46 males) were included in the study and treated between November 2008 and July 2011. Among them, 26 (38.2%) were no smokers; 29 (42.6%) were lightly smokers (<10 cigarettes/day), and 13 (19.1%) were heavy smokers. Because of an exacerbation of their systemic disease, two patients (each of them had two implants in the mandible with removable prosthesis) dropped out from the study between T0 and T1, thus resulting in a final sample of  $N = 66$  patients at T1 (190 fixtures) (Figure 1).

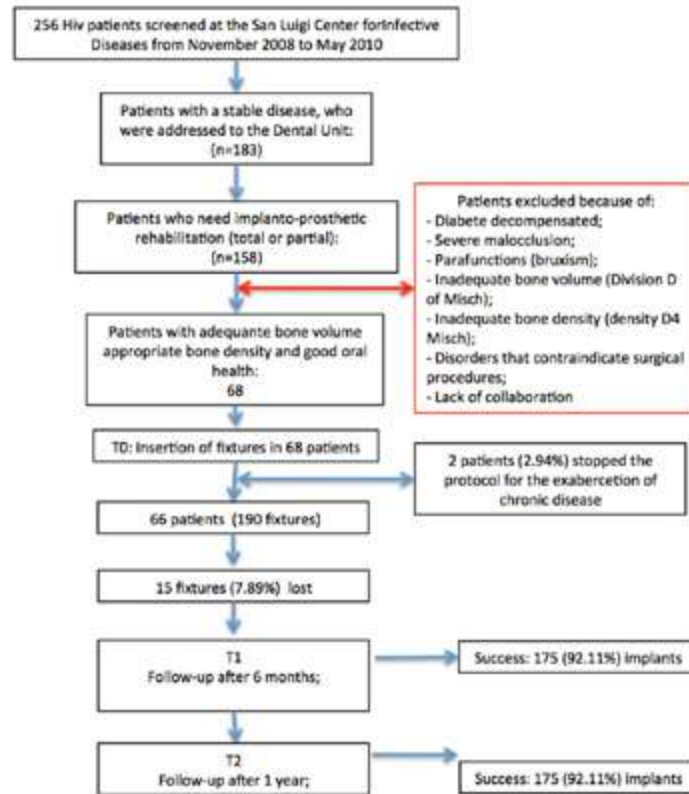


Figure 1 Flow chart of the sample included in the study.

Demographic data of patient population are reported in Table 2.

Fifty-seven patients (83.8%) received two to four fixtures, nine patients (13.2%) received a single fixture, and two patients (3%) received five and six fixtures; consequently, 48 patients (70.6%) were rehabilitated with total removable dentures (among them,

30 subjects received the upper dental arch, and 18 patients received the lower dental arch); 11 patients (16.2%) received partial prosthesis, and nine patients (13.2%) received single element rehabilitations (Figure 2 and Table 3).

The trend of periodontal health indices over time for the whole sample is shown in Figure 3. The appointments with the dental hygienist were scheduled each 2

TABLE 2 Demographic Data of Patient Population	
Whole Sample N: 68 (100%)	
Age	55.3 ± 17.2 Years (range 40–73)
Gender	46 Males (67.6%) 22 Females (32.4%)
CD4+ count (cell/mm <sup>3</sup> )	CD4+ count: 726.3 ± 201.4 cell/mm <sup>3</sup> (range 400–1,100 cell/mm <sup>3</sup> )
Smokers	42 (30 males; 12 females)

TABLE 3 Implant Diameter and Length				
Diameter (mm)	Length of the Fixtures (mm)			
	9 (%)	11 (%)	13 (%)	Total (%)
3.3	53 (27.9)	9 (4.7)	5 (2.6)	67 (35.2)
3.8	16 (8.4)	15 (7.9)	18 (9.5)	49 (25.8)
4.5	29 (15.3)	26 (13.7)	19 (10)	74 (38.9)
Total	98 (51.6)	50 (26.3)	42 (22.1)	190

6 Clinical Implant Dentistry and Related Research, Volume \*, Number \*, 2015

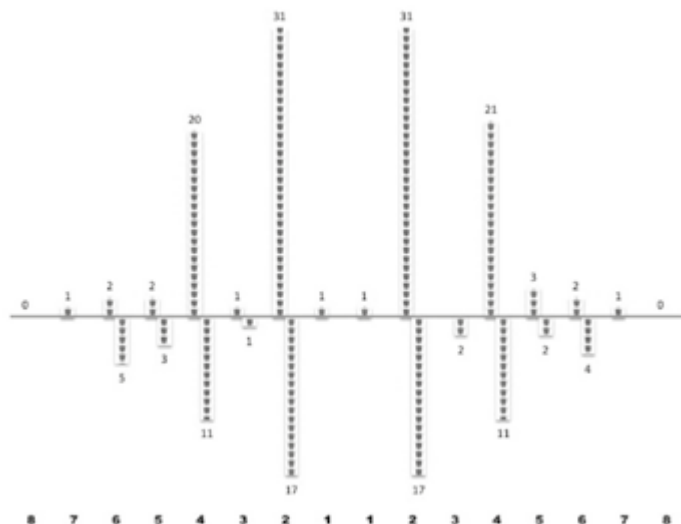


Figure 2 Distribution of the implants in the various sites of the mouth.

months during the follow-up. Sometimes, patients failed to visit the hygienist but they were always recalled for an another appointment.

**Prosthetic Failure**

Prosthetic failure was registered in two patients (2.9%) who had suffered the loss of all the implants positioned in their mouth; prosthetic failure occurred before T1.

One patient was a female smoker, (CD4+ level 675 cell/mm<sup>3</sup>; PI = 1) who lost four out of four implants before T1 (two implants due to peri-implantitis and two implants due to primary infection) and had received an upper prosthesis.

The other patient was a male smoker (CD4+ level 689 cell/mm<sup>3</sup>; PI = 0) who lost two out of two implants before T1 (one implant due to peri-implantitis and one implant due to primary infection) and had received an upper prosthesis.

**Implant Failure**

Nine patients (out of 66) experienced implant failure, and a total of 15 fixtures out of 190 (7.9%) were lost (Table 4). The cumulative survival rate was 92.1%. Ten implant out of 190 (5.2%) were lost for peri-implantitis in seven patients; five implants out of 190 (2.7%) were lost for primary infection in two patients. No fixture fracture occurred.

Five patients (7.5%) suffered the failure of one implant: three of them due to peri-implantitis before T1 and the other two due to primary infection soon after the insertion of the fixture.

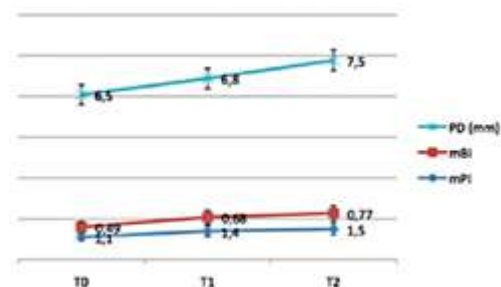


Figure 3 Trend of the periodontal health indices over time for the whole sample of patients analyzed (n = 66).

TABLE 4 Cumulative Survival Rate (CSR) of Implants			
	Fixtures	Lost Fixtures	CSR (%)
Surgery–10 days	190	1 (Primary failure)	99.47
10 Days–1 month	189	3 (Primary failure)	97.89
1–3 Months	186	1 (Primary failure)	97.37
3–6 Months	185	10 (Peri-implantitis)	92.11
6–1 Year	175	0	92.11

Three subjects (4.5%) suffered the failure of two implants. Specifically, a male smoker (CD4+ count: 774 cell/mm<sup>3</sup>) lost two out of four implants due to peri-implantitis before T1; another male smoker (CD4+ count: 689 cell/mm<sup>3</sup>) lost two out of two implants, one due to peri-implantitis before T1 and the other due to primary infection; and the third subject was a female smoker (CD4+ count: 845 cell/mm<sup>3</sup>) who lost two out of two implants due to peri-implantitis before T1.

One patient lost four out of four implants: Two implants were lost for peri-implantitis before T1, and two implants were lost due to primary infection; this woman is a smoker (CD4+ count: 675 cell/mm<sup>3</sup>) and lost the totality of the implants placed in her mouth before T1.

Once established as hopeless, the operator removed all failed implants due to their serious mobility; therefore, implants were removed without additional bone tissue.

#### Biological and Prosthetic Complications

Peri-implantitis was diagnosed in seven patients (10.6%), and 10 fixtures out of 190 total fixtures were interested (5.2%).

Further, in all of these patients, peri-implantitis always resulted in the loss of the interested fixture before T1. In all 10 cases, the peri-implantitis has been diagnosed after a period of 1 to 3 months from the prosthetic loading. Treatment procedure was not possible in any case since, in all cases, the need to remove the fixture in order to allow adjustment of the prosthesis and prevent prosthetic failure was immediately evident.

Three patients (4.5% of the whole sample) suffered from peri-implantitis, which affected the totality (100%) of their fixtures and also caused the complete loss of fixtures (100%). The remaining four patients (6% of the whole sample) suffered from peri-implantitis, which, instead, affected half (50%) of the positioned fixtures and also caused the loss of the 50% of the inserted fixtures.

Pus was observed in 4/7 patients with peri-implantitis. Pain was registered in 3/7 patients with peri-implantitis. In three patients, pus and pain were observed together. These three patients were affected by serious peri-implantitis; two of them lost the totality of their fixtures and also experienced prosthesis failure.

No paresthesia and no prosthetic complications were registered in the whole sample.

#### Peri-Implant MBLCs

At T2, in 66 patients with 190 fixtures, the mean peri-implant MBLC was  $-1.19 \text{ mm} \pm 0.87 \text{ mm}$  ( $-1.18 \text{ mm} \pm 0.85 \text{ mm}$  in the mesial site and  $-1.21 \text{ mm} \pm 0.89 \text{ mm}$  in the distal site).

MBLC did not differ among patients with different prosthetic rehabilitations (one-way ANOVA:  $F = 0.53$ ,  $p = .662$ ). Estimated means for MBLC were  $-1.16 \text{ mm} \pm 0.32$  in patients with total removable denture on ball attachment (superior);  $-1.03 \text{ mm} \pm 0.30$  in patients with total removable denture on ball attachment (inferior);  $-1.11 \text{ mm} \pm 0.4$  in patients wearing partial fixed prosthetic bridges (cemented); and  $-1.07 \text{ mm} \pm 0.44$  in patients with single crowns (cemented). A nonparametric Kruskal-Wallis test for independent samples confirmed the absence of statistical differences in MBLC levels among the four groups of patients (test statistic = 1.35,  $p = .716$ ).

#### DISCUSSION

This clinical trial aimed to evaluate the survival of implant-prosthetic rehabilitation in controlled HIV-positive patients with a stable disease, requiring implant rehabilitation, with good oral hygiene. A cumulative survival rate of 92.11% was reported. Other authors<sup>7,18-20</sup> reported higher survival rates of implants placed in HIV-positive patients, similar to the healthy population.

In a pilot study by Oliveira and colleagues,<sup>18</sup> 60 dental implants were placed in the posterior mandibles of 40 volunteers, divided into three groups: the first group was composed of HIV-positive patients receiving protease inhibitor (PI)-based HAART; the second was composed of HIV-positive patients receiving non-nucleoside reverse transcriptase inhibitor-based HAART (without PI); the third control group was composed of HIV-negative participants. The authors assessed peri-implant health 6 and 12 months after implant loading. After a follow-up period of 12 months, one patient died for exacerbation of AIDS, and the remaining implants healed uneventfully, with a good osseointegration. They concluded that the placement of dental implants in HIV-positive patients is a reasonable treatment option, with no statistically significant differences with healthy population, without evidence of possible increased risks associated with dental implant placement in HIV-positive patients.

Kolhatkar and colleagues<sup>19</sup> reported two cases of immediate postextraction implants in HIV-positive

patients with 100% success and, reviewing the literature about implantology in HIV-positive patients, described a total success rate up to 98.6%.

Moreover, Stevenson and colleagues<sup>10</sup> reported a 100% success rate in overdenture supported by two implants in HIV-positive patients compared with healthy subjects.

However, in the current literature, there are no studies with implant placements in more than 20 HIV patients, and often, single case reports were published and smokers were often excluded.<sup>7-9</sup> In our study, 66 patients were followed with 190 implants; 42 of them were smokers. Fifteen implants out of 190 (7.9%) in nine patients were early lost (before 6 months from the insertion), and prosthetic failure was registered before T1 in two patients (2.9% of the patients) who had suffered early implant failures.

In healthy subjects with healthy tissues and appropriate biomechanical load, long-term success rates of 93% to 98% for the fixtures have been described,<sup>20-22</sup> and early failure is generally reported in a percentage of 3% due to lack of osseointegration.<sup>23</sup> In the present study, early implant failure was caused by primary infection (before loading) which occurred in five implants out of 190 (2.7%) in two patients. Peri-implantitis was detected in 10 implants out of 190 (5.2%) (seven patients) and led to implant loss. Two patients experienced both primary infections and peri implantitis. This higher incidence of infections could probably be linked to immunologic condition, considering that oral hygiene was maintained at a good acceptable level, in which oral indices (mPI and mBI) did not show statistically significant changes over time (Figure 3). Possible clinical suggestion is to do a meticulous follow-up and increase the antimicrobial control in HIV patients.

Clinically suggestive is the presence of deep pockets around implants (mean value  $6.5 \text{ mm} \pm 0.49$ ), and PD increased over time in the whole sample, from a mean value of  $6.5 \pm 0.49 \text{ mm}$  to  $7.5 \pm 0.51 \text{ mm}$ , although a good oral hygiene has been maintained. This trend, although not statistically significant, could suggest a possible correlation with the HIV-positive status of these patients, but this data must be better investigated by subsequent studies, recalling these patients 3 to 4 years after implant placement and re-evaluating their PD.<sup>24,25</sup>

Mean bone loss was  $1.19 \text{ mm} \pm 0.87 \text{ mm}$ , slightly higher than values found by Oliveira and colleagues

about in HIV-positive patients ( $0.47\text{--}0.49 \text{ mm}$ ).<sup>18</sup> Perhaps the difference could be related to the presence of smokers, as Oliveira and colleagues<sup>18</sup> did not include smokers, or to the fact that bone loss was measured from implant insertion and not from implant loading.

However, other studies measured bone loss from implant placement in healthy patients, including smokers of less than 10 cigarettes/day, and reported similar values.<sup>17,26,27</sup>

At 1-year follow-up, all remaining fixtures achieved good osseointegration, documented by orthopantomograph and, clinically, by stability, absence of pain on percussion, and presence of infection. A good healing of the soft tissues and absence of prosthetic complications were observed in all the patients.

However, the present study presents some limits. Significant interpatient heterogeneity was recorded for the values of periodontal health, which could affect the results and the role of patient-related aspects (smoking habits, oral hygiene, CD4+ level), which could potentially influence periodontal health, and implant survival will be analyzed in a following paper.

A specific type of micro-rough implant surface, obtained with a galvanostatic anodizing process in a phosphate-sulfate bath, was used. The surface roughness could have an influence on the onset of peri-implantitis. The eventual influence of surface roughness will be investigated in a future trial.

The patients were followed in a specialized center, with expert clinicians working in collaboration with an infection center, so the generalization of the results should be considered. Expert clinicians and specialized hospitals seem much more adequate – with respect to private medical practice – to properly select HIV patients eligible for implantology and for the strict follow-up needed by these patients. In particular, infectious disease specialists could have an important role in determining the parameters to monitor the status of the systemic immune system of HIV-positive patients and to collaborate actively in the selection of patients at lower risk for implant-prosthetic rehabilitation treatment.

The results suggest that HIV patients should be included in a strict follow-up protocol monitoring oral hygiene and peri-implant health, mostly during the early phase of implant healing (0–6 months), to manage undesired complications and early implant failure.



## CONCLUSIONS

Within its limits, the study showed that in a well-controlled population of HIV patients who maintained proper oral hygiene and accepted to follow a proper professional maintenance protocol, implant rehabilitation can be a suitable options with results slightly worse to those obtained in normal population. A higher incidence of peri implant infections in the first six months was present pointing to the need of a proper protocol of infection control.

## ACKNOWLEDGMENT

This study was co-funded by the Italian Ministry of Health, protocol number RF-FSR-2007-646412.

## REFERENCES

- Murphy R. Treatment of HIV infection. In: Crowe S, Hoy J, Mills J, eds. Management of the HIV infected patient. 2nd ed. London: Martin Dunitz Ltd., 2002:117–128.
- Passaes CP, Saez-Cirion A. HIV cure research: advances and prospects. *Virology* 2014; 454–455:340–352.
- Bergendal B. Evidence and clinical improvement: current experiences with dental implants in individuals with rare disorders. *Int J Prosthodont* 2006; 19:132–134.
- Hwang D, Wang HL. Medical contraindications to implant therapy: part II: relative contraindications. *Implant Dent* 2007; 16:13–23.
- Patton L, Glick M. Clinician's guide to treatment of HIV-infected patients. 3rd ed. Baltimore, MD: American Academy of Oral Medicine, 2001.
- Alves M, Mulligan R, Passaro D, et al. Longitudinal evaluation of loss of attachment in HIV-infected women compared to HIV-uninfected women. *J Periodontol* 2006; 77:773–779.
- Achong RM, Shetty K, Arribas A, Block MS. Implant in HIV-positive patients: 3 case reports. *J Oral Maxillofac Surg* 2006; 64:1199–1203.
- Baron M, Gritsch F, Hansy AM, Haas R. Implants in HIV-positive patient: a case report. *Int J Oral Maxillofac Implants* 2004; 19:425–430.
- Strietzel FP, Rothe S, Reichart PA, Schmidt-Westhausen AM. Implant-Prosthetic treatment in HIV-infected patients receiving highly active antiretroviral therapy: report of cases. *Int J Oral Maxillofac Implants* 2006; 21:951–956.
- Stevenson GC, Riano PC, Moretti AJ, Nichols CM, Engelmeier RL, Flaitz CM. Short-term success of osseointegrated dental implants in HIV-positive Individuals: a prospective study. *J Contemp Dent Pract* 2007; 8:1–10.
- Buser D, Mericske-Stern R, Dula K, Lang NP. Clinical experience with one-stage, non-submerged dental implants. *Adv Dent Res* 1999; 13:153–161.
- Albrektsson T, Isidor F. Consensus report in Session V. In: Lang NP, Karring T, eds. Proceedings of the 1st European workshop on periodontology. London: Quintessence, 1993:365–369.
- von Elm E, Altman DG, Egger M, et al. The Strengthening the Reporting of Observational Studies in Epidemiology (STROBE) statement: guidelines for reporting observational studies. *J Clin Epidemiol* 2008; 61:344–349.
- Hanson BP. Designing, conducting and reporting clinical research. A step by step approach. *Injury* 2006; 37: 583–594.
- Misch CE. Divisions of available bone in implant dentistry. *Int J Oral Implantol* 1990; 7:9–17.
- Misch CE. Bone classification, training keys to implant success. *Dent Today* 1989; 8:39–44.
- Crespi R, Capparé P, Gherlone E. A 4-year evaluation of the peri-implant parameters of immediately loaded implants placed in fresh extraction sockets. *J Periodontol* 2010; 81:1629–1634.
- Oliveira MA, Gallottini M, Pallos D, Maluf P, Jablonka F, Ortega KL. The success of endosseous implants in human immunodeficiency virus-positive patients receiving anti-retroviral therapy. A pilot study. *J Am Dent Assoc* 2011; 142:1010–1016.
- Kolhatkar S, Khalid S, Rolecki A, Bhola M, Winkler JR. Immediate dental implant placement in HIV-positive patients receiving highly active antiretroviral therapy: a report of two cases and a review of the literature of implants placed in HIV-positive individuals. *J Periodontol* 2011; 82:505–511.
- Shetty K, Achong R. Dental implants in the HIV-positive patient. Case report and review of the literature. *Gen Dent* 2005; 53:434–437.
- Papaspyridakos P, Mokti M, Chen CJ, Benic GI, Gallucci GO, Chronopoulos V. Implant and prosthodontic survival rates with implant fixed complete dental prostheses in the edentulous mandible after at least 5 years: a systematic review. *Clin Implant Dent Relat Res* 2014; 16:705–717.
- Pjetursson BE, Thoma D, Jung R, Zwahlen M, Zembic A. A systematic review of the survival and complication rates of implant-supported fixed dental prostheses (FDPs) after a mean observation period of at least 5 years. *Clin Oral Implants Res* 2012; 23(Suppl 6):22–38.
- Han HU, Kim S, Han DH. Multifactorial evaluation of implant failure: a 19-year retrospective study. *Int J Oral Maxillofac Implants* 2014; 29:303–310.
- Manor Y, Oubaid S, Mardinger O, Chaushu G, Nissan J. Characteristics of early versus late implant failure: a retrospective study. *J Oral Maxillofac Surg* 2009; 67:2649–2652.
- Patton LL, Shugards DA, Bonito AJ. A systematic review of complication risks for HIV-positive patients undergoing invasive dental procedures. *J Am Dent Assoc* 2002; 133:195–203.

10 *Clinical Implant Dentistry and Related Research, Volume \*, Number \*, 2015*

26. Prosper L, Crespi R, Valenti E, Capparé P, Gherlone E. Five-year follow-up of wide-diameter implants placed in fresh molar extraction sockets in the mandible: immediate versus delayed loading. *Int J Oral Maxillofac Implants* 2010; 25:607–612.
27. Crespi R, Capparé P, Gherlone E. Immediate versus delayed loading of dental implants placed in fresh extraction sockets in the maxillary esthetic zone: a clinical comparative study. *Int J Oral Maxillofac Implants* 2008; 23:753–758.

310

## MINIMALLY INVASIVE FLAP TECHNIQUE FOR KERATINIZED GINGIVA PLACEMENT AROUND IMPLANTS

Dott. Pierluigi Pelagalli – Dott. Gian Luca Carlesi  
Private practice Rome

Topic: Implant therapy outcomes, surgical aspect

### Abstract

The presence of an adequate width of keratinized gingiva around implants is an essential condition for long maintenance of implant health. That condition achieve more natural perimplant prosthetic profiles, a more easy cleaneability, a more resistance to bacterial attack of oral environment. After tooth extraction occurs a reduction of the amount of keratinized gingiva due to the contraction of the tissues in the early stages of healing.

Therefore the restoration of an adequate proportion of keratinized gingiva around the implant is essential for a proper placement of a dental implant. Usually at the second stage of implant surgery is necessary to lift a partial thickness flap to reposition the keratinized gingiva from the top of the ridge to the buccal side of the implant suturing it to the periosteum, meanwhile a flapless approach results in a execution of an operculum of keratinized tissue whose margins, in many cases can be too close to the mucogingival line, not guaranteeing a minimum bandwidth of keratinized gingiva.

Current implant surgery looks more and more towards a minimally invasive approach and therefore the opportunity to perform techniques ensuring less morbidity for patient, less bone resorption around implants, less surgical sessions.

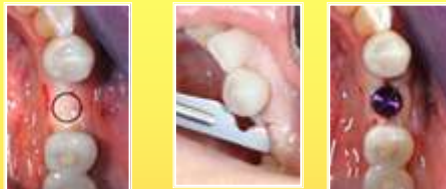
In this study, we propose a surgical technique that, without lifting a flap, allows us to gain an amount of keratinized gingiva at the same time of implant placement, reducing the number of surgery stages and the invasiveness of the procedure.

### Background and Aim

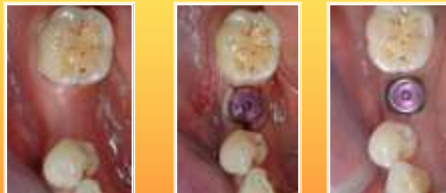
The aim of this study is to asseverate the validity of a surgical technique called Minimally Invasive Flap (MIF) which with a very limited invasivity at the level of the soft tissues lead to an increase of the perimplant keratinized bandwidth.

MIF technique is applied in cases where, although the gingival tissues are still preserved, the opercularization of a flapless approach is excessively mutilating and does not guarantee the preservation of an adequate band of keratinized gingiva, and when an apical repositioned flap have to be considered excessively intrusive.

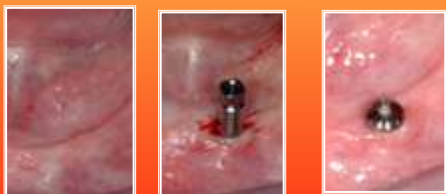MIF technique has the purpose, through a minimally invasive partial thickness flap, to move the crestal keratinized gingiva buccally and to reposition the mucogingival line more apical.



Case 1



Case 2



Case 3

### Methods and Materials

The indication of the tecnique is in cases where the residual amplitude of keratinized gingiva is between 6 and 8 mm.

We selected 20 cases to evaluate the average gain of keratinized gingiva with the approach of minimally invasive flap.

We measured the amplitude of keratinized tissue prior to implant placement (T0), immediately after insertion(T1), at three months, before the protesitation (T2), at 6 (T3) and 12 (T4) months after insertion.

We expect an increase of the band of keratinized gingiva that be stable after surgery.

Trasmucosal implants with large prosthetic platform or submerged implants with dedicated trasmucosal screws were used to help buccal stabilisation of the flap.

### Surgical Technique

A partial thickness flap was made by an incision along axis of adjacent teeth, without involving papille, with a sharp horizontal dissection in buccal side. The dissection extends till mucogengiva line, mesially and distally the programmed implant position. No releasing incision was made. The pocket flap obtained have the sufficient mobilization to be moved in buccal and apical direction by only the pressure imprinted by the trasmucosal platform of inserted implant. Usually no suture is necessary because flap results sufficiently stable.

Healing is made by first intention.

Case	Age	Sex	Site	Implant	Pre-op	Post-op	3 months	6 months	12 months	Final
1	55	F	Max	ITI	6	8	7	7	7	7
2	62	M	Max	ITI	7	9	8	8	8	8
3	58	F	Max	ITI	5	7	6	6	6	6
4	60	M	Max	ITI	8	10	9	9	9	9
5	57	F	Max	ITI	6	8	7	7	7	7
6	61	M	Max	ITI	7	9	8	8	8	8
7	59	F	Max	ITI	6	8	7	7	7	7
8	63	M	Max	ITI	7	9	8	8	8	8
9	56	F	Max	ITI	5	7	6	6	6	6
10	64	M	Max	ITI	8	10	9	9	9	9
11	58	F	Max	ITI	6	8	7	7	7	7
12	60	M	Max	ITI	7	9	8	8	8	8
13	57	F	Max	ITI	6	8	7	7	7	7
14	62	M	Max	ITI	7	9	8	8	8	8
15	59	F	Max	ITI	6	8	7	7	7	7
16	61	M	Max	ITI	7	9	8	8	8	8
17	56	F	Max	ITI	5	7	6	6	6	6
18	63	M	Max	ITI	8	10	9	9	9	9
19	58	F	Max	ITI	6	8	7	7	7	7
20	60	M	Max	ITI	7	9	8	8	8	8

### Results

In all 20 patients was obtained an augmentation of band of keratinized tissue between 3 and 5 mm. The apical migration of mucogingival junction was observed in totality of cases. The neck of implants was always surrounded by a wide keratinized band.

The healing time is less than an apical repositioning flap because the healing is always by first intention due to no presence of granulation tissue. The morbidity is comparable at flapless implant insertion.

The tecnique reduce the surgical session: no second surgery is needed. The healing period of mucosal tissues coincides with osteointegration period reducing the cumulative treatment time.

The prosthetic neck of implants results more natural and esthetic, easy to clean by oral hygiene aids.

The gain of keratinized gingiva appear stable during one year follow up.

### Conclusions

The surgical tecnique (MIF) allows to increase the amount of perimplant keratinized gingiva by a mini invasive partial-thickness flap at the same time of first surgery without additional interventions.

For the type of approach, for the amount of the gain of tissue, the tecnique appears to be limited to cases in which is needed an improvement of the prosthetic profile of the implant and in which there is not a severe deficiency of keratinized gingiva.

The tecnique need medium and long term followup to confirm clinical results obtained.

The tecnique have to be applied at selected cases, and always not in substitution of tissue regeneration procedures.

### References

- Shrago L, Wenzel A, Kostopoulos L, Karring T. Bone healing and soft tissue contour changes following single-tooth extraction: A clinical and radiographic 12 months prospective study Int J Perio Rest Dent 2003; 23:313-323
- Linkavicius T, et al. - The Influence of Soft Tissue Thickness on Crestal Bone Changes Around Implants: A 1-Year Prospective Controlled Clinical Trial - J Oral Maxillofacial Implants 2009; 24:712-719
- Lin GH, Chan HL, Wang H - The Significance of Keratinized Mucosa on Implant - Health: A Systematic Review. J Periodontol. 2013 Mar

Presented at





## CASO CLINICO

## La previsualizzazione estetica digitale in implantologia

### *Preoperative digital image processing for aesthetics in implant dentistry*



angelo\_cardarelli@libero.it



Digital smile design, impianti post estrattivi, odontoiatria estetica, virtual planning.

Digital smile design, post extraction implants, aesthetic dentistry, virtual planning.

## SCOPO DEL LAVORO

Scopo del lavoro è presentare i vantaggi del Digital Smile Design (DSD), una tecnica computerizzata per progettare il caso clinico, che permette di lavorare con foto e video dei pazienti. La moderna tecnologia digitale, unita all'esperienza ed alla sensibilità estetica dell'odontoiatra, è fondamentale ai fini del successo del Digital Smile Design, che offre al paziente migliore pianificazione dell'iter terapeutico e maggiore predicibilità di risultati estetici finali. Il DSD rappresenta quindi uno strumento per migliorare la comunicazione e il confronto con il paziente, grazie al fatto che, attraverso l'uso di immagini elaborate, sarà possibile vedere sul monitor digitale le fotografie prima/dopo.

## MATERIALI E METODI

Viene presentato il caso di una paziente di anni 60 sottoposta ad una riabilitazione protesica fissa implanto-supportata nell'arcata superiore e ad una riabilitazione protesica fissa su denti naturali nell'arcata inferiore. Il protocollo DSD (Digital Smile Design) utilizzato ha previsto innanzitutto l'acquisizione delle immagini del paziente a mezzo di fotografie digitali e video, che hanno consentito di rilevare le fasi dinamiche del sorriso (mimetica, fonetica, rapporti dento-labiali). Il passo seguente è stato il virtual planning, attraverso l'elaborazione delle immagini, a cui sono seguiti il wax up diagnostico digitale ed analogico, il mock up, la realizzazione del provvisorio e del restauro definitivo.

## RISULTATI E CONCLUSIONI

Il caso presentato dimostra come anche nelle riabilitazioni complesse la programmazione virtuale del piano di trattamento è uno strumento utile sia per l'odontoiatra, che riesce in questo modo a trasmettere più informazioni possibili e dettagliate al proprio odontotecnico, sia per il paziente, che riesce ad avere in anteprima un'idea precisa del timing operativo e di quale sarà il risultato finale del trattamento a cui si sottoporrà, interagendo in maniera esplicita con l'odontoiatra. Il risultato estetico finale

ottenuto, nel caso presentato, è sovrapponibile al progetto virtuale iniziale e dimostra, pertanto, che il DSD è un valido strumento anche in implantologia.

L'estetica del sorriso è una nuova disciplina odontoiatrica che si ispira al concetto di bellezza risalente alle teorie matematiche delle proporzioni del viso dell'antica Grecia, all'epoca rinascimentale italiana e a innumerevoli studi sull'argomento.

Il sorriso, poiché posto al centro del viso, è al centro della comunicazione espressiva ed emotiva del soggetto; quindi una buona estetica del sorriso è data dalla armonicità con le proporzioni del viso e dalla coerenza con la personalità e con l'emotività della persona.

Oggi l'uso di software 2D e 3D, associato al fototocco, offre la possibilità di elaborare dati e parametri personalizzandoli per ogni specifica esigenza clinico-estetica.

La soddisfazione del paziente per il risultato del trattamento estetico a cui si sottopone dipende dalla capacità dell'odontoiatra di capire le sue esigenze ed i suoi desideri e di trasferire tali informazioni al proprio odontotecnico. In questo contesto si colloca il Digital Smile Design, una tecnica computerizzata per progettare il caso clinico, che permette di lavorare con foto e video dei pazienti (1, 2, 3, 4). Il protocollo prevede innanzitutto l'acquisizione di fotografie digitali e video del paziente, che consentano di rilevare le fasi dinamiche del sorriso (mimetica, fonetica, rapporti dento-labiali). L'importazione di questi dati è ovviamente complementare all'anamnesi, poiché parte integrante dell'esame obiettivo intra ed extra orale. Il passo seguente è il virtual planning attra-



Angelo Cardarelli

Raffaele Vinci  
Enrico Felice Gherlone

Università Vita-Salute  
San Raffaele, Milano  
Corso di Laurea Magistrale in  
Odontoiatria  
e Protesi Dentaria  
Presidente:  
professor E. Gherlone  
IRCCS Ospedale  
San Raffaele, Milano  
Dipartimento di Odontoiatria  
San Raffaele Dental Clinic  
Direttore:  
professor E. Gherlone

## CASO CLINICO

verso l'elaborazione delle immagini, a cui seguirà il wax up diagnostico digitale ed analogico, il mock up, la realizzazione del provvisorio e del restauro definitivo (figg. 1, 2 e 3).

La posizione più corretta per ritrarre il viso del paziente è quella relativa al piano estetico, perpendicolare al piano che corre al centro dell'angolo che si forma tra il piano di Francoforte e quello di Camper. Per quanto riguarda l'importazione delle reali misure del soggetto fotografato è possibile usare strumenti di misurazione "artigianali", come squadre e righelli, preferibilmente metallici, in modo da poterli sterilizzare. Per avere una misurazione precisa e dettagliata degli elementi dentali e dei parametri gengivali, si può fare uso di calibri digitali. Le misure così ottenute risulteranno efficaci nella comunicazione tra odontoiatra e odontotecnico e verranno tradotte nella ceratura diagnostica tridimensionale e nei consecutivi mock-up che verranno presentati ed analizzati direttamente nel cavo orale del paziente (5, 6, 7, 8).

L'elaborazione digitale delle immagini può essere eseguita con diversi software facilmente reperibili sul web freeware o a pagamento; nel nostro protocollo abbiamo utilizzato il Keynote (applicazione di presentazione sviluppata da Apple per le piattaforme Mac OS X), che rende semplice lo Smile Design grazie al disegno dentale schematizzato con veri e propri outline (contorni digitali). Inoltre abbiamo creato la libreria Digital Dental Photos Database, comprendente tipologie diverse di dentature relativamente alla forma e al colore, quest'ultimo facilmente modificabile in relazione alla quantità e qualità di luce (fig. 4). Sono disponibili anche librerie dentali preformate per protesi mobili fornite dalle aziende leader nel settore; inoltre è possibile creare delle smile library costituite da fotografie con visi di modelli e modelle sorridenti, le cui dentature possono essere estrapolate e utilizzate per l'elaborazione delle immagini (9, 10, 11, 12, 13).

La trasposizione deve essere calibrata, cioè gli elementi devono essere spostati nelle posizioni desiderate mantenendo



Fig. 1  
Digital Smile Design.



Fig. 2  
Strumentazione digitale.

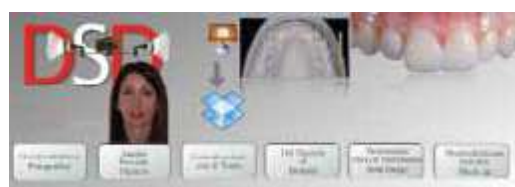

Fig. 3  
Protocollo DSD.



Fig. 4  
Digital Dental Design.

do invariate le misure anatomiche; sarà così possibile effettuare un calcolo affidabile della futura composizione dentale, non solo esteticamente ma anche funzionalmente

## MATERIALI E METODI

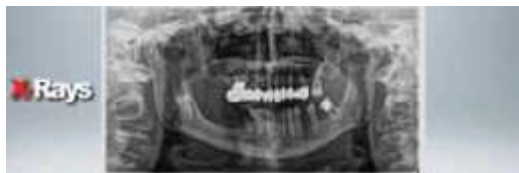
## Descrizione del caso

Paziente di sesso femminile, età 60 anni, si è presentata presso la nostra struttura lamentando difficoltà alla masticazione, mobilità degli elementi dentali dell'arcata superiore, mancanza di alcuni elementi dentali nell'arcata inferiore ed esprimendo il desiderio di migliorare l'estetica del suo sorriso. All'anamnesi non si registravano patologie di rilievo e la paziente riferiva di fumare circa 20 sigarette al giorno. All'esame clinico e radiografico si

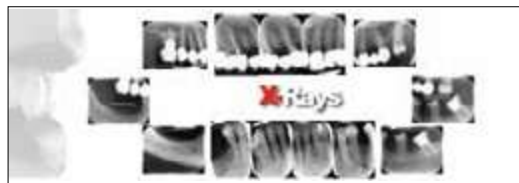presentava un quadro di parodontopatia cronica diffusa con mobilità dei monconi protesici dell'arcata superiore. L'arcata inferiore mostrava un quadro parodontopatico meno grave con assenza degli elementi 3.4, 3.6, 3.7, 4.4, 4.6, 4.7 (figg. 5 e 6). La paziente ha rifiutato di sottoporsi ad interventi di rigenerazione ossea, pertanto il piano di trattamento elaborato ha previsto per l'arcata superiore una riabilitazione implantoprotesica, estraendo gli elementi dentali compromessi ad eccezione dei due canini che sono stati mantenuti anche nella protesizzazione definitiva. Nell'arcata inferiore, considerando lo spessore esiguo della cresta, la ridotta altezza ossea e la richiesta esplicita della paziente di non volersi sottoporre ad ulteriori interventi, si è deciso di recuperare dal punto di vista parodontale gli elemen-



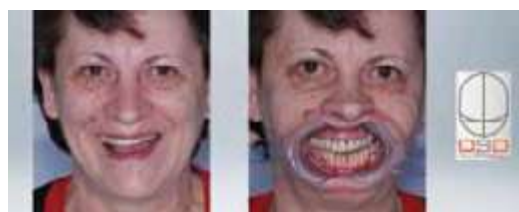## CASO CLINICO



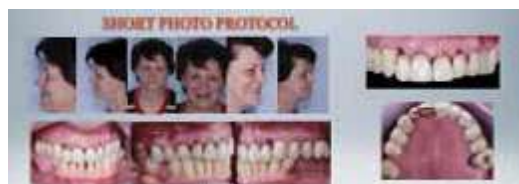**Fig. 5**  
Ortopantomografia iniziale.



**Fig. 6**  
Full radiografico.



**Fig. 7a, 7b e 7c**  
Documentazione fotografica iniziale.



ti dentari residui ed eseguire un riabilitazione protesica fissa.

La progettazione del caso clinico è stata eseguita mediante l'utilizzo del Digital Smile Design, con l'impiego della piattaforma Mac OS X e del programma Keynote. Le fotografie ed i video raccolti (figg. 7a, 7b e 7c) sono stati scaricati e inseriti nella presentazione di Keynote, quindi si è proceduto all'analisi estetica digitale del volto e del sorriso ed all'elaborazio-

ne virtuale della riabilitazione protesica, utilizzando delle smile library, costituite da prototipi di denti, di forma e dimensioni diverse.

Il primo passo è stato quello di tracciare sulla foto extraorale frontale del paziente una linea orizzontale ed una verticale. L'immagine viene centrata, spostata e ruotata fino a quando la linea bipupillare diventa orizzontale, successivamente viene definita la linea mediana del viso.

Vengono misurate le proporzioni corrette e disegnate le linee ai margini di ogni dente anteriore, l'asse dei denti, i contorni delle labbra e la linea del sorriso. Successivamente il progetto virtuale viene inviato al laboratorio; rilevate le impronte delle arcate dentarie del paziente, viene fabbricato un modello in gesso sul quale viene modellata la nuova sagomatura dei denti corrispondente allo studio eseguito con lo Smile Design. Su questo modello cerato viene poi stampata una mascherina di silicone, che fungerà da stampo per fabbricare la mascherina in resina acrilica che il paziente indosserà direttamente sui propri denti, visualizzando immediatamente quello che sarà il risultato estetico finale.

Sulla base del mock-up e delle modifiche ad esso apportate, vengono realizzati dapprima i provvisori ed infine il manufatto protesico definitivo (figg. 8a-8h).

#### Procedure chirurgiche e protesiche

Previa bonifica degli elementi dentari dell'arcata superiore, ad eccezione degli incisivi centrali e dei canini, si procede all'inserimento degli impianti sommersi (Winsix, Biosafin) in posizione 1.2, 1.4, 1.5 e 2.2, 2.4, 2.5 (figg. 9 e 10). I lembi vengono suturati con filo in seta 4/0. Subito dopo la fase chirurgica, si ribasa un provvisorio armato in resina acrilica precedentemente preparato sulla base della ceratura diagnostica e del progetto virtuale (DSD), che viene cementato sugli elementi dentari residui (figg. 11 e 12).

Nell'arcata inferiore vengono preparati i monconi protesici che supporteranno un provvisorio in resina acrilica precedentemente preparato.

La paziente viene così dimessa con terapia farmacologica di supporto antibiotica e antidolorifica e le suture rimosse dopo 7 giorni. Dopo 4 mesi dalla fase chirurgica, stabilizzati i tessuti ed avvenuta l'osteointegrazione, si procede alla riapertura degli impianti ed all'avulsione degli incisivi centrali, quindi vengono prese le impronte e si procede al confezionamento di un secondo provvisorio a supporto implantare (figg. 13 e 14). A distanza di 6 mesi dal secondo provvisorio vengono prese le



CASO CLINICO

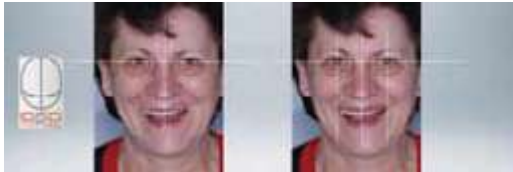

Fig. 8a Virtual Planning.

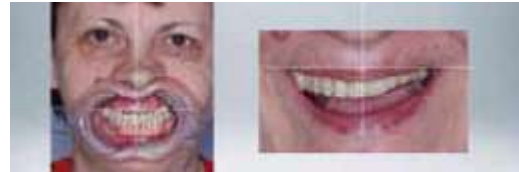

Fig. 8b Virtual Planning.

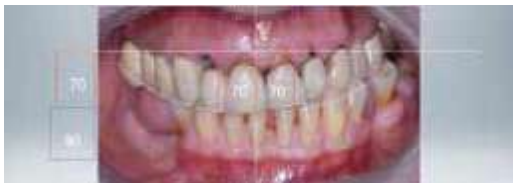

Fig. 8c Virtual Planning.

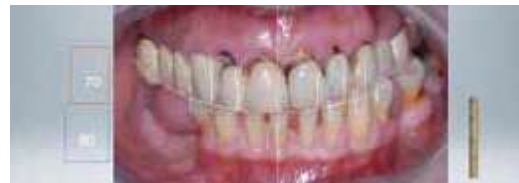

Fig. 8d Virtual Planning.



Fig. 8e Virtual Planning.

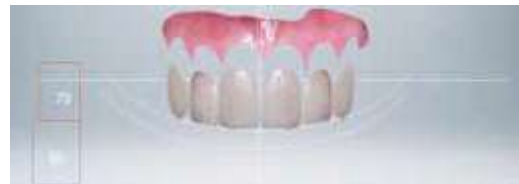

Fig. 8f Virtual Planning.

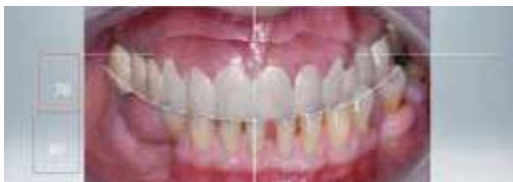

Fig. 8g Virtual Planning.

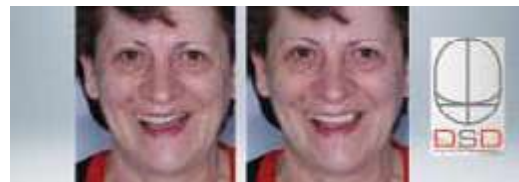

Fig. 8h Analisi prima/dopo.

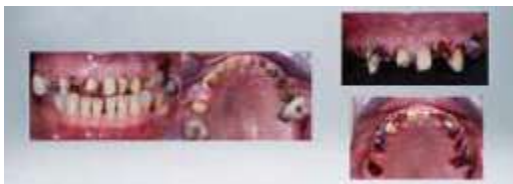

Fig. 9 Avulsione degli elementi dentari ed inserimento degli impianti.

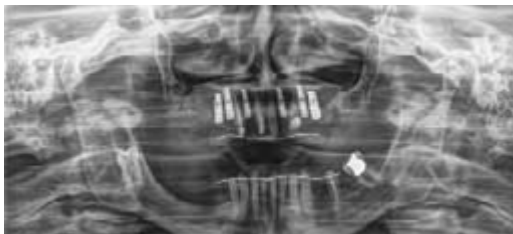

Fig. 10 Ortopantomografia postoperatoria.

impronte definitive e viene realizzata una struttura in lasermelting e ceramica nell'arcata superiore, in zirconia nell'arcata inferiore. Le strutture sono realizzate sovrapponendo con il CAD i provvisori alle impronte definitive (figg. 15-19).

**DISCUSSIONE**

Per individuare il piano di trattamento e i risultati clinici, l'odontoiatra deve discutere con il paziente una serie di fattori, tra cui le aspettative personali riguardo al risultato estetico e funzionale, la prognosi a lungo termine, il numero di denti interessati ed il materiale restaurativo da impiegare.

## CASO CLINICO



Fig. 11 Ceratura diagnostica.

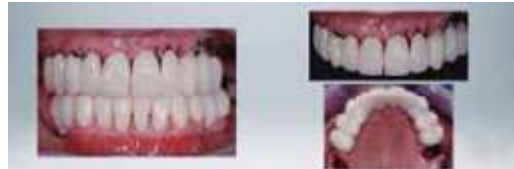

Fig. 12 Primo provvisorio post chirurgia.

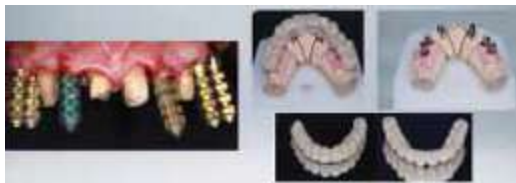

Fig. 13 Impronte degli impianti osteointegrati.

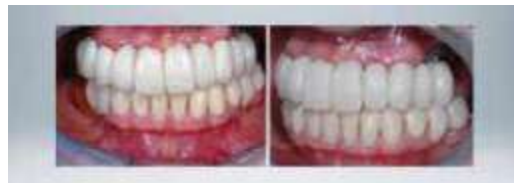

Fig. 14 Secondo provvisorio a supporto implantare.

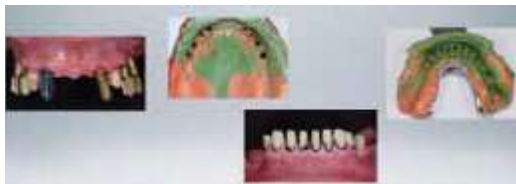

Fig. 15 Impronte per realizzazione del definitivo.



Fig. 16 Elaborazione CAD.

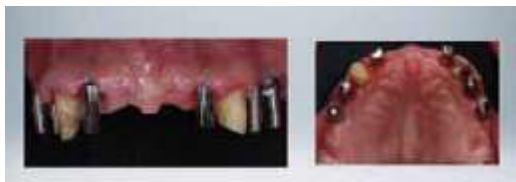

Fig. 17 Situazione intraorale con monconi definitivi.

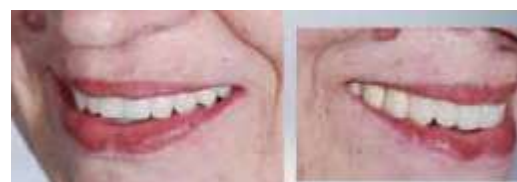

Fig. 18a e 18b Finalizzazione protesica.

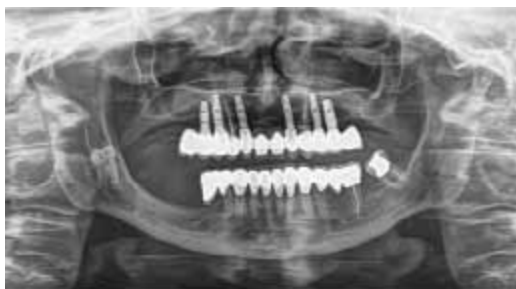

Fig. 19 Ortopantomografia finale.

Il Digital Smile Design rappresenta quindi uno strumento per migliorare la comunicazione con il paziente, considerando il

fatto che, proprio attraverso l'uso di immagini elaborate, sarà possibile vedere sul monitor digitale le fotografie prima/

dopo, indice di predicibilità ed elemento di confronto esplicito con il paziente stesso. L'utilizzo del DSD può essere

## CASO CLINICO

fatto in odontoiatria estetica adesiva, in protesi, ortodonzia, parodontologia ed implantologia.

## CONCLUSIONI

Il caso presentato dimostra come anche nelle riabilitazioni complesse la programmazione virtuale del piano di trattamento sia uno strumento utile sia per l'odontoiatra, che riesce in questo modo a trasmettere più informazioni possibili e dettagliate al proprio odontotecnico, sia per il paziente, che riesce ad avere in anteprima un'idea precisa del timing operativo e di quale sarà il risultato finale del trattamento a cui si sottoporrà, interagendo in maniera esplicita con l'odontoiatra. Il risultato estetico finale ottenuto, nel caso in questione, è sovrapponibile al progetto virtuale iniziale e dimostra pertanto che il DSD è un valido strumento anche in implantologia. ●

## AIM OF THE WORK

Digital Smile Design (DSD) is a computer programme for treatment planning based on photographs and videos of the patient. Modern digital technology combined with experience and aesthetic sensitivity of the dentist is the basis of the success of DSD in predicting the final aesthetic result and planning the procedures. DSD is a tool that improves communication with patients: image processing enables to show them on a digital monitor the final outcome before starting treatment, which can be better understood by the patient.

## MATERIALS AND METHODS

We report the case of a 60 years old female patient requiring an implant-supported fixed prosthesis in the upper jaw and a fixed prosthodontic rehabilitation on natural teeth in the lower jaw. The DSD protocol enabled, through the use of images and videos of the patient, to show her the dynamic phases of the smile (camouflage, pho-

netics, dental-labial relationships). The next step was the virtual planning, that is image processing, which was followed by the digital and analogic diagnostic wax-up, the mock-up and subsequently the placement of the temporary and, eventually, the final prostheses.

## RESULTS AND CONCLUSIONS

The case reported shows how, even in complex rehabilitations, virtual treatment planning is a useful tool for both the dentist, who can supply clearer and more detailed information to the dental technician, and the patient, who can better understand operative timing and the final results of the treatment, and hopefully be more compliant. The final aesthetic result of the case reported is very similar to the initial virtual plan, thus showing that DSD is a valid tool also in oral implantology.

## BIBLIOGRAFIA

1. Bini V. Analogic Transfer System Communication e Aesthetic Digital Smile Design. *Cad Cam Digital Dentistry Italy* 2014; 2.
2. Bini V. Aesthetic Digital Smile Design: odontoiatria estetica software assistita. Part 2. *Cosmetic Dentistry Int It* 2014; 1.
3. Bini V. Aesthetic Digital Smile Design: odontoiatria estetica software assistita. Part 1. *Cosmetic Dentistry Int It* 2013; 4.
4. Bini V. Bio protesizzazione cosmetica funzionale e zirconia monolitica software assistita. *Cad Cam Int Digital Dentistry* 2013; 2.
5. McLaren EA, Garber DA, Figueira J. The Photoshop Smile Design technique (part 1): digital dental photography. *Compend Contin Educ Dent* 2013 Nov-Dec; 34(10):772-6 passim.
6. Tauheed S, Shaikh A, Fida M. Microaesthetics of The Smile: Extraction vs Non-extraction. *J Coll Physicians Surg Pak* 2012 Apr;22(4):230-4.
7. Van Dooren E, Calamita M, Calgaro M, Coachman C, Ferencz JL, Pinho C, Silva NR. Mechanical, biological and clinical aspects of zirconia implants. *Eur J Esthet Dent* 2012 Winter;7(4):396-417. Review.
8. Coachman C, Salama M, Garber D, Calamita M, Salama H, Cabral G. Prosthetic gingival reconstruction in fixed partial restorations. Part 3: laboratory procedures and maintenance. *Int J Periodontics Restorative Dent* 2010 Feb.
9. Touchstone A, Nieting T, Ulmer N. Digital transition: the collaboration between dentists and laboratory technicians on CAD/CAM restorations. *J Am Dent Assoc* 2010 Jun;141 Suppl 2:15S-9S.
10. McLaren EA, Cao PT. Smile Analysis and Esthetic Design. In the zone *Inside Dentistry* 2009; 6, 7.
11. Coachman C, Van Dooren E. An integrated cosmetic treatment plan: soft tissue management and metal-free restoration. *Pract Proced Aesthet Dent* 2009 Jan-Feb;21(1):29-33.
12. Goldstein RE, Decker BC. *Esthetics in Dentistry. Vol.1: Principles, Communication, Treatment, Methods.* 1998.
13. Rufenacht CR. *Fundamentals of Esthetics.* Chicago: Quintessence; 1990.



# RICERCA CONTINUA

ANALISI RETROSPETTIVA A **9 ANNI** DEGLI ESITI DI TRATTAMENTO IMPLANTO-PROTESICO ESEGUITI CON SISTEMA WINSIX®.

Autori: Unità Operativa di Odontoiatria - Università Vita - Salute San Raffaele di Milano, dir. Prof. Enrico F. Gherlone

**Materiali e Metodi.** Sono stati valutati 3312 impianti posizionati in 1537 pazienti tra marzo 2006 e marzo 2015 presso l'Unità Operativa Complessa di Odontoiatria dell'I.R.C.C.S. Ospedale San Raffaele di Milano. Di questi impianti, 2673 sono stati posizionati in 1427 pazienti che si sottopongono con regolarità a programma di mantenimento presso il Centro di Igiene Orale e Prevenzione attivo presso l'U.O.C. Odontoiatria

## (Grafico 1)

I restanti pazienti, invece, non hanno aderito al programma di mantenimento. Nei pazienti sottoposti a mantenimento è stato possibile rilevare, per ciascun impianto, l'insieme dei parametri clinici atti a valutare lo stato di salute del sito implantare: profondità di sondaggio (PPD), sanguinamento a sondaggio (BoP),

segni radiografici di evidente riassorbimento osseo perimplantare e mobilità.

**Analisi dei dati.** Sul campione di 3312 impianti, l'1,99%, pari a 66 unità posizionate in 63 pazienti, sono andati incontro a fallimento, mostrando un dato percentuale di incidenza di insuccesso allineato ai valori osservabili in letteratura

## (Grafico 2).

È stato osservato come, tra i 66 impianti falliti, 18 erano stati posizionati in soggetti dediti al tabagismo e 37 in pazienti già colpiti da parodontite. Restringendo l'analisi solo ai pazienti sottoposti a follow-up, l'incidenza di fallimento scende al valore percentuale dell'1,35%, per totali 36 impianti. Sempre tra questi pazienti, il valore medio della PPD (**Grafico 3**),

rilevato in quattro siti per ciascun impianto, si dimostra nel 84,7% dei casi < 4mm (9056 siti di sondaggio su 10692 complessivi).

Analizzando infine i dati relativi ai valori medi dell'indice di placca secondo O'Leary (PI) e di sanguinamento (BoP) nei pazienti in mantenimento, nei soggetti andati incontro a fallimento si è osservato per entrambi i parametri un valore medio nettamente più alto rispetto ai valori osservati tra coloro che invece mostrano buone condizioni di salute dei tessuti perimplantari: nello specifico, tra i pazienti in buone condizioni di salute dei tessuti perimplantari il dato medio del PI è del 16,5% e per quanto riguarda il BoP del 5,9%. Nei pazienti andati incontro a fallimento implantare i valori medi si attestano invece, rispettivamente, al 42,3% ed al 61,5% (**Grafico 4**).

**Conclusioni.** Nella ricerca del successo a lungo termine delle riabilitazioni protesiche a supporto implantare, un programma di mantenimento calibrato in base alle specifiche peculiarità del paziente risulta essere un fattore fondamentale, in quanto occasione utile a fare prevenzione della patologia perimplantare ed a intercettare in fase precoce l'insorgenza di fenomeni infiammatori dei tessuti perimplantari e/o problematiche meccaniche dell'insieme impianto-protesico.

L'abbattimento dell'incidenza di fallimento osservato in pazienti afferenti ad un tale programma di follow-up, pur in assenza di indagini relative ai fenomeni microbiologici alla base di questi risultati, può comunque essere ritenuto elemento probatorio dell'efficacia di un simile atteggiamento clinico.

#### GRAFICO 1

- Impianti in follow up
- Drop-out



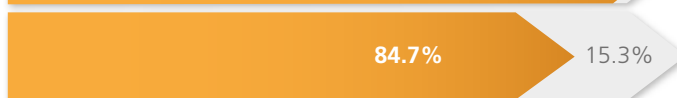#### GRAFICO 2

- Impianti in successo sopravvivenza
- Impianti falliti

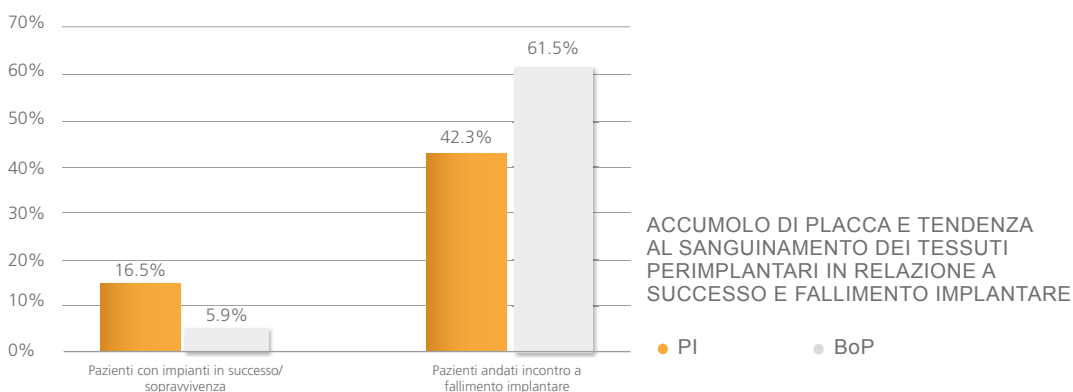


#### GRAFICO 3

- PPD<4 mm
- PPD>4 mm



#### GRAFICO 4





# JUST ON 4: 4 ANNI DOPO

## GENNAIO 2011 APRILE 2015

Autori: Unità Operativa di Odontoiatria - Università Vita - Salute San Raffaele di Milano, dir. Prof. Enrico Gherlone



**742** IMPIANTI TORQUE TYPE®  
**165** ARCADE IN TOTALE  
**137** ARCADE SINGOLE  
**28** ENTRAMBI I MASCELLARI

La tecnica Just on 4/6® (di seguito JO4/6) consente di riabilitare l'arcata edentula del paziente colpito da grave atrofia dei mascellari con una soluzione immediata full-arch a supporto implantare. L'approccio è tale da garantire una minima invasività chirurgica e una soddisfacente resa estetica del manufatto protesico avvitato, limitando il costo biologico e allo stesso tempo economico a carico del paziente.

La possibilità di utilizzare nella costruzione della protesi la barra di rinforzo CAB®, annegandola all'interno del manufatto, consente inoltre di raggiungere ottime performance in termini di resistenza

strutturale protesica sotto il carico masticatorio.

L'utilizzo sinergico di JO4/6 e CAB® ha consentito fino ad oggi il raggiungimento di risultati clinici, in termini di percentuali di successo/sopravvivenza implantari e protesiche, straordinari, incontrando la soddisfazione del paziente che, in una unica seduta, viene riabilitato con il posizionamento della protesi provvisoria.

L'impiego sistematico di questo approccio presso l'U.O.C. di Odontoiatria dell'I.R.C.C.S. Ospedale San Raffaele ha consentito, nel periodo compreso tra Gennaio 2011 ed Aprile 2015, la riabilitazione com-

piessiva di 165 arcate edentule (124 con JO4 e 41 con JO6 per totali 742 impianti) in 137 pazienti (maschi 72, femmine 65) di età media 60 anni, 28 dei quali sottoposti a riabilitazione di entrambi i mascellari.

Tutti i pazienti riabilitati secondo la tecnica JO4/6 sono stati quindi inseriti in un programma di follow-up igienico professionale che prevede l'esecuzione di sedute di profilassi a cadenza quadrimestrale, con lo smontaggio delle protesi una volta all'anno per consentire un trattamento professionale più diretto dei tessuti perimplantari.

### SUCCESSO/SOPRAVVIVENZA IMPLANTARE

Impianti Posizionati	Mancata Osteointegrazione	Impianti Riposizionati	Sopravvivenza	Successo
742	12	12	100%	98,39%

### COMPLICANZE PROTESICHE

	Tipologia	Incidenza	Sopravvivenza	Successo
Senza CAB®	frattura di 5 protesi provvisorie	14,7%	100%	85,3%
Con CAB®	nessuna	0	100%	100%



**CONSIDERAZIONI** Dall'analisi dei dati estratti dalle cartelle cliniche dei pazienti sottoposti a riabilitazione JO4/6 è stato possibile stabilire che la sistematica ha prodotto un tasso di sopravvivenza implantare pari al 98,39% (fallimento 1,61%, pari a 12 impianti). I casi di fallimento implantare sono avvenuti tutti in fase precoce, verosimilmente per mancata realizzazione di osteointegrazione, cui ha fatto seguito il riposizionamento di nuovi impianti che hanno raggiunto la funzionalità.

Delle complessive 165 arcate protesiche, 34 non sono state

armate internamente con barra CAB®. Di queste, 5 provvisorie sono andate incontro a frattura, successivamente riparate. Nessuna arcata realizzata con armatura CAB® ha sofferto di fratture. Alla luce di questi dati possiamo stabilire un successo protesico del 100% nei casi di protesi realizzate su CAB® (131 arcate) e dell'85,3% per le protesi sprovviste della barra, che comunque incontrano un tasso di sopravvivenza del 100%.

Sotto il profilo del mantenimento professionale del paziente sottoposto a riabilitazione JO4/6, nessun impianto risulta colpito

da perimplantite. E' tuttavia da sottolineare in tal senso l'importanza di un corretto design protesico, che faciliti la detersione domiciliare delle superfici della protesi prospicienti l'osteomucosa, e l'impiego delle più avanzate tecnologie applicate all'igiene orale professionale, come i dispositivi di air polishing per l'utilizzo sopragengivale e nel solco perimplantare e gli scalers ultrasonici in materiali plastici, che si dimostrano efficaci ma rispettosi dei materiali impianto-protesici.

#### BIBLIOGRAFIA

Gherlone EF, Ferrini F, Crespi R, Gastaldi G, Capparé P. Digital Impressions for fabrication of definitive "all-on-four" restorations. *Implant Dent.* 2015 Feb;24(1):125-9. doi: 10.1097/ID.0000000000000206.

Gherlone EF, Pasi M, Polizzi E, Crespi R, Capparé P. Edentulous patients rehabilitated according to the "all on four" procedure with prefabricated bar system. *Quintessence Int* 2015, in submission.

Agliardi EL, Pozzi A, Stappert CF, Benzi R, Romeo D, Gherlone E. Immediate fixed rehabilitation of the edentulous maxilla: a prospective clinical and radiological study after 3 years of loading. *Clin Implant Dent Relat Res.* 2014 Apr;16(2):292-302. doi: 10.1111/j.1708-8208.2012.00482.x. Epub 2012 Aug 9.

Crespi R, Vinci R, Capparé P, Romanos GE, Gherlone E. A clinical study of edentulous patients rehabilitated according to the "all on four" immediate function protocol. *Int J Oral Maxillofac Implants.* 2012 Mar-Apr;27(2):428-34.

Agliardi EL, Romeo D, Wenger A, Gastaldi G, Gherlone E. Immediate rehabilitation of the posterior maxilla with extensive sinus pneumatization with one axial and one trans-sinus tilted implant: A 3-year clinical report and a classification. *J Prosthet Dent.* 2015 Mar;113(3):163-8. doi: 10.1016/j.prodent.2014.07.017. Epub 2014 Nov 25.



CASO CLINICO DEL MESE

# Riabilitazione estetica complessa in paziente con esiti di fallimento implantare

✉ angelo\_cardarelli@libero.it



Angelo Cardarelli,  
Filippo Cardarelli,  
Romeo Pascetta,  
Raffaele Vinci

Dipartimento di Odontoiatria, IRCCS  
Ospedale San Raffaele, Milano  
Direttore: Prof. E.F. Gherlone

Corso di Laurea in Odontoiatria  
e Protesi Dentaria  
Università Vita-Salute  
San Raffaele, Milano  
Presidente:  
Prof. E.F. Gherlone



**FIG. 1**

Ortopanoramica iniziale.

**FIG. 2**

Situazione iniziale, visione frontale: presenza di fistole in corrispondenza degli elementi dentari residui, incongruità del manufatto protesico.

**FIG. 3**

Situazione iniziale dopo rimozione del manufatto protesico.

**FIG. 4**

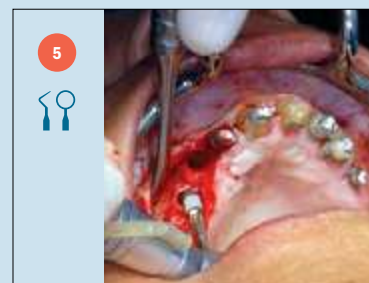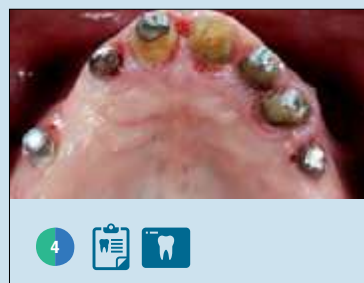
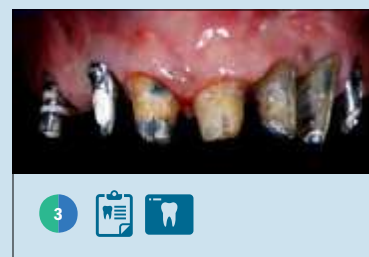
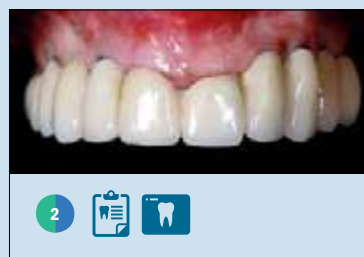
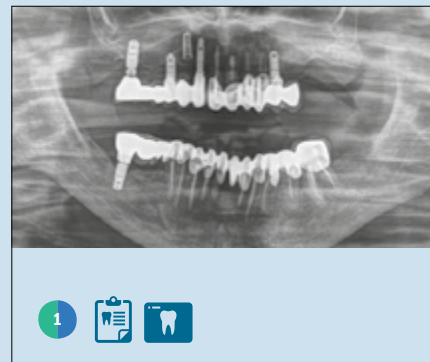
Situazione iniziale, visione occlusale.



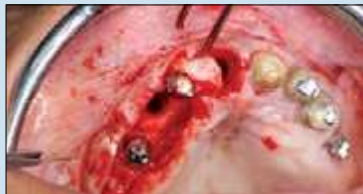**FIG. 5**

Inserimento impianti.

Il presente caso clinico descrive la riabilitazione implantoprotesica mascellare di una paziente in esiti di fallimento implantare con grave compromissione degli elementi dentari residui. Si decide pertanto di rimuovere gli impianti non osteointegrati mantenendone solo alcuni, inserendone altri con carico immediato previa bonifica degli elementi dentari residui. Viene realizzata quindi una riabilitazione fissa a supporto implantare. Il risultato estetico finale dimostra un'ottima guarigione e gestione dei tessuti molli.



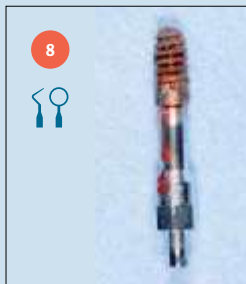
CASO CLINICO DEL MESE



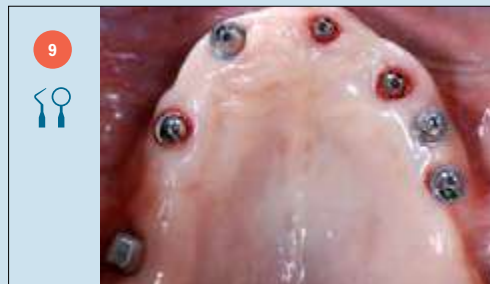6



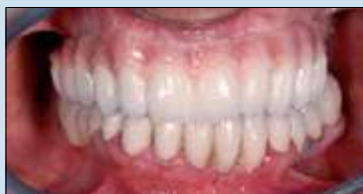7



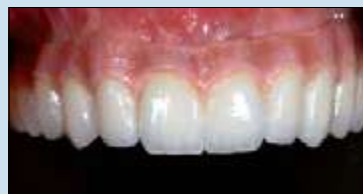8



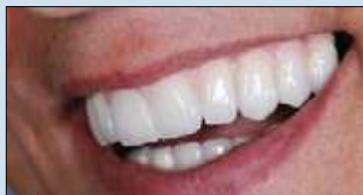9



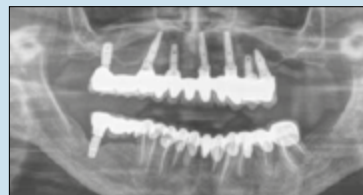10



11



12



13

**FIG. 6**

Innesto connettivale perimplantare; vengono mantenuti gli impianti osteointegrati.

**FIG. 7**

Estrazioni dei denti residui, rimozione ed inserimento di nuovi impianti con carico immediato.

**FIG. 8**

Rimozione impianti non osteointegrati.

**FIG. 9**

Guarigione a 6 mesi.

**FIG. 10**

Finalizzazione protesica.



**FIG. 11**

Situazione finale.

**FIG. 12**

Situazione finale extraorale.

**FIG. 13**

Ortopanoramica finale.

LEGENDA



diagnosi



studio



trattamento



controllo

% IMG

15%

15%

50%

20%



## ABSTRACT

**Digital planning and surgery with RealGUIDE™ workflow: the ultimate image based procedure for a successful immediate loading rehabilitation**

M. Manacorda <sup>1</sup>, A. Merlone <sup>1</sup>, F. Bova <sup>1</sup>, R. Pagani <sup>2</sup>, G. Gastaldi <sup>1</sup>, R. Vinci <sup>1</sup>

<sup>1</sup>Department of Dentistry, IRCCS San Raffaele Milano and Dental School, Vita-Salute University, Milan, Italy

<sup>2</sup>Maxillofacial Unit, Carlo Poma Hospital, Mantova, Italy

**Aim.** More than 20 programs offers today methods for virtual implant planning on TC images. The great diffusion of CBCT exam enables the 3D diagnosis on most of the patients due to its low radiation exposure compared to the standard CT, giving the doctors the possibility to integrate the standard bidimensional diagnosis with a digital 3D reconstruction and implant planning.

Computer-assisted implanto-prosthetic planning allows the morphological, functional and aesthetic study of teeth and maxillofacial bones, with the aim of planning an implantsupported dentoalveolar prosthesis. The scientific literature reports many studies about different methods and their accuracy in computer guided surgery techniques, explaining the possible errors occurring in the workflow.

Most of the digital prosthetics planning techniques anyway are based on high level technologies that are generally owned by the industry, giving the surgeons and laboratories just a partial control over the full process. The scope of this article is to illustrate a procedure that uses the most advanced technologies, both for planning and manufacturing, but differently from the others it can be fully managed in a seamless workflow between the doctor and the laboratory. In the following paragraphs the technique, as well as the application on two real surgical cases will be illustrated.

**Methods.** The "RealGUIDE" procedure (3DIEMME, Italy) is described:

1. PATIENT DIAGNOSIS AND PROSTHETIC PLANNING: considered as a guideline for the final rehabilitation, can be developed through conventional stone models into articulation or by modern dental laboratory software.

2. RADIOLOGIC GUIDE SET-UP: the correct teeth position obtained with the previous step is clinically checked with a diagnostic prosthesis and transferred to a radiologic guide that the patient should wear during the CBTC exam.

3. OPTICAL SCANNING AND CT/CBCT EXAM: the patient is scanned wearing the radiologic guide with a single scan protocol with the 3DMarker in the acquisition volume. The results are exported in standard DICOM format.

4. DATA FUSION: all the files are imported in the medical imaging software (3Diagnosys 4.0, 3DIEMME, Italy) that is able to match optical STL and Dicom files.

5. IMPLANT PLANNING: implant position is performed using the library, also the prosthetic connection is completed for a real prosthetic guided implantology.

6. SURGICAL GUIDE MODELLING: the project is exported into the guide modelling software, then it's possible to generate automatically both the surgical guide and the real model.

7. PROSTHESIS MODELLING AND MANUFACTURING: after design, the prosthesis is made with CAD/CAM technology for an immediate loading.

**Results.** The proposed method, as reported in the case studies presented, aims to demonstrate how the digital workflow in dentistry can be employed in a seamless pro-

cedure between the surgery and the laboratory environments. The use of an open system enables the project exchange between different software packages and the resulting objects manufacturing with any CAD/CAM or RP machine. In particular the use of the stereolithographic technology used for manufacturing (DWS, Italy), thanks to the possibility of using different materials on the same machine, enables the laboratory to produce all the objects needed (models, guides and provisionals) directly in-house with very low time and cost for production.

**Conclusion.** The use of diagnostic softwares and stereolithographic technology enables the laboratory to produce models, surgical guides and provisionals directly in-house, and plan a miniminvasive surgery for the immediate loading protocol on.

### Edentulous patients rehabilitated according to the "all-on-four" procedure with prefabricated bar system

P. Capparé<sup>1,2</sup>, M. Pasi<sup>1,2</sup>, G. I. Di Domenico<sup>2</sup>, I. Cisternino<sup>2</sup>, E. Polizzi<sup>1,2</sup>, R. Crespi<sup>1,2</sup>

<sup>1</sup>Department of Dentistry, IRCCS San Raffaele Hospital, Milan, Italy

<sup>2</sup>Dental School, Vita-Salute University, Milan, Italy

**Aim.** the aim of this clinical study was to evaluate a new type of prefabricated bar system, supported by axial and tilted implants in patients with completely edentulous jaws at 1year follow-up.

**Methods.** Patients edentulous in one or both jaws, with severe atrophy of the mandible or maxilla in posterior regions, were randomly selected for this study. Complete-arch immediately loaded prostheses supported by 4 implants (2 axial and 2 tilted) were placed. After the surgical procedure, according to the "all-on-four" protocol, angulated abutments (Extreme Abutment, EA® Winsix, Biosafin, Ancona, Italy) were set at either 17° for anterior implants and, at 30° those for posterior implants, to compensate for the lack of parallelism. Pickup impressions of the implants were made at the conclusion of the surgery, an interocclusal registration was performed using the prefabricated prosthesis.

On master cast, Clip Abutment Bar adapters (CAB®, Winsix, Biosafin, Ancona, Italy) were connected to each fixture analog and the inter-implant distance was measured. The height of the adapters was 3 mm and 1 mm, respectively parallel with occlusal plane. The tube bar was then inserted into the cutting tool and cut to correct length using the cutting disc. The bar assembly was then connected to the implant adapters and torqued into place. No soldering were performed, the universal nature of the ball joint allows the tube bar to be located in the horizontal plane in a truly stress free alignment.

Follow-up visits were performed at 3, 6, and 12 months after implant insertion. Radiographic assessments were made using panoramic radiographs obtained immediately after surgery and at each follow-up visit. Bone level measurements were reported at 6 and 12 months, and bone loss around the upright and tilted implants was compared by means of a Student t test.

**Results.** Thirty patients were randomly selected for this study. They were treated with immediately loaded 34 complete-arch prostheses (13 maxillary and 21 mandibular region) supported by 4 implants (in total 136 implants). The 12-month overall implant survival rate was 100% for axially positioned implants and 97.95% for tilted implants. The implant survival rates were 100% in the maxilla and 97.92% in the mandible. None of the 34 fixed prostheses were lost during the observation period, representing a prosthetic survival rate of 100%. No statistically significant differences ( $P>0.05$ ) in crestal bone loss between tilted and upright implants was detected at 6 and 12-month follow-up evaluation in either jaw.

**Conclusion.** This clinical study bear the risk of implant failure is therefore significantly reduced for prefabricated bar "all on four" immediate prosthetic rehabilitation, however more long-term prospective clinical trials are needed to affirm the effectiveness of the surgical-prosthetic protocol



## ABSTRACT

**Implant-supported prosthetic rehabilitation in a patient with infiltrating epidermoid carcinoma of the tongue**

N. D'Ovidio, N. Verza, L. S. Martinez, R. Franco, M. Miranda  
*Medicina Traslazionale, Roma*

**Aim.** This study wants to show the more suitable therapeutic choices for the prosthetic rehabilitation which can improve the health and quality of life of patients suffering with oral carcinoma. The profound alteration in both soft and hard tissues of these patients represents indeed an important clinical challenge for a correct prosthetic rehabilitation.

We will depict how these difficulties can be overcome using endosseous dental implants.

**Methods.** The case refers to a 70-year-old Caucasian woman with a right hemiglossectomy's history, caused by an infiltrating epidermoid carcinoma, came to our ward for a new prosthetic rehabilitation. The patient presented a total edentulia in lower dental arch, a reduced mandible bone density and the interrelated total lack of lingual and vestibular fornix. After considering her previous expositions to a radiotherapy treatment and after making multidisciplinary valuation about her generally compromised health status, the implant-supported prosthesis rehabilitation was carried out with an overdenture medical device supported by two implants, Blosafin Winstix 3,8 mm x 11 mm internal hexagon, placed in the interforaminal area, based on locator.

**Results.** The functional rehabilitation is an essential point in the treatment of patients suffering with oral carcinoma, especially when physical functions are related with the patient quality of life. When missing teeth are not replaced with prosthesis, the quality of social patient's life can get worse both for healthy and oncological patients. In oncological patients the prosthetic rehabilitation frequently presents a variety of problems due to both their post oncological anatomic conditions, and to their predisposition to undergo other surgical invasive operations. In this clinical case, the prosthetic rehabilitation inserting only two osseointegrated implants provided the achievement of all therapeutic objectives: it guaranteed a perfect physical function and good aesthetic results but it did not weigh on the already compromised patient condition. The management of the prosthetic rehabilitation and the achievement of good functional/aesthetic results is as important as the management of the disease. The correct functions of speech, mastication and swallowing allow the patient an adequate standard of living. This modern dental treatment confers a great importance to these functional factors in order to reach optimal results.

**Conclusion.** After making multidisciplinary valuations, we can say that this kind of implant-supported rehabilitation could be also reliable for those patients with several systemic disease caused by the treatment with radiotherapy and chemotherapy. We can reach good and suitable results just applying simple implant-prosthetic solutions even in patients with systemic or local physical problems, and even in patients who cannot economically afford or physically/psychologically tolerate this therapy. The patients and we declare us satisfied with the results of this treatment.

### Five-year retrospective analysis of implant-prosthetic treatment with Winsix implant system

F. Bova, R. Iozzo

Università Vita-Salute San Raffaele, Corso di Laurea in Igiene Dentale; U.O.C. Odontoiatria, Centro di Igiene Orale e Prevenzione, IRCCS Ospedale San Raffaele, Milano

**Aim.** Implant-prosthetic techniques allows to restore function and aesthetic of edentulous areas with high expectation of long-term success percentage, which in literature is about 90-95%. The achievement of these results is related to the use of valid materials and surgical and prosthetic protocols. However, current dental implants may occur in mechanical and/or biological complications, that could lead to a failure of rehabilitation. The early intercept of any of these issues is essential to ensure the durability of rehabilitation. Aim of this study is to evaluate the health of the implant sites at 5 years from the functional loading in patients placed in maintenance program at the Centre for Oral Hygiene and Prevention - U.O.C. Dentistry - I.R.C.C.S. San Raffaele Hospital, by monitoring over time of appropriate technical and clinical parameters.

**Methods.** In 2009, were placed 412 Winsix implants in 160 patients. Of these 160 patients, 85 were then included in the maintenance program at the Centre for Oral Hygiene and Prevention, enabling the monitoring of a total of 218 plants. Consulting the surgical registers of UOC Dentistry, medical records on paper and digital medical records, were collected and analyzed relevant parameters to describe the implant health status.

**Results.** Based on the data collected in the sample under examinations, the five-year survival rate is evaluated in 97.71%, then only the 2.21% of the implants lost the osseointegration. These data are in agreement with those reported in literature, which confirmed the reliability of the implant-prosthetic procedures. In observed failure cases, has been identified the role of the know nrisk factors for the development of peri-implant complications. In summary, it was established that, after 5 years of function, 16 implant sites were affected by peri-implantitis and 29 implants were positive to BOP. 5 implants are failed: with regard to the role of risk factors 3 failed implants were placed in patients with periodontitis, two of which are also smokers, and 1 in a smoker.

**Conclusion.** The analysis of collected data suggest that implant failure could be caused by inadequate plaque control in both professional and home environments. For these reasons the maintenance protocol for implant-prosthetic rehabilitation actually in use at the Centre for Oral Hygiene and Prevention, is based on the time variable because of the need to periodically reinforce the motivation of patients to maintain high levels of oral hygiene and to be able to monitor the state of health of the implant sites, looking for any signs that may presage mechanical or biological complications. The clinical experience matured at the Centre for Oral Health and Prevention has also shown that this approach also allows to detect late complications related to prosthetic superstructure, like loosening or unscrewing of the components.

### Application of innovative technologies in aesthetic fixed prosthodontic

F. Cattoni <sup>1</sup>, F. Ferrini <sup>1</sup>, M. Manacorda <sup>1</sup>

<sup>1</sup>Department of Dentistry IRCCS San Raffaele Hospital, Milan, Italy, Dental School Vita-Salute San Raffaele University, Milan, Italy

**Aim.** Aesthetics of the cranio-facial district is a discipline that deals with the recovery of the patient's functions and natural harmony of hard and soft tissues.

In detail, the aesthetics of the mouth aims for the same goal, with the same care: the restoration of function, in respect of the natural dental-tissue harmony. Purpose of this work is the evaluation of the applicability in an aesthetic perspective of new technologies, sequentially applied to a single case report, in order to verify the clinical efficiency of these technologies, since the diagnostic to the end of the treatment.

**Methods.** For diagnostic and therapeutic planning we used the Dental digitized design technique (Digital Smile Design), followed by a traditional objective and functional evaluation to confirm the diagnostic project. So we used a Laser Soft Tissue Design through the surgical protocol: 980 nm laser diode, previously enabled optical fiber 300 micron, continuous wave 2 watts power, putting the instrument at 90 degrees from the tissue's surface.

Then we took an optical impression using an Intraoral Scanner (Carestream).

The technical construction of the prosthodontic elements was processed via CAD/CAM.

The patient is an adult, female, 24 years old, who needs restoration of the natural elements 11 and 21, for both functional and aesthetic purpose. The element 11 is not vital, already reconstructed and needs an aesthetic crown in Lithium disilicate adhesively cemented. For the element 21, which is vital, an adhesively cemented Lithium disilicate aesthetic veneer was planned.

**Results.** The clinical case has been dealt with innovative methods and there has been a good match of the digital design with the functional and aesthetic needs of the patient, both verified in the oral cavity in the provisional as well as in the definitive stage. The result has been an ideal healing of the tissues post laser guided surgery and precision in the ultimate artifacts.

**Conclusions.** The use of new digital and surgical technologies both in diagnostics and through the treatment, aims to maximize the final result, prosthetically as well as aesthetically.



- 1 Equine and porcine bone substitutes in maxillary sinus augmentation: a histological and immunohistochemical analysis of VEGF expression**  
S. Tetè, V.L. Zizzari, R. Vinci, S. Zara, U. Di Tore, M. Manica, A. Cataldi, C. Mortellaro, A. Piattelli, E. F. Gherlone - The Journal of Craniofacial Surgery 2014 - May;25(3):835-9. doi: 10.1097/SCS.0000000000000679

---
- 2 Maxillary Sinus Augmentation with Autologous and Heterologous Bone Graft: A Clinical and Radiographic Report of Immediate and Delayed Implant Placement**  
M. Santagata, U. Tozzi, G. Tartaro, V. Santillo, C. Giovanni, E. Lamart, A. Iтро, G. Colella  
Journal of Maxillofacial and Oral Surgery (Oct-Dec 2014) 13 (4):401-408 - DOI 10.107/ s12663-013-0569-5

---
- 3 Seven - years retrospective analysis of implant - prosthetic treatment with Winsix® Implant System**  
P. Capparè, F. Bova, D. Defilippi, E.M. Polizzi, E.F. Gherlone Minerva Stomatologica 2014; 63(4, Suppl.1): 241

---
- 4 Connection between prosthetic overimplant mesostructures and abutments, precision performance using different realization techniques - a preliminary study**  
M. Manacorda, D. Defilippi, A. Ligabue, G. Gastaldi, R. Vinci - Minerva Stomatologica 2014; 63 (4, Suppl. 1): 210

---
- 5 Treatment options in cases of misplacement implant**  
A. Cardarelli, A. Ligabue, D. Defilippi, R. Vinci Minerva Stomatologica 2014; 63 (4, Suppl. 1): 251

---
- 6 Rehabilitation of atrophic maxilla with a minimally invasive technique**  
F. Ferrini, M. Manacorda, A. Cardarelli, P. Capparè, R. Vinci - Minerva Stomatologica 2014; 63 (4, Suppl. 1 ): 236

---
- 7 Analisi retrospettiva con follow-up massimo a sette anni di riabilitazioni implantoprotesiche con Sistemica WINSIX®**  
P. Capparè, F. Bova, D. Defilippi, E.M. Polizzi, E.F. Gherlone - Corso di Laurea in Igiene Dentale, Università Vita Salute - San Raffaele, Milano - Poster Scientifico presentato al Collegio dei Docenti - Milano 2014

---
- 8 Newsletter Biosaf In: analisi retrospettiva a 8 anni degli esiti di trattamento implanto-protesico eseguiti con Sistema WINSIX®**  
Autori: Unità Operativa di Odontoiatria - Università Vita - Salute San Raffaele di Milano, dir. Prof. E.F. Gherlone



## ORIGINAL ARTICLE

## Equine and Porcine Bone Substitutes in Maxillary Sinus Augmentation: A Histological and Immunohistochemical Analysis of VEGF Expression

Stefano Tetè, MD, DDS,\* Vincenzo Luca Zizzari, DDS,† Raffaele Vinci, MD, DDS,‡ Susi Zara, PhD,† Umberto Di Tore, DDS,\* Marco Manica, DDS,§ Amelia Cataldi, MD,† Carmen Mortellaro, MD, DDS,||¶ Adriano Piattelli, MD, DDS,\* and Enrico Gherlone, MD, DDS‡

**Abstract:** The aim of this work was to investigate the morphological structure and the expression of vascular endothelial growth factor (VEGF) after maxillary sinus augmentation through equine and porcine bone substitutes in humans.

Ten patients showing edentulous posterior maxilla underwent maxillary sinus augmentation through particulate equine bone substitute and 10 patients through particulate porcine bone substitute. At the moment of implants insertion, 6 months after grafting, bone specimens were withdrawn and processed for morphological and immunohistochemical analyses.

Notwithstanding the almost comparable clinical performances of both bone substitutes, histological results showed a better integration when an equine bone substitute was used compared to a porcine one. In particular, evident signs of particles resorption were observed in equine bone substitute group specimens compared to porcine ones. Immunohistochemical analysis showed a statistically significant increase of VEGF expression in equine compared to porcine bone substitute group specimens.

These results showed both bone substitutes to achieve comparable clinical performance, indicating their successful use for bone regenerative procedures. However, in the same experimental time, equine group specimens showed evident resorption phenomena, whereas no or little signs of resorption were evident in the porcine group specimens. However, a more rapid and intense vascularization was achieved in equine bone substitute group, as demonstrated by immunohistochemical analysis for VEGF expression. Even if differences in vascularization significantly affect the clinical performance of a heterologous bone substitute, its ability to be resorbed is also very important in influencing long-term integration and long-term predictability of implant-prosthetic rehabilitation in regenerated sites.

**Key Words:** Equine bone substitute, porcine bone substitute, maxillary sinus augmentation, immunohistochemical analysis, VEGF

(*J Craniofac Surg* 2014;25: 835–839)

To allow implant-supported rehabilitation of edentulous ridges affected by severe bone atrophy, bone regeneration procedures are often necessary. Especially in the posterior maxilla, after teeth extraction, alveolar bone undergoes remodeling phenomena together with maxillary sinus hyperpneumatization, resulting in an insufficient bone height to ensure stability to implant insertion.<sup>1</sup> A classification of residual bone in the posterior maxilla was introduced with the purpose of considering, besides the width and the height of the residual alveolar bone, also the relationship between upper and lower jaw after the remodeling phenomena take place.<sup>2</sup> To correct severe bone defects when the intermaxillary relationship is maintained and to have suitable prosthetic results, maxillary sinus augmentation procedure represents a valid treatment solution.<sup>3,4</sup> In recent years, different materials have been proposed and used to ensure bone regeneration through grafting the maxillary sinus: intraoral or extraoral autologous bone, homologous grafts, heterologous grafts, alloplastic grafts, or a combination of these.<sup>5–8</sup> Autologous bone graft is still considered the gold standard for bone regeneration. However, the morbidity involved with its use may induce many patients to refuse this treatment. Instead, different heterologous bone substitutes were utilized for sinus augmentation.<sup>9</sup> As previously reported, heterologous biomaterials were found to be as clinically efficient as autologous bone for their osteoconductive potential, though not much is known about their capability to be fully resorbed or about the time they need to be entirely substituted by newly formed bone.<sup>7</sup> As the biological response of the host tissue can be related to the biomaterial derivation and to the treatment it underwent before its clinical use, attention was addressed on the interactions occurring between bone substitutes and host tissue.<sup>9–11</sup> Different heterologous biomaterials have been proposed for clinical use in oral surgery; bovine-derived bone substitutes represent one of the most popular and well-documented categories. They were described to have osteoconductive properties and to be well integrated in host bone tissue as shown in both *in vitro* histological and clinical studies.<sup>12</sup> However, the possibility of prion disease transmission associated with the use of this source of heterologous bone led to other different sources for bone substitutes.<sup>13,14</sup> In literature, few data are reported concerning the use of equine or porcine bone substitutes. Recent studies described equine-derived bone as being able to induce osteoblast differentiation, to be resorbed *in vitro* by osteoclasts, and to be successfully used in mandibular ridge augmentation.<sup>15,16</sup> On the other hand, porcine-derived bone may be successfully used to obtain osteogenesis in guided bone regeneration techniques.<sup>17,18</sup> Independently by their derivation, all bone substitutes from a non-human mammal species must undergo a series of deantigenation processes to make them suitable for clinical use by reducing antigenicity

From the \*Departments of Medical, Oral and Biotechnological Sciences and †Pharmacy, University “G. d’Annunzio,” Chieti-Pescara; ‡Department of Dentistry, University “Ateneo Vita-Salute S. Raffaele,” Milan; §Pistoia (private practice); ||Department of Medical Science, Faculty of Medicine, University of Eastern Piedmont, Novara; and ¶Oral Surgery Unit, Regina Margherita Pediatric Hospital, Turin, Italy.

Received June 4, 2013.

Accepted for publication January 7, 2014.

Address correspondence and reprint requests to Stefano Tetè, MD, DDS, Department of Medical, Oral and Biotechnological Sciences, University “G. d’Annunzio,” Via dei Vestini, 31-66100 Chieti, Italy; E-mail: tete@unich.it

The authors report no conflicts of interest.  
Copyright © 2014 by Mutaz B. Habal, MD  
ISSN: 1049-2275  
DOI: 10.1097/SCS.0000000000000679

and any possible risks of cross-infections. One of the most utilized way to completely eliminate the organic components (sugars, lipids, proteins) of an animal-derived bone tissue is the thermal deantigenation at high temperatures (about 500–1200°C). Even if it allows the removal of the entire organic component, thus avoiding the onset of an immune response of the host, this treatment also modifies the mineral structure of bone hydroxyapatite, and thus the resulting biomaterial usually possesses a reduced resorption potential. On the contrary, equine-derived bone substitutes are deantigenated by a proteolytic process through digestive enzymes at about 37°C, selective for the organic component, which leaves unaltered the ability of the biomaterial to be reabsorbed *in vivo*.<sup>19</sup>

The host tissue response to a bone substitute may be evaluated by immunohistochemical analysis for the expression of molecules specifically involved in the bone healing process.<sup>11</sup> In this process, vascular endothelial growth factor (VEGF) plays an important role. VEGF is produced by endothelial cells and osteoblasts, and is involved in initial bone remodeling phases because it regulates osteoblast evolution.<sup>20,21</sup> VEGF is also capable of inducing the growth of new blood vessels and plays a significant role in the preservation and development of endothelial fenestrations,<sup>22,23</sup> thus supporting new blood vessels formation in the site of grafting, which is a fundamental phase for graft integration.

The aim of this work was to evaluate the morphological structure and the expression of VEGF after maxillary sinus augmentation through equine and porcine bone substitutes in humans.

## PATIENTS AND METHODS

### Patients

Twenty patients, 8 males and 12 females, aged between 51 and 63 years, with inadequate bone volume in the posterior maxilla, classified as class C according to Chiapasco's classification of the posterior maxilla,<sup>2</sup> who were scheduled for maxillary sinus augmentation procedures before implants placement, were included in this study. All patients gave written informed consent in accordance with the Local Ethics Committee, in compliance with Italian legislation and with the code of Ethical Principles for Medical Research involving Human Subjects of the World Medical Association (Declaration of Helsinki). The patients were randomly divided into 2 groups. Ten patients (3 males, 7 females; age range 51–59) underwent maxillary sinus augmentation procedure through a particulate bone substitute of equine origin (BioBone Osteoconductor Mix; BioSAF IN S.r.l., Ancona, Italy), and 10 patients (5 males, 5 females; age range 52–63) underwent maxillary sinus augmentation procedure through a particulate bone substitute of swine origin (Gen-Os; Tecnoss, Turin, Italy). BioBone Osteoconductor Mix is a resorbable, collagen-deprived, and deantigenated osteoconductive biomaterial, obtained after deantigenation at 37°C in a humid atmosphere, made up of a corticocancellous mixture of equine origin (particle width 0.5–1 mm). Gen-Os are commercially available collagenated swine-derived corticocancellous bone chips, with particle width between 250 and 1000 µm.

Before surgical procedures, patients underwent complete medical anamnesis and radiographic examinations, including orthopantomography and cone beam computed tomography. All the selected patients had healthy systemic conditions, including the absence of any diseases that would contraindicate oral surgery. The exclusion criteria were uncontrolled periodontal disease, sinusitis, severe illness, unstable diabetes, drug abuse, a history of head and neck irradiation, and chemotherapy. Moreover, antibiotic therapy (amoxicillin 875 mg/clavulanic acid 125 mg, Augmentin, 2 g an hour before) was administered to all patients preoperatively.

### Surgical Procedures

The soft tissue was incised and flapped back to expose the underlying lateral wall of the maxillary sinus. The bone wall was then removed with a piezoelectric instrument (Easy Surgery; BioSAF IN S.r.l.) exposing the Schneiderian membrane. The membrane was then cut back from the inner face of the lower portion of the maxillary sinus cavity. The newly formed space within the bone cavity of the sinus inferior to the intact membrane was filled with the heterologous bone substitute and then covered by a collagen membrane (BioBone Collagen Membrane; BioSAF IN S.r.l.).

Closure of the surgical access was obtained with 3-0 sutures (Silkam/Virgin Silk; B. Braun Melsungen AG, Germany). For all patients, the postoperative therapy protocol comprised administration of antibiotic (Augmentin) 2 g/day for 10 days, nonsteroidal analgesic drug (ketoprofen, OKI; Dompè, L'Aquila, Italy) at a dose of 200 mg twice daily for 3 days, and cortisone (Betametason, Bentelan; Defiante Farmaceutico, Madeira, Portugal) 4 mg/day for 2 days and 2 mg on day 3. Moreover, soft diet and oral hygiene, including rinsing 3 times daily with 0.2% chlorhexidine (Corsodyl; GlaxoSmithKline) mouthwash and the application at the surgical site of 1% chlorhexidine gel (Corsodyl), were prescribed. Sutures were removed 10 days after the intervention and postoperative check-ups scheduled weekly for the first month, and then monthly by clinical and radiographical examination with periapical x-rays in the grafted area.

As postoperative healing was uneventful for all the patients, after about 6 months they all underwent a second surgery for implant placement. The implant features (diameter and length) were decided according to the anatomic situation individuated by clinical and radiographic examinations. However, all implants inserted had diameters between 3.3 mm and 4.5 mm, and lengths between 9 mm and 13 mm.

During implant insertion, bone samples were retrieved by a 3-mm-diameter and 8-mm-height trephine bur under sterile saline solution irrigation at the sites of implant placement to obtain significant specimens of bone regenerated with both heterologous bone substitutes. Pharmacological protocol included antibiotic (Augmentin 2 g an hour before) and nonsteroidal analgesic drugs to be taken as required.

### Light Microscopy and Immunohistochemical Analysis

Bone specimens, fixed in phosphate-buffered formalin solution, were decalcified in 10% tetrahydrated EDTA solution according to data sheet (MIELODEC kit; Bio-Optica, Milan, Italy), dehydrated through ascending alcohol concentrations, and then paraffin-embedded, to be sectioned at 5 µm thick. Sections were then dewaxed (alcohols progressively lower concentrations) and processed for hematoxylin-eosin staining and for immunohistochemical analysis.

Tissue sections with hematoxylin-eosin staining were observed to detect the presence of area of tissue remodeling.

To detect VEGF, immunohistochemical analysis was performed on 5-µm-thick tissue sections for each experimental specimen, by means of Ultravision LP Detection System HRP Polymer and DAB Plus Chromogen (Lab Vision Thermo, Fremont, CA). Sections were incubated in the presence of rabbit polyclonal anti-VEGF antibody (Santa Cruz Biotechnology, Santa Cruz, CA) and successively in the presence of specific HRP-conjugated secondary antibody. Peroxidase was developed using diaminobenzidine chromogen and nuclei were hematoxylin counterstained. Negative controls were performed by omitting the primary antibody.

Samples were then observed by means of Leica DM 4000 light microscopy (Leica Cambridge Ltd, Cambridge, UK) equipped with a Leica DFC 320 camera (Leica Cambridge Ltd) for computerized images.



**Image Analysis and Statistical Evaluation**

After digitizing the images derived from hematoxylin-eosin stained sections, the presence of native bone tissue was recognized by the presence of osteocyte lacunae-containing cells, whereas the newly formed bone tissue was recognized by the absence of lacunae.

Densitometric evaluation was obtained by measuring the percentage area ( $\pm$ SD) determined by direct visual evaluation of 10 fields (mean values) for each of 5 slides per specimen at 20 $\times$  magnification.

After digitizing the images derived from immunohistochemical stained sections, QWin Plus 3.5 software (Leica Cambridge Ltd) was used to evaluate VEGF expression. Image analysis of protein expression was performed through the quantification of threshold area for brown color, as average value per 10 fields, randomly chosen, for each sample at light microscope observation. Negative control images were randomly chosen. The statistical significance was evaluated by the Wilcoxon and Mann-Whitney tests, using R Software, version 2.12.1 for Mac and setting  $P = 0.05$ . After collecting results, the mean data were reported and shown in a histogram using Excel 2008 for Mac.

**RESULTS**

Morphological analysis was performed by light microscope after hematoxylin-eosin staining (Fig. 1). A better integration was shown when an equine bone substitute is used compared to a porcine one, and more evident signs of particles resorption were observed in equine bone substitute group specimens compared to porcine ones.

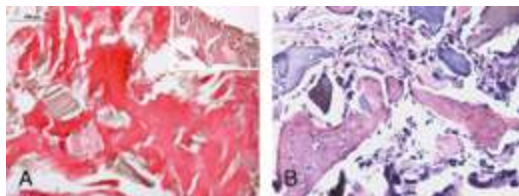
In particular, hematoxylin-eosin staining highlights new bone formation in equine bone substitute group along with areas of native bone tissue and connective fibers. Moreover, the grafted biomaterial particles are easily distinguishable because of lack of cellular structure, and they appear in part resorbed and well integrated with the newly formed bone tissue. Abundant areas of newly formed bone tissue are recognizable for the lack of bone lacunae.

In samples from the porcine bone substitute group, the bone particles are still clearly distinguishable from native bone tissue for absence of viable cells. The size of the bone particles appears quite unchanged and no clear evidence of resorption is detected. Samples from equine bone substitute group showed a significant higher amount of newly formed bone tissue compared to the native tissue than in porcine ones (Fig. 2).

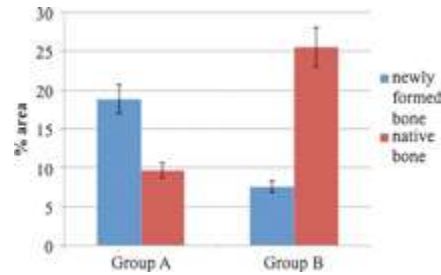
VEGF expression modifications occurring after different bone graft insertion and the evaluation of clinical applicability and integration ability of these grafts were then carried out. Densitometric values obtained from immunohistochemical analysis reveal a statistically significant increase in VEGF expression in samples from equine compared to porcine bone substitute group ( $P < 0.05$ ) (Fig. 3).

**DISCUSSION**

Most previous studies, to assess the success of a maxillary sinus augmentation procedure, take into consideration the survival rate of



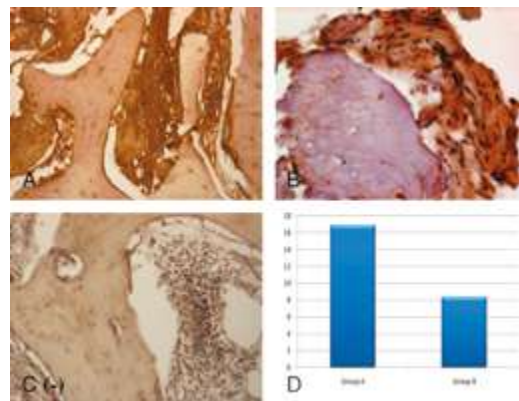
**FIGURE 1.** Hematoxylin and eosin staining of equine and porcine bone substitutes specimens. Magnification  $\times 20$  (inset  $\times 40$ ). Group A: bone tissue specimens obtained from equine bone substitute grafted area; group B: bone tissue specimens obtained from porcine bone substitute grafted area.



**FIGURE 2.** Graphic representation of densitometric evaluation of newly formed bone tissue and native bone in equine and porcine bone substitutes specimens. Data are expressed as area % ( $\pm$ SD) determined by direct visual evaluation of 10 fields (mean values) for each of 5 slides per specimen at  $\times 20$  magnification. Group A, bone tissue specimens obtained from equine bone substitute grafted area; Group B, bone tissue specimens obtained from porcine bone substitute grafted area. \*Group A newly formed bone tissue versus group B newly formed bone tissue,  $P < 0.05$ ; group A native bone tissue versus group B native bone tissue,  $P < 0.05$ .

implants placed in regenerated sites.<sup>24,25</sup> In our study, we evaluated the success of regenerative therapy directly at the time of implant placement, that is 6 months after grafting, by histological and immunohistochemical analyses.

Treatment of edentulous sites in the posterior maxilla requires a correct approach to obtain a functional implant-supported restoration. This goal may be achieved through adequate reconstruction by regenerative techniques with the use of bone substitutes. Even if the best performance of autologous bone grafts was widely demonstrated,<sup>23,26</sup> clinicians are constantly searching for a heterologous bone substitute that permits to combine the osteoregenerative features of autologous bone, eliminating at the same time the limits imposed by the need for a second surgical intervention for withdrawal.<sup>10</sup> Moreover, most heterologous bone substitutes currently used in clinical practice do not show ideal characteristics for bone regeneration such



**FIGURE 3.** Immunohistochemical analysis of VEGF expression in equine and porcine bone substitutes specimens. Magnification  $\times 20$ . Group A, bone tissue specimens obtained from equine bone substitute grafted area; Group B, bone tissue specimens obtained from porcine bone substitute grafted area; C (-), negative control; D, graphic representation of VEGF positive area % ( $\pm$ SD) densitometric analysis determined by direct visual counting of 10 fields (mean values) for each of 5 slides per specimen at  $\times 20$  magnification. \*Group A versus group B,  $P < 0.05$ .

as biological safety; osteogenic, osteoinductive, and angiogenic potentials; long shelf-life; no size restrictions; and reasonable cost.<sup>27,28</sup>

Heterologous biomaterials of different origins are successfully used as filling material for maxillary sinus augmentation.<sup>29,30</sup> As previously described, heterologous bone particles work only as osteoconductive biomaterial and they usually undergo slow resorption.<sup>31,32</sup> A biomaterial exhibiting no or scarce resorption could cause problems for a correct bone regeneration because of lower osteogenesis capability in respect to native autologous bone during the remodeling phase.<sup>33</sup> The biological behavior of a heterologous bone substitute is also affected by the treatment it undergoes before in vivo utilization. Most heterologous bone substitutes of animal origin, such as bovine and porcine, are treated by thermal deantigenation to make them suitable for clinical use by reducing antigenicity and possible risks of cross-infections. However, this treatment is known to alter the mineral structure of bone hydroxyapatite, thus reducing the osteoclastic remodeling rate of the bone substitute. Clinically, the performance of the biomaterial is not significantly affected by this kind of treatment, as the bone substitute acts principally as a bioinert scaffold. In fact, bovine and porcine bone substitutes have been successfully used for years in guided bone regeneration techniques, even if residual biomaterial particles could be detected after many years from grafting.<sup>20,33</sup>

On the contrary, equine-derived bone substitutes are deantigenated by a proteolytic, low-temperature process, selective for the organic component, that seems to increase the capabilities of a bone substitute subjected to this kind of process to be resorpted.<sup>34</sup> In fact, recent scientific evidence shows that biomaterials treated in this way undergo resorption and remodeling in about 12 months.<sup>20</sup> In literature, only a few studies have reported on the use of an equine bone substitute, which appeared to be able to induce osteoblasts differentiation, to be resorbed in vitro by osteoclasts, and to be safely used in mandibular bone regeneration.<sup>20,35</sup>

The aim of this work was to investigate the morphological aspect and the expression of VEGF after maxillary sinus augmentation through equine and porcine bone substitutes in humans. Light microscopic analysis strongly evidenced that sites treated with the equine bone substitute showed good integration between host tissue and graft. Moreover, after a mean healing period of 6 months, the grafted biomaterial seemed to have activated intense remodeling phenomena, as confirmed by the existence of large areas of newly formed bone tissue, while particles of the porcine-derived bone substitute showed only few signs of resorption.

To support these morphological aspects, the occurrence of new angiogenic processes was evaluated by checking VEGF expression. Vasularization has a crucial role in the regulation of bone remodeling and repair. New blood vessel formation is necessary to allow circulating osteoblast precursors to reach the remodeling site.<sup>20</sup> Moreover, VEGF is also involved in supporting osteoblast growth during the initial phase of bone graft integration.<sup>36</sup> In the present study, VEGF expression resulted higher in sites treated with equine bone substitute than in those treated with the porcine one, indicating that neoangiogenic phenomena occurred both earlier and an intense way between the 2 groups at the same healing time.

Even if long-term results are not yet available to evaluate host-tissue response after a longer healing period, the present results indicate that both equine- and porcine-derived bone substitutes could be successfully used for regenerative therapy of intraoral bone defects. Still aware that differences in vascularization significantly affect the clinical performance of a heterologous bone substitute, its ability to be resorbed is also very important in influencing long-term integration and long-term predictability of implant-prosthetic rehabilitation in regenerated sites. In fact, the higher resorption capabilities of the equine-derived bone substitute compared to porcine-derived one,

which probably could be due to the deantigenation process this biomaterial undergoes, could represent an added value to this category of bone substitute.

#### ACKNOWLEDGMENTS

The authors thank the FIRB-Accordi di Programma 2010, "Processi degenerativi dei tessuti mineralizzati del cavo orale, impiego di biomateriali e controllo delle interazioni con i microrganismi dell'ambiente," Prof. A. Cataldi, for the fellowship attributed to V.L.Z.

#### REFERENCES

- Tallgren A. The continuing reduction of the residual alveolar ridges in complete denture wearers: a mixed-longitudinal study covering 25 years. *J Prosthet Dent* 2003;89:427-435
- Chiapasco M, Zaniboni M. Methods to treat the edentulous posterior maxilla: implants with sinus grafting. *J Oral Maxillofac Surg* 2009;67:867-871
- Ariji Y, Kuroki T, Moriguchi S, et al. Age changes in the volume of the human maxillary sinus: a study using computed tomography. *Dentomaxillofac Radiol* 1994;23:163-168
- Jensen J, Sindet-Pedersen S, Oliver AJ. Varying treatment strategies for reconstruction of maxillary atrophy with implants: results in 98 patients. *J Oral Maxillofac Surg* 1994;52:210-216
- Tetè S, Vinci R, Zizzari VL, et al. Maxillary sinus augmentation procedures through equine-derived biomaterial or calvaria autologous bone: immunohistochemical evaluation of OPG/RANKL in humans. *Eur J Histochem* 2013;57:60-65
- De Leonardi D, Pecora GE. Augmentation of the maxillary sinus with calcium sulfate: one-year clinical report from a prospective longitudinal study. *Int J Oral Maxillofac Implants* 1999;14:869-878
- Mangano C, Scarano A, Iezzi G, et al. Maxillary sinus augmentation using an engineered porous hydroxyapatite: a clinical, histological, and transmission electron microscopy study in man. *J Oral Implantol* 2006;32:122-131
- Aguirre-Zorzano LA, Rodriguez-Tojo MJ, Aguirre-Urizar JM. Maxillary sinus lift with intraoral autologous bone and B-tricalcium phosphate: histological and histomorphometric clinical study. *Med Oral Patol Oral Cir Bucal* 2007;2:532-536
- Jensen OT, Shulman LB, Block MS, et al. Report of the sinus consensus conference of 1996. *Int J Oral Maxillofac Implants* 1998; 13(Suppl):11-45
- Cho YR, Gosain AK. Biomaterials in craniofacial reconstruction. *Clin Plast Surg* 2004;31:377-385
- Tetè S, Zara S, Vinci R, et al. Vascular endothelial growth factor and e-nitric oxide synthase-mediated regenerative response occurring upon autologous and heterologous bone grafts. *Int J Immunopathol Pharmacol* 2009;22:1105-1116
- Tetè S, Mastrangelo F, Carone L, et al. Morphostructural analysis of human follicular stem cells on highly porous bone hydroxyapatite scaffold. *Int J Immunopathol Pharmacol* 2007;20:819-826
- Sogal A, Tofe AJ. Risk assessment of bovine spongiform encephalopathy transmission through bone graft material derived from bovine bone used for dental applications. *J Periodontol* 1999;70:1053-1063
- Kim Y, Nowzari H, Rich SK. Risk of prion disease transmission through bovine-derived bone substitutes: a systematic review. *Clin Implant Dent Relat Res* 2011. doi: 10.1111/j.1708-8208.2011.00407.x
- Perrotti V, Nicholls BM, Piattelli A. Human osteoclast formation and activity on an equine spongy bone substitute. *Clin Oral Implants Res* 2009;20:17-23
- Artese L, Piattelli A, Di Stefano DA, et al. Sinus lift with autologous bone alone or in addition to equine bone: an immunohistochemical study in man. *Implant Dent* 2011;20:383-388
- Traini T, Degidi M, Sammons R, et al. Histologic and elemental microanalytical study of anorganic bovine bone substitution following sinus floor augmentation in humans. *J Periodontol* 2008;79:1232-1240

18. Orsini G, Scarano A, Piattelli M, et al. Histologic and ultrastructural analysis of regenerated bone in maxillary sinus augmentation using a porcine bone-derived biomaterial. *J Periodontol* 2006;77:1984–1990
19. Pagnutti S, Maggi S, Di Stefano DA, et al. An enzymatic deantigenation process allows achieving physiological remodeling and even osteopromoting bone grafting materials. *Biotechnol & Biotechnol* 2007;21:4
20. Gerber HP, Vu TH, Ryan AM, et al. VEGF couples hypertrophic cartilage remodeling, ossification and angiogenesis during endochondral bone formation. *Nat Med* 1999;5:623–628
21. Hiltunen MO, Ruuskanen M, Huuskonen J, et al. Adenovirus-mediated VEGF-A gene transfer induces bone formation in vivo. *FASEB J* 2003;17:1147–1149
22. Yokomori H, Oda M, Yoshimura K, et al. Vascular endothelial growth factor increases fenestral permeability in hepatic sinusoidal endothelial cells. *Liver Int* 2003;23:467–475
23. Darland DC, Massingham LJ, Smith SR, et al. Pericyte production of cell-associated VEGF is differentiation-dependent and is associated with endothelial survival. *Dev Biol* 2003;264:275–288
24. Del Fabbro M, Rosano G, Taschieri S. Implant survival rates after maxillary sinus augmentation. *Eur J Oral Sci* 2008;116:497–506
25. Pjetursson BE, Tan WC, Zwalhem M, et al. A systematic review of the success of sinus floor elevation and survival of implants inserted in combination with sinus floor elevation. *J Clin Periodontol* 2008;35:216–240
26. Crespi R, Vinci R, Capparè P, et al. Calvarial versus iliac crest for autologous bone graft material for a sinus lift procedure: a histomorphometric study. *Int J Oral Maxillofac Implants* 2007;22:527–532
27. Tetè S, Vinci R, Zara S, et al. Long-term evaluation of maxillary reconstruction by iliac bone graft. *J Craniofac Surg* 2011; 22:1702–1707
28. Tetè S, Vinci R, Zara S, et al. Atrophic jaw reconstruction by means of calvarial bone graft: long-term results. *J Craniofac Surg* 2010;21:1147–1152
29. Tetè S, Zara S, Zizzari VL, et al. Immunohistochemical analysis of matrix metalloproteinase-9, vascular endothelial growth factor, bone sialoprotein and i-nitric oxide synthase in calvaria vs. iliac crest bone grafts. *Clin Oral Implants Res* 2012;23:1254–1260
30. Finkemeier CG. Bone-grafting and bone-graft substitutes. *J Bone Joint Surg Am* 2002;84-A:454–464
31. John HD, Wenz B. Histomorphometric analysis of natural bone mineral for maxillary sinus augmentation. *Int J Oral Maxillofac Implants* 2004;19:199–207
32. Hallman M, Lundgren S, Sennerby L. Histological analysis of clinical biopsies taken 6 months and 3 years after maxillary sinus floor augmentation with 80% bovine hydroxyapatite and 20% autogenous bone mixed with fibrin glue. *Clin Implant Dent Relat Res* 2001;3:87–96
33. Cypher TJ, Grossman JP. Biological principles of bone graft healing. *J Foot Ankle Surg* 1996;35:413–417
34. Mordenfeld A, Hallman M, Johansson CB, et al. Histological and histomorphometrical analyses of biopsies harvested 11 years after maxillary sinus floor augmentation with deproteinized bovine and autogenous bone. *Clinical Oral Implants Research* 2010;21:961–970
35. Di Stefano DA, Artese L, Iezzi G, et al. Alveolar ridge regeneration with equine spongy bone: a clinical, histological, and immunohistochemical case series. *Clin Implant Dent Relat Res* 2009;11:90–100
36. Gerstenfeld LC, Cullinane DM, Barnes GL, et al. Fracture healing as a post-natal developmental process: molecular, spatial, and temporal aspects of its regulation. *J Cell Biochem* 2003;88:873–884

J. Maxillofac. Oral Surg. (Oct–Dec 2014) 13(4):401–408  
DOI 10.1007/s12663-013-0569-5

REVIEW PAPER

## Maxillary Sinus Augmentation with Autologous and Heterologous Bone Graft: A Clinical and Radiographic Report of Immediate and Delayed Implant Placement

Mario Santagata · Umberto Tozzi · Gianpaolo Tartaro ·  
Vincenzo Santillo · Corrado Giovanni · Ettore Lamart ·  
Angelo Itro · Giuseppe Colella · Salvatore D'Amato

Received: 7 June 2013 / Accepted: 7 August 2013 / Published online: 30 August 2013  
© Association of Oral and Maxillofacial Surgeons of India 2013

### Abstract

**Purpose** The aim of this study was to evaluate cumulative survival rate of implants placed on augmented maxillary sinus using a mixture of autologous bone harvested from the maxillary tuberosity and bovine-derived HA and to assess the height of the grafted material through radiographic evaluation.

**Methods** Thirty-five patients were treated with maxillary sinus augmentation and 93 implant fixtures were installed. The height of the augmented sinus and the gain of bone volume were measured by Cone Beam CT Scan and intraoral radiographs immediately after augmentation and up to 48 months subsequently. Changes in the height of the sinus graft material were calculated radiographically.

**Results** The cumulative survival rate was 98.92 % in all 93 implants. Additionally, normal healing process without any complication was observed in all patients. The original sinus height was a mean of 4.52 mm (range 2.0–6.4 mm) and the augmented sinus height was a mean of 14.1 mm (range 12.0–16.5 mm) after the surgery. The bone volume gain was a mean 9.613 mm (range 7–13 mm).

**Conclusions** Within the limitations of this study, it would appear from the clinical and radiographic results that the sinus lift procedure with autologous bone graft harvested from the maxillary tuberosity combined with deproteinized

bovine bone allows for a predictable outcome regarding the amount of bone formation in sinus floor augmentation and the immediate placement of implants, when possible, is recommended.

**Keywords** Dental implants · Maxillary sinus · Autologous bone graft · Heterologous bone graft · Survival rate · Immediate implant placement · Delayed implant placement

### Purpose

The presence of alveolar bone with sufficient volume and/or density is considered to be a prerequisite for implant placement, integration, and load behavior. However, bone resorption following tooth extraction or due to advanced periodontal disease and/or pneumatization of the maxillary sinus may result in insufficient bone in horizontal and/or more frequently vertical dimension for the placement of dental implants. Although good results have been presented with short implants [1], larger implants are generally preferable in order to endure loading forces on the prosthetic reconstruction; in fact, increased failure rates with short and/or narrow implants have been reported previously [2, 3]. The most common treatment planning in the posterior maxilla is the augmentation of the maxillary sinus floor, which involves a modification/reduction of the sinus cavity aiming at the production of bone inside a space previously being a portion of the sinus cavity. This is most often achieved in combination with bone grafts and/or substitutes that are placed inside the sinus cavity with the aim to create space for and accelerate bone formation. Implant placement is performed simultaneously with the sinus-lift procedure if adequate amounts of alveolar bone

M. Santagata · U. Tozzi · G. Tartaro · V. Santillo ·  
C. Giovanni · E. Lamart · A. Itro · G. Colella · S. D'Amato  
Multidisciplinary Department of Medical and Dental Specialties,  
Oral and Maxillofacial Surgery Unit, AOU-SUN (Second  
University of Naples), Naples, Italy

M. Santagata (✉)  
Piazza Fuori Sant'Anna, 17, 81031 Aversa, Italy  
e-mail: mario.santagata@tin.it

are present and a good primary stability of the implants can be achieved or at a later time point when some new bone formation is expected to have occurred inside the sinus cavity.

The aim of this study was to determine the clinical and radiographic efficacy of a mixture of autologous bone harvested from the maxillary tuberosity using bone scraper (safescraper twist—META, Reggio Emilia, Italy), bovine-derived HA (Bio-Osss—Geistlich Pharma, Wolhusen, Switzerland; particle size of 0.25–1 mm) placed as a graft to elevate the maxillary sinus floor, and the use of a bioresorbable porcine-derived collagen membrane (Bio-Gides, Geistlich Pharma, Wolhusen, Switzerland) covering lateral access window. In order to accomplish this, the survival rate of the implants was evaluated. Furthermore, in all patients mean values were calculated. Differences in RHBG (residual height bone graft) according to the timing of implantation were analyzed. Correlation between the RHBG and follow-up period was determined.

## Materials and Methods

### Patients

A total of 35 patients (15 women and 20 men; ages ranged 24–75 years) were included in this study and provided with a total of 93 implants (Table 1). The study was performed according to the Helsinki declaration of [4].

The preoperative diagnosis was made by carrying out Cone Beam CT Scan and periapical radiography. Patients were included in the study if no systemic or local contraindications were encountered. Particularly, the evaluation included the general health and the oral health status, and the correct interarch relationship.

Inclusion criteria were severe atrophy (< 7 mm) of the alveolar process in the sinus area bi- or unilaterally and the presence of a Misch type 3 or 4 sinus situation [5]. All patients received oral hygiene instructions before entering the study. After information about the procedure they were required to sign a consent form. Exclusion criteria were poor general health, e.g., severe renal/or liver disease, acute myocardial infarction within the past 12 months, uncontrolled coagulation disorders, uncontrolled metabolic diseases, radiotherapy to the head in the past 24 months, treatment with intravenous bisphosphonates or with oral bisphosphonates for >3 years, psychiatric problems, heavy smoking (>10 cigarettes/day), alcohol or drug abuse, maxillary sinus pathologies, oral infections, and uncontrolled periodontal disease.

Sinus floor augmentation was carried out on both sides in five patients and on one side in 30 patients. Thus, a total of 35 patients with severe atrophic maxillae or sinus

pneumatization undergoing 40 sinus lift augmentation procedures were evaluated prospectively.

### Surgical Procedure

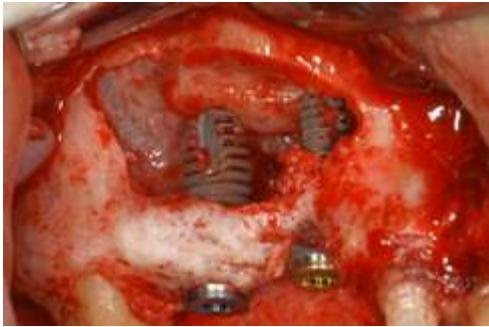One hour before starting the surgical procedure, all patients received 2 g of amoxicillin, and immediately before the surgical procedure, they rinsed for 2 min with a 0.2 % chlorhexidine solution. All surgical procedures were completed by the same surgeon under local anesthesia. A mid-crestal incision was made, and a vertical releasing incision was additionally placed anteriorly, normally just posterior to the canine area. A mucoperiosteal flap was elevated buccally and palatally, allowing access to the lateral sinus wall. Then, an osteotomy was performed at the lateral surface of the sinus wall using a piezoelectric device (Piezosurgery, Mectron Spa, Carasco Genova, Italy) and the sinus membrane was carefully elevated superiorly starting from the inferior border of the osteotomy site, and completely and carefully dissected from the medial and inferior walls of the sinus. All surgical procedures were performed with high accuracy to avoid perforation of the sinus membrane, in order to prevent sinusitis and loss of bone graft material. The floor, lateral wall and posterior wall of the membrane were carefully detached and pushed upward to provide the required space for the implant to be placed. Two-stage implant system was used (Fig. 1). The number, diameter and length of implants in each case was determined according to the prosthetic plan and the quality and quantity of the recipient bone. Then, a portion of the antral space was filled with a composite graft consisting of the autogenous bone harvested from maxillary tuberosity by a bone scraper (safescraper twist—META, Reggio Emilia, Italy) and Bio-Osss (Geistlich Pharma, Wolhusen, Switzerland; particle size of 0.25–1 mm) (Fig. 2) and gently packed over the bone into the sinus (Fig. 3). The amount of harvested bone was obviously dependent of the lateral maxillary wall thickness; hence, the maxillary plate in the sinus area provided an amount of bone that ranged from 0.5 to 2 ml. This bone graft was placed in a receptacle in which additional Bio-Oss granules were added to increase the final graft volume that was dependent on the sinus size with a mixture in a 1:1 ratio. The lateral access window was then covered with a bioresorbable porcine-derived collagen membrane (Bio-Gides, Geistlich Pharma, Wolhusen, Switzerland) to prevent soft tissue invasion and bone graft spreading, and to promote bone formation. The Bio-Gides membrane was trimmed to cover the osteotomy window, extending about 3 mm beyond its borders, and it was not fixed with pins or tacks (Fig. 4). The mucoperiosteal flap was repositioned and sutured using 4/0 resorbable suture material (Trofilorc, LorcaMarin, SA, Murcia, Spain) to achieve closure of a tension-free flap.

**Table 1** Case summary

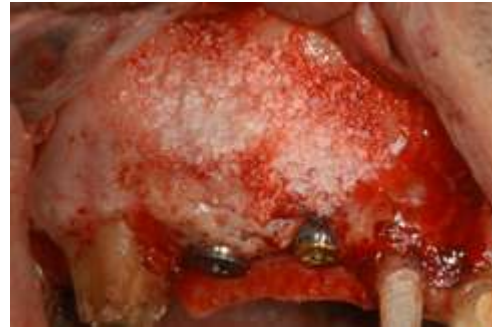Case	Age	Sex	Area	System	Diameter	Length	Stage	OSH	ASH	BHG	Bone quality	Follow-up	RHBG (mm)
1	59	F	26 27	Biohorizons	4.6	12	1	4.8	13.8	9	IV	9	8.6
2	50	M	26 27	3i	3.75	13	2	2.7	14.2	11.5	IV	60	10.6
3	46	F	15 16 17	Biohorizons	3.8	12	1	6.3	14.9	8.6	IV	24	7.9
3	46	F	26 27	Biohorizons				5.7	13.7	8			7.3
4	51	M	25	Biohorizons	3.8	12	1	5.1	12.9	7.8	IV	12	7.3
4	51	M	26	Biohorizons	4.6	12							
4	51	M	27	Biohorizons	3.8	12							
5	75	F	15 16 17	Biohorizons	4.6	12	2	3.5	12.8	9.3	V	25	8.59
6	60	F	25 26	Biohorizons	3.8	12	1	6.4	15.1	8.7	IV	48	7.9
6	60	F	27	Biohorizons	4.6	12							
7	61	M	16 17	Biohorizons	3.8	12	1	5.6	13.3	7.7	IV	10	7.29
7	61	M	26 27	Biohorizons	3.8	12	1	6.4	13.8	7.4			6.99
8	75	M	15 16 17	Biohorizons	4.6	12	1	5.5	13.2	7.7	III	15	7.17
8	75	M	25 26 27	Biohorizons	4.6	12	1	5.4	13	7.6			7.07
9	45	M	16 17	Biohorizons	4.6	12	2	2.5	15.2	12.7	IV	9	12.3
10	55	M	15 16 17	Biohorizons	4.6	12	1	3.8	14.2	10.4	III	12	9.9
11	58	M	26 27	Biohorizons	4.6	12	1	5.4	14.6	9.2	III	9	8.8
12	70	M	15 16	Biohorizons	3.8	12	1	5.6	14.8	9.2	III	11	8.78
13	56	F	25 26	Biohorizons	4.6	12	1	4.4	14.4	10	III	13	9.45
14	46	F	24 25 26	Xive	3.8	13	1	5	15	10	IV	48	9.2
15	40	F	14 15 16	Xive	3.8	13	1	3	13.9	10.9	IV	48	10.1
15	40	F	14 15 16	Xive	3.8	13							
15	40	F	14 15 16	Xive	4.5	11							
15	40	F	25 26	3i	3.75	13	2						
16	48	M	14 15 16	Nobel	4	13	1	4.5	14.5	10	V	48	9.2
16	48	M	14 15 16	Nobel	4			4	16.5	12.5			11.7
17	50	M	15 16	3i	4	13	1	3.2	15	11.8	IV	48	11
18	60	M	13 14	Xive	3.8		1	4.1	14.2	10.1	V	36	9.34
18	60	M	13 14	Xive	4.5								
18	60	M	23 24 25	Xive	13		2	3.9	14.5	10.6			9.84
19	54	F	15 16	Winsix	3.8	11	1	4.9	13.5	8.6	IV	48	7.8
20	48	M	16 17	Winsix	5.2	11	1	5.1	13.7	8.6	IV	36	7.84
21	61	F	15 16 26 27	Winsix	4.5	13	2	2.9	15.9	13	IV	44	12.22
22	41	M	26 27	Winsix	4.5	13	1	5	12	7	IV	45	6.22
23	53	F	15 17	Winsix	3.8	11	1	5.1	12.9	7.8	IV	48	7
24	69	M	25 27	Winsix	5.9	11	1	5	15.6	10.6	IV	37	9.84
25	37	F	15 17 25 27	Winsix	3.8	13	2	2.7	14.6	11.9	IV	47	11.11
26	71	M	15 17 25 27	Winsix	4.5	13	1	4.8	13.7	8.9	IV	46	8.11
27	51	F	26 27	Winsix	4.5	11	1	5	13.9	8.9	IV	45	8.12
28	43	M	16 17	Winsix	4.5	13	1	4.3	15.1	10.8	IV	48	10
29	29	M	15	Winsix	4.5	13	1	4.7	12.9	8.2	III	45	7.42
30	33	M	15 16	Winsix	3.8	11	2	3	14.2	11.2	IV	47	10.41
31	68	F	26	Winsix	4.5	13	1	5.3	15.3	10	IV	48	9.2
32	24	M	15	Winsix	4.5	13	1	4.9	13.2	8.3	III	48	7.5
33	35	M	16 17	Winsix	4.5	11	1	4.7	14.7	10	IV	45	9.22
34	59	F	14 16	Winsix	4.5	13	2	2	13.1	11.5	IV	48	10.7
35	52	F	26	Winsix	3.8	11	1	4.9	13.9	9	IV	48	8.2

OSH Original sinus height, ASH Augmented sinus heights, BHG Bone height gain, RHBG Reduced heights bone gain





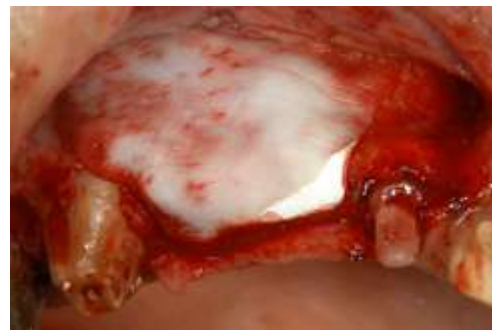**Fig. 1** The floor, lateral and posterior wall of the membrane were carefully detached and pushed upward to provide the required space for the implant to be placed



**Fig. 3** Bone harvested from maxillary tuberosity and Bio-Oss were gently packed over the bone into the sinus



**Fig. 2** Autogenous bone harvested from maxillary tuberosity by a bone scraper



**Fig. 4** The lateral access window was then covered with a bioresorbable porcine-derived collagen membrane

Postoperatively, all patients received 1 g of amoxicillin 6 h after surgery and 2 g twice daily for 4 days after surgery and non-steroid analgesic postoperatively as needed. All the patients were also instructed to rinse twice daily over a period of 2 weeks using a 0.12 % chlorhexidine gluconate solution. They were also advised not to blow their noses for 15 days. Ten days after surgery the sutures were removed.

In 9 cases, the sinus were of type 4 of Misch [5], and therefore implants were placed after a healing period of 8 months (two-stage surgery). In the remaining 31 cases, on which there were >5 mm of bone present between the residual alveolar crest and the floor of the maxillary sinus, the implants were immediately placed.

A total of 93 screw-shaped titanium implants were inserted: 37 tapered internal implants with a laser

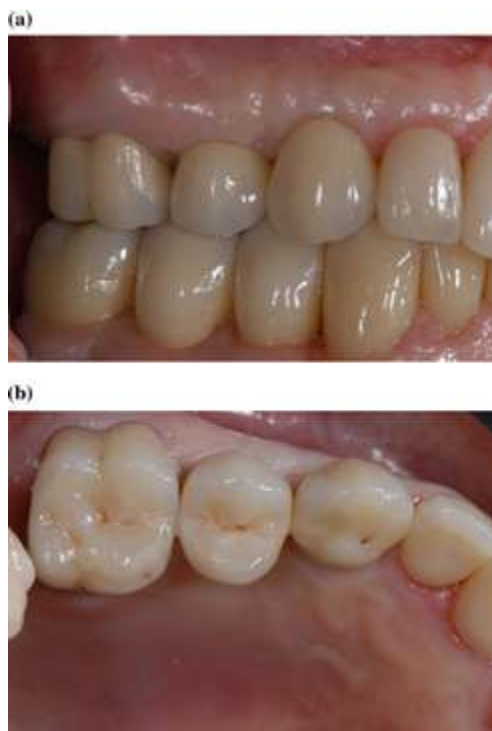microgrooved coronal design (Biohorizons, Birmingham, Ala); 36 implants Winsix (Winsix Ltd, Lincoln Inn's Field, London); 3 implants Branemark System (NobelBiocare AB, Gotenborg, Sweden); 11 implants were from Xive (Dentsply Friadent, Mannheim, Germany), and 6 implants were from 3i (BIOMET 3i, Riverside Drive Palm Beach Gardens, FL). The diameters of Biohorizons's implants were 3.8 mm (15); 4.6 mm (22) and their lengths were 12 mm. The diameters of Winsix's implants were 3.8 mm (11); 4.5 mm (21); 5.2 mm (2); 5.9 mm (2) and their lengths were 11 mm (15) and 13 mm (21). The diameter of Branemark's implants were 4.0 mm (3) and their lengths were 13 mm (3). The diameters of Xive's implants were 3.8 mm (8); 4.5 mm (3) and their lengths were 11 mm (1) and 13 mm (10).

All patients were rehabilitated with fixed implant-supported prostheses (Fig. 5). None of the patients were rehabilitated with removable implant-supported overdentures. All implants were loaded.

**Table 2** Radiographic analysis (mean  $\pm$  SD)

12 months: RHBG (mm)/Time (mo): mean $0.71 \pm 0.41$
48 months: RHBG (mm)/Time (mo): mean $0.90 \pm 0.41$
R2:0.089

RHBG reduced height of bone graft

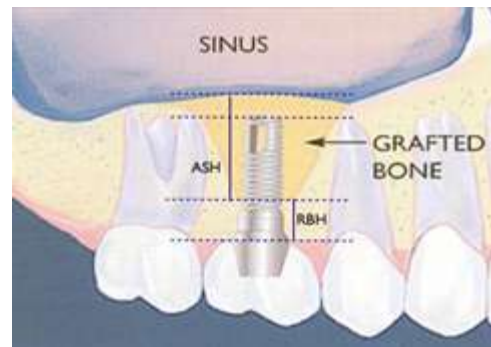


**Fig. 5** All patients were rehabilitated with fixed implant-supported prostheses: **a** From buccal point of view, **b** from occlusal point of view

#### Radiographic Examinations

Cone Beam CT scan was obtained before the surgery (baseline), immediately after the sinus augmentation, the 1 year after the surgery. Additional radiographs were obtained every 12 months through the follow-up period. In the defined implant area, bone density was measured in Hounsfield units.

The periapical radiographs used for analysis were taken with the long-cone technique and were analyzed by a computerized measuring technique with image analysis software (Digora, Soredex, Helsinki, Finland) measuring the distance between two points. Internal calibration was



**Fig. 6** Schematic drawing of the parameters measured on radiographs

performed for each radiograph on three inter-thread distances (3.7 mm), given that the tips of two consecutive threads are separated by 1.2 mm. The precision of the measuring system was 0.01 mm.

The landmarks, appearing in Fig. 6, served to calculate the measurements, where:

**RBH:** the vertical distance between the most coronal bone-implant contact and the most apical implant-bone contact.

**ASH:** were measured from the 1st bone to implant contact points to the base of the maxillary sinus, which was elevated with bone graft at the mesial and distal aspects of the implants.

All measurements were made twice by one blinded investigator with a 12-month interval between the measurements.

The augmented sinus heights (ASH) were measured from the 1st bone to implant contact points to the base of the maxillary sinus, which was elevated with bone graft at the mesial and distal aspects of the implants. The volume of marginal bone loss (MBL) was obtained compared with the periapical radiographs and CBCT scan, cross-sectional slices, immediately taken after the surgery and 1 year postoperatively. The reduced height of bone graft (RHBG) was calculated based on the changes in the ASH and MBL.

#### Statistical Analysis

In all patients mean values were calculated. There was a substantial difference in the sample means of RHBG in the two sub-samples (Stage 1 and Stage 2) respectively of 8.47 and 10.70 mm. This result was subjected to a test of significance to verify the inference result of the sample on the population of origin.

**Table 3** Differences according to the timing of implantation (mean  $\pm$  SD)

	Simultaneous	Delayed
RHBG (mm)	8.47 $\pm$ 0.41	10.70 $\pm$ 0.31

RHBG reduced height of bone graft

It was assumed that the two populations were independent with unknown but equal variances.

Therefore we wanted to test whether the two means were equal to each other ( $H_0: \mu_1 = \mu_2$ ) against the alternative hypothesis that the sample mean (Stage 1) was less than the average for the second sample (Stage two) ( $H_1: \mu_1 < \mu_2$ ).

Estimating that the sampling variances will reach a value of statistical Student's *t* test of  $-7,569$ , compared with the value of the standardized *t* distribution with 91 degrees of freedom and a significance level of 0.05, is much lower:

$$t(91) < t(91)_{0.05} \rightarrow -7,569 < -1,662$$

This result leads to the rejection of the null hypothesis and acceptance of the alternative hypothesis of a significant reduction in the sample RHBG Stage 1 vs Stage 2.

There was no linear correlation between RHBG and follow-up, in fact the adjusted  $R^2$  was 0.089, which was very close to 0 hence the linear model does not fit our case.

#### Patient Outcome Analysis

In all cases, implant lengths, time of follow-up, and peri-operative and postoperative complications were recorded (Table 1). In this study, data on implant survival were considered only for those implants that were loaded for a minimum of 9 months.

#### Implant Survival Rate

The success criteria for implants presented by Buser et al. [6] was used.

#### Results

Thirty-five patients with a total of 40 sinus graft procedures were followed clinically in a prospective manner. All patients were initially evaluated at intervals of 3–6 months for the first year and annually thereafter for up to 4 years. Mucosal tears occurred in five of 40 sinuses grafted (12.5 %) and since the tears were very less no treatment was needed.

In two cases (5.0 %), there were infections in the post-operative period that were resolved with antibiotics.

Implants were loaded after a healing interval of 4 months for the two-stage approach and after 9 months for one-stage cases. The range length of follow-up after implant loading was 9–48 months.

The original sinus height (OSH) was a mean of 4.52 mm (range 2.0–6.4 mm) and the augmented sinus height (ASH) was a mean of 14.1 mm (range 12.0–16.5 mm) after the surgery. The bone height gain was a mean of 9.613 mm (range 7–13 mm). The marginal bone loss up to 1 year was measured as 0.30  $\pm$  0.45 mm.

Linear measurements to evaluate the marginal bone levels were performed on digitized images. The graft apical to the implants demonstrated a gradual reduction in height. The RHBG 1 year postoperatively was 0.71  $\pm$  0.41 mm, and at 48 months postoperatively was 0.90  $\pm$  0.41 mm (Table 2).

A substantial difference in the reduced volume of the bone graft was observed according to the timing of implantation (Table 3).

One implant was lost before loading (1.075 %). The remaining 92 implants were stable and free of complications at the end of the study. Thus, the implant survival rate was 98.92 %.

#### Discussion

Since the initial description of maxillary sinus floor elevation by Boyne and James [7] and Tatum [8], several sinus augmentation techniques have been proposed. Initially, a modified Caldwell–Luc procedure was used to approach the sinus, by fracturing a rectangular or trapezoidal osteotomy of the lateral wall of the maxilla. Later, Garg and Quiñones [9] modified this technique, designing the osteotomy in an ovoid shape in order to minimize the chances of schneiderian membrane perforation with sharp corners produced in a rectangular or a trapezoidal osteotomy. Here, we propose this technique.

The choice of augmentation material is of principal importance in sinus surgery. However, the ideal bone graft has not yet been determined. Autologous bone is considered the gold-standard material in terms of osteogenic potential, because it supplies not only osteoblasts but also provides organic and inorganic matrices for osteoinduction and osteoconduction [10, 11]. Bone can either be gained extraorally, from the iliac crest [7] or the cranial vault [5], or harvested intraorally, mainly from the chin [12]. However, a limited amount of bone is available at intraoral donor sites, and the use of an extraoral one usually calls for general anesthesia, increasing the time and the cost of treatment and giving rise to considerable morbidity [13]. Furthermore, autologous bone shows a trend toward bone resorption that reduces the initial graft volume, and

morbidity at the donor site, which could be seen in almost 8 % of operations [11, 14]. The source of autologous bone could be relevant.

When an autogenous bone is harvested from the oral cavity, such as the mandible ramus or the symphysis, its quantity is frequently insufficient for the surgical procedure that a sinus floor elevation involves [15]. To surmount these problems, bone substitutes have been used instead of bone or mixed with it [16, 17].

Bovine-derived HA or anorganic bone is a xenogenic material from which all organic components have been removed [18], which ensures that no immune response or allergy *in vivo* is induced. Bovine HA is a highly biocompatible and osteoconductive material [19–21], and it seems to promote more early bone formation than other bone substitutes [22]. However, its long term fate is still unknown, because the literature is not conclusive regarding its degradation.

According to Misch and Dietsch [23], a mixture of autologous bone with synthetic material was most frequently used in clinical trials investigating sinus floor augmentation. A significant advantage of this approach was healing time reduction when anorganic bone was combined with autografts. In fact, a healing period of 6–8 months is necessary to allow for the vascularization and incorporation of the grafts and subsequent maturation of newly formed bone tissue [23], less time than needed when only a bone substitute is used as a graft. In this work, we describe a technique that consists of grafting the maxillary sinus with a mixture in a 1:1 ratio of deproteinized bovine bone and autologous bone harvested from the maxillary tuberosity, thus avoiding the need for the use of a different or even a distant donor site.

Controversy still exists regarding the need to cover the lateral osteotomy site with a membrane to contain the grafted material, prevent its migration or dispersion into the soft tissues and limit soft tissue invasion into the sinus cavity. Tawill and Mawla [24] observed that the use of a collagen barrier to cover the antrotomy site when machined-surface implants were used in sinuses grafted with Bio-Oss seemed to improve the quality of the graft healing and the survival rate of the implants loaded between 6 and 9 months after placement. Instead, implants used in this study have moderately rough surfaces that probably yield a better survival rate than the implants used in the Tawill and Mawla study [24].

The implant success rate following sinus graft with deproteinized bovine bone varies from 90 to 98 % [15, 25]. In the present study, only one of 93 implants had to be removed. Consequently, the survival rate was 98.92 %.

Hieu et al. [26] radiographically evaluated the changes in height of the xenogenic materials (Bio-Oss, Geistlich Sons,

Wolhusen, Switzerland) after maxillary sinus augmentation over the course of 2 years. This study reported that significant material resorption can take place over time. Nonetheless, it could be assumed that many other factors, e.g., the air pressure in the maxillary sinus, the form of augmented material, the density of the grafted material, the use of a bioresorbable porcine-derived collagen membrane are more important than the time flow. Therefore, it is possible that the resorption rate of the grafted material is affected by the host's environment. This would be expected to be clarified with further study.

Linear measurements to evaluate the marginal bone levels were performed on digitized images. The graft apical to the implants demonstrated a gradual reduction in height. In fact, the residual height bone graft (RHBG) was  $0.71 \pm 0.41$  mm in the first year and at the 4-year examination, it was  $0.90 \pm 0.41$  (Table 2).

Two dimensional panoramic radiographs have been used to evaluate the grafted material and its relationship with implants [27].

In the present study, in addition to periapical radiographs we also used the Cone Beam Computed Tomography in cross-sectional slices which supplies 3-dimensional images that would provide a more accurate volumetric measurement of the bone graft. A substantial difference in the reduced volume of the bone graft was observed according to the timing of implantation. In fact, there was a substantial difference in the sample means of RHBG in the two sub-samples (Stage 1 and Stage 2) respectively of 8.46 and 10.70 mm. This result was subjected to a test of significance to verify the inference result of the sample on the population of origin.

There was no linear correlation between RHBG and follow-up, in fact the adjusted  $R^2$  was 0.089, which was very close to 0 hence the linear model does not fit our case. After careful analysis: we want to test the correlation between RHBG as the dependent variable (or subsequent) and the dichotomous variable Stage as an independent (or earlier). The method of least squares was used to estimate the parameters reached in this regression line:  $RHBG = 6.23 + 2.23$  STAGE.

This means that, given that the regression coefficient (2.23), increases by one unit of STAGE, the RHBG increases more than proportionally, namely, in going from 1 to 2 timing of implantation, we will have an average increase reduction of bone height of 2.23 mm. The model explains only 38 % (adjusted  $R^2 = 0.38$ ) of the variability of the empirical RHBG. However, combining this result with statistics on the sample differences, it is confirmed that the results obtained from the sample of observed cases is found in the starting population and that in passing from Stage 1 to Stage 2 there is considerable loss of bone height.

### Conclusion

In conclusion, within the limitations of this study, it would appear from the clinical and radiographic results that the sinus lift procedure with autologous bone graft harvested from the maxillary tuberosity combined with deproteinized bovine bone allows for a predictable outcome regarding the amount of bone formation in sinus floor augmentation and the immediate placement of implants, when possible, is recommended. In fact, there was a substantial difference of RHBG with a value of 8.47 mm in case of immediate implant placement after maxillary sinus augmentation and 10.70 mm in case of delayed implant placement.

**Conflict of interest** The authors report no conflicts of interest.

### References

- Renouard F, Nisand D (2006) Impact of implant length and diameter on survival rates. *Clin Oral Implants Res* 17(2):35–51
- Winkler S, Morris HF, Ochi S (2000) Implant survival to 36 months as related to length and diameter. *Ann Periodontol* 5(1):22–31
- Ferrigno N, Laureti M, Fanali S, Grippaudo G (2002) A long-term follow-up study of non-submerged ITI implants in the treatment of totally edentulous jaws. Part I: Ten-year life table analysis of a prospective multicenter study with 1286 implants. *Clin Oral Implants Res* 13(3):260–273
- Schuklenk U (2001) Helsinki declaration revisions. *Issues Med Ethics* 9:29
- Misch CE (1999) The maxillary sinus lift and sinus graft surgery. In: Misch CE (ed) *Implant dentistry*, 2nd edn. Mosby, St. Louis, pp 469–495
- Buser D, Weber HP, Lang NP (1990) Tissue integration of non-submerged implants. 1-year results of a prospective study with 100 ITI hollow-cylinder and hollow-screw implants. *Clin Oral Implants Res* 1:33–40
- Boyne PJ, James RA (1980) Grafting of the maxillary sinus floor with autogenous marrow and bone. *J Oral Surg* 38(8):613–616
- Tatum H Jr (1986) Maxillary and sinus implant reconstructions. *Dent Clin North Am* 30(2):207–229
- Garg AK, Quiñones CR (1997) Augmentation of the maxillary sinus: a surgical technique. *Pract Periodontics Aesthet Dent* 9(2):211–219
- Pejrone G, Lorenzetti M, Mozzati M, Valente G, Schierano GM (2002) Sinus floor augmentation with autogenous iliac bone block grafts: a histological and histomorphometric report on the two-step surgical technique. *Int J Oral Maxillofac Surg* 31:383–388
- Tulasne JF, Saade J, Riachi A (1993) Greffe osseuse du sinus maxillaire et implants de Brånemark. *Cah Prothet* 2:101–116
- Moy PK, Lundgren S, Holmes RE (1993) Maxillary sinus augmentation: histomorphometric analysis of graft materials for maxillary sinus floor augmentation. *Int J Oral Maxillofac Surg* 51:857–862
- Gerngrob H, Burri C, Kinzl L, Merk J, Müller GW (1982) Komplikationem an der Entnahmestelle autologer Spongiosa transplantate. *Aktuelle Traumatologie* 12:146–152
- Younger EM, Chapman MW (1989) Morbidity at bone graft donor site. *J Orthop Trauma* 3:192–195
- Yildirim M, Spiekermann H, Biesterfeld S, Edelhoft D (2000) Maxillary sinus augmentation using xenogenic bone substitute material Bio-Oss in combination with venous blood. A histologic and histomorphometric study in humans. *Clin Oral Implants Res* 11:217–229
- Hurzeler MB, Quinones CR, Kirsch A, Schupbach P, Krause A, Strub JR, Caffesse RG (1997) Maxillary sinus augmentation using different grafting materials and dental implants in monkeys. Part III: evaluation of autogenous bone combined with porous hydroxyapatite. *Clin Oral Implants Res* 8:401–411
- Schlegel KA, Fichtner G, Schultze-Mosgau S, Wiltfang J (2003) Histologic findings in sinus augmentation with autogenous bone chips versus a bovine bone substitute. *Int J Oral Maxillofac Implants* 18(1):53–58
- Valentini P, Abensur D (1997) Maxillary sinus floor elevation for implant placement with demineralized freeze-dried bone and bovine bone (Bio-Oss): a clinical study of 20 patients. *Int J Periodontics Restorative Dent* 17:232–241
- Pinholt EM, Bang G, Haanaes HR (1991) Alveolar ridge augmentation in rats by Bio-Oss. *Scand J Dent Res* 99:1–7
- Wetzel AC, Stich H, Caffesse RG (1995) Bone apposition onto oral implants in the sinus area filled with different grafting materials. A histological study in beagle dogs. *Clin Oral Implants Res* 6:155–163
- Piattelli M, Favero GA, Scarano A, Orsini G, Piattelli A (1999) Bone reactions to anorganic bovine bone (Bio-Oss) used in sinus augmentation procedures: a histologic long-term report of 20 cases in humans. *Int J Oral Maxillofac Implants* 14(6):835–840
- Klinge B, Alberius P, Isaksson S, Jonsson J (1992) Osseous response to implanted natural bone mineral and synthetic hydroxylapatite ceramics in the repair of experimental skull bone defects. *Int J Oral Maxillofac Surg* 50:241–249
- Misch CE, Dietsch F (1994) Endosteal implants and iliac crest grafts to restore severely resorbed totally edentulous maxillae. A retrospective study. *J Oral Implantol* 20:100–110
- Tawill G, Mawla M (2001) Sinus floor elevation using a bovine bone mineral (Bio-Oss) with or without the concomitant use of a bilayered collagen barrier (Bio-Gide): a clinical report of immediate and delayed implant placement. *Int J Oral Maxillofac Implants* 16:713–721
- Valentini P, Abensur D, Densari D, Graziani JN, Hammerle C (1998) Histological evaluation of Bio-Oss in a 2-stage sinus floor elevation and implantation procedure. A human case report. *Clin Oral Implants Res* 9:59–64
- Hieu PD, Chung JH, Yim SB, Hong KS (2010) A radiographical study on the changes in height of grafting materials after sinus lift: a comparison between two types of xenogenic materials. *J Periodontal Implant Sci* 40:25–32
- Hatano N, Shimizu Y, Ooya K (2004) A clinical long-term radiographic evaluation of graft height changes after maxillary sinus floor augmentation with a 2:1 autogenous bone/xenograft mixture and simultaneous placement of dental implants. *Clin Oral Implants Res* 15:339–345





Corso di Laurea in Igiene Dentare  
Presidente: Prof. Enrico F. Gherlone



Centro di Igiene Orale e Prevenzione  
Direttore: Prof. Enrico F. Gherlone



## Analisi retrospettiva con follow-up massimo a sette anni di riabilitazioni implantoprotetiche con sistematica Winsix

P. Capparè\*, F. Bova, D. Defilippi, E. M. Polizzi, E. F. Gherlone

**Introduzione.** Il mantenimento a lungo termine dei risultati ottenuti attraverso percorsi riabilitativi impianto-protetici passa attraverso il rispetto di corretti protocolli chirurgici, protetici, merceologici e programmi di follow-up dei tessuti perimplantari.

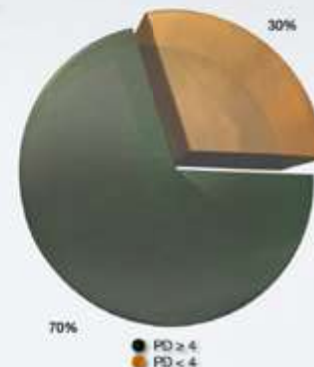
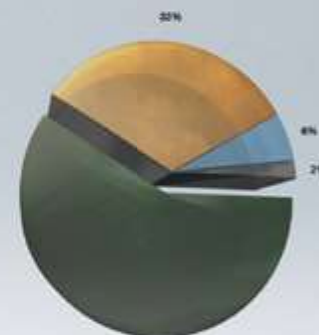
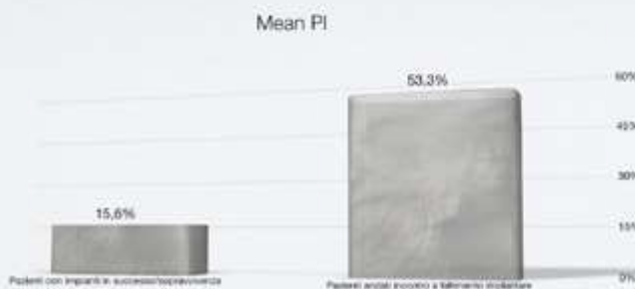
**Obiettivi.** L'obiettivo del presente studio è stato quello di valutare la salute perimplantare in pazienti sottoposti a riabilitazioni implantoprotetiche mediante sistematica Winsix con follow-up massimo a 7 anni (periodo Marzo 2006-Marzo 2013) presso il Dipartimento di Odontoiatria dell'Ospedale San Raffaele di Milano. Una parte dei pazienti inclusi sono stati sottoposti a successivo protocollo di mantenimento presso il Centro di Igiene Orale e Prevenzione (CIOP) dello stesso Dipartimento.

**Materiali e metodi.** Attraverso un'analisi dei dati registrati nel database digitale dell'unità di Chirurgia Implantare relativamente ai pazienti sottoposti a riabilitazioni implantoprotetiche con sistematica Winsix, sono stati selezionati per il presente studio retrospettivo 2761 impianti posizionati in 1172 pazienti, dei quali 942 sono stati sottoposti al programma di mantenimento perimplantare presso il CIOP. Questo ha permesso il monitoraggio di 2201 impianti: i restanti pazienti hanno interrotto o rifiutato il protocollo di mantenimento (drop-out 19,6%). Tutti gli impianti sono stati posizionati da 2 operatori. Oltre alle misurazioni dei parametri radiografici, per ogni impianto sono stati misurati i valori clinici maggiormente utilizzati in letteratura per valutare la salute dei tessuti perimplantari. In particolare, tra i parametri presi in considerazione, abbiamo misurato il Plaque Index, il Bleeding on Probing (BoP), il Probing Depth (PD). Tali dati sono stati successivamente analizzati mediante una metodologia statistica di tipo osservazionale.

**Risultati.** Dall'analisi complessiva dei risultati analizzati, la percentuale di sopravvivenza degli impianti posizionati è risultata del 97,8%, con una percentuale di fallimento del 2,2% dei casi. La percentuale di perimplantite è stata del 6,2% e di mucosite del 33%. I valori medi di BoP sono stati del 25,2% nei pazienti che non hanno perso impianti, mentre è stata del 61,9% nei pazienti che sono andati incontro a perdita implantare. I valori medi di PI sono risultati del 15,6% in pazienti che non hanno perso impianti, mentre è stata del 53,3% nei pazienti che sono andati incontro a perdita implantare. Per il PD, il 77% dei siti di sondaggio è risultato minore di 4 mm ed il 33% maggiore uguale a 4.

**Conclusioni.** L'applicazione di un protocollo di mantenimento implantare si conferma essere un efficace metodo per favorire la sopravvivenza implantare a medio e lungo termine. È inoltre necessario educare e motivare il paziente alle più appropriate tecniche di igiene orale domiciliare al fine di controllare il biofilm batterico, informarlo in merito ai fattori di rischio per il fallimento implantare e valutare l'esposizione del paziente ai stessi fattori di rischio. Sulla base di questi dati e dei parametri clinici misurati sarebbe appropriato stabilire un programma di mantenimento adeguato non solo per prevenire ed intercettare possibili problematiche implantari, ma anche per assicurare il più elevato livello di salute dei tessuti perimplantari.

Implants	2671 (in follow up 2201)
Patients	1172 (in follow up 942)
Cumulative Survival Rate	97,8% (Failed 58)



BIBLIOGRAFIA: von Marlow-Peice-Janssen, Christian Lindahl, Helena Renner and Stefan Renner "Five to fourteen year follow-up of implant treatment. Part I. Implant loss and association to various factors". J Oral Rehabilitation 2008; 35:285-296. Von Winkelhoff AJ, van der Aant PJ, Wismeijer D. Intraosseous consolidation with dental implants. New Technol Orthodol 2003; Apr; vol. 17(5): 183-187. Javed T, Lekholm U, Johansson CB. Bone response to implant-supported frameworks with differing degrees of mesh porosity in vivo study in rabbits. Clin Implant Dent Relat Res 2005;



winsix®

performing implant system

## ANALISI RETROSPETTIVA A OTTO ANNI DEGLI ESITI DI TRATTAMENTO IMPLANTO-PROTESICO ESEGUITI CON SISTEMA WINSIX®.

Autori: Dipartimento di Odontoiatria dell'Istituto Scientifico Universitario Vita Salute San Raffaele di Milano, dir. Prof. Enrico F. Gherlone.

**Materiali e Metodi.** Sono stati valutati 2998 impianti posizionati in 1354 pazienti tra marzo 2006 e marzo 2014 presso l'Unità Operativa Complessa di Odontoiatria dell'I.R.C.C.S. Ospedale San Raffaele di Milano. Di questi impianti, 2381 sono stati posizionati in 1271 pazienti che si sottopongono con regolarità a programma di mantenimento presso il Centro di Igiene Orale e Prevenzione attivo presso l'U.O.C. Odontoiatria (Grafico 1)

I restanti pazienti, invece, non hanno aderito al programma di mantenimento. Nei pazienti sottoposti a mantenimento è stato possibile rilevare, per ciascun impianto, l'insieme dei parametri clinici atti a valutare lo stato di salute del sito implantare: profondità di sondaggio (PPD), sanguinamento a sondaggio (BoP), segni radiografici di evidente riassorbimento osseo

perimplantare e mobilità.

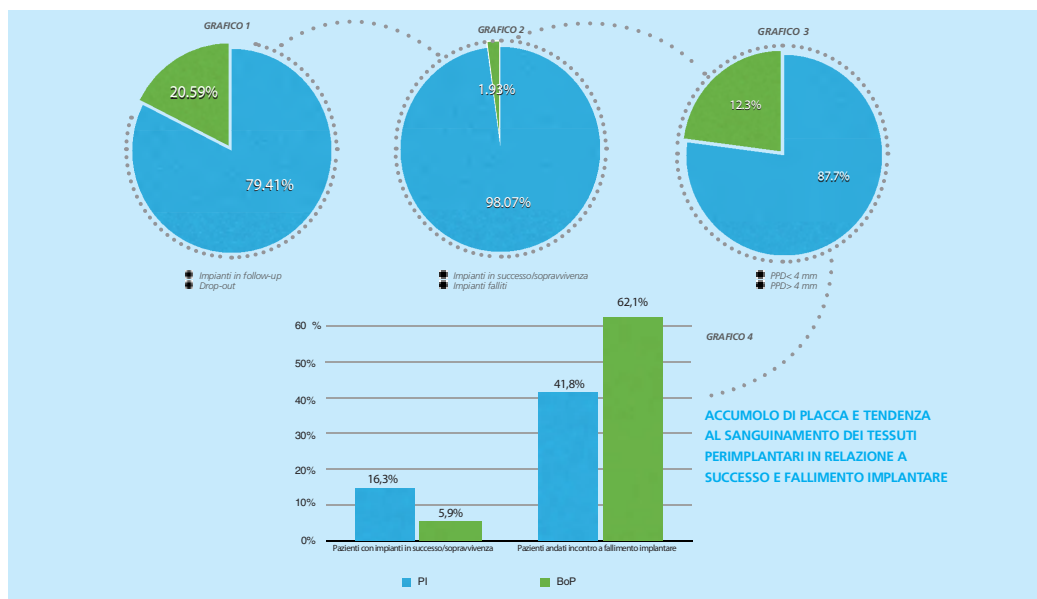
**Analisi dei dati.** Sul campione di 2998 impianti, l'1,93%, pari a 58 unità posizionate in 56 pazienti, sono andati incontro a fallimento, mostrando un dato percentuale di incidenza di insuccesso allineato ai valori osservabili in letteratura (Grafico 2).

È stato osservato come, tra i 58 impianti falliti, 14 erano stati posizionati in soggetti dediti al tabagismo e 35 in pazienti già colpiti da parodontite. Restringendo l'analisi solo ai pazienti sottoposti a follow-up, l'incidenza di fallimento scende al valore percentuale dell'1,3%, per totali 31 impianti. Sempre tra questi pazienti, il valore medio della PPD (Grafico 3), rilevato in quattro siti per ciascun impianto, si dimostra nel 87,7% dei casi < 4mm (8358 siti di sondaggio su 9524 complessivi).

**Analizzando infine i dati relativi** ai valori medi dell'indice di placca secondo O'Leary (PI) e di sanguinamento (BoP) nei pazienti in mantenimento, nei soggetti andati incontro a fallimento si è osservato per entrambi i parametri un valore medio nettamente più alto rispetto ai valori osservati tra coloro che invece mostrano buone condizioni di salute dei tessuti perimplantari: **nello specifico, tra i pazienti in buone condizioni di salute dei tessuti perimplantari il dato medio del PI è del 16,3% e per quanto riguarda il BoP del 5,9%. Nei pazienti andati incontro a fallimento implantare i valori medi si attestano invece, rispettivamente, al 41,8% ed al 62,1% (Grafico 4).**

**Conclusioni.** Nella ricerca del successo a lungo termine delle ri-

abilitazioni protesiche a supporto implantare, un programma di mantenimento calibrato in base alle **specifiche peculiarità del paziente** risulta essere un fattore fondamentale, in quanto occasione utile a fare prevenzione della patologia perimplantare ed a intercettare in fase precoce l'insorgenza di fenomeni infiammatori dei tessuti perimplantari e/o problematiche meccaniche dell'insieme implanto-protesico. L'abbattimento dell'incidenza di fallimento osservato in pazienti afferenti ad un tale programma di follow-up, pur in assenza di indagini relative ai fenomeni microbiologici alla base di questi risultati, può comunque essere ritenuto elemento probatorio dell'efficacia di un simile atteggiamento clinico.



## RIABILITAZIONI IMPLANTOPROTESICHE MEDIANTE IMPIANTI WINSIX® IN PAZIENTI DISABILI, FASCE SOCIALI DEBOLI E HIV POSITIVI: STUDIO PROSPETTICO COFINANZIATO DAL MINISTERO DELLA SALUTE

Autori: Dipartimento di Odontoiatria dell'Istituto Scientifico Universitario Vita Salute San Raffaele di Milano, dir. Prof. Enrico F. Gherlone.

Il Sistema implantare WINSIX® è stato il protagonista di uno studio clinico prospettico cofinanziato dal Ministero della Salute nel triennio 2008-2011, eseguito presso il Dipartimento di Odontoiatria dell'Istituto Scientifico Universitario Vita Salute San Raffaele di Milano, diretto dal Prof. Enrico Gherlone.

Il trial clinico, diretto dallo stesso Prof. Gherlone, ha avuto l'obiettivo di valutare la sopravvivenza, il successo e quindi l'efficacia di riabilitazioni implantoprotetiche in pazienti HIV positivi, e/o appartenenti a fasce sociali deboli, o disabili secondo la classificazione dell'Organizzazione Mondiale della Sanità (WHO).

Innanzitutto, è stato necessario impostare dei protocolli mirati, volti a definire in modo accurato i criteri di inclusione ed esclusione dei pazienti, soprattutto alla luce delle problematiche riguardanti le condizioni di salute orale e sistemica (ad esempio nei pazienti HIV positivi) e di scarsa collaborazione che in genere si affronta in questa particolare tipologia di pazienti.

Di conseguenza è stato necessario stabilire un tavolo di lavoro comprendente, oltre all'odontoiatra, altre figure professionali, tra le quali l'igienista dentale, l'infettivologo, il Medico Laboratorista, l'Internista, ecc.

In particolare gli infettivologi hanno avuto un ruolo importante nel determinare i parametri sistemici per monitorare lo stato del sistema immunitario dei pazienti HIV positivi e nel collaborare fattivamente nella selezione dei pazienti a minor rischio. Allo stesso tempo si è rilevato di fondamentale importanza il ruolo dell'igienista dentale, poiché, oltre alla valutazione dei parametri classici dello stato di salute orale del paziente, si è voluta applicare una maggiore attenzione nella motivazione del paziente all'igiene orale ed alla misurazione di parametri clinici efficaci, obiettivi e veloci da misurare (data la scarsa compliance dei pazienti selezionati).

Quindi è stato realizzato un protocollo di riabilitazione implanto-protesica e follow-up a medio termine in questa popolazione di pazienti.

**1 Maxillary sinus augmentation procedures through equine-derived biomaterial or calvaria autologous bone: immunohistochemical evaluation of OPG/RANKL in humans**

S. Tetè, R. Vinci, V.L. Zizzari, S. Zara, V. La Scala, A. Cataldi, E.F. Gherlone, A. Piattelli  
European Journal of Histochemistry Vol.57:e10 2013

---

**2 An In Vitro Evaluation of Heat Production during Osteotomy preparation for Dental Implants with compressive Osteotomes**

A. Quaranta, S. Andreana, L. Spazzafumo, M. Piemontese Implant Dentistry Vol.22 N°2 2013

---

**3 Riabilitazione dei mascellari edentuli:  
presentazione di una nuova tecnica software assistita**

M. Manacorda, R. Vinci, F. Bova, M. Nagni, E.F. Gherlone Doctor Os, Vol. XXIV - maggio 2013

---

**4 Airpolishing: protocollo sperimentale di studio in vitro per la gestione dei pazienti implantari affetti da mucosite e perimplantite**

P.P. Paganin - L'Igienista Moderno - Marzo 2013

---

**5 Terapia Implantare in Pazienti HIV positivi: studio clinico prospettico**

G. Gori, P. Capparé, A. Ligabue, A. Cardarelli, D. DeFilippi, M. Nagni, R. Vinci - Dental School (Dean Prof. Enrico F. Gherlone) Vita Salute University San Raffaele, Milano - Italy Sessione Poster - Collegio dei Docenti Roma 18-20 aprile 2013

---

**6 Un ausilio all'igiene orale in pazienti disabili**

E. M. Polizzi, A. Marchisio, M. Nagni, M. Roncati, A. Lucchese - Università Vita Salute San Raffaele, Milano - Corso di Laurea in Igiene Dentale - IRCCS Ospedale SR Unità Operativa complessa di Odontoiatria - Italy Sessione Poster - Collegio dei Docenti  
Collegio dei Docenti di Odontoiatria, Roma 18-20 aprile 2013

## Maxillary sinus augmentation procedures through equine-derived biomaterial or calvaria autologous bone: immunohistochemical evaluation of OPG/RANKL in humans

S. Tetè,<sup>1</sup> R. Vinci,<sup>2</sup> V.L. Zizzari,<sup>3</sup> S. Zara,<sup>3</sup> V. La Scala,<sup>4</sup> A. Cataldi,<sup>3</sup> E. Gherlone,<sup>2</sup> A. Piattelli<sup>1</sup>

<sup>1</sup>Department of Medical, Oral and Biotechnological Sciences, University "G. D'Annunzio", Chieti, Italy

<sup>2</sup>Department of Oral Science, University "Ateneo Vita – Salute" S. Raffaele, Milan, Italy

<sup>3</sup>Department of Pharmacy, University "G. D'Annunzio", Chieti, Italy

<sup>4</sup>Private practice, Pistoia, Italy

### Abstract

Autologous bone is considered the *gold standard* for bone regeneration, even if different heterologous bone substitutes have been proposed to overcome the limits related to its use. The aim of this study was to analyze and to compare the molecular events switched on by autologous or heterologous bone graft insertion, focusing on TGF $\beta$ 1 expression and OPG/RANKL ratio, to analyze resorption process, and estimating graft vascularization, new bone tissue deposition and its mineralization, through VEGF, BSP and SPARC expression evaluation, respectively. Patients needing pre-prosthetic rehabilitation of the posterior maxilla were treated using an equine-derived biomaterial (Group 1) or calvaria autologous bone (Group 2), according to the morphology of the bone defect. Bone graft integration was evaluated on bone samples obtained from the treated areas at the moment of dental implant insertion, by morphological and immunohistochemical analyses for TGF $\beta$ 1, OPG, RANKL, VEGF, BSP, and SPARC expression. Morphological analysis shows the presence of biomaterial residual granules in Group 1, in parallel to a good integration between graft and host tissue. Moderate TGF $\beta$ 1 expression is seen in both Group 1 and Group 2. OPG/RANKL ratio appear higher in Group 1; VEGF expression appears very strong in Group 1 and strong in Group 2, while BSP and SPARC expression results weak in Group 1 and moderate in Group 2. Results reveal the good integration between both types of graft and the host tissue, even though autologous graft seems to produce a faster regenerative process, as evidenced by the different expression of the investigated

molecules. According to these observations, the clinical use of heterologous particulate equine-derived biomaterial may ensure long-term predictability of implant-prosthetic rehabilitation, comparable to that obtained with autologous bone graft.

### Introduction

The use of regenerative procedures before implant-prosthetic oral rehabilitation is required to counteract vertical and horizontal bone loss and, mostly, to obtain an adequate bone quantity and quality to ensure primary stability at implant insertion. Several bone grafting materials were proposed for bone regeneration, such as autogenous, allogenic and xenogenic biomaterials, or a combination of them and, as the biological response of host tissue can be related to biomaterial origin, attention was focused on the interactions occurring between grafts and host tissue.<sup>1,2</sup> As already reported by Mangano et al., heterologous biomaterials were found to be as clinically efficient as autologous bone for their capacity of osteoconduction, even if little is known about their capability to be resorbed, and about the time they need to be fully replaced by newly formed bone tissue.<sup>3</sup> In fact, a biomaterial showing a too rapid resorption rate may result unsuitable for bone augmentation procedures, because it could be completely resorbed before osteogenic cells have colonized the defect; on the other hand, a biomaterial showing no resorption could cause problems to the regeneration of bone with a lower osteogenesis ability in respect to native autologous bone.<sup>4,5</sup>

In literature, only a few studies were reported about the use of an equine-derived bone substitute, which seems to be able to induce osteoblast differentiation, to be resorbed in vitro by osteoclasts and to be successfully used in mandibular ridge augmentation.<sup>6,7</sup> Moreover, the integration of a bone graft results in a remodeling process similar to the physiological bone healing event following a bone fracture.<sup>8</sup> Bone remodeling occurs through different steps, which start from a lesion of the vascular structure at the site of the injury reducing the supply of nutrients and determining an initial bone resorption. The hematoma generated activates signaling molecules and growth factors, which stimulate proliferation and differentiation of osteo-progenitor cells. Among them, Transforming Growth Factor- $\beta$  (TGF- $\beta$ ) superfamily and angiogenic factors are included. In particular, TGF $\beta$ 1 is essential for osteoblastic differentiation of mesenchymal precursors, it induces the synthesis of bone morphogenetic proteins (BMPs) and promotes osteoid and extracellular protein production such as collagen, osteopontin and osteonectin.<sup>9</sup> Moreover, TGF- $\beta$ 1 is

Correspondence: Dr. Susi Zara, Department of Pharmacy, University "G. D'Annunzio", via dei Vestini 31, 66100 Chieti Scalo (CH), Italy. Tel./Fax: +39.0871.3554507. E-mail: s.zara@unich.it

Key words: osteoconduction, OPG/RANKL ratio, biomaterial resorption, integration bone graft, calvaria, equine-derived biomaterial

Acknowledgments: the authors wish to thank FIRB-Accordi di Programma 2010 Project *Processi degenerativi dei tessuti mineralizzati del cavo orale, impiego di biomateriali e controllo delle interazioni con i microrganismi dell'ambiente*, Prof A. Cataldi, for the fellowship attributed to Dr. V. L. Zizzari.

Received for publication: 12 November 2012.  
Accepted for publication: 29 December 2012.

This work is licensed under a Creative Commons Attribution NonCommercial 3.0 License (CC BY-NC 3.0).

©Copyright S. Tetè et al., 2013  
Licensee PAGEPress, Italy  
European Journal of Histochemistry 2013; 57:e10  
doi:10.4081/ejh.2013.e10

an important factor for osteoclasts and osteoblasts coupling: in fact, it not only promotes the recruitment of hematopoietic osteoclast precursors, but also shows an inhibitory effect on bone resorption and stimulates the production of osteoprotegerin (OPG).<sup>10</sup>

OPG is expressed by osteoblasts and regulates bone homeostasis by inhibiting osteoclastogenesis and bone resorption.<sup>11</sup> OPG, binding to RANKL on osteoblast/stromal cells, blocks the RANKL/RANK interaction between osteoblast/stromal cells and osteoclast precursors, inhibiting osteoclast precursor differentiation, reducing osteoclast production and regulating osteoclast-mediated resorption.<sup>12</sup> Moreover, in such processes a main role is also played by angiogenic factors, among which Vascular Endothelial Growth Factor (VEGF) is included. VEGF is produced by endothelial cells and osteoblasts and is involved in early bone remodeling phases since it controls osteoblast growth.<sup>13</sup>

The early phases of bone graft integration are followed by remodeling phenomena driven by molecules produced by osteoblasts, as Bone Sialoprotein (BSP) and Secreted Protein Acidic and Rich in Cysteine (SPARC), leading to new extracellular matrix deposition and to its subsequent mineralization. BSP is a component of the extracellular matrix which plays important functions in the regulation of new bone apposition and remodeling. BSP expression is up-regulated by factors inducing osteoblast differentiation, released by active osteogenic cells at the site of new bone formation, even though it has also been shown to



promote osteoclastic resorption of mineralized surfaces.<sup>14,15</sup>

SPARC, also known as osteonectin, is a collagen-binding glycoprotein that appears to regulate cell growth through interactions with extracellular matrix (ECM) and cytokines.<sup>16</sup> It is secreted by osteoblasts during bone formation, initiating a mineralization process and promoting mineral crystal formation. It is a modulator of the mineralizing process, essential for bone graft integration, such as the bone healing around dental implants.<sup>17</sup>

Based on this knowledge, the aim of our work was to analyze and to compare the molecular events switched on by autologous or heterologous bone graft insertion, focusing our attention on TGFβ1 expression and OPG/RANKL ratio, to analyze resorption process, and to estimate bone graft vascularization, new bone formation and its mineralization, through VEGF, BSP and SPARC expression evaluation, respectively. By understanding the mechanism underlying graft integration and by comparing the results obtained with the use of the heterologous bone substitute to that obtained with the use of autologous bone it should be verified if equine-derived bone substitute possesses characteristic, which may permit a good integration with the host bone tissue, thus clinically ensuring an adequate primary stability to the implant and predictability of the implant-prosthetic rehabilitation.

## Materials and Methods

### Patients selection

Twenty patients (13 males, 7 females; age ranging 45-58) with inadequate bone volume in the posterior maxilla, were scheduled for bone augmentation procedures followed by implant placement. The patients were divided into two groups (n=10), according to the severity and morphology of the bone defect, mirroring Classes C and F of the Chiapasco's Classification of the Posterior Maxilla (Table 1).<sup>18</sup> All patients received sufficient information about the inclusion in this study and gave written consent in accordance with Italian Legislation and with the code of Ethical Principles for Medical Research involving Human Subjects of the World Medical Association (Declaration of Helsinki). Ten patients (8 males, 2 females; age ranging 45-54), having Class C bone defects, underwent maxillary sinus augmentation procedure with a bone substitute of equine origin (BioBone® Osteoconductor Mix, BioSAF IN S.r.l., Ancona, Italy) (Group 1), and ten patients (5 males, 5 females; age ranging 46-58), with Class F bone defects, received an onlay bone graft and a maxillary sinus augmentation procedure with

bone obtained from the parietal region of the calvaria (Group 2).

BioBone® Osteoconductor Mix is a resorbable, collagen-deprived, and deantigenated osteoconductive biomaterial, obtained after a biological process of deantigenation at 37°C in a humid atmosphere, made up of a cortico-cancellous mixture of equine origin (particles width 0.5-1 mm). The autologous bone blocks from the parietal region of calvaria were taken from calvaria under general anesthesia by a piezoelectric instrument (Easy Surgery®, BioSAF IN S.r.l., Ancona, Italy), shaped according to the dimension of the defects, properly fitted in the recipient site, and fixed with lag screw to rebuild the alveolar ridge. All gaps between the bone blocks and the recipient sites and the maxillary sinus were packed with bone chips obtained from the same donor site, and the grafted areas covered with a resorbable barrier (Biobone® Collagen Membrane, BioSAF IN S.r.l.).

Post-operative healing was uneventful for all the patients, and therefore, after about 6

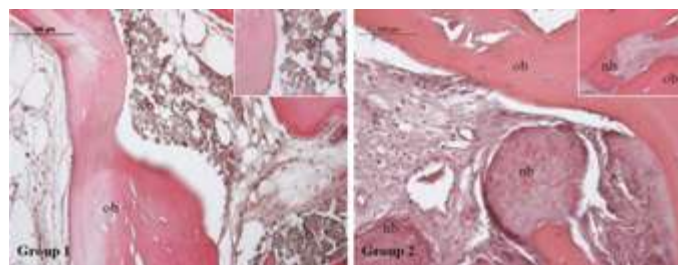
months they were scheduled for a second surgery for implant placement. Contextually the intervention of implant insertion, bone samples were retrieved by a 3 mm-diameter and 8 mm-height trephine bur under sterile saline solution irrigation in the sites of implant placement, in order to obtain significant specimens of bone regenerated with heterologous bone substitute in Group 1 patients, while in Group 2 patients bone samples were obtained from the lateral maxillary wall between the sites of implant placement.

### Light microscopy analysis and immunohistochemistry

Samples of bone tissues were fixed in 10% phosphate-buffered formalin for 24 h, and decalcified in 10% tetrahydrated EDTA, according to data sheet (MIELODEC kit, Bio-Optica, Milan, Italy). Subsequently, they were dehydrated through ascending alcohols and xylene, and then paraffin embedded. Samples were de-waxed (xylene and alcohol at progressively

**Table 1. Chiapasco's classification of the posterior maxilla.**

Class	Height of the residual ridge	Thickness of the residual ridge	Interarch distance
A	>5 mm <8 mm	≥6 mm	Normal
B	>5 mm <8 mm	<6 mm	Normal
C	<5 mm	≥6 mm	Normal
D	<5 mm	<6 mm	Normal
E	>5 mm <8 mm	≥6 mm	Increased
F	>5 mm <8mm	<6 mm	Increased
G	<5 mm	≥6 mm	Increased
H	<5 mm	<6 mm	Increased
I	Completely resorbed alveolar ridge with increased distance interarch and Class III skeletal relationships		



**Figure 1. Hematoxylin and eosin staining of Group 1 and Group 2 specimens. Magnification 20x. Group 1: bone tissue specimens obtained from equine-derived bone substitute grafted area; Group 2: bone tissue specimens obtained from calvaria bone grafted area. Inset (40x) shows, in group 1 specimens, grafted biomaterial particles, in group 2 specimens, large mineralized areas within which newly formed bone can be recognized because of osteocyte lacunae lack and absence of lamellar organization; xb, xenogenous bone; ob, old bone; nb, new bone.**



## Original Paper



decreasing concentrations), sliced 5  $\mu\text{m}$  thick and processed for hematoxylin-eosin staining and for immunohistochemical analysis.

In order to detect TGF $\beta$ 1, OPG, RANKL, VEGF, BSP, and SPARC proteins, immunohistochemistry was performed on 5  $\mu\text{m}$ -thick sections by means of Ultravision LP Detection System HRP Polymer & DAB Plus Chromogen (Lab Vision Thermo, CA, USA). To reduce non-specific background staining due to endogenous peroxidase, sections were incubated with hydrogen peroxidase block solution for 10 min. Slides were then incubated in the presence of mouse anti-TGF $\beta$ 1, anti-RANKL and anti-SPARC monoclonal antibodies, and rabbit anti-VEGF polyclonal antibody (Santa Cruz Biotechnology, Santa Cruz, CA, USA), mouse anti-OPG monoclonal antibody (Acris Antibodies, Herford, Germany), and mouse anti-BSP monoclonal antibody (Calbiochem, Darmstadt, Germany).

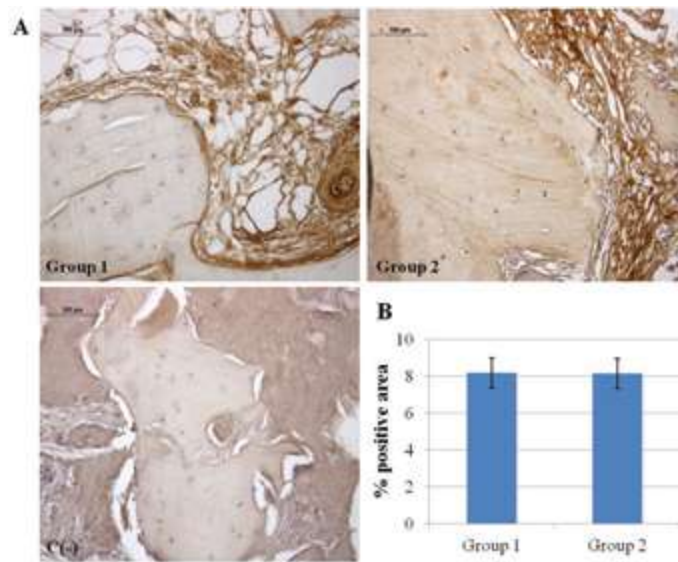
Sections were incubated in the presence of specific HRP-conjugated secondary antibodies. Peroxidase was developed using diaminobenzidine chromogen (DAB), and nuclei were hematoxylin counterstained. Negative controls were performed by omitting the primary antibody. Randomly selected slides belonging to each sample were then observed by means of Leica DM 4000 light microscopy (Leica Cambridge Ltd, Cambridge, UK), equipped with a Leica DFC 320 camera (Leica Cambridge Ltd) for computerized images.

#### Computerized morphometry measurements and image analysis

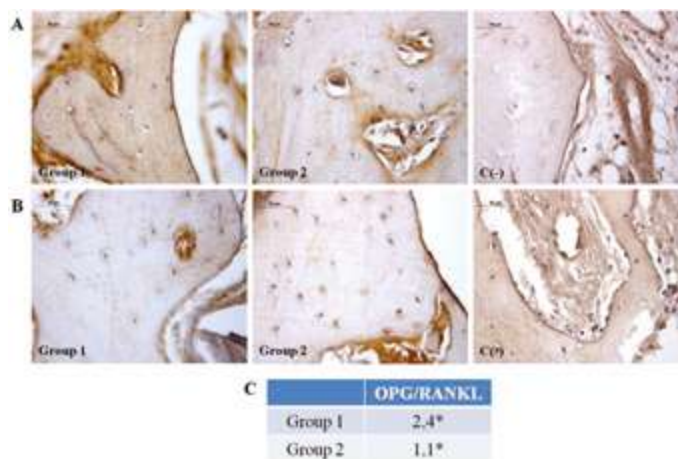
After digitizing the images obtained from the immunohistochemical stained sections, QWin Plus 3.5 software (Leica Cambridge Ltd) was used to evaluate TGF $\beta$ 1, OPG, RANKL, VEGF, BSP and SPARC expression. Image analysis of protein expression was performed through the quantification of immunohistochemical brown chromogen, expressed as percentage of positive area respect to total area of the field, as an average value per ten fields, randomly chosen, for each sample at light microscope observation.

Moreover, intensity of staining (IS) was graded on a scale of 0-4, according to the following assessments: 0, no detectable staining; 1, weak staining; 2, moderate staining; 3, strong staining; 4, very strong staining, as previously reported.<sup>19</sup> The positive immunolabeling for TGF $\beta$ 1, OPG, RANKL, and VEGF was cytoplasmic; the positive immunolabeling for BSP and SPARC was in the pericellular space.

Quantification of immunohistochemical brown chromogen was performed at 20x magnification by three different researchers, and the final result was a mean value of the three separate evaluations. Cohen's kappa coefficient was applied to measure the agreement between the three observers and averaged over all three to evaluate overall agreement using



**Figure 2.** A) Immunohistochemical analysis of TGF $\beta$ 1 expression in Group 1 and Group 2 specimens. Magnification 20x. Group 1: bone tissue specimens obtained from equine-derived bone substitute grafted area; Group 2: bone tissue specimens obtained from calvaria bone grafted area; C(-), negative control. Moderate TGF $\beta$ 1 immunolabeling of both Group 1 and Group 2 bone tissue; no TGF $\beta$ 1 immunostaining is seen in negative control. B) Graphic representation of densitometric analysis of TGF $\beta$ 1 positive area  $\pm$  SD, determined by direct visual counting of ten fields (mean values) for each of five slides per specimens at 20x magnification.



**Figure 3.** A) Immunohistochemical analysis of OPG expression in Group 1 and Group 2 specimens. Moderate OPG immunolabeling in Group 1 and weak OPG immunolabeling in Group 2 bone tissue; no OPG immunostaining is seen in negative control. B) Immunohistochemical analysis of RANKL expression, in Group 1 and Group 2 specimens, respectively. Magnification 40x. Group 1: bone tissue specimens obtained from equine-derived bone substitute grafted area; Group 2: bone tissue specimens obtained from calvaria bone grafted area; C(-), negative control. Weak RANKL immunolabeling in both Group 1 and Group 2 bone tissue; no RANKL immunostaining is seen in negative control. C) OPG/RANKL ratio values.



the following grading: 0-0.2 (slight), 0.21-0.40 (fair), 0.41-0.60 (moderate), 0.61-0.80 (substantial), and 0.81-1.0 (almost perfect)<sup>20</sup>.

Negative control images were randomly chosen. The statistical significance of the results was evaluated by the Wilcoxon, Mann-Whitney Test, using R Software, ver. 2.12.1 for Mac and setting  $P=0.05$ . After collecting results, the mean data were reported and showed in an histogram using Excel 2010 for Microsoft Windows.

## Results

### Light microscopy analysis and immunohistochemistry

Morphological analysis was performed at light microscope after hematoxylin-eosin staining (Figure 1). In Group 1 specimens the native bone tissue and connective tissue fibers could be identified. Moreover, the grafted bio-material particles were easily distinguished (purple areas) due to their lack of tissue structure, as better shown by the inset. Group 2 sample showed large mineralized areas close to dense areas of connective tissue, within which newly formed bone was recognizable because of osteocyte lacunae lack and absence of lamellar organization (inset). Molecular modifications occurring after bone substitutes placement, concerning their ability to be integrated and to be clinically suitable, were then investigated by immunohistochemical analysis. TGF- $\beta$ 1 expression, essential for osteoblastic differentiation and osteoid and extracellular proteins production, did not show any statistically significant difference between the two experimental groups (Figure 2); in fact, moderate TGF- $\beta$ 1 immunolabeling is seen both in Group 1 and Group 2. Moreover, since TGF- $\beta$ 1 stimulates OPG production, inhibiting the RANKL/RANK interaction, OPG and RANKL expressions were checked. Moderate OPG immunolabeling is found in Group 1 and weak OPG immunolabeling in Group 2, whereas weak RANKL immunolabeling is seen both in Group 1 and Group 2. The OPG/RANKL ratio was higher than 1 in both groups. However, Group 1 samples showed a mean ratio of about four fold higher than that observed in Group 2 specimens (2.4 *vs* 1.1), due to the concomitant increase of OPG and a significant decrease of RANKL expression in samples from sites regenerated with the equine-derived bone substitute (Figure 3). When the expression of VEGF, an angiogenic factor involved in early bone remodeling phases, was evaluated finding very strong VEGF immunolabeling in Group 1 and strong VEGF immunolabeling in Group 2 (Figure 4) ( $P<0.05$ ).

Finally, new bone formation and bone mineralizing processes were assessed taking into

Original Paper

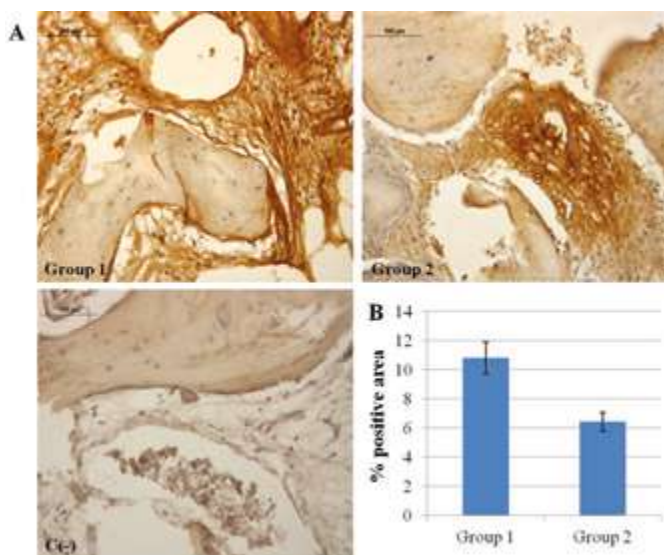


Figure 4. A) Immunohistochemical analysis of VEGF expression in Group 1 and Group 2 specimens. Magnification 20x. Group 1: bone tissue samples obtained from equine-derived bone substitute grafted area; Group 2: bone tissue specimens obtained from calvaria bone grafted area; C(-), negative control. Very strong VEGF immunolabeling in Group 1 and strong VEGF immunolabeling in Group 2 bone tissue; no VEGF immunostaining is seen in negative control. B) Graphic representation of densitometric analysis of VEGF positive area  $\pm$  SD determined by direct visual counting of ten fields (mean values) for each of five slides per specimens at 20x magnification ( $*P<0.05$ ).

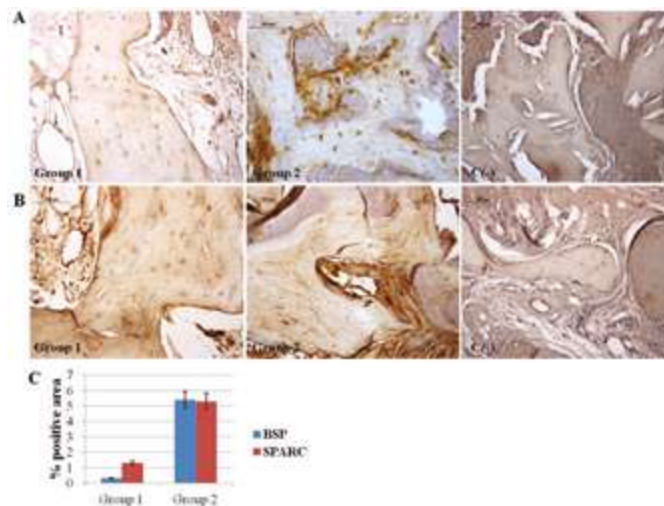


Figure 5. A) Immunohistochemical analysis of BSP expression in Group 1 and Group 2 specimens, respectively. Weak BSP immunolabeling in Group 1 and moderate BSP immunolabeling in Group 2 bone tissue; no BSP immunostaining is seen in negative control. B) Immunohistochemical analysis of SPARC expression, in Group 1 and Group 2 specimens, respectively. Magnification 20x. Group 1: bone tissue specimens obtained from equine-derived bone substitute grafted area; Group 2: bone tissue specimens obtained from calvaria bone grafted area; C(-), negative control. Weak SPARC immunolabeling in Group 1 and moderate SPARC immunolabeling in Group 2 bone tissue; no SPARC immunostaining is seen in negative control. C) Graphic representation of densitometric analysis of BSP and SPARC positive area  $\pm$  SD determined by direct visual counting of ten fields (mean values) for each of five slides per specimens at 20x magnification ( $*P<0.001$ ;  $**P<0.001$ ).





## Original Paper



consideration BSP and SPARC expression levels, respectively. Weak BSP immunolabeling in Group 1 and moderate BSP immunolabeling in Group 2 is seen, whereas weak SPARC immunolabeling in Group 1 and moderate SPARC immunolabeling in Group 2 is evidenced ( $P < 0.001$ ) (Figure 5). For all densitometric evaluations, interobserver agreement, measured using the Kappa coefficient, was 0.90 (almost perfect).

## Discussion

Regenerative procedures employing autologous, homologous or heterologous bone grafts lead to bone defect repair through different biological mechanisms. The very good results obtained with the use of autologous bone grafts were widely demonstrated.<sup>21,22</sup> Histological and clinical studies showed the possibility to have predictable results with the use of calvaria bone grafts, with no inflammatory phenomena and a minimum resorption rate during the healing period, along with a high rate of clinical success for the subsequent implant rehabilitation.<sup>23</sup>

Clinicians are constantly searching for a heterologous bone substitute that combines the osteo-regenerative features of autologous bone eliminating the limits imposed by the need for a second surgery. Most of the currently used heterologous grafts do not show ideal characteristics for bone regeneration such as osteogenic, osteoinductive and angiogenic potentials, biological safety, no size restrictions, long shelf life and reasonable cost.<sup>24</sup>

The present study aimed to evaluate, by morphological and immunohistochemical analyses, an equine bone substitute and an autologous bone graft, 6 months after the graft placement, in terms of ability of integration with the host tissue. The graft integration process is in part similar to bone fracture healing.<sup>8</sup> Complete healing is obtained during the remodeling phase, when osteoblasts and osteoclasts cooperate to convert the callus of a fracture in a definitive functional bone structure. Bone resorption and formation events are tightly coordinated and balanced in healthy bone.<sup>25</sup> For this reason, the first step of our study was to evaluate TGF $\beta$ 1 expression, as its role in osteoblast/osteoclast coupling was demonstrated.<sup>10</sup> Both Group 1 and Group 2 show a discrete TGF $\beta$ 1 expression, suggesting that bone remodeling phenomena occurred in all the grafted areas. To better elucidate the host tissue response to the different bone substitutes, attention was focused on the OPG/RANKL ratio, often used as a bone resorption index.<sup>11</sup> In fact, OPG, by inhibiting the RANKL/RANK binding, protects osteoclast-mediated bone resorption acting on osteoclasts differentiation from precursors.<sup>8</sup> Recent

studies showed an increasing expression and activity of RANKL in bone pathologies characterized by bone resorption such as osteoporosis and osteoarthritis, and a compensatory increase of OPG in bone diseases, such as Paget's syndrome, in which an anomalous higher bone formation takes place.<sup>25</sup>

The balance between RANKL and OPG controls the osteoclast activity and undergoes an endocrine regulation. In fact, it is usually preferable to evaluate OPG/RANKL ratio rather than OPG and RANKL absolute values. Thus an OPG/RANKL ratio  $< 1$  suggests a RANKL predominant activity, and, as a consequence, bone resorption events are predominant; on the other hand an OPG/RANKL ratio  $> 1$  reveals OPG greater activity and predominant in new bone formation processes.<sup>26</sup> The specimens of both groups show an OPG/RANKL ratio  $> 1$ , suggesting that the bone protection process was predominant on RANKL/RANK cascade activation. However, the lower values of Group 2 specimen led us to hypothesize that the integration between host bone and autologous graft could be at a more advanced stage in respect to Group 1 specimens, since the occurrence of bone resorption and new bone apposition phenomena was nearer to balance in Group 2. This evidence is also confirmed by morphological analysis, that reveals a stronger integration between host tissue and bone graft in Group 2 specimens while, on the contrary, in Group 1 specimens some of the equine-derived biomaterial particles are still evident and few newly formed mineralized tissue areas can be observed.

In order to support these morphological aspects, angiogenesis, new bone formation and mineralization processes were evaluated, by investigating VEGF, BSP, and SPARC expression, respectively. Angiogenesis has a crucial role in the regulation of bone remodeling and repair.<sup>27</sup> New blood vessel formation is essential to allow circulating osteoclast and osteoblast precursors to move towards the site of remodeling.<sup>28</sup> Moreover, VEGF supports osteoblast growth in the initial phase of bone graft integration.<sup>13</sup> In our study, VEGF expression is higher in Group 1 specimens indicating that intense neo-angiogenic phenomena were occurring in heterologous bone grafted sites, six months after the maxillary sinus augmentation procedure. This evidence could point to the fact that in autologous bone grafts this phase was already ended. In previous reports from our laboratory, in fact, extra-oral autologous bone grafts, showing an intense angiogenesis phenomena four months after grafting, with VEGF values significantly higher than in native bone tissue were found.<sup>29</sup>

Furthermore, the expression of molecules, such as BSP and SPARC, index of graft consolidation involved in new bone formation and mineralizing activity, indicate that sites treated with calvaria bone graft seemed to reach

earlier a higher stage of mineralization compared to the equine bone grafted specimens.

Such results led us to conclude that host bone tissue, undergoing regenerative phenomena, positively reacted to the placement of both biomaterials. In particular, the equine-derived biomaterial shows good characteristics, in terms of both clinical and microscopic integration. However, at the same experimental time, sites treated with autologous bone clearly show a better organization, which could ensure a better primary stability to the implant and a higher predictability of the implant-prosthetic rehabilitation. In addition, in sites treated with autologous bone, a balance between matrix deposition and resorption is observed, suggesting that the regenerative process shows a higher rate of progression, than in sites treated with the equine bone graft in which this process seems to be slower.

## References

- Jensen OT, Shulman LB, Blocks MS, Iacono VJ. Report of the sinus consensus conference of 1996. *Int J Oral Max Impl* 1998;13:11-45.
- Tetè S, Zara S, Vinci R, Zizzari V, Di Tore U, Mastrangelo F, et al. Vascular endothelial growth factor and e-nitric oxide synthase-mediated regenerative response occurring upon autologous and heterologous bone grafts. *Int J Immunopathol Pharmacol* 2009;22:1105-16.
- Mangano C, Scarano A, Iezzi G, Orsini G, Perrotti V, Mangano F, et al. Maxillary sinus augmentation using an engineered porous hydroxyapatite: a clinical, histological, and transmission electron microscopy study in man. *J Oral Implantol* 2006;32:122-31.
- Hallman M, Lundgren S, Sennerby L. Histologic analysis of clinical biopsies taken 6 months and 3 years after maxillary sinus floor augmentation with 80% bovine hydroxyapatite and 20% autogenous bone mixed with fibrin glue. *Clin Implant Dent R* 2001;3:87-96.
- Mordenfeld A, Hallman M, Johansson CB, Albrektsson T. Histological and histomorphometrical analyses of biopsies harvested 11 years after maxillary sinus floor augmentation with deproteinized bovine and autogenous bone. *Clin Oral Implan Res* 2010;21:961-70.
- Di Stefano DA, Artese L, Iezzi G, Piattelli A, Pagnutti S, Piccirilli M, et al. Alveolar ridge regeneration with equine spongy bone: a clinical, histological, and immunohistochemical case series. *Clin Implant Dent R* 2009;11:90-100.
- Perrotti V, Nicholls BM, Piattelli A. Human osteoclast formation and activity on an



- equine spongy bone substitute. *Clin Oral Implan Res* 2009;20:17-23.
8. Dimitriou R, Jone, E, McGonagle D, Giannoudis PV. Bone regeneration: current concepts and future directions. *BMC Med* 2011;9:66.
  9. Lieberman JR, Daluiski A, Einhorn TA. The role of growth factors in the repair of bone. Biology and clinical applications. *J Bone Joint Surg Am* 2002; 84: 1032-1044.
  10. Quinn JMW, Itoh K, Udagawa N, Hausler K, Yasuda H, Shima N, et al. Transforming growth factor  $\beta$  affects osteoclast differentiation via direct and indirect actions. *J Bone Min Res* 2001;16:1787-94.
  11. Trouvin AP, Goëb V. Receptor activator of nuclear factor- $\kappa$ B ligand and osteoprotegerin: maintaining the balance to prevent bone loss. *Clin Interv Aging* 2010;5:345-54
  12. Khosla S. Minireview: the OPG/RANKL/RANK system. *Endocrinology* 2001;142:5050-55.
  13. Gerber HP, Vu TH, Ryan AM, Kowalski J, Werb Z, Ferrara N. VEGF couples hypertrophic cartilage remodeling, ossification and angiogenesis during endochondral bone formation. *Nat Med* 1999;5:623-28.
  14. Raynal C, Delmas PD, Chenu C. Bone sialoprotein stimulates in vitro bone resorption. *Endocrinology* 1996;137:2347-2354.
  15. Malaval L, Wade-Guéye NM, Boudiffa M, Fei J, Zirngibl R, Chen F, et al. Bone sialoprotein plays a functional role in bone formation and osteoclastogenesis. *J Exp Med* 2008;205:1145-53.
  16. Boudiffa M, Wade-Gueye NM, Guignandon A, Vanden-Bossche A, Sabido O, Aubin JE, et al. Bone sialoprotein deficiency impairs osteoclastogenesis and mineral resorption in vitro. *J Bone Min Res* 2010;25:2669-79.
  17. Alford AI, Hankenson KD. Matricellular proteins: Extracellular modulators of bone development, remodeling, and regeneration. *Bone* 2006;38:749-57.
  18. Misch CE, Chiapasco M, Jensen OT. Indications for and Classification of Sinus Bone Grafts. In: Jensen OT, ed. *The Sinus Bone Graft*. Quintessence Publishing Co, 2006.
  19. Musumeci G, Loreto C, Carnazza ML, Coppolino F, Cardile V, Leonardi R. Lubricin is expressed in chondrocytes derived from osteoarthritic cartilage encapsulated in poly (ethylene glycol) diacrylate scaffold. *Eur J Histochem*. 2011;55:e31.
  20. Musumeci G, Carnazza ML, Loreto C, Leonardi R, Loreto C.  $\beta$ -defensin-4 (HBD-4) is expressed in chondrocytes derived from normal and osteoarthritic cartilage encapsulated in PEGDA scaffold. *Acta Histochem*. 2012;114:805-12.
  21. Crespi R, Vinci R, Capparè P, Gherlone E, Romanos GE. Calvarial versus iliac crest for autologous bone graft material for a sinus lift procedure: a histomorphometric study. *Int J Oral Max Impl* 2007;22:527-32.
  22. Gutta R, Waite PD. Outcomes of calvarial bone grafting for alveolar ridge reconstruction. *Int J Oral Max Impl* 2009;24:131-36.
  23. Tetè S, Vinci R, Zara S, Zizzari V, Cataldi A, Mastrangelo F, et al. Atrophic jaw reconstruction by means of calvarial bone graft: long-term results. *J Craniofac Surg* 2010;21:1147-52.
  24. Fröhlich M, Grayson WL, Wan LQ, Marolt D, Drobnic M, Vunjak-Novakovic G. Tissue engineered bone grafts: biological requirements, tissue culture and clinical relevance. *Curr Stem Cell Res Ther* 2008;3:254-64.
  25. Alvarez L, Peris P, Guanabens N, Vidal S, Ros I, Pons F, et al. Serum osteoprotegerin and its ligand in Paget's disease of bone: relationship to disease activity and effect of treatment with bisphosphonates. *Arthritis Rheum-US* 2003;48:824-28.
  26. Fonseca JE, Cortez-Dias N, Francisco A, Sobral M, Canhão H, Resende C, et al. Inflammatory cell infiltrate and RANKL/OPG expression in rheumatoid synovium: comparison with other inflammatory arthropathies and correlation with outcome. *Clin Exp Rheumatol* 2005;23:185-92.
  27. Gerstenfeld LC, Cullinane DM, Barnes GL, Graves DT, Einhorn TA. Fracture healing as a post-natal developmental process: molecular, spatial, and temporal aspects of its regulation. *J Cell Biochem* 2003;88:873-84.
  28. van Oers RF, Ruimerman R, Tanck E, Hilbers PA, Huiskes R. A unified theory for osteonal and hemi-osteonal remodeling. *Bone* 2008;42:250-59.
  29. Tetè S, Vinci R, Zara S, Zizzari V, De Carlo A, Falco G, et al. Long-term evaluation of maxillary reconstruction by iliac bone graft. *J Craniofac Surg* 2011;22:1702-7.



## An *In Vitro* Evaluation of Heat Production During Osteotomy Preparation for Dental Implants With Compressive Osteotomes

A. Quaranta, DDS, PhD,\* S. Andreana, DDS, MS,† L. Spazzafumo, MD,‡ and M. Piemontese, MD, DDS§

AU4

Excessive trauma during surgery is considered an important cause of implant failure because of thermal vascular and mechanical factors that contribute to the formation of necrotic tissue, thereby affecting the maturation of tissue at the bone-implant interface.<sup>1-4</sup> Repeated use of cutting tools progressively increase their wear and decrease their cutting efficiency, thus producing more friction heat. Excessive heat production caused by worn drills can result in failure to achieve osseointegration.<sup>5,6</sup> It has also been proven that heat production and, with it, the potential for damage increase with the depth of osteotomy.<sup>7</sup> An osteotome is a surgical tool used for bone cutting or marking.<sup>8</sup> Dental osteotomes are hand surgical instruments that can form and shape bone preparation for the placement of dental implants.<sup>9,10</sup> Bone density is directly proportional to the percent of bone-implant surface contact, which is one of the critical determinants of implant success. The posterior maxilla shows often a D3, D4 bone density

\*Adjunct Professor, Master in Periodontics and School of Dentistry, Università Politecnica delle Marche, Ancona, Italy.  
†Associate Professor and Director of the Implant Dentistry School of Dental Medicine, University at Buffalo, Buffalo, NY.  
‡Medical Statistics Researcher, INRCA, Ancona, Italy.  
§Associate Professor and Director of the Master in Periodontics, School of Dentistry, Università Politecnica delle Marche, Ancona, Italy.

Reprint requests and correspondence to: Alessandro Quaranta, DDS, PhD, School of Dentistry, Università Politecnica delle Marche, Polo Murri, Room #47, Via Tronto 10, 60020, Torrette di Ancona, Ancona, Italy, Phone: +393381770918, E-mail: alessandro.quaranta@univpm.it

ISSN 1056-6163/13/02202-001  
Implant Dentistry  
Volume 22 • Number 2  
Copyright © 2013 by Lippincott Williams & Wilkins  
DOI: 10.1097/ID.0b013e318285984c

**Background:** To assess heat production using osteotomes under conditions simulating implant placement in D3, D4 bone.

**Material and Methods:** Implant osteotomes were tested (Winsix, Biosafin, Italy). Site preparations were performed on porcine ribs through a compressive fashion. The ribs were partially immersed in a custom-made water bath/water pump system that maintained the baseline temperature at 36°C. Temperatures generated at different depths (2, 5, and 9 mm) during a series of 25 osteotomies were measured using 3 thermocouples connected to a digital thermometer.

**Results:** The mean temperatures never exceeded 37°C and were all significantly lower than those reported

during preparation with standard implant drills. Statistical evaluation of the temperature during implant site preparation showed slight significant variations between the baseline values and those of the different depth preparations.

**Conclusions:** Within the limits of this study, the production of heat during implant preparation using osteotomes shows significant variations at different depths. However, these variations are not clinically relevant because they never increased over the values that negatively affect bone that may jeopardize osseointegration. (*Implant Dent* 2013;22:1-4)

**Key Words:** osteotomes, dental implants, heat production

that is characterized by soft trabecular bone.<sup>11-15</sup> In these clinical conditions, the adoption of dental osteotomes to perform the implant site preparation is highly recommended.<sup>16-20</sup> The less the bone resistance, the more indication there is for consideration of the use of the osteotomes to compact the bone.<sup>16</sup> It has been demonstrated that after bone condensing, significantly higher implant stability was recorded immediately after surgery and during the whole observation period of 6 weeks compared with bone-drilling technique.<sup>21</sup> Consequently, the bone-condensing technique is highly recommended as an alternative surgical approach for

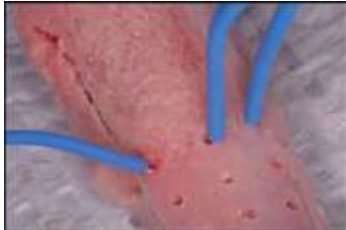implant site preparation in reduced bone density. Although there is well-documented information about the temperature generated by implant site preparation with surgical drills,<sup>2,5-7</sup> no evidence is available about the heat production during implant site preparation with manual instruments. The aim of the present study was to assess the heat production during osteotomy preparation for dental implants with compressive osteotomes.

### MATERIALS AND METHODS

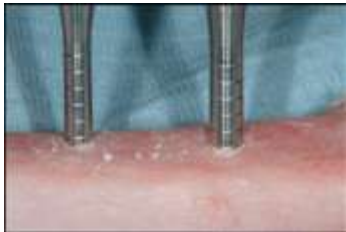
In the present study, brand new compressive concave osteotomes were tested (Winsix Biosaf, Ancona, Italy). A series of 25 implant site preparations

2 *IN VITRO* EVALUATION OF HEAT PRODUCTION DURING OSTEOTOMY • QUARANTA ET AL

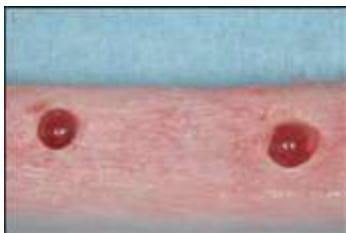
AU1



**Fig. 1.** Three canals for thermocouples at different depths (2, 5, and 9 mm) were drilled on the external surface of each specimen. The implant sites were done on the upper surface of the specimen.



**Fig. 2.** The preparation of implant sites was performed with the manual compressive osteotomes in a progressive cumulative way. On the left side, a 8-mm depth osteotomy was performed with a 3.8-mm diameter osteotome, whereas on the right side, a 9-mm depth osteotomy with a 4.5-mm diameter osteotome is displayed.



**Fig. 3.** Two 9-mm deep adjacent osteotomies (3.8 and 4.5 mm diameter) with an interimplant distance of 15 mm were performed.

were performed on porcine ribs through a compressive approach with surgical osteotomes by a single experienced operator. Temperatures generated at different depths (2 mm: T1; 5 mm: T2; and 9 mm: T3) were measured for each osteotome at each implant preparation. Porcine ribs were used because bone

density and the relationship between cortical and cancellous bone are similar in porcine bone and in human maxillary bone. In fact, the bone density of this animal model is similar to D3, D4 bone as classified by Misch.<sup>12</sup> The specimens were secured in a custom-made screw assisted metal holder. Three canals for thermocouples, 1 at T1 depth and the others at T2 and T3 depths, were drilled into each specimen using a 1.5-mm twist drill and intermittent cutting at a distance of 1 mm from the implant site similar to what was previously described<sup>22,23</sup> (Fig. 1). The thermocouples were secured to the bone blocks and insulated from outer environment with sticky wax applied to the canal opening. The thermocouples were connected to a digital thermometer (BK Precision Type K, Taiwan), which allowed constant reading of the temperature within the bone block. The bone block was partially immersed in a custom-made water bath/water pump system that allowed control of the baseline bone temperature, which was set at 36°C. The surgical osteotomes used in the present study show a concave tip (to retain saline, carry the bone, and exert less pressure on the sinus membrane when used for sinus elevation), a sharpened edge (to add shaved bone as graft material), and a continuous taper (to gradually compact the layers of bone adjacent to the osteotomy) design. The complete set of osteotomes is composed of 6 instruments with different diameters. The first 2 osteotomes show different diameters (2.0 and 2.2 mm) and a small very sharpened tip that is useful to start the site preparation by seating the instrument into the cortical bone and then pass through it. The following osteotomes all show a concave sharp tip and different increasing diameters (3.3, 3.8, 4.5, and 5.2 mm), thus allowing the implant preparation by cutting and condensing the bone until the planned depth and

simultaneously enlarging the osteotomy. The preparation of implant sites with the manual osteotomes was performed by activating the different osteotomes with a surgical mallet in a cumulative way until the planned diameter (4.5 mm) and depth (9 mm) were reached (Figs. 2 and 3). After 5, 10, and 25 series of osteotomies, the manual instruments were cleaned with alcohol prep pads (Select Medical Devices, Jacksonville, FL) and then sterilized with an autoclave device. Values were expressed as mean  $\pm$  standard deviation. ANOVA test for repeated measures was used to compare the mean temperatures obtained for each CW osteotome over different depths (T1, T2, and T3) and to compare the mean temperatures obtained at each different depth (T1, T2, and T3) using all the CW osteotomes (I–V). Nonparametric analysis (Kruskal-Wallis test) was adopted to assess differences in heat generation (mean of T1 + T2 + T3 in each of the 25 preparations) using each single osteotome during the series of 25 implant site preparations. The value for statistical significance was set at  $P$  value  $< 0.05$ .

## RESULTS

In all the series of 25 preparations performed with each osteotome, the single temperatures recorded by the digital thermometer never exceeded 38°C. The mean temperatures never exceeded 37°C (Table 1). The ANOVA for repeated measure showed significant differences ( $P < 0.001$ ) in mean temperatures generated by each osteotome at the 3 different depths (T1, T2, and T3) during the series of 25 implant site preparations. As a matter of fact, differences were found between the T1 and T2 and T3 temperatures. The analysis to assess mean temperatures generated during the implant site preparation in each depth (T1, T2, and T3) using the various CW

**Table 1.** Mean Temperatures Generated at Different Depths With the CWI–CWW Osteotome

Variables	T1 (Mean $\pm$ SD)	T2 (Mean $\pm$ SD)	T3 (Mean $\pm$ SD)	$P$
CWI	36.07 $\pm$ 0.31	36.47 $\pm$ 0.34	36.53 $\pm$ 0.41	$< 0.001$
CWII	36.02 $\pm$ 0.31	36.63 $\pm$ 0.53	36.58 $\pm$ 0.41	$< 0.001$
CWIII	36.04 $\pm$ 0.28	36.68 $\pm$ 0.46	36.70 $\pm$ 0.52	$< 0.001$
CWIV	36.05 $\pm$ 0.50	36.54 $\pm$ 0.47	36.59 $\pm$ 0.38	$< 0.001$
CWV	36.04 $\pm$ 0.38	36.60 $\pm$ 0.56	36.63 $\pm$ 0.45	$< 0.001$



AU3

**Table 2.** Kruskal-Wallis Test at T1, T2, and T3 Depths Regarding the Temperatures Generated During the 25 Implant Site Preparations

Source	F	Significance
Measure: T1 CWI-CWV	0.209	0.933
	0.209	0.903
	0.209	0.930
	0.209	0.652
Measure: T2 CWI-CWV	1.180	0.325
	1.180	0.325
	1.180	0.325
	1.180	0.289
Measure: T3 CWI-CWV	1.251	0.295
	1.251	0.298
	1.251	0.297
	1.251	0.275

CWI-CWV indicates compressive osteotomes; F, analysis of variance test (Kruskal-Wallis test).

osteotomes (osteotomes I-V) showed no significant difference ( $P > 0.05$ ). Kruskal-Wallis test did not show any significant difference in heat generation (T1 + T2 + T3 mean) using each single osteotome during the series of 25 implant site preparations (Table 2).

T2

## DISCUSSION

Excessive heat production during implant site preparation may compromise osseointegration and determine implant failure. In sites of minimal bone density, the use of compressive osteotomes to preserve the maximum amount of bone and to improve the primary stability was suggested.<sup>24,25</sup> The aim of the present *in vitro* study was to evaluate the heat production generated by compressive osteotomes during implant site preparations under conditions simulating minimal (D3, D4) bone density. In all the 25 preparations, the temperatures generated using each single osteotome never exceeded 38°C. The mean temperatures never exceeded 37°C. Statistical evaluation of differences in mean temperatures generated by each osteotome at the 3 different depths (T1, T2, and T3) during the series of 25 implants site preparations showed significant differences. Differences were evident between the T1 and T2 and T1 and T3 temperatures. Although these

differences were statistically significant, they are not to be considered relevant from the clinical point of view. In fact, all the temperatures were so far from the temperatures that are considered harmful for bone vitality (temperature higher than 47°C for more than 1 minute).<sup>5</sup> This result is very important because it indicates that compressive osteotomes are safer devices in the preparation of the implant site in comparison with rotatory instruments (drills). Moreover, although it has been demonstrated that, when using drills, heat production and, with it, the potential for damage increase with the depth of osteotomy,<sup>7</sup> the present study showed minimal variations in temperatures with the increase of the depth of the manually prepared implant site. Furthermore, no significant variation of mean temperatures was observed using osteotomes with increasing diameters. These data may indicate that compressive osteotomes may be considered safer instruments than drills when there is a clinical need to obtain a deeper site preparation into the bone. Finally, the temperatures generated by each single osteotome during the 25 implant site preparations were homogeneous, and no significant differences were observed. There was a minimal instrument wear that did not compromise the bone vitality.

## CONCLUSIONS

Within the limits of the present *in vitro* study, the production of heat during implant site preparation using compressive osteotomes did not increase over the values that negatively affect living bone that may jeopardize osseointegration (47°C). The mean temperatures values are very homogenous and significantly lower than the mean values reported during preparation with standard implant drills. The minimal increase of the temperature observed at higher preparation depths is not relevant from the clinical point of view.

## DISCLOSURE

The authors claim to have no financial interest, either directly or indirectly, in the products or information listed in the article.

## REFERENCES

1. Adell R, Eriksson B, Lekholm U, et al. Long-term follow-up study of osseointegrated implants in the treatment of totally edentulous jaws. *Int J Oral Maxillofac Implants.* 1990;5:347-359.
2. Jaffin RA, Berman CL. The excessive loss of Branemark fixtures in type IV bone: A 5-year analysis. *J Periodontol.* 1991;62:2-4.
3. Brånemark PI. Osseointegration and its experimental background. *J Prosthet Dent.* 1983;50:399-410.
4. Adell R. Tissue integrated prostheses in clinical dentistry. *Int Dent J.* 1985; 35:259-265. Review.
5. Eriksson RA, Albrektsson T. Temperature threshold level for heat-induced bone tissue injury: A vital-microscopic study in the rabbit. *J Prosthet Dent.* 1983;50:101-107.
6. Albrektsson T, Eriksson A. Thermally induced bone necrosis in rabbits: Relation to implant failure in humans. *Clin Orthop Relat Res.* 1985;195:311-312.
7. Haider R, Watzek G, Plenck H. Effects of drill cooling and bone structure on IMZ implant fixation. *Int J Oral Maxillofac Implants.* 1993;8:83-91.
8. Webster's online dictionary. Available at: <http://www.websters-online-dictionary.org/definitions/Osteotome>.
9. Devlin H, Horner K, Ledgerton D. A comparison of maxillary and mandibular bone mineral densities. *J Prosthet Dent.* 1998;79:323-327.
10. Ulm CW, Kneissel M, Hahn M, et al. Characteristics of the cancellous bone of edentulous mandibles. *Clin Oral Implants Res.* 1997;8:125-130.
11. Sakka S, Coulthard P. Bone quality: a reality for the process of osseointegration. *Implant Dent.* 2009;18:480-485.
12. Misch CE. Density of bone: effect on treatment plans, surgical approach, healing, and progressive bone loading. *Int J Oral Implantol.* 1990;6:23-31.
13. Shahlaie M, Gantes B, Schulz E, et al. Bone density assessments of dental implant sites: 1. Quantitative computed tomography. *Int J Oral Maxillofac Implants.* 2003;18:224-231.
14. Aranyarachkul P, Caruso J, Gantes B, et al. Bone density assessments of dental implant sites: 2. Quantitative cone-beam computerized tomography. *Int J Oral Maxillofac Implants.* 2005;20:416-424.
15. Trisi P, Rao W. Bone classification: clinical-hist Summers RB. Sinus floor elevation with osteotomes. *J Esthet Dent.* 1998; 10:164-171.
16. Toffler M. Minimally invasive sinus floor elevation procedures for simultaneous and staged implant placement. *N Y State Dent J.* 2004;70:38-44.

AU2

**4 IN VITRO EVALUATION OF HEAT PRODUCTION DURING OSTEOTOMY • QUARANTA ET AL**

17. Cavicchia F, Bravi F, Petrelli G. Localized augmentation of the maxillary sinus floor through a coronal approach for the placement of implants. *Int J Periodontics Restorative Dent.* 2001;21:475-485.
18. Leblebicioglu B, Ersanli S, Karabuda C, et al. Radiographic evaluation of dental implants placed using an osteotome technique. *J Periodontol.* 2005;76:385-390.
19. Brägger U, Gerber C, Joss A, et al. Patterns of tissue remodeling after placement of ITI dental. *Clin Oral Implants Res.* 2004;15:158-166.
20. Marković A, Calasan D, Colić S, et al. Implant stability in posterior maxilla: Bone-condensing versus bone-drilling: A clinical study. *Oral Surg Oral Med Oral Pathol Oral Radiol Endod.* 2011;112:557-563.
21. Matthews LS, Hirsch C. Temperatures measured in human cortical bone when drilling. *J Bone Joint Surg Am.* 1972;54:297-308.
22. Ercoli C, Funkenbusch PD, Lee HJ, et al. The influence of drill wear on cutting efficiency and heat production during osteotomy preparation for dental implants: A study of drill durability. *Int J Oral Maxillofac Implants.* 2004;19:335-349.
23. Nocini PF, Albanese M, Fior A, et al. Implant placement in the maxillary tuberosity: The Summers' technique performed with modified osteotomes. *Clin Oral Implants Res.* 2000;11:273-278.
24. Martinez H, Davarpanah M, Missika P, et al. Optimal implant stabilization in low density bone. *Clin Oral Implants Res.* 2001;12:423-432.
25. Davarpanah M, Martinez H, Tecucianu JF, et al. The modified osteotome technique. *Int J Periodontics Restorative Dent.* 2001;21:599-607.



# CASO CLINICO

## Riabilitazione dei mascellari edentuli: presentazione di una nuova tecnica software assistita

Computer aided rehabilitation



**Michele Manacorda\***  
micmanacorda@gmail.com

**Raffaele Vinci\***  
**Francesco Bova\***  
**Matteo Nagni\*\***  
**Enrico Gherlone\***

\* Ateneo Vita Salute San Raffaele, Milano,  
Presidente CLOPD: professor E. Gherlone  
\*\* Studente in odontoiatria

### SCOPO DEL LAVORO

Si presenta un caso clinico di riabilitazione implantare e protesica full-arch maxillare. L'intervento chirurgico, effettuato con tecniche mininvasive, è guidato dalla dima chirurgica. L'obiettivo è verificare che il progetto chirurgico implantare, programmato con un software dedicato, risponda alle caratteristiche cliniche di precisione richieste. Anche la protesi provvisoria per il carico immediato, progettata con l'aiuto dello studio virtuale, deve soddisfare i parametri di funzionalità ed estetica.

### MATERIALI E METODI

Per la realizzazione di questa riabilitazione è stato utilizzato il software di diagnostica 3Diagnosys 4.0 (3DIEMME) con il quale è possibile determinare il posizionamento implantare e costruire una dima chirurgica su modello CAD/CAM. La protesi postchirurgica (Toronto bridge) è stata realizzata su impronte

di precisione e rinforzata con un innovativo sistema modulare (Clip Abutment Bar, Winsix) che consente al laboratorio di assemblare una barra prefornata senza bisogno di fusioni metalliche, così da garantire un robusto rinforzo passivizzato del manufatto.

### RISULTATI E CONCLUSIONI

La precisione in fase progettuale, sia della componente chirurgico-implantare che del layout protesico sviluppato sul software dedicato in 3D, giustifica l'impiego di questo approccio terapeutico nei casi di grandi riabilitazioni implanto-supportate dei mascellari edentuli. Estetica e funzionalità, verificate attraverso la clinica e l'esame tomografico di controllo, confermano la validità di questo protocollo. I risultati ottenuti seguendo l'accurato iter diagnostico e terapeutico sono predicibili e superano mediamente quelli ottenuti con altre metodiche tradizionali e di diagnostica computer assistita.

### AIM OF THE WORK

We present a clinical case of implant and full-arch maxillary prosthetic reconstruction. The surgical implant operation carried out with mini-invasive techniques is made through a surgical guide. The objective is to check that the surgical implant planning, obtained with the dedicated software, complies with the precise clinical characteristics required. Also the temporary crown for immediate loading, planned using the virtual projection, must adhere to the parameters of functionality and aesthetics.

### MATERIALS AND METHODS

In order to carry out this reconstruction, we used the 3Diagnosys 4.0 (3DIEMME) diagnostic software, with which we've been able to plan the implant positioning and build the surgical guide using a CAD/CAM model. The post-surgical Toronto bridge prosthetic was built on the precise dental impressions made after flapless surgery and reinforced with an innovative

modular system (Clip Abutment Bar, Winsix). This system allows the laboratory to assemble pre-shaped components without using metallic fusion, so to guarantee a strong correct passive fit.

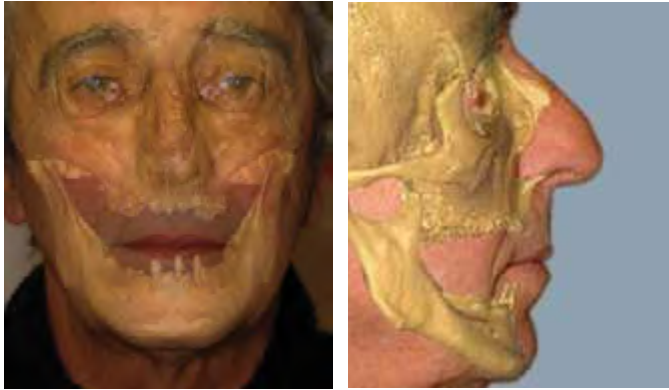### RESULTS AND CONCLUSIONS

Planning-stage precision of both the implant-surgical side and the prosthetic layout developed

on the dedicated 3D software justifies the purpose of this therapeutic approach in cases of implant-supported reconstructions of edentulous jaws. Aesthetics and functionality, checked via the clinical exams and a CT scan, confirm this protocol to be valid. The final results can be predicted and they are - by average - over and above those obtained with traditional techniques and conventional prosthetics.

IMPLANTOLOGIA PROTESICAMENTE GUIDATA / RIABILITAZIONE COMPUTER ASSISTITA / DIAGNOSTICA PER IMMAGINI / TELERADIOGRAFIA TRIDIMENSIONALE / BARRA ASSEMBLATA / PROSTHETICALLY GUIDED IMPLANTOLOGY / COMPUTER AIDED REHABILITATION / IMAGE BASED DIAGNOSIS / 3D TELERADIOGRAPHY / CLIP ABUTMENT BAR

CASO



FIGG. 1

Ricostruzione 3D delle basi ossee in "matching" sulle foto diagnostiche. Il programma diagnostico-terapeutico si basa sulle nuove tecnologie applicate alla diagnostica per immagini.

## INTRODUZIONE

### Un nuovo approccio terapeutico integrato

**N**ei pazienti che necessitano della ricostruzione protesica implantosupportata di un'intera arcata deve spesso essere considerata anche la necessità di una riabilitazione dell'estetica facciale, che coinvolge non solo i processi alveolari e i denti, ma anche il terzo medio e inferiore del volto nella sua struttura complessiva. Questo avviene nel paziente edentulo perché l'atrofia ossea dei processi alveolari e dell'osso basale porta come conseguenza un drastico cambiamento della morfologia dei tessuti periorali, modificando l'intero aspetto del viso. Come insegnano i dettami per la costruzione di una protesi totale, anche nella progettazione di una protesi full-arch supportata da impianti vanno considerati diversi fattori: dalla ricostruzione dei rapporti interarcata alla salute articolare, alla fonazione.

Il nostro intervento coinvolge l'intero sistema stomatognatico. Occorre perciò avere un approccio multidisciplinare, che non si limiti alla scelta degli impianti in base alla disponibilità dell'osso residuo, ma coinvolga già in fase progettuale tutti gli aspetti terapeutici dei quali la chirurgia non è che una componente. Nel caso trattato, l'analisi diagnostica è stata condotta secondo uno specifico protocollo di indagini cliniche e strumentali che abbiamo denominato CAR (Computer Aided Rehabilitation). Tale procedura include, oltre alla semeiotica clinica e strumentale classica e all'esame obiettivo del viso (esame facciale),

anche esami più approfonditi basati sull'elaborazione delle immagini tomografiche ottenute dalla CBTC del massiccio facciale. Tra questi ricordiamo, ad esempio, la cefalometria 3D che è in grado di valutare i rapporti scheletrici e cutanei direttamente sulle immagini elaborate della TC (1, 2). Sulle immagini radiografiche tridimensionali, alle quali è possibile oggi sovrapporre anche il progetto protesico proposto, possiamo progettare l'intervento chirurgico implantare protesicamente guidato (3). Lo studio completo, trasferito poi al modello realizzato in CAD/CAM, permette al tecnico di confezionare la dima chirurgica e una precisa protesi provvisoria da impiegarsi nel carico immediato, ancor prima dell'intervento chirurgico (figg. 1).

## PROCEDURE DIAGNOSTICHE

Clinicamente la fase diagnostica della CAR prevede un iter in diverse fasi. Da un punto di vista pratico gli strumenti e i passaggi operativi impiegati nel trattamento del paziente comprendono l'esame obiettivo e la semeiotica clinica classica intra ed extraorale. Le fotografie diagnostiche sono utili per l'esame facciale (4) e in un secondo tempo possono essere accoppiate allo studio tridimensionale della TC (figg. 2 e 3). La diagnostica clinica e strumentale dell'occlusione, con il montaggio in articolatore a valori medi dei modelli di partenza, fornisce importanti dati sulle eventuali correzioni da portare al montaggio dei denti, all'occlusione, ai rapporti intermascellari e alla dimensione verticale. Infine la diagnostica per immagini: si avvale delle indagini radiografiche di primo livello come l'ortopantomografia, la tele-

radiografia latero-laterale e le proiezioni endorali che completano la prima fase diagnostica di raccolta dei dati.

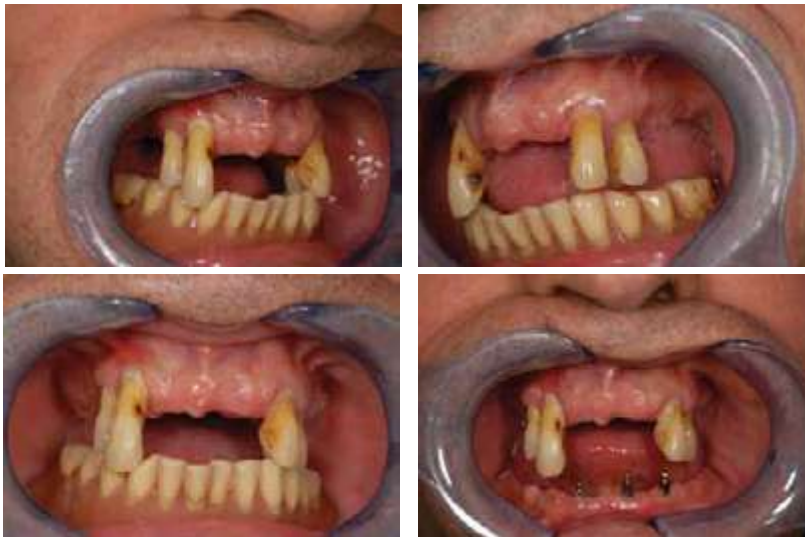
## PROGRAMMA TERAPEUTICO

Dopo aver bonificato l'arcata superiore dagli elementi dentali residui, non più recuperabili a causa della grave mobilità dovuta alla parodontopatia cronica, viene consegnata una protesi totale immediata. Si procede poi con il montaggio dei modelli al fine di costruire valli di registrazione oclusale secondo il classico protocollo seguito in protesi totale. Il piano di cure prevede anche la sostituzione dell'overdenture preesistente all'arcata inferiore, per correggere dimensione verticale e inclinazione del piano oclusale dimostratesi incongrui (figg. 4).

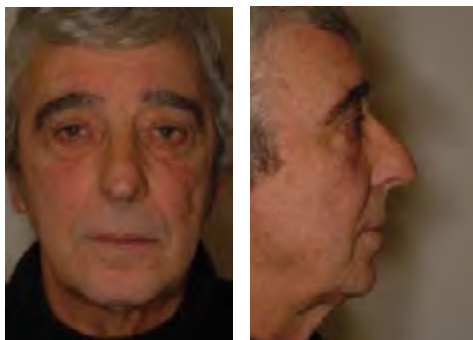Con i valli in relazione centrica, muniti di elementi radiopachi, si effettua una teleradiografia latero-laterale. L'esame cefalometrico può evidenziare la congruità della riabilitazione proposta sia in relazione alle strutture scheletriche che al supporto dei tessuti molli periorali. Siamo così in grado di verificare precocemente la correttezza del progetto ricostruttivo protesico e di apportarvi eventuali modifiche strutturali prima di finalizzare la protesi diagnostica. Quando la protesi diagnostica è funzionalizzata e il suo riscontro clinico-estetico è soddisfacente si effettua la TC con la protesi inserita e in occlusione.

### Programmazione integrata (computer assistita) del percorso riabilitativo

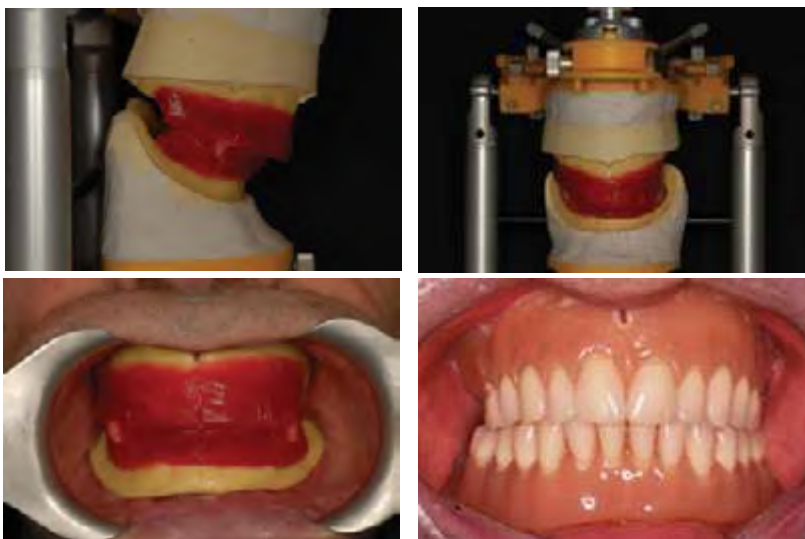
Alla protesi diagnostica, durante l'esame CBTC esteso al massiccio facciale,



**FIGG. 2**  
 Visione dell'edentulia parziale maxillare in prima visita. Il programma terapeutico esclude il recupero degli elementi residui a causa delle gravi condizioni parodontali. Il progetto prevede la costruzione di due protesi totali diagnostiche dalle quali si possano trarre informazioni fondamentali per il recupero delle funzioni orali.



**FIGG. 3**  
 Le foto diagnostiche evidenziano una discreta conservazione dei rapporti facciali, malgrado l'edentulia all'arcata inferiore incorsa in età prematura e l'atrofia ossea conseguente siano solo parzialmente compensate dalla protesi rimovibile, con evidente riduzione delle dimensioni verticali del terzo inferiore del volto e insufficiente sostegno dei tessuti periorali.



**FIGG. 4**  
 In seguito alla bonifica si procede con la costruzione di due protesi totali diagnostiche, secondo il protocollo classico per la realizzazione della protesi totale. Le protesi finite e funzionalizzate serviranno come guida al posizionamento protesicamente guidato degli impianti. La loro scansione ottica viene infatti trasferita al programma di progettazione degli impianti.

CASO

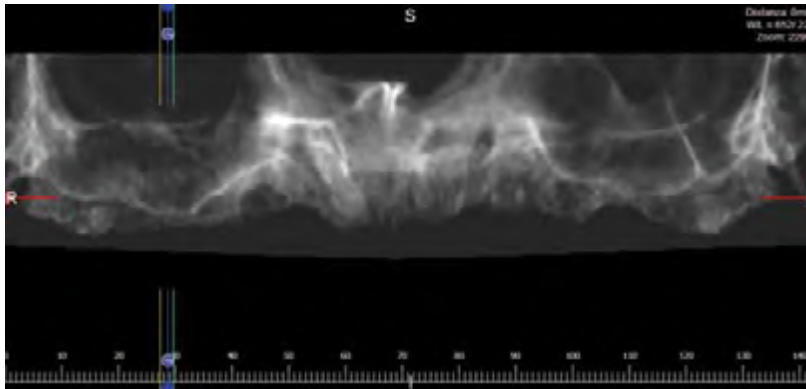
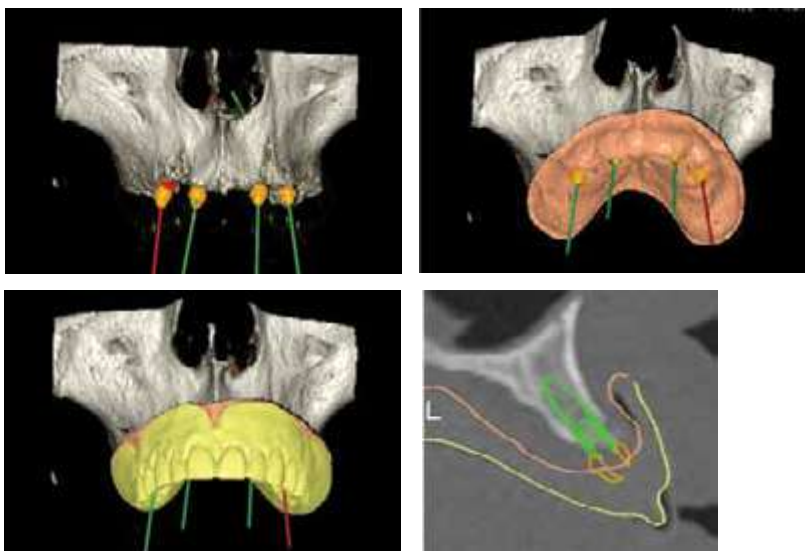
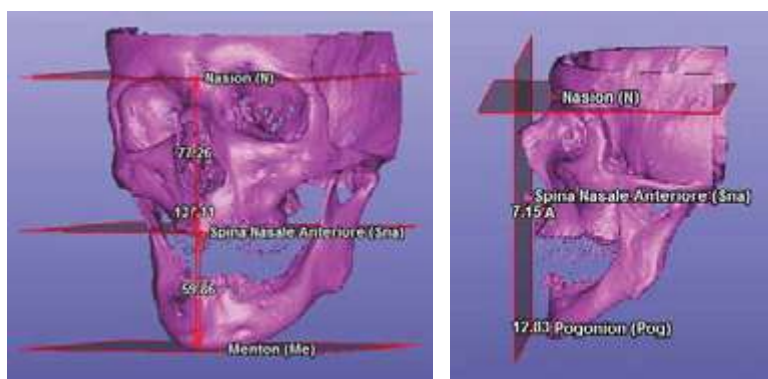


FIG 5  
Panorex prechirurgica



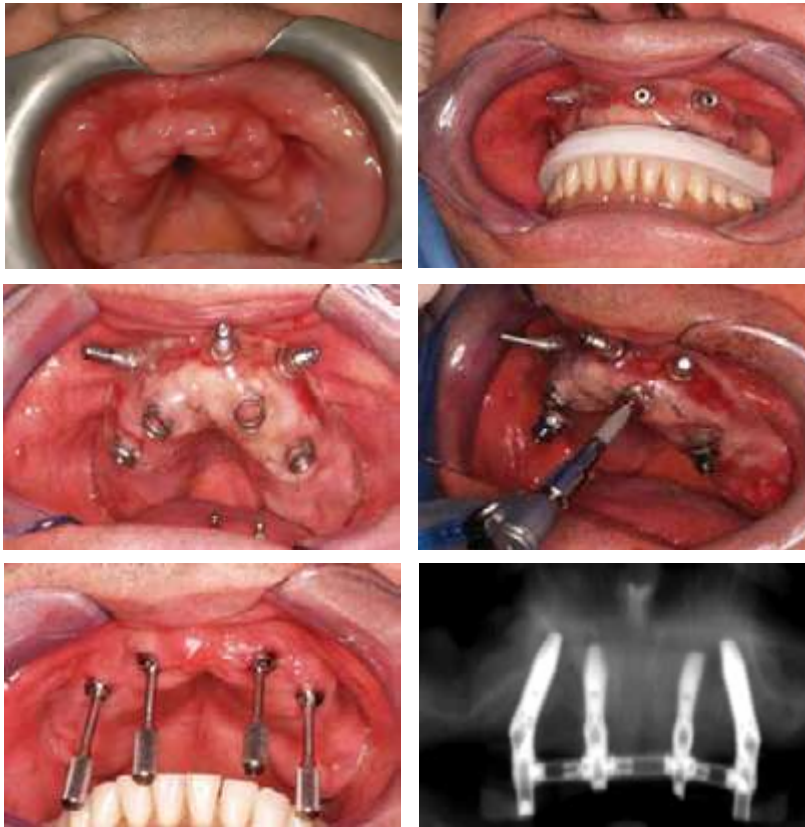
FIGG. 6  
Il progetto computer guidato: sono programmati quattro impianti dei quali due inclinati a 30° e vengono scelti dalla libreria del software anche gli abutment con il loro ideale asse di rotazione. Grazie al "matching" delle scansioni ottiche è visibile la futura emergenza delle fixture dalla mucosa e il rapporto delle viti di serraggio con la sovrastruttura protesica.



FIGG. 7  
L'esame cefalometrico in 3D secondo il protocollo TFA permette di individuare e misurare oggettivamente i parametri scheletrici e cutanei del progetto riabilitativo. Nelle immagini visualizzate sono misurati i rapporti scheletrici sul piano sagittale e le dimensioni verticali.



CASO



**FIGG. 8**  
Le fasi chirurgiche: per l'inserimento degli impianti viene usato in kit specifico di frese e un mounter dedicato, propri della sistemica implantare utilizzata. Panorex di controllo post intervento.

abbiamo collegato un repere radiologico preformato. Questo permette al software di pianificazione di leggere le coordinate spaziali della TC rispetto al repere e sovrapporre alla scansione ottica della protesi. Il file in formato Dicom della tomografia è inserito nel programma dedicato alla progettazione dell'intervento implantare insieme ai file STL del modello e della protesi diagnostica. Grazie al procedimento Optical Fusion abbiamo sovrapposto le indagini radiografiche a quelle della protesi e dei tessuti, ottenendo una visione completa dei rapporti fra le fixture progettate e gli elementi della futura protesi, che deve essere identica alla protesi diagnostica, poiché già rispondente ai requisiti funzionali ed estetici. Dallo studio della TC, che inizia da una visione d'insieme delle strutture ossee sulla pseudopanoramica (fig. 5), si programma il numero e la posizione degli impianti necessari per sostenere la struttura protesica tipo Toronto bridge. Le opzioni chirurgiche riabilitative prevedono, in un paziente edentulo con

questo grado di atrofia, l'elevazione del pavimento sinusale al fine di ricreare una quantità sufficiente di osso per un corretto supporto agli impianti. Qualora coesistono discrepanze orizzontali o verticali di grado significativo può rendersi necessario l'impiego di innesti ossei per la loro correzione (5). Essendo il nostro paziente un forte tabagista con concomitanti patologie sistemiche cardiovascolari, si è optato per un intervento che prevedesse l'utilizzo del solo volume osseo esistente mediante la tecnica "Just on Four" flapless computer assistita (6, 7, 8, 9) per ridurre l'invasività chirurgica (figg. 6). La verifica della congruità del progetto viene controllata attraverso lo studio cefalometrico in 3D (10, 11), realizzato sul modulo OMS del software Siplant (Materialise). La cefalometria delle parti molli serve per una validazione estetica e oggettiva degli effetti portati dal progetto protesico sul sostegno del labbro e sui rapporti del terzo medio e inferiore del viso (figg. 7).

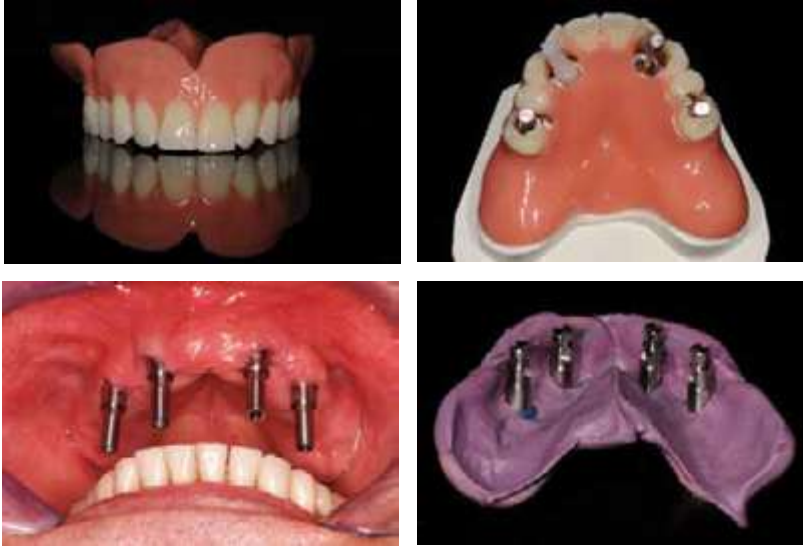
Il progetto digitale concluso viene tra-

sformato in un modello fisico con tecnologia CAD/CAM mediante fresatura e poi montato in articolatore. Su questo modello, su cui vengono già montati gli analoghi degli impianti, il laboratorio costruisce sia la guida chirurgica che l'indice chirurgico: un vallo in silicone che il chirurgo utilizza per il corretto posizionamento della dima ad appoggio mucoso prima della sua fissazione.

#### L'intervento flapless minivasivo guidato

Al paziente in anestesia locale viene posizionata la dima chirurgica, verificandone il fitting con l'indice chirurgico. La dima è fissata con almeno 3 pin di fissazione, per renderla stabile durante tutto l'intervento. Dopo l'alesatura progressiva dei neoalveoli con frese dedicate guidate, si inseriscono gli impianti con mounter dedicati, anch'essi attraverso le cannule guida, che garantiscono l'inserimento senza margine d'errore rispetto al progetto (12). Come da pianificazione di intervento con

CASO



FIGG 9

Il provvisorio per il carico immediato è una replica della protesi diagnostica, preconfezionato sul modello CAD/CAM. Viene forato in corrispondenza delle emergenze implantari e usato come porta-impronta. I monconi a spalla variabile della barra in posizione sono utilizzati come transfert nell'impronta di posizione.

tecnica Just on Four abbiamo inserito due impianti Winsix TTx 3,8 x 13 in zona 22 e 12 e due impianti Winsix TTx 3,8 x 15 in zona 14 e 24, inclinandoli di 30 gradi (figg. 8). Una volta rimossa la dima chirurgica vengono montati gli abutment e il paziente è pronto per il rilevamento delle impronte.

#### Il carico immediato: finalizzazione della protesi dentoalveolare avvitata

Le impronte post chirurgia vengono rilevate direttamente sui monconi della barra assemblata usando come porta-impronte individuale la protesi precostruita sul modello CAD/CAM. Durante la presa del polietere il paziente resta in occlusione centrica sul porta-impronte. Il paziente viene dimesso e porta la protesi diagnostica ancora una giornata in attesa della finalizzazione del provvisorio avvitato (figg. 9).

In laboratorio le difficoltà principali riguardano la rapidità di esecuzione e la precisione del manufatto, che deve garantire la passivazione e il raggiungimento di un alto valore estetico (13). Nel caso in esame, come struttura di supporto abbiamo utilizzato una linea protesica appositamente studiata per la realizzazione di barre a componenti preformate che vengono assemblate per un immediato e passivo supporto implantare (CAB-Clip Abutment Bar, Winsix). Alla struttura protesica preconfezionata è stata rimodellata l'estensione della porzione rosa, inserita e resi-

nata la barra. La Toronto bridge, rifinita e lucidata, è stata consegnata al paziente, a ventiquattro ore dall'intervento, avvitata sugli abutment: il paziente ha dimostrato immediatamente grande benessere e soddisfazione per il risultato estetico (figg. 10). Dopo un accurato controllo dell'occlusione è stato inviato dall'igienista per l'istruzione alle manovre di igiene orale domiciliare (14).

#### Mantenimento e igiene professionale

Come per ogni altra tipologia di riabilitazione implantoprotesica, anche nel caso di soluzioni fisse full-arch su impianti inclinati il mantenimento nel tempo dei risultati ottenuti passa attraverso una scrupolosa igiene orale domiciliare, cui si affianca un programma di igiene professionale volto a completare quanto eseguito dal paziente nel quotidiano per evitare l'accumulo di placca sulle superfici protesiche e i pilastri implantari.

Attualmente sul mercato è possibile reperire moltissimi presidi domiciliari per l'igiene orale. Tra questi, i fili interdentali di tipo spugnoso, gli scovolini interprossimali e gli spazzolini monocuffo si rivelano molto efficaci per pulire correttamente gli abutment e le basi protesiche, al fine di scongiurare l'insorgenza di processi flogistici a carico dei tessuti perimplantari molli e duri.

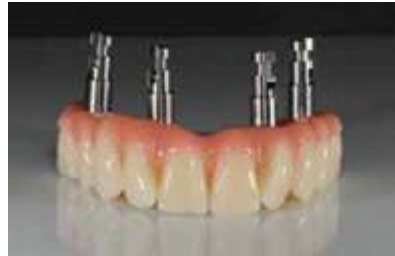Quanto fatto domiciliariamente non è tuttavia sufficiente per operare un attento controllo della flora batterica orale. È quindi

necessario predisporre un programma di mantenimento professionale che consenta da un lato di ottimizzare le condizioni igieniche della cavità orale, e dall'altro di intercettare precocemente l'insorgenza di eventuali complicazioni flogistiche o meccaniche.

In sede professionale, per l'esecuzione della profilassi di igiene, buoni risultati si possono ottenere, ad esempio, attraverso l'impiego di sistemi di air-polishing veicolanti polveri a bassa granulometria che garantiscono efficacia nella rimozione della placca batterica e rispetto dei materiali. Questi sistemi sono capaci di operare tanto in sede sopragengivale (quindi efficaci su abutment e superfici protesiche), quanto a livello del solco implantare (15). Accanto a queste sistematiche, per l'asportazione di eventuali depositi di tartaro, l'uso di inserti per ultrasuoni in plastica o rivestiti in materiale plastico rappresenta, attualmente, un'efficace alternativa, nel rispetto della costruzione implantoprotesica (16). Se da un lato questa tipologia di dispositivi rappresenta lo "stato dell'arte" per il mantenimento professionale delle riabilitazioni implantoprotesiche, anche sistemi più tradizionali, come scaler in materiale plastico e/o coppette da profilassi in gomma morbida utilizzate con paste da lucidatura a bassa abrasività, dimostrano comunque una buona efficacia benché siano complesse da usare in aree cruciali e di difficile accesso, come la base protesica in appoggio sulla mucosa, tipica delle riabilitazioni tipo Toronto bridge su impianti inclinati (figg. 11).

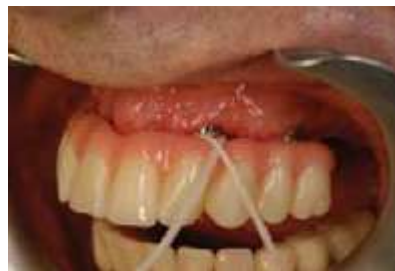
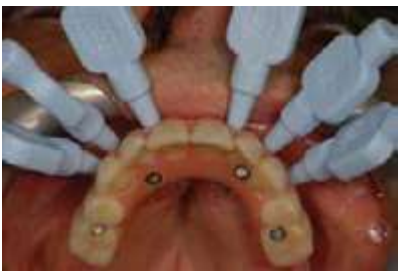
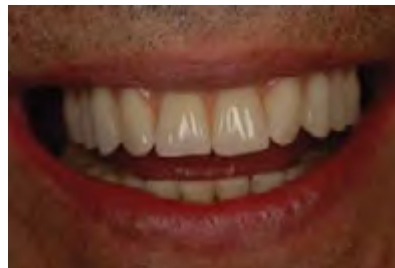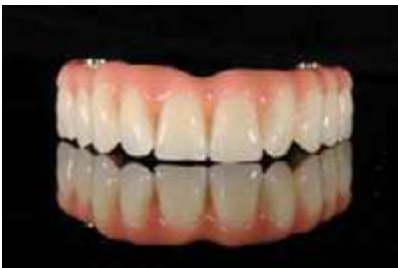CASO



FIGG.10

La barra CAB appena assemblata e avvitata sul modello prima del bloccaggio delle componenti col cemento per metalli, la rifinitura e la lucidatura finale con la massima cura anche nelle zone di ponti. (Realizzazione odontotecnica: Laboratorio Lazetera, Savona).



FIGG.11

Visita di controllo del provvisorio avvitato per la verifica del mantenimento dell'igiene orale domiciliare. L'istruzione del paziente sulle tecniche di mantenimento e la scelta dello strumentario sono fondamentali per la salute dei pilastri implantari nel tempo.

**CONCLUSIONI**

Una delle critiche mosse alla progettazione computer assistita è stata per un lungo periodo la sua imprecisione una volta trasferita al modello fisico. Le performance di affidabilità e precisione dipendono da molti fattori: dalla qualità

delle immagini tomografiche, dalla fedeltà del modello e, non ultimo, dal posizionamento della dima e dalle tolleranze della componentistica chirurgica. È quindi corretto, al termine della fase chirurgica, ripetere l'esame CBTC per controllo e per una misurazione affidabile della precisione ottenuta nel

posizionamento guidato degli impianti. Sovrapponendo i due esami in maniera automatica è possibile misurare l'errore tra progettazione e performance clinica. I risultati di questa metodica, del tutto confortanti e ben superiori della media riportata nelle review della letteratura sono illustrati nella figura 12 (17, 18, 19).

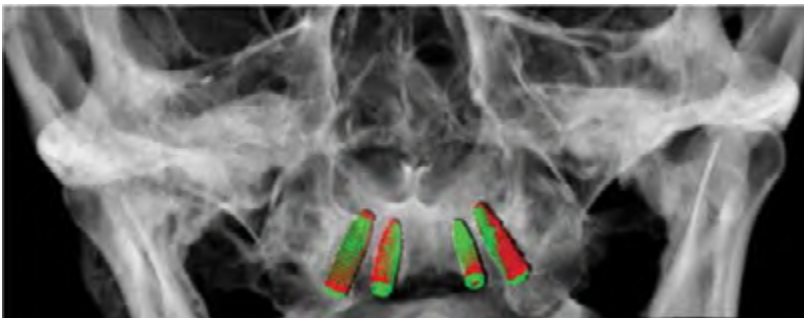


FIG.12

Matching tra progetto ed effettivo posizionamento delle fixture. Scostamento medio lineare al collare degli impianti 0,76 mm, all'apice 0,92 mm, scostamento angolare medio 3,79 mm.



## BIBLIOGRAFIA

- 1) Brown AA, Scarfe WC, Scheetz JP, Silveira AM, Farman AG. Linear accuracy of cone beam CT derived 3D images. *Angle Orthod* 2009 Jan;79(1):150-7.
- 2) Jung RE, Schneider D, Ganeles J, Wismeijer D, Zwahlen M, Hämmerle CH, Tahmaseb A. Computer technology applications in surgical implant dentistry: a systematic review. *Int J Oral Maxillofac Implants* 2009;24 Suppl:92-109. Review
- 3) Manacorda M, Vinci R, Pasi M, Gherlone EF. Teeth Just on six, riabilitazione implantoprotesicane nei casi di edentulia completa. *Odontoiatria* 2011 maggio; xxx: 9-19.
- 4) Arnett GW, Mc Laughlin RP. Facial and Dentofacial Planning for Orthodontists and Oral Surgeons. St Louis (Mo): Mosby, Elsevier; 2004.
- 5) Vinci R. Bone grafts from calvaria: diagnosis, instrumentation, harvesting techniques and surgical procedures. In: Bone augmentation in oral implantology; Khoury et Al. Quintessence Pub 2007;7:213-40.
- 6) Agliardi E, Clericò M, Ciancio P, Massironi D. Immediate loading of full-arch fixed prosthesis supported by axial and tilted implants for the treatment of edentulous atrophic mandible. *Quintessence international* 2010 Apr;41(4).
- 7) Maló P, De Araujo Nobre M, Lopes A. The use of computer guided flapless implant surgery and four implants placed in immediate function to support a fixed denture: preliminary results after a mean follow-up period of thirteen months. *J Prosthet Dent* 2007 Jun;97(6 Suppl):S26-34.
- 8) Maló P, de Araujo Nobre M, Lopes A, Francischone C, Rigolizzo M. "All-on-4" immediate-function concept for completely edentulous maxillae: a clinical report on the medium (3 years) and long-term (5 years) outcomes. *Clin Implant Dent Relat Res* 2012 May;14 Suppl 1:e139-50.
- 9) Testori T, Galli F, del Fabbro M. Il carico immediato, la nuova era dell'implantologia orale. Viterbo: Ed ACME; 2009.
- 10) Jacobson RL. Facial analysis in two and three dimensions. In: Jacobson A ed. *Radiographic Cephalometry: from basics to Videomaging*. Chicago: Quintessence; 1995. p. 273-94.
- 11) Perrotti G, De Vecchi L, Weinstein T, Motroni A, Testori T, Del Fabbro M. La teleradiografia laterolaterale in implantologia e riabilitazione orale: dall'analisi bidimensionale alla diagnostica 3D. *Dental Cadmos* 2010; Giu:78-88.
- 12) Ganz SD. Computer aided design/computer aided manufacturing applications using CT and ConeBeam scanning technology. *Dent Clin North Am* 2008 Oct; 52(4):777-888.
- 13) Sanna A, Molly L, van Steenberghe D. Immediately loaded CAD-CAM manufactured fixed complete dentures using flapless implant placement procedures: a cohort study of consecutive patients. *J Prosthet Dent* 2007;97:331-9.
- 14) Gherlone EF. Riabilitazioni implantoprotesiche e chirurgia minimamente invasiva. Carimate (CO): Ed. Ariesdue; 2013.
- 15) Muthukuru M, Zainvi A, Esplugues EO, Flemmig TF. Non-surgical therapy for the management of peri-implantitis: a systematic review. *Clin Oral Implants Res* 2012 Oct;23 Suppl 6:77-83.
- 16) Sahm N, Becker J, Santel T, Schwarz FJ. Non-surgical treatment of peri-implantitis using an air-abrasive device or mechanical debridement and local application of chlorhexidine: a prospective, randomized, controlled clinical study. *Clin Periodontol* 2011;38:872-8.
- 17) Journa Marchack CB. An immediately loaded CAD/CAM- guided definitive prosthesis: a clinical report. *J Prosthet Dent* 2005;93:8-12.
- 18) Rosenfeld AI, Mandelaris GA, Tardieu BP. Prosthetically directed implant placement using computer software to ensure precise placement and predictable prosthetic outcome. Part 1: diagnostic imaging, and collaborative accountability. *Int J Period Rest Dent* 2006 Jun;26(3):215-21.
- 19) Schneider D, Marquardt P, Zwahlen M, Jung RE. A systematic review on the accuracy and the clinical outcome of computer-guided template-based implant dentistry. *Clin Oral Implants Res* 2009 Sep;20 Suppl 4:73-86.

➔ prevenzione - implantologia

## Airpolishing: protocollo sperimentale di studio *in vitro* per la gestione dei pazienti implantari affetti da mucosite e perimplantite

• Pier Paolo Paganin  
Dottore in Igiene Dentale

L'implantologia nella riabilitazione orale dei pazienti parzialmente o totalmente edentuli è un trattamento universalmente accettato con predicibilità a 5 anni >95%<sup>1</sup>. Un posto di rilievo lo occupano le patologie peri-implantari, termine collettivo usato per indicare le alterazioni patologiche dei tessuti che circondano gli impianti, indotte per la maggioranza dei casi da placca batterica. Con il termine mucosite si intende l'infiammazione reversibile che interessa i soli tessuti molli peri-implantari, mentre la peri-implantite determina una reazione flogistica responsabile di un rapido riassorbimento osseo progressivo fino alla perdita funzionale della fixture. Le mucositi hanno un'incidenza in circa l'80% dei soggetti (50% dei siti) riabilitati con impianti. Le peri-implantiti, invece, incidono tra 28-56% dei soggetti (12-40% dei siti)<sup>2</sup>. L'European Federation of Periodontology (2006) aveva già definito l'importanza dei seguenti punti per il mantenimento a medio lungo termine del risultato ottenuto con la riabilitazione implantare: buona igiene orale domiciliare, diagnosi corretta e controllo dentale. Le complesse cause eziopatogenetiche di queste patologie sono riconducibili all'infezione da placca batterica nel caso della mucosite, mentre nella peri-implantite sono attribuibili a un duplice meccanismo eziopatogenetico

rappresentato dall'infezione da placca batterica con o senza l'associazione di complicanze tecniche come il sovraccarico biomeccanico. Diversi studi confermano che i batteri responsabili della parodontite sono essenzialmente gli stessi ritrovati nelle tasche peri-implantari con sondaggio patologico (anaerobi e Gram negativi: *Actinomyceten-comitans*, *Porphyromonas gingivalis*, *Prevotella intermedia*, *Spirochete*). È stato dimostrato come le due lesioni (peri-implantite/parodontite) siano diverse in quanto la prima si sviluppa in maniera meno regolata e molto più aggressiva rispetto alla seconda. È necessario sottolineare che entrambe le patologie hanno gli stessi fattori di rischio: scarsa igiene orale, fumo, malattie sistemiche (diabete non compensato, ipercolesterolemia), gravidanza, familiarità. La rapida evoluzione clinica delle peri-implantiti è dettata da caratteristiche anatomiche peculiari. Sull'impianto non vi è cemento radicolare né inserzioni di fibre collagene; inoltre queste ultime decorrono parallelamente all'impianto e non perpendicolarmente come naturalmente nel dente. La sola barriera che previene la disseminazione batterica nel solco peri-implantare è costituita dal sigillo creato dalle fibre circolari. Necessariamente, prima e dopo la riabilitazione implantoprotesica tutti i pazienti devono essere inquadrati

in un programma di mantenimento adeguatamente disegnato per le individuali necessità denominato "Terapia Parodontale di Supporto" (TPS). Nella fase diagnostica vengono valutati, a livello degli impianti, i seguenti parametri: Indice di Placca; Sanguinamento al Sondaggio; Suppurazione; Sondaggio peri-implantare; Evidenza radiografica di perdita ossea. Sulla base della valutazione di questi parametri diagnostici fondamentali, il professor Andrea Mombelli consiglia di procedere all'adozione del protocollo terapeutico CIST (Cumulative Interceptive Supportive Therapy) elaborato da lui et al. nel 1999. Si tratta di un protocollo cumulativo composto da quattro terapie di intervento specifiche, o associate o in sequenza a seconda del crescente potenziale antibatterico da adottare in proporzione alla severità e all'estensione della lesione:

- A. Detossificazione meccanica (presenza di placca e tartaro sui tessuti peri-implantari, sanguinamento al sondaggio, sondaggio peri-implantare ≤4);
- B. Terapia antisettica (da applicare se ai segni di infiammazione riportati al punto "A" si aggiunge un sondaggio peri-implantare di 4-5 mm);
- C. Terapia antibiotica (se sondaggio peri-implantare >5 e difetto osseo apprezzabile radiograficamente).

Effettuate queste prime tre fasi del protocollo CIST, si può procedere al protocollo chirurgico D, solo in caso di remissione

dell'infiammazione e dell'infezione con assenza di segni di suppurazione:

- D. Terapia chirurgica. In base a considerazioni estetiche e alle caratteristiche morfologiche del difetto si può considerare l'esecuzione di una chirurgia rigenerativa o resettiva;
- E. Espianto inevitabile qualora l'impianto raggiunga la mobilità.

### L'aspetto sperimentale

Grazie a un attento lavoro di ricerca, la comunità scientifica internazionale è d'accordo nel considerare i dispositivi implantari con le superfici rugose i presidi migliori vs i dispositivi implantari con le superfici lisce perché favoriscono meglio e più velocemente il processo di osteointegrazione. La nota sfavorevole della superficie rugosa è rappresentata dalla ritenzione batterica consentita grazie alle asperità presenti<sup>34</sup>.

Attualmente le strumentazioni come curette da impianti, ablatore con punte in materiale plastico e laser non sono considerate un trattamento elettivo in grado di soddisfare appieno l'esigenza di rimozione della placca batterica e, inoltre, creano dei danni irreversibili sulle superfici<sup>56</sup>.



1. Air Flow Master (EMS Sa).

### Materiali e metodi

Per lo studio abbiamo utilizzato un apparecchio dell'azienda EMS (Electro Medical System SA di Nyon, CH) ed è stata usata una nuova unità "AirFlow Master" che permette di avere a disposizione una pressione di lavoro di circa 5 bar per l'aria e 4,5 bar per l'acqua. Due serbatoi di polvere sono previsti e utilizzabili in modo alternato. Due cordoni indipendenti con i rispettivi manipoli per AP sono stati così preparati in modo tale da poter disporre di circuiti aria-acqua-polvere completamente separati. Per una maggiore predicibilità di trattamento si è preferito adottare un'unica configurazione di settaggio (max-polvere e max-flusso di acqua). Il sistema è stato preparato con un doppio serbatoio/circuito nella funzione convenzionale AirFlow (pressione out-put circa 5 bar) così da non avere né diversi parametri di valutazione né mix tra le polveri Soft e Perio all'interno del sistema durante il trattamento che potessero inficiare i risultati finali (Figure 1-2).

Sono stati prodotti n. 12 dischetti in titanio non sterili gentilmente forniti dall'azienda BioSaf. Le dimensioni dei dischetti erano di 8 mm di diametro per uno spessore di 2 mm (Figura 3). 6 (primo gruppo test) presentavano trattamento di superficie FCC (Full Contact Covering) (Figure 4a e 4b).

FCC è una nuova superficie ottenuta elettrochimicamente dove lo strato di ossido superficiale naturale dell'impianto viene accresciuto "esplosivamente" generando una superficie porosa. Il processo scaturisce da una differenza di potenziale tra un elettrodo e il "dispositivo implantare" da trattare, che si comporta come anodo immerso in una soluzione conduttiva.

La dimensione e la forma dei pori dipendono direttamente dalle condizioni del processo. Numerosi studi in vitro hanno osservato che la nanotopografia influenza il comportamento cellulare, favorendone l'adesione alla superficie dell'impianto e migliorando, perciò, la velocità di guarigione e le percentuali




2. Manipolo su stativo magnetico e flaconi polveri Soft/Perio (EMS Sa).



3. Dimensioni dischetti.



4a-4b. Dischetti FCC.



## → prevenzione - implantologia

di successo in situazioni difficili come per esempio osso di scarsa qualità)<sup>7-9</sup>. L'analisi SEM degli impianti Full Contact Covering (FCC) ha mostrato, a basso ingrandimento, una morfologia e una microrugosità di superficie ancora più regolare di quella SLA, mentre a un elevato ingrandimento (2000 x) il trattamento elettrochimico ha conferito un tipico aspetto microscopico, costituito da valli poco profondi e creste simili a "vulcani". Il secondo gruppo test era formato da 6 dischetti in titanio con trattamento di superficie SLA (Sand-blasted, Large grit, Acidetched), ossia tutto il corpo dell'impianto è stato trattato con un processo di asportazione di materiale tramite sabbiatura differenziata. Un procedimento che eliminava il rischio di contaminazione e riduceva quello di diffusione di particelle di titanio durante l'intervento chirurgico.

A questo si è sommato un procedimento di acidificazione per creare ulteriori microanfratti, inferiori ai 2 µm, che migliorassero l'adesione cellulare e quindi accelerassero il processo di guarigione dei tessuti-ossei.

Entambi i gruppi tests (FCC + SLA) sono stati trattati dal laboratorio Nobel BioRicerche di Portocomaro di Asti che si è occupato anche di produrre sia le scansioni al SEM del gruppo di controllo che le scansioni al SEM di tutti i campioni post trattamento AirPolishing.

Successivamente si è provveduto a dividere le tipologie di dischetti (FCC e SLA) in 2 sottogruppi di lavoro.

Un numero di 3 dischetti FCC è stato denominato con la lettera A e poi numerato rispettivamente in 1 A, 2 A, 3 A e quindi sottoposto a 3 diversi "step" di esposizione al getto di AP per un tempo di trattamento con polvere EMS Soft rispettivamente di 5" per il dischetto 1 A, 10" per il dischetto 2 A, 20" per il 3 A (Tabella 1).

3 dischetti del secondo sottogruppo FCC sono stati denominati 1 B, 2 B, 3 B e sottoposti a ulteriori 3 "step" con lo stesso criterio di esposizione del gruppo A, ma con polvere EMS Perio (Tabella 2).

Successivamente, il gruppo di 6 dischetti con superficie SLA è stato suddiviso in 2 sottogruppi da tre elementi ciascuno e denominati 1 C, 2 C, 3 C e 1 D, 2 D, 3 D e trattati con parametri uguali ai gruppi di dischetti con superficie FCC. Schematicamente, così rappresentato: (A) = (C) e (B) = (D).

Dunque con tempi di esposizione e tipi di polveri (Soft e Perio) identici all'esperimento eseguito sul gruppo di dischetti FCC (Tabelle 3 e 4).

Ulteriori trattamenti con le stesse modalità sono stati riservati a un gruppo di studio inserito in questa sperimentazione come

ulteriore parametro comparativo.

Il quinto gruppo test era rappresentato da 4 denti denominati 1 E, 2 E, 3 E, 4 E.

Dopo essere stati estratti sono stati immersi in soluzione fisiologica sodio cloruro al 0,9%. Nelle 24 ore successive i denti hanno subito il trattamento con l'AP che è stato indirizzato sulle superfici radicolari con la polvere Perio Ø <63 µm sottoponendoli agli stessi protocolli di lavoro utilizzati per trattare i dischetti in titanio del gruppo B (FCC) e D (SLA) (Tabella 5).

Preventivamente al trattamento AP tutti i denti sono stati trattati con colorazione con eritrosina che ha pigmentato tutta la superficie radicolare.

Dopo il trattamento i denti sono stati separati e messi in soluzione di formalina tamponata al 10% (formaldeide al 4%). Tutti i dischetti e i denti sono stati trattati dallo stesso operatore e sottoposti al flusso dell'AP a una distanza di circa 5 mm (Figure 5-7).

Dopo il trattamento i dischetti FCC e SLA sono stati sottoposti a una procedura di detersione per rimuovere i residui di polvere dalle superfici prima di essere inviati al laboratorio Nobel BioRicerche per i risultati.

**TABELLA 1 - PROTOCOLLI DI TRATTAMENTO GRUPPO A.**

Trattamento	Polvere Soft		
	5 sec	10 sec	20 sec
Superficie			
FCC 1A	X		
FCC 2A		X	
FCC 3A			X

**TABELLA 2 - PROTOCOLLI DI TRATTAMENTO GRUPPO B.**

Trattamento	Polvere Perio		
	5 sec	10 sec	20 sec
Superficie			
FCC 1B	X		
FCC 2B		X	
FCC 3B			X

**TABELLA 3 - PROTOCOLLI DI TRATTAMENTO GRUPPO C.**

Trattamento	Polvere Soft		
	5 sec	10 sec	20 sec
Superficie			
SLA 1C	X		
SLA 2C		X	
SLA 3C			X

**TABELLA 4 - PROTOCOLLI DI TRATTAMENTO GRUPPO D.**

Trattamento	Polvere Perio		
	5 sec	10 sec	20 sec
Superficie			
SLA 1D	X		
SLA 2D		X	
SLA 3D			X

**TABELLA 5 - PROTOCOLLI DI TRATTAMENTO GRUPPO E.**

Trattamento	Polvere Perio		
	5 sec	10 sec	20 sec
Sup. Radicolare			
Dente 1E	X		
Dente 2E	X		
Dente 3E		X	
Dente 4E			X

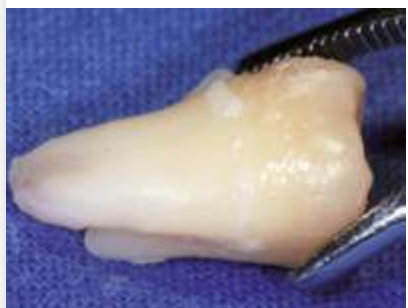



5. Distanza di lavoro.



6. Trattamento AP dischetto.



7. Dente 1 E prima del trattamento.

Le immagini al SEM sono state effettuate al fine di evidenziare su tutti i campioni trattati, titanio e denti, eventuali danni iatrogeni provocati dall'effetto meccanico (abrasione) creato dall'AP. Le osservazioni microscopiche sono state eseguite con uno strumento SEM LEO 420 (Leo Electron Microscopy Ltd).

Sono state realizzate immagini a ingrandimenti 500 x, 2000 x, 5000 x, 7500 x per i dischetti e 100 x, 500 x, 2000 x e 5000 x per i denti.

Preventivamente con il SEM avevamo provveduto a creare un caso controllo per entrambe le superfici dei dischetti, mentre il controllo delle superfici radicalari è stato eseguito lontano dalle aree trattate con l'AP.

### Risultati


Per meglio comprendere, commentare e diversificare i risultati delle superfici trattate, d'accordo con il laboratorio che ha effettuato le scansioni al SEM abbiamo adottato un sistema di codifica con valori da 0-1-2-3 assegnandola a ognuno dei campioni a seconda del grado di effetto meccanico dell'AP mostrato dal SEM nei confronti del controllo.

La codifica prevedeva un valore crescente rispetto al danno iatrogeno.


Quindi un valore  $\leq 0$  se il campione non mostrava variazioni post-trattamento, passando per i vari step: un valore  $\geq 1$  se il danno visibile risultava lieve; un valore  $\geq 2$  qualora il danno era netto; un valore  $\geq 3$  in caso di danno palese.

I dischetti (A) esaminati al SEM si presentano come qui di seguito descritto.


- 1 A: la morfologia della superficie appare leggermente modificata con l'estremità dei crateri smussati e appiattiti (Figura b); mostrando lievi differenze (codice 1) con il controllo (Figura a).
- 2 A: la morfologia della superficie appare nettamente modificata (codice 2) (Figura d) con l'estremità dei crateri decapitati rispetto




a. FCC: controllo a 5000 x.



b. FCC: dischetto 1 A a 5000 x.



c. FCC: controllo a 5000 x.




d. FCC: dischetto 2 A a 5000 x.


al controllo (Figura c).

- 3 A: il campione è poco valutabile e con un danno iatrogeno palese (codice 3) di superficie (Figura f) a causa dei tempi troppo lunghi di esposizione; sembra scomparso completamente l'ossido di


→ prevenzione - implantologia




e. FCC: controllo a 7500 x.




g. FCC: controllo a 5000 x.




l. FCC: controllo a 7500 x.



f. FCC: dischetto 3 A a 7500 x.



h. FCC: dischetto 1 B a 5000 x.




m. FCC: dischetto 3 B a 7500 x.

titanio rispetto al controllo (Figura e).  
I dischetti (B) esaminati al SEM si presentano come qui di seguito descritto.


- 1 B: non ci sono danni iatrogeni; la superficie (Figura h) risulta integra (codice 0) e sovrapponibile al controllo (Figura g).
- 2 B: la morfologia della superficie appare lievemente modificata (codice 1) (Figura k) con danni per l'estremità dei crateri più esposti al getto dell'AP rispetto al controllo (Figura i).
- 3 B: il campione è poco valutabile e con un danno iatrogeno di superficie evidente (codice 3) (Figura m) e a causa dei tempi troppo lunghi di esposizione la stessa sembra intrisa di polvere depositata tra le rugosità; sembra essere scomparso completamente l'ossido di titanio rispetto al controllo (Figura l).

I dischetti (C) esaminati al SEM si presentano come qui di seguito riportato.


- 1 C: la morfologia della superficie appare leggermente modificata (Figura o) con lievi differenze (codice 1) con il controllo (Figura n).




i. FCC: controllo a 5000 x.



n. SLA: controllo a 5000 x.




k. FCC: dischetto 2 B a 5000 x.




o. SLA: dischetto 1 C a 5000 x.

- 2 C: l'immagine della superficie appare appiattita e arrotondata (Figura q); il confronto con il controllo mostra un lieve codice 1, ma visibile danno iatrogeno (Figura p).


- 3 C: il campione è poco valutabile e con un palese danno iatrogeno (codice 3) di superficie (Figura s); la stessa sembra intrisa di polvere depositata sulla rugosità. Potrebbe essere scomparso




p. SLA: controllo a 5000 x.




t. SLA: controllo a 5000 x.




y. SLA: controllo a 7500 x.




q. SLA: dischetto 2 C a 5000 x.




u. SLA: dischetto 1 D a 5000 x.




z. SLA: dischetto 3 D a 7500 x.




r. SLA: controllo a 7500 x.



v. SLA: controllo a 5000 x.



s. SLA: dischetto 3 C a 7500 x.



w. SLA: dischetto 2 C a 5000 x.

completamente l'ossido di titanio rispetto al controllo (Figura r).

I dischetti (D) esaminati al SEM si presentano come qui di seguito descritto.

- 1 D: non ci sono danni iatrogeni evidenti

(codice 0) sulla superficie (Figura u) e nessuna differenza con il controllo (Figura t).

- 2 D: la morfologia della superficie appare lievemente modificata (codice 1) (Figura w) con danni visibili minimi rispetto al

controllo (Figura v).

- 3 D: il campione è poco valutabile e con un danno iatrogeno di superficie (Figura z) evidente (codice 3) a causa dei tempi di esposizione troppo lunghi; la polvere dell'AP si è depositata sulla rugosità e potrebbe essere scomparso completamente l'ossido di titanio rispetto al controllo (Figura y).


Le superfici radicolari dei denti trattati si presentavano al SEM come segue.

- 1 E: la superficie radicolare del dente appena estratto e trattato nelle 24 ore successive e poi sottoposta al getto dell'AP per 5 sec.


Finita l'esposizione di 5 sec all'AP con polvere Perio l'area sottoposta alla miscela aria acqua e polvere si mostrava a occhio nudo pulita dal pigmento eritrosina, ma con un'apparente depressione sulla radice come visibile a basso ingrandimento (x 100) per poi scomparire e mostrare il cemento radicolare integro a maggiori ingrandimenti (codice 0) (x 500; x 2000; x 5000). Il controllo x 2000 e x 5000




→ prevenzione - implantologia




1 E/1. Radice dentale nell'area trattata a 100 x.




1 E/2. Radice dentale nell'area trattata a 500 x.




1 E/3. Radice dentale nell'area trattata a 2000 x.




1 E/4. Radice dentale nell'area trattata a 5000 x.




1 E/5. Radice dentale non trattata a 2000 x.




1 E/6. Radice dentale non trattata a 5000 x.




2 E/1. Radice dentale nell'area trattata a 100 x.




2 E/2. Radice dentale nell'area trattata a 500 x.




2 E/3. Radice dentale nell'area trattata a 2000 x.



2 E/4. Radice dentale nell'area trattata a 5000 x.



2 E/5. Radice dentale non trattata a 2000 x.



2 E/6. Radice dentale non trattata a 5000 x.


ingrandimenti eseguito sulla stessa superficie radicolare, ma lontano dalla zona trattata, ci mostra l'intreccio delle fibre del legamento parodontale perfettamente adeso al cemento

probabilmente strappato durante le manovre di avulsione (Figure 1 E/1-1 E/6).


- 2 E: finita l'esposizione di 5 sec all'AP con polvere Perio l'area sottoposta alla miscela aria acqua e polvere si mostrava

a occhio nudo pulita dal pigmento eritrosina, ma con un'apparente depressione sulla radice visibile a basso ingrandimento (x 100) per poi scomparire e mostrare il cemento radicolare integro a


➔ prevenzione - implantologia




**3 E/1. Radice dentale nell'area trattata a 100 x.**




**3 E/2. Radice dentale nell'area trattata a 500 x.**




**3 E/3. Radice dentale nell'area trattata a 2000 x.**




**3 E/4. Radice dentale nell'area trattata a 5000 x.**




**3 E/5. Radice dentale non trattata a 2000 x.**




**3 E/6. Radice dentale non trattata a 5000 x.**




**4 E/1. Radice dentale nell'area trattata a 100 x.**




**4 E/2. Radice dentale nell'area trattata a 500 x.**




**4 E/3. Radice dentale nell'area trattata a 2000 x.**



**4 E/4. Radice dentale nell'area trattata a 5000 x.**



**4 E/5. Radice dentale non trattata a 2000 x.**



**4 E/6. Radice dentale non trattata a 5000 x.**

maggiori ingrandimenti (codice 0) (x 500; x 2000; x 5000). Il controllo (zona non trattata) x 2000 e x 5000 ingrandimenti ci mostrano l'intreccio di fibre del legamento parodontale perfettamente

adeso al cemento e forse strappato durante le manovre di avulsione (Figure 2 E/1-2 E/6).

- 3 E: finita l'esposizione di 10° all'AP con polvere Perio l'area sottoposta alla miscela

aria acqua e polvere si mostrava a occhio nudo pulita dal pigmento eritrosina, ma con una depressione sulla radice visibile a basso ingrandimento (x 100) per poi mostrare assenza di cemento radicolare e



## ➔ prevenzione - implantologia

tubuli dentinali visibili (codice 2) a maggiori ingrandimenti (x 500; x 2000; x 5000). Il controllo a ingrandimenti x 2000 e x 5000 eseguito sulla stessa superficie radicolare, ma lontano dalla zona trattata, ci mostra l'intreccio di fibre del legamento parodontale perfettamente adeso al cemento probabilmente strappato durante le manovre di avulsione (Figure 3 E/1-3 E/6).

- 4 E: finita l'esposizione di 20 sec all'AP con polvere Perio l'area sottoposta alla miscela aria acqua e polvere si mostrava a occhio nudo pulita dal pigmento eritrosina, ma con un'evidente depressione sulla radice visibile a basso ingrandimento (x 100) per poi mostrare l'assenza di cemento radicolare con i tubuli dentinali esposti e visibilmente pervi (codice 3) a maggiori ingrandimenti (x 500; x 2000; x 5000) (Figure 4 E/1-4 E/6).

Abbiamo riportato tutti i dati ottenuti perché siano interpretati come sperimentali nella Tabella 6.

Dall'analisi al SEM delle foto, le superfici dei dischi di titanio trattati con il tempo di 5" e con polvere Perio sono risultati non danneggiati dall'effetto meccanico abrasivo del sistema AP.

Le irregolarità della morfologia

dell'impianto, trattato a una pressione di lavoro con settaggi estremi, si sono presentate doppie in funzione del tempo di esposizione all'AP, quindi il danno iatrogeno è direttamente proporzionale rispetto a questi parametri.

L'azione meccanica abrasiva della miscela aria acqua e polvere può creare grosse irregolarità indesiderate indipendentemente dalla superficie trattata.

### Discussione e conclusioni

Una delle principali problematiche nel trattamento della mucosite e peri-implantite è l'eliminazione dei depositi batterici dalla superficie implantare. L'effetto dell'AP ha dimostrato un'estrema efficacia sia con polveri di bicarbonato che con polvere Perio su pazienti in TPS (Terapia Parodontale di Supporto)<sup>10,11</sup>. Attualmente nella terapia parodontale chirurgica e non chirurgica per il trattamento delle infezioni peri-implantari si effettuano manovre con una strumentazione manuale o meccanica associate a un trattamento farmacologico. Nuove indicazioni prevedono l'uso dell'AP come trattamento decontaminante<sup>12,13</sup>.

Nel caso di impianti con superficie rugosa

la decontaminazione batterica potrebbe essere più semplice se eseguita con l'AP rispetto al trattamento delle superfici lisce. La strumentazione meccanica e/o manuale altera la topografia superficiale dell'elemento implantare<sup>12</sup>.

Dai risultati dell'analisi al SEM non si notano cambiamenti nella morfologia della superficie in titanio nel caso in cui si usino tempi di lavoro ridotti associati con polvere Perio in quanto decisamente meno abrasiva dell'AP convenzionale con polvere di Bicarbonato.

Evidenti danni iatrogeni di superficie con codice 3 (+++) rispetto al gruppo controllo, si sono mostrati indipendentemente dalla polvere utilizzata o dal tipo di campione (FCC, SLA o denti) trattato con AP.

Tutti i campioni con il codice 3 (+++) provenivano dagli step di trattamento con un tempo di esposizione di 20" corrispondenti ai dischetti 3 A (FCC), 3B (FCC), 3C (SLA), 3D (SLA) e al dente 4E (dente).

Quattro codici 1 (+) si sono avuti con i campioni di dischetti 1A (FCC), 1 C (SLA), 2 B (FCC), 2 D (SLA), corrispondenti i primi due a un'esposizione all'AP di 5" con polvere Soft (Ø 125 µm) e i secondi due a 10 sec di esposizione all'AP con polvere Perio (Ø 63 µm).

Tre codici 2 (++) si sono ottenuti con i campioni 2 A (FCC), 2 C (SLA) e 3 E (dente) corrispondenti a 10 sec di esposizione all'AP con polvere Soft (Ø 125 µm).

Quattro codici 0 (-) si sono ritrovati sui campioni 1 B (FCC), 1 D (SLA), 1 E (dente) e 2E (dente) corrispondenti a un tempo di 5" di esposizione all'AP con polvere Perio (Ø 63 µm).

Si sono dimostrati danni visibili nel caso in cui i gruppi di campioni siano stati trattati con tempi di esposizione lunghi (>5") e con polveri con granulometria Ø >63 µm mentre con tempi di esposizione di ≤5" il danno iatrogeno è stato nullo<sup>13</sup>.

TABELLA 6 - RISULTATI DEI DIFFERENTI STEP

Tempo	FCC*	FCC**	SLA*	SLA**	ROOTS**
5"	+	-	+	-	-
10"	++	+	+	+	++
20"	+++	+++	+++	+++	+++

#### Legenda

*	Polvere Soft
**	Polvere Perio
+	Danno
-	No danno

## ➔ prevenzione - implantologia

L'analisi al microscopio elettronico a scansione, per sua natura, fornisce informazioni solo sulle modificazioni della morfologia superficiale degli impianti post-trattamento.

Inoltre, il SEM non ci dice se la chimica degli strati superficiali trattati con questo sistema, oggetto dello studio, si sia modificata negli impianti e nelle radici dentali, cioè quelli che interagiscono con i sistemi biologici.

I risultati del presente studio hanno dimostrato che non tutti i tempi e le polveri sono idonee per evitare un danno iatrogeno.

Un cauto utilizzo deve essere riservato all'utilizzo dell'AP con polvere Soft prevedendo sempre un tempo limite di 5" per area di trattamento.

È fondamentale porre attenzione anche alla superficie da trattare in quanto a parità di tempo di esposizione la FCC è risultata essere più sensibile alla metodica AP rispetto alla superficie SLA.

Infatti, diversi valori di codice si sono presentati sul dischetto FCC campione 2 A

(codice 2++) vs dischetto SLA campione 2 C (codice 1+) entrambi sottoposti a 10" di esposizione con AP abbinato alla polvere Soft.

Da qui la considerazione che tutte le fasi di riabilitazione implantoprotesica, compresa la conoscenza della superficie dell'impianto inserito, sono di competenza dell'igienista dentale.

Il professionista anche quando non è coinvolto come attore principale ha l'obbligo di conoscere tutte le informazioni utili nelle fasi di "follow up" del paziente indispensabili per il successo a medio-lungo termine della terapia implantare.

In particolare, è importante sapere che la AP con polvere Perio si è dimostrata valida su tutte le superfici oggetto di questo studio, sia sui dischetti in titanio che sulle superfici radicolari dei denti, a patto che l'AP venga utilizzato con il limite massimo di 5" per area di trattamento se non si vuole creare un evidente danno iatrogeno.

Alla luce dei risultati ottenuti dall'analisi di tutti i campioni trattati emerge come il nostro studio abbia confermato i dati

conclusivi pubblicati da Petersilka e coll.<sup>11</sup> nei quali veniva raccomandato l'utilizzo di questa metodica AP con glicina (polvere Perio Ø ≤63 µm) per un tempo limite di esposizione di 5" per superficie (mesiale, distale, vestibolare o linguale) nel mantenimento di pazienti parodontali durante la TPS.

I risultati ottenuti dalle analisi *in vitro* della presente ricerca scientifica saranno poi da confermare con studi *in vivo* su superfici implantari da trattare nei casi di peri-implantite e su superfici radicolari in pazienti affetti da parodontite.

© RIPRODUZIONE RISERVATA

### Corrispondenza

Pier Paolo Paganin  
Tel. +39 3484515170  
ppaganin@me.com

### Ringraziamenti

Desidero ringraziare particolarmente per la collaborazione coloro che hanno reso possibile la stesura di questo lavoro: la dottoressa Elisabetta Maria Polizzi, Dir. Centro di Igiene Orale e Prevenzione IRCCS Ospedale San Raffaele di Milano, e il dottor Carlo Alberto Cortella, Consulente Univ. Vita Salute San Raffaele di Milano.

● **PAROLE CHIAVE:** mucosite, perimplantite, airpolishing, dental implant, Air Abrasion.

## bibliografia

- Esposito et al. A 5-years follow up comparative analysis of various osteointegrated dental implant systems: a systematic review of randomized controlled clinical trials. *Int J Oral Maxillofac Implants* 2005;20:557-568.
- Sixth European Workshop on Periodontology. *J Clin Periodontol* 2008;35(8):282-285.
- Quiriyenen M, et al. The influence of surface free energy and surface roughness on early plaque formation. *J Clin Periodontol* 1990;17:138.
- Quiriyenen M, et al. Infections risks for oral implants: A review of the literature. *Clinical Oral Implants Research* 2002;13(1):1-19.
- Homiak AW, et al. Effects of hygiene instrumentation on titanium abutments: A scanning electron microscopy study. *J of Prosth Dent* 1992;67(3):364-9.
- Mengel R, et al. An in vitro study of the treatment of implant surfaces with different instruments. *Int J of Oral and Maxillofacial Implants* 1998;13(1):91-96.
- Bianchi AE. Implantologia e Implantoprotesi. *Basi biologiche, biomeccanica, applicazioni cliniche*. Torino: Utet, 1999.
- Cochran DL. A comparison of endosseous dental implant surfaces. *J Periodontol* 1999;70:1523-1539.
- Suzuki K, et al. Effects of surface roughness of titanium implants on bone remodeling activity of femur in rabbits. *Bone* 1997;21:507-514.
- Flemmig TF, et al. Subgingival debridement efficacy of glycine powder air-polishing. *Journal of Periodontology* 2007;78:1002-1010.
- Petersilka G, et al. Subgingival Plaque Removal at Interdental Sites Using a Low Abrasive Air Polishing Powder. *J Periodontol* 2003;74(3):307-11.
- Matarasso S, et al. Maintenance of implants: An in vitro study of titanium implant surface modifications subsequent to the application of different prophylaxis procedures. *Clinical Oral Implants Research* 1996;7(1):64-72.
- Petersilka G, et al. In vitro evaluation of novel low abrasive air polishing powders. *J Clin Periodontol* 2003;30:9-13.



## TERAPIA IMPLANTARE IN PAZIENTI HIV POSITIVI: STUDIO CLINICO PROSPETTICO

Dental School (Dean Prof. Enrico F. Gherlone)  
Vita-Salute University San Raffaele, Milan - Italy

\* G. Gori, P. Capparè, A. Ligabue, A. Cardarelli, D. De Filippi, M. Nagni, R. Vinci

*Roma, 18-20 Aprile 2013*



### Introduzione

Le riabilitazioni implantari sono considerate una possibilità terapeutica affidabile nei casi di estrazioni dentarie. Negli anni i protocolli chirurgici e protesici sono cambiati: dal primo articolo di Branemark del 1977 che studiava impianti sommersi lasciati guarire per mesi, oggi è dimostrato come anche gli impianti post estrattivi ed il carico immediato abbiano una elevata percentuale di successo. Le controindicazioni per l'osteointegrazione possono essere divise in "sistemiche" e "locali" in relazione al fatto che i fattori di rischio siano legati allo stato di salute del paziente o al sito di intervento. I pazienti immunocompromessi sono considerati una popolazione ad elevato rischio di complicazioni e fallimenti per la terapia implantare.

#### SCOPO DELLO STUDIO

Valutare la percentuale di sopravvivenza degli impianti in pazienti immunocompromessi con follow up a 12 mesi.

#### MATERIALI E METODI

Nel nostro studio sono stati arruolati solo pazienti HIV positivi, con necessità di riabilitazioni implanto-protesiche, parzialmente o totalmente edentuli, con un adeguato volume di osso e valori ematici che rientrassero nei seguenti parametri ematochimici: > 8 mg/dl; Conta assoluta dei neutrofili > 750 cellule/mm<sup>3</sup>; Piastrine > 75.000/mm<sup>3</sup>; AST < 5 volte il valore normale; Billirubina < 2.5 volte il valore normale; Fosfatasi alcalina < 5 volte il valore normale; Creatinina < 2.5 mg/ml(ULN). Sono stati inseriti gli impianti in accordo con il piano di trattamento concordato con il paziente. Dopo una guarigione di 60 giorni per la mandibola e di 90 per la mascella è stato eseguito il carico protesico. Le visite di controllo sono state programmate a 3, 6 e 12 mesi dopo l'inserzione degli impianti. Ad ogni controllo sono stati rilevati e registrati gli indici di salute implantare, quali la profondità di sondaggio, l'indice di placca e il test di sanguinamento. Il livello osseo attorno agli impianti è stato valutato con l'esecuzione di rx periapicali con supporti personalizzati.








### RISULTATI

Tra novembre 2008 e Maggio 2011, 68 pazienti sono stati arruolati in questo studio condotto presso l'Istituto Scientifico Universitario San Raffaele di Milano. Tre pazienti non hanno completato il periodo di follow up. Età media dei pazienti: 55,3±17,2 anni; il valore medio di linfociti di: 769 celle/mm<sup>3</sup>. Sono stati inseriti 190 impianti; 15 impianti sono falliti nei primi 2 mesi a causa di perimplantiti, con un tasso di sopravvivenza del 92,1%. PD, PI e BOP non hanno evidenziato importanti differenze dalla baseline. Il riassorbimento osseo medio è stato di 1,09±0,81 mm.

### Conclusioni

Questo studio ha dimostrato che risultati prevedibili possono essere raggiunti anche nei pazienti affetti da HIV, quando degli specifici criteri d'inclusione vengono selezionati. Abbiamo riscontrato l'importanza della figura dell'igienista dentale che ha motivato i pazienti al mantenimento di una corretta igiene orale ad ogni visita di controllo.

**BIBLIOGRAFIA**

Oliveira MA, Gallotini M, Fallois D, Mahf PS, Jablonka F, Ontogo KL. The success of endosseous implants in human immunodeficiency virus-positive patients receiving antiretroviral therapy: a pilot study. *J Am Dent Assoc* 2011; Sep; 142:1010-1016.

Kollathkar S, Khalid S, Roloeki A, Bhole M, Winkler JR. Immediate dental implant placement in HIV-positive patients receiving highly active antiretroviral therapy: a report of two cases and a review of the literature of implants placed in HIV-positive individuals. *J Periodontol* 2011; Mar; 82: 505-511.

Stevenson GC, Riano PC, Murrell AJ, Nichols CM, Engelmeier RL, Flatz CM. Short-term success of osseointegrated dental implants in HIV-positive individuals: a prospective study. *J Contemp Dent Pract* 2007; Jan; 8:1-10.



I.R.C.C.S. Ospedale San Raffaele (MI)  
Unità Operativa Complessa di Odontoiatria  
Centro di Igiene Orale e Prevenzione  
Direttore: Prof. Enrico F. Gherlone



Università Vita-Salute San Raffaele (MI)  
Facoltà di Medicina e Chirurgia  
Corso di Laurea in Igiene Dentale  
Presidente: Prof. Enrico F. Gherlone

## Un ausilio all'igiene orale in pazienti disabili

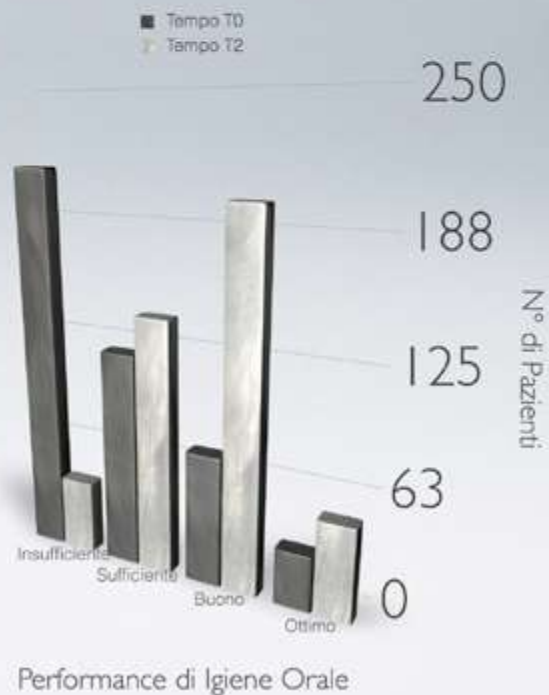
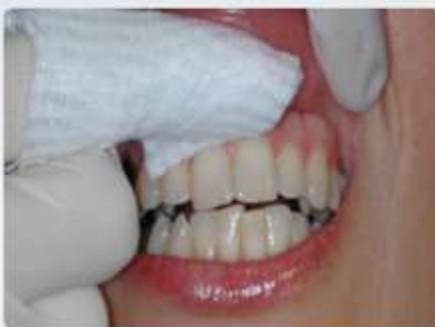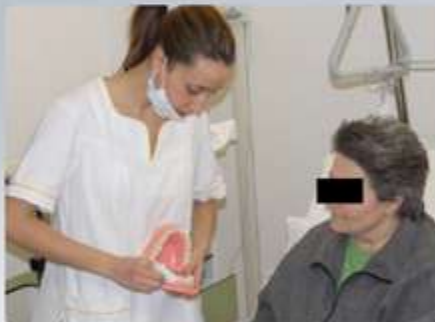E. M. Polizzi\*, A. Marchisio\*, M. Nagni\*, M. Roncati\*\*, A. Lucchese\*\*\*

**Obiettivi:** lo scopo dello studio è verificare l'ipotesi di come l'uso di una garza monouso imbevuta di 3ml di clorexidina 0.12%, possa risultare efficace in pazienti diversamente abili come ausilio alle metodiche di igiene orale tradizionale.

**Materiali e Metodi:** è stato compilato un questionario per valutare le abilità del paziente disabile nelle tecniche d'igiene orale domiciliare (T0). Il paziente è stato istruito all'utilizzo di una garza come ausilio all'igiene orale quotidiana. È stato utilizzato un set didattico composto da un opuscolo informativo e da un modello di una bocca. Dopo 45 giorni il questionario è stato ricompilato per valutare il miglioramento della "performance" (T1).

**Risultati:** l'utilizzo di una garza associata all'insegnamento delle corrette manovre di igiene orale si è rivelato un ottimo strumento per il miglioramento della salute.

**Conclusioni:** visti i risultati, è emersa la necessità immediata di diffondere le basi della prevenzione odontoiatrica all'interno delle strutture riabilitative, nelle comunità di lunga degenza, nei centri territoriali e centri diurni.



\*Università Vita e Salute San Raffaele  
\*\*Praticante Libero Professionista  
\*\*\*Università di Ferrara





**1 Injectable Magnesium - Enriched Hydroxyapatite Putty in Perimplant Defects: A Histomorphometric Analysis in Pigs**

R. Crespi, P. Capparè, A. Addis, E. F. Gherlone

The International Journal of Oral & Maxillofacial Implants Vol 27, N° 1 2012

---

**2 Use of Piezosurgery During Maxillary Sinus Elevation: Clinical Results of 40 Consecutive Cases**

M. Cassetta, L. Ricci, G. Iezzi, S. Calasso, A. Piattelli, V. Perrotti

The International Journal of Periodontics & Restorative Dentistry Vol.32 N°6 2012

---

**3 Effects of Mechanical versus manual non surgical periodontal therapy on patient comfort and periodontal healing: a randomized controlled clinical trials**

A.Quaranta, G.Rappelli, E.Santarelli, M.Bossù e M.Piemontese

European Journal of Inflammation Vol.10 N°2 vol.10 No (S),0-0 (2012)

---

**4 Immunohistochemical analysis of Matrix Metalloproteinase -9, Vascular Endothelial Growth Factor. Bone Sialoprotein and i-Nitric Oxide Synthase in Calvaria vs. iliac Crest Bone Grafts**

S. Tetè, S. Zara, V. Zizzari, A. De Carlo, R. Vinci, A. Cataldi, E. F. Gherlone

Clinical Oral Implant Research 2012; vol.30 n.3: 217-23

---

**5 Macroscopic and Microscopic evaluation of a new implant design supporting immediately loaded full arch rehabilitation**

S. Tetè, V. Zizzari, A. De Carlo, B. Sinjari, E. F. Gherlone

Annali di Stomatologia 2012; vol.3 n.2: 44-50

---

**6 Crestal bone remodeling around platform switched, immediately loaded implants placed in sites of previous failures**

A.Quaranta, A.Cicconetti, L.Battaglia, M.Piemontese, G.Pompa,I.Vozza

European Journal of Inflammation Vol.10 N°2 Accepted July 30 2012

## Injectable Magnesium-Enriched Hydroxyapatite Putty in Peri-Implant Defects: A Histomorphometric Analysis in Pigs

Roberto Crespi, MD, MS<sup>1</sup>/Paolo Capparà, MD<sup>2</sup>/Alessandro Addis, DVM<sup>3</sup>/Enrico Gherlone, MD, DMD, PhD<sup>4</sup>

**Purpose:** The purpose of this study was to evaluate the healing of an injectable mixture of nanoparticles of magnesium-enriched hydroxyapatite (mHA) in peri-implant defects. **Materials and Methods:** Thirty-two dental implants were placed in 16 tibiae of eight female Large White pigs. In each animal, four implant beds (two sites each tibia) with medial three-wall intrabony defects were prepared. Via random selection, one bone defect in each tibia was filled with injectable mHA putty ( $n = 16$ , test group), whereas the other defect was not filled ( $n = 16$ , control group). Two animals were sacrificed after 2 weeks, two after 4 weeks, two after 6 weeks, and two after 8 weeks. In all, 32 block section samples were obtained for histologic and histomorphometric analyses. **Results:** The test group exhibited statistically significantly higher values for bone-to-implant contact (BIC) and lower amounts of connective tissue (CT) over time. The test group showed a remarkable increase in vital bone values between 6 and 8 weeks after implant placement. After 8 weeks, the injectable mHA was almost completely resorbed. **Conclusions:** Injectable mHA putty could be a useful and suitable bone grafting material in peri-implant defects. *INT J ORAL MAXILLOFAC IMPLANTS* 2012;27:95-101

**Key words:** animal study, bone graft, hydroxyapatite, magnesium-enriched hydroxyapatite, peri-implant defect

Peri implant gaps are the most common type of bone defect associated with placement of an implant in a fresh extraction socket<sup>1</sup> and in manifestations of peri-implantitis.<sup>2</sup> The increasing trend toward implant placement immediately after extraction<sup>3-7</sup> makes problems associated with peri-implant bone defects more likely because of the incongruity of extraction socket walls and implant walls; such sites may require a bone graft to fill the defect gap.

Bone dehiscence resulting from peri-implantitis, overheating of bone during surgical procedures, and a low volume of native bone may be treated by several procedures, but they do not address bone regeneration. Guided bone regeneration procedures can treat bone defects adjacent to dental implants,<sup>8</sup> but membrane exposure and subsequent bacterial colonization can lead to treatment failure.<sup>9</sup>

To preserve alveolar bone and avoid invasive ridge augmentation procedures, several biomaterials have been advocated immediately following tooth extraction to ensure the formation of alveolar bone within implant sites. Bone allograft, bone autograft, and xenografts<sup>10</sup> have all been proposed to maintain bone volume of the alveoli. Because of their biocompatibility and bioactivity, hydroxyapatite (HA) ceramics are commonly used in bone grafting and dental devices as bone substitutes,<sup>11,12</sup> since they have the ability to induce mesenchymal cells to differentiate into osteoblasts; this capacity means that HA ceramics are a potential scaffold material for bone tissue engineering.<sup>13,14</sup> Furthermore, animal and human studies of block, granulated, and powdered forms of calcium phosphate ceramics have proven their efficacy as bone substitute materials for the repair of bone defects.<sup>15,16</sup>

Histologic studies of the healing response to these graft materials with respect to the implant-biomaterial interface and defect filling are mandatory for clinicians to build a scientific basis for selection of the most suitable grafting material(s) for the resolution of defects around implants. The purpose of this study, therefore, was to evaluate histologically the healing during the first 8 weeks following injection of a mixture of nanoparticles of magnesium-enriched hydroxyapatite (mHA) placed in peri-implant bone defects in an animal model.

<sup>1</sup>Clinical Professor, Department of Dentistry, Vita Salute University, San Raffaele Hospital, Milan, Italy.

<sup>2</sup>Clinician, Department of Dentistry, Vita Salute University, San Raffaele Hospital, Milan, Italy.

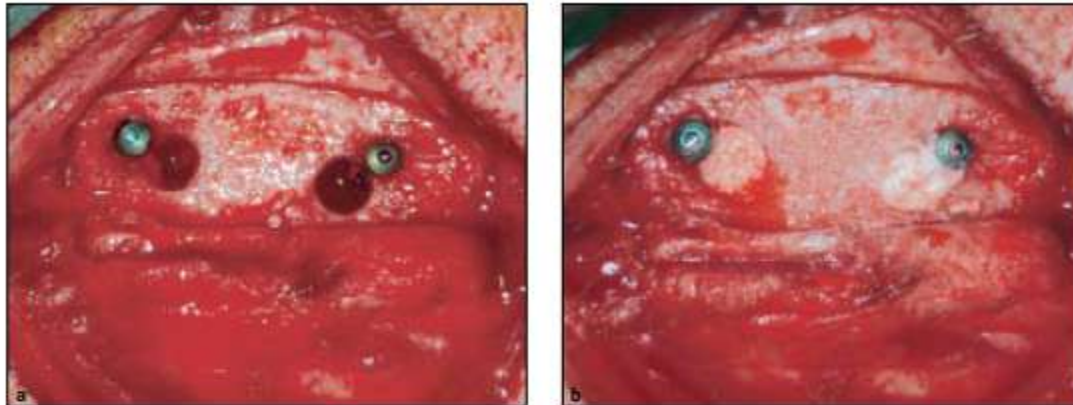
<sup>3</sup>Private practice, Laboratory Animal Science Lazzaro Spallanzani, Milan, Italy.

<sup>4</sup>Full Professor and Chairman, Department of Dentistry, Vita Salute University, San Raffaele Hospital, Milan, Italy.

**Correspondence to:** Dr Roberto Crespi, Department of Dentistry, Vita Salute University, San Raffaele Hospital, Via Olgettina No. 48, 20123 Milano, Italy. Email: robcresp@libero.it



Crespi et al



**Fig 1.** (a) Implants and defects. The 5-mm-diameter defects were created on the medial of each implant site with a trephine bur. (b) MHA graft in place in the defects.

## MATERIALS AND METHODS

### Animals

Eight female Large White pigs, about 5 months old and weighing on average 70 kg ( $70 \pm 4$  kg), were used. All animals were treated in accordance with the policies and principles of laboratory animal care and with the European Union guidelines (86/609/EEC) approved by the Italian Ministry of Health (Law 116/92).

Pigs were housed separately in standard boxes in temperature-controlled rooms ( $15^{\circ}\text{C}$  to  $20^{\circ}\text{C}$ ) and were allowed to move freely within their boxes. They underwent an adaptation and observation period for 1 week prior to surgery, during which they were fed twice daily with a standard commercial pig diet. Prior to surgery, the pigs fasted overnight, but they were allowed free access to water.

### Surgical Treatment

For all procedures, heavy sedation was first obtained by intramuscular administration of ketamine (10 mg/kg) and midazolam (0.5 mg/kg). Anesthesia was obtained via an oronasal mask with a mixture of isoflurane 4% and oxygen and maintained through intubation with the same gas mixture (isoflurane 3.5%). Intraoperative analgesia was provided with tramadol (1 mg/kg intravenously) plus meloxicam (0.4 mg/kg). To prevent infection, the animals received marbofloxacin (2 mg/kg intravenously) and long-acting amoxicillin (15 mg/kg intramuscularly) at the time of surgery.

The legs were shaved, washed, and decontaminated with a povidone-iodine scrub prior to surgical draping. The proximal tibial metaphysis was surgically exposed via a skin incision and the muscles were dissected to allow elevation of the periosteum using sterile surgical

techniques. In each animal, four implant beds (two sites in each tibia) were prepared with a medial three-walled intrabony defect. Two implants (Winsix) were placed in each tibia. By random selection, the medial bone defect was filled with injectable mHA putty (SintLife Putty, Finceramica) (test group), while the other defect was not filled (control group). The injectable mHA putty (SintLife Putty, Finceramica) used in this study is a novel malleable bone paste made up of nanoparticles and 450- to 900- $\mu\text{m}$  granules of mHA in phosphate-buffered saline solution; its chemical (composition) and chemical-physical (crystallinity) properties correspond to those of human bone matrix. In total, 32 implants were placed (16 in the test group and 16 in the control group).

The implant sites were prepared following the Brånemark protocol (Nobel Biocare). A series of drills with increasing diameters were used under profuse irrigation with sterile saline. Before implant placement, a standardized three-wall intrabony defect ( $5 \times 5 \times 5$  mm) was created at the medial of each intended implant site with a 5-mm-diameter trephine bur (Fig 1a). The bone on the distal side of each implant was left intact.

Dental implants (Winsix), 3.3 mm in diameter and 15 mm in length with a sandblasted surface, were positioned such that the coronal-most portion of the implant body was level with the osseous crest. The implants were placed after threading with a screw tap, with the head on top of the cortex. All implants achieved good primary stability following insertion. For the 16 experimental implants, the injectable mHA was spread by a syringe into the three-wall defect sites; in the 16 control sites, the bone defects were unfilled. Excess putty was removed and the remaining material was shaped to the geometry of the defect (Fig 1b). The



soft tissues were reapproximated and closed with 4-0 resorbable sutures. The fascia and skin were sutured in separate layers with resorbable sutures.

Postoperatively, the animals were given meloxicam (0.4 mg/kg intramuscularly) and enrofloxacin (5 mg/kg intramuscularly) once a day for the following 4 days.

Two animals were sacrificed after 2 weeks of healing, two animals after 4 weeks, two after 6 weeks, and two after 8 weeks with an intravenous overdose of potassium chloride after they had been anesthetized as described previously.

### Histologic Preparation

The tibiae were block-resected with an oscillating autopsy saw. The recovered segments with implants were preserved and fixed for 7 days in 4% buffered paraformaldehyde, dehydrated in a graded series of alcohols (24 hours each in 50%, 75%, 95%, and 100%), and embedded in methyl methacrylate (Merck Schuchardt).

The samples were cleaned of all soft tissue; then they were fixed in Karnovsky's fixative and dehydrated in a graded series of alcohols for undecalcified bone processing in glycol methyl methacrylate. Blocks were sectioned along the sagittal plane, perpendicular to the implant's major axis, and cut with a 1600 machinery cutter (Leica Microsystems). Three sections per implant were obtained in a longitudinal direction, parallel to the implant axis.

Sections, each 15  $\mu$ m thick, were obtained and stained with Goldner trichrome (modification). The sections were placed in Weigert hematoxylin, washed in tap water, and differentiated with 0.5% acid alcohol. Next, they were stained in Ponceau/acid fuchsin/azophloxine and counterstained with phosphomolybdic acid/orange G and light green (so that nuclei would appear blue-black, osteoid and collagen fibers would appear red, and mineralized bone would stain green). Histologic samples were observed with a FOMI III microscope by Normasky differential interference contrast (Fomi III, Carl Zeiss).

### Histomorphometric Analysis

Measurements were made in the area of the previous bone defect outside the implant threads.<sup>17</sup> For each defect site, the percentages of bone-to-implant contact (BIC), vital bone (VB), connective tissue (CT), and residual graft material (RGM) were recorded using histomorphometric analysis and were evaluated. BIC was defined as the percentage of the length of the region in which bone is directly opposed to the implant without the presence of fibrous tissue. All measurements were repeated for test and control sites, and the presented data were based on the average of the three measured sections.

For measurement of the bone-regenerative efficacy of the mHA injectable putty in the bone defects, each section was examined at a magnification of 10 $\times$  with a light microscope (Axioskope, Carl Zeiss) connected to a digital camera (Leica DC 280, Leica Microsystems), and a software program (Alexasoft Image Pro Plus 2.5, Microcontrol) was used to evaluate and calculate the histomorphometric parameters.

### Statistical Analysis

Dedicated software was used for all statistical analyses (SPSS version 11.5.0, IBM). All values were presented as means  $\pm$  standard deviations. Comparisons between test and control groups were performed with the Student *t* test ( $P < .05$  was considered the threshold for statistical significance).

## RESULTS

Postoperative healing at different intervals following implant placement was uneventful in all pigs. Radiologic examination revealed no pathologic processes around implants.

### Histologic Findings

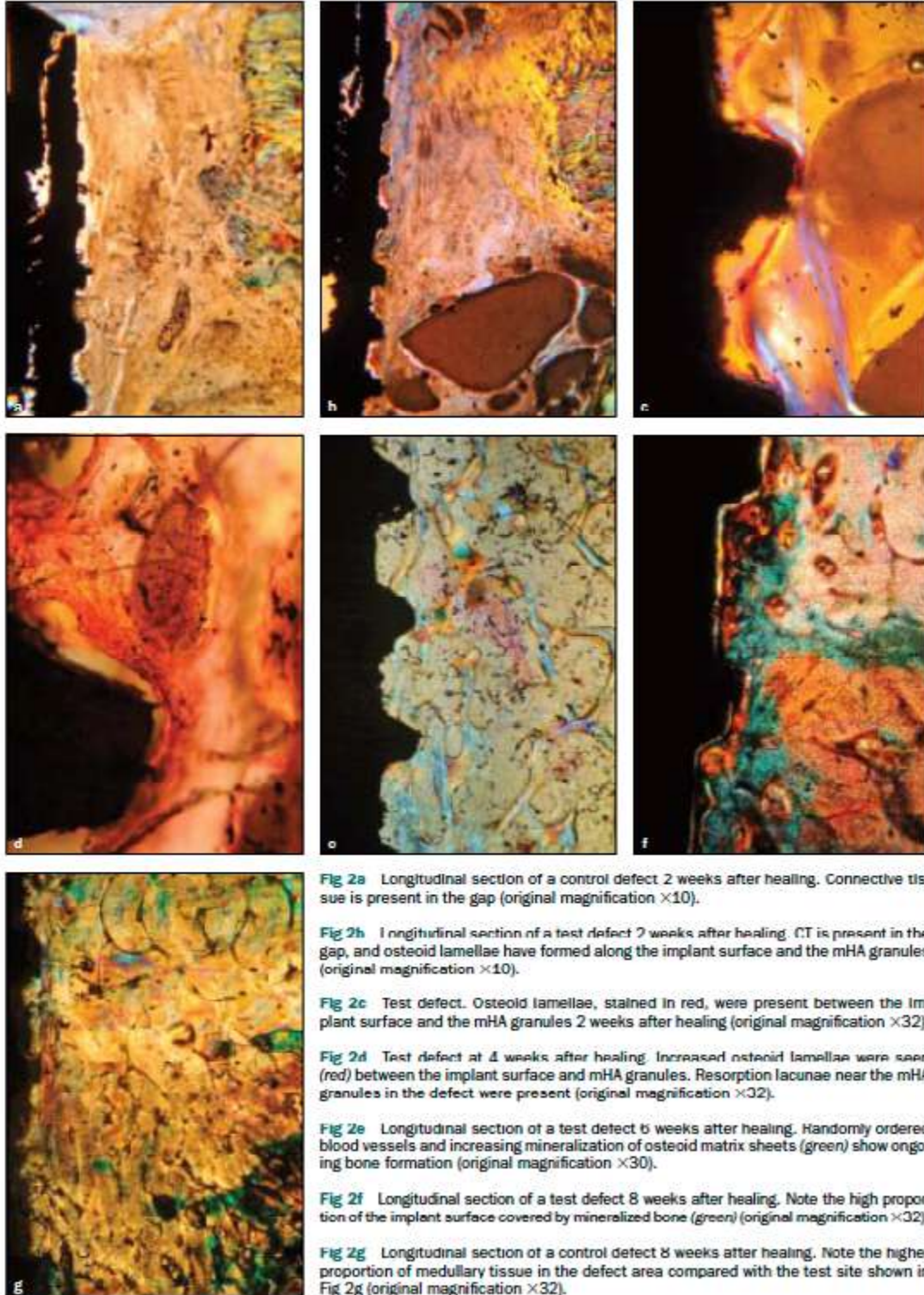
All implants were osseointegrated, and there was no sign of inflammatory response. After 2 weeks it was possible to observe osteoid matrix between the implant surface and the mHA particles, showing the good osteogenic potential of the bone substitute. New bone formation began just after surgery, since osteoid lamellae were present between the implant surface and the mHA granules. In comparison, no lamellar formation was observed after 2 weeks in unfilled defects (Figs 2a to 2c).

After 4 weeks, osteogenic activity could be seen originating from the bottom and the walls of the defect, and an osteoid deposition matrix surrounded the mHA granules and implant surfaces (Fig 2d). At that time osteoclastlike cells were seen in resorption lacunae, providing evidence that the biomaterial was being actively replaced by new bone. Osseointegration and remodeling processes could be observed along the bone-implant interface in both test and control sections.

After 6 weeks, the mHA was in direct contact with the host bone in all sections, and woven bone tissue was in contact with the implant surface (Fig 2e). After 8 weeks, the mHA in the defect sites had been replaced by new bone and new osteons were seen (Fig 2f). A lamellar pattern, stained in green, revealed bone apposition along the implant surface and the resorption of mHA granules by macrophagic activity. In test group specimens at 8 weeks, more lamellar bone apposition was observed than in the control specimens, where more medullary tissue rich in fat cells was seen (Fig 2g).



Crespi et al





**Table 1 Histomorphometric Results 2 Weeks After Implant Placement**

Parameter	Test (n = 4)	Control (n = 4)
BIC (%)	44.1 ± 11.9*	18.7 ± 7.0*
VB (%)	27.1 ± 11.9	11.1 ± 11.9
CT (%)	17.7 ± 6.3*	61.2 ± 8.1*
RGM (%)	63.2 ± 11.1	–

\*Statistically significant difference between test and control groups ( $P < .05$ ).

**Table 2 Histomorphometric Results 4 Weeks After Implant Placement**

Parameter	Test (n = 4)	Control (n = 4)
BIC (%)	47.3 ± 11.3*	27.0 ± 5.9*
VB (%)	28.8 ± 10.5	36.1 ± 11.3
CT (%)	23.3 ± 5.6*	58.6 ± 9.2*
RGM (%)	50.1 ± 8.4	–

\*Statistically significant difference between test and control groups ( $P < .05$ ).

**Table 3 Histomorphometric Results 6 Weeks After Implant Placement**

Parameter	Test (n = 4)	Control (n = 4)
BIC (%)	49.9 ± 8.1*	31.9 ± 6.7*
VB (%)	30.0 ± 9.7	36.8 ± 10.7
CT (%)	23.8 ± 7.0*	61.2 ± 10.1*
RGM (%)	49.8 ± 9.1	–

\*Statistically significant difference between test and control groups ( $P < .05$ ).

**Table 4 Histomorphometric Results 8 Weeks After Implant Placement**

Parameter	Test (n = 4)	Control (n = 4)
BIC (%)	57.2 ± 6.9*	40.8 ± 7.8*
VB (%)	65.1 ± 11.2*	42.3 ± 9.5*
CT (%)	29.0 ± 7.9*	64.5 ± 10.6*
RGM (%)	6.2 ± 5.1	–

\*Statistically significant difference between test and control groups ( $P < .05$ ).

These observations provide evidence that mHA served as a good scaffold for new bone regeneration, maintaining the volume of the defect and allowing the bone to mineralize around the implant surface.

#### Histomorphometric Observations

The recorded histomorphometric values in test and control sites are reported in Tables 1 to 4.

In sections obtained from pigs sacrificed after 2 weeks (Table 1), test sites demonstrated statistically significantly higher mean BIC values than control sites. At the same time, test group samples presented statistically significantly lower values for CT than control group samples. No statistically significant differences were found for VB. RGM was 63.2% ± 11.1%.

In sections obtained from pigs sacrificed after 4 and 6 weeks (Tables 2 and 3, respectively), a similar trend was observed. The test group demonstrated a statistically higher mean BIC value than the control group, along with statistically significant lower CT values than the control group at both time points. No statistically significant differences were found for VB.

At 8 weeks after implant placement (Table 4), the test group again demonstrated statistically significantly greater mean BIC values than the control group (57.2% ± 6.9% versus 40.8% ± 7.8%, respectively) and statistically significantly lower values for CT than the control group (29.0% ± 7.9% versus 64.5% ± 10.6%). At this time point, statistically significant differences were found for VB: the test group reported a significantly

higher value than the control group (65.1% ± 11.2% versus 42.3% ± 9.5%). Residual graft material was 6.2% ± 5.1%.

Overall, the test group reported consistently higher values for BIC and lower values for CT. In addition, between 6 and 8 weeks after implant placement, test sites showed a remarkable increase in VB. After 8 weeks, the graft material had been almost completely resorbed.

#### DISCUSSION

In the present study, oral implants were placed in pig tibiae to evaluate the effect of placement of an injectable mHA putty in a peri-implant dehiscence model, since the pig features bone remodeling processes that are similar to those of humans, comprising both trabecular and intracortical basic multicellular unit-based remodeling.<sup>18,19</sup> A study of the effects of fluoride on cortical bone remodeling in growing pigs showed that these animals have a cortical bone mineralization rate that is similar to that of humans.<sup>20</sup> Therefore, pig tibiae seem to be suitable for evaluation of a peri-implant bone defect, as this site features abundant bone volume. The animals were sacrificed every 2 weeks to evaluate the deposition of osteoid matrix, the formation of lamellar bone between the implant surface and the biomaterial granules, and the timing of the resorption of injectable mHA putty.



## Crespi et al

The current study demonstrated a beneficial effect on bone formation and mineralization following the addition of injectable mHA putty to the bone defects, since osteoid lamellar bone was present after only 2 weeks between the implant surface and the mHA granules. In comparison, no lamellar formation was observed at 2 weeks in the unfilled defects. The osteoid matrix was successively substituted by lamellar bone around the implant surfaces, resulting in a high percentage of BIC.

No foreign-body reactions or inflammatory responses were observed histologically around the injectable mHA putty used in this study. Only small circular zones of the biomaterial remained in direct contact with new bone tissue after 8 weeks. Furthermore, after 8 weeks of healing, no injectable mHA particles were observed in contact with the implant surface, showing favorable biodegradation and substitution because of the chemical composition and micromorphometry of the biomaterial.

These histologic and histomorphometric results may be explained better by a study in humans in which mHA and autogenous bone graft for maxillary sinus elevation were compared.<sup>21</sup> Gene expression analyses indicated that primary osteoblasts from mHA-grafted samples displayed enhanced expression of the osteoblast-specific differentiation factor *Cbfa1* and osteocalcin, a marker of matrix forming activity. Moreover, osteoblasts from the biomaterial-engrafted sites revealed a marked decrease in receptor activator of nuclear factor kappa B ligand (RANKL) expression, with comparable levels of osteoprotegerin, thus revealing a decreased RANKL/osteoprotegerin ratio; this may explain the decreased osteoclast differentiation and activity and the comparable bone volume yield in the two groups. Together, the data are compatible with a higher bone-forming activity coupled with reduced osteoclastogenic activity and decreased bone resorption, and they may explain why similar percentages of total BV are generated by biomaterial grafts, despite higher percentages of nonvital bone (containing osteocytic lacunae) and lower VB. The simultaneous evaluation of osteoblast-specific factors involved in matrix deposition, together with the ratio between the crucial osteoblast related pro- and anti osteoclastogenic factors RANKL and osteoprotegerin, could enable a determination not only of the activity of osteoblasts as matrix secretors, but also the cross-talk between osteoblastic cells with nascent and active osteoclasts. The present study strongly suggests that analysis of the gene expression profiles of primary osteoblasts would be useful to determine whether a given biomaterial possesses not only direct osteoconductive but also indirect osteoinductive effects.

The histologic findings reported in the present study and gene expression values explained previ-

ously may help clarify the results of a clinical study that evaluated radiographic parameters of implants positioned in grafted alveoli with three different biomaterials: mHA, calcium sulfate, and heterologous porcine bone.<sup>22</sup> The aim of the study was to evaluate the clinical outcome of implants placed in previously grafted alveoli and expanded at stage-two surgery by the osteotome technique.<sup>23</sup> The study showed that after 2 and 3 years, the success of implants placed in grafted sockets was not influenced by the biomaterial used, since no negative impacts were seen on the clinical outcome.

Human studies<sup>24-26</sup> have reported encouraging histomorphometric data about porous HA as a sinus grafting material, as revealed by light microscopy and transmission electron microscopy. In most cases, the biomaterial particles remained in close contact with bone, which appeared compact, with well-organized lamellae. A cementlike line was barely visible at the bone-biomaterial interface, but there were no gaps or interposed connective tissue in between. Histology and histomorphometry showed that the incompletely resorbed HA graft was well integrated into the biopsy specimens and in complete continuity with the newly formed bone.

Arisan et al<sup>27</sup> applied an injectable calcium phosphate cement to standardized buccal dehiscence peri implant defects after implant site preparation in the right proximal tibiae of five beagle dogs. Healing was uneventful in all dogs. The injectable calcium phosphate putty showed good space maintenance and osteoconductive properties and did not provoke any foreign-body reactions. BIC was 34.42% ( $\pm 19.88\%$ ) and 37.00% ( $\pm 21.33\%$ ) ( $P = .375$ ), while LBH was 84.23% ( $\pm 19.73\%$ ) and 96.10% ( $\pm 6.66\%$ ) ( $P = .125$ ) for test and control sites, respectively. In another study,<sup>28</sup> the healing of different bone grafting materials adjacent to titanium plasma-sprayed endosseous dental implants was investigated. The results indicated that percent BIC and percent bone height fill in intrabony defects around titanium plasma-sprayed implants were statistically significantly higher with the use of demineralized freeze-dried bone allograft in comparison to control defects that were left unfilled.

## CONCLUSIONS

Within the limits of the present animal study, injectable mHA putty could be considered a useful and suitable bone grafting material for peri-implant defects. Further studies are needed to evaluate this biomaterial in humans.



## ACKNOWLEDGMENTS

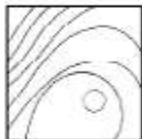The authors are grateful to Dr Elisabetta Mariani and BoNetwork (San Raffaele Scientific Institute, Milan, Italy) for preparation of the histologic samples.

## REFERENCES

- Mellonig JT, Nevins M. Guided bone regeneration of bone defects associated with implants: An evidence based outcome assessment. *Int J Periodontics Restorative Dent* 1995;15:168-185.
- Ilammerle CI, Karing T. Guided bone regeneration at oral implant sites. *Periodontol 2000* 1998;17:151-175.
- Jolman U, Keller E. Endosseous implant placement immediately following dental extraction and alveoloplasty: Preliminary report with 6-year follow-up. *Int J Oral Maxillofac Implants* 1991;6:24-28.
- Wilson TG, Schank R, Buser D, Cochran D. Implants placed in immediate extraction sites: A report of histologic and histometric analyses of human biopsies. *Int J Oral Maxillofac Implants* 1998;13:333-341.
- Cornelini H, Langini F, Lovani U, Wilson I. Immediate restoration of implants placed into fresh extraction sockets for single-tooth replacement: A prospective clinical study. *Int J Periodontics Restorative Dent* 2005;25:439-447.
- Barone A, Rispoli L, Vozza I, Quaranta A, Covani U. Immediate restoration of single implants placed immediately after tooth extraction. *J Periodontol* 2006;77:1914-1920.
- Crespi R, Cappare P, Gherlone E, Romanos GE. Immediate occlusal loading of implants placed in fresh sockets after tooth extraction. *Int J Oral Maxillofac Implants* 2007;22:955-962.
- Becker W, Dahlin C, Becker B, et al. The use of a PTFE barrier membranes for bone promotion around titanium implants placed into extraction sockets: A prospective multicenter study. *Int J Oral Maxillofac Implants* 1994;9:31-40.
- Chiapasco M, Zaniboni M, Boisco M. A prospective clinical study of bone augmentation techniques at immediate implants. *Clin Oral Implants Res* 2005;2:176-184.
- Artzi Z, Tal H, Dohan D. Porous bovine bone mineral in healing of human extraction sockets. Part I. Histomorphometric evaluation at 9 months. *J Periodontol* 2000;71:1015-1023.
- Ripamonti U. The morphogenesis of bone in replicas of porous HA obtained from conversion of calcium carbonate exoskeletons of coral. *J Bone Joint Surg* 1991;73A:692-703.
- Yuan H, Li Y, Yang Z, Feng J, Zhang XD. An investigation on the osteoinduction of synthetic porous phase pure HA ceramics. *Biomed Eng Appl Basis Com* 1997;9:274-278.
- Okumura M, Ohgushi H, Dohi Y, et al. Osteoblastic phenotype expression on the surface of HA ceramics. *J Biomed Mater Res* 1997;37:122-129.
- Norman MT, Eigendy HM, Shors EC, el-Amin ST, Laurencin CI. An in vitro evaluation of coralline porous HA as a scaffold for osteoblast growth. *Clin Mater* 1994;17:85-91.
- Ooms EM, Wolke JC, van der Waerden JP, Jansen JA. Trabecular bone response to injectable calcium phosphate (Ca-P) cement. *J Biomed Mater Res* 2002;1:9-18.
- Fellah BH, Weiss P, Gauthier O. Bone repair using a new injectable self-crosslinkable bone substitute. *J Orthop Res* 2006;4:628-635.
- Sanchez AR, Sheridan PJ, Eckert SE, Weaver AL. Regenerative potential of platelet-rich plasma added to xenogenic bone grafts in peri-implant defects: A histomorphometric analysis in dogs. *J Periodontol* 2005;76:1637-1644.
- Mosekilde L, Kragstrup J, Richards A. Compressive strength, ash weight, and volume of vertebral trabecular bone in experimental fluorosis in pigs. *Calcif Tissue Int* 1987;40:318-322.
- Mosekilde L, Weisbrode SE, Safron JA, et al. Calcium-restricted ovariectomized Sinclair S-1 minipigs: An animal model of osteopenia and trabecular plate perforation. *Bone* 1993;14:379-382.
- Kragstrup J, Richards A, Fejerskov O. Effect of fluoride on cortical bone remodeling in the growing domestic pig. *Bone* 1989;10:421-424.
- Crespi R, Mariani E, Benasciutti E, Cappare P, Cenci S, Gherlone E. Magnesium-enriched hydroxyapatite versus autologous bone in maxillary sinus grafting: Combining histomorphometry with osteoblast gene expression profiles in vivo. *J Periodontol* 2009;80:586-598.
- Crespi R, Cappare P, Gherlone E. Dental implants placed in extraction sites grafted with different bone substitutes: Radiographic evaluation at 24 months. *J Periodontol* 2009;80:1616-1621.
- Crespi R, Cappare P, Gherlone E. Osteotome sinus floor elevation and simultaneous implant placement in grafted biomaterial sockets: 3 years follow-up. *J Periodontol* 2010;81:144-149.
- Mangano C, Scarano A, Iezzi G, et al. Maxillary sinus augmentation using an engineered porous hydroxyapatite. A clinical, histological, and transmission electron microscopy study in man. *J Oral Implants* 2006; 32:122-131.
- Smeets R, Grosjean MB, Jelitte G, et al. Hydroxyapatite bone substitute (Ostim) in sinus floor elevation. Maxillary sinus floor augmentation: Bone regeneration by means of a nanocrystalline in-phase hydroxyapatite (Ostim) [in French, German]. *Schweiz Monatsschr Zahnmed* 2008;118:203-212.
- Lee YM, Shin SY, Kim JY, Kye SB, Ku Y, Rhyu IC. Bone reaction to bovine hydroxyapatite for maxillary sinus floor augmentation: Histologic results in humans. *Int J Periodontics Restorative Dent* 2006;26:471-481.
- Arisan V, Ozdemir T, Anil A, Jansen JA, Özer K. Injectable calcium phosphate cement as a bone-graft material around peri-implant dehiscence defects: A dog study. *Int J Oral Maxillofac Implants* 2008;23:1053-1062.
- Hall E, Mettert HM, Hermann JS, Mellonig JJ, Cochran UL. Comparison of bioactive glass to demineralized freeze-dried bone allograft in the treatment of intrabony defects around implants in the canine mandible. *J Periodontol* 1999;70:526-535.

e182

## Use of Piezosurgery During Maxillary Sinus Elevation: Clinical Results of 40 Consecutive Cases



Michele Cassetta, DDS, PhD<sup>1</sup>/Laura Ricci, DDS<sup>2</sup>  
Giovanna Iezzi, DDS, PhD<sup>3</sup>/Sabrina Calasso, DDS<sup>4</sup>  
Adriano Piattelli, MD, DDS<sup>5</sup>/Vittoria Porrotti, DDS, PhD<sup>2</sup>

*The aim of this study was to evaluate the performance of piezoelectric devices during sinus elevation to determine the percentage of sinus membrane perforation and the time required to perform the antrostomy and elevation of the membrane. A total of 35 patients and 40 grafted sinuses were included. The parameters recorded were bony window length and height, bone thickness, osteotomy area, operative time, and number of perforations. Seven (17.5%) membrane perforations were observed, which were repaired with resorbable membranes. The mean length, height, and thickness of the osteotomy were  $13.8 \pm 2.9$  mm,  $6.9 \pm 1.4$  mm, and  $1.4 \pm 0.4$  mm, respectively. The mean osteotomy area was  $96.8 \pm 32.2$  mm<sup>2</sup>, and the mean operative time was  $10.3 \pm 2.1$  minutes. This study demonstrated that a piezoelectric device could be an attractive alternative for successful sinus augmentation. (Int J Periodontics Restorative Dent 2012;32:e182–e188.)*

<sup>1</sup>Assistant Professor, Department of Oral and Maxillofacial Sciences, School of Dentistry, "Sapienza" University of Rome, Rome, Italy.

<sup>2</sup>Research Fellow, Dental School, University of Chieti-Pescara, Chieti, Italy.

<sup>3</sup>Researcher, Dental School, University of Chieti-Pescara, Chieti, Italy.

<sup>4</sup>Research Fellow, School of Dentistry, "Sapienza" University of Rome, Rome, Italy.

<sup>5</sup>Professor of Oral Pathology and Medicine, Dental School, University of Chieti-Pescara, Chieti, Italy.

Correspondence to: Prof Adriano Piattelli, Via F. Sciucchi 63, 66100 Chieti, Italy;  
fax: +39 0871 3554076; email: apiattelli@unich.it.

Maxillary sinus elevation, first used by Boyne and James<sup>1</sup> in 1980, has become a predictable surgical procedure to achieve an effective and sustainable vertical augmentation of the severely atrophic posterior maxilla using a multitude of grafting materials.<sup>2,3</sup> The sinus elevation procedure is usually performed with different forms of rotary surgical instrumentation, such as an air-driven or electric handpiece with diamond or carbide burs.<sup>4</sup> During sinus elevation, the most frequent intraoperative complication, occurring in 7% to 35% of procedures,<sup>5</sup> is the accidental perforation of the sinus membrane either with burs during the osteotomy or with manual elevators during separation of the membrane.<sup>6</sup> A review of the literature showed that the perforation rate in lateral window sinus elevation surgery ranged from 14% to 56%.<sup>7</sup>

Preservation of the sinus membrane is essential for a successful sinus grafting procedure.<sup>8</sup> In particular, its integrity is crucial to stabilize grafting materials during the healing period and to allow revascularization, which in turn will lead



to the maturation and mineralization of the bone tissue.<sup>9</sup> Perforation occurs most frequently during the rotary osteotomy stage when using a round diamond handpiece.<sup>10</sup> Piezoelectric techniques were developed in response to the need for greater precision and safety in bone surgery than was available with other manual and motorized instruments.<sup>6</sup> A histologic study showed that Piezosurgery provides more favorable osseous repair and remodeling than carbide or diamond burs when surgical osteotomy and osteoplasty procedures are performed.<sup>11</sup> The piezoelectric bony osteotomy through the mineralized tissue occurs without damaging the membrane and allows easy separation.<sup>6</sup> At present, the use of piezoelectric instruments for sinus elevation seem to have several advantages: reduction of the membrane perforation rate, intraoperative bleeding, and surgical trauma and improved intraoperative visibility.<sup>4</sup>

Vercellotti et al<sup>9</sup> found no membrane perforations in 95% of 21 osteotomies performed in 15 patients using a piezoelectric device. In a recent clinical study of 26 maxillary sinus elevations, 4 perforations were observed, representing 15.3% of procedures.<sup>12</sup> Moreover, this alternative approach reduces not only the complications of the surgical technique but also the operating time and therefore the morbidity of the patient.<sup>9</sup> However, the time factor seems to depend on the bone structure and thickness, and the duration of the osteotomy procedure can be increased by up

to fivefold when compared with conventional osteotomy devices.<sup>13</sup>

The aim of this clinical series was to evaluate the performance of a piezoelectric device during maxillary sinus floor elevation to determine the percentage of sinus membrane perforations and the time required to perform the antrostomy and elevation of the membrane.

### Method and materials

Thirty-five consecutive patients (17 women, 18 men) with a mean age of 53.6 years (range, 42 to 67 years) were selected at the Department of Oral Science of "Sapienza" University, Rome, Italy, between June 2005 and January 2007. A total of 40 sinus elevation procedures (5 bilateral, 30 unilateral) were performed by means of a Piezosurgery device.

All patients were systemically healthy and completely edentulous in the posterior maxilla with a residual bone crest of approximately 4 mm.<sup>9</sup> Maxillary bone atrophy was scored (Class V) on the basis of the Cawood and Howell classification<sup>14</sup> and assessed by either preoperative orthopantomography (OPT) or computed tomography (CT).

The following exclusion criteria were used to select the patient population: history of systemic disorders that would contraindicate surgical treatment; history of maxillary sinus, nose, or throat pathologies; and smoking more than 10 cigarettes per day. With respect to tobacco use, 28 patients were non-smokers and 7 smoked 1 to 10 cig-

arettes per day. Patients completed a presurgical questionnaire aimed at screening their medical, dental, and habitual histories and underwent blood tests. Before treatment, radiographic examinations, such as OPT and CT scans, were used to assess the anatomical conditions, position, and dimension of the bony window (Fig 1). In addition, the CT examination determined the mean thickness of the sinus lateral wall, and it was ascertained that there was no sinus pathology.

All patients were informed of the therapeutic alternatives to sinus elevation and of the possible complications of such an intervention. Informed written consent was obtained from the patients, and approval of the surgical procedure was granted by the Ethics Committee of the "Sapienza" University of Rome.

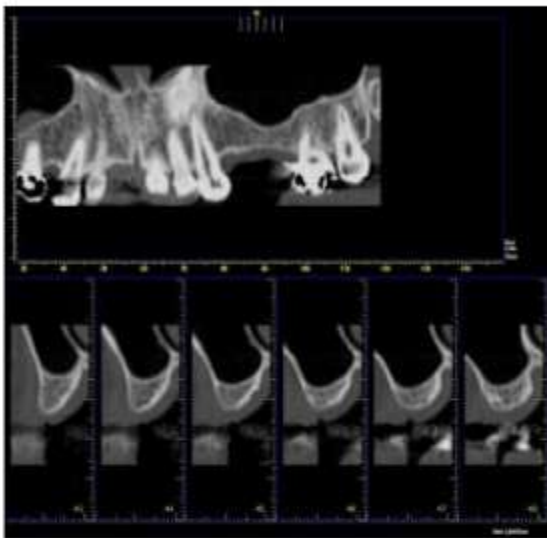
Either autologous bone or a mixture of 50% autologous bone and 50% deantigenated collagenated bone substitute of porcine origin (OsteoBiol, Gen-Os) was used as a filling material. The autologous bone was collected from the retromolar trigone.

### Surgical procedure

Antibiotic therapy (1 g of amoxicillin) was prescribed 1 hour before intervention and twice a day for 5 days. Patients were asked to rinse with a 0.2% chlorhexidine digluconate solution for 2 minutes before surgery, and postoperative medication included analgesics and 0.12% chlorhexidine digluconate



e184



**Fig 1** Presurgical CT scan used to determine the correct position of the bony window and to measure the thickness of the lateral sinus walls. The bone height was 4 mm. No sinus pathology was present.

mouthrinse for 10 days. All procedures were completed by the same surgeon. Patients were treated with a local anesthetic by infiltration with Articaine (Ubistesin 4%, ESPE Dental) associated with epinephrine 1:100,000.

A horizontal crestal incision was made with two additional vertical releasing incisions, and a full-thickness mucoperiosteal flap was lifted to expose the complete lateral wall of the maxilla. The osteotomy for sinus access was performed using a Piezosurgery device (Easy Surgery, BioSAFIN), and the following surgical procedure was carried out. A window osteotomy was performed on the lateral wall of the maxillary sinus using a BioS 520 ES diamond insert to draw an outline. The posterior margin of the osteotomy was placed 3 to 4 mm above

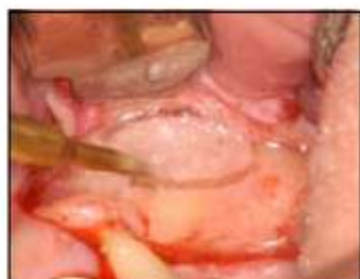the sinus (Fig 2a). The osteotomy was completed by rounding the angles of the bony window. Separation of the sinus membrane was performed using a BioS 540 ES surgery tip, which was inserted up to 2 mm into the edge of the exposed sinus membrane (Fig 2b). Membrane elevation was completed using manual sinus elevators or a BioS 532 ES surgery tip as with manual procedures, and the sinus mucosa was carefully dissected.

The space obtained with the sinus elevation was filled with graft material (autologous bone or a mixture of 50% autologous bone and 50% deantigenated collagenated bone substitute of porcine origin) (Fig 2c). The total amount of graft material at each site varied according to the extent of maxillary bone resorption and the sinus anatomy.

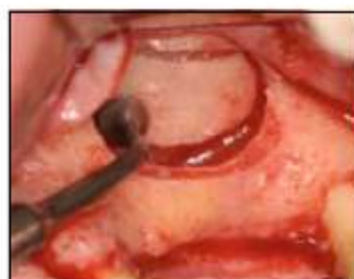During the sinus elevation procedure, seven perforations occurred, and in those cases, the bony sinus windows were covered with a resorbable membrane (OsteoBio) (Fig 2d).

Periosteal horizontal incisions were made to extend the flap as far coronally as needed over the bony window, and the mucoperiosteal flaps were sutured using tension-free single sutures (GORE-TEX, W.L. Gore), which were removed 10 days after surgery. Patients were restricted to a soft diet for 4 weeks, and oral hygiene instructions were provided. During the postoperative healing period, the occurrence of clinical complications such as acute or chronic sinus infection or bleeding was recorded.

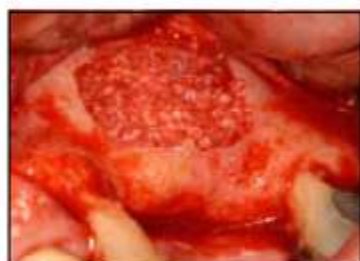Radiographic examinations (OPT and CT scan) were performed after



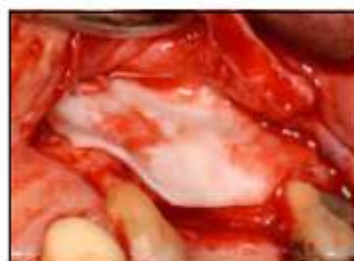**Fig 2a (left)** Osteotomy to access the maxillary sinus was performed using a BioS 520 L5 diamond insert.



**Fig 2b (right)** Sinus membrane elevation and separation was performed using a BioS 540 surgery tip.

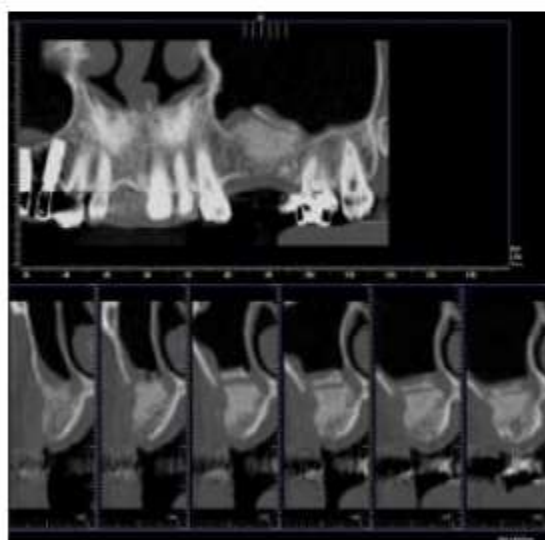


**Fig 2c (left)** Sinus filled with graft material.



**Fig 2d (right)** Bony sinus window covered with a resorbable membrane.

**Fig 3** After 2 months, an adequate amount of radiopaque material was present, and no signs of maxillary sinus infection could be observed.



a period of 2 months to evaluate the outcome of the surgical procedure (Fig 3). The parameters recorded were bony window length

and height, bone thickness, and osteotomy area—the latter calculated by multiplying bony window length by height.<sup>13</sup>

Moreover, the time necessary for the osteotomy and sinus elevation as well as the number of surgical complications were calculated.



e186

The mean values and standard deviations were determined for each parameter in all cases.

## Results

A total of 40 consecutive sinus elevation procedures (30 unilateral, 5 bilateral) were performed with a Piezosurgery system in 35 patients who required sinus floor elevation for implant-prosthetic rehabilitation.

Postoperative healing was uneventful and free of complications. In all patients, except for inflammation and swelling of the surgical site. Only one patient showed dehiscence of the covering soft tissues, but no clinical inflammatory signs or infections were observed. This patient was instructed to apply a 1% chlorhexidine gel twice a day. After 2 months, at radiographic analysis, an adequate amount of radiopaque material with greater density than the bone was present, and no signs of maxillary sinus infection were observed (Fig 3).

Seven perforations of the sinus membrane (17.5%) were observed, all of which were less than 3 mm. Six perforations occurred during the antrostomy, and one perforation during initial membrane elevation was related to the presence of a septum and an extremely thin membrane. The perforations were repaired using a collagen membrane in direct contact with the sinus membrane.

The maxillary sinuses showed a mean bone thickness at the window of  $1.4 \pm 0.4$  mm. The mean

length of the osteotomy was  $13.8 \pm 2.9$  mm, and its height was  $6.9 \pm 1.4$  mm. The mean osteotomy area was  $96.8 \pm 32.2$  mm<sup>2</sup>. The mean time necessary for the osteotomy procedures and sinus membrane elevation with the piezoelectric device was  $10.3 \pm 2.1$  minutes. The values for operating time were compared with the osteotomy area, and it was determined that the larger the bony window area, the greater the time required to perform the augmentation procedures.

## Discussion

The Piezosurgery system uses ultrasonic vibration to work only on mineralized hard tissue, not on soft tissue, and therefore does not cause any nerve damage. During osteotomy in sinus bone grafting, the use of ultrasonic techniques has advantages over other conventional instruments, including a highly precise cut geometry without the need for excessive force and efficient bone ablation, minimizing the risk of accidental damage to the sinus membrane.<sup>11,15</sup>

In this study, sinus membrane perforation occurred in 7 of 40 cases, representing 17.5% of procedures. These results are similar to those reported by several authors<sup>4,9,12,16</sup> who also found very low perforation percentages using piezoelectric devices. Vercellotti et al<sup>9</sup> noted perforation in only 5% of 21 maxillary sinus elevations. Moreover, a few studies<sup>4,13</sup> analyzed the membrane perforation rate by

comparing piezoelectric devices and conventional instruments. In a series of 100 consecutive cases, Wallace et al<sup>4</sup> found that the membrane perforation rate had been reduced from the mean reported rate of 30% with rotary instrumentation to 7% using the piezoelectric technique. Additionally, all perforations with the piezoelectric technique occurred during the hand instrumentation phase. These results were not in agreement with the data reported in a recent comparative study by Barone et al<sup>13</sup> in which membrane perforation occurred in 30% of sites in the test group (piezoelectric device) and 23% of sites in the control group (conventional instruments), with no statistically significant differences between the two groups.

Despite the ability of the piezoelectric technique to selectively cut the different tissues, the sinus membrane may be perforated or injured by excessive mechanical force from the instrument tip.<sup>16</sup> In this study, six perforations occurred during osteotomy using a BioS 520 ES diamond insert and one perforation occurred during initial membrane elevation, but the latter was associated with the presence of a septum and an extremely thin membrane. The initial release of the membrane from the bony window is the most difficult part of sinus elevation surgery.<sup>9</sup> In this study, only one perforation occurred at this moment. This is probably a result of the use of a noncutting BioS 540 ES surgery tip. Such an insert was specifically designed to safely work on the in-



teral part of the sinus bone wall and to easily achieve a small internal elevation through piezoelectric cavitation.

The dimensions of the sinus membrane perforations in this study were less than 3 mm; therefore, perforations were patched with a resorbable membrane in direct contact with the sinus membrane. In most instances, the repair of this perforation is necessary to contain particulate grafting material and to finalize the procedure.<sup>7</sup> Several studies showed successful sealing of sinus membrane perforations using fibrin glue and resorbable collagen membrane.<sup>17-19</sup> However, the repair increased the cost of the procedure and the time necessary to complete the surgery; therefore, this resulted in a higher sinus graft infection rate and increased patient morbidity.<sup>4</sup>

The most clear disadvantage in clinical routine use of piezosurgery is the longer time required for the osteotomy.<sup>13,20</sup> Barone et al<sup>13</sup> showed that the time necessary for the osteotomy and sinus membrane elevation with conventional instruments was  $10.2 \pm 2.4$  minutes, while it was  $11.5 \pm 3.8$  minutes with the piezoelectric device, with no statistically significant differences. These findings were in agreement with the data recorded in this study, where the mean operating time with the piezoelectric device was  $10.3 \pm 2.1$  minutes. In this investigation, the time necessary for the osteotomy procedures and the sinus membrane elevation was also compared with the osteotomy area.

It has been found that the larger the area of the bony window, the greater the time required for the augmentation procedure. According to other studies,<sup>13,21</sup> the bone structure and thickness affected the time required for surgery. Moreover, this study revealed that the location and size of the sinus septa encountered in sinus elevation procedures also increased the surgical period. Radiographic examinations (OPT and CT) are essential to predict sinus volume and degree of septation and to evaluate the thickness of the sinus lateral wall to avoid an increase in operative time. Interestingly, in all cases evaluated in this analysis, the presence of perforations lengthened the surgical time. Further clinical studies are needed to confirm these results and to better understand the relationship between the possible factors affecting operating time and the rate of complications.

Based on the results of this study, sinus augmentation can be successfully performed by means of a piezoelectric device, which was demonstrated to be an attractive alternative to simplify sinus elevation procedures and offer promising results in terms of complications such as sinus membrane perforations.

### Acknowledgment

This work was partially supported by the Ministry of Education, University, and Research (M.I.U.R.), Rome, Italy.

### References

1. Boyne PJ, James RA. Grafting of the maxillary sinus floor with autogenous marrow and bone. *J Oral Surg* 1980;38:613-616.
2. Mandelaris GA, Rosenfeld AL. A novel approach to the antral sinus bone graft technique: The use of a prototype cutting guide for precise outlining of the lateral wall. A case report. *Int J Periodontics Restorative Dent* 2008;28:569-575 [erratum 2009;29:105].
3. Stübinger S, Saldamli B, Seitz O, Sader R, Landes CA. Palatal versus vestibular piezoelectric window osteotomy for maxillary sinus elevation: A comparative clinical study of two surgical techniques. *Oral Surg Oral Med Oral Pathol Oral Radiol Endod* 2009;107:648-655.
4. Wallace SS, Mazor Z, From SJ, Cho SC, Tamow DP. Schneiderian membrane perforation rate during sinus elevation using piezosurgery: Clinical results of 100 consecutive cases. *Int J Periodontics Restorative Dent* 2007;27:413-419.
5. Schwartz-Arad D, Harshbarg R, Dolev F. The prevalence of surgical complications of the sinus graft procedure and their impact on implant survival. *J Periodontol* 2004;75:511-516.
6. Labanca M, Azzola F, Vinci R, Rodella LG. Piezoelectric surgery: Twenty years of use. *Br J Oral Maxillofac Surg* 2008;46:265-269.
7. Testori T, Wallace SS, Del Fabbro M, et al. Repair of large sinus membrane perforations using stabilized collagen barrier membranes: Surgical techniques with histologic and radiographic evidence of success. *Int J Periodontics Restorative Dent* 2008;28:9-17.
8. van den Bergh JP, ten Bruggenkate CM, Disch FJ, Tuinzing DB. Anatomical aspects of sinus floor elevations. *Clin Oral Implants Res* 2000;11:256-265.
9. Vercellotti T, De Paoli S, Nevins M. The piezoelectric burr window osteotomy and sinus membrane elevation: Introduction of a new technique for simplification of the sinus augmentation procedure. *Int J Periodontics Restorative Dent* 2001;21:561-567.
10. Torrella F, Pitarich J, Cabanes G, Anitua E. Ultrasonic osteotomy for the surgical approach of the maxillary sinus: A technical note. *Int J Oral Maxillofac Implants* 1998;13:697-700.

e188

11. Vercellotti T, Nevins ML, Kim DM, et al. Osseous response following resective therapy with Piezosurgery. *Int J Periodontics Restorative Dent* 2005;25:543–549.
12. Sánchez-Rocio C, Peñarocha-Diago M, Peñarocha-Diago M, Peñarocha-Oltra U. Maxillary sinus lift performed using ultrasound. Evaluation of 21 patients. *Med Oral Patol Oral Cir Bucal* 2010;15: e371–e374.
13. Barone A, Santini S, Marconcini S, Giacomelli L, Gherlone E, Covani U. Osteotomy and membrane elevation during the maxillary sinus augmentation procedure. A comparative study: Piezoelectric device vs. conventional rotative instruments. *Clin Oral Implants Res* 2008;19:511–515.
14. Cawood JI, Howell RA. Reconstructive pre-prosthetic surgery. I. Anatomical considerations. *Int J Oral Maxillofac Surg* 1991; 20:75–82.
15. Muñoz-Guerra MF, Naval-Gias L, Capote-Moreno A. Le fort I osteotomy, bilateral sinus lift, and inlay bone-grafting for reconstruction in the severely atrophic maxilla: A new vision of the sandwich technique, using bone scrapers and piezosurgery. *J Oral Maxillofac Surg* 2009; 67:613–618.
16. Stübinger S, Kittenberger J, Filippi A, Sader R, Zeilhofer HF. Intraoral piezosurgery: Preliminary results of a new technique. *J Oral Maxillofac Surg* 2005;63: 1283–1287.
17. Shin HI, Sohn DS. A method of sealing perforated sinus membrane and histologic finding of bone substitutes: A case report. *Implant Dent* 2005;14:328–333.
18. Proussaefs P, Lozada J, Kim J, Rohrer MD. Repair of the perforated sinus membrane with a resorbable collagen membrane: A human study. *Int J Oral Maxillofac Implants* 2004;19:413–420.
19. Fuqazzotto PA, Vlassis J. A simplified classification and repair system for sinus membrane perforations. *J Periodontol* 2003; 74:1534–1541.
20. Maurer P, Kriwalsky MS, Block Veras R, Vogel J, Syrowatka F, Heiss C. Micro-morphometrical analysis of conventional osteotomy techniques and ultrasonic osteotomy at the rabbit skull. *Clin Oral Implants Res* 2008;19:570–575.
21. Hoigne DJ, Stübinger S, Von Kaenel O, Shamdasani S, Hasenboehler P. Piezoelectric osteotomy in hand surgery: First experience with a new technique. *BMC Musculoskelet Disord* 2006;7:36.



## EFFECTS OF MECHANICAL VERSUS MANUAL NON SURGICAL PERIODONTAL THERAPY ON PATIENT COMFORT AND PERIODONTAL HEALING: A RANDOMIZED CONTROLLED CLINICAL TRIAL

A. QUARANTA<sup>1</sup>, G. RAPPELLI<sup>2</sup>, E. SANTARELLI<sup>3</sup>, M. BOSSÙ<sup>4</sup>  
and M. PIEMONTESE<sup>1</sup>

<sup>1</sup> Division of Periodontology, School of Dentistry and Post Graduate Master in Periodontics, Università Politecnica delle Marche. <sup>2</sup> Division of Prosthodontics, School of Dentistry, Università Politecnica delle Marche, Ancona, Italy. <sup>3</sup> Private Practice, Rome, Italy. <sup>4</sup> Division of Pediatric Dentistry, School of Dentistry, "Sapienza" University of Rome

Received February 9, 2012 – Accepted July 27, 2012

Few studies have focused on the problem of pain and discomfort experienced during and after periodontal debridement. The aim of this study was to evaluate the effect of manual versus hand driven non surgical periodontal instrumentation on the patient's comfort, perception of pain and dental hypersensitivity during and after the instrumentation. Moreover, the influence of the treatment modality on the healing of slight to moderate periodontitis was assessed with careful attention to indices of periodontal inflammation. 22 subjects with a minimum of  $\geq 6$  mm periodontal pockets with 3 to 4 mm attachment loss in different quadrants, the presence of  $\geq 20$  teeth with a minimum of four molars were enrolled. PD (probing depth, 6 sites per tooth), number of sites with PD  $> 6$  mm, buccal and lingual recessions were collected. Two quadrants Mouth Bleeding and Plaque Scores (T.M.P.S, T.M.B.S.) were assessed as the presence or absence of bleeding on probing and plaque following disclosing in quadrants 1-4 and 2-3. Non surgical periodontal treatment was delivered in two appointments performed within one week. In the first appointment the first and the fourth quadrants (patient's right side) were completely treated by mechanical or manual devices according to the randomization codes. In the second appointment the remaining two quadrants (patient's left side) were instrumented with the other therapeutical approach. The duration of each session, need for local anesthesia and additional information were recorded during the instrumentation appointments. All the patients were requested to fill in a form regarding pain, hypersensitivity, and need for painkillers following the two debridement appointments. Two drop outs were observed. Mean pain scores after treatment were higher in manual than in machine driven side ( $3.11 \pm 1.40$  vs  $2.33 \pm 1.41$ ), whereas mean dentine hypersensitivity scores were slightly higher in mechanical side ( $4.40 \pm 1.56$  vs  $3.77 \pm 1.11$ ). The need for painkillers after both treatment approaches was minimal. 6 out of 20 patients asked for local anesthesia and clustering regarding the request for both treated sides was observed. The mean instrumentation time was significantly lower for mechanical versus manual instrumentation ( $84.57 \pm 12.92$  vs  $119.25 \pm 13.50$ ,  $p < 0.001$ ). Periodontal healing was similar in both the hand and machine driven instrumented sides. TMPS and TMBS were significantly lower at baseline compared to re-evaluation visits and the within group changes were significant lower at re-evaluation. Most of patients well tolerated non surgical periodontal treatment despite the type of instruments that are chosen by the clinician. Pain is infrequently reported and is more common after manual instrumentation compared to machine driven one. The need for local anesthesia is quite uncommon and is surely subject-dependent. Temporary, slight dentine hypersensitivity is a common adverse effect reported by most of patients after subgingival debridement. Machine driven debridement shows a dramatic advantage compared to manual treatment due to the lower amount of time needed to complete the instrumentation.

*Key-words:* Dental scaling; root planing; periodontal diseases; dentine hypersensitivity; pain

*Mailing Address:* Alessandro Quaranta, DDS, PhD.  
Division of Periodontology, School of Dentistry  
and Post Graduate Master in Periodontics  
Università Politecnica delle Marche,  
Polo Murri, Room #47. Via Tronto 10, 60020,  
Torrette di Ancona, Ancona, Italy  
Mobile Phone: +393381770918  
email address: s40ale@gmail.com  
alessandro.quaranta@univpm.it

1721-727X (2012)

Copyright © by BIOLIFE, s.a.s.

This publication and/or article is for individual use only and may not be further reproduced without written permission from the copyright holder.

Unauthorized reproduction may result in financial and other penalties  
DISCLOSURE: ALL AUTHORS REPORT NO CONFLICTS OF  
INTEREST RELEVANT TO THIS ARTICLE.

Inflammatory and immune reactions to microbial plaque are the predominant features of periodontal diseases. Inflammatory and immune processes operate in the gingival tissues to protect against local microbial attack and prevent bacteria and their damaging products from spreading into or invading the tissues. These host defense reactions are, however, also considered potentially harmful to the host in that inflammation can damage surrounding cells and connective tissue structures (1). The goal of periodontal treatment is the restoration of the attachment apparatus lost due to disease onset and progression (2). The process of the disease is arrested by non surgical periodontal treatment and proper oral hygiene procedures. Non surgical periodontal treatment aims to eliminate subgingival biofilm and calculus from the root surface and periodontal pockets. Although a complete elimination of pathogenic bacteria is very difficult, a reduction in total bacterial load leads to a reduction in the severity of gingival inflammation, determining beneficial clinical changes. The elimination of subgingival biofilm can be reached by manual and mechanical (hand driven) devices. No difference in the quality of root debridement with manual and hand driven instruments was observed (3) and recent reviews confirmed that both instrumentation approaches led to similar clinically significant improvements in clinical periodontal parameters (3-5). Few researchers have addressed the problem of pain and discomfort during and after periodontal debridement (6-9). Tissue trauma may occur during non surgical periodontal therapy (10). This trauma triggers local mechanoreceptors and nociceptors, the activation of which leads to the release of chemicals, such as prostaglandins, bradykinin, and histamine, and ultimately to the perception of pain in the central nervous system (11). Quantifying pain is difficult as it cannot be measured directly. Philstrom et al. (9) observed that patients' pain following periodontal instrumentation may be of significant duration and magnitude. Furthermore, patients may experience dentine hypersensitivity after the treatment of periodontal disease. These two side effects are of great concern and play a key role in determining impairment of the patient's quality of life. Moreover, patients' discomfort may highly reduce the individual's compliance during the periodontal therapy. The aim of the present study was to investigate the effect of manual versus hand driven non surgical periodontal instrumentation on patient's comfort, as evaluated on a VAS (Visual Analogue Score), perception of pain (need of local anesthesia during the treatment, need for painkillers after the treatment) and dental hypersensitivity during and after the instrumentation. Finally, the influence of the treatment modality on the healing of slight to moderate periodontitis was assessed with careful attention to indices of periodontal inflammation.

## MATERIALS AND METHODS

### *Patient selection*

A split mouth single-masked randomized clinical trial was designed. 22 patients were enrolled between September 2009 and January 2010 from those referred for periodontal treatment to the School of Dental Hygiene C, Polo Pontino, "Sapienza" University of Rome. Subjects were invited to participate if they were diagnosed with slight to moderate periodontitis. Inclusion criteria consisted of a minimum of 4  $\geq$  6mm periodontal pockets with 3 to 4mm attachment loss in different quadrants, the presence of  $\geq$ 20 teeth with a minimum of four molars. Exclusion criteria were periodontal treatment within the last 6 months, acute dental and periodontal lesions (endodontic lesions, gingival and periodontal abscesses, peri-coronitis), uncontrolled diabetes, drug use or alcohol abuse. Additional exclusion criteria were: required antibiotic medication prior to treatment, long term anti-inflammatory or other painkiller medication (more than 10 days in the previous 2 months). 22 patients were considered eligible and recruited for the study. All the patients were informed about treatment modality, the purpose of the study and signed a written comprehensive consent form. Outcomes were evaluated over a 2 month period.

### *Experimental Parameters*

Calibration of clinical periodontal parameters used in the present study was carried out on 15 subjects not included in the experimental trial. Intraexaminer repeatability was evaluated. Assessing agreement was based on Cohen's Kappa test (9) and the measurements were judged to be reproducible when there was an agreement with  $k$  values of 0.80. During the comprehensive baseline periodontal examination, performed at baseline and 8 weeks after non surgical periodontal treatment, the following periodontal parameters were recorded using a University of North Carolina 15 periodontal probe with a force of 0.4 N applied by the calibrated examiner (M.P.) rounding up to the nearest millimeter:

- PD (probing depth, 6 sites per tooth) measured from the gingival margin until the bottom of the pocket as clinically assessed
- Buccal and lingual recessions assessed as the distance from the cement-enamel junction to the migrated gingival margin
- Number of sites with PD > 6mm
- T.M.B.S. (Two quadrants Mouth Bleeding Scores) recorded as the presence or absence of bleeding following measurement of PD in quadrants 1-4 and 2-3 modified from the original Full Mouth Bleeding Score (13)
- T.M.P.S. (Two quadrants Mouth Plaque Scores) recorded as the presence or absence of plaque following disclosing in quadrants 1-4 and 2-3 modified from the original Full Mouth Plaque Score (14). Dentine hypersensitivity was not evaluated at baseline. Two computer-generated restricted randomization lists were made. The randomization codes (1 or 2) were enclosed in sequentially numbered identical sealed envelopes that were opened at the moment of the scaling sessions to choose the first appointment treatment modality (1=mechanical, 2=manual) in which the first and the fourth quadrants were instrumented.

All patients underwent the same treatment. The treatment was carefully delivered in two appointments performed within one week, during the first appointment the first and the fourth quadrants (patient's right side) were completely treated by mechanical or manual devices according to the randomization codes. During the second appointment, the remaining two quadrants (patient's left side) were instrumented with the other therapeutical approach. All the debridement sessions were carried out by a single dentist graduated in Oral Surgery and highly trained in periodontology (A.Q.). All the patients were informed about appropriate oral hygiene procedures performed with toothbrushes and interdental devices.

#### Treatments

- In the mechanical side, patients were instrumented with machine driven devices (Air Flow Master Piezon® A,P and PS debridement tips, EMS Switzerland), whereas in the manual side hand instruments standard and mini-five curets were used (SG7-897; SG11-1293; SG13-1498; SAS7-897; SAS11-1293; SAS13-149, Hu-Friedy®, Chicago, USA). The duration of each session, need for local anesthesia and additional information were recorded by an undergraduate dental hygiene student (E.S.). Follow-up visits were scheduled at 2 and 6 weeks from the completion of the treatment to assess and reinforce oral hygiene procedures. 8 weeks after the last debridement appointment, periodontal re-evaluation was carried out and clinical parameters were collected as in the baseline visit. Before the start of the second appointment all the patients were requested to complete a form regarding pain, hypersensitivity, and need for painkillers following the first session treatment. An identical form regarding the second instrumentation session was completed by all the subjects involved in the study before the re-evaluation visit. Response to pain and tooth sensitivity ranged from a minimum of 0 (no pain or dentine hypersensitivity) to a maximum possible score of 10. All the patients were asked by an independent person to fill in the form in a private area after an accurate verbal explanation of the questionnaire.

#### Data Management and Statistical analysis

The primary outcomes of the present study were patient comfort and perception of pain. Statistical power and sample size calculation were elaborated by a public domain online software (Raosoft <http://www.raosoft.com/samplesize.html>). Since clinical changes between the two treatment approaches were not the primary outcome in this investigation and significant differences were not expected, no power calculation was carried out based on clinical outcomes. A power calculation was performed to detect a difference in effect sizes between groups (manual versus machine driven) for patient centered outcomes. Considering the data as a single sample, the study was powered to detect a moderate difference between before and after treatment (  $n=22$  per group would have 80% power at an effect size of 0.8 and  $\alpha=0.05$  for a two-sided test). In order to perform the analysis, all the data was inserted in a spreadsheet and proofed for data/entry errors. All the data regarding TMPS and TMBS was calculated as percentages  $\pm$  standard deviation. Moreover, non parametric tests (Friedman and Wilcoxon signed-rank tests) were performed to calculate within and between

differences for TMPS and TMBS. All the other parameters were expressed as means  $\pm$  standard deviation. The significance of the differences within the same group (same treatment side) at baseline and re-evaluation were assessed with the paired sample t test. The significance of the differences between the two group treatments ( manual versus machine driven) treatment were tested with independent sample t test. The statistician was blind regarding the treatment group assignment. A sub-analysis of the study results was conducted including sites with PPD > 6mm only. More precisely, subject-level means for sites with PD > 6mm were calculated and were expressed as mean  $\pm$  standard deviation. Within-group (same side) changes were analyzed using the paired t test for PD and CAL and using non-parametric tests (Friedman and Wilcoxon signed-rank tests) for TMPS and TMBS. Between group (manual side versus mechanical side) changes were analyzed using the independent sample t test for PD > 6mm and the nonparametric Mann-Whitney U test for TMPS and TMBS.

## RESULTS

#### Study Population

Twenty-two subjects were enrolled in the study and all received non-surgical periodontal therapy using mechanical or manual instrumentation in different quadrants of the mouth. Two drop-outs were observed during the study. Neither subject did showed up at the re-evaluation appointment.

Subject characteristics at baseline are displayed in Table I. There were 9 females and 11 males, and 10 subjects were smokers (defined as smoking >1 cigarette/day).

#### Clinical Parameters

The intraexaminer  $k$  value was 80% to 87%. The results for clinical parameters are described in Table II and III. The mean of sites with baseline PD  $\geq 6$  mm were  $10.65 \pm 8.52$  and  $9.05 \pm 6.82$  for the manual and mechanical sides respectively. At the re-evaluation the mean of sites with baseline PD  $\geq 6$  mm were  $2.20 \pm 3.21$  and  $1.15 \pm 1.90$  for the manual and mechanical sides respectively. All the within group differences included PDs and CALs were significantly different at baseline compared to reevaluation ( $p < 0.001$ ). The median TMPS

**Table I.** Study group profile.

Patients Profile	n
Baseline	22
Drop outs	2
Gender	9 females, 11 males
Smokers	10

110 (S)

A. QUARANTA ET AL.

**Table II.** *Plaque, Bleeding Scores and number of sites with PD≥6mm.*

Patient Number	Sex	Smoking	TMPS MA 0	TMPS MA 1	TMPS MD 0	TMPS MD 1	TMBS MA 0	TMBS MA 1	TMBS MD 0	TMBS MD 1	P6 MA 0	P6 MA 1	P6 MD 0	P6 MD 1
1	0	0	89.28%	11.78%	83.33%	12.08%	100%	9.78%	100%	12.08%	24	3	12	1
2	1	0	100%	40%	100%	25%	98.07%	39.28%	98.07%	27%	9	3	8	0
3	0	0	100%	1,312%	100%	16.25%	93.75%	14.12%	96.87%	17.07%	6	0	7	2
4	1	1	96.87%	20.31%	95.31%	25%	100%	19.37%	98.43%	26.25%	8	0	2	0
5	1	1	70%	26%	76.56%	29.68%	70%	13.33%	79.68%	15.62%	1	0	0	0
6	1	0	60.93%	9.37%	57.81%	14.68%	62.50%	10.01%	60.93%	9%	3	0	3	0
7	0	0	77.08%	10.41%	6,666%	14.16%	78.84%	18.41%	95.83%	14.16%	13	0	24	0
8	1	1	100%	34.37%	100%	35%	100%	29.37%	100%	15%	26	9	6	0
9	0	1	58.33%	18.75%	71.87%	23.43%	71.65%	11.66%	82.81%	13.01%	27	9	21	7
10	1	0	70.83%	56.25%	66.07%	48%	97.91%	54.10%	96.15%	30.92%	5	0	9	2
11	1	0	100%	31.12%	100%	29.61%	100%	21.56%	100%	23.84%	0	0	2	0
12	0	1	42%	10.41%	31%	4.16%	40%	5.21%	38%	3.01%	7	0	13	0
13	0	1	98%	25.92%	100%	33.33%	98.21%	13.57%	100%	21.01%	7	1	12	1
14	0	1	51.56%	10.93%	50%	16.25%	71.87%	11.03%	62.50%	15%	17	7	11	4
15	1	0	71.87%	20.31%	78.33%	23.33%	75%	11.56%	78.33%	0%	11	1	4	0
16	0	0	65%	13.33%	75%	18.33%	66.66%	5%	78.33%	3.33%	21	5	17	4
17	0	0	67.85%	28.57%	62.50%	16.07%	67.85%	18.92%	70%	10.04%	17	6	18	2
18	1	0	53.33%	15%	70%	18.33%	50%	11.66%	43.33%	10.08%	5	0	4	0
19	1	1	54.68%	45.31%	50	43.33%	57.81%	17.18%	51.66%	21.66%	4	0	5	0
20	1	1	100%	50%	100	65%	100%	56.66%	100%	63.30%	2	0	3	0
Percentage or Mean Score	NA	NA	76.38%	24.56%	76.72%	25.55%	80.01%	19.59%	81.55%	17.57	10.65	2.2	9.05	1.15
SD	NA	NA	19.87%	14.29%	20.53%	14.19%	19.27%	14.58%	20.66%	13.56%	8.52	3.21	6.82	1.9

SD: Standard deviation, NA: Not Applicable

Sex: 0 female, 1 male; Smoking: 0 non smoker, 1 smoker

TMPS MA 0: Two quadrants mouth Plaque Score Manual Debridment Baseline TMPS MA1: Two quadrants Mouth Plaque Score Manual Debridment Re-evaluation

TMPS MD 0: Two quadrants mouth Plaque Score Machine Driven Debridment Baseline TMPS MD1: Two quadrants Full Mouth Plaque Score Machine Driven Debridment Re-evaluation

TMBS MA 0: Two quadrants mouth Bleeding Score Manual Debridment Baseline TMBS MA1: Two quadrants Mouth Bleeding Score Manual Debridment Re-evaluation

TMBS MD 0: Two quadrants mouth Bleeding Score Machine Driven Debridment Baseline TMBS MD1: Two quadrants Mouth Bleeding Score Machine Driven Debridment Re-evaluation

P6 MA 0: Number of sites with PD≥6mm at baseline on the manual debridment side, P6 MA 1: Number of sites with PD≥6mm at re-evaluation on the manual debridment side

P6 MD 0: Number of sites with PD≥6mm at baseline on the machine driven debridment side, P6 MD 1: Number of sites with PD≥6mm at re-evaluation on the machine driven debridment side

PDMA0: Mean PD (mm) at the baseline on the manual debridment side PDMA1: Mean PD (mm) at the re-evaluation on the manual debridment side PDMA1

PD MD0: Mean PD (mm) at the baseline on the mechanical debridment side PD MD1: Mean PD (mm) at the re-evaluation on the mechanical debridment side

for the manual side decreased from 76.38±19.87% at baseline to 24.56 ±14.29% at 8 weeks re-evaluation and from 76.72±20.53% to 25.55±14.19%, respectively, in the mechanical side. These within-group changes were statistically significant (p <0.01). Similarly, the median TMBS for the manual side decreased from 80.01±19.27%

at baseline to 19.56±14.58% at 8 weeks re-evaluation and from 81.55±20.66% to 17.57±13.56% in the mechanical and in the curet groups respectively. These changes were also statistically significant (p <0.01). Differences in TMPS and TMBS between the groups were not statistically significant.

**Table III.** PD, CAL and REC values

Treatment Modality	Visit	PD (Mean±SD) (mm)	CAL (Mean±SD) (mm)	REC (Mean±SD) (mm)
Manual	Baseline	3.05±0.55	3.31±0.41	0.26±0.14
Manual	Re-evaluation	2.87±0.41*#	3.16±0.26*#	0.29±0.25
Machine Driven	Baseline	3.03±0.17	3.28±0.34	0.25±0.15

\*  $p < 0.05$  compared to baseline

# :  $p > 0.05$  (non statistically significant compared to the other treatment approach)

#### Mean Instrumentation time

Mean treatment duration for each session was measured and expressed in minutes (Tab. IV).

The mean time for the mechanical side was  $84.75 \pm 12.92$  minutes. This mean time was significant lower than the time needed for the manual side ( $119.25 \pm 13.50$ ,  $p < 0.05$ ).

#### Need for local anesthesia

The need for local anesthesia during the two instrumentation sessions was (Tab. IV). Only 6 out of 20 patients requested local anesthesia. Among these subjects 5 people asked for local anesthesia in both the treated sides, while another patient needed local anesthesia only for the treatment of the side instrumented with mechanical devices.

#### Adverse Effects and need for painkillers after treatment

No serious events occurred during the study period and all the healing were uneventful. Five out of 20 patients reported to take analgesics to relieve pain after treatment (Tab. IV). Among these subjects 3 patients took painkillers after both manual and mechanical debridement whereas the other 2 took analgesic medication just after manual non-surgical treatment. These two patients were excluded from analysis when comparing postoperative pain and sensitivity among the treatment groups. All the patients were prescribed ketoprofen 200 mg tablets 3 per day for a total period of 3 days. The 2 patients that took the painkillers after both the manual treatment took the analgesics for the entire prescription period (3 days). The 3 patients that took the painkillers after both the two instrumentation approaches reported that they needed less analgesic therapy following the mechanical therapy (usually 1 or 2 days analgesic therapy)

#### Pain Scores

Median pain scores at various visits are displayed in Table IV. In the manual side, median score following non surgical therapy was  $3.11 \pm 1.40$ , while in the mechanical side was  $2.33 \pm 1.41$ . Differences between the groups were statistically significant with higher scores for the manual side ( $p < 0.05$ ).

#### Dentine Hypersensitivity Scores

Median dentine hypersensitivity scores are displayed in Table IV. In the manual side, median score following non surgical therapy was  $3.77 \pm 1.11$  while in the mechanical side was  $4.44 \pm 1.14$ . Differences between the groups were statistically significant with higher scores for the mechanical side ( $p < 0.01$ ).

## DISCUSSION

Non surgical periodontal therapy may be performed with various devices as hand instruments, mechanical (sonic and ultrasonic) instruments and laser therapy. In addition, antiseptics (22) may be useful in the treatment of periodontal and peri implant diseases in which many microbiota (23) determine an host response with the increasing expression of different inflammation mediators (22,24,25). Hand instrumentation allow good tactile sensation while minimizing the risk of contaminated aerosol production. However, it tends to be more time consuming and may lead to excessive root surface cementum. In contrast to manual instruments, machine driven devices are less technique sensitive, require less time to complete and remove less tooth surfaces. Unfortunately, reduced clinician's tactile sensation and contaminated aerosols may be a limitation in their usage. While it has been



112 (S)

A. QUARANTA ET AL.

**Table III.** Instrumentation Time, need for anesthesia, Pain and Hypersensitivity Scores

Patient Number	Sex	Smoking	TMA	TMD	A MA	A MD	PMA	PMD	DMA	DMD
1	0	0	125	85	0	0	0	0	3	5
2	1	0	100	90	1	1	5	NA	NA	NA
3	0	0	125	100	0	1	4	4	3	5
4	1	1	120	95	0	0	3	2	3	3
5	1	1	130	95	0	0	2	2	3	4
6	1	0	120	85	0	0	3	2	3	4
7	0	0	100	70	1	1	2	2	3	3
8	1	1	140	50	1	1	5	NA	NA	NA
9	0	1	115	85	0	0	0	0	4	4
10	1	0	90	75	0	0	4	5	5	4
11	1	0	110	80	0	0	3	2	2	3
12	0	1	120	80	0	0	5	4	5	6
13	0	1	120	95	0	0	3	3	6	7
14	0	1	145	105	0	0	4	0	6	4
15	1	0	110	85	1	1	4	3	4	5
16	0	0	130	75	0	0	4	2	4	5
17	0	0	115	80	0	0	3	2	3	4
18	1	0	115	85	0	0	4	3	4	5
19	1	1	135	105	1	1	5	4	3	3
20	1	1	120	75	0	0	3	2	4	6
Mean Score	NA	NA	119.25	84.75	NA	NA	3.11	2.33	3.77	4.44
SD	NA	NA	13.5	12.92	NA	NA	1.40	1.41	1.11	1.14
SNF	NA	NA	1	1	NA	NA	1	1	1	1

*Italics: Patients that took analgesics following manual debridement and were subsequently not included in pain and dentine hypersensitivity assessment*

*SD: Standard deviation, NA: Not Applicable*

*SNF: Significance; 0, non statistically significant, 1, statistically significant*

*Sex: 0 female, 1 male; Smoking: 0 non smoker, 1 smoker*

*T MA : Duration of the manual debridement session expressed in minutes*

*T MD: Duration of the machine driven debridement session expressed in minutes*

*A MA :Need for anesthesia during the manual debridement session*

*A MD :Need for anesthesia during the machine driven debridement session, ); no need, 1: need for anesthesia*

*P MA: Pain score experienced by the patient following the manual debridement session (0 to 10)*

*P MD: Pain score experienced by the patient following the machine driven debridement session (0 to 10)*

*D MA: Dentine hypersensitivity experienced by the patient following the manual debridement session (0 to 10)*

*D MD: Dentine hypersensitivity experienced by the patient following the machine driven debridement session (0 to 10)*

demonstrated that both these therapeutical approaches determine similar periodontal healing in terms of probing pocket depths, bleeding on probing and periodontal attachment gain (19-25), several Authors reported that there is need for less time to treat periodontal patients with the mechanical debridement method (4,25,26). Our results

agree with these studies since the mean treatment time for instrumentation of two quadrants was 84.75 minutes for the mechanical versus 119.25 minutes for the manual side. This is highly appreciate by both the operator and the patient and is dramatically relevant from the cost-effective point of view in the treatment of periodontally

compromised patients at University and Hospital facilities. Clinical studies about pain experience following non surgical periodontal therapy are scarce (6,9). Pain perception to a similar stimulus is highly variable from individual to individual. A widely adopted method to measure pain is the adoption of visual analogue scales whereby the subject is asked to indicate their level of pain by a mark on graduated scale from no pain to the most severe pain imaginable (27). In the present study it was possible to observe that the pain reported by the patient after treatment and their consequent need for analgesics was definitely lower in the mechanical side compared to the manual side. On the contrary, dentine hypersensitivity was mainly experimented by patients after subgingival debridement with mechanical instruments. Moreover, most of the patients that took painkillers after the instrumentation (3 out of 5) took the analgesic drug following both the types of non surgical debridement. It is possible to state that there is a subgroup of population among those treated for periodontal disease that show high possibility to experience pain following non surgical periodontal therapy, despite the type of approach (curet or machine driven) selected by the operator. In this study no pre-operative assessment of pain and dentin hypersensitivity was performed. This aspect might be occasionally critical in evaluating possible within-quadrants differences in pain and dentin hypersensitivity due to the presence of other pathologies and recessions. Moreover, no evaluation by a blind operator was made to evaluate the presence of residual calculus and the roughness of the surface following instrumentation. However, the primary outcome of the present study was not the assessment of the clinical efficiency of different non surgical periodontal instrumentation methods. The need for an optimal and cost effective management of the clinical university facilities with the parallel effort to reduce the number of patients' visits determined a minimal discrepancy in the time-points for pain and sensitivity evaluation between manual and mechanical instrumentation quadrants. However, due to the randomized design of the present study this discrepancy was homogeneously distributed between the manual and mechanical instrumentation sides. Within the limits of the present randomized clinical trial it is possible to conclude that most of patients well tolerate non surgical periodontal treatment despite the type of instruments that are chosen by the clinician. In the present work most of the patients that requested anesthesia asked for it during both the debridement sessions (manual and mechanical procedures). Slight dentin hypersensitivity is a common adverse effect reported by most of the patients especially after subgingival curet debridement. However, it usually features a short time duration and don't determine need for analgesic assumption. Finally, machine driven

debridement shows a dramatic advantage compared to manual treatment due to the lower amount of time needed to complete the instrumentation. This is definitely a huge advantage in treatment efficacy and therapeutic ergonomics and is also appreciated by most of the patients.

## REFERENCES

1. Kinane DF, Berglundh T., Lindhe J. In Lindhe J. Clinical Periodontology and Implant Dentistry 5<sup>th</sup> Edition. Blackwell Munksgard Edition 2008. p285
2. Claffey N. Polyzois I. In Lindhe J. Clinical Periodontology and Implant Dentistry 5<sup>th</sup> Edition. Blackwell Munksgard Edition 2008. p766
3. Matia JI, Bissada NF, Maybury JE, Ricchetti P. Efficiency of scaling of the molar furcation area with and without surgical access. *Int J Periodontics Restorative Dent* 1986; 6(6):24-35
4. Tunkel J, Heinecke A, Flemmig TF. A systematic review of efficacy of machine-driven and manual subgingival debridement in the treatment of chronic periodontitis. *J Clin Periodontol* 2002; 29 Suppl 3:72-81.
5. Hallmon WW, Rees TD. Local anti-infective therapy: mechanical and physical approaches. A systematic review. *Ann Periodontol* 2003; 8(1):99-114.
6. Aslund M, Suvan J, Moles DR, D'Aiuto F, Tonetti MS. Effects of two different methods of non-surgical periodontal therapy on patient perception of pain and quality of life: a randomized controlled clinical trial. *J Periodontol* 2008; 79(6):1031-40.
7. Tammaro S, Wennström JL, Bergenholtz G. Root-dentin sensitivity following non-surgical periodontal treatment. *J Clin Periodontol* 2000; 27(9):690-7.
8. Van Steenberghe D, Garmyn P, Geers L, Hendrickx E, Maréchal M, Huizar K, Kristofferson A, Meyer-Rosberg K, Vandenhoven G. Patients' experience of pain and discomfort during instrumentation in the diagnosis and non-surgical treatment of periodontitis. *J Periodontol*. 2004; 75(11):1465-70.
9. Philstrom B.L., Hargreaves K.M., Bouwsama O.J., Myers W.R. Goodale M.B., dOyle M.J. Pain after periodontal scaling and root planning. *Journal of the American Dental Association* 1999; 130,801-807
10. Claffey N, Loos B, Gantes B, Martin M, Heins P, Egelberg J. The relative effects of therapy and periodontal disease on loss of probing attachment after root debridement. *J Clin Periodontol* 1988; 15(3):163-9).
11. Claffey N. Polyzois I. In Lindhe J. Clinical Periodontology and Implant Dentistry 5<sup>th</sup> Edition. Blackwell Munksgard Edition 2008. p773

114 (S)

A. QUARANTA ET AL.

12. Cohen J. A Coefficient of agreement for nominal scales. *Educ Psychol Measur* 1960; 20; 37-46
13. Ainamo J, Bay I. Problems and proposals for recording gingivitis and plaque. *Int Dent J* 1975; 25:229
14. O'Leary T, Drake R, Naylor J. The plaque control record. *J Periodontol* 1972; 43:38.
15. Quaranta A, Ronconi LF, Di Carlo F, Vozza I, Quaranta M. Electrochemical behaviour of titanium in ammine and stannous fluoride and chlorhexidine 0.2 percent mouthwashes. *Int J Immunopathol Pharmacol* 2010;23(1):335-43.
16. Schierano G, Pejrone G, Roana J, Scalas D, Allizond V, Martinasso G, Pagano M, Canuto RA, Cuffini AM. A split-mouth study on microbiological profile in clinical healthy teeth and implants related to key inflammatory mediators. *Int J Immunopathol Pharmacol* 2010; 23(1):279-88.
17. Zizzi A, Aspriello SD, Rubini C, Goteri G. Peri-implant diseases and host inflammatory response involving mast cells: a review. *Int J Immunopathol Pharmacol* 2011; 24(3):557-66.
18. Guerra M, Vozza I, Quaranta A. Histological evaluation of peri-implant soft tissues in immediately loaded implants featuring different implant-abutment connections: a preliminary study. *European Journal of Inflammation* 2012; 10(1):91-98
19. Badersten A, Nilvéus R, Egelberg J. Effect of nonsurgical periodontal therapy. I. Moderately advanced periodontitis. *J Clin Periodontol* 1981; 8(1):57-72.
20. Badersten A, Nilvéus R, Egelberg J. Effect of nonsurgical periodontal therapy. VII. Bleeding, suppuration and probing depth in sites with probing attachment loss. *J Clin Periodontol* 1985; 12(6):432-40
21. Badersten A, Nilvéus R, Egelberg J. Effect of non-surgical periodontal therapy. VI. Localization of sites with probing attachment loss. *J Clin Periodontol* 1985; 12(5):351-9.
22. Lindhe J, Nyman S. Scaling and granulation tissue removal in periodontal therapy. *J Clin Periodontol* 1985; 12(5):374-88.
23. Laurell L. Periodontal healing after scaling and root planing with the Kavo Sonicflex and Titan-S sonic scalers. *Swed Dent J* 1990; 14(4):171-7.
24. Yukna RA, Scott JB, Aichelmann-Reidy ME, LeBlanc DM, Mayer ET. Clinical evaluation of the speed and effectiveness of subgingival calculus removal on single-rooted teeth with diamond-coated ultrasonic tips. *J Periodontol* 1997; 68(5):436-42.
25. Wennström JL, Tomasi C, Bertelle A, Dellasega E. Full-mouth ultrasonic debridement versus quadrant scaling and root planing as an initial approach in the treatment of chronic periodontitis. *J Clin Periodontol* 2005; 32(8):851-9.
26. Christgau M, Männer T, Beuer S, Hiller KA, Schmalz G. Periodontal healing after non-surgical therapy with a modified sonic scaler: a controlled clinical trial. *J Clin Periodontol* 2006; 33(10):749-58.
27. Claffey N, Polyzois I. Non surgical therapy. In Lindhe J. *Clinical Periodontology and Implant Dentistry 5<sup>th</sup> Edition*. Blackwell Munksgard Edition 2008.p773

## CLINICAL ORAL IMPLANTS RESEARCH

Stefano Tetè  
Susi Zara  
Vincenzo Luca Zizzari  
Alessandro De Carlo  
Raffaele Vinci  
Amelia Cataldi  
Enrico Gherlone

## Immunohistochemical analysis of matrix metalloproteinase-9, vascular endothelial growth factor, bone sialoprotein and i-nitric oxide synthase in calvaria vs. iliac crest bone grafts

**Authors' affiliations:**

Stefano Tetè, Vincenzo Luca Zizzari, Alessandro De Carlo, Department of Oral Science, Nano and Biotechnology, University "G. d'Annunzio", Chieti, Italy  
Susi Zara, Department of Drug Sciences, University "G. d'Annunzio", Chieti, Italy  
Raffaele Vinci, Enrico Gherlone, Department of Oral Science, University "Ateneo Vita – Salute" S. Raffaele, Milan, Italy  
Amelia Cataldi, Department of Medicine and Ageing Sciences, University "G. d'Annunzio", Chieti, Italy

**Corresponding author:**

Stefano Tetè  
Department of Oral Science, Nano and Biotechnology, Chair of Oral Surgery  
University "G. d'Annunzio"  
Via dei Vestini, 31  
66100 Chieti Scalo (CH), Italy  
Tel./Fax: +3908713554095  
e-mail: tete@unich.it

**Key words:** angiogenesis, autologous bone graft, calvaria, iliac crest

**Abstract**

**Objectives:** The aim of this study was to investigate, in parallel to clinical and histological modifications, the expression of specific proteins involved in different extraoral autologous bone grafts integration in humans.

**Material and methods:** Patients needing oral rehabilitation of posterior maxilla, with inadequate bone volume for implant placement, received bone grafts from calvaria (Group 1) and iliac crest (Group 2), respectively. From five patients from each group, with a total of 10 subjects, bone biopsy specimens were collected at two different experimental time points: at bone blocks withdrawal for grafting (T0), from donor sites, and after 4 months, from reconstructed sites. Samples were processed for light microscope and immunohistochemical analyses to evaluate MMP9, VEGF, BSP, iNOS expression.

**Results:** Morphological analysis of T0 calvaria evidenced areas of extracellular matrix, uniformly stained and organized in concentric mineralized lamellae edging few vascular canals, while T0 iliac crest showed greater cellularity compared to calvaria, with rare mineralized areas, surrounding wide bone marrow lacunae. In T1, Group 1 samples showed large areas of extracellular matrix, uniformly stained, at the same time as Group 2 samples disclosed few areas of mineralized tissue. Although no significant differences were found in proteins expression among calvaria and iliac crest T0 samples, MMP9, VEGF and BSP expression at T1 were discovered higher in Group 1 samples than in Group 2 ones, while iNOS expression increased in Group 2 samples compared to the others. In any group, molecules expression increased passing from T0 to T1.

**Conclusion:** These findings suggested that, even though clinically both extraoral sources of autologous bone could be considered suitable for grafting in case of large oral rehabilitation, some differences might be detected microscopically and biologically. Calvaria bone graft seemed to enhance not only the quantity of bone tissue at the defect site, but also its quality, better than iliac crest bone do. Then, while both grafts appeared to promote a suitable neoangiogenesis, as showed by morphological analysis and by MMP9 and VEGF expression, in terms of new bone formation and lack of occurrence of inflammatory events, calvaria could be considered a more suitable donor site for bone grafts.

Bone augmentation represents a treatment of choice for all cases of alveolar deficiency in oral surgery. Implant rehabilitation needs an adequate size and morphology of the alveolar process to obtain a successful outcome. In this way, correct prosthetic rehabilitation could be achieved regarding function and aesthetics. Different techniques have been proposed for deficient alveolar ridge reconstruction and a variety of autologous bone grafts from both extraoral and intraoral donor

sites, and heterologous biomaterials have been used in the last few years (Mangano et al. 2006; Aguirre-Zorzano et al. 2007; Chiapasco et al. 2009; Esposito et al. 2009)

Autologous extraoral bone grafts have demonstrated lower infection rates and greater availability for harvesting compared to other autologous sources for grafting (Ozaki & Buchman 1998; Smolka et al. 2006). In some studies, intramembranous bone has been proved to be more efficient in bone defect

**Date:**

Accepted 7 July 2011

**To cite this article:**

Tetè S, Zara S, Zizzari VL, De Carlo A, Vinci R, Cataldi A, Gherlone E. Immunohistochemical analysis of Matrix Metalloproteinase-9, Vascular Endothelial Growth Factor, Bone Sialoprotein and i-Nitric Oxide Synthase in Calvaria vs. Iliac Crest Bone Grafts.  
*Clin. Oral Impl. Res.* 23, 2012, 1254–1260  
doi: 10.1111/j.1600-0501.2011.02300.x

repairs than endochondral grafts in craniofacial defects (Wong & Rabie 1999; Bianchi et al. 2004; Crespi et al. 2007).

Moreover, many authors agree that, independently of the embryologic origin, the number of the corticals and the macroscopic architecture of the tissue harvested might affect the clinical success in bone grafting (Lu & Rabie 2004).

Due to bone accessibility and availability of an adequate quantity of both cortical and cancellous bone, iliac crest is considered a useful donor site for autogenous bone grafting (Nkenke et al. 2004). Moreover, the retrieval procedure is associated with a lower morbidity and less post-operative complications at the donor site, with differences in their incidence and severity according to the harvesting techniques used (Ishii et al. 2010; Schaaf et al. 2010).

Any action affecting bone and a tissue in general, such as growth, repair and remodelling, gives rise to a range of biological processes, all regulated by specific factors and molecules. In bone graft integration, these processes begin with graft resorption and tissue revascularization, followed by remodelling events (Faria et al. 2008).

Initially, endothelial cells, lining the existing microvessels, in response to angiogenic stimuli, degrade their basement membrane by secreting proteolytic enzymes, included matrix metalloproteinases (MMPs), thus providing the physical space for endothelial cell proliferation and for new blood vessels creation. MMPs belong to a family of enzymes playing a central role in ECM turnover and remodelling, based on their ability to hydrolyze major protein components of the extracellular matrix, and also to determine the timing and the sites where resorption should initiate and its relationship with new bone formation (Delaisse et al. 2000; Cawston & Young 2010).

To date, there are more than twenty known MMPs, differing from each other for their substrate specificity, but sharing a number of common structural and functional similarities. Among these, MMP2 and MMP9 are well known for their ability to degrade the collagen filaments at the vascular basement membrane and to assist other specific collagenases in the degradation of the interstitium. New vessels grow after interstitium degradation, supported also by vascular endothelial growth factor (VEGF), which, in addition, plays an important role in the maintenance and development of endothelial fenestrations and in endothelial survival, as demonstrated by *in vivo* and *in vitro* studies (Kamba et al.

2006; Winder & Lenz 2010). Vascular support in the tissue interstices allows the passage of new and additional signals and growth factors that trigger the production of new bone matrix, and of undifferentiated mesenchymal stem cells to colonize the grafted area from the peripheral areas to the centre (Nguyen et al. 2001; Holmes et al. 2007).

The completion of resorption and subsequent bone formation is also regulated by bone sialoprotein (BSP), a highly glycosylated tyrosine-sulphated, serine-phosphorylated protein, component of the ECM. Immunohistochemical analyses showed positive staining for BSP in active osteogenic cells at the site of new bone formation, and at the mineralization front concurrent with or just before mineral deposition. However, its expression was showed not only to be related to the mature osteoblastic phenotype, but also up-regulated by factors inducing osteoblasts differentiation (Chen et al. 1994).

As any bone graft could be recognized by the host organism as non-self, an inflammatory response should also be expected. Among the molecules involved in the occurrence of inflammation, those belonging to

nitric oxide synthase family, mainly iNOS were involved (Umar & van der Laarse 2010).

Thus, the aim of this study was to investigate the expression of specific molecules involved in graft integration, in terms of angiogenesis, osteogenesis and inflammatory processes occurring at sites treated with two different extraoral autologous bone graft, obtained from calvaria and iliac crest, respectively.

## Material and methods

Patients in need of oral rehabilitation of the posterior maxilla, with inadequate bone volume for implant placement, were scheduled for bone augmentation with autologous extraoral bone grafts. All the bone defects considered could be classified as Class G according to Chiapasco's Classification of the Posterior Maxilla (2004) (Misch et al. 2006). All patients received sufficient information about this research and gave written consent in accordance with Italian Legislation and with the code of Ethical Principles for Medical Research involving Human Subjects of the

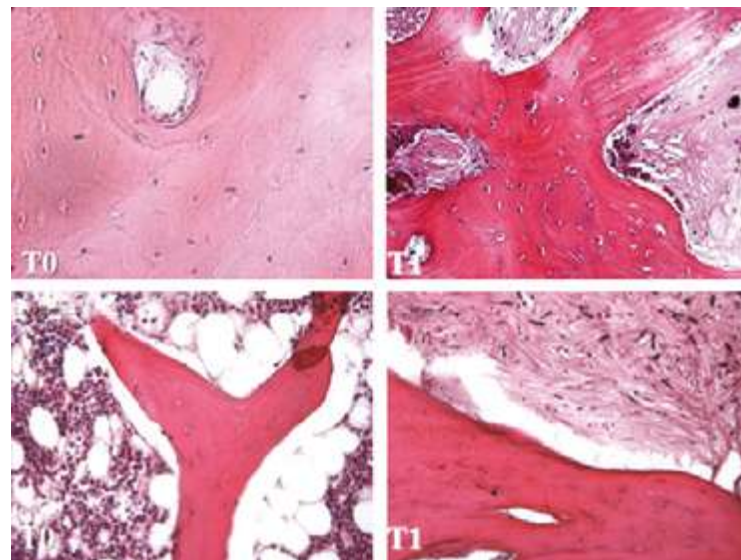


Fig. 1. Haematoxylin and eosin staining of the T0 and T1 iliac crest samples. Magnification 20 $\times$ . Upper panel: calvaria bone samples; lower panel: iliac crest bone samples. The staining highlights, in T0 calvaria sample, large areas of mineralized extracellular matrix with disc-shaped cavities, showing depressions in the face of the disc, the bone gaps, in which osteocytes (oc) were entrapped, concentric sheets which edge Haver's canal (H) can be distinguished. On the contrary, T0 iliac crest sample evidences large areas of bone marrow (bm) with little areas of mineralized matrix. T1 calvaria sample discloses a dynamic structure with mineralized areas containing bone gaps and oc surrounded by connective tissue, with elastic fibres, where blood vessels, Haver's canal (H) and lines of osteoblasts (ob) at the periphery of the extracellular matrix can be identified. In T1 iliac crest sample, two separated structures areas of mineralized tissue and of connective tissue, without any integration, can be identified.



Tetè et al. *In vivo* behaviour of calvaria vs. iliac crest bone graft

World Medical Association (Declaration of Helsinki).

Before surgical procedures, patients underwent complete medical anamnesis and radiographic examinations. Preoperative radiographic evaluation included orthopantomograms and computed tomography of the jaw (TAC Dentascan).

Among the patients who underwent surgical procedures for bone augmentation, we selected randomly 10 patients, with ages ranging from 45 to 65 years: five who received extraoral autologous bone blocks obtained from the parietal region of the calvaria (Group 1) and five from iliac crest (Group 2), respectively. All the patients included in the study had healthy systemic conditions, including the absence of any disease that would contraindicate surgery. The exclusion criteria were: uncontrolled periodontal disease, severe illness, unstable diabetes, drug abuse, a history of head and neck irradiation, chemotherapy. Bone regeneration was achieved by combining two regenerative surgical techniques: the maxillary onlay graft and sinus lift. Before any surgical treatment, prophylactic antibiotic therapy (2 g ceftriaxone an hour before) was administered to all patients.

The autologous bone blocks from the parietal region of calvaria were taken utilizing the split-*in situ* calvarial graft of Paul Tessier (Tessier 1982), under general anaesthesia. After skin incision, the outline of the strips were drawn with a piezoelectric instrument (Easy Surgery, BioSAF Srl, Ancona, Italy). After having completely osteotomized the margins, the fragments were detached with differently angled scalpels.

The surgical access to iliac crest was about 4 cm posterior to the anterior superior iliac spine, performing a skin incision about 2 cm long. The skeletonization of the internal iliac hole was performed, followed by an anterior-medial bicortical grafting according to the Grillon technique (Grillon et al. 1984). After shaping bone tissue by piezosurgery, the bone blocks were mobilized through the use of chisels.

The cortical bone of the recipient site was perforated with a 1-mm-diameter round bur to increase the blood supply from the endosseous vessels, as previously suggested (Pedrosa et al. 2009). The withdrawn bone blocks were shaped according to the dimension of the defects, properly fitted in the recipient site and then fixed with lag screw to rebuild the alveolar ridge.

All gaps between the bone blocks and the recipient sites were packed with bone chips obtained from the same donor site. For each

group, the sinus was filled with particulate bone obtained from the same donor sites with a bone scraper.

The grafted areas were covered with a resorbable barrier. After releasing the vestibular periosteum, the flap was sutured. Post-operative therapy protocol comprised administration of antibiotic (ceftriaxone) 2 g/day for 10 days, non-steroidal analgesic drug (ketoprofen) at a dose of 200 mg twice daily for 3 days and thereafter if required, cortisone (betametason) 4 mg/day for 2 days and 2 mg on day 3. Moreover, soft diet and oral hygiene, including three times daily rinsing with 0.2% chlorhexidine mouthwash and the application on the surgical site of 1% chlorhexidine gel, were prescribed. Sutures were removed 10 days after the intervention, and post-operative check-ups scheduled weekly for the first month, and then monthly.

After the first surgery, patients were checked up monthly by clinical and radiographical examination with periapical X-rays in the grafted area. Post-operative healing was uneventful for all the patients, therefore after about 4 months they were scheduled for a second surgery for implant placement. During implant placement intervention, the fixation screws were removed and bone biopsies were collected by a 3 mm-diameter and 8 mm-height Trephine in the sites of implant placement, to obtain significant specimens of bone regenerated with extraoral autologous bone grafts.

The implant features (diameter and length) were decided according to the individual anatomic structure. The implant was allowed to heal unloaded for 6 months for bone integration before prosthetic rehabilitation beginning. Pharmacological protocol included antibiotic (amoxicillin) 2 g an hour preopera-

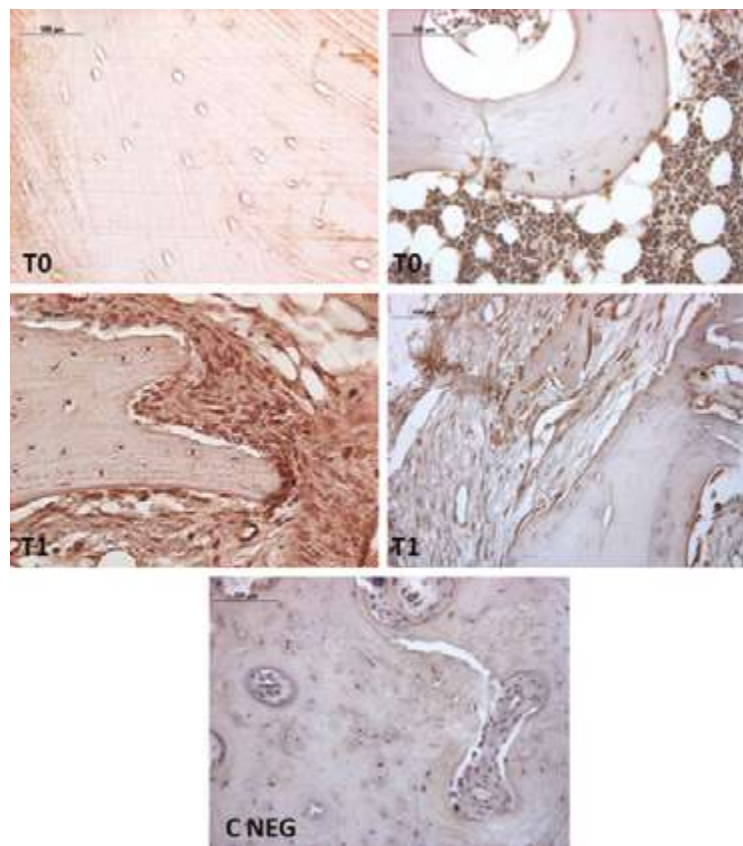


Fig. 2. Immunohistochemical analysis of MMP9 at different experimental times. Magnification 20 $\times$ . T0: samples at withdrawal time, T1: bone samples from the regenerated area 4 months after grafting, C NEG: negative control. Left panel: calvaria; right panel: iliac crest. Negative control shows large areas of mineralized tissue, some blood vessel and little areas of connective tissue.

tively and 1 g twice for the following 5 days and non-steroidal analgesic drug to be taken as required.

The two samples, used for morphological and immunohistochemical analysis, were:

- (1). T0: samples of bone tissue obtained from calvaria and iliac crest bone at the moment of bone block withdrawal for the grafting;
- (2). T1: samples of bone tissue collected from the grafted area at the moment of implant placement, i.e. about 4 months after the first intervention.

#### Light microscopy analysis and immunohistochemistry

Tissues were fixed in 10% phosphate-buffered formalin for 72 h and decalcified in 10% tetrahydrated EDTA, according to data sheet (MIELODEC kit, Bio-Optica, Milan, Italy). Subsequently, they were dehydrated through ascending alcohols and xylene and then paraffin-embedded. Tissues were subjected to standard histotechnical processing, the samples were then de-waxed (xylene and alcohol at progressively decreasing concentrations) and the slides, 5 µm thick, were processed for haematoxylin-eosin staining and for immunohistochemical analysis.

To detect MMP9, VEGF, BSP and iNOS proteins, immunohistochemistry was performed on 5 µm-thick sections by means of Ultravision LP Detection System HRP Polymer & DAB Plus Chromogen (Lab Vision Thermo, Fremont, CA, USA). Slides were incubated in the presence of mouse anti-MMP9 monoclonal antibody (Santa Cruz Biotechnology, Santa Cruz, CA, USA), rabbit anti-VEGF, mouse anti-BSP and rabbit anti-iNOS monoclonal antibody (Calbiochem Merck, Cambridge, MA, USA). Sections were incubated in the presence of specific HRP-conjugated secondary antibodies. Peroxidase was developed using diaminobenzidin chromogen (DAB) and nuclei were haematoxylin counterstained. Negative controls were performed by omitting the primary antibody.

Samples were then observed by means of Leica DM 4000 light microscopy (Leica Cambridge Ltd, Cambridge, UK) equipped with a Leica DFC 320 camera (Leica Cambridge Ltd) for computerized images.

#### Computerized morphometry measurements and image analysis

After digitizing the images derived from immunohistochemical-stained sections, QWin Plus 3.5 software (Leica Cambridge Ltd) was used to evaluate MMP9, VEGF, BSP and iNOS expression. Image analysis of protein expres-

sion was performed through the quantification of thresholded area for immunohistochemical brown colour, as average value per 10 fields, randomly chosen, for each sample at light microscope observation. Negative controls belonged to T1 Group and negative control images were randomly chosen. The statistical significance of the results was evaluated by the Wilcoxon, Mann-Whitney Test, using R Software, version 2.12.1 for Mac (It is a free opensource software), and setting  $P = 0.05$ . After collecting results, the mean data were reported and showed in a histogram using Excel 2008 for Mac.

## Results

### Morphological analysis

In T0 samples from Group 1, light microscope observation showed areas of extracellu-

lar matrix, uniformly stained and organized in concentric lamellae edging few vascular canals. Inside the extracellular matrix, disc-shaped cavities could also be distinguished showing depressions in the face of the disc, bone gaps, in which few osteocytes were entrapped. T0 samples of Group 2 bone showed more cells than samples of autologous calvaria bone. Rare areas of mineralized tissue, surrounding wide lacunae containing bone marrow were evident in these samples.

In T1 samples from Group 1 a great number of osteoblasts, recognizable for their polyhedral form, could be identified. Osteoblasts were arranged in lines and localized at the section periphery. Large areas of extracellular matrix, uniformly stained, could also be recognized. Autologous iliac crest bone samples (Group 2) did not disclose a dynamic situa-

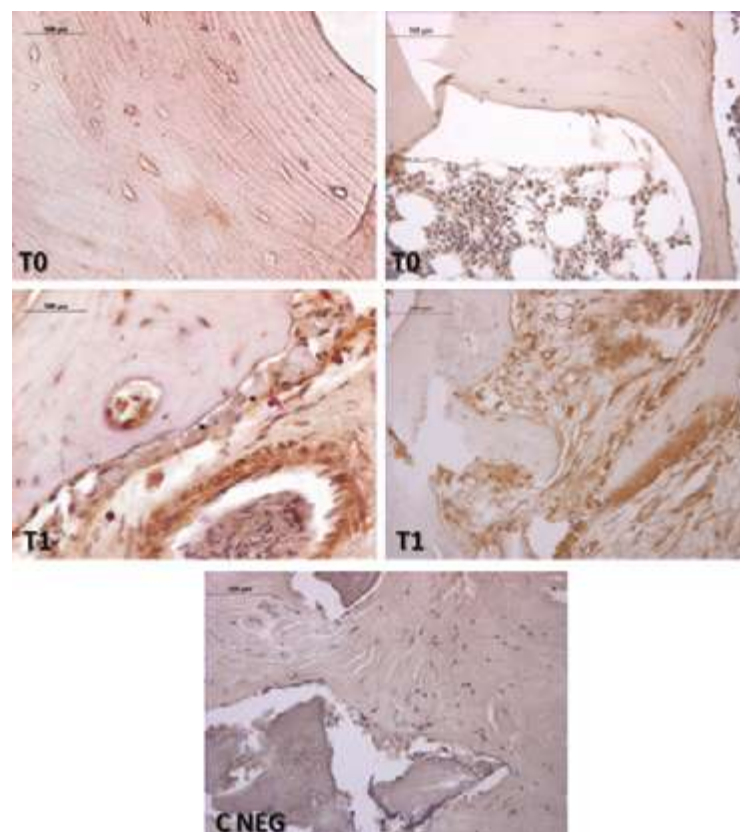


Fig. 3. Immunohistochemical analysis of VEGF at different experimental times. Magnification 20×. T0: withdrawal time of samples; T1: bone samples from the regenerated area 4 months after grafting; C NEG: negative control. Left panel: calvaria; right panel: iliac crest. Negative control shows a wide areas of connective tissue with elastic fibres and a little area of mineralized extracellular matrix.

Tetè et al. *In vivo* behaviour of calvaria vs. iliac crest bone graft

tion: both areas of mineralized tissue and of connective tissue were represented (Fig. 1).

#### Immunohistochemical analysis

In both calvaria and iliac crest MMP9 expression resulted higher in T1 samples than in T0 ones. At T0, the MMP9 level was higher in iliac crest bone than in the calvaria, while in T1 MMP9 was more expressed in samples from calvaria bone grafts (Fig. 2).

Angiogenic activity in samples at different experimental times was evaluated by performing VEGF immunohistochemical analysis. In T0 samples, VEGF expression showed no significant differences between iliac crest and calvaria bone, while in T1 samples its expression was higher in calvaria bone graft, when compared to the iliac crest (Fig. 3).

At T0, the BSP level was higher in iliac crest bone than in calvaria. On the contrary, its expression in T1 samples showed a remarkable increase in calvaria bone, which highlighted BSP localization at the sites of *de novo* bone formation and at the mineralization front (Fig. 4).

As for iNOS expression, it was not significantly different in either T0 samples, while in T1 it resulted over-expressed in iliac crest compared to calvaria (Fig. 5).

To show the tendency of molecular expression the mean data, in T0 and in T1 samples, were indicated in Fig. 6.

#### Discussion

Correction of large bone defects in the posterior maxilla requires a delicate approach to obtain a functional implant restoration and to prevent construction of non-axial prosthetic solutions. Bone grafts are considered necessary to recreate a correct relationship between alveolar ridges. The topic of several recent researches was to understand biological processes underlying bone graft–host tissue interaction and to identify which factors may support bone graft integration (Thorwarth et al. 2005).

Grafts for alveolar ridge augmentation induce a reaction in the host organism, as it recognizes the graft as a non-self element. The organism reacts by switching on several processes, including new bone and vessel formation along with inflammation, which can be investigated by morphological and molecular approaches (Andrade et al. 2010).

In this study, to assess the response of bone tissue to different autologous extraoral bone grafts, obtained from calvaria and iliac crest bone, respectively, and in particu-

lar to detect angiogenic activity and new bone formation, in parallel to morphological analysis, MMP9, VEGF, BSP and iNOS immunohistochemical analyses were carried out.

The superiority of autologous bone grafts has been previously proved in comparison with heterologous bone grafts, along with the advantages related to the use of extraoral donor sites, as they may provide a higher quantity of bone tissue than that obtained from an intraoral donor site (Tetè et al. 2009; Klijn et al. 2010).

Data from light microscopy observation of T0 samples confirm what has been previously described about calvaria and iliac crest bone tissues morphology by Chiodo's and our group (Chiodo et al. 2010; Tetè et al. 2010): large mineralized areas can be

observed in calvaria samples, while iliac crest ones show few trabeculae surrounded by wide lacunae containing active haematopoietic marrow.

The good performance showed by calvaria grafts could be explained by the peculiar features of native calvaria bone tissue: in fact in a study conducted in an animal model, histological analysis demonstrated the presence of more osteoblastic and less osteoclastic activity in sites treated with calvaria graft than in sites regenerated with iliac crest graft (Donovan et al. 1993).

In addition, Chen et al. (1994) evidenced a lower osteoclastic activity and a lower revascularization in calvaria bone grafts than in iliac crest grafts. The present data show a more dynamic structure in T1 calvaria samples than that observed in iliac crest samples,

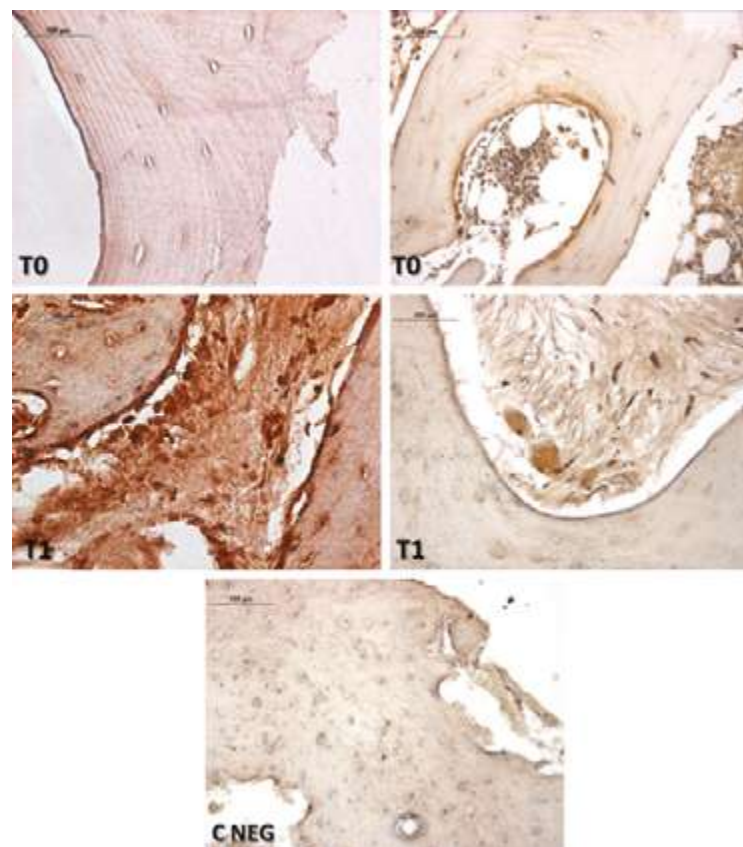


Fig. 4. Immunohistochemical analysis of BSP at different experimental times. Magnification 20 $\times$ . T0: withdrawal time of samples; T1: bone samples from the regenerated area 4 months after grafting; C NEG: negative control. Left panel: calvaria; right panel: iliac crest. Negative control shows large areas of mineralized extracellular matrix.



Tetè et al. *In vivo* behaviour of calvaria vs. iliac crest bone graft

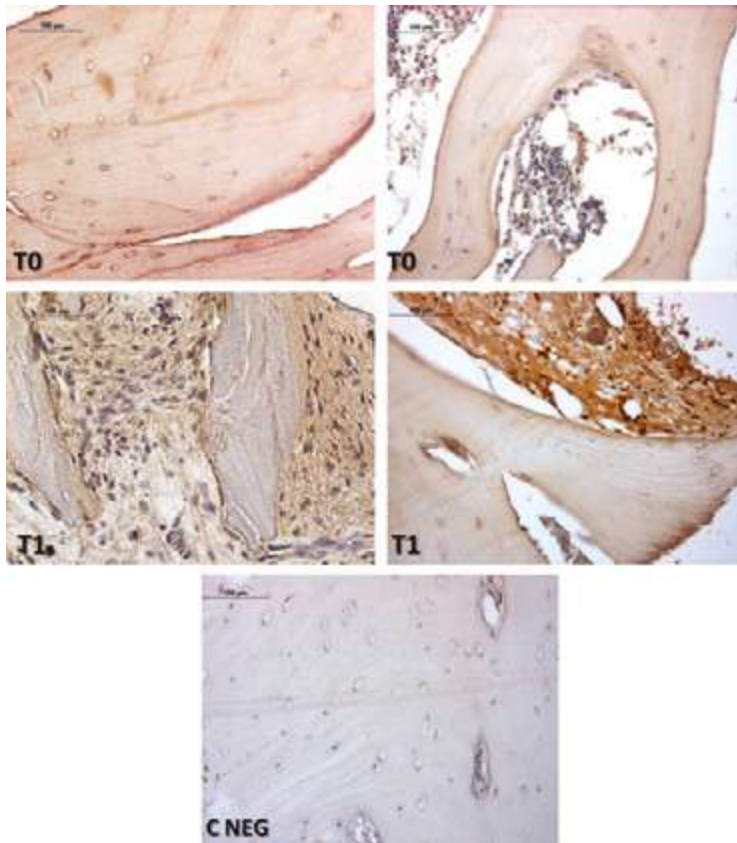


Fig. 5. Immunohistochemical analysis of iNOS at different experimental times. Magnification 20×. T0: withdrawal time of samples; T1: bone samples from the regenerated area 4 months after grafting; C NEG: negative control. Left panel: calvaria; right panel: iliac crest. Negative control shows large areas of mineralized extracellular matrix.

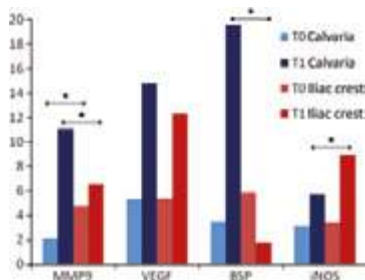


Fig. 6. Graphic representation of densitometric analysis of MMP9, VEGF, BSP and iNOS positive area  $\pm$ SD determined by direct visual counting of 10 fields for each of five slides per sample (mean values) at 20× magnification, both at T0 and T1. \*MMP9 T0 calvaria vs. MMP9 T0 iliac crest  $P < 0.05$ . \*MMP9 T1 calvaria vs. MMP9 T1 iliac crest  $P < 0.05$ . \*BSP T1 calvaria vs. BSP T1 iliac crest  $P < 0.05$ . \*iNOS T1 calvaria vs. iNOS T1 iliac crest  $P < 0.05$ .

with large areas of vascularized connective tissue and mineralized matrix, surrounded at the periphery by lines of osteoblasts and osteocytes, indicating bone formation and remodelling phenomena. Unlike what was previously reported, in samples from sites regenerated with calvaria graft, active revascularization is found after 4 months.

Moreover, graft resorption determined not only volume reduction of the graft itself, but also a reduction in bone density, which may affect the primary stability of the inserted implants [Norton & Gamble 2001; Sivarajasingam et al. 2001]. The present findings indicate sites regenerated with calvaria grafts showing features more similar to the donor site bone tissue than to the recipient site, thus improving bone quality and quantity of the grafted area.

Histological findings reflect the clinical performance of the graft; in fact, the main problem of bone regenerative process is the graft resorption rate. The clinical observation of the grafted areas after a 4 months healing confirmed that, even if slight differences may occur depending on the surgical procedures, the incidence of graft resorption in calvaria bone grafts is lower than that in iliac crest [Iizuka et al. 2004; Smolka et al. 2006; Crespi et al. 2007].

Moreover, calvaria and iliac crest bone grafts were investigated from a biological point of view, according to the angiogenic and inflammatory responses of the host tissue.

As MMP9 and VEGF were suggested to be able to induce new blood vessel growth [Nguyen et al. 2001; Kamba et al. 2006], the higher expression of MMP9 and VEGF recorded in T1 samples from sites regenerated with calvaria graft indicated that the graft integration implies new blood vessel formation.

Bone Sialoprotein, an extracellular matrix protein, detected in active osteogenic cells, at sites of *de novo* bone formation [Chen et al. 1994], plays a functional role in the regulation of mineral formation.

In T1, BSP expression is significantly higher in calvaria bone graft sites than in iliac crest bone grafts, suggesting calvaria as a more appropriate donor site and, at the same time, iliac crest graft as less suitable to induce new bone formation.

Concerning iNOS expression evaluation, similar level in both T0 samples and increased levels in T1 iliac crest sample compared to the T1 calvaria ones, are demonstrated, suggesting that iliac crest bone graft may be responsible for more intense inflammatory events. However, this hypothesis needs to be confirmed by further investigations such as *in vivo* iNOS activity assay.

Thus, even if clinical observations suggested that both donor sites were adequate for obtaining bone suitable for the regenerative procedure of the posterior maxilla, the morphological and molecular features showed in the present study indicate that the iliac crest graft is a favourable bone substitute in terms of angiogenesis, as demonstrated by MMP9 and VEGF expression. However, calvaria bone may be considered more suitable for grafting in all situations requiring wide oral rehabilitation, in terms of new bone formation and lack of occurrence of inflammatory events, as demonstrated by BSP and i-NOS expression.

Tetè et al. *In vivo* behaviour of calvaria vs. iliac crest bone graft

**Acknowledgements:** This work has been supported by FIRB-Accordi di

Programma 2010, "Processi degenerativi dei tessuti mineralizzati del cavo orale, impiego di

biomateriali e controllo delle interazioni con i microrganismi dell'ambiente", Prof. A.Cataldi.

## References

- Aguirre-Zorano, L.A., Rodriguez-Tojo, M.J. & Aguirre-Urizar, J.M. (2007) Maxillary sinus lift with intraoral autologous bone and B-tricalcium phosphate: histological and histomorphometric clinical study. *Medicina oral, patología oral y cirugía bucal* **12**: E532-E536.
- Andrade, M.G., Moreira, D.C., Dantas, D.B., Sá, C. N., de Bittencourt, T.C. & Sadigursky, M. (2010) Pattern of osteogenesis during onlay bone graft healing. *Oral Surgery, Oral Medicine, Oral Pathology, Oral Radiology & Endodontics* **110**: 713-719.
- Bianchi, A.E., Vinci, R., Torti, S. & Sanfilippo, F. (2004) Atrophic mandible reconstruction using calvarial bone grafts and implant-supported overdentures: radiographic assessment of autograft healing and adaptation. *The International Journal of Periodontics & Restorative Dentistry* **24**: 334-343.
- Cawston, T.E. & Young, D.A. (2010) Proteinases involved in matrix turnover during cartilage and bone breakdown. *Cell and Tissue Research* **339**: 221-235. *Journal of Bone and Mineral Research* **7**: 987-997.
- Chen, N.T., Glowacki, J., Bucky, L.P., Hong, H.Z., Kim, W.K. & Yaremchuk, M.J. (1994) The roles of revascularization and resorption on endurance of craniofacial onlay bone grafts in the rabbit. *Plastic and Reconstructive Surgery* **93**: 714-724.
- Chiapasco, M., Casentini, P. & Zaniboni, M. (2009) Bone augmentation procedures in implant dentistry. *The International Journal of Oral & Maxillofacial Implants* **24S**: 237-259.
- Chiodo, C.P., Hahne, J., Wilson, M.G. & Glowacki, J. (2010) Histological differences in iliac and tibial bone graft. *Foot & Ankle International* **31**: 418-422.
- Crespi, R., Vinci, R., Cappare, P., Gherlone, E. & Romanos, G.E. (2007) Calvarial versus iliac crest for autologous bone graft material for a sinus lift procedure: a histomorphometric study. *The International Journal of Oral & Maxillofacial Implants* **22**: 527-532.
- Delaisse, J.M., Engsig, M.T., Everts, V., del Carmen Ovejero, M., Ferreras, M., Lund, L., Vu, T.H., Werb, Z., Winding, B., Lochter, A., Karsdal, M.A., Troen, T., Kirkegaard, T., Lenhard, T., Heegaard, A.M., Neff, L., Baron, R. & Foged, N.T. (2000) Proteinases in bone resorption: obvious and less obvious roles. *Clinica Chimica Acta* **291**: 223-234.
- Donovan, M.G., Dickerson, N.C., Hellstein, J.W. & Hanson, L.J. (1993) Autologous calvarial and iliac onlay bone grafts in miniature swine. *Journal of Oral and Maxillofacial Surgery* **51**: 898-903.
- Esposito, M., Grusovin, M.G., Felice, P., Karatzopoulos, G., Worthington, H.V. & Coulthard, P. (2009) Interventions for replacing missing teeth: horizontal and vertical bone augmentation techniques for dental implant treatment. *Cochrane Database of Systemic Reviews* **4**: CD003607.
- Faria, P.E., Okamoto, R., Bonilha-Neto, R.M., Xavier, S.P., Santos, A.C. & Salata, L.A. (2008) Immunohistochemical, tomographic and histological study on onlay iliac grafts remodeling. *Clinical Oral Implants Research* **19**: 393-401.
- Grillon, G.L., Gunther, S.F. & Connole, P.W. (1984) A new technique for obtaining iliac bone grafts. *Journal of Oral and Maxillofacial Surgery* **42**: 172-176.
- Holmes, K., Roberts, O.L., Thomas, A.M. & Cross, M.J. (2007) Vascular endothelial growth factor receptor-2: structure, function, intracellular signalling and therapeutic inhibition. *Cellular Signalling* **19**: 2003-2012.
- Iizuka, T., Smolka, W., Hallermann, W. & Mericske-Stern, R. (2004) Extensive augmentation of the alveolar ridge using autogenous calvarial split bone grafts for dental rehabilitation. *Clinical Oral Implants Research* **15**: 607-615.
- Ishii, S., Shishido, F., Miyajima, M., Sakuma, K., Shigihara, T., Tameta, T., Miyazaki, M. & Hashimoto, N. (2010) Imaging findings at the donor site after iliac crest bone harvesting. *The Journal of Skeletal Radiology* **39**: 1017-1023.
- Kamba, T., Tam, B.Y., Hashizume, H., Haskell, A., Sennino, B., Mancuso, M.R., Norberg, S.M., O'Brien, S.M., Davis, R.B., Gowen, L.C., Anderson, K.D., Thurston, G., Joho, S., Springer, M.L., Kuo, C.J. & McDonald, D.M. (2006) VEGF-dependent plasticity of fenestrated capillaries in the normal adult microvasculature. *American Journal of Physiology - Heart and Circulatory Physiology* **290**: H560-H576.
- Klijn, R.J., Meijer, G.J., Bronkhorst, E.M. & Jansen, J.A. (2010) Sinus floor augmentation surgery using autologous bone grafts from various donor sites: a meta-analysis of the total bone volume. *Tissue Engineering Part B: Reviews* **16**: 295-303.
- Lu, M. & Rabie, A.B.M. (2004) Quantitative assessment of early healing of intramembranous and endochondral autogenous bone grafts using micro-computed tomography and Q-win image analyzer. *Journal of Oral and Maxillofacial Surgery* **33**: 369-376.
- Mangano, C., Scarano, A., Iezzi, G., Orsini, G., Perrotti, V., Mangano, F., Montini, S., Piccirilli, M. & Piattelli, A. (2006) Maxillary sinus augmentation using an engineered porous hydroxyapatite: a clinical, histological, and transmission electron microscopy study in man. *Journal of Oral Implantology* **32**: 122-131.
- Misch, C.E., Chiapasco, M. & Jensen, O.T. (2006) Indications for and Classification of Sinus Bone Grafts. In: Jensen, O.T. Ed. *The Sinus Bone Graft*. Chicago: Quintessence Publishing Co.
- Nguyen, M., Arkell, J. & Jackson, C.J. (2001) Human endothelial gelatinases and angiogenesis. *The International Journal of Biochemistry & Cell Biology* **33**: 960-970.
- Nkenke, E., Weisbach, V., Winckler, E., Kessler, P., Schultze-Mosgau, S., Wiltfang, J. & Neukam, F.W. (2004) Morbidity of harvesting of bone grafts from the iliac crest for preprosthetic augmentation procedures: a prospective study. *Journal of Oral and Maxillofacial Surgery* **33**: 157-163.
- Norton, M.R. & Gamble, C. (2001) Bone classification: an objective scale of bone density using the computerized tomography scan. *Clinical Oral Implants Research* **12**: 79-84.
- Ozaki, W. & Buchman, S.R. (1998) Volume maintenance of onlay bone grafts in the craniofacial skeleton: micro-architecture versus embryologic origin. *Plastic and Reconstructive Surgery* **102**: 291-299.
- Pedrosa, W.F., Okamoto, R., Faria, P.E., Arnez, M.F., Xavier, S.P. & Salata, L.A. (2009) Immunohistochemical, tomographic and histological study on onlay bone graft remodeling. Part II: calvarial bone. *Clinical Oral Implants Research* **20**: 1254-1264.
- Schaaf, H., Lendeckel, S., Howaldt, H.P. & Streckbein, P. (2010) Donor site morbidity after bone harvesting from the anterior iliac crest. *Oral Surgery, Oral Medicine, Oral Pathology, Oral Radiology & Endodontics* **109**: 52-58.
- Sivarajasingam, V., Pell, G., Morse, M. & Shepherd, J.P. (2001) Secondary bone grafting of alveolar clefts: a densitometric comparison of iliac crest and tibial bone grafts. *Cleft Palate-Craniofacial Journal* **38**: 11-14.
- Smolka, W., Eggensperger, N., Carollo, V., Ozdoba, C. & Iizuka, T. (2006) Changes in the volume and density of calvarial split bone grafts after alveolar ridge augmentation. *Clinical Oral Implants Research* **17**: 149-155.
- Tessier, P. (1982) Autogenous bone grafts taken from the calvarium for facial and cranial applications. *Clinical Plastic Surgery* **9**: 531-538.
- Tetè, S., Vinci, R., Zara, S., Zizzari, V., Cataldi, A., Mastrangelo, F., Mortellaro, C. & Gherlone, E. (2010) Atrophic jaw reconstruction by means of calvarial bone graft: long-term results. *Journal of Craniofacial Surgery* **21**: 1147-1152.
- Tetè, S., Zara, S., Vinci, R., Zizzari, V., Di Tore, U., Mastrangelo, F., Cataldi, A. & Gherlone, E. (2009) Vascular endothelial growth factor and e-nitric oxide synthase-mediated regenerative response occurring upon autologous and heterologous bone grafts. *International Journal of Immunopathology and Pharmacology* **22**: 1105-1116.
- Thorwarth, M., Srour, S., Felszeghy, E., Kessler, P., Schultze-Mosgau, S. & Schlegel, K.A. (2005) Stability of autogenous bone grafts after sinus lift procedures: a comparative study between anterior and posterior aspects of the iliac crest and an intraoral donor site. *Oral Surgery, Oral Medicine, Oral Pathology, Oral Radiology & Endodontics* **100**: 278-284.
- Umar, S. & van der Laarse, A. (2010) Nitric oxide and nitric oxide Synthase isoforms in the normal, hypertrophic, and failing heart. *Molecular Cell Biochemistry* **333**: 191-201.
- Winder, T. & Lenz, H.J. (2010) Vascular endothelial growth factor and epidermal growth factor signaling pathways as therapeutic targets for colorectal cancer. *Gastroenterology* **138**: 2163-2176.
- Wong, R.W.K. & Rabie, A.B.M. (1999) A quantitative assessment of the healing of intramembranous and endochondral autogenous bone grafts. *European Journal of Orthodontics* **21**: 119-126.



Copyright of Clinical Oral Implants Research is the property of Wiley-Blackwell and its content may not be copied or emailed to multiple sites or posted to a listserv without the copyright holder's express written permission. However, users may print, download, or email articles for individual use.

## Original article

## Macroscopic and microscopic evaluation of a new implant design supporting immediately loaded full arch rehabilitation

Stefano Tetè, MD, DDS<sup>1</sup>  
 Vincenzo Zizzari, DDS<sup>2</sup>  
 Alessandro De Carlo, DDS<sup>1</sup>  
 Bruna Sinjari, DDS<sup>1</sup>  
 Enrico Gherlone, MD, DDS<sup>3</sup>

<sup>1</sup> Department of Medical, Oral and Biotechnological Sciences, "G. d'Annunzio" University, Chieti, Italy

<sup>2</sup> Department of Drug Science "G. d'Annunzio" University, Chieti, Italy

<sup>3</sup> Department of Oral Sciences, "Vita-Salute San Raffaele" University, Milano, Italy

### Corresponding author:

Stefano Tetè, MD, DDS  
 Department of Medical, Oral and Biotechnological Sciences, "G. d'Annunzio" University, Chieti, Italy  
 e-mail: tete@unich.it

### Summary

The purpose of this study is to evaluate macroscopic and microscopic appearance of a new implant design, with particular emphasis given to the type of prosthesis connection. Two dental implants of the same type (Torque Type®, WINSIX®, BioSAFin. S.r.l. - Ancona, Italy), with sandblasted and acid etched surfaces (Micro Rough Surface®), but differing from each other for the prosthesis connection system, were examined by scanning electron microscope (SEM) analysis at different magnifications: TTI implant, with a hexagonal internal connection, and TTX implant, with a hexagonal external connection. SEM analysis showed that the Torque Type® implant is characterized by a truncated cone shape with tapered tips. The implant body showed a double loop thread and double pitch with blunt tips. For both types of connection, the implant neck was 0.7 mm in height with a 3% taper. This implant design may be able to guarantee osteotomic properties at the time of insertion in a surgical site suitably prepared, a facilitated screwing, thanks to the thread pitch and to the broad and deep draining grooves, thereby ensuring a good primary stability. The different connection design appears defined and precise, in order to ensure a good interface between the fixture and the prosthetic components. Therefore, this design appears to be particularly suitable in cases where a good primary stability is necessary and a precise

coupling between endosseous and prosthetic components, as it allows an easy insertion of the fixture even in conditions of reduced bone availability, and in cases of immediately loaded full-arch rehabilitations.

**Key words:** dental implant, Scanning Electron Microscope (SEM), implant connection.

### Introduction

Osseointegrated implantology, thanks to many studies, is now considered a surgical discipline with proven effectiveness. Success in implant dentistry consists in getting a good rate of integration between implant and host bone, which defines a good osseointegration according to the principles initially introduced by Branemark and subsequently developed by numerous studies over the years (1-3).

The implant design is a key factor to achieve good primary stability. It should be designed to guarantee the establishment of a direct connection between bone tissue and implant surface during the early stages of the healing process, without the interposition of fibrous tissue, as well as to achieve an even distribution of the loads which, through the masticatory system, are transmitted to the peri-implant bone tissue whilst chewing (4,5).

There are two fundamental aspects of implant design: the macro-structure, characterized by the shape of the body, the characteristics of the neck and the apex, by the design, by the number and pitch of the thread, and the microstructure, characterized by the surface treatment. In addition, there is also the good accuracy of the prosthetic components (6-8).

It is known that differences in implant shapes induce significant changes in force distribution on the surrounding bone (9). The macroscopic geometric pattern of a dental implant can assume a cylindrical or conical form. For some years some companies have marketed the tapered form, with the aim of combining the advantages of both designs. A tapered implant creates the basis for an excellent primary stability by gradually allowing thin ridge expansion and determining the least stress possible at the interface with the surrounding bone (10,11). The design of the implant neck, or crestal module, has undergone considerable evolution in recent years. The implant neck represents the transosseous area of the implant body where the highest concentration of mechanical stresses are evinced and where the transition between the hard tissue and soft tissue support occurs. Discriminating elements of the crestal module could be

*Implant design for full arch rehabilitation*

identified in the geometrical design and in the surface type. The possible geometric profiles of the implant neck are essentially three: straight walls, diverging walls and converging walls. Despite the diverging walls type seeming to be the best form, as it can provide a slightly higher primary stability after the implant insertion, from the clinical point of view the behavior of the bone before and after the load is not dissimilar between the three geometric figures. In fact, an aspect commonly observed at the level of the crestal module is the different bone level before and after the occlusal loading. Before loading, if the implant was positioned so that the prosthetic platform is at the level of the crestal bone, there will always be a clinical situation where the bone covers the entire implant neck. After application of the load there is invariably a vertical bone loss, the level of which is located in correspondence of the first thread. All this takes place independently from the geometrical shape and the level of the first thread.

The crestal module height was reduced over time by various manufacturers, until today, when the height of the smooth collar is reduced to less than 2 mm.

The morphology of the crestal module evolved in the same way - from a smooth surface to a treated surface with microthreads for increased stability of bone in the coronal zone, to favour aesthetics and peri-implant health (12).

The use of the smooth neck arises from the necessity to limit the plaque retention at the border zone between the implant, bone and soft tissue. The presence of micro retentions at the level of the crestal module is designed to adequately dissipate forces that are expressed at the cervical area of the bone-implant interface in the presence of occlusal stress, in all implant types, thus allowing to maintain the height of the bone spikes in accordance with the law of Wolff (13), a phenomenon that in the presence of a smooth neck does not happen.

As regards the design and the pitch of the threads, these must be designed to maximize the transmission of forces between the implant and surrounding bone tissue, and to correctly distributed stress arising between the bone interface and the implant (14). Their main role is to increase primary stability and extend the available surface of the implant for bone contact.

Among the various thread designs, the V-shaped threads and the broader square threads have been shown to generate less stress and to better distribute the loading forces compared to the thin threads and tapered apex threads (15). The phenomenon is best appreciated in the bone marrow, while no difference have been found in cortical bone.

Another important factor necessary to achieve success in implantology is represented by the surface properties of the material used (16). The micro-topography of the implant surface is able to affect the percentage of BIC (Bone-to-Implant Contact) and the cellular response of the host tissue (17). The treated surfaces stimulate osteoblast proliferation, as demonstrated by the increased expression of biological markers, which transposes into an increase of osteogenesis, thus assuming an impor-

tant role regarding the long-term survival of the osseointegrated implants (18).

The titanium surface can be prepared with different techniques in order to obtain an optimal degree of roughness of the surface, as it has been shown that the wider the functional surface is in contact with the bone, the better the support for the prosthesis (19,20).

The rough implant surfaces determine a slightly better bone tissue response in quantitative terms of bone-implant contact percentage (21-23). The purpose of the surface treatment is to increase the contact area between the bone and the implant, thus improving the osseointegration. Even with only the threads, the resistance degree to tensile forces and compression is greater than smooth implants not threaded, and the presence of microretentions on the surface of the fixture allows to increase the tensile and torsion strength of the implant. In addition, some authors have demonstrated how macrophages, epithelial cells and osteoblasts, have a high tropism against rough surfaces (24,25).

In order to obtain a surface topography able to promote the process of osseointegration, various surface treatments have been tried out, such as sandblasting (26), acid etching (27), combined treatment of blasting and etching (28), surface coating with micro-granules of hydroxyapatite (29) or particles of titanium oxide (30), or electrochemical deposition (31). Recent researches highlighted how the micro-roughness obtained by blasting and acid etching is compatible with best clinical and histological results.

Several options also affect the types of connections between the endosseous fixture and implant prosthetic components.

External hexagonal connection was the first connection system used in implantology which was ideated by Branemark only as coupling mechanism to easily guide the stump insertion; its function was then expanded to become a real anti-rotation mechanism. The interface and the tightening screw are subject to very high masticatory loads, subjecting the screw to insidious lateral bending forces, tilting and elongation that may mobilize it (32).

Of the internal connections, the most widely used are internal hexagonal, internal octagonal, conical screw and Morse connections. The internal connections have shown an increased stability, better mechanical stability and resistance to lateral forces than external ones.

The aim of this study is to describe the macroscopic and microscopic appearance of a new implant design, with particular emphasis on the type of prosthesis connection.

**Materials and Methods**

In this study, the macroscopic and microscopic appearance of a new implant design was evaluated, with particular emphasis on the type of prosthetic connection. Two dental implants of the same type (Torque Type®, WINSIX®, BioSAFin S.r.l., Ancona, Italy), with sandblast-

S. Tetè et al.

ed and acid etched surfaces (Micro Rough Surface®), but differing from each other for the prosthesis connection system, were examined by scanning electron microscope (SEM) analysis at different magnifications: TTI implant (Torque Type® Implant I), with a hexagonal internal connection, and TTX implant (Torque Type® Implant X), with a hexagonal external connection.

The macrostructure of the geometrical design of the different segments of the fixture, the characteristics of the prosthetic connection, and the microstructure of the implant surface were analyzed by Scanning Electron Microscope (Zeiss EVO-50, Cambridge, UK). Electron acceleration potential was kept between 15 and 25 kV, and the working distance kept between 9 and 12 mm, according to the different requirements and types of samples.

## Results

At SEM analysis, both TTI and TTX implants were characterized by a truncated cone shape, with a tapered apex (Fig. 1).

Both implants showed a reduced crestal module represented by a smooth neck 0.7 mm height and 3% taper. The implant-prosthetic connection was characterized by a very deep lodging for the fixing screw, with a hexagonal form with a double parallel type connection (Fig. 2). The TTX implant includes a crestal module with a smooth surface, dominated by the external hexagonal connection module (Fig. 3). At SEM analysis, the neck surface seemed completely smooth and well polished; at 3000x magnification there were signs of lathing, typical of machined surfaces (Fig. 4).

With regard to the implant body, this was equipped with a double thread and double pitch. The thread pitch was 0.60 mm. The threads are "V" shaped with rounded tips and slopes inclined at approximately 45°.

The main thread has a step along its apical side which forms the smaller thread (Fig. 5). The depth of the main threads is 0.375 mm, as long as the depth of the secondary threads is 0.125 mm. The main thread width ranges from 0.07 mm at the top to 0.50 mm at the base, while




Figure 1 - SEM visualization of WINSIX® TT and TTX implants. It may be noticed the truncated shape of the fixture with tapered apex.




Figure 2 - SEM visualization of a TT implant-prosthetic connection with a deep lodging of hexagonal form and smooth crestal module.




Figure 3 - SEM visualization of a TTX external implant-prosthetic connection constitute of smooth crestal module dominated by an hexagonal connection.




Figure 4 - SEM visualization of the machined neck surface (149x magnification).

### *Implant design for full arch rehabilitation*

the distance between each thread is 0.10 mm at the base and 0.53 mm at the peak. The implant shape is maintained constant along the entire implant body.

The apical portion shows a bevel apex, nearly flat, characterized by broad and deep drainage furrow, with increasing size apically (Fig. 6).

The surface of the implant body, defined by the manufacturer of Micro Rough Surface®, and realized by a subtraction process for etching and sandblasting, was regularly distributed along the surface (low magnification) (Fig. 7). In the apical portion, at 1980x magnification, it can be seen how the rough aspect of this surface recalls that typical of tooth enamel after acid etching. At higher magnification the surface appears to be characterized by small depressions and elevations of 2-4 µm (Fig. 8).

### **Discussion**

In scientific literature it is widely reported that the macroscopic structure and the surface characteristics of




Figure 5 - SEM visualization of the continuous step that forms the smaller threads from the main threads (192x magnification).




Figure 6 - SEM visualization of the bevel apex characterized by furrows drain.

dental implants play a decisive role in obtaining success in osseointegrated implantology (33). In particular, the geometrical design of the threads, their position and




Figure 7 - SEM visualization of the Micro Rough Surface® regularly distributed (721x magnification).




Figure 8A




Figure 8B - SEM visualization of the Micro Rough Surface® at higher magnification (A:1980x; B: 7330x).



S. Tetè et al.

their pitch along the implant body determine a different response to functional loads and transmission of those forces to the surrounding bone tissue (34). The implant design plays an even more important role if surgical protocols providing immediate loading are adopted. It is known that in the initial stages following implant insertion, and especially after immediate loading, implant stability should be guaranteed by mechanical relationship between the fixture and the bone tissue rather than a biological bone integration. Therefore, the percentage of bone-implant contact and the friction that is obtained during the insertion play an important role in the mechanical behaviour of immediate loaded prosthetic implants.

The tapered shape of the implant fixtures TTI and TTX ensures a gradual expansion of the thin crests during the insertion phase of the fixture by determining the least possible stress to the surrounding bone. This factor is of fundamental importance in cases of reduced bone availability, where preserving cortical bone tissue is appropriate, as well as carrying out a three-dimensional expansion and compaction of the walls of the newly formed alveolar bone. The implant type analyzed showed a thread design that allows to release more force and give easy access to good primary stability. The thread geometry contributes to obtaining primary stability, responsible for the biomechanical behaviour of the bone-implant interface after the healing process (35).

The thread height is defined as the distance between the major and the minor diameter of the coil. A shallow thread depth, as well as those present in the Torque Type implants, favors insertion. In fact, although deeper threads ensure an increase of the surface and represent an advantage in areas of low density bone and high occlusal stress, on the other hand shallow threads allow an easy insertion in alveolar ridges with more dense bone without the need to perform tapping before the implant insertion (36).

In a study conducted by finite element analysis, it was demonstrated that the height of the thread more than its thickness is able to influence primary stability, and in particular threads with a height exceeding 0.44 mm is able to provide excellent biomechanical response when inserted into bone tissue of medium or low density with immediate loading (37).

In addition, these threads have an osteotomic effect, allowing to pack the peri-implant bone using a surgical technique that provides preparation of the implant site according to "press-fit" protocol. *In vitro* studies showed that in case of poor quality bone, such as in the posterior maxilla, implants with chamfer thread design produced lateral compressive forces which increased the bone-implant contact and consequently improved the primary stability (38). This factor is very important in case of immediate load technique of several implants, as in the case of rehabilitation providing the immediate solidification using bar techniques (Just on 4° and Just on 6°). Furthermore, as already demonstrated, under vertical load the presence of threads with bevel peak allows a reduction of divergent forces, thereby reducing the stress at the bone implant interface (39).

TTi and TTX implants also have a double loop thread, a principal and a secondary smaller one, due to the presence of a groove on the apical side of the main thread. An implant with double coil has an insertion speed twice as fast compared to an implant with a single coil. Some studies report that implants with a high number of loop threads and a reduced pitch possess a high percentage of BIC, due to increased surface area (40). Some studies showed how the ideal threads pitch to obtain a good primary stability, and an optimal distribution of the stress should be not more than 0.8 mm (41). A thread pitch less than this measurement was seen to positively influence the load distribution along the peri-implant bone walls, accompanied by a smaller crestal bone resorption (42). The osteotomic effect at the implant site during the implant screwing phase is further achieved through the tapered apex and the self-tapping implant design with the cutting apical portion. Moreover, the presence of deep grooves at the apical level, constituting an anti-rotational system, is necessary for bone chip collection and clot discharge during the screwing phase (43).

With regard to the crestal module, the manufacturer's choice to use a smooth neck reflects the concept to guarantee the minimum plaque retention, allowing to obtain an optimal integration with the bone tissue (44).

The constant size of the internal hexagon for the various implant diameters allows the use of few components, making the prosthetic steps and the eventual choice to adopt the Platform Switching technique easier.

The connection type through a long screw, ensures high connection stability, with considerable reduction of the stress between abutment and implant, and a greater contact surface which limits the microcirculation of biological fluids (45).

Another important factor analyzed was the implant surface, because the surface of the fixture is the only part to come into direct contact with the host tissue, influencing cellular and biochemical responses, acting also on the stability between bone and implant (46). SEM analysis allowed to assess the degree of roughness present on the implant body and on the apical portion, typical of a sandblasted and acid etched surface with signs of streaks, depressions and elevations highly variable in size and shape.

Recent clinical studies showed how an implant with a rough surface can be loaded before the traditional treatment protocols (47). Some studies showed that dental implants with low roughness values, as for the implant with machined surface, can promote the formation of fibrous tissue around the implant, reduce the percentage of bone-implant contact and show a lower resistance to the removal than implants with rough surfaces (48).

The implants with sandblasted and etched surfaces, for the presence of more regular micro-roughness produced by the etching treatment, seem to favor the bone healing process, also by the marked incidence of the increased cytokine production, such as osteogenic prostaglandin E2 (PGE<sub>2</sub>), and transforming growth factor-beta (TGF-β1), with the latter less sensitive to surface roughness than in the case of PGE<sub>2</sub> (49). According to some

*Implant design for full arch rehabilitation*

authors, this treatment promotes osseointegration due to an increase in initial cell anchorage by osteoblasts (50). All in all, the results obtained prove that dental implants of a design that complies with the results of research regarding the macrostructural aspect and the microstructural surface topography, if used according to correct surgical and prosthetic protocols assure safe and predictable results.

**References**

1. Branemark PI, Hansson BO, Adell R et al. Osseointegrated implants in the treatment of the edentulous jaw. Experience from a 10-year period. *Scand J Plast Reconstr Surg Suppl* 1977; 16: 1-132.
2. Lekholm U, Zarb GA. *Tissue integrated prostheses: osseointegration in clinical dentistry*. Chicago: Branemark, Zarb & Albrektsson Eds.; 1985: 87-102.
3. Albrektsson T, Branemark PI, Hansson HA et al. Osseointegrated titanium implants. Requirements for ensuring a long-lasting, direct bone - to - implant anchorage in man. *Acta Orthop Scand* 1981; 52: 155-170.
4. Bozkaya D, Muftu S, Muftu A. Evaluation of load transfer characteristics of five different implants in compact bone at different load levels by finite elements analysis. *J Prosthet Dent*. 2004 Dec; 92(6): 523-30.
5. Brunski JB. Biomaterials and biomechanics in dental design. *Int J Oral Maxillofac Implants* 1988; 3(2) 85-97.
6. Siegele D, Soltesz U. Numerical investigations of the influence of implant shape on stress distribution in the jaw bone. *Int J Oral Maxillofac Implants* 1989; 4: 333-340.
7. Weinländer M, Neugebauer J, Lekovic V et al. Mechanical stability and histological analysis of immediate loaded implants with various surfaces and design. *Clin Oral Impl Res* 2003; 14: 34.
8. Steigenga JT, al-Shammari KF, Nociti FH, Misch CE, Wang HL. (2003) Dental implant design and its relationship to long-term implant success. *Implant Dentistry* 12: 306-317.
9. Chun HJ, Cheong SY, Han JH, Heo SJ, Chung JP, Rhyu IC, Choi YC, Baik HK, Ku Y, Kim MH. (2002) Evaluation of design parameters of osseointegrated dental implants using finite element analysis. *Journal of Oral Rehabilitation* 29: 565-574.
10. Dos Santos MV, Elias CN, Cavalcanti Lima JH. The effects of superficial roughness and design on the primary stability of dental implants. *Clin Implant Dent Relat Res*. 2011 Sep; 13(3): 215-23.
11. Moon SH, Um HS, Lee JK, Chang BS, Lee MK. The effect of implant shape and bone preparation on primary stability. *J Periodontal Implant Sci*. 2010 Oct; 40(5): 239-43.
12. Hermann JS, Jones AA, Bakaeen LG, Buser D, Schoolfield JD, Cochran DL. Influence of a machined collar on crestal bone changes around titanium implants: a histometric study in the canine mandible. *J Periodontol*. 2011 Sep; 82(9): 1329-38. Epub 2011 Apr 12.
13. Hansson S. The implant neck: smooth or provided with retention elements. A biomechanical approach. *Clin Oral Implants Res*. 1999 Oct; 10(5): 394-405.
14. Chun HJ, Cheong SY, Han JH, Heo SJ, Chung JP, Rhyu IC, Choi YC, Baik HK, Ku Y, Kim MH. Evaluation of design parameters of osseointegrated dental implants using finite element analysis. *eJ Oral Rehabil*. 2002 Jun; 29(6): 565-74.
15. Hansson S, Werke M. The implant thread as a retention element in cortical bone: the effect of thread size and thread profile: a finite element study. *J Biomech*. 2003 Sep; 36(9): 1247-58.
16. Gorrieri O, Fini M, Kyriakidou K, Zizzi A, Mattioli-Belmonte M, Castaldo P, De Cristofaro A, Natali D, Pugnali A, Biagini G. In vitro evaluation of bio-functional performances of Ghimas titanium implants. *Int J Artif Organs*. 2006 Oct; 29(10): 1012-20.
17. Tetè S, Mastrangelo F, Quaresima R, Vinci R, Sammartino G, Stupia L, Gherlone E. Influence of novel nano-titanium implant surface on human osteoblast behavior and growth. *Implant Dent*. 2010 Dec; 19(6): 520-31.
18. Ivanovski S. Osseointegration—the influence of implant surface. *Ann R Australas Coll Dent Surg*. 2010 Mar; 20: 82-5. Review.
19. Buser D, Schenk RK, Steinemann S, Fiorellini JP, Fox CH, Stich H. Influence of surface characteristics on bone integration of titanium implants. A histomorphometric study in miniature pigs. *J Biomed Mater Res* 1991; 25: 889-902.
20. Lazzara RJ, Testori T, Trisi P, Porter SS, Weinstein RL. A human histologic analysis of osseotite and machined surface using implants with 2 opposing surfaces. *Int J Perio Rest Dent* 1999;19: 117-129.
21. Wennerberg A et al. "Bone tissue response to commercially pure titanium implants blasted with fine and coarse particles of aluminium oxide" *Int. J. Oral Maxillofac. Impl.* 1996; 11: 38-45.
22. Piattelli A et al. "Direct bone formation on sandblasted titanium implant: an experimental study" *Biomaterials* 1996; 17 (10): 1015-8.
23. Vercaigne S et al. "Bone healing of titanium plasma sprayed and hydroxylapatite-coated oral implants" *Clin. Oral Impl. Res.* 1998; 9: 261-71
24. Fossombroni G. "Tornitura a secco: un successo". *Macchine utensili*, 124-126,1999.
25. Brunette DM. "The effects of implant surface topography on the behavior of cells". *Int. J. Oral Maxillofac. Implants*, 3: 231-246, 1988.
26. Wennerberg A, Albrektsson T, Johansson C, Andersson B. An experimental study of turned and grit-blasted screw-shaped implants with special emphasis on effects of blasting material and surface topography. *Biomaterials* 1996; 17: 15-22.
27. Buser D, Nydegger T, Oxland T, Cochran D, Schenk R, Hirt HP et al. Interface shear strength of titanium implants with a sandblasted and acid-etched surface : A biomechanical study in the maxilla of miniature pigs. *J Biomed Mater Res* 1999; 45: 75-83.
28. Cochran D, Oates T, Morton D, Jones A, Buser D, Peters F. *Clinical Field Trial Examining an Implant With a Sand-Blasted, Acid-Etched Surface* *J Periodontol*. 2007 Jun; 78(6) :974-982.
29. Krauser J. Hydroxylapatite-coated dental implants. Biologic retention and surgical technique. *Dent Clin N Amer* 1989; 33: 879.
30. Nasatzky E, Gultchin J, Schwartz Z. The role of surface

S. Tetè et al.

- roughness in promoting osteointegration, Refuat Hapeh Vehashinayim. 2003 Jul; 20(3): 8-19, 98.
31. Tetè S, Mastrangelo F, Traini T, Vinci R, Sammartino G, Marenzi G, Gherlone E. A macro- and nanostructure evaluation of a novel dental implant. *Implant Dent.* 2008 Sep; 17(3): 309-20.
  32. Pita MS, Anchieta RB, Barão VA, Garcia IR Jr, Pedrazzi V, Assunção WG. Prosthetic platforms in implant dentistry. *J Craniofac Surg.* 2011 Nov; 22(6): 2327-31.
  33. Esposito M, Coulthard P, Thomsen P, Worthington HV. The role of implant surface modifications, shape and material on the success of osseointegrated dental implants. A Cochrane systematic review. *Eur J Prosthodont Restor Dent.* 2005 Mar; 13(1): 15-31. Review
  34. Weinländer M, Neugebauer J, Lekovic V, Zoeller JE, Vasilic N, Plenik jr H. Mechanical stability and histological analysis of immediate loaded implants with various surfaces and design. Abstract: *Clin Oral Impl Res* 2003; 14 (4): x, No. 34.
  35. L. Baggi, I. Cappelloni, F. Maceri, G. Vairo. Stress-based performance evaluation of osseointegrated dental implants by finite-element simulation, *Simul. Model. Pract. Th.* 16 (2008) 971-987.
  36. Misch CE. Implant design considerations for the posterior regions of the mouth . *Contemporary Implant Dentistry* (1999 ) 8: 376-386.
  37. Ao J, Li T, Liu Y, Ding Y, Wu G, Hu K, Kong L. Optimal design of thread height and width on an immediately loaded cylinder implant: a finite element analysis. *Comput Biol Med.* 2010 Aug; 40(8): 681-6.
  38. Kim DR, Lim YJ, Kim MJ, Kwon HB, Kim SH. Self-cutting blades and their influence on primary stability of tapered dental implants in a simulated low-density bone model: a laboratory study. *Oral Surg Oral Med Oral Pathol Oral Radiol Endod.* 2011 Nov; 112(5): 573-80.
  39. Misch CE, Strong T, Bidez MW. (2008) Scientific rationale for dental implant design. In: Misch CE, ed. *Contemporary Implant Dentistry*. 3 edition, 200-229. St. Louis: Mosby.
  40. Roberts WE, Smith RK, Zilberman Y, Mozsary PG, Smith RS. Osseous adaptation to continuous loading of rigid endosseous implants. *Am J Orthod.* 1984 Aug; 86(2): 95-111.
  41. Ma P, Liu HC, Li DH, Lin S, Shi Z, Peng QJ. [Influence of helix angle and density on primary stability of immediately loaded dental implants: three-dimensional finite element analysis]. *Zhonghua Kou Qiang Yi Xue Za Zhi.* 2007 Oct; 42(10): 618-21.
  42. Abuhussein H, Pagni G, Rebaudi A, Wang HL. The effect of thread pattern upon implant osseointegration. *Clin Oral Implants Res.* 2010 Feb; 21(2): 129-36.
  43. Chong L, Khocht A, Suzuki JB, Gaughan J. Effect of implant design on initial stability of tapered implants. *J Oral Implantol.* 2009; 35(3): 130-5.
  44. Heinemann F, Bourauel C, Hasan I, Gedrange T. Influence of the implant cervical topography on the crestal bone resorption and immediate implant survival. *J Physiol Pharmacol.* 2009 Dec; 60 Suppl 8: 99-105.
  45. Lavrentiadis G, Yousef H, Luke A, Flinton R. Changes in abutment screw dimensions after off-axis loading of implant-supported crowns: a pilot study. *Implant Dent.* 2009 Oct; 18(5): 447-53.
  46. Lossdorfer S, Schwartz Z, Wang L, Lohmann CH, Turner JD, Wieland M, Cochran DL, Boyan BD. Microrough implant surface topographies increase osteogenesis by reducing osteoclast formation and activity *J Biomed Mater Res A.* 2004 Sep 1; 70(3): 361-9.
  47. Grassi S, Piattelli A, de Figueiredo LC et al. Histologic evaluation of early human bone response to different implant surfaces. *J Periodontol* 2006; 77: 1736-1743.
  48. Wennerberg A, Albrektsson T, Andersson B et al. A histomorphometric and removal torque study of screw-shaped titanium implants with three different surface topographies. *Clin Oral Implan Res* 1995; 6: 24-30.
  49. Boyan BD, Batzer R, Kieswetter K, Liu Y, Cochran DL, Szmuckler-Moncler S, Dean DD, Schwartz Z. Titanium surface roughness alters responsiveness of mg63 osteoblast-like cells to  $1\alpha,25\text{-(oh)}_2\text{d}_3$ . *J Biomed Mater Res* 1998; 39: 77-85.
  50. Cochran D, Oates T, Morton D, Jones A, Buser D, Peters F. Clinical Field Trial Examining an Implant With a Sand-Blasted, Acid-Etched Surface *J Periodontol.* 2007 Jun; 78(6): 974-982.

## CRESTAL BONE REMODELING AROUND PLATFORM SWITCHED, IMMEDIATELY LOADED IMPLANTS PLACED IN SITES OF PREVIOUS FAILURES

A. QUARANTA<sup>1</sup>, A. CICONETTI<sup>2</sup>, L. BATTAGLIA<sup>3</sup>, M. PIEMONTESE<sup>1</sup>, G. POMPA<sup>2</sup>  
and I. VOZZA<sup>2</sup>

<sup>1</sup>Dental School and Graduate Master in Periodontics, Università Politecnica delle Marche, Ancona, Italy;

<sup>2</sup>Dental School, "Sapienza" University of Rome, Rome, Italy; <sup>3</sup>Private Practice, Rome, Italy

Received April 12, 2012 – Accepted July 30, 2012

The possibility to insert immediately-loaded implants in post-extraction sites where previously inserted implants had failed and had never received a prosthesis has not been sufficiently studied to the present day. Only few articles in the literature address this problem. The aim of the present study was to evaluate crestal bone remodeling around implants with a platform-switched design inserted and loaded immediately after the failure of the previous implants. This study has a follow-up of 36 months. Failed implants that had never received a prosthesis have been removed in 68 patients. In the present study 10 patients, whose bone crest measured at least 8 mm in width, were selected and 16 immediately loaded implants with a platform-switched design and a sandblasted and acid etched SLA surface, (Winsix®, Biosaf srl, Italy) were placed. Statistically significant differences were observed in crestal bone remodeling between 12 and 36 months ( $p < 0.05$ ) and between 24 and 36 months ( $p < 0.001$ ), although no statistically significant differences were found between 12 and 24 months ( $p > 0.05$ ). The values of periodontal indices have sometimes been borderline, although they returned normal later on. The cumulative success-rate of all the 16 implants inserted was of 93.75%, while the survival rate was 100%. Results show that immediately loaded platform-switched implants are a practicable solution for the rehabilitation of sites of early failed implants.

Many studies describe the success of implants in time (1-4), but only a small number investigate the causes of implant failure, while studies describing the possibility to insert new implants used for a fixed prosthetic rehabilitation in the site of implants previously failed, (for various reasons) are even fewer (5-6). Very often in the past, patients who had suffered implant failure were treated with an overdenture to avoid additional implant surgery which was not predictable at that time. Only one article treated the insertion of implants in sites where previously inserted implants had failed, but the surgery was performed after 9 to 12 months after the removal of the failed implants (7). Today clinicians may choose between various implant designs, such as macro-implants, short implants, which allow implant insertion where bone volume is insufficient. It has been proven that in conventional dental implants, consisting in a fixture and

an abutment, the peri-implant bone resorbs between 1 to 2 mm after -prosthetic loading, when the implant platform is positioned at a crestal level (8). Some investigators have demonstrated that when the implant platform is positioned at a sub-crestal level, bone resorption increases (9). According to certain authors, crestal bone remodeling is caused by masticatory stress (10). Another hypothesis suggests that soft tissue inflammation may cause the crestal bone to resorb (11). Some researchers have demonstrated that in all two-piece implant systems there is a gap between the implant and the abutment. The gap measures approximately 10  $\mu$ m and is responsible for the formation of an inflammatory infiltrate (12). A group of researchers has proven that the inflammatory effects of the implant-abutment gap are independent from the position of the implant platform in relation to the crest. In fact, inflammation appears when the implant is positioned

*Key words: bone maintenance, immediate loading, platform switching, diagnostic imaging, dental implants, radiograph*

Mailing address: Alessandro Quaranta, DDS, PhD.  
Division of Periodontology, School of Dentistry  
and Post Graduate Master in Periodontics,  
Università Politecnica delle Marche,  
Polo Murri, Room #47. Via Tronto 10, 60020,  
Torrette di Ancona, Ancona, Italy  
Tel.: +39 3381770918 e-mail: s40ale@gmail.com

115 (S)

1721-727X (2012)  
Copyright © by BIOLIFE, s.a.s.  
This publication and/or article is for individual use only and may not be further  
reproduced without written permission from the copyright holder.  
Unauthorized reproduction may result in financial and other penalties  
DISCLOSURE: ALL AUTHORS REPORT NO CONFLICTS OF  
INTEREST RELEVANT TO THIS ARTICLE.

both above the crestal level and below crestal level and it is deemed responsible of the crestal bone resorption (13-14). It's important to underline that inflammatory processes caused by the micro gap and noted by various investigators have been observed on implants restored with matching-diameter abutments. Lazzara et al. introduced the platform-switched prosthetic modality, by connecting large diameter implants to narrower abutments (15). Periodic radiographic controls of platform-switched implants showed a reduced peri-implant bone resorption if compared with that observed around dental implants restored with matching diameter abutments; the reduced bone resorption is attributed to the lateral shifting of the infiltrated tissue, which is moved away from the crest by a non-infiltrated connective tissue adjacent to the implant-abutment junction (16-17). The objective of the present study was to evaluate whether valid osseointegration and a reduced crestal bone remodeling may be obtained when platform-switched implants are inserted in the sites of previously early failed implants, which had never received a prosthesis.

#### MATERIALS AND METHODS

All the patients included in the present study were treated in cooperation between the Division of Dental Surgery Implant Prosthodontics at the Dental School of the "Sapienza" University of Rome. A total of 68 patients were treated for the removal of 109 previously inserted implants. These implants were never restored because they were not osseointegrated, could not be used from a prosthetic point of view or were inserted in close proximity of anatomic structures which might be damaged because of the implants. The patients that underwent the implant removal were of both genders, with an age range comprised between 22 and 70 years. The implants were distributed almost homogeneously between the two arches, (tab.I). Among the 68 patients who underwent the explantation procedure, a total of 10 patients responding to the following criteria were selected.

The following inclusion criteria were adopted: the presence of one or more implants considered failed from the clinical and radiographic point of view, a residual alveolar width following the implant explantation sufficient to place a standard implant (3.8 mm diameter) in the site of the failed implant. Exclusion criteria were the following: natural teeth adjacent to surgical area affected by untreated periodontal and endodontic infections, peri-implant bone defects requiring bone augmentation, absence of opposing occlusion. Additional exclusion criteria were: poor oral hygiene, smoking, parafunctional habits, severe maxillomandibular space discrepancies, drug use or alcohol abuse. A total of 16 implants (Winsix® , Biosaf SRL, Italy) were placed in the sites of previously failed implants. All the patients were appropriately informed regarding the study and signed a written consent form. The titanium implants used in this study are grade II titanium dental implants approved for human use and are internal hex implant with thread design. The implant surface is sandblasted and acid etched. The implant

features of the fixtures used in the study and the jaw position are displayed in Tab. I. A week before the surgical removal of failed implants a session of full mouth periodontal debridement and scaling was performed and oral hygiene instructions were reinforced. All the patients underwent the same surgical protocol for both the explantation and the implant surgeries. All subjects adopted an antimicrobial prophylaxis with a mouthwash of 0.12% chlorhexidine rinsing for 1 minute prior to surgery and three times a day for the following 10 days (Dentosan 0,12%, Johnson & Johnson, USA) and antibiotics 1gr per day of clavulanic acid and amoxicillin for 3 days starting 1 hour before surgery (Augmentin 1gr, Smith-Kline Beecham, New York, NY, USA) Local anesthesia was induced by infiltration with articaine/epinephrine (Ecocain ® 20mg/ml, Molteni Dental, Italy). Crestal and intrasulcular peri-implant incisions were made with maximum effort to maintain the periodontal tissues of adjacent teeth intact, vertical release incisions were made to obtain a better visibility only if necessary. A full thickness flap was reflected buccally and lingually to expose the failed fixture. The implant removal was performed with the implant driver or using piezo-surgical devices and surgical forceps. Closure of the flap was obtained without tension using 4.0 silk sutures (Ethicon, Silk ® 4.0 Ethicon, USA). One of the patients included in the study had undergone the insertion of three implants two months before the beginning of the study (teeth # 4.7-4.6 and 4.5). The fixtures had never received a prosthesis. The patient referred persistent pain around the implants and a slight paresthesia was assessed. Radiographic data and peri-implant probing revealed an advanced peri-implantitis on 4.6 and 4.5, while 4.7 was completely osseointegrated, but had been inserted into the mandibular canal (fig.1a-1b) After a period of 50 days following the implant removal, orthopantomographs and CT scan exams were repeated to evaluate the bone healing process and the residual bone volume. These radiographic exams were also necessary to plan a correct treatment (fig 1c-1d). The same medications and surgical protocol were used. The preparation of the recipient site was performed following the instructions of the implant manufacturer under abundant saline solution irrigation. All the implants were rigorously placed at the crestal bone level using a driver mounted on an handpiece with an insertion torque of at least 35 N and low speed (50 rpm). The biologic distance between implants was respected, as was the distance between implants and adjacent natural dentition and between implants and contiguous anatomical structures (fig.2a). No bone grafting was needed. Closure of the flap was obtained without tension using 4.0 silk sutures. Patients were instructed to maintain a liquid or semiliquid diet for the first three days and then gradually return to a normal diet. Painkiller medications were prescribed and adopted by patient when needed (Aulin ®, nimesulide 100mg, Roche SPA, Italia). Sutures were removed 7 days after surgery. According to the consensus statement of Cochran et al. (18) about recommended clinical procedures regarding loading protocols for endosseous dental implants all the implants were immediately loaded and received provisional restorations 24 hours after the implant surgery. Immediately after the suture, impression posts were connected to the implants, and direct impressions were made with vinylsiloxane material. Waxing sleeves with gold alloy base and plastic extensions



were burned out and cast to obtain platform switched custom made abutments (fig.2b). Methacrylate provisional restorations were fabricated and delivered within 24 hours (fig.2c). Multiple implants were connected to each other. An insertion torque of all the abutments to the implants of 25N/cm was obtained with a torque wrench device. All the restorations were designed with minimal contact in maximum intercuspal position or centric relation while working and balancing contacts were removed. Final metal-ceramic restorations were delivered four months after the implant placement (fig.2d).

#### *Criteria for success and follow-up examinations*

The following conditions were considered for implant success and recorded by a previously calibrated and masked operator for each implant: absence of fixture mobility, absence of peri-implant radiopacity/radiolucency at radiographic assessment, bone loss lower than 1.5 mm at 12 months radiographic exam, absence of suppuration, pain, infection and paresthesia (19).

All the patients were placed under a strict plaque control regimen until complete soft tissue healing was obtained and were recalled at 6,12,24 and 36 months after prosthetic loading. Peri-implant probing was recorded at four aspects for each implant (mesio and disto buccal, buccal, lingual), percentages of sites positive at the bleeding on probing were recorded, modified plaque and gingival indexes (mPI, mGI) (20) were collected, occlusion was checked, radiographs were performed. The results of the peri-implant bone remodeling are reported in Tab. II.

#### *Radiographic assessment*

Radiographic evaluation was performed according to a previously published study (21). Briefly, a previously calibrated and masked operator made all the x-ray exams. Standardized peri-apical radiographs were taken using a customized bite record fabricated with acrylic resin on a Rinn XCP Ring positioner (Dentsply®, Costanza, Germany) and a beam guiding rod to allow parallelization between the x-ray tube and the film and standardize all the radiographs. The radiographs were performed with a dental x-ray machine (TM 2002® CC Planmeca Proline, Planmeca Group Helsinki, Finland) equipped with a long tube that operated at 70 Kw/7.5 mA and were developed in an automatic developer under standardized conditions. The radiographs were taken at baseline, 12, 24 and 36 months after implant placement (fig. 3a-3b-3c). The radiographs, set on a cephalometric unit in a darkroom, were acquired and converted in digital images with a camera, saved into a computer memory in TIFF format.

Later each image was processed with specific software (Beta Scion Immagine® 4.03 for Windows XP, Scion LTD USA). and displayed on a high resolution monitor. A computer assisted calibration was accurately made on mesial and distal side of each implant measuring the known distance between 2 threads. This calibration allowed a correct measurement even if there was a slight deviation of the central beam and a consequent magnification of the image. The following reference points were assessed on each image: fixture-abutment junction, threads, first contact of the crestal bone with the implant on both mesial and distal side. Knowing the values of the implant diameter and length, this enabled us to make linear measurements of remaining peri-implant bone measured from the mesial and distal marginal bone levels and the fixture-abutment junction. The linear measurements were made by a trackball driven cursor on a 10 times magnified digitized image of the implant on the monitor. The amount of bone change over the baseline to 12,24 and 36 months after implant placement were calculated for all implants.

#### *Statistical Evaluation*

The remodeling of peri-implant bone tissue was analysed using Friedman's non-parametric statistical test and the differences were evaluated with Dunn's multiple comparisons test. All data were expressed as averages ± the standard error (SE); differences were considered statistically significant for  $p < 0.05$ .

## RESULTS

#### *Clinical observations*

10 patients were treated with the placement of 16 platform switched, immediately loaded dental implants in the sites of previously failed implants. No drop-out was observed. Peri-implant status was assessed by the means of probing depth and bleeding on probing recordings, mPI and mGI. The average peri-implant probing values were all normal and not deeper than 4mm. All the modified plaque and gingival indexes were between 0 and 1.5. Although a careful plaque control regimen was performed during the entire study, at 36 months post-operative control, a slight peri-implant inflammation was detected, and positive B.O.P. values were sometimes observed. Differences in crestal

**Table I.** Implants location

Site implant	Incisors	Canines	Premolars	Molars
Maxilla	1	0	2	7
Mandible	0	0	2	4

118 (S)

A. QUARANTA ET AL.

**Table II.** Mean values  $\pm$  standard errors (SE) of peri-implant bone remodeling at 12, 24 and 36 months follow-up

Implant number	12 months	24 months	36 months
1	0.29	0.3	0.49
2	0.22	0.2	0.41
3	0.09	0.1	0.32
4	0.28	0.3	0.30
5	0.19	0.1	0.35
6	1.05	0.3	0.97
7	0.30	0.2	0.65
8	0.37	0.2	0.41
9	0.26	0.1	0.52
10	0.20	0.1	0.57
11	1.24	0.3	1.01
12	0.52	0.2	0.98
13	0.35	0.4	0.43
14	0.48	0.2	0.51
15	0.40	0.1	0.70
16	0.57	0.4	1.02
<b>Mean <math>\pm</math> SE</b>	<b>0.42 <math>\pm</math> 0.077</b>	<b>0.21 <math>\pm</math> 0.026</b>	<b>0.60 <math>\pm</math> 0.064</b>

**Table III.** Peri-implant bone remodeling by Dunn's Multiple Comparison Test

Time	P values
12 months vs 24 months :	p >0.05 (ns)
12 months vs 36 months:	p $\square$ 0.05*
24 months vs 36 months:	p $\square$ 0.001***

ns: no significant

\*: significant

bone remodeling were statistically significant between 12 and 36 months ( $p < 0.05$ ) and between 24 and 36 months ( $p < 0.001$ ), while no statistically significant differences were found between 12 and 24 months ( $p > 0.05$ ) (Tab III). No implant was lost and all the fixtures placed fulfilled the aforementioned evaluated requirements for success. (Tab. II). Minimal recession associated with positive bleeding on probing was observed on the buccal aspect of an implant supporting a single crown in patient #10. Therefore the cumulative success rate after 36 months was of 93.75%, while the cumulative survival rate was 100%.

#### DISCUSSION

The purpose of the present study was to evaluate by standardized peri-apical radiographs the crestal bone maintenance around platform switched, immediately

loaded dental implants placed in sites of previously failed implants. To our best knowledge this is the only study in which the radiographic evaluation of platform switched immediately loaded dental implants placed in the sites of previously failed implants has been performed and observed for 36 months. From the clinical point of view the placement of dental implants in the sites of previously failed implants may be considered similar to a post-extraction implant in the socket of a single-root tooth with intact walls.

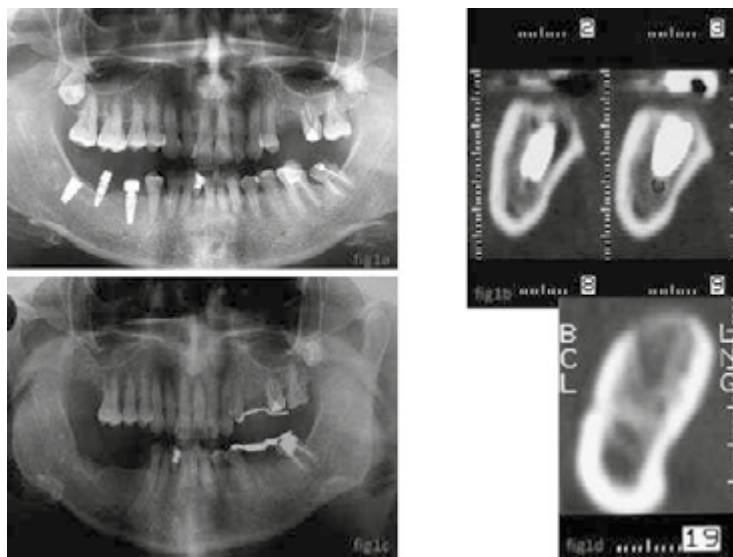
Positive data were reported about immediately loaded, immediate post-extraction implants. Covani et al. (22) inserted 18 single implants in fresh extraction sockets that were immediately restored with temporary abutments and crowns. During the 12-month follow-up period, one fixture was removed 4 weeks after implant placement following an abscess. All remaining implants healed

**Table IV.** Peri-implant clinical measurements at 12,24 and 36 months

Follow-up period	Average Probing depth	Average Probing depth	Average Probing depth	Average Probing depth	Percentage of positive sites at BOP assessment	mGI
	□SD (mm) mesiofacial	□SD (mm) facial	□SD (mm) distofacial	□SD (mm) lingual		
Baseline (maxilla)	NA	NA	NA	NA	NA	NA
12 months	3.50□0.4	2.53□0.41	3.16□0.45	2.64□0.56	4.10%	0.34 ±0.15
24 months	3.55□0.3	2.01±0.30	3.03□0.35	2.75□0.5	4.20%	0.54 ±0.25
36 months	4.55□0.3	2.90□0.45	4.45□0.35	2.85□0.15	8.1%	1.5± 0.35

*Sd: Standard Deviation*

*Na: Not Assessed*



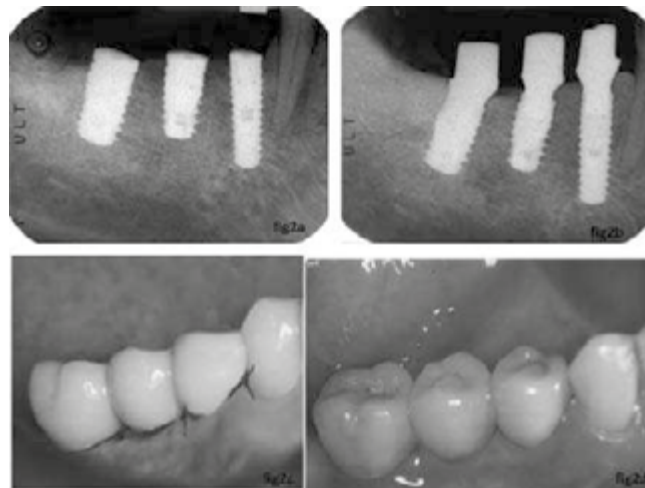
**Fig.1.** A) Baseline orthopantomograph exam. B) Multiple CT axial views showed that the implants were placed in contact with the alveolar inferior nerve. C) Orthopantomograph 30 days following the removal of the failed implants. D) CT Axial view of an healed area in the site of a previously failed implant

uneventfully with no complications and were assessed as stable and successful at the 12-month checkup. Mozzati et al (23) placed 334 dental implants in postextraction sockets that were immediately loaded. The two-years retrospective evaluation showed a 100 % survival rate and a 97.9 %implant survival rate. Similarly, Malchiodi et al. (24) placed 64 single postextraction implants,that were

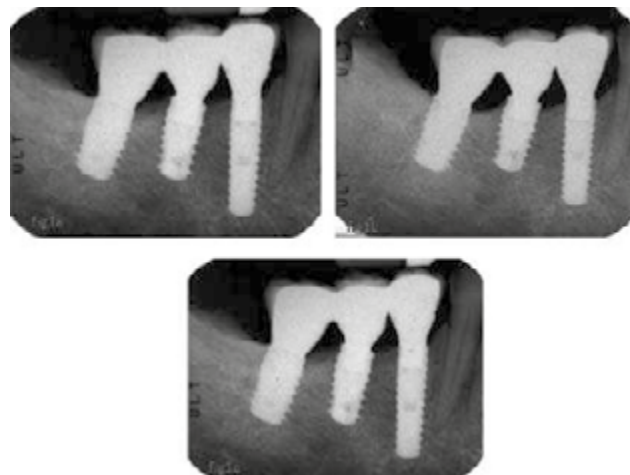
immediately loaded . Clinical and radiographic data were recorded at the time of surgery, at the time of definitive restoration, and after 3 years of functioning, in order to evaluate soft tissues esthetics and bone tissue condition. No implants had failed and the implant success rate was 100%. All parameters were stable and steady during the 3-year follow-up. The data of the present study are in

120 (S)

A. QUARANTA ET AL.



**Fig. 2.** A) Immediate, post-operative peri-apical radiograph: three new implants were placed 50 days after the removal of the failed implants. The biologic distance among the different implants and the implants and the adjacent natural dentition was respected. B) Post-operative peri-apical radiograph with platform switched custom made abutments seated. C) Methacrylate provisional restorations were delivered within 24 hours the surgical placement of the implants D) Clinical view of the final restorations that were delivered 4 months following the implant placement



**Fig. 3.** A) Crestal bone maintenance around the platform switched immediately loaded dental implants (12 months). B) Crestal bone maintenance around the platform switched immediately loaded dental implants (24 months). C) Crestal bone maintenance around the platform switched immediately loaded dental implants (36 months).

good agreement with the aforementioned results since in our study there was no implant failure after 36 months. Among the 10 patients included in the present study, one underwent the removal of three early failed implants. One

of these implants, (4.7), although perfectly osseointegrated, had failed not because of thermal damage to bone tissue, peri-implantitis or occlusal overload, but due to an incorrect insertion. The fixture had been positioned in

contact with the mandibular neuro-vascular bundle and had caused paresthesia. This rare iatrogenic event occurs between 0 and 8% according to various researchers and patients recount it as a dramatic experience. At times, the likelihood of this event may be increased by an anomalous position of the inferior alveolar nerve (25-26); following the removal of the failed implant causing the neural pathology and the surgically complex insertion of another implant in the same site, the authors reported a success for the newly positioned implant after 36 months.

The prosthetic concept of platform-switching has been studied a great deal in recent years (15,27). The minimal amount of crestal bone remodeling observed with this design has shown that platform-switching may help to limit bone loss around dental implants. The results of the present study indicate that the use of platform-switching may help to limit the extent of bone remodeling in the sites of previously failed implants. Other recent studies report excellent percentages of success for implants restored with platform-switching (28,29). The results obtained, within the limits of the present study, suggest that immediately loaded platform-switched implants are a practicable solution for the rehabilitation of previously failed implant sites. Radiographic and clinical data collected at 12, 24 and 36 months was successful and showed a minimal amount of crestal bone remodeling. The comparison between average bone remodeling at 24 and 36 months from prosthetic loading exhibited very significant statistical differences ( $p < 0.001$ ). Although some values indicated a significant amount of bone remodeling, results at 24 months were better than those reported by other authors (16). In conclusion, the prosthetic procedure known as platform switching may help in reducing the crestal bone remodeling around immediately loaded implants inserted where other implants had previously failed. The authors acknowledge the need for larger long-term studies investigating the use of this implant design in sites of previously failed implants. Furthermore, the possible options for the reduction of prosthetic loads should be further investigated and better defined.

#### ACKNOWLEDGEMENTS

The Authors wish to thank Dr Lucrezia Paterno-Holtzman for her great contribution to the manuscript final version and submission.

#### REFERENCES

1. Buser D, Weber HP, Donath K, Fiorellini JP, Paquette DW, Williams RC. Soft tissue reactions to non-submerged unloaded titanium implants in beagle dogs. *J Periodontol* 1992; 63: 225-235.
2. Lijenberg B, Gualini F, Berglundh T, Tonetti M, Lindhe J. Some characteristics of the ridge mucosa before and after implant installation. A prospective study in humans. *J Clin Periodontol* 1996; 23: 1008-1013.
3. Piattelli A, Scarano A, Piattelli M, Bertolai R, Panzoni E. Histologic aspects of the bone and soft tissues surrounding three titanium non-submerged plasma-sprayed implants retrieved at autopsy. A case report. *J Periodontol* 1997; 68: 694-700.
4. Schrotenboer J, Tsao YP, Kinariwala V, Wang HL. Effect of microthreads and platform switching on crestal bone stress levels. A finite element analysis. *J Periodontol* 2008; 79: 2166-2172.
5. Warden PJ, Scuba JR. Surgical repositioning of a malposed unserviceable implant: case report. *J Oral Maxillofac Surg* 2000; 58: 433-435.
6. Kim YK, Parkjy, Kim SG, Lee HJ. Prognosis of the implants after removal of failed dental implants. *Oral Surg Oral Med Oral Pathol Oral Radiol Oral Endod* 2010; 110(3): 281-286.
7. Evian CI, Cutler SA. Direct replacement of failed CP titanium implants with larger-diameter, HA-coated Ti-6Al-4V implants: report of five cases. *Int J Oral Maxillofac Implants* 1995 Nov-Dec; 10(6): 736-43.
8. Adell R, Ericsson B, Leckolm U, Branemark PI, Jemt T. A long-term follow-up study of osseointegrated implants in the treatment of totally edentulous jaws. *Int J Oral Maxillofac Implants* 1990; 5: 347-359.
9. Hermann JS, Cochran DL, Nummikoski PV, Buser D. crestal bone changes around titanium implants. A radiographic evaluation of unloaded nonsubmerged and submerged implants in the canine mandible. *J Periodontol* 1997; 8: 1117-1130.
10. Kitamura E, Stegaroiu R, Nomura S, Miyakawa O. Biomechanical aspects of marginal bone resorption around osseointegrated implants. Considerations based on a three-dimensional finite element analysis. *Clin Oral Implants Res* 2004; 15: 401-412.
11. Todescan FF, Pustiglioni FE, Imbroni AV, Albrektsson T, Gioso M. Influence of the micro gap in the perimplant hard and soft tissues: a histomorphometric study in dogs. *Int J Oral Maxillofac Implants* 2002; 17: 467-472.
12. Ericsson I, Berglundh T, Mariniello CP, Lijenberg B, Lindhe J. Long-standing plaque and gingivitis at implants and teeth in the dog. *Clin Oral Implants Res* 1992; 3: 99-103.
13. Jansen VK, Conrads G, Richter EJ. Microbial leakage and marginal fit of the implant-abutment interface. *Int J Oral Maxillofac Implants* 1997 Jul-Aug; 12(4): 527-40.
14. Abrahamsson I, Berglundh T, Lindhe J. Soft tissue



122 (S)

A. QUARANTA ET AL.

- response to plaque formation at different implant systems. A comparative study in the dog. *Clin Oral Implants Res* 1998 Apr; 9(2): 73-9.
15. Lazzara RJ, Porter SS. Platform switching: a new concept in implant dentistry for controlling postrestorative crestal bone levels. *Int J Periodont Rest Dent* 2006 Feb; 26(1): 9-17.
  16. Cocchetto R, Traini T, Caddeo F, Celletti R. Evaluation of hard tissue response around wider platform-switched implants. *Int J Periodontics Rest Dent* 2010 Apr; 30(2): 163-71.
  17. Guerra M, Vozza I, Quaranta A. Histological evaluation of peri-implant soft tissues in immediately loaded implants featuring different implant-abutment connections: a preliminary study. *Eur J Infl* 2012; 10: 91-98.
  18. Cochran DL, Morton D, Weber HP. Consensus statements and recommended clinical procedures regarding loading protocols for endosseous dental implants. *Int J Oral Maxillofac Implants* 2004; 19 Suppl: 109-13.
  19. Albrektsson T, Zarb G, Worthington P, Eriksson AR. The long-term efficacy of currently used dental implants: a review and proposed criteria of success. *Int J Oral Maxillofac Implants* 1986; 1(1): 11-25
  20. Lang NP, Wilson TG, Corbet EF. Biological complications with dental implants: their prevention, diagnosis and treatment. *Clin Oral Implants Res* 2000; 11 Suppl 1: 146-55.
  21. M. Danza, P. Tortora, A. Quaranta, V. Perrotti, I. Vozza, A. Piattelli. Randomised study for the 1-year crestal bone maintenance around modified diameter implants with different loading protocols: a radiographic evaluation. *Clin Oral Investig* 2010; 14(4): 417-2
  22. Covani U, Cornelini R, Calvo JL, Tonelli P, Barone A. Bone remodeling around implants placed in fresh extraction sockets. *Int J Periodontics Restorative Dent*. 2010 Dec;30(6):601-7.
  23. Mozzati M, Arata V, Gallesio G, Mussano F, Carossa S. Immediate postextraction implant placement with immediate loading for maxillary full-arch rehabilitation: A two-year retrospective analysis. *J Am Dent Assoc* 2012; 143(2): 124-33.
  24. Malchiodi L, Cucchi A, Ghensi P, Nocini PF. Evaluation of the Esthetic Results of 64 Nonfunctional Immediately Loaded Postextraction Implants in the Maxilla: Correlation between Interproximal Alveolar Crest and Soft Tissues at 3 Years of Follow-Up. *Clin Implant Dent Relat Res* 2011 Dec 16. doi: 10.1111/j.1708-8208.2011.00424.x. [Epub ahead of print].
  25. Krasny A, Krasny N, Prescher A. Anatomic variations of neural canal structures of the mandible observed by 3-tesla magnetic resonance imaging. *J Comput Assist Tomogr* 2012 Jan; 36(1): 150-3.
  26. Kilic C, Kamburoglu K, Ozen T, Balcioglu HA, Kurt B, Kutoglu T, Ozan H. The position of the mandibular canal and histologic feature of the inferior alveolar nerve. *Clin Anat* 2010 Jan; 23(1): 34-42.
  27. Barone A, Rispoli L, Vozza I, Quaranta A, Covani U. Immediate restoration of single implants placed immediately after tooth extraction. *J Periodontol* 2006; 77(11): 1914-20.
  28. Canullo L, Quaranta A, Teles RP. The microbiota associated with implants restored with platform switching: a preliminary report. *J Periodontol* 2010; 81(3):403-11.
  29. Al-Nsour MM, Chan HL, Wang HL. Effect of the Platform-Switching Technique on Preservation of Peri-implant Marginal Bone: A Systematic Rev *Int J Oral Maxillofac*

**1 Long-Term Evaluation of Maxillary Reconstruction by Iliac Crest Bone Graft: A Morphologic and Immunohistochemical Study**

S. Tetè, R. Vinci, S. Zara, V. Zizzari, A. De Carlo, G. Falco, D. Tripodi, A. Cataldi, C. Mortellaro, E. F. Gherlone  
The Journal of Craniofacial Surgery Vol. 22, N°5 - Sept. 2011

**2 Microcomputed and Histologic Evaluation of Calvarial Bone Grafts: A pilot Study in Humans**

R. Vinci, A. Rebaudi, P. Capparè, E. F. Gherlone  
The International Journal of Periodontics & Restorative Dentistry Vol.31, N° 4 2011

**3 Valutazione istologica, istomorfometrica e microtomografica dell'osteointegrazione di impianti con scaffolds nanostrutturati**

Paolo Capparè, Antonio Apicella, Alberto Barlattani, Fernando Zarone, Roberto Crespi, Enrico Gherlone  
Doctor Os, supplemento maggio 2011 - XXII (5)

**4 Isolamento di progenitori osteogenici provenienti da liquido amniotico utilizzando un protocollo di coltura cellulare single step**

Stefano Tetè, Ivana Antonucci, Giuseppe D'Apolito, Umberto Di Tore, Vincenzo Zizzari, Alessandro De Carlo, Margherita Tumedei, Liborio Stuppia, Enrico Gherlone  
Doctor Os, supplemento maggio 2011 - XXII (5)

**5 Valutazione della macrostruttura e della nanostruttura di un nuovo tipo di impianti dentali**

Giuseppe D'Apolito, Umberto Di Tore, Alessandro De Carlo, Margherita Tumedei, Renato Grilli, Vincenzo Zizzari, Liborio Stuppia, Enrico Gherlone, Stefano Tetè  
Doctor Os, supplemento maggio 2011 - XXII (5)

**6 Valutazione morfostrutturale al SEM di cellule staminali da follicolo dentario su differenti scaffold di titanio**

Umberto Di Tore, Giuseppe D'Apolito, Vincenzo Zizzari, Alessandro De Carlo, Margherita Tumedei, Liborio Stuppia, Raimondo Quaresima, Enrico Gherlone, Stefano Tetè  
Doctor Os, supplemento maggio 2011 - XXII (5)

**7 Valutazione degli effetti di differenti tecniche osteotomiche sul tessuto osseo**

Raffaele Vinci, Stefano Tetè, Giuseppe D'Apolito, Umberto Di Tore, Luisella Benzo, Alessandro De Carlo, Margherita Tumedei, Vincenzo Zizzari, Liborio Stuppia, Enrico Gherlone,  
Doctor Os, supplemento maggio 2011 - XXII (5)

**8 Analisi retrospettiva a quattro anni degli esiti di trattamento implanto-protesico eseguiti con sistematica WINSIX®**

S.Zandonella Necca, F.Bova, Enrico Gherlone  
Doctor Os, supplemento maggio 2011 - XXII (5)

**9 TEETH JUST ON SIX: Riabilitazione Implantoprotesica nei casi di Edentulia completa: un approccio diagnostico-terapeutico integrato**

M. Manacorda, R. Vinci, M. Pasi, E. F. Gherlone  
Odontoiatria, Rivista Amici di Brugg n°1, anno 30° - Maggio 2011

**10 Tecniche Chirurgiche Piezoelettriche**

R. Vinci, M. Pasi, S. Tetè, E. F. Gherlone  
Panorama Dentale - Sept. 2011

## CLINICAL STUDY

## Long-Term Evaluation of Maxillary Reconstruction by Iliac Bone Graft

Stefano Tetè, MD, DDS,\* Raffaele Vinci, MD, DDS,† Susi Zara, PhD,‡ Vincenzo Zizzari, DDS,\*  
Alessandro De Carlo, DDS,\* Giorgio Falco, DDS,\* Domenico Tripodi, MD, DDS,\*  
Amelia Cataldi, MD,§ Carmen Mortellaro, MD, DDS,||# and Enrico Gherlone, MD, DDS†

**Abstract:** The aim of this study was to analyze histologic and immunohistochemical modifications taking place in maxillary sites reconstructed by iliac crest bone grafts, 4 months ( $T_1$ ) and 10 years ( $T_2$ ) after grafting, in comparison to native iliac crest bone ( $T_0$ ).

By light microscopy,  $T_1$  samples showed well-organized osteoblasts and extracellular matrix (ECM), and surrounding areas of connective tissue where a discrete number of blood vessels can be distinguished. Samples obtained from reconstructed areas after a long period of follow-up ( $T_2$ ) were characterized by uniform mineralized ECM with cavities containing osteocytes, whereas  $T_0$  samples disclosed both mineralized matrix and bone marrow. Matrix metalloproteinase 2 (MMP-2), vascular endothelial growth factor (VEGF), inducible nitric oxide synthase (iNOS), and bone sialoprotein (BSP) expressions were investigated by immunohistochemical analysis. Both MMP-2 and VEGF showed significantly increased expression in  $T_1$ , with respect to  $T_0$ , and lowered in  $T_2$ . Otherwise, BSP expression, which was elevated in native iliac crest bone ( $T_0$ ), was deeply decreased in  $T_1$  and  $T_2$  samples. Moreover, changes in iNOS expression and in apoptotic cell nuclei percentages (TUNEL analysis) seemed to have a similar trend, increasing in  $T_1$  and lowering in  $T_2$ .

After a period of 4 months, iliac crest bone graft–reconstructed sites show mineralizing nuclei not strongly represented, as suggested by BSP lower expression, whereas new blood vessel proliferation and active remodeling phenomena are developing. After a long period from the grafting ( $T_2$ ), BSP expression decreases along with MMP-2, VEGF, and iNOS, suggesting the presence of only weak arrangement phenomena of the graft.

**Key Words:** Iliac crest bone graft, matrix metalloproteinase 2, vascular endothelial growth factor, inducible nitric oxide synthase, bone sialoprotein

(*J Craniofac Surg* 2011;22: 1702–1707)

**H**ard tissue defects, resulting from trauma, infections, or tooth loss, often lead to an unfavorable anatomy of maxillary and mandibular alveolar processes requiring bone grafting before implant therapy.<sup>1,2</sup> The goal of bone augmentation before implant placement in deficient alveolar ridge is the reconstruction of a correct alveolar structure by horizontal and vertical ridge augmentation, sinus bone grafting, and other.<sup>3,4</sup> In recent years, a variety of bone grafts and biomaterials have been used for augmentation of deficient alveolar ridge before implant treatment in partially and completely edentulous patients, including autogenous, allogenic, xenogenic, synthetic bone, and combinations of these.<sup>5,6</sup> However, the use of autologous bone graft remains the criterion standard of therapy.<sup>7</sup> Extraoral grafts have been estimated as a good solution to correct bone lack, obtaining a large quantity of bone tissue,<sup>8</sup> with a lower resorption rate than intraoral bone graft during the healing process.<sup>9,10</sup> Extraoral sites of autogenous block grafts include ilium, calvarium, tibia, rib, and others.<sup>11,12</sup>

The iliac crest is one of the most common donor sites for autogenous bone grafting owing to the bone accessibility and to the availability of an adequate quantity of both cortical and cancellous bone and comparably low morbidity associated to the procedure.<sup>13</sup> Many studies have described postoperative conditions and complication at the donor site, with differences in their incidence and severity according to the location of the iliac crest donor site and the harvesting techniques used.<sup>14,15</sup>

After bone graft insertion, to ensure new bone formation at the site of bone augmentation, graft resorption and the formation of new blood vessels seem essential.<sup>16</sup> Moreover, the neoangiogenic process allows undifferentiated mesenchymal stem cells, diffusing from blood vessels, to colonize the grafted area from the peripheral zone to the center, accompanied by an inflammatory response. Neoangiogenesis and bone integration processes involve a number of molecules, of which matrix metalloproteinase 2 (MMP-2), vascular endothelial growth factor (VEGF), bone sialoprotein (BSP), and inducible nitric oxide synthase (iNOS) expressions were investigated in this study.

The vascular network between bone graft and the recipient site is provided by endothelial cell proliferation and the creation of new blood vessels, which include the activation of many transcription factors producing cytokines, matrix proteases, and adhesion molecules.<sup>17–19</sup> Initially, endothelial cells lining the existing microvessels, in response to angiogenic stimuli, degrade their basement membrane by secreting proteolytic enzymes, including MMPs and serine proteases, thus providing the physical space for MMPs.

From the \*Department of Oral Science, Nano and Biotechnologies, University "G. d'Annunzio," Chieti; †Department of Oral Science, University "Ateneo Vita - Salute S. Raffaele," Milan; ‡Department of Drug Sciences, University "G. d'Annunzio," Chieti; §Department of Medicine and Ageing Sciences, University "G. d'Annunzio," Chieti; ||Department of Medical Science, Faculty of Medicine, University of Eastern Piedmont, Novara; and #Oral Surgery Unit, Regina Margherita Pediatric Hospital, Turin, Italy.

Received September 29, 2010.

Accepted for publication January 23, 2011.

Address correspondence and reprint requests to Carmen Mortellaro, MD, DDS, Oral Surgery Unit, Regina Margherita Pediatric Hospital, Piazza Polonia 94-10126, Via Sacchi 4, Turin, Italy; E-mail: carmenmortellaro@hotmail.com

The authors report no conflicts of interest.  
Copyright © 2011 by Mutaz B. Habal, MD  
ISSN: 1049-2275

DOI: 10.1097/SCS.0b013e31822e5cb

These belong to a family of enzymes playing a central role in ECM turnover and remodeling, based on their ability to hydrolyze major protein components of the ECM.<sup>20</sup> Matrix metalloproteinase 2, the constitutive form of MMPs, degrades collagen at the vascular basement membrane and involves other specific collagenases in interstitium degradation.<sup>21</sup>

New vessels grow after the degradation of the extracellular components. This growth is supported also by VEGF, which plays an important role in the maintenance and development of endothelial fenestrations<sup>22,23</sup> and in endothelial survival, as demonstrated by in vitro and in vivo studies.<sup>24,25</sup>

Bone sialoprotein, as a component of the ECM, regulates bone apposition and remodeling. It plays important functional roles in the promotion of the osteoclastic resorption of mineralized surfaces. Previous studies demonstrated positive staining for BSP in active osteogenic cells at the site of new bone formation.<sup>26,27</sup> However, its expression is not only related to the mature osteoblastic phenotype but also upregulated by factors inducing osteoblast differentiation.<sup>28,29</sup>

After graft insertion, any host tissue reacts with an inflammatory response, which could be still recognizable 4 months after the grafting. In this sense, iNOS expression, a calcium-independent molecule expressed in response to endotoxins and to inflammatory cytokines in macrophages and many other cell types,<sup>30,31</sup> could be evaluated to estimate the entity of the inflammatory reaction.

In this work, the morphologic modifications and the expression of MMP-2, VEGF, iNOS, and BSP have been investigated in samples obtained from iliac crest bone graft reconstructed sites, 4 months ( $T_1$ ) and 10 years ( $T_2$ ) after grafting, in comparison to native iliac crest bone ( $T_0$ ).

## MATERIALS AND METHODS

Patients needing oral rehabilitation of the posterior maxilla, with bone volume inadequate for implant placement, were scheduled for bone augmentation with autologous bone graft. All the bone defects considered could be classified as class G according to Chiapasco's Classification of the Posterior Maxilla (2004).<sup>32</sup>

Samples of the specimens used for morphologic and immunohistochemical analysis were evaluated at 3 different experimental times:

- $T_0$ : samples of bone tissue obtained from the iliac crest at the moment of bone block withdrawal for the grafting;
- $T_1$ : samples of bone tissue collected from the grafted area at the moment of implant placement, that is, approximately 4 months after the first intervention;
- $T_2$ : samples of bone tissue collected from the grafted area after 10 years from grafting.

In all cases, bone specimens were collected by a 3-mm-diameter trephine.

All patients who underwent surgical procedures and who were included in this research gave written informed consent in accordance with the local ethics committee and in compliance with Italian legislation and with the code of Ethical Principles for Medical Research Involving Human Subjects of the World Medical Association (Declaration of Helsinki).

Complete medical anamnesis and radiographic examinations were carried out on all patients before surgical procedures. Healthy systemic conditions, including the absence of any disease that would contraindicate surgery, were necessary to be included in the study. The exclusion criteria were uncontrolled periodontal disease, severe illness, unstable diabetes, drug abuse, a history of head and neck irradiation, chemotherapy. Orthopantomograms and computed tomographic scans of the jaw were included in preoperative radiographic evaluation.

Maxillary reconstructions were performed under general anesthesia by positioning onlay iliac crest bone blocks. All patients received prophylactic antibiotic therapy (ceftriaxone). The surgical access to iliac crest was made approximately 4 cm behind the anterior upper iliac spine, by a skin incision approximately 2 cm long. The skeletonization of the internal iliac hole was performed, followed by an anterior-medial bicortical grafting according to the technique of Grillon et al.<sup>12</sup> After shaping the bone tissue by piezosurgery (Easy Surgery; BioSAF Srl, Ancona, Italy), the bone blocks were mobilized using chisels.

The dimension of the defects regulated the bone block shape, correctly fitted in the recipient site. Before insertion, to increase the blood supply from endosseous vessels, the cortical bone of the recipient site was perforated with a 1-mm-diameter round bur, and the bone blocks were fixed with lag screw to rebuild the alveolar ridge. All gaps between the bone blocks and the recipient sites were packed with particulate bone from the same donor site. The maxillary sinus was filled with bone chips obtained from the same donor sites. The grafted areas were covered with a resorbable barrier. After releasing the vestibular periosteum, the flap was sutured. Postoperative therapy protocol comprised administration of antibiotic (ceftriaxone) 2 g/d for 10 days, nonsteroidal analgesic drug (ketoprofen) at a dose of 200 mg twice daily for 3 days and thereafter as required, cortisone (betamethasone) 4 mg/d for 2 days, and 2 mg on day 3. Moreover, soft diet and oral hygiene, including 3 times daily rinsing with 0.2% chlorhexidine mouthwash and application of 1% chlorhexidine gel on the surgical site, were prescribed. Sutures were removed 10 days after the intervention, and postoperative checkups were scheduled weekly for the first month and then monthly. After 4 months, the patients underwent a second surgical step for implant insertion ( $T_1$ ). Contextually, the fixation screws were removed. The implant features (diameter and length) were decided according to the individual anatomic situation. The implants were allowed to heal unloaded for 6 months for osseointegration before prosthetic rehabilitation was initiated. Pharmacologic protocol included antibiotic (amoxicillin) 2 g 1 hour before the surgery and 1 g twice per day for the following 5 days and nonsteroidal analgesic drug to be taken as required. After prosthetic finalization, patients were enrolled in an oral hygiene program with evaluation twice a year. Patients with a 10-year follow-up, with optimal general health conditions, were asked to be subjected to bone biopsy in the site reconstructed with iliac crest bone graft ( $T_2$ ).

## Light Microscopy Analyses and Immunohistochemistry

Bone samples, 5  $\mu$ m thick, fixed in phosphate-buffered formalin solution, were dehydrated through ascending alcohols and xylene and then paraffin-embedded and decalcified in EDTA solution according to the manufacturer's instructions (MIELODEC kit; Bio-Optica, Milan, Italy). The samples were then dewaxed (xylene and alcohol at progressively lower concentrations) and processed for hematoxylin and eosin staining and for immunohistochemical analyses.

Samples were then observed by means of a light microscope (DM 4000; Leica Cambridge Ltd, Cambridge, UK) equipped with a camera (DFC 320; Leica Cambridge Ltd) for computerized images.

Immunohistochemistry was performed on 5- $\mu$ m-thick sections by means of Ultravision LP Detection System HRP Polymer and DAB Plus Chromogen (LabVision Thermo, Fremont, CA) to detect MMP-2, VEGF, BSP, and iNOS proteins. Slides were incubated in the presence of mouse anti-MMP-2 monoclonal antibody (Santa Cruz Biotechnology, Santa Cruz, CA), rabbit anti-VEGF and anti-iNOS polyclonal antibodies (Santa Cruz Biotechnology), and mouse anti-BSP monoclonal antibody (Calbiochem Merck, Cambridge, MA). Sections were incubated in the presence of specific HRP-conjugated secondary antibodies. Peroxidase was developed

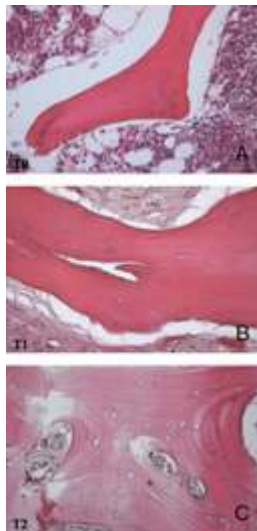
using diaminobenzidine chromogen, and nuclei were hematoxylin-counterstained. Negative controls were performed by omitting the primary antibody.

### TUNEL Analysis

Terminal-deoxynucleotidyl-transferase-mediated dUTP nick end-labeling (TUNEL) is a method of choice for quantification and rapid identification of apoptotic cells. Paraffin-embedded tissue sections were dewaxed and rehydrated. DNA strand breaks, generated during apoptosis, can be identified by labeling free 3'-OH termini with modified nucleotides in an enzymatic reaction. After 2 rinses in PBS, slides were dehydrated, mounted by using a permanent media, and analyzed with a light microscope (Leica Cambridge Ltd). Five slides from each sample were assessed, and apoptotic cell counts were performed on 10 fields per slide. The negative control was performed by omitting the incubation in the presence of the enzymatic mixture, and the positive control was performed by treating 1 slide with DNase I. All steps were realized with FragEL DNA fragmentation Detection Kit according to the manufacturer's instructions (Calbiochem Merck, Cambridge, MA).

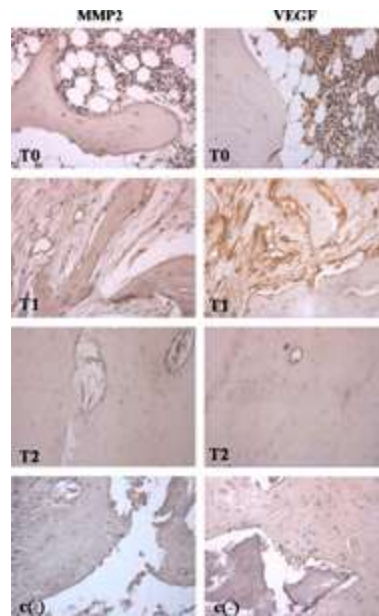
### Computerized Morphometry Measurements and Image Analysis

After digitizing the images deriving from immunohistochemical stained sections, QWin Plus 3.5 software (Leica Cambridge Ltd)



**FIGURE 1.** Hematoxylin and eosin staining of the  $T_0$ ,  $T_1$ , and  $T_2$  samples. Original magnification,  $\times 20$ . A,  $T_0$  sample: samples of bone tissue obtained from the native iliac crest. B,  $T_1$  sample: samples of bone tissue collected from the grafted area at the moment of implant placement (4 months after the first intervention). C,  $T_2$  sample: samples of bone tissue collected from the grafted area after 10 years after iliac crest bone graft. Note in  $T_0$  sample large areas of bone marrow; on the contrary, there are not a lot of mineralized areas.  $T_1$  sample evidences a dynamic situation, with connective tissue and mineralized areas.  $T_2$  sample shows a large presence of mineralized ECM areas in which osteocytes can be distinguished.

1704



**FIGURE 2.** Immunohistochemical detection of MMP-2 (left panel) and VEGF (right panel) in the  $T_0$ ,  $T_1$ , and  $T_2$  samples. Original magnification,  $\times 20$ .

was used to evaluate MMP-2, VEGF, BSP, and iNOS expressions. Image analysis of protein expression was carried out through the quantification of the thresholded area for immunohistochemical brown color per 10 fields of light microscope observation. QWin assessments were logged onto Microsoft Excel (Microsoft Corp, Redmond, WA) and processed for SDs and histograms. The statistical significance of the results was evaluated using the *t*-test and the linear regression test, with  $P = 0.05$ .

### RESULTS

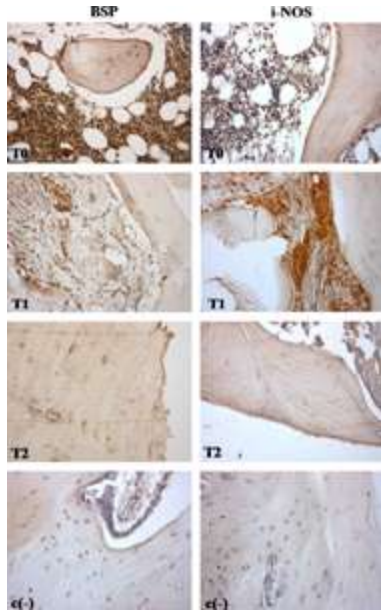
Morphologic analysis carried out by light microscope, after hematoxylin and eosin staining, shows rare areas of mineralized tissue in native iliac crest bone ( $T_0$  samples) surrounding wide lacunae containing bone marrow (Fig. 1A).

Samples obtained 4 months after grafting ( $T_1$  samples) show both mineralized and nonmineralized areas, and the quantity of mineralized components is greater than that observed in  $T_0$  samples. Among these areas, large sites of vascularized connective tissue, with few blood vessels, can be distinguished (Fig. 1B). In  $T_2$  samples, the staining highlights the presence of mineralized ECM areas with disk-shaped cavities, showing gaps in which osteocytes are entrapped (Fig. 1C).

Angiogenic activity in samples at different experimental times was evaluated by performing MMP-2 and VEGF immunohistochemical analysis. Both molecule expressions are increased in the  $T_1$  sample, whereas in  $T_2$ , their expression dramatically lowers ( $P < 0.05$ ; Figs. 2 and 4).

Because the bone graft insertion induces a resorption reaction, BSP expression analysis was performed. Bone sialoprotein is highly expressed in the  $T_0$  sample, decreasing in the  $T_1$  and  $T_2$





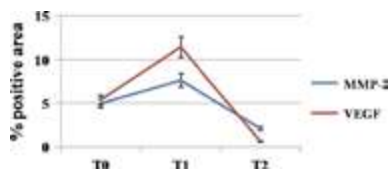
**FIGURE 3.** Immunohistochemical detection of BSP (left panel) and iNOS (right panel) in  $T_0$ ,  $T_1$ , and  $T_2$  samples. Original magnification,  $\times 20$ .

samples ( $P < 0.05$ ), in which values seem strictly related to each other. Moreover, changes in iNOS expression were also measured. This protein shows its greatest expression in  $T_1$  samples, whereas it is almost not detectable in  $T_2$  (Figs. 3 and 5).

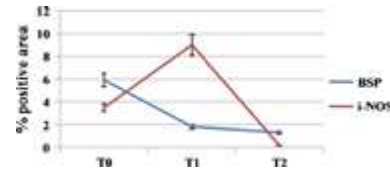
Finally, the apoptotic response of the host tissue was evaluated by TUNEL analysis. Apoptotic nuclei percentage results higher in the  $T_1$  sample, whereas in the  $T_0$  and  $T_2$  samples, the apoptotic nuclei percentage is lower and compatible with physiological values (Fig. 6).

**DISCUSSION**

Implant treatment for some patients would not be an option without horizontal or vertical bone augmentation. In the literature, autologous bone grafts are considered as the criterion standard, with high biologic and mechanical properties.<sup>33,34</sup> Extraoral



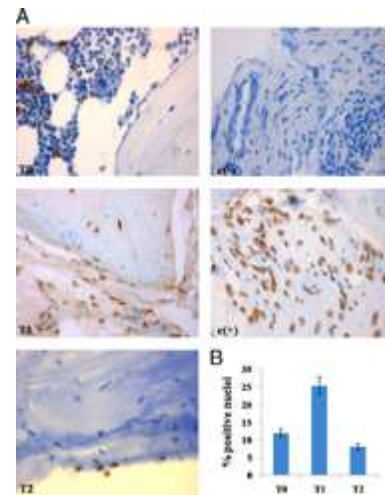
**FIGURE 4.** Graphic representation of densitometric analysis of MMP-2 and VEGF-positive area determined by direct visual counting of 10 fields for each of 5 slides per sample at  $\times 20$  magnification (mean values  $\pm$  SD) ( $P < 0.05$ ).



**FIGURE 5.** Graphic representation of densitometric analysis of BSP and iNOS-positive area determined by direct visual counting of 10 fields for each of 5 slides per sample at  $\times 20$  magnification (mean values  $\pm$  SD) ( $P < 0.05$ ).

grafts allow to obtain a large amount of bone tissue with a good cortical/cancellous bone ratio. According to bone graft embryological derivation and to microarchitecture, many authors agree that calvarial bone has a minimal resorption rate, a good biologic integration, and a more predictable clinical outcome when used for reconstructing atrophic jaw.<sup>35-37</sup>

On the other hand, other authors state that, despite the embryologic origin, the number of cortical layers and the microscopic architecture of the tissue harvested are the only variables that may affect clinical success of the bone graft.<sup>38,39</sup> The use of autologous bone graft could be accompanied by the risk of intraoperative complications: postoperative temporary or permanent patient morbidity. The incidence of complications may vary according to the donor site, to the patient's age and general conditions, to the surgical technique used, and to the surgeon's ability.<sup>12,40</sup> Because of its easy accessibility, availability of a large quantity of bone compared with other donor sites, good quality, and low donor site morbidity, the iliac crest could be considered a good source for harvesting bone grafts.<sup>14</sup> In our study,



**FIGURE 6.** A, Detection of apoptotic nuclei in  $T_0$ ,  $T_1$ , and  $T_2$  samples by TUNEL; positive nuclei are brown, negative ones are blue. Original magnification,  $\times 40$ . B, Graphical representation of TUNEL analysis. Five slides were examined per sample. Apoptotic cells were counted of a total of 100 cells and expressed as percentage. Values represented in the graph are mean  $\pm$  SD.  $n = 3$  for all groups.

iliac crest bone blocks were used as onlay grafts to reconstruct posterior maxilla, whereas bone chips harvested from the same donor sites were used for maxillary sinus filling to replace bone height reduced by early tooth loss. Onlay grafts have been successfully used in the correction of the bone defects in edentulous ridges; however, a considerable resorption of the graft before implant insertion has been reported.<sup>41</sup> Several studies report a 50% average volume loss of grafted iliac crest for onlays<sup>42,43</sup>; only for iliac crest grafts onlay-positioned in the posterior maxilla did a study report smaller percentage of resorption (16%).<sup>44</sup> In our study, we found a moderate resorption of the graft after 4 months, when implant insertion occurs, although no significant difference could be noticed in bone height between  $T_1$  and  $T_2$ , probably indicating that implant insertion is fundamental to ensure long-period volume maintenance of the graft. According to previous reports,<sup>45-47</sup> the survival and success rates of implants placed in grafted bone, along with the peri-implant bone resorption recorded during the follow-up period, do not show significant differences with those inserted in native bone. Otherwise, the early bone loss detected could be associated to a major difficulty in soft tissue management in onlay reconstruction, which is often associated to an elevate risk of dehiscence with subsequent necrosis or infection of the graft.

To evaluate the graft integration with host tissue after short and long periods, we investigated samples obtained from sites reconstructed by iliac crest bone graft after approximately 4 months ( $T_1$ ) and after approximately 10 years ( $T_2$ ), in comparison to iliac crest samples obtained from donor sites at the moment of withdrawal for the grafting ( $T_0$ ).

As the graft integration requires, in the initial phase, ECM resorption and new blood vessel formation, the regenerative response was evaluated by investigating MMP-2, VEGF, BSP, and iNOS expression.

The 72-kd type IV collagenase, also known as MMP-2, plays an important functional role in the development of new blood vessels by degrading endothelial basement membrane and ECM collagen, thereby supplying adequate space for endothelial cell proliferation. In this research, its expression is well appreciated in  $T_1$  samples, sustaining its involvement in the phase of graft integration. This behavior could be related to morphologic structure revealed by hematoxylin and eosin staining. In fact, after 4 months, samples obtained from the grafted areas show a possible presence of remodeling phenomena, thus explaining a more intense angiogenic activity in  $T_1$  samples. These phenomena are otherwise less evident in  $T_0$  and  $T_2$  samples, where the situation is not dynamic, showing a predominance of connective or mineralized tissue.

As VEGF plays an important role in the maintenance and development of endothelial fenestrations and in endothelial survival,<sup>23,25</sup> the higher expression of both MMP-2 and VEGF in  $T_1$  samples, compared with  $T_0$  and  $T_2$  samples, suggests that, after approximately 4 months, the integration of the grafts needs the synthesis of new blood vessel formation.

Unlike angiogenic processes, which are highly evident in  $T_1$  samples, BSP labeling, detecting new bone formation areas,<sup>26,27</sup> highlights few osteogenic sites, both in  $T_1$  and  $T_2$  samples. This suggests insufficient and weak osteogenic events also during the tissue remodeling phase ( $T_1$ ). Furthermore, the inflammation process, indicated by iNOS expression, a molecule expressed in response to endotoxins and to inflammatory cytokines,<sup>30,31</sup> is shown to undergo an evident increase from the  $T_0$  condition to the  $T_1$  one and to return after 10 years from the graft insertion, showing a strong and unexpected reaction concerning the host tissue during the remodeling phase and allowing us to hypothesize evident inflammatory events during the integration process. In parallel, the biologic effect, measured by TUNEL analysis of apoptotic cells, supports this hypothesis, showing the highest number of apoptotic nuclei in the  $T_1$  sample.

All in all, these results, even considering the great amount of samples, the easy withdrawing possibility, the good bone quality and the discreet integration due to the good vascularization but not supported by new bone synthesis, suggest that the iliac crest bone graft is not an ideal solution, especially when compared with calvaria bone graft for the cell viability performance, as reported in our previous study.

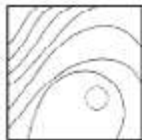## REFERENCES

- Chiapasco M, Casentini P, Zaniboni M. Bone augmentation procedures in implant dentistry. *Int J Oral Maxillofac Implants* 2009;24:237-259
- Hallman M, Mordenfeld A, Strandkvist T. Bone replacement following dental trauma prior to implant surgery—status. *Dent Traumatol* 2009;25:2-11
- Esposito M, Grusovin MG, Rees J, et al. Interventions for replacing missing teeth: augmentation procedures of the maxillary sinus. *Cochrane Database Syst Rev* 2010;3:CD008397
- Esposito M, Grusovin MG, Felice P, et al. Interventions for replacing missing teeth: horizontal and vertical bone augmentation techniques for dental implant treatment. *Cochrane Database Syst Rev* 2009;4:CD003607
- Jensen SS, Terheyden H. Bone augmentation procedures in localized defects in the alveolar ridge: clinical results with different bone grafts and bone-substitute materials. *Int J Oral Maxillofac Implants* 2009;24:218-236
- Mangano C, Scarano A, Iezzi G, et al. Maxillary sinus augmentation using an engineered porous hydroxyapatite: a clinical, histological, and transmission electron microscopy study in man. *J Oral Implantol* 2006;32:122-131
- Triplet RG, Schow SR. Autologous bone grafts and endosseous implants: complementary techniques. *J Oral Maxillofac Surg* 1996;54:486-494
- Cuesta Gil M, Bucci T, Duarte Ruiz B, et al. Reconstruction of the severely atrophic mandible using autologous calvarial bone graft: an “inverted sandwich” graft technique and dental rehabilitation with fixed implant-supported prostheses. *J Craniomaxillofac Surg* 2009;38:379-384
- Crespi R, Vinci R, Cappare P, et al. Calvarial versus iliac crest for autologous bone graft material for a sinus lift procedure: a histomorphometric study. *Int J Oral Maxillofac Implants* 2007;22:527-532
- Bianchi AE, Vinci R, Torti S, et al. Atrophic mandible reconstruction using calvarial bone grafts and implant-supported overdentures: radiographic assessment of autograft healing and adaptation. *Int J Periodontics Restorative Dent* 2004;24:334-343
- Lizuka T, Smolka W, Hallermann W, et al. Extensive augmentation of the alveolar ridge using autogenous calvarial split bone grafts for dental rehabilitation. *Clin Oral Implants Res* 2004;15:607-615
- Grillon GL, Gunther SF, Connole PW. A new technique for obtaining iliac bone grafts. *J Oral Maxillofac Surg* 1984;42:172-176
- Nkenke E, Weisbach V, Winckler E, et al. Morbidity of harvesting of bone grafts from the iliac crest for preprosthetic augmentation procedures: a prospective study. *Int J Oral Maxillofac Surg* 2004;33:157-163
- Schaaf H, Lendeckel S, Howaldt HP, et al. Donor site morbidity after bone harvesting from the anterior iliac crest. *Oral Surg Oral Med Oral Pathol Oral Radiol Endod* 2010;109:52-58
- Ishii S, Shishido F, Miyajima M, et al. Imaging findings at the donor site after iliac crest bone harvesting. *Skeletal Radiol* 2010;39:1017-1023
- Faria PE, Okamoto R, Bonilha-Neto RM, et al. Immunohistochemical, tomographic and histological study on onlay iliac grafts remodeling. *Clin Oral Implants Res* 2008;19:393-401
- Amâlinei C, Câruntu ID, Bălan RA. Biology of metalloproteinases. *Rom J Morphol Embryol* 2007;48:323-334
- Nguyen M, Arkell J, Jackson CJ. Human endothelial gelatinases and angiogenesis. *Int J Biochem Cell Biol* 2001;33:960-970
- Holmes K, Roberts OL, Thomas AM, et al. Vascular endothelial growth factor receptor-2: structure, function, intracellular signalling and therapeutic inhibition. *Cell Signal* 2007;19:2003-2012

20. Birkedalhansen H. Role of matrix metalloproteinases in human periodontal diseases. *J Periodontol* 1993;64:474-484
21. Cawston TE, Young DA. Proteinases involved in matrix turnover during cartilage and bone breakdown. *Cell Tissue Res* 2010;339:221-235
22. Winder T, Lenz HJ. Vascular endothelial growth factor and epidermal growth factor signaling pathways as therapeutic targets for colorectal cancer. *Gastroenterology* 2010;138:2163-2176
23. Yokomori H, Oda M, Yoshimura K. Vascular endothelial growth factor increases fenestral permeability in hepatic sinusoidal endothelial cells. *Liver Int* 2003;23:467-475
24. Darland DC, Massingham LJ, Smith SR, et al. Pericyte production of cell-associated VEGF is differentiation-dependent and is associated with endothelial survival. *Dev Biol* 2003;264:275-288
25. Kamba T, Tam BY, Hashizume H, et al. VEGF-dependent plasticity of fenestrated capillaries in the normal adult microvasculature. *Am J Physiol Heart Circ Physiol* 2006;290:H560-H576
26. Coleman R, Brown J, Terpos E, et al. Bone markers and their prognostic value in metastatic bone disease: clinical evidence and future directions. *Cancer Treat Rev* 2008;34:629-639
27. Zhou HY, Takita H, Fujisawa R, et al. Stimulation by bone sialoprotein of calcification in osteoblast-like MC3T3-E1 cells. *Calcif Tissue Int* 1995;56:403-407
28. Chen J, Shapiro HS, Sodek J. Development expression of bone sialoprotein mRNA in rat mineralized connective tissues. *J Bone Miner Res* 1992;7:987-997
29. Raynal C, Delmas PD, Chenu C. Bone sialoprotein stimulates in vitro bone resorption. *Endocrinology* 1996;137:2347-2354
30. Beck KF, Eberhardt W, Frank S, et al. Inducible NO synthase: role in cellular signaling. *J Exp Biol* 1999;202:645-653
31. Kuhr F, Lowry J, Zhang Y, et al. Differential regulation of inducible and endothelial nitric oxide synthase by kinin B1 and B2 receptors. *Neuropeptides* 2010;44:145-154
32. Misch CE, Chiapasco M, Jensen OT. Indications for and classification of sinus bone grafts. In: Jensen OT ed. *The Sinus Bone Graft*. Chicago: Quintessence Publishing Co, 2006
33. Klijn R, Meijer G, Bronkhorst EM, et al. A meta-analysis of histomorphometric results and graft healing time of various biomaterials compared to autologous bone used as sinus floor augmentation material in humans. *Tissue Eng Part B Rev* 2010;16:493-507
34. Tetè S, Zara S, Vinci R, et al. Vascular endothelial growth factor and e-nitric oxide synthase-mediated regenerative response occurring upon autologous and heterologous bone grafts. *Int J Immunopathol Pharmacol* 2009;22:1105-1116
35. Kusiak JF, Zins JE, Whitaker LA. The early revascularization of membranous bone. *Plast Reconstr Surg* 1985;76:510-516
36. Wong RWK, Rabie ABM. A quantitative assessment of the healing of intramembranous and endochondral autogenous bone grafts. *Eur J Orthod* 1999;21:119-126
37. Tetè S, Vinci R, Zara S, et al. Atrophic jaw reconstruction by means of calvarial bone graft: long-term results. *J Craniofac Surg* 2010;21:1147-1152
38. Ozaki W, Buchman SR. Volume maintenance of onlay bone grafts in the craniofacial skeleton: micro-architecture versus embryologic origin. *Plast Reconstr Surg* 1998;102:291-299
39. Lu M, Rabie ABM. Quantitative assessment of early healing of intramembranous and endochondral autogenous bone grafts using micro-computed tomography and Q-Win image analyzer. *Int J Oral Maxillofac Surg* 2004;33:369-376
40. Joshi A, Kostakis GC. An investigation of post-operative morbidity following iliac crest graft harvesting. *Br Dent J* 2004;196:167-171
41. Schwartz-Arad D, Levin L, Sigal L. Surgical success of intraoral autogenous block onlay bone grafting for alveolar ridge augmentation. *Implant Dent* 2005;14:131-138
42. Johansson B, Grepe A, Wannfors K, et al. A clinical study of changes in the volume of bone grafts in the atrophic maxilla. *Dentomaxillofac Radiol* 2001;30:157-161
43. Vermeeren JJ, Wismeijer D, van Waas MA. One-step reconstruction of the severely resorbed mandible with onlay bone grafts and endosteal implants. A 5-year follow-up. *Int J Oral Maxillofac Surg* 1996;25:112-115
44. Sbordone L, Toti P, Menchini-Fabris GB, et al. Volume changes of autogenous bone grafts after alveolar ridge augmentation of atrophic maxillae and mandibles. *Int J Oral Maxillofac Surg* 2009;38:1059-1065
45. Aghaloo TL, Moy PK. Which hard tissue augmentation techniques are the most successful in furnishing bony support for implant placement? *Int J Oral Maxillofac Implants* 2007;22:49-70
46. Chiapasco M, Colletti G, Romeo E, et al. Long-term results of mandibular reconstruction with autogenous bone grafts and oral implants after tumor resection. *Clin Oral Implants Res* 2008;19:1074-1080
47. Sbordone L, Toti P, Menchini-Fabris G, et al. Implant survival in maxillary and mandibular osseous onlay grafts and native bone: a 3-year clinical and computerized tomographic follow-up. *Int J Oral Maxillofac Implants* 2009;24:695-703



## Microcomputed and Histologic Evaluation of Calvarial Bone Grafts: A Pilot Study In Humans



Raffaele Vinci, MD, DMD\*/Alberto Rebaudi, MD, DDS\*\*  
Paolo Capparè, MD\*\*\*/Enrico Gherlone, MD, DMD, PhD\*\*\*\*

Two evaluation techniques (histology and microcomputed tomography [micro-CT]) were synergistically applied to calvarial bone graft to verify whether additional bone information can be obtained for the assessment of bone grafts. Ten extensive bone defects in the anterior and posterior maxilla or mandible involving crestal bone were treated by grafted blocks and chips of autogenous calvarial bone. The grafts were fixed with lag screws and left to heal for 4 months. No complications were observed. At surgical reentry for implant placement, a cylindrical bone biopsy of both graft and native bone was retrieved and analyzed with both micro-CT and standard histology. Two- and three-dimensional (2D, 3D) micro-CT analyses allowed bone connectivity indices to be evaluated. This is useful for estimating bone strength and observing bone structure. The integration of the grafted calvarial bone with the residual bone of the recipient site was considered satisfactory. Histologic analysis allowed observations to be made at a higher resolution. Calvarial bone grafts seem to have positive effects when used as grafting materials. The application of both histologic and micro-CT techniques allows a better evaluation of grafted bone by concurrently allowing 2D and 3D visual and morphometric analysis of bone vitality, structure, turnover, and strength. (*Int J Periodontics Restorative Dent* 2011;31:e29–e36.)

\*Chief, Advanced Oral Surgery Unit, Department of Dentistry, Vita Salute University, San Raffaele Hospital, Milan, Italy.

\*\*Contract Professor, University of Genova, Genova, Italy; Vice President, Biomaterials Clinical-Histological Research Association, Genova, Italy.

\*\*\*Resident, Department of Dentistry, Vita Salute University, San Raffaele Hospital, Milan, Italy.

\*\*\*\*Full Professor and Chair, Department of Dentistry, Vita Salute University, San Raffaele Hospital, Milan, Italy.

Correspondence to: Dr Alberto Rebaudi, Piazza della Vittoria 8/12, Genova 16121, Italy; fax: +39 (0)10 564641; email: al.reb@tin.it.

Implant-supported prosthetic rehabilitation is frequently compromised by atrophy of the maxilla or mandible after tooth loss, trauma, or resection. Distraction osteogenesis has been proposed, but in severe atrophies, the osteotomy and anchorage sometimes cannot be properly executed.<sup>1</sup> Clinical success has been obtained in the posterior maxilla by grafting the sinus,<sup>2,4</sup> obtaining histologic evidence of new bone formation,<sup>5</sup> but sinus graft procedures do not coronally rebuild the vertical dimension of the bone crest.<sup>1</sup> Also, guided bone regeneration methods using reinforced membranes have been proposed,<sup>6</sup> but in extensive reconstruction, autogenous bone block grafting is considered the gold standard technique.<sup>7</sup> Several studies have reported that grafted bone blocks resorb rapidly<sup>8</sup>; however, membranous bone has been shown to be more effective than endochondral bone in maintaining volume.<sup>9</sup> Intraoral donor sites should be considered to retrieve membranous bone to rebuild small defects, whereas calvarium is a useful donor site for

other purposes.<sup>10</sup> In 1929, Dandy<sup>11</sup> grafted the orbital wall with autologous calvarial bone, while Tessier<sup>12</sup> and Tulasne et al<sup>13</sup> described various methods for harvesting and grafting parietal bone in maxillo-facial surgery. Boyne and Jamos<sup>4</sup> described sinus and alveolar ridge augmentation via bone blocks and chips harvested from the calvaria.

Dental research employs qualitative and quantitative morphometry for evaluating the bone integration of grafts, dental implants, biomaterials, and regenerative procedures.<sup>14</sup> Bone volume, bone structure, and several dynamic parameters can be assessed to evaluate the development of bone tissue during the healing period or when subjected to a functional load.<sup>15-17</sup> In addition to standard bone morphometric analysis, which is generally based on two-dimensional histologic sections, microcomputed tomography (micro-CT) outlines and quantifies bone, implants, and biomaterials in three dimensions.<sup>18-20</sup> The synergy between histologic and micro-CT analysis allows the examination of bone structure, tissue, and cells.<sup>19,20</sup> The development of grafted bone tissue has not been fully clarified from a biomechanical viewpoint, and questions remain regarding the reasons for bone graft resorption and differences in healing and maintaining volume, in particular between membranous and endochondral bone.<sup>21</sup> A three dimensional (3D) analysis of the bone graft and recipient bed could better clarify the biomechanical qualities, healing mechanisms, and development of grafted bone.

The aim of the present study was to use micro-CT in addition to histology for evaluating the bone biopsy of a grafted site.

### Method and materials

Ten patients in good general health requiring extensive bone reconstruction for the placement of dental implants (Fig 1a) received calvarial autogenous bone grafts in block form for complete reconstruction of the bone crest. Prior to treatment, all patients signed an informed consent form. In some patients, simultaneous maxillary sinus grafting with autogenous bone particles was performed. Bone grafts were harvested from the parietal bone using the split calvarial graft technique *in situ*.<sup>10,12</sup> Grafts were prepared so that the bone ridge could be rebuilt with lag screw fixation (Fig 1b) and left to heal for 4 months, completely covered by soft tissue. Temporary splints were not used in the edentulous region to prevent wound dehiscence. During healing, a surgical guide was prepared for correct positioning of the implants. Reentry was performed after 4 months (Fig 1c), and implants were placed in the grafted bone (Fig 1d). The grafted area was checked clinically and evaluated radiographically using endooral radiographs (panoramic and CT; Figs 2a and 2b). In one patient, at surgical reentry, a cylindrical bone biopsy of grafted and native bone was retrieved using a trephine bur along the implant insertion axis to perform micro-CT and histologic analysis. Thirty-two

rough endosseous titanium dental implants (3.7 to 5 mm in diameter, 10 to 13 mm in length; WINSIX, BioSAF)<sup>6</sup> were placed in the augmented areas. The implants healed submerged for 3 months before being progressively loaded with a provisional fixed partial denture.

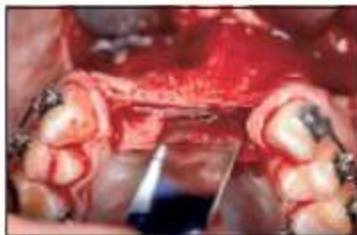
### Sample preparation

After retrieval, the biopsy was sent to Dr Paula Trisi, director of the laboratory of the Biomaterials Clinical Histological Research Association, Genova, Italy, and processed for micro-CT and histologic examination. The sample was initially fixed in 10% neutral buffered formalin and analyzed using 3D micro-CT (Scanco Medical). The specimen was then dehydrated in an ascending series of alcohol dilutions and embedded in Remacryl resin (Cesare Scala). After polymerization, micro-CT analysis was performed, and later, the specimen was processed into thin ground sections for histologic examination.

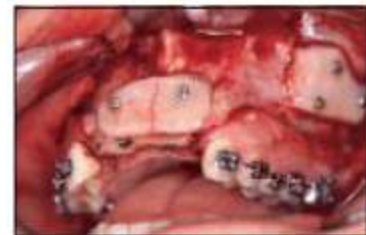
### Micro-CT processing

A high-resolution microtomography system (microCT-40, Scanco Medical) was used in multislice mode. Each 3D image data set consisted of approximately 400 micro-CT slice images (1,024 × 1,024 pixels with 16-bit gray levels).<sup>19,20</sup> The specimen was scanned in high resolution mode with an x, y, and z resolution of approximately 20 µm.

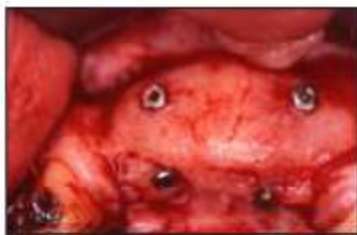



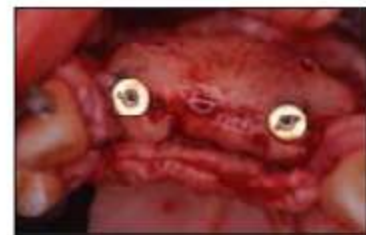**Fig 1a (left)** Clinical view of the surgical area. In this patient, bone atrophy following trauma caused extreme resorption of the crestal maxillary bone, requiring extensive vertical and lateral bone reconstruction.



**Fig 1b (right)** Surgical phase of bone reconstruction with calvarial bone grafts prepared to rebuild the bone ridge through lag screw fixation. Grafts were harvested from the parietal bone using the split calvarial graft technique in situ, which allowed sufficient bone to be harvested for an extensive maxillary reconstruction.



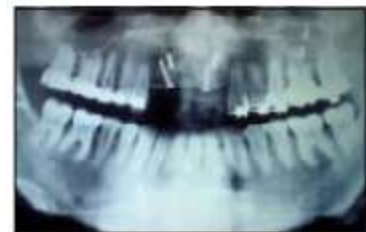**Fig 1c (left)** Reentry procedure. The calvarial graft appeared well integrated and firm, with no visible signs of resorption.



**Fig 1d (right)** During reentry, two implants were placed, and primary stability was obtained.



**Fig 2a (left)** CT scan performed 4 months after implant placement showed good integration of the grafts and implants. It also showed that the rebuilt alveolar bone crest of the treated area had the typical anatomy of normal maxillary bone.



**Fig 2b (right)** Panoramic radiograph 4 months after implant placement.

The voxel size was  $15 \times 15 \times 15 \mu\text{m}^3$ . Scanning time was approximately 4 hours.

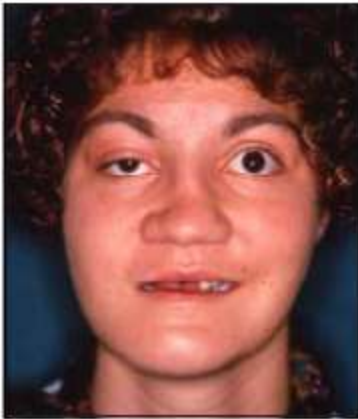#### *Histologic processing*

After micro-CT scanning, the specimen was sectioned into 200- to 250- $\mu\text{m}$  sections with a Micromet

high-speed rotating blade microtome and subsequently ground to approximately 40 to 50  $\mu\text{m}$  using an LS2 grinding machine (Pace Technologies). A routine stain with toluidine blue and acid fuchsin was applied to the slides. Three sections of the biopsy were produced, and histomorphometric analysis was conducted by digitizing the

microscope images via a JVC TK-C1380 Colour Video Camera (JVC Victor) and a frame grabber. Routine analysis of the digitized images followed, using the image analysis software IAS 2000 (Delta Sistemi). The images were acquired using a 5 $\times$  lens.

e32



**Fig 3a** (left) Photograph of a treated patient 1 year after an accident that caused facial trauma and bone atrophy (photograph taken prior to surgical treatment).

**Fig 3b** (right) Photograph of the treated patient 9 months after surgical and prosthetic treatment.



### Morphometric measurements

The morphometric parameters calculated with micro-CT and histology were: total volume (TV), bone volume (BV), relative bone volume (BV/TV), connectivity density, trabecular number, trabecular thickness, and trabecular separation. The morphometric values obtained with micro CT were compared with those obtained by standard histomorphometric analysis. Micro-CT measurements were calculated using the mean of the values obtained from 400 slices (sections), while the histomorphometric measurements were calculated using the mean values of the 3 sections of the sample.

### Results

#### Clinical findings

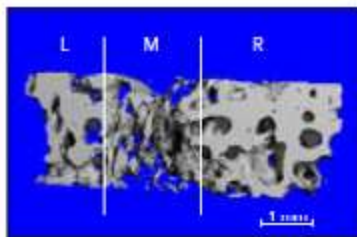
The 4-month healing period yielded no complications for any grafting procedure. Upon clinical and radiographic examination, the healed bone grafts appeared to be well integrated and in tight contact with the recipient buccal plate. Implant surgery in the grafted sites was successful, and after 4 months, bone density evaluated by hand drilling appeared mostly medium/normal (D2 to D3) or hard (D1), and all implants placed in the grafted sites presented good primary stability. The autogenous bone chips used as filling material for the minor defects between bone blocks and the recipient bone plate appeared to be incorporated within the newly formed

alveolar ridge. At periodic recalls after implant loading, radiographic bone loss was not observed to be excessive, and clinical signs of failure were absent. The 3D reconstruction of the sequence on CT images from the micro-CT analysis allowed the correlation of the 2D section with the 3D structures. After 6 months of submerged healing, a definitive ceramic prosthesis was placed. All patients showed good functional and esthetic results (Figs 3a and 3b).

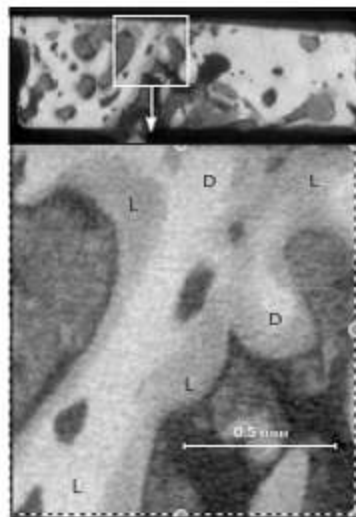
#### Micro-CT histologic and histomorphometric results

Morphometric results of the bone micro-CT evaluation were as follows: TV = 31.80 mm<sup>3</sup>, BV = 12.25 mm<sup>3</sup>, BV/TV = 38.50%, and connectivity density = 485.42 mm<sup>3</sup>.





**Fig 4** 3D micro-CT reconstruction of the antine biopsy retrieved from the grafted area. Morphologic 3D analysis allowed observation of the dense bone of the graft on the left (L), the thin trabeculae of the junction between native bone and graft in the middle (M), and the thick trabeculae of the native bone on the right (R). In the junction, thin trabeculae of woven bone connected the graft to the recipient site. In this portion of the sample, several bone fragments are also evident (original magnification  $\times 10$ ).



**Fig 5a (left)** Native bone was denser when compared to grafted bone. New bone apposition during the healing period at both native and grafted bone was evident, especially in the cancellous bone of the junction between native bone and graft (original magnification  $\times 10$ ). In fact, at higher magnification (white outline, magnification  $\times 20$ ), it is possible to clearly see less mineralized younger bone (L) apposing older bone (D).

**Fig 5b (above)** Micro-CT 2D evaluation showing thin trabeculae of a low density, a possible expression of thin woven bone trabeculae similar to that found in bone fractures healing through a callus formation. Fragments of bone are also visible both in the central and in the grafted portions (right side of biopsy), probably autogenous cancellous chips of the graft (original magnification  $\times 10$ ).

#### Morphologic description of 2D and 3D micro-CT images

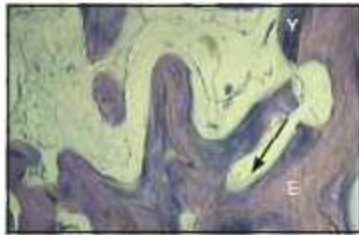
Visual assessment of the bony structure obtained by micro-CT produced several 2D slices and a 3D computed reconstruction of the specimens. The 3D micro-CT reconstruction gave a precise representation of the bony trabeculae and allowed visual exploration of the bone microarchitecture in every part of the biopsy. A 3D reconstruction of the maxillary bone and calvarial grafts was obtained; morphostructural micro-CT investigation showed satisfactory integration of the grafts, with similar structure to native bone. Biopsies showed a similar dense structure in both basal bone and grafts connected in the middle by cancellous bone composed of thin

trabeculae and large medullary spaces (Fig 4).

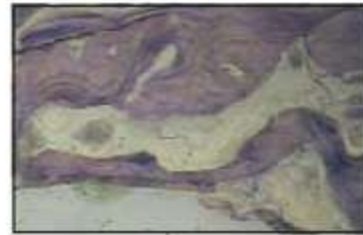
The 2D slices showed that the structure of the grafted bone was very similar to that of native bone. In nature, the bony structure of calvarial bone is often similar to the structure of maxillary bone. Native bone was slightly denser on radiographs if compared to the grafted bone. Many of the trabecular surfaces on both sides of the biopsy were covered with newly formed bone, confirmed by the cementing lines visible in the micro-CT 2D sections. New bone apposition both at the native and grafted bone areas was also evident, especially in the cancellous bone at the junction between bone and graft (Fig 5a). The 2D micro-CT analysis showed a dense structure composed of thick trabeculae well connected to

each other by bone bridges both in the grafted area and in the native bone. Radiopaque particles that were probably autogenous calvarial chips were evident in contact with mineralized bone or in the marrow in some slices (Fig 5b). The mineralized bone, as measured by micro-CT, occupied 61.50% of the total space of the biopsy. At the interface between native bone and graft, very thin trabeculae of a low radiographic density were present, a possible expression of the thin woven bone trabeculae that usually characterize bone healing fractures with a scar. Histologic analysis confirmed the micro-CT observations. Remodeling took place both in recipient sites and grafted sites of the sample (Fig 6). Layers of osteoid matrix covered at least 30% of the bone surface.

e34



**Fig 6a** (left) Histology confirmed the presence of younger bone (Y) and osteoid (arrow), revealing active bone remodeling and new bone apposition to pre-existing trabeculae in the grafted bone. C – native bone. (original magnification  $\times 25$ ).



**Fig 6b** (right) Histology also showed younger bone and osteoid in recipient sites. Both native bone and graft revealed similar bone remodeling patterns (original magnification  $\times 25$ ).

## Discussion

Loads applied in the posterior maxilla are heavy, but the bone is often soft in quality and lacking in quantity.<sup>22</sup> Bone rebuilding of the atrophic posterior maxilla, according to functional and esthetic requirements, needs good bone quality and quantity for safe implant placement. Sinus grafting, bone regeneration, and osteodistraction procedures have been proposed but are limited to select favorable cases; the mechanical properties of the newly formed bone are often low, even after several months of healing.<sup>1</sup> The quality of newly formed bone depends on an undisturbed healing period<sup>6,23</sup> and on the density of the pre-existing bone.<sup>24</sup> In the case of severe skeletal alterations, autologous bone grafts may be a suitable alternative.<sup>8</sup> Good intrinsic mechanical properties of bone grafts are able to avoid the risk of micromovements of fixation screws, grafts, and implants throughout the healing period during either bone reconstruction or implant osseointegration.

Several studies described graft resorption<sup>7,25-27</sup> as related to its microarchitecture<sup>9</sup>: Calvarial graft seems to be ideal because of its corticocancellous ratio. Histology and micro-CT techniques in other animal studies evaluated the healing period of calvarial grafts: Viability of bone tissue and good incorporation into the recipient bed were demonstrated.<sup>28,29</sup> CT scans<sup>3</sup> and panoramic and retromolar radiographs<sup>30</sup> are useful techniques to evaluate volume and density of calvarial bone grafts; physiologic bone adaptation during both graft healing and implant loading was found.

Preservation of calvarial graft volume was claimed to be related to functional loading through correct rebuilding of the bone crest and implant placement<sup>3,28-31</sup>: Bone resorption seemed to be avoided by applying physiologic strain through load application.<sup>17,24</sup> According to the literature, other factors involved in bone graft maintenance include periosteal preservation, distribution of mechanical forces, and interaction between microarchitectural features of bone graft and local

mechanical environment.<sup>21,21</sup> According to the results of this study, survival was optimal when bone grafts closely duplicated the architecture of the recipient bed.<sup>31,32</sup> Previously published studies observed that the thick and compact cortical layer forming the membranous bone allowed lag screw fixation, gradual revascularization with more controlled resorption, and better new bone formation in comparison to endochondral bone grafts.<sup>31-33</sup> Lag screws seem to decrease bone graft stress and increase graft-to-recipient bone contact; graft fixation and absence of micromotion result in low-strain conditions, which minimize the early resorption phase of creeping substitution as well as stimulate direct intracortical remodeling and lamellar bone production.<sup>33-35</sup> With interfragmentary motion, lamellar ossification is not possible,<sup>35</sup> such as with large bone defects where connective tissue does not differentiate in bone tissue. Membranous bone heals with more and thicker trabeculae and lower connectivity than endochondral bone.<sup>36</sup> Osteogenic cells with



no cartilaginous stage characterized integration of the intramembranous bone graft.<sup>37,38</sup>

Histomorphologic and micro-CT studies have demonstrated that integration of intramembranous bone grafts within membranous bone defects is better than endochondral grafts.<sup>27,39</sup> The results of this study suggest that fixed autogenous calvarial grafts are a suitable alternative to rebuild most challenging cases of large bony defects because of their characteristics and the greater quantity of bone available in the form of blocks and chips. One of the most interesting histologic observations in this study was that the 3D structure of grafted bone was very similar to that of the native bone. The 3D architecture of the bone graft after healing could explain its mechanical competence, positive clinical behavior, and the short healing time needed for dental implants.

Feldkamp et al<sup>18</sup> introduced a radiographic micro-CT system to create 3D images. More recent developments<sup>40</sup> have allowed higher-resolution 3D images and quantitative measurements.<sup>19</sup> Micro-CT was validated as a method for the 3D assessment and analysis of cancellous bone by Müller et al in 1998.<sup>41</sup> Recent studies have introduced micro-CT for dental implant research.<sup>19,20</sup> The mechanical properties of bone largely depend on its 3D structure,<sup>31,41</sup> which is measured by bone volume and connectivity indexes. In the field of bone reconstruction for dental implant rehabilitation, the ultimate goal of any clinical bone measurement is to estimate

bone strength.<sup>19,20</sup> For this reason, it is important to quantify bone microarchitecture using a 3D technique, such as micro-CT 3D analysis.

In all patients treated in this study, the quantity and quality of bone obtained can be considered, from a clinical viewpoint, ideal for an esthetic and functional rehabilitation. Moreover, the biopsy performed confirmed the observation of a medium/normal bone quality (D2 to D3),<sup>23</sup> with values of BV around 38% obtained 3 to 4 months after calvarial grafting. Medium/normal bone is considered ideal for predictable implant placement,<sup>23</sup> and the obtained values of BV can be considered satisfying. Recent studies have confirmed that bone volume is related to expected bone-implant contact.<sup>42</sup> Connectivity indexes calculated using micro-CT have also indicated that grafted bone is strong enough for implant placement. Histologic analysis has demonstrated grafted bone to be bound through physiologic functional processes to bone homeostasis.

### Conclusion

Micro-CT may help investigate the relative importance of bone architecture after calvarial bone grafting as a better index of bone strength. Histology allows the soft tissues and cells to be evaluated so as to verify the integration and vitality of the grafted bone. The synergy between histology and micro-CT may lend improvement to present knowledge in this field.

### Acknowledgments

This study was conducted under a grant from the nonprofit foundation Biomaterials Clinical Research Association. The authors wish to thank Dr Paolo Trisi and Mrs Gabriella Tommasina Paolnelli for the histologic and histomorphometric analyses and Dr Angelo Itri for his help.

### References

1. Simion M. Distraction osteogenesis vs onlay bone grafts and guided bone regeneration: What we know and what we suppose. *J Oral Maxillofac Surg* 2002; 60:722.
2. Tatum II Jr. Maxillary and sinus implant reconstructions. *Dent Clin North Am* 1986; 30:207-229.
3. Tulasne JF. Sinus grafting with calvarial bone. In: Jensen OT. *The Sinus Bone Graft*. Chicago: Quintessence, 1999:12-44.
4. Boyne PJ, James RA. Grafting of the maxillary sinus floor with autogenous marrow and bone. *J Oral Surg* 1980;30:613-610.
5. Wallace SS, Froum SJ, Tarnow DP. Histologic evaluation of sinus elevation procedure: A clinical report. *Int J Periodontics Restorative Dent* 1996;16:47-51.
6. Simion M, Fontana F, Kasperini G, Maiorana C. Long-term evaluation of osseointegrated implants placed in sites augmented with sinus floor elevation associated with vertical ridge augmentation: A retrospective study of 38 consecutive implants with 1 to 7 year follow up. *Int J Periodontics Restorative Dent* 2004; 24:208-221.
7. Tessier P, Kawamoto H, Matthews D, et al. Autogenous bone grafts and bone substitutes—Tools and techniques. I. A 20,000-case experience in maxillofacial and craniofacial surgery. *Plast Reconstr Surg* 2005;116(suppl):6S-24S.
8. Tolman DE. Reconstructive procedures with endosseous implants in grafted bone: A review of the literature. *Int J Oral Maxillofac Implants* 1995;10:275-294.
9. Ozaki W, Buchman SR, Goldstein SA, Fyhrie DP. A comparative analysis of the microarchitecture of cortical membranous and cortical endochondral onlay bone grafts in the craniofacial skeleton. *Plast Reconstr Surg* 1999;104:139-147.



10. Tessier P, Kawamoto H, Posnick J, Raulo Y, Tulasne JF, Wolfe SA. Taking calvarial grafts, either split in situ or splitting of the parietal bone flap *ex vivo*—Tools and techniques: V A 9650—case experience in craniofacial and maxillofacial surgery. *Plast Reconstr Surg* 2005;116(suppl):545–715.
11. Dandy WE. An operative treatment for certain cases of meningocele (or encephalocele) into the orbit. *Arch Ophthalmol* 1929;2:123–127.
12. Tessier P. Autogenous bone grafts taken from the calvarium for facial and cranial applications. *Clin Plast Surg* 1982;9:531–538.
13. Tulasne JF, Saade J, Riachi A. Greffe osseuse du sinus maxillaire et implants de Branemark. *Implant* 1993;5:11.
14. Garetto LP, Chen J, Parr JA, Roberts WE. Remodeling dynamics of bone supporting rigidly fixed titanium implants: A histomorphometric comparison in four species including humans. *Implant Dent* 1995;4:235–243.
15. Frost HM. The skeletal intermedullary organization. *Metab Bone Dis Relat Res* 1983;4:281–290.
16. Parfitt AM, Mathews CH, Villanueva AR, Kleerekoper M, Frame B, Rao DS. Relationships between surface, volume, and thickness of iliac trabecular bone in aging and in osteoporosis. Implications for the micro-anatomic and cellular mechanisms of bone loss. *J Clin Invest* 1983;72:1396–1409.
17. Insi P, Rebaudi A. Progressive bone adaptation of titanium implants during and after orthodontic load in humans. *Int J Periodontics Restorative Dent* 2002;22:31–43.
18. Feldkamp LA, Goldstein SA, Parfitt AM, Jasion G, Kleerekoper M. The direct examination of three-dimensional bone architecture *in vitro* by computed tomography. *J Bone Miner Res* 1989;4:3–11.
19. Insi P, Rebaudi A, Calvari F, Lazzara RJ. Sinus graft with biogran, autogenous bone, and PRP: A report of three cases with histology and micro-CT. *Int J Periodontics Restorative Dent* 2006;26:113–125.
20. Rebaudi A, Trisi P. Microcomputed tomographic analysis of the peri-implant bone. *Int J Periodontics Restorative Dent* 2004;24:316–325.
21. Ozaki W, Buchman SR. Volume maintenance of onlay bone grafts in the craniofacial skeleton: Microarchitecture versus embryologic origin. *Plast Reconstr Surg* 1998;112:8291–299.
22. Misch CE, Judy KW. Classification of the partially edentulous arches of implant dentistry. *Int J Oral Implantol* 1987;4:7–13.
23. Rebaudi A, Trisi P, Cella R, Cecchini G. Preoperative evaluation of bone quality and bone density using a novel CT/microCT-based hard-normal-soft classification system. *Int J Oral Maxillofac Implants* 2010;25:75–85.
24. Trisi P, Rao W, Rebaudi A, Fiore P. Histologic effect of pure-phase beta-tricalcium phosphate on bone regeneration in human artificial jawbone defects. *Int J Periodontics Restorative Dent* 2002;23:69–77.
25. Carinci F, Farina A, Zanetti U, et al. Alveolar ridge augmentation: A comparative longitudinal study between calvaria and iliac crest bone grafts. *J Oral Implantol* 2005;31:39–45.
26. Bell RB, Blakey GH, White RP, Hillebrand DG, Molina A. Staged reconstruction of the severely atrophic mandible with autogenous bone graft and endosteal implants. *J Oral Maxillofac Surg* 2002;60:1135–1141.
27. Vinci R, Torti S, Bianchi AE, Zanaboni M. Iliac vs calvarial bone graft in pre-implant surgery of the atrophic maxilla [abstract]. *J Craniomaxillofacial Surg* 2000;28:154.
28. Vinci R, Bianchi AE, Torti S. L'impiego della calvaria nella chirurgia pre-implantologica (rapporto preliminare). *La chirurgia ricostruttiva oro-maxillo-facciale (Societa' italiana di chirurgia maxillofacciale)*. Milano, G.De Nicola Edizioni, 2001;1:87–99.
29. Orsini G, Bianchi AE, Vinci R, Piattelli A. Histologic evaluation of autogenous calvarial bone in maxillary onlay bone grafts: A report of 2 cases. *Int J Oral Maxillofac Implants* 2003;18:594–598.
30. Bianchi AE, Vinci R, Torti S, Sanfilippo F. Atrophic mandible reconstruction using calvarial bone grafts and implant-supported overdentures: Radiographic assessment of autograft healing and adaptation. *Int J Periodontics Restorative Dent* 2004;24:334–343.
31. Vinci R. Bone grafts taken from the calvarium. In: Khoury F, Antoun H, Missika P. *Bone Augmentation in Oral Implantology*. Chicago: Quintessence, 2007:213–240.
32. Kusiak JF, Zins JE, Whitaker LA. The early revascularization of membranous bone. *Plast Reconstr Surg* 1985;76:510–516.
33. Phillips JH, Rahn BA. Fixation effects on membranous and endochondral onlay bone graft revascularization and bone deposition. *Plastic Reconstr Surg* 1990;85:871–877.
34. Phillips JH, Rahn BA. Fixation effects on membranous and endochondral onlay bone-graft resorption. *Plastic Reconstr Surg* 1988;82:872–877.
35. Prein J. *Manual of Internal Fixation in the Cranio-facial Skeleton*. Berlin: Springer, 1998.
36. Zins JE, Whitaker LA. Membranous versus endochondral bone: Implications for craniofacial reconstruction. *Plast Reconstr Surg* 1983;72:178–185.
37. Rabie AB, Lie Ken Jie RK. Integration of endochondral bone grafts in the presence of demineralized bone matrix. *Int J Oral Maxillofac Surg* 1996;25:311–318.
38. Rabie AB, Wong RW, Hägg U. Composite autogenous bone and demineralized bone matrices used to repair defects in the parietal bone of rabbits. *Br J Oral Maxillofac Surg* 2000;38:565–570.
39. Lu M, Rabie ABM. Quantitative assessment of early healing of intramembranous and endochondral autogenous bone grafts using micro-computed tomography and Q-win image analyzer. *Int J Oral Maxillofac Surg* 2004;33:369–376.
40. Hildebrand T, Rüeggsegger P. Quantification of bone microarchitecture with the Structure Model Index. *Comput Methods Biomech Biomed Engin* 1997;1:15–23.
41. Müller R, Van Campenhout H, Van Damme B, et al. Morphometric analysis of human bone biopsies. A quantitative structural comparison of histological sections and micro-computed tomography. *Bone* 1998;23:59–66.
42. Trisi P, Lazzara R, Rao W, Rebaudi A. Bone-implant contact and bone quality: Evaluation of expected and actual bone contact on machined and osseointegrated implant surfaces. *Int J Periodontics Restorative Dent* 2002;22:535–545.

# LAVORI ORIGINALI

RICERCA

## Valutazione istologica, istomorfometrica e microtomografica dell'osteointegrazione di impianti con scaffolds nanostrutturati

Paolo Capparé  
Antonio Apicella  
Alberto Barlattani  
Fernando Zarone  
Roberto Crespi  
Enrico Gherlone

### INTRODUZIONE

L'osteointegrazione di impianti dentali è fondamentale per il successo nelle riabilitazioni implantoprotesiche.

La superficie di interfaccia tra osso e titanio ormai da diversi anni è oggetto di studio, poiché si sta tentando di passare dall'utilizzo di materiali bioinerti a materiali bioattivi. Analisi istologiche condotte fino ad oggi non permettono di avvalorare teorie circa un contatto osso-impianto attraverso sistemi giunzionali o altro. Tuttavia è stata rilevata una continuità a livello degli osteociti a diretto contatto con la superficie, attraverso i canali osteocitari: immagini al SEM documentano la loro presenza.

Biomateriali bioattivi potrebbero favorire e potenziare la differenziazione verso il fenotipo osteoblastico che avviene durante la guarigione della ferita chirurgica provocata dall'impianto, così da avere una migliore osteointegrazione in tempi molto più brevi. Recenti studi documentano le caratteristiche di composti nanostrutturati i quali sembrerebbero favorire l'osteointegrazione: nanostrutture di carbonio ed alluminio che mimano la geometria nanodimensionale dell'idrossiapatite, applicate ad impianti ortopedici, aumentano la attività osteoblastica e quindi aumentano la

Histologic, histomorphometric and microtomographic evaluation of the osseointegration of nanostructured scaffolds dental implants

### SCOPO DEL LAVORO

Valutare, mediante istologia, istomorfometria e microtomografia computerizzata, l'osteointegrazione a breve periodo di impianti dentali con superficie FCC, associati o meno a rivestimenti nanostrutturati.

### MATERIALI E METODI

Sono stati posizionati 24 impianti dentali a livello dell'epifisi prossimale tibiale di 6 conigli tipo "New Zealand White Rabbit". In ogni coniglio, sono stati posizionati su una tibia 2 impianti con superficie FCC (gruppo controllo) e, sul lato opposto, 2 impianti con superficie FCC e coating nanostrutturato (gruppo test). Gli animali sono stati sacrificati a 2, 4 e 12 settimane, e sono state eseguite delle biopsie tipo block section. Sono state quindi effettuate delle scansioni microtomografiche e delle analisi istologiche ed istomorfometriche, con l'obiettivo di studiare il contatto osso-impianto (BIC = Bone to Implant Contact).

### RISULTATI E CONCLUSIONI

La sopravvivenza degli impianti dentali è stata del 100%. In ogni caso, non si sono osservate complicanze a livello degli animali da esperimento. L'analisi istologica ha rilevato una crescita ossea che si è sviluppata in senso corono-apicale dal margine della corticale lungo la superficie dell'impianto, con un grado di maturazione e rivascolarizzazione progressiva. I campioni ottenuti a 12 settimane hanno presentato un elevato grado di maturazione ossea, sia in termini quantitativi che qualitativi. La microCT ha rilevato un BIC a 12 settimane del 53,40 ± 4,01 % per il gruppo controllo e del 56,62 ± 4,92 % per il gruppo test. L'impianto oggetto di studio ha mostrato notevoli qualità in termini di osteoconduzione e precocità dei tempi di guarigione, sia

con che senza coating nanostrutturato.

### AIM OF THE WORK

Histologic, histomorphometric and microtomographic evaluation of the osseointegration of FCC surface dental implants, with or without nanostructured coatings.

### MATERIALS AND METHODS

Twenty-four implants were positioned in the proximal tibial epiphysis of 6 New Zealand white rabbits. Each rabbit received, in a randomly selected side, 2 dental implant with FCC surface (control group), and, in the opposite side, 2 dental implants with FCC surface and nanostructured coating (test group). Animals were sacrificed at 2, 4 and 12 weeks from implants placement, and block section biopsies were obtained. Microtomographic, histologic and histomorphometric analyses were performed to measure the bone-to-implant contact (BIC).

### RESULTS AND CONCLUSION

Dental implants survival was 100%. No complications in animals were observed. Histologic analysis revealed a crown-apical bone growth, from the cortical edge along the implant surface, with a progressive bone maturation and revascularization. Samples obtained at 12 weeks revealed a good mature bone quantity and quality. At 12 weeks, microCT reported a BIC value of 53.40 ± 4.01 % for control group and 56.62 ± 4.92 % for test group. Dental implants used in the present study, demonstrated good osteoconductive properties and early healing period, with or without nanostructured coating.

MANIFATTURE / MICROE / BIOMATERIALI / BIOMEDICINA /  
MANUFACTURE / MICROE / BIOMATERIALS / BIOMEDICINE

<sup>1</sup> Università Vita Salute San Raffaele, Milano, Cattedra di Clinica Odontoiatrica e Corso di Laurea in Igiene Dentale, Presidente: Prof. E. Gherlone  
<sup>2</sup> Seconda Università di Napoli, Material Lab, Dipartimento di Cultura del Progetto  
<sup>3</sup> Università di Roma Tor Vergata, Insegnamento di Protesi Dentale, titolare: Prof. A. Barlattani  
<sup>4</sup> Università "Federico II" di Napoli, Insegnamento di Protesi Fissa, titolare: Prof. F. Zarone



SUPPLEMENTO DOCTOR DS MAGGIO 2011 VOL. XXII (5)

deposizione di osso. Altri studi hanno dimostrato come biomateriali nanostrutturati che mimano i cristalli di idrossiapatite favoriscono la proliferazione, l'adesione e la produzione di fosfatasi alcalina in cellule osteoblast-like. Lo stesso tipo di risultato si potrebbe ottenere attraverso lo sviluppo tecnologico di superfici implantari biomimetiche, che abbiano una sempre maggiore tendenza all'osteconduzione. Molti Autori hanno pubblicato studi che riportano una correlazione diretta tra l'utilizzo di superfici rugose ed un elevato contatto tra osso e impianto (parametro definito "BIC"). Altri recenti studi, effettuati sia in vitro che in vivo, mostrano come la rugosità di superficie favorisca l'adesione degli osteoblasti all'impianto, oltre a promuovere la loro differenziazione e la produzione di matrice extracellulare mineralizzata. L'analisi SEM di impianti con superficie Full

Contact Covering (FCC) ha mostrato, a basso ingrandimento, una morfologia ed una micro rugosità di superficie molto regolare. Ad elevato ingrandimento si è potuto rilevare come il trattamento elettrochimico abbia conferito un tipico aspetto microscopico, costituito da valli poco profonde e creste simili a "vulcani". Tale topografia superficiale promuove notevolmente la reazione di guarigione iniziale, poiché le sue proprietà osteoconduttive favoriscono l'apposizione di nuovo tessuto osseo sulla superficie dell'impianto, consentendo di ottenere nell'arco di poche settimane un'ottima stabilità secondaria. L'obiettivo del presente studio è quello di valutare, mediante istologia, istomorfometria e microtomografia computerizzata, l'osteointegrazione di impianti dentali con superficie FCC, associati o meno a rivestimenti nanostrutturati.

## MATERIALI E METODI

Sono stati utilizzati per il presente studio 6 conigli tipo "New Zealand White Rabbit". Tutti gli animali sono stati trattati in accordo con le politiche e i principi di cura degli animali da laboratorio e con le linee guida dell'Unione Europea (86/609/EEC) approvate dal Ministero della Salute (Legge 116/92).

Il sito di posizionamento dell'impianto è stata la epifisi prossimale della tibia, a livello anteriore (fig. 1).

Il particolare sito chirurgico ha richiesto la realizzazione di un impianto endosseo di dimensioni particolari (diametro 3,3 mm, lunghezza 7,0 mm), peraltro già ampiamente utilizzato da diversi Autori per esperimenti di implantologia dentale in modello sperimentale animale New Zealand White Rabbit. Le fixtures, del tipo a vite filettata, sono state prodotte dalla Winsix Ltd (London, U.K.). La superficie prevista per gli impianti era del tipo FCC (Full Contact Covering), ottenuta mediante trattamento elettrochimico, in grado di ottenere una soddisfacente e predicabile osteointegrazione e, allo stesso tempo, ideale per il trattamento con il coating nanostrutturato.

In anestesia generale sono stati posizionati 2 impianti per ogni tibia di coniglio (4 impianti/coniglio) per un totale di 24 impianti in 6 animali (fig. 2). Per ciascun animale sono stati inseriti 2 impianti con superficie FCC rivestiti da coating nanostrutturato a livello di una tibia selezionata random, e 2 impianti FCC di "controllo" (senza rivestimento) nell'altra tibia.

Per valutare la guarigione ossea perimplantare, il timing di espianto è stato (fig. 3):

- ▶ due conigli sacrificati a 2 settimane dal posizionamento degli impianti;
- ▶ due conigli sacrificati a 4 settimane dal posizionamento degli impianti;
- ▶ due conigli sacrificati a 12 settimane dal posizionamento degli impianti.

La biopsia ossea contenente gli impianti osteointegrati è stata ottenuta mediante block-section dell'epifisi prossimale tibiale.

Gli espianti sono stati effettuati includendo la porzione di tibia contenente l'impianto con un margine di 1,5 cm di osso perimplantare, al fine di valutare tutte le caratteristiche quantitative e qualitative di quel tessuto attraverso le tecniche previste.

I campioni sono stati quindi suddivisi in tre gruppi in base alla loro data di espianto.

- ▶ GRUPPO A: biopsie ottenute a 2 settimane dal posizionamento dell'impianto.



Fig. 1

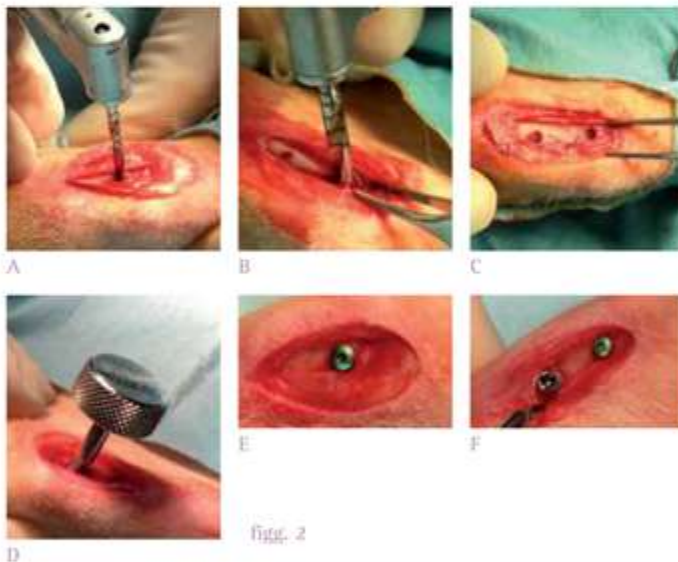


Fig. 2

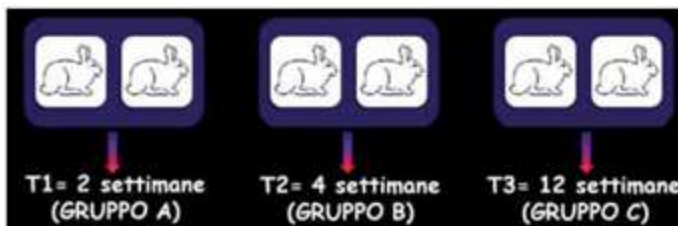

Fig. 3

Fig. 1: Sito chirurgico di posizionamento dell'impianto: epifisi prossimale della tibia, regione anteriore (sezione assiale di microtomografia computerizzata).

Fig. 2: Fase chirurgica su modello animale.

Fig. 3: Suddivisione in gruppi e timing di espianto.



fig. 4




fig. 5



fig. 6

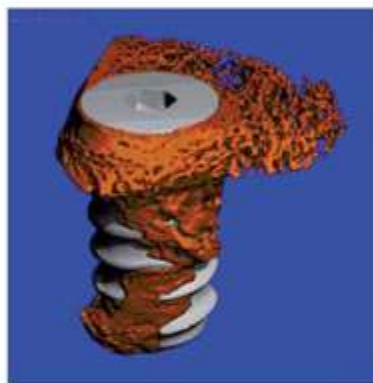


fig. 7



fig. 8

- GRUPPO B: biopsie ottenute a 4 settimane dal posizionamento dell'implanto.
- GRUPPO C: biopsie ottenute a 12 settimane dal posizionamento dell'implanto.

I campioni sono stati immediatamente immersi in soluzione di formalina tamponata. Tale conservazione e fissazione ha permesso di effettuare in un primo tempo la scansione microtomografica (effettuata solo per i gruppi B e C), ed in un secondo tempo di preparare i campioni per la analisi istologica.

#### Analisi microtomografica

Le scansioni sono state effettuate mediante microtomografia computerizzata ad elevata risoluzione di contrasto, per differenziare la componente ossea corticale da quella trabecolare, e ad una elevata risoluzione spaziale per analizzare la componente ossea trabecolare. Si è utilizzato una microtomografia ad alta risoluzione tipo Scanco Medical ( $\mu$ -CT-40, Scanco Medical AG, Zurich Switzerland). Le scansioni sono state effettuate in modalità multislice, con approssimativamente 400  $\mu$ m per slice (1024x1024 pixels con livelli di grigio 16 pixels). La risoluzione nominale di scansione è stata di circa 20  $\mu$ m sugli assi X, Y e Z; la risoluzione tridimensionale è stata di 1 voxel=15x15x15  $\mu$ m<sup>3</sup>.

Nell'ambito dei gruppi B e C, i gruppi test e controllo sono stati analizzati con esame visivo morfometrico microcomputerizzato (microCT) a due e tre dimensioni (2D e 3D). Uno dei parametri analizzati è stata la BIA (Bone to Implant Apposition), o BIC (Bone to Implant Contact), ovvero la quantità di osso trovata in contatto con la superficie dell'implanto (fig. 4 e 5).

L'analisi è stata determinante per escludere dall'esame dell'area midollare la parte all'apice di quegli impianti che avevano ottenuto una bicorticalizzazione, ovvero che avevano raggiunto un contatto con la corticale contrapposta al punto di inserimento (fig. 6). Tali parti dell'implanto, se fossero state incluse nelle misurazioni, avrebbero modificato i risultati in quanto nella zona di contatto con la corticale, la BIC era più alta. Tale accorgimento è stato utilizzato anche per l'analisi istomorfometrica.

#### Tecnica microCT della sottrazione di immagine per la valutazione visiva della BIC

La tecnica della sottrazione di immagine ha permesso di esaminare visivamente l'osso perimplantare dopo aver virtualmente asportato l'implanto. Questo è possibile lavorando sulle soglie della scala dei grigi della mi-

croCT: infatti l'implanto in titanio ha una densità radiografica diversa dall'osso (fig. 7 e 8).

croCT: infatti l'implanto in titanio ha una densità radiografica diversa dall'osso (fig. 7 e 8).

croCT: infatti l'implanto in titanio ha una densità radiografica diversa dall'osso (fig. 7 e 8).

croCT: infatti l'implanto in titanio ha una densità radiografica diversa dall'osso (fig. 7 e 8).

croCT: infatti l'implanto in titanio ha una densità radiografica diversa dall'osso (fig. 7 e 8).

croCT: infatti l'implanto in titanio ha una densità radiografica diversa dall'osso (fig. 7 e 8).

croCT: infatti l'implanto in titanio ha una densità radiografica diversa dall'osso (fig. 7 e 8).

croCT: infatti l'implanto in titanio ha una densità radiografica diversa dall'osso (fig. 7 e 8).

croCT: infatti l'implanto in titanio ha una densità radiografica diversa dall'osso (fig. 7 e 8).

croCT: infatti l'implanto in titanio ha una densità radiografica diversa dall'osso (fig. 7 e 8).

croCT: infatti l'implanto in titanio ha una densità radiografica diversa dall'osso (fig. 7 e 8).

croCT: infatti l'implanto in titanio ha una densità radiografica diversa dall'osso (fig. 7 e 8).

croCT: infatti l'implanto in titanio ha una densità radiografica diversa dall'osso (fig. 7 e 8).

croCT: infatti l'implanto in titanio ha una densità radiografica diversa dall'osso (fig. 7 e 8).

croCT: infatti l'implanto in titanio ha una densità radiografica diversa dall'osso (fig. 7 e 8).



SUPPLEMENTO DOCTOR DS MAGGIO 2011 VOL. XXII (5)

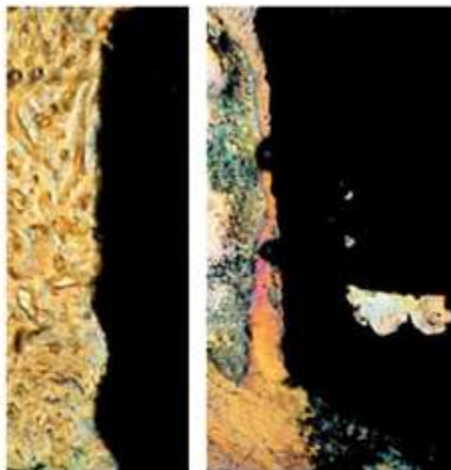


Fig. 9

Fig. 10

Gruppo A	Istomorfometria
Controllo	38,71 ± 9,23
Test	40,27 ± 8,92
T test	p=0,338

tab. 1

Fig. 9 Impianto del gruppo controllo, espantato a 2 settimane dal suo posizionamento.

Fig. 10 Impianto del gruppo test, espantato a 2 settimane dal suo posizionamento.

tab. 1 GRUPPO A: valori del BIC (%) per il gruppo controllo ed il gruppo test misurati con istomorfometria. Nella tabella sono inoltre indicati i risultati del confronto tra le medie dei due gruppi.

Fig. 11 Impianto del gruppo controllo, espantato a 4 settimane dal suo posizionamento.

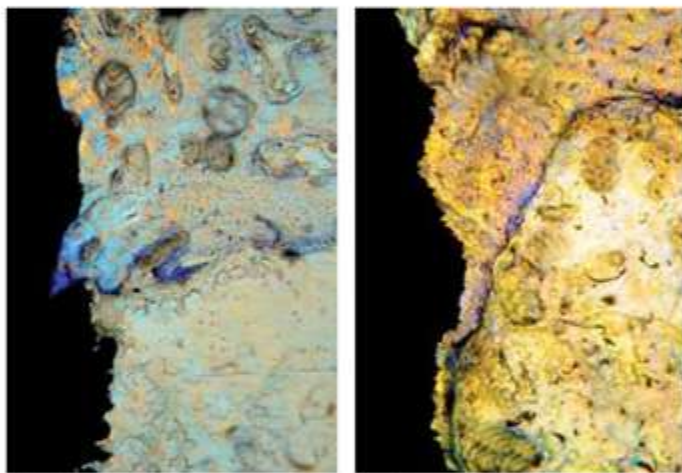


Fig. 11

Fig. 12

Gruppo B	Istomorfometria	Microtomografia
Controllo	57,41 ± 5,72	50,32 ± 3,21
Test	58,01 ± 6,19	51,47 ± 6,07
T test	p=0,428	p=0,442
Correlazione	0,374	

tab. 2

Fig. 12 Impianto del gruppo test, espantato a 4 settimane dal suo posizionamento.

tab. 2 GRUPPO B: valori del BIC (%) per il gruppo controllo ed il gruppo test misurati con istomorfometria e microtomografia. Nella tabella sono inoltre indicati i risultati del confronto tra le medie dei due gruppi, separatamente per istomorfometria e microtomografia, ed il coefficiente di correlazione tra le misurazioni effettuate con le due tecniche.

### Analisi statistica

I dati sono presentati come medie ± deviazioni standard.

Per il gruppo A non sono stati effettuati misurazioni microtomografiche, ma solo valutazione istologica ed istomorfometrica, per questo sono stati riportati i valori del BIC medio per la misurazione istomorfometrica per i gruppi test e controllo.

Per i gruppi B e C sono stati riportati i valori del BIC medio per la misurazione istomorfometrica e microtomografica per i gruppi test e controllo.

Per ogni gruppo (A, B e C) e per ogni sottogruppo (microtomografia ed istomorfometria), è stato eseguito il test "t" di Student (per dati non appaiati) al fine di ottenere il confronto tra due medie (test e controllo), con un livello di significatività impostato sul 95%.

Successivamente, è stata effettuata un'analisi della correlazione secondo Pearson tra i risultati ottenuti con le due tecniche nei diversi gruppi.

Le analisi sono state eseguite senza che l'operatore fosse a conoscenza del gruppo a cui appartenevano i campioni esaminati.

### RISULTATI

La sopravvivenza degli impianti dentali è stata del 100%. In ogni caso non si sono osservate complicanze a livello degli animali da esperimento.

In tutte le immagini presentate gli impianti sono stati orientati in modo che la parte coronale, che attraversa la corticale dell'osso, fosse rivolta verso l'alto nelle figure, mentre la parte apicale verso il basso.

### Gruppo A (numero impianti n=8)

**Istologia:** le sezioni istologiche del gruppo test presentano nella regione dell'osso marginale corticale una quantità di tessuto osseo sviluppatosi lungo la superficie implantare superiore rispetto al gruppo di controllo. La crescita ossea si è sviluppata in senso corono-apicale dal margine della corticale lungo la superficie dell'impianto. Tale tipo di tessuto osseo è piuttosto immaturo, con un elevato numero di lacune osteocitarie prive di vascolarizzazione ed una elevata quantità di tessuto a fibre intrecciate, indice allo stesso tempo di precoce guarigione ed immaturità (fig. 9 e 10).

**Istomorfometria:** il BIC è risultato per il gruppo controllo del 38,71 ± 9,23% e per il gruppo test del 40,27 ± 8,92%. Tra i due valori non è stata rilevata una differenza statisticamente significativa (tab. 1).



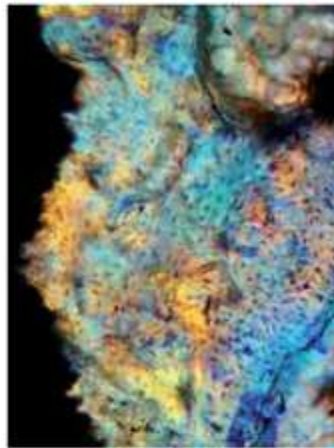


Fig. 13




Fig. 14

Gruppo B	Istomorfometria	Microtomografia
Controllo	62,52 ± 3,03	53,40 ± 4,01
Test	65,21 ± 3,07	56,62 ± 4,92
T test	p=0,314	p=0,328
Correlazione	0,853	

tab. 3

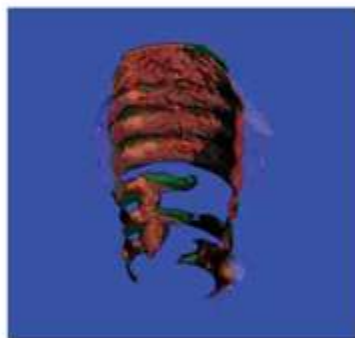

Fig. 15

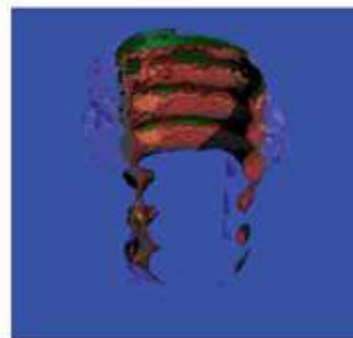

Fig. 16

### Gruppo B (numero impianti n=8)

**Istologia:** le sezioni istologiche del gruppo test presentano nella regione dell'osso marginale corticale una quantità di tessuto osseo sviluppato lungo la superficie implantare superiore rispetto al gruppo di controllo. La crescita ossea si è sviluppata in senso corono-apicale dal margine della corticale lungo la superficie dell'implanto. Il tessuto osseo presenta un grado di maturazione e rivascolarizzazione decisamente maggiore rispetto al gruppo A (fig. 11 e 12).

**Istomorfometria:** il BIC è risultato per il gruppo controllo del 57,41 ± 5,72 % e per il gruppo test del 58,01 ± 6,19 % (tab. 2). Tra i due valori non è stata rilevata una differenza statisticamente significativa (tab. 2).

**Microtomografia:** il BIC è risultato per il gruppo controllo del 50,32 ± 3,21 % e per il gruppo test del 51,47 ± 6,07 %. Tra i due valori non è stata rilevata una differenza statisticamente significativa (tab. 2).

Tra i valori istomorfometrici e microtomografici è stato rilevato un coefficiente di correlazione di 0,874, indice di correlazione lineare tra le misurazioni effettuate con le due tecniche (tab. 2).

### Gruppo C (numero impianti n=8)

**Istologia:** le sezioni istologiche del gruppo test presentano nella regione dell'osso mar-

ginale corticale una quantità di tessuto osseo sviluppatosi lungo la superficie implantare superiore rispetto al gruppo di controllo. La crescita ossea si è sviluppata in senso corono-apicale dal margine della corticale lungo la superficie dell'implanto. Il tessuto osseo presenta un grado di maturazione e rivascolarizzazione decisamente maggiore rispetto al gruppo B (fig. 13 e 14).

**Istomorfometria:** il BIC è risultato per il gruppo controllo del 62,52 ± 3,03 % e per il gruppo test del 65,21 ± 3,07 % (tab. 3, fig. 15 e 16). Tra i due valori non è stata rilevata una differenza statisticamente significativa (tab. 3).

**Microtomografia:** il BIC è risultato per il gruppo controllo del 53,40 ± 4,01 % e per il gruppo test del 56,62 ± 4,92 %. Tra i due valori non è stata rilevata una differenza statisticamente significativa (tab. 3).

Tra i valori istomorfometrici e microtomografici è stato rilevato un coefficiente di correlazione di 0,853, indice di correlazione lineare tra le misurazioni effettuate con le due tecniche.

## DISCUSSIONE E CONCLUSIONI

La struttura macroscopica e microscopica di un impianto dentale presenta un ruolo determinante ai fini della sopravvivenza e del suc-

cesso della riabilitazione implantoprotesica. Diversi studi hanno dimostrato come le caratteristiche di superficie e la geometria macrostrutturale influenzino in modo significativo l'ottenimento di una stabilità primaria della fixture e la graduale trasmissione del carico masticatorio all'osso.

Il presente studio ha analizzato su modello animale (New Zealand White Rabbit) l'osteointegrazione di impianti dentali WINSIX® con superficie FCC (con e senza coating nanostrutturato).

Tale analisi è stata condotta attraverso microtomografia computerizzata, istologia ed istomorfometria.

Per quanto riguarda l'analisi istologica, sono emerse delle interessanti differenze tra il gruppo test ed il gruppo controllo. Infatti, in tutti i casi, le sezioni istologiche del gruppo test presentano nella regione dell'osso marginale corticale una quantità di tessuto osseo sviluppatosi lungo la superficie implantare superiore rispetto al gruppo di controllo. La crescita ossea si è sviluppata in senso corono-apicale dal margine della corticale lungo la superficie dell'implanto. Tali risultati indicano una maggior attività osteoconduttrice della superficie con coating nanostrutturato, anche se non sono state rilevate delle differenze statisticamente significative.

Per quanto riguarda l'analisi istomorfometri-

Fig. 13 Impianto del gruppo controllo, espantato a 12 settimane dal suo posizionamento.

Fig. 14 Impianto del gruppo test, espantato a 12 settimane dal suo posizionamento.

tab. 3 GRUPPO C: valori del BIC (%) per il gruppo controllo ed il gruppo test misurati con istomorfometria e microtomografia. Nella tabella sono inoltre indicati i risultati del confronto tra le medie dei due gruppi, separatamente per istomorfometria e microtomografia, ed il coefficiente di correlazione tra le misurazioni effettuate con le due tecniche.

Fig. 15 Impianto del gruppo test, che presenta all'analisi della BIC 3D una BIC elevata sia nella parte coronale che nella parte apicale di questo impianto.

Fig. 16 Impianto del gruppo di controllo, presenta all'analisi della BIC 3D una BIC elevata solo nell'area della corticale o coronale, mentre nella zona apicale la BIC appare più bassa all'esame visivo.

## SUPPLEMENTO DOCTOR DS MAGGIO 2011 VOL. XXII (5)

ca, sono stati ottenuti dei dati relativi alla percentuale di contatto tra osso e impianto (BIC) piuttosto elevati, ed in alcuni casi (come nella regione midollare) presentano valori di gran lunga superiori rispetto a quelli riportati da recenti pubblicazioni (Park 2005, Park 2010). Tali risultati indicano una maggiore velocità di guarigione ossea, sia in termini quantitativi che qualitativi (maggiore grado di maturazione ossea).

La microtomografia computerizzata ha analizzato i volumi ossei perimplantari in modo non distruttivo, senza la necessità di sezionare le biopsie e quindi perdere inevitabilmente del tessuto perimplantare. A partire dal calcolo dei volumi ossei perimplantari, è stato possibile anche in questo caso, stimare il BIC, parametro che ci ha permesso di valutare l'osteointegrazione.

Nell'ambito della valutazione delle immagini microtomografiche, l'analisi visiva è soggettiva e non permette di calcolare con precisione la quantità di contatto con l'osso, ma permette di dimostrare la quantità di osso presente all'interfaccia e nelle vicinanze dell'interfaccia, valutando anche la presenza di trabecole neoformate, la loro forma ed orientamento spaziale.

Le analisi visive effettuate dimostrano che le superfici test hanno un comportamento simile a quello delle superfici controllo nell'osso compatto, mentre in osso midollare presentano una migliore performance le superfici test rispetto alle superfici controllo. Le curve

ottenute dai valori presentati nelle tabelle dimostrano come, in entrambi i casi, le superfici FCC abbiano presentato una netta tendenza alla osteoconduttività.

Tali risultati, in particolare la notevole qualità del grado di maturazione del tessuto osseo perimplantare, sembrano confermare quanto precedentemente analizzato in studi in vitro sulla superficie di tali impianti. Infatti, la superficie FCC "Full Contact Covering" è prodotta attraverso un processo elettrolitico, che consiste nell'applicazione di una differenza di potenziale tra un elettrodo ed il "dispositivo" da trattare, il quale diventa un anodo immerso in una soluzione conduttiva. Questo comporta la crescita "esplosiva" dello strato di ossido, ossia si genera una superficie porosa la cui dimensione e forma dei pori dipendono dalle condizioni del processo. Tale topografia superficiale promuove notevolmente la reazione di guarigione iniziale, poiché le sue proprietà osteoconduttive favoriscono l'apposizione di nuovo tessuto osseo sulla superficie dell'impianto, consentendo di ottenere nell'arco di poche settimane un'ottima stabilità secondaria. Questa produzione accelerata di tessuto osseo sulla superficie FCC accorcia i tempi di guarigione, come rilevato dai risultati del nostro studio.

Altro risultato importante si è dimostrato la validità del metodo di analisi utilizzato per valutare il tessuto osseo perimplantare e l'osteointegrazione degli impianti endosse. Infatti, le tre metodiche d'analisi sono risultate per-

fettamente complementari ed i risultati ottenuti dalle misurazioni istomorfometriche e microtomografiche si sono rivelate linearmente correlate.

In conclusione, si può affermare che l'impianto oggetto di studio ha mostrato notevole qualità in termini di osteoconduzione e precocità dei tempi di guarigione, sia con che senza coating nanostrutturato.

Futuri studi dovrebbero indagare in modo più approfondito su numerose popolazioni di pazienti le caratteristiche di tali superfici, poiché la loro applicazione potrebbe portare ad una predicibile e precoce integrazione di impianti dentali con notevoli vantaggi da un punto di vista clinico.

## RINGRAZIAMENTI

Il presente studio è stato condotto dall'Unità di Ricerca Il diretta dal Prof. Gherlone nell'ambito di un Progetto di Ricerca di Interesse Nazionale (PRIN 2005) "Biomeccanica e biomimetica: un approccio integrato per la validazione funzionale dell'utilizzo dei materiali nanostrutturati nelle riabilitazioni implantoprotetiche" cofinanziato dal Ministero dell'Istruzione, Dell'Università e della Ricerca, coordinato dal Prof. Antonio Apicella.

Si ringrazia il Dott. Alberto Rebaudi per l'analisi microtomografica e le immagini microTC.

## BIBLIOGRAFIA

1. Buser D, Nydegger J, Olsard T et al. Interface shear strength of titanium implants with a sandblasted and acid etched surface: A biomechanical study in the maxilla of miniature pigs. *J Biomed Mater Res* 1999;45:75-83.
2. Wang W, Feldman S, Hawley CE, Garofalo J. A multi-center study comparing dual-acid-etched and machined-surfaced implants in various bone qualities. *J Periodontol* 2001;72:1384-1390.
3. Monheerd JP, Dutzopoulos M, Chappard D. 2-hydroxyethyl-methacrylate (HEMA): chemical properties and applications in biomedical fields. *J Macromol Sci Macromol Res* 1992;32:1-34.
4. Pradhantha K, Nizanth Kumar Pai K, Shenjira BS, Prasanna Kumar S. Interpenetrating polymer networks based on poly(methyl methacrylate) and poly(2-hydroxyethylmethacrylate): synthesis, chemical, mechanical and thermal properties. *Mater Sci* 2001;24(5):525-8.
5. Kabra B, Gehrke SH, Huang ST, Reichel W. Modification of the dynamic swelling behavior of grafted. *J Appl Polym Sci* 1991;42:2489-95.
6. Apreola A, Cappello E, Del Nobile MA, La Rotonda MI, Merloni G, Nicolai L. Poly(ethylene oxide) (PEO) and different molecular weight PEO's blends: amorphous devices for drug release. *Biomaterials* 1993;14:83-90.
7. Peltola G, Peltola O, Anderson JM, Ambrosio M, Nicolai L, Milone MB, Eschbach FG, Huang SJ. The differential effects of poly(2-hydroxyethylmethacrylate) and poly(2-hydroxyethyl-methacrylate)/poly(ε-caprolactone) polymers on cell proliferation and collagen synthesis by human lung fibroblasts. *J Biomed Mater Res* 1991;34:327-35.
8. Schiavella C, DiGenzio A, Oliva A, Ferrara A, De Rosa A, Apicella A, Averio R, De Rosa M. Development of hybrid materials based on hydroxyethylmethacrylates supports for improving cell adhesion and proliferation. *Biomaterials* 2004; 25: 3645-3653.
9. Park YS, Yi Ky, Lee H, Jung YC. Correlation Between Microtomography And Histomorphometry For Assessment Of Implant Osseointegration. *Clin Oral Implants Res* 2005 Apr;16(2):156-60.
10. Catledge SA, Vahro YK, Bellis SC, Sawyer AA. Mesenchymal Stem Cell Adhesion And Spreading On Nanostructured Biomaterials. *J Nanosci Nanotechnol* 2004; 4(8): 986-9.
11. Price RJ, Haberstroh RM, Webster TJ. Enhanced Functions Of Osteoblasts On Nanostructured Surfaces Of Carbon And Alumina. *Med Biol Eng Comput* 2003; 41(3):372-5.
12. Gavanzi G, Ambrosio L et al. Histomorphometric, Ultrastructural And Microanalysis Evaluation Of The Osseointegration Of A Nanostructured Titanium Oxide Coating By Metal-Organic Chemical Vapour Deposition. *An In Vivo Study*. *Biomaterials* 2004; 25:5503-5591.
13. Rebaudi A, Keller B, Lab A, Irosi P. Microcomputed Tomographic Analysis Of The Peri-implant Bone. *Int J Periodont Restorative Dent* 2004; 24(4):317-325.
14. Tan J, Mark Saltzman W. Biomaterials With Hierarchically Defined Micro- And Nanoscale Structure. *Biomaterials* 2004; 25:3203-3601.
15. Park YS, Lee SP, Han CH, Kwon JH, Jung YC. The Microtomographic Evaluation Of Marginal Bone Resorption Of Immediately Loaded Scaloped Design Implant With Various Microthread Configurations In Canine Maxilla: Pilot Study. *J Oral Implants* 2010;36(5):257-62.
16. Crespi R, Mariani E, Benazzi E, Capparo P, Cecchi S, Gherlone E. Magnesium-Enriched Hydroxyapatite Versus Autologous Bone In Maxillary Sinus Grafting: Combining Histomorphometry With Osteoblast Gene Expression Profiles. *Ex Vivo*. *J Periodontol* 2009 Apr;80(4):586-93.
17. Crespi R, Vico R, Capparo P, Gherlone E, Romano G. Coronal Versus Buccal Crest For Autologous Bone Graft Material For A Sinus Lift Procedure: A Histomorphometric Study. *Int J Oral Maxillofac Implants* 2007 Jul-Aug;22(4):527-32.
18. Feldman S, Bittel N, Bierig D, Kohles SS, Stach RM. Five-Year Survival Distributions Of Short Length (10 mm or less) Machined-Surfaced And Osseointegrated Implants. *Clin Implant Dent Relat Res* 2004;6(1):16-21.
19. Albrektsson T, Wennerberg A. Oral Implant Surfaces: Part 1—Review Focusing On Topographic And Chemical Properties Of Different Surfaces And In Vivo Responses To Them. *Int J Prosthodont* 2004 Sep-Oct;17(5):536-43.
20. Earlsman JC, Sheets CG, Fiquette JM, Kaminski FM, Nordard WP, Koen RG, Wu JC. Tissue Engineering In Dentistry. *Clin Plast Surg* 2003 Oct;30(4):627-39.
21. Du C, Meijer GJ, Van De Valk C, Haan RE, Beumer JM, Henseling SC, Gu FZ, De Groot R, Lagijcke P. Bone Growth In Biomimetic Apatite-Coated Porous Polyacrylate 3000(pmg20h430) Implants. *Biomaterials* 2002 Dec;23(27):4649-56.
22. Magrin P, Douglas WH. Revascularization Of Esthetic Restorative Dentistry Bared On Biomimetics. *J Esthet Dent* 1999;11(1):5-75.
23. Semerly L, Thomson P, Ericson LE. A Morphometric And Biomechanical Comparison Of Titanium Implants Inserted In Rabbit Cortical And Cancellous Bone. *Int J Oral Maxillofac Implants* 1992;7(1):62-71.
24. Semerly L, Thomson P, Ericson LE. Early Tissue Response To Titanium Implants Inserted In Rabbit Cortical Bone. Part I: Light Microscopic Observations. *J Mater Sci Mater Med* 1993 May;4(3):240-250.
25. Semerly L, Wennerberg A, Piroo F. A New Microtomographic Technique For Non-Invasive Evaluation Of The Bone Structure Around Implants. *Clin Oral Implants Res* 2005 Feb;12(1):51-4.

## RICERCA SPERIMENTALE

# Isolamento di progenitori osteogenici provenienti da liquido amniotico utilizzando un protocollo di coltura cellulare single step

Isolation of osteogenic progenitor from amniotic fluid using a single step cell culture protocol

\* Stefano Tetè  
\*\* Ivana Antonucci  
\* Giuseppe D'Apolito  
\* Umberto Di Tore  
\* Vincenzo Zizzari  
\* Alessandro De Carlo  
\* Margherita Tumedei  
\*\* Liborio Stuppia  
\*\*\* Enrico Gherlone

\* Università "G. d'Annunzio", Chieti, Dipartimento di Scienze Orali, Nano e Biotecnologie  
\*\* Università "G. d'Annunzio", Chieti, Dipartimento di Scienze Biomediche  
\*\*\* Università Vita-Salute San Raffaele, Milano, Cattedra di Clinica Odontoiatrica e Corso di Laurea in Igiene Dentale, Presidente: Prof. E. Gherlone

### SCOPO DEL LAVORO

Nel presente studio è riportato un protocollo single step per la differenziazione osteoblastica di cellule staminali provenienti da liquido amniotico.

### MATERIALI E METODI

Al fine di testare la capacità proliferativa di queste cellule sulle superfici utilizzate in implantologia orale, sono stati effettuati test su differenti dischi come il rame liscio, il titanio machined e il titanio sabbiato e acidificato (WMRS®, WINSIX® della BioSAFin). Le cellule così ottenute sono state sottoposte ad analisi RT-PCR e marcate con Alizarin Red per evidenziare la presenza di noduli calcifici espressione di matrice ossea mineralizzata.

### RISULTATI E DISCUSSIONE

Il processo di coltura single step consente una riduzione di 20 giorni del tempo di coltura

rispetto ai protocolli tradizionali. Il numero di cellule ottenute usando il nostro protocollo sembra essere sufficiente per future finalità terapeutiche a livello locale. L'osservazione effettuata tramite l'utilizzo della microscopia elettronica ha mostrato una crescita ottimale e una adesione valida delle cellule osteoblastiche sulla superficie in titanio WMRS® attualmente utilizzata negli impianti dentali.

### CONCLUSIONE

Il protocollo descritto nel presente studio mostra la capacità di produrre cellule osteoblastiche da campioni di liquido amniotico in un tempo molto breve, essendo queste cellule già altamente differenziate entro un mese dal prelievo. L'utilizzo del liquido amniotico come fonte di tali cellule presenta il vantaggio di provenire da campioni clinici già disponibili.

### AIM OF THE WORK

The present study reports a single step protocol for osteoblastic differentiation of stem cells obtained from amniotic fluid.

### MATERIALS AND METHODS

In order to test the proliferative ability of these cells on the surfaces used in oral implantology, tests on disks of different materials such as smooth copper, machined titanium and sandblasted and acid etched titanium (WMRS®, WINSIX® by BioSAFin) were performed. The samples underwent RT-PCR analysis and staining with Alizarin Red to show the presence of calcific nodules, as the expression of mineralized bone matrix.

### RESULTS AND DISCUSSION

The single step culture protocol presented in this study reduced of 20 days cell culture time compared to previous protocols.

The number of cells obtained with this protocol seems to be enough for future local treatment. The observation at the electron microscope showed a good adhesion of osteoblastic cells on the WMRS® titanium surface currently used in titanium implants.

### CONCLUSION

The protocol described in this study confirms that it is possible to obtain osteoblastic cells from samples of amniotic fluid in a very short time, being these cells already highly differentiated within a month from harvesting. The use of amniotic fluid as source for such cells has the advantage of being easily obtained from routine amniocentesis samples.

LIQUIDO AMNIOTICO / CELLULE STAMINALI / IMPIANTI ORALI IN TITANIO / DIFFERENZIAMENTO OSTEOGENICO / AMNIOTIC FLUID / STEM CELLS / ORAL TITANIUM IMPLANT / OSTEOGENIC DIFFERENTIATION





## INTRODUZIONE



e cellule staminali isolate dal liquido amniotico sono note per essere in grado di differenziarsi in diversi tipi cellulari. Vengono quindi considerate come un

potenziale strumento per la terapia cellulare di diverse malattie umane.

Nel presente studio, riportiamo un unico protocollo, un passo innovativo per la differenziazione osteoblastica di cellule provenienti dal liquido amniotico.

Il protocollo descritto è in grado di fornire cellule osteoblastiche producendo noduli calcifici mineralizzati entro 18 giorni dal prelievo dei campioni di liquido amniotico. Queste cellule presentano una completa espressione dei marcatori osteogenici (Col1, ONC, OPN, OCN, OPG, BSP, Runx2) entro 30 giorni dal prelievo. Al fine di testare la capacità proliferativa di queste cellule sulle superfici di uso comune in implantologia orale osteointegrata, abbiamo effettuato test su dischi di coltura diversi, rame liscio, titanio machined ed il titanio sabbiato e acidificato (titanio WMRS®). Tali dischi sono stati forniti dall'azienda BioSAFin. Successive analisi di microscopia elettronica hanno evidenziato una migliore crescita cellulare sulla superficie di quest'ultimo.

Il protocollo descritto fornisce uno strumento efficace che permette di risparmiare tempo per la produzione di cellule osteogeniche da liquido amniotico che in futuro potrebbero essere utilizzate in implantologia orale osteointegrata.

Nel presente studio è stata ottenuta una differenziazione in senso osteoblastico utilizzando due differenti protocolli di coltura di cellule provenienti da liquido amniotico. Nel primo protocollo, le AFMSCs sono state trasferite nel medium osteogenico al sesto passaggio, mentre nel secondo protocollo campioni di liquido amniotico sono stati direttamente sospesi nel medium osteogenico senza la selezione delle AFMSCs.

Nel protocollo 1, sette giorni dopo l'avvio della coltura principale, cellule simil fibroblastiche sono apparse sia in forma isolata che in colonie. Dopo 20-22 giorni di coltura, si aveva confluenza del 70-80%, le cellule sono state quindi raccolte. L'analisi RT-PCR, effettuata su RNA estratto dalle cellule in questa fase, ha evidenziato la presenza di geni precedentemente segnalati come espressi nelle AFMSCs, vale a dire SDF1, CXCR4, Oct-4, SCF, GATA-4, Vim, FGF-5, Pax-6, NCAM, AFP, BMP-2.

Le cellule raccolte a 20-22 giorni sono

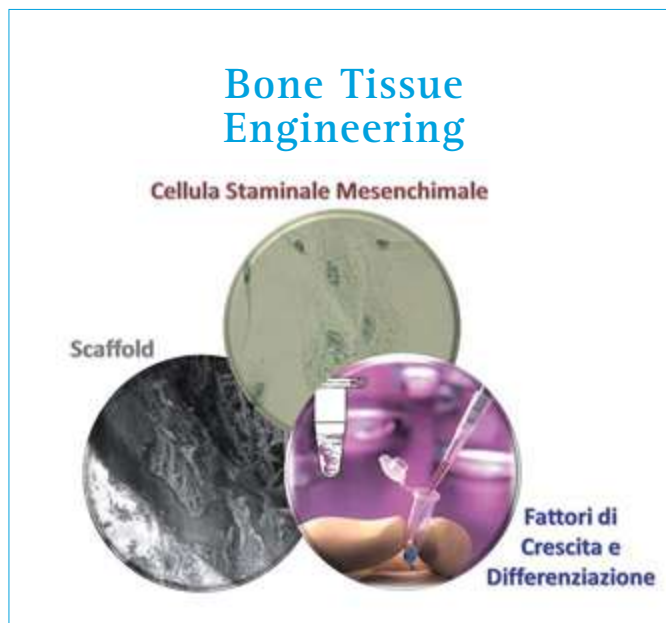


FIG. 1

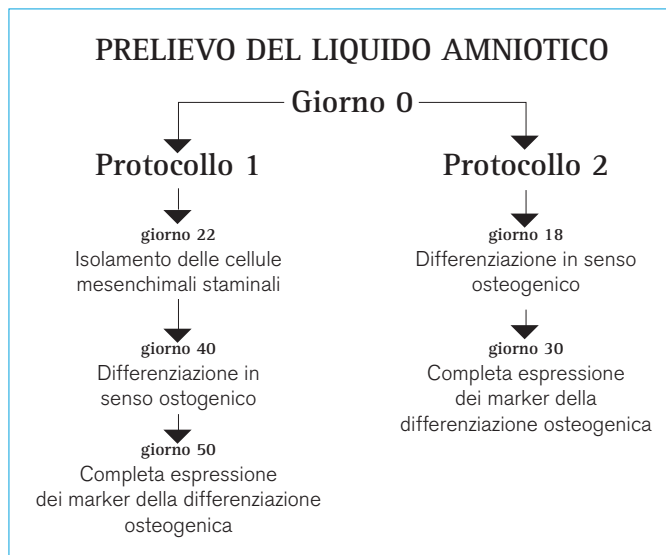


FIG. 2

state trasferite in coltura nel mezzo osteogenico. Dopo 18 giorni di coltura nel terreno osteogenico (40 giorni dal prelievo), le cellule hanno mostrato una confluenza del 70-75%, e la presenza di noduli di mineralizzazione del calcio è stata apprezzabile. Il numero e le dimensioni di questi aggregati è aumen-

tato nei giorni seguenti. Le cellule coltivate direttamente nel terreno osteogenico (protocollo 2) hanno raggiunto il 70-75% di confluenza dopo 18 giorni dal prelievo. Tale confluenza è aumentata ulteriormente nei giorni seguenti. La colorazione con Alizarin Red conferma la presenza di mineralizzazione.



### Caratterizzazione fenotipica (protocollo 1)



Le AFMSCs dopo 7 giorni di induzione. È possibile osservare cellule simili a fibroblasti.



Le AFMSCs dopo 20-22 giorni di induzione. È possibile osservare cellule in confluenza (70 - 80%).

FIG. 3

### Caratterizzazione fenotipica (protocollo 2)



Le AFMSCs dopo 18 giorni di induzione.



È possibile osservare la presenza di noduli minerali.

FIG. 4

### Culture cellulari su differenti Scaffold



FIG. 5

La presenza di impianti con differenti trattamenti superficiali, e diversa morfologia della superficie, ci permette di valutare quella che potrebbe risultare la superficie migliore per garantire una ottimale proliferazione delle cellule osteoblastiche e aumentare e favorire l'osteointegrazione attorno all'impianto. Nei nostri esperimenti non sono state rilevate cellule adese alla superficie liscia del rame, mentre un diverso comportamento delle cellule simil osteoblastiche è stato osservato nel titanio machined e nel titanio WMRS®. Sulle superfici di titanio machined, si trovano poche cellule aderenti. Al contrario, le cellule aderenti hanno ricoperto interamente la superficie del disco in titanio WMRS®.

Al fine di valutare la stabilità mitotica delle cellule, l'indagine citogenetica è stata condotta sul protocollo di coltura n. 2 al giorno 30, ed è stato mostrato un normale cariotipo diploide in tutte le metafasi esaminate.

### MATERIALI E METODI

Campioni di liquido amniotico sono stati ottenuti da 11 donne sottoposte ad amniocentesi per la diagnosi prenatale durante il periodo compreso tra le 16 e 19 settimane di gravidanza dopo il consenso informato scritto. Lo studio è stato approvato dal Comitato Etico per la ricerca biomedica dell'Università degli studi "G. d'Annunzio" di Chieti. Dopo 7 giorni, le cellule non aderenti sono state rimosse e le cellule aderenti sono rimaste a proliferare nel medium. Quando la coltura ha raggiunto la confluenza (circa 20 giorni dopo la coltura principale), le cellule sono state trattate con tripsina 0,05% e 0,02% EDTA, poi contate e immesse in 2 fiasche di coltura da 25 cm.

### Differenziazione osteogenica

Due protocolli di coltura diversi sono stati utilizzati per la differenziazione osteogenica delle cellule del liquido amniotico.

- › Nel primo protocollo (protocollo 1) le AFMSCs al sesto passaggio sono state trasferite in un terreno osteogenico consistente in un terreno di coltura semplice alpha-MEM con l'aggiunta di 150 mg/l  $\beta$ -glicerofosfato, 50 mg/ml di acido ascorbico e  $10^{-8}$  M di desametasone.
- › Nel secondo protocollo (protocollo 2) pellets di campioni di liquido amniotico sono stati direttamente sospesi nel medium osteogenico senza la selezione delle AFMSCs.



RICERCA

Per visualizzare i sedimenti di calcio, le cellule trattate con il protocollo 2 sono state colorate in tempi diversi (19, 22 e 30 giorni dal prelievo) con Alizarin Red. La mineralizzazione è stata dimostrata dalla presenza di depositi di pigmento rosso.

**Coltura su superfici diverse**

Sono stati utilizzati tre dischi test (diametro 10 mm, spessore 5 mm) per ogni superficie, vale a dire rame liscio, titanio machined e titanio sabbiato e acidificato (titanio WMRS®). Tali dischi sono stati forniti dall'azienda BioSAFin. Dopo la differenziazione, al giorno 15, le cellule osteoblastiche ottenute con il protocollo 2 sono state divise in tre gruppi. Quando è stata osservata confluenza al 70% (dopo 2-3 giorni di coltura), le cellule sono state preparate e analizzate mediante SEM.

L'RNA è stato isolato da:

- › cellule AFMSCs dopo 20 giorni di coltura in terreno standard (protocollo 1);
- › cellule differenziate dopo 30 giorni in medium osteogenico (protocolli 1 e 2);
- › RNA dal liquido amniotico usato come controllo.

L'amplificazione è stata eseguita con primers specifici per due classi di geni:

- › i geni espressi nelle cellule mesenchimali (SDF1, CXCR4, Oct-4, SCF, GATA-4, Vim, FGF-5, Pax-6, NCAM, AFP, BMP-2);
- › geni espressi durante la differenziazione osteogenica (col1, ONC, OPN, OCN, OPG, BSP e Runx2).

**DISCUSSIONE**

Nel presente studio abbiamo dimostrato la capacità di AFS umane di differenziarsi in cellule osteogeniche utilizzando un processo di coltura single step, consentendo una riduzione di 20 giorni per quanto riguarda il tempo di coltura rispetto ai protocolli riportati in precedenza. Questo potrebbe rappresentare un passo importante in vista di una possibile applicazione terapeutica di queste cellule.

Il numero di cellule ottenute usando il nostro protocollo sembra essere sufficiente per future finalità terapeutiche a livello locale.

Al fine di testare la capacità delle cellule osteoblastiche ottenute da liquido amniotico a proliferare sulle superfici di uso comune in implantologia cranio-facciale e di valutare la loro utilità per l'ingegneria tissutale, abbiamo provato

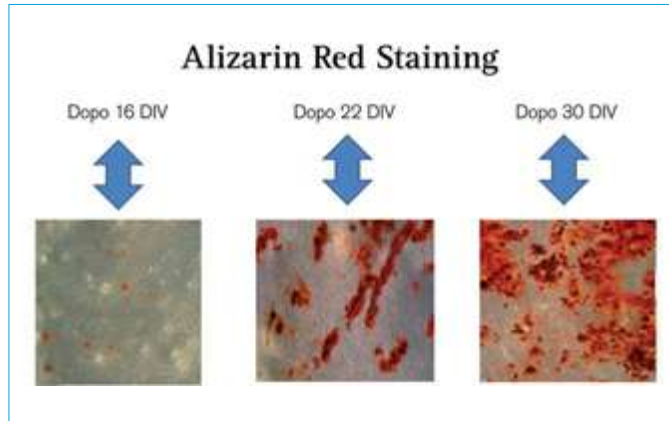


FIG. 6

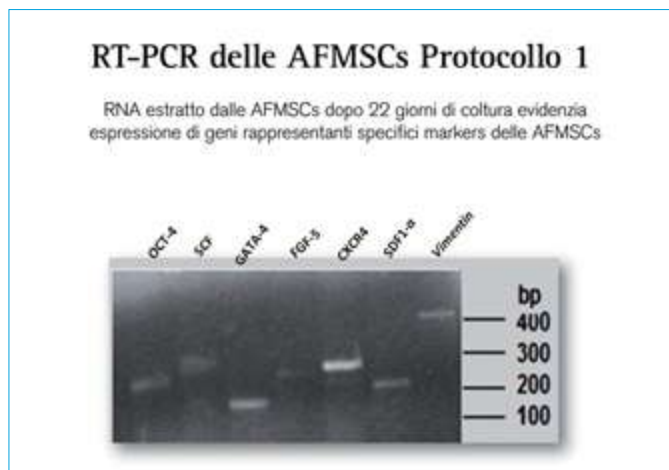


FIG. 7

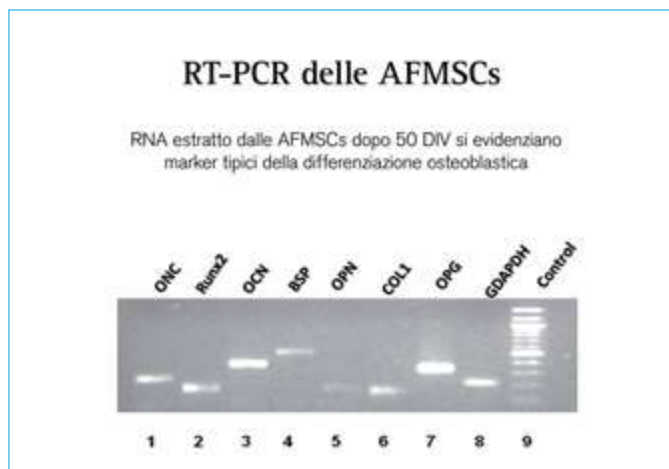


FIG. 8



le cellule ottenute su dischi in titanio machined e titanio WMRS®.

L'osservazione effettuata tramite l'utilizzo della microscopia elettronica ha mostrato una crescita ottimale e un'adesione valida delle cellule osteoblastiche sulla superficie in titanio WMRS® attualmente utilizzata negli impianti dentali WINSIX®.

## CONCLUSIONE

Il protocollo descritto nel presente studio mostra la capacità di produrre cellule osteoblastiche da campioni di liquido amniotico in un tempo molto breve, essendo queste cellule già altamente differenziate entro un mese dal prelievo. Anche se progenitori osteoblastici possono essere efficacemente ottenuti dalle cellule stromali del midollo osseo, l'uso di liquido amniotico come fonte di queste cellule è molto rilevante in quanto le AFS possono essere facilmente ottenute da amniocentesi di routine da campioni clinici che altrimenti sarebbero buttati via.

## BIBLIOGRAFIA

- 1) Chiapasco M, Gatti C, Gatti F. Immediate loading of dental implants placed in severely resorbed edentulous mandibles reconstructed with autogenous calvarial grafts. *Clin Oral Implants Res.* 2007;18:13-20.
- 2) Cipriani S, Bonini D, Marchina E, Balgkouranidou I, Caimi L, Grassi Zucconi G, Barfati S. Mesenchymal cells from human amniotic fluid survive and migrate after transplantation into adult rat brain. *Cell Biol Int.* 2007;31:845-850.
- 3) De Coppi P, Bartsch G, Jr, Siddiqui MM, Xu T, Santos GC, Perin L, Mostoslavsky G, Serre AC, Snyder EY, Yoo JJ, Furth ME, Soker S, Atala A. Isolation of amniotic stem cell lines with potential for therapy. *Nat Biotechnol.* 2007;25:100-106.
- 4) Fauza D. Amniotic fluid and placental stem cells. *Best Pract Res Clin Obstet Gynaecol.* 2004 Dec;18(6):877-91.
- 5) Gregory CA, Gunn WG, Peister A, Prockop DJ. An Alizarin red-based assay of mineralization by adherent cells in culture: comparison with cetylpyridinium chloride extraction. *Anal Biochem.* 2004;329:77-84.
- 6) Gronthos S, Mankani M, Brahimi J, Robey PG, Shi S. Postnatal human dental pulp stem cells (DPSCs) in vitro and in vivo. *Proc Natl Acad Sci USA.* 2000;97:13625-13630.
- 7) Holden C. Stem cells. Versatile stem cells without the ethical baggage? *Science.* 2007;315:170.
- 8) In 't Anker PS, Scherjon SA, Kleijburg-van der Keur C, Noort WA, Claas FH, Willemze R, Fibbe WE, Kanhai HH. Amniotic fluid as a novel source of mesenchymal stem cells for therapeutic transplantation. *Blood.* 2003 Aug 15;102(4):1548-9.
- 9) Kaviani A, Perry TE, Dzakovic A, Jennings RW, Ziegler MM, Fauza DD. The amniotic fluid as a source of cells for fetal tissue engineering. *J Pediatr Surg.* 2001;36:1662-1665.
- 10) Kim J, Lee Y, Kim H, Hwang KJ, Kwon H, Kim SK, Cho DJ, Kang SG, You J. Human amniotic fluid-derived stem cells have characteristics of multipotent stem cells. *Cell Prolif.* 2007;40:75-90.
- 11) Mao JJ, Giannobile WV, Helms JA, Hollister SJ, Krebsbach PH, Longaker MT, Shi S. Craniofacial tissue engineering by stem cells. *J Dent Res.* 2006;85:966-979.
- 12) Tetè S, Mastrangelo F, Quaresima R, Vinci R, Sammartino G, Stuppia L, Gherlone E. Influence of novel nano-titanium implant surface on human osteoblast behavior and growth. *Implant Dent.* 2010 Dec;19(6):520-31.
- 13) Tsai MS, Lee JL, Chang YJ, Hwang SM. Isolation of human multipotent mesenchymal stem cells from second-trimester amniotic fluid using a novel two-stage culture protocol. *Hum Reprod.* 2004;19:1450-1456.

## RICERCA SPERIMENTALE

# Valutazione della macrostruttura e della nanostruttura di un nuovo tipo di impianti dentali

Evaluation of macrostructure  
and nanostructure of a new type  
of dental implants

- \* Giuseppe D'Apolito
- \* Umberto Di Tore
- \* Alessandro De Carlo
- \* Margherita Tumedei
- \* Renato Grilli
- \* Vincenzo Zizzari
- \*\* Liborio Stuppia
- \*\*\* Enrico Gherlone
- \* Stefano Tetè

\* Università "G. d'Annunzio", Chieti, Dipartimento  
di Scienze Orali, Nano e Biotecnologie

\*\* Università "G. d'Annunzio", Chieti, Dipartimento  
di Scienze Biomediche

\*\*\* Università Vita-Salute San Raffaele, Milano, Cattedra  
di Clinica Odontoiatrica e Corso di Laurea in Igiene  
Dentale, Presidente: Prof. E. Gherlone

### SCOPO DEL LAVORO

Scopo di questo studio è stato quello di valutare la macrostruttura e la nanostruttura di una nuova superficie implantare, FCC® (Full Contact Covering®).

### MATERIALI E METODI

La nuova superficie implantare, FCC®, ottenuta con tecnica elettrochimica, è stata analizzata mediante analisi profilometrica al SEM e microanalisi a raggi X.

### RISULTATI E CONCLUSIONE

I risultati ottenuti dall'analisi di questa superficie sono stati confrontati con quelli relativi alle superfici sabbiata e sabbiata e mordenzata.

### AIM OF THE WORK

The purpose of this study was to assess the macrostructure and the nanostructure of a new implant surface, FCC® (Full Contact Covering®).

### MATERIALS AND METHODS

The new implant surface, FCC®, obtained by an electrochemical technique, was analyzed through SEM profilometry analysis and X-ray microanalysis.

### RESULTS AND CONCLUSION

The results obtained from this surface analysis were compared with those of the Sandblasted and Sandblasted Acid-Etched surfaces.

FCC® / ANALISI PROFILOMETRICA AL SEM /  
BIC / MICROANALISI A RAGGI X /  
FCC® / SEM PROFILOMETRY ANALYSIS / BIC /  
X-RAY MICROANALYSIS

### INTRODUZIONE



Il successo in terapia implantare è strettamente legato all'ottenimento dell'osteointegrazione, condizione che si verifica quando si ha un contatto otti-

male tra superficie implantare e tessuto osseo. Un ruolo di grande importanza per il raggiungimento di questa condizione è rivestito dalla forma dell'impianto, dalle spire presenti sul corpo implantare, dal loro numero, dalla loro forma in sezione, dal disegno in punta dell'impianto e dalla rugosità di superficie, che aumenta l'interfaccia di contatto tra tessuto osseo e fixture, favorendo così l'osteointegrazione.

Diversi studi hanno evidenziato come il BIC (Bone to Implant Contact) aumenti notevolmente mediante l'utilizzo di impianti in titanio che presentino superfici

rugose che in tal modo possono influenzare il processo di osteointegrazione condizionando i meccanismi cellulari.

Le cellule osteoblastiche sembrano essere suscettibili alla rugosità di superficie che le induce ad orientarsi ed a migrare lungo le microcavità. Le superfici ruvide possono essere ottenute mediante sabbiatura, acidificazione o con una combinazione delle due tecniche.

In questo studio viene analizzata una nuova tipologia di superficie chiamata FCC® (Full Contact Covering®) ottenuta con tecnica elettrochimica, della quale vengono analizzati la macrostruttura geometrica, la topografia di superficie e la composizione chimica comparando tali caratteristiche a quelle degli impianti con superficie sabbiata e sabbiata e mordenzata (fig. 1).

### MATERIALI E METODI

#### Valutazione della macrostruttura e rugosità della superficie

Gli impianti dentali utilizzati sono stati forniti dall'azienda BioSAFin e appartengono al sistema WINSIX®.



Gli impianti appartengono a 3 gruppi:

1. Sab, con superficie sabbiata, di forma cilindrica;
2. WMRS, con superficie sabbiata e mordenzata, di forma cilindrica;
3. FCC® (Full Contact Covering®), conici con le spire che diventano più fitte dalla porzione coronale a quella apicale, il che gli conferisce aspetto cilindrico.

Le superfici sono state analizzate al SEM ed è stata effettuata una valutazione profilometrica, oltre che una analisi della composizione chimica di superficie tramite spettroscopia fotoelettronica a raggi x (XPS).

## RISULTATI

L'analisi dei 3 tipi di impianti dentali ha dimostrato sensibili differenze tra le varie superfici sia a livello microscopico che macroscopico.

- › Nei Sab a basso ingrandimento si nota il passo uguale tra le spire con le spire con sezione a forma di "V".
- › Negli WMRS a basso ingrandimento si nota il passo uguale tra le spire con le spire con sezione a forma di "V".
- › Negli FCC® a basso ingrandimento si nota che il passo tra le spire diminuisce procedendo verso l'apice, risultando così cilindrico e con le spire a sezione quadrata verso la porzione crestale e con sezione a forma di "V" in zona apicale.

A maggiore ingrandimento le differenze risultano ancora più evidenti.

- › Nei Sab si ha una tipica macrorugosità dovuta alla sabbiatura che determina una irregolare distribuzione della porosità con profonde valli alternate a picchi alti e taglienti.
- › Negli WMRS si ha una microrugosità di superficie con cavità e "colline" ben distribuite dovute all'azione della sabbiatura e poi del trattamento acido che attenua ed uniforma l'opera della sabbiatura.
- › Negli FCC® la microporosità di superficie è più regolare dato che il trattamento elettrochimico determina una tipica morfologia con basse valli e creste simili a "vulcani" poiché presentano al loro interno dei fori che ricordano appunto il camino vulcanico (figg. 2-5).

## DISCUSSIONE

Grande importanza in letteratura è data alla stabilità primaria per il successo implantare. Tale condizione è ottenuta me-



FIG. 1

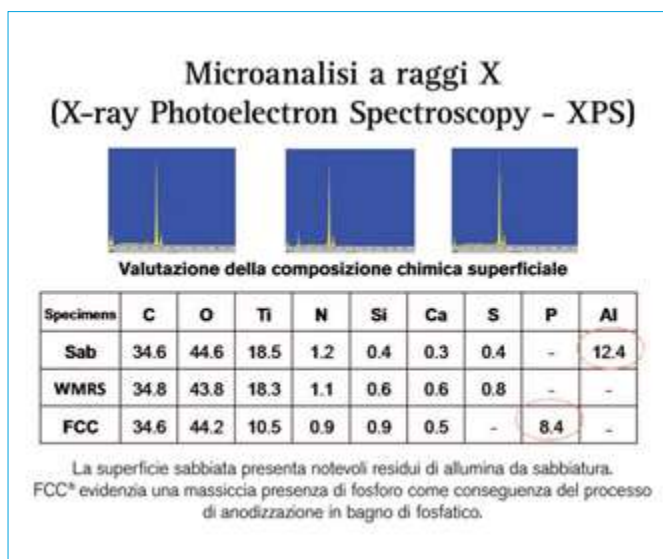


FIG. 2

dante un adeguato studio del disegno delle spire che coprono l'impianto, del loro profilo e del loro passo nonché della superficie che riveste la vite implantare.

- › Gli impianti Sab mostrano delle spire arrotondate e regolari, che permettono di dissipare adeguatamente i carichi se posizionati nelle regioni posteriori.
- › Il disegno conico degli impianti WMRS, con il passo regolare tra le spire, permette una ottimale distribuzione dei carichi soprattutto nell'osso mandibolare.
- › Il disegno conico degli impianti

FCC®, in associazione alle spire con passo variabile dalla porzione crestale a quella apicale, e con diversa sezione, permette di garantire una ottimale dissipazione delle forze masticatorie ed occlusali e a livello apicale permette di garantire una elevata stabilità primaria e quindi un elevato BIC.

## CONCLUSIONI

In questo studio sono stati analizzati gli impianti con superficie FCC® sia a livello macro-strutturale che micro-struttu-

RICERCA




FIG. 3

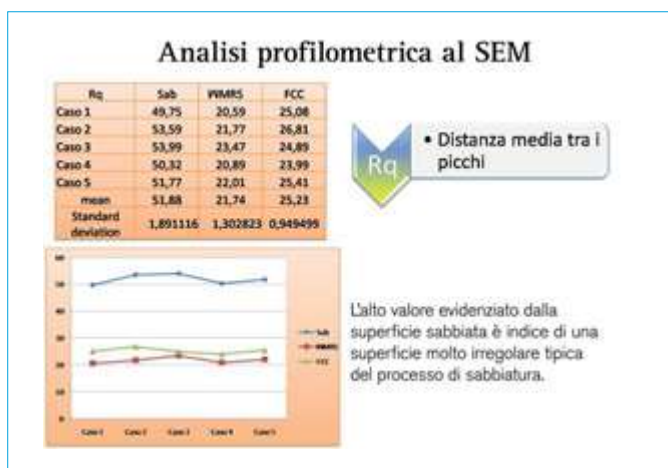


FIG. 4




FIG. 5

rale. Risultano avere un disegno che possa garantire una elevata capacità di dissipazione delle forze masticatorie e dei carichi occlusali. In particolare la presenza della forma a V delle spire apicali permette una adeguata stabilità primaria e determina una buona resistenza dell'impianto durante l'inserimento in cresta. Tutto questo grazie all'ampia superficie di contatto determinata dal trattamento elettrochimico. Ulteriori studi in vivo potranno verificare se l'utilizzo della superficie FCC® possa avere successo nella pratica clinica per permettere di ottenere una rapida e precificabile osteointegrazione e per ridurre il periodo di guarigione post operatorio del tessuto osseo intorno all'impianto.

**BIBLIOGRAFIA**

- Antonucci I, Iezzi I, Morizio E, Mastrangelo F, Pantalone A, Mattioli-Belmonte M, Gigante A, Salini V, Calabrese G, Tetè S, Palka G, Stuppia L. Isolation of osteogenic progenitors from human amniotic fluid using a single step culture protocol. BMC Biotechnol. 2009 Feb 16;9:9.
- Bowers KT, Keller JC, Randolph BA, Wick DG, Michaels CM. Optimization of surface micromorphology for enhanced osteoblast responses in vitro. Int J Oral Maxillofac Implants. 1992 Fall;7(3):302-10.
- Buser D, Schenk RK, Steinemann S, Fiorellini JP, Fox CH, Stich H. Influence of surface characteristics on bone integration of titanium implants. A histomorphometric study in miniature pigs. J Biomed Mater Res. 1991 Jul;25(7):689-902.
- Buser D. Titanium for dental applications (II): Implants with roughened surfaces. In: Brunette DM, Tengvall P, Textor M, Thomsen P, eds. Titanium in Medicine. Berlin: Springer; 2001:676-88.
- Cooper LF. A role for surface topography in creating and maintaining bone at titanium endosseous implants. J Prosthet Dent. 2000 Nov;84(5):522-34.
- Davies JE. Understanding peri-implant endosseous healing. J Dent Educ. 2003 Aug;67(8):932-49.
- Martin JY, Schwartz Z, Hummert TW, Schraub DM, Simpson J, Lankford J Jr, Dean DD, Cochran DL, Boyan BD. Effect of titanium surface roughness on proliferation, differentiation, and protein synthesis of human osteoblast-like cells (MG63). J Biomed Mater Res. 1995 Mar;29(3):389-401.
- Prosper L, Redaelli S, Pasi M, Zarone F, Radaelli G, Gherlone EF. A randomized prospective multicenter trial evaluating the platform-switching technique for the prevention of postrestorative crestal bone loss. Int J Oral Maxillofac Implants. 2009 Mar-Apr;24(2):299-308.
- Smith DC. Surface characterization of implants: Biological implications. In: Davies JE, ed. Bone Biomaterial Interface. Toronto: Toronto University Press; 1991:9-17.
- Tetè S, Mastrangelo F, Quaresima R, Vinci R, Sammartino G, Stuppia L, Gherlone E. Influence of novel nano-titanium implant surface on human osteoblast behavior and growth. Implant Dent. 2010 Dec;19(6):520-31.
- Tetè S, Mastrangelo F, Traini T, Vinci R, Sammartino G, Marenzi G, Gherlone E. A macro- and nanostructure evaluation of a novel dental implant. Implant Dent. 2008 Sep;17(3):309-20.
- Wennberg A, Albrektsson T, Andersson B, Krol JJ. A histomorphometric and removal torque study of screwshaped titanium implants with three different surface topographies. Clin Oral Implants Res. 1995 Mar;6(1):24-30.



## RICERCA SPERIMENTALE

# Valutazione morfostrutturale al SEM di cellule staminali da follicolo dentario su differenti scaffold di titanio

SEM morphostructural evaluation  
of stem cells from dental follicle  
on different titanium scaffold

• **Umberto Di Tore**  
• **Giuseppe D'Apolito**  
• **Vincenzo Zizzari**  
• **Alessandro De Carlo**  
• **Margherita Tumedei**  
\*\* **Liborio Stuppia**  
\*\*\* **Raimondo Quaresima**  
\*\*\*\* **Enrico Gherlone**  
• **Stefano Tetè**

\* Università "G. d'Annunzio", Chieti, Dipartimento  
di Scienze Orali, Nano e Biotecnologie

\*\* Università "G. d'Annunzio", Chieti, Dipartimento  
di Scienze Biomediche

\*\*\* Università "G. d'Annunzio", Chieti, Dipartimento  
di Chimica, Ingegneria Chimica e Materiali

\*\*\*\* Università Vita-Salute San Raffaele, Milano, Cattedra  
di Clinica Odontoiatrica e Corso di Laurea in Igiene  
Dentale, Presidente: Prof. E. Gherlone

### SCOPO DEL LAVORO

Scopo del lavoro è stato quello di valutare mediante analisi biomolecolare e di microscopia, la capacità di cellule staminali, prelevate da follicolo dentario umano (hDPHSCs), di differenziarsi in senso osteogenico.

### MATERIALI E METODI

Dopo aver selezionato cellule che hanno mostrato aspetti fenotipici caratteristici della linea osteoblastica, si è andati ad analizzare in vitro il livello di proliferazione di tali cellule differenziate su scaffold rappresentati dalle diverse superfici mediante l'utilizzo del SEM, dell'analisi citofluorimetrica e della RT-PCR. La comparazione della rugosità delle diverse superfici impiegate come scaffold è stata effettuata mediante l'analisi profilometrica al SEM.

### RISULTATI E DISCUSSIONE

Le colture di hDPHSCs a contatto con superfici in titanio hanno mostrato in vitro una buona affinità dopo differenziazione in senso osteogenico con la presenza di cellule osteoblastiche attive e formazione di primi nuclei di deposizione di matrice extracellulare, mostrando una maggiore affinità verso le superfici in Titanio (FCC®).

### CONCLUSIONE

Il Ti nanostrutturato mediante lavorazione FCC®, a parità di timing, sembra svolgere una buona funzione di scaffold per la crescita cellulare rispetto al Ti Machined. Si auspicano ulteriori studi sulle cellule staminali derivate da follicolo dentario in grado di differenziarsi e proliferare in maniera ottimale, favorendo processi di rigenerazione ossea ed osteointegrazione.

### AIM OF THE WORK

The aim of this study was to evaluate by molecular and microscope analysis, the ability of stem cells taken from human dental follicle (hDPHSCs) to differentiate into osteogenic direction.

### MATERIALS AND METHODS

After selecting the cells that showed phenotypic characteristic aspects of the osteoblastic cell line, we in vitro investigated the level of proliferation of these cells differentiated scaffold, represented by the various surfaces by SEM, flow cytometric analysis and RT-PCR. The comparison of the roughness of the different areas used as scaffold was performed by SEM profilometry analysis.

### RESULTS AND DISCUSSION

The hDPHSCs cultures, in contact with the titanium surface showed a good affinity for Titanium (FCC®) surfaces in

vitro: after the osteogenic differentiation active osteoblastic cells and formation of the first nuclea of extracellular matrix deposition could be found.

### CONCLUSION

Nanostructured Titanium surfaces through the FCC® process seemed to be, within the same timing, a better scaffold for cellular growth than Machined Titanium. Further studies on the ability of dental follicle derived stem cells to differentiate and proliferate, in order to help bone regeneration and osseointegration processes, are required.

 HDPHSCS / ANALISI PROFILOMETRICA AL SEM /  
CELLELE STAMINALI / IMPIANTI / TITANIO /  
HDPHSCS / SEM PROFILOMETRY ANALYSIS / STEM CELLS /  
IMPLANTS / TITANIUM



## INTRODUZIONE



Le ricerche più complesse in campo odontoiatrico sono, attualmente, quelle che riguardano la branca dell'implantologia e sono mirate alla realizzazione di dispositivi impiantabili dentali, validi supporti per il riposizionamento di elementi dentali mancanti. Lo scopo principale è di migliorare i materiali costitutivi, le tecniche implantoprotesiche, le prestazioni meccaniche e i tempi di guarigione.

Oggi, la metodica sviluppata da Brånemark rappresenta il punto di partenza di ogni trattamento implantare. Le sperimentazioni attuali sui dispositivi impiantabili dentali, tuttavia, hanno come obiettivo l'individuazione dell'optimum tra gli impianti che renda più rapido il processo di osteointegrazione e consenta, quindi, il carico precoce.

Scopo del nostro lavoro è stato quello di valutare mediante metodiche di analisi bio-molecolare e di microscopia, la capacità di cellule staminali, prelevate da follicolo dentario umano (hDPhSCs), di differenziarsi in senso osteogenico. Si è passati alla comparazione tra varie tipologie superficiali utilizzando la profilometria, una metodica che consente di apprezzare anche le più piccole variazioni presenti sulle superfici dei metalli. Una volta che tali cellule hanno mostrato aspetti fenotipici caratteristici della linea osteoblastica, si è andati ad analizzare in vitro il livello di proliferazione di tali cellule differenziate su scaffold rappresentati dalle diverse superfici.

## MATERIALI E METODI

Sono stati selezionati individui sani, di età compresa tra i 10 ed i 16 anni, per cui erano stati programmati uno o più interventi di germectomia del terzo molare per motivi ortodontici. Tutti gli individui hanno ricevuto adeguate informazioni riguardo la partecipazione alla sperimentazione ed hanno fornito il loro consenso.

L'estrazione è stata eseguita previa anestesia locale e sotto copertura antibiotica. Si è proceduto all'incisione del lembo ed allo scollamento muco-periostale, successivamente si è disposta l'osteotomia del tessuto circostante ed eventualmente soprastante il terzo molare in modo da consentire la presa del dente e la sua estrazione. Il sito chirurgico post-estrattivo è stato sottoposto ad accurato management ed infine sono stati apposti punti di sutura staccati in numero

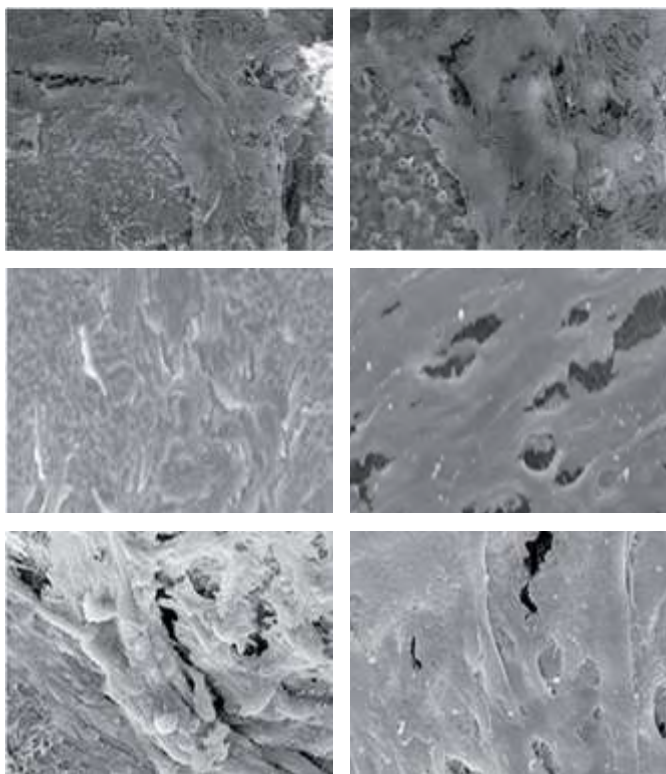


FIG. 1

adeguato all'estensione del lembo chirurgico. Dopo che l'elemento dentario è stato estratto, si è provveduto all'isolamento del materiale cellulare proveniente dal follicolo, subito conservato in una provetta contenente una soluzione di enzimi.

La digestione enzimatica delle cellule del follicolo dentario è stata effettuata a 37°C per un'ora. Una volta avvenuta la digestione, le cellule sono state filtrate ed immerse in un terreno di coltura.

### Preparazione dei campioni biologici

La fissazione chimica per il SEM viene eseguita con glutaraldeide. Successivamente i campioni vengono inglobati in blocchetti di resina per essere poi sezionati mediante microtomo.

### Preparazione del terreno di differenziazione

La differenziazione in senso osteogenico delle cellule prelevate dal follicolo

dentale è stata ottenuta in accordo con quanto già riportato in letteratura; si è cioè utilizzato un terreno semplice MEM (alpha modification of Eagle's Medium; Cod. M 8042, Sigma) al quale sono stati aggiunti il 15% di Fetal Bovine Serum (Cod. 10270-106, Invitrogen), l'1% di Penicillina/Streptomycin (Cod. 15140-12, Invitrogen), l'1% di L-Glutamine (Cod. G 6392, Sigma), 50 µg/ml di 2-phospho-L-ascorbic acid trisodium salt (Cod. 49752, Fluka, Sigma), 3 mM di glicerol-2-phosphate disodium salt (Cod. G9891, Sigma) e 10 nM desametasone (G 6392, Sigma).

### Preparazione dei campioni sui dischi

Una volta che le cellule del secondo passaggio hanno raggiunto la confluenza sono state divise in cinque gruppi: il primo gruppo di cellule è stato posto su un disco in rame da 10 mm con terreno di coltura osteogenico (controllo negativo); il secondo gruppo di cellule è stato posto su un disco in Titanio ma-

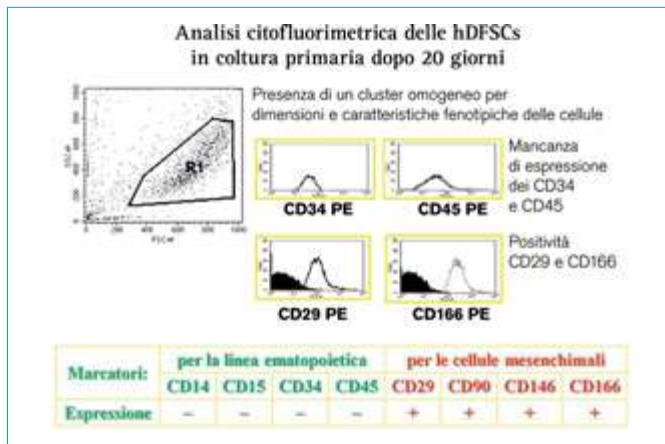


FIG. 2

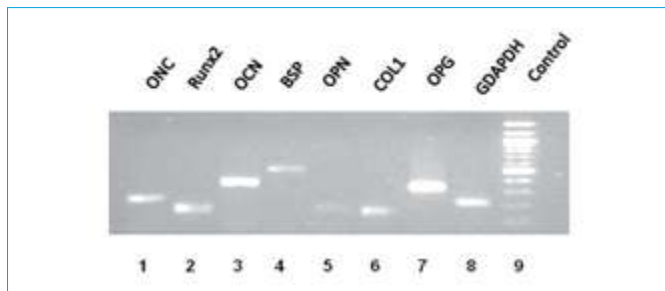


FIG. 3

chined da 10 mm in presenza di terreno di coltura osteogenetico (controllo positivo); la terza popolazione cellulare è stata posta su dischi da 10 mm che presentano una superficie WMRS® (test); la quarta popolazione cellulare è stata posta su dischi da 10 mm che presentano una superficie Sab (test); la quinta popolazione cellulare è stata posta su dischi da 10 mm che presentano una superficie FCC® (test).

Le cellule seminate sui dischi sono state incubate a 37°C in un'atmosfera contenente il 5% di CO<sub>2</sub> per 40 giorni, alla fine dei quali sono state esaminate al SEM.

## RISULTATI

### Analisi al Microscopio Elettronico a Scansione (SEM) delle cellule follicolari prima della confluenza

L'analisi al Microscopio Elettronico a Scansione delle cellule derivate da folli-

colo dentario umano (hDPhSCs) ha mostrato una popolazione eterogenea, con presenza di cellule fusate, tondeggianti e poligonali. All'interno di tale popolazione cellulare, alcune presentano una morfologia simil-fibroblastica tipica di elementi mesenchimali indifferenziati (fig. 1).

### Analisi citofluorimetrica di colture cellulari primarie del follicolo dentale indifferenziate

L'analisi fenotipica della popolazione di cellule staminali è stata condotta a 15-20 giorni dalla messa in coltura, utilizzando anticorpi in grado di marcare specificamente la linea ematopoietica (CD34 e CD45), quella monocitica (CD14 e CD15) e la linea mesenchimale (CD29, CD90, CD146 e CD166). La scelta di tali antigeni di superficie si è basata sull'evidenza che le cellule staminali del follicolo dentale umano (hDPhSCs), che possono essere indotte al differenziamento in senso

osteo/odontogenico sono di origine mesenchimale, così come quelle derivanti dal midollo osseo (BMSCs). L'eterogeneità delle cellule presenti all'interno delle colture è stata verificata mediante un'analisi citofluorimetrica al FACS (fig. 2).

### Analisi al RT-PCR di cellule differenziate in medium osteogenico di Owen

Dopo la selezione della popolazione, le cellule hDPhSCs sono state caratterizzate mediante tecniche di biologia molecolare, RT-PCR.

I dati dell'analisi hanno mostrato come le colture esprimano livelli paragonabili di fosfatasi alcalina (ALP), osteopontina, osteocalcina, osteonectina, collagene di tipo I e collagene di tipo VIII.

Dopo essere state selezionate mediante FACS, le cellule sono state seminate su piastre contenenti medium di crescita con l'aggiunta di fattori osteogenici. Tali cellule in coltura con terreno di Owen, tendono a costituire una popolazione prevalentemente di morfologia poligonale e fusiforme con nuclei centrali ben evidenti e numerose estensioni citoplasmatiche; il citoscheletro appare ben strutturato. Queste cellule tendono a disporsi in un singolo strato (fig. 3).

### Analisi profilometrica

È stata eseguita un'analisi profilometrica delle superfici dei dischi test in Titanio machined, sabbiato, FCC® ed WMRS® e dischi controllo in Rame.

L'analisi della superficie in Rame (controllo negativo) ha evidenziato una superficie regolare con presenza di striature e solchi che si vengono a creare al momento della tornitura.

L'esame profilometrico dei dischi in titanio Machined (controllo positivo) ha evidenziato immagini del tutto sovrapponibili a quelle mostrate dal Rame, in quanto i dischi sono ottenuti mediante lo stesso processo di lavorazione per tornitura.

L'esame profilometrico dei dischi in titanio Sabbiato (controllo positivo) ha fatto risaltare una superficie con rugosità altamente disomogenea con presenza di elevazioni aguzze e profonde valli.

L'analisi profilometrica condotta sui dischi in titanio WMRS® sabbiato e mordenzato, ha mostrato una superficie omogenea ed uniforme tipica, con una moltitudine di depressioni ed elevazioni smusse di piccole dimensioni.

L'analisi della superficie dei dischi di Titanio con superficie FCC® (controllo positivo) ha mostrato una superficie alta-

## RICERCA

mente regolare con presenza di basse valli e di creste a forma di "vulcani" poiché presentano al loro interno dei fori che ricordano il cammino vulcanico (fig. 4).

Le cellule derivate dal follicolo dentario e sottoposte a proliferazione guidata mediante medium osteogenico di Owen sono state posizionate su scaffold costituite da dischi di dimensioni standard (diametro 10 mm, altezza 5 mm) di: Titanio Machined, Titanio WMRS<sup>®</sup>, Titanio Sabbiato, Titanio FCC<sup>®</sup> e Rame (Cu<sup>++</sup>). In primo luogo l'analisi è stata condotta su una superficie in rame. Dalle immagini dal SEM della superficie controllo negativo non risultava evidente alcuna presenza di cellularità.

Sullo scaffold test costituito da titanio semplicemente machined è stato possibile rilevare la presenza di rare cellule che hanno aderito sul disco.

Sullo scaffold test costituito da titanio sabbiato vi è la presenza di cellule aderenti alla superficie.

Sullo scaffold test del dischetto di titanio FCC<sup>®</sup> vi è la presenza di un gran numero di cellule, con filopodi che si diramano sulla superficie indice di una attiva proliferazione e differenziazione.

Infine l'analisi al SEM degli scaffold in Titanio WMRS<sup>®</sup>, allo stesso timing, ha evidenziato una diffusa presenza di cellule sull'intera superficie esaminata.

## CONCLUSIONI

Lo scopo della nostra ricerca è stato quello di valutare la proliferazione e l'affinità di cellule staminali prelevate da follicolo dentario poste a contatto con diverse superfici.

Abbiamo dimostrato in vitro che colture di hDPhSCs a contatto con superfici in titanio mostrano una buona affinità dopo differenziazione in senso osteogenico con la presenza di cellule osteoblastiche attive e formazione di primi nuclei di deposizione di matrice extracellulare. Dalle analisi effettuate è emerso come tali cellule staminali abbiano mostrato una maggiore affinità verso le superfici in Titanio (FCC<sup>®</sup>). Nella nostra ricerca è stato possibile valutare il grado di affinità ed una presenza di cellule osteoblastiche maggiore rispetto ai dischi in Titanio Machined. Pertanto i dati emersi sembrerebbero confermare come il Ti nanostrutturato mediante lavorazione FCC<sup>®</sup>, a parità di timing, possa svolgere una ottima funzione di scaffold per la crescita cellulare rispetto al Ti Machined.

Inoltre i risultati ottenuti sembrerebbero incoraggiare lo sviluppo di ulteriori studi




FIG. 4

sulle cellule staminali derivate da follicolo dentario in grado di differenziarsi e proliferare in maniera ottimale, favorendo processi di rigenerazione ossea ed osteointegrazione.

## BIBLIOGRAFIA

- 1) Buser D, Schenk R, Steinemann S, Fiorellini J, Fox C, Stich H. Influence of surface characteristics on bone integration of titanium implants. A histomorphometric study in miniature pigs. *J Biomed Mater Res* 1991;25:889-902.
- 2) Buser D. Titanium for dental applications (II): Implants with roughened surfaces. In: Brunette DM, Tengvall P, Textor M, Thomsen P, editors. *Titanium in Medicine*. Berlin: Springer; 2001. p 876-888.
- 3) Caplan AL. Mesenchymal stem cells. *J Orthop Res*. 1991 Sep;9(5):641-50.
- 4) Cooper LF. A role for surface topography in creating and maintaining bone at titanium endosseous implants. *J Prosthet Dent* 2000;84:522-34.
- 5) Farley JR, Hall SL, Tanner MA, Wergedal JE. Specific activity of skeletal alkaline phosphatase in human osteoblast-line cells regulated by phosphate, phosphate esters, and phosphate analogs and release of alkaline phosphatase activity inversely regulated by calcium. *J Bone Miner Res*. 1994 Apr;9(4):497-508.
- 6) Hamamoto N, Hamamoto Y, Nakajima T, Ozawa H. Histological, histochemical and ultrastructural study on the effects of surface charge on bone formation in the rabbit mandible. *Arch Oral Biol*. 1995 Feb;40(2):97-106.
- 7) Kilpadi DV, Lemons JE. Surface energy characterization of unalloyed titanium implants. *J Biomed Mater Res*. 1994 Dec;28(12):1419-25.
- 8) Owen M, Friedenstein AJ. Stromal stem cells: marrow-derived osteogenic precursors. *Ciba Found Symp*. 1988;136:42-60.
- 9) Pittenger MF, Mackay AM, Beck SC, Jaiswal RK, Douglas R, Mosca JD, Moorman MA, Simonetti DW, Craig S, Marshak DR. Multilineage potential of adult human mesenchymal stem cells. *Science*. 1999 Apr 2;284(5411):143-7.
- 10) Tete S, Nargi E, Mastrangelo F, Zizzari V, D'Apolito G, Traini T, Costanzo G, Dadorante V, D'Alimonte I, Caputi S, Caciagli F, Ciccarelli R. Changes in matrix extracellular phosphoglycoprotein expression before and during in vitro osteogenic differentiation of human dental papilla mesenchymal cells. *Int J Immunopathol Pharmacol*. 2008 Apr-Jun;21(2):309-18.
- 11) Wennerberg A, Albrektsson T, Johansson C, Andersson B. Experimental study of turned and grit-blasted screw-shaped implants with special emphasis on effects of blasting material and surface topography. *Biomaterials*. 1996 Jan;17(1):15-22.
- 12) Wieland M, Sittig C, Brunette DM, Textor M, Spencer ND. Measurement and evaluation of the chemical composition and topography of titanium implant surfaces. In: Davies JE, editor. *Bone Engineering*. Toronto: Em Squared; 2000. p 163-182.

## RICERCA SPERIMENTALE

# Valutazione degli effetti di differenti tecniche osteotomiche sul tessuto osseo

Evaluation of different osteotomy techniques on bone tissue

\* Raffaele Vinci  
\*\* Stefano Tetè  
\*\* Giuseppe D'Apolito  
\*\* Umberto Di Tore  
\* Luisella Benzo  
\*\* Alessandro De Carlo  
\*\* Margherita Tumedei  
\*\* Vincenzo Zizzari  
\*\*\* Liborio Stuppia  
\* Enrico Gherlone

\* Università Vita-Salute San Raffaele, Milano, Cattedra di Clinica Odontoiatrica e Corso di Laurea in Igiene Dentale, Presidente: Prof. E. Gherlone  
\*\* Università "G. d'Annunzio", Chieti, Dipartimento di Scienze Orali, Nano e Biotecnologie  
\*\*\* Università "G. d'Annunzio", Chieti, Dipartimento di Scienze Biomediche

### SCOPO DEL LAVORO

Lo studio analizza gli effetti sul tessuto osseo di due tecniche osteotomiche, effettuate con lo strumento piezoelettrico e con gli strumenti rotanti.

### MATERIALI E METODI

Nel presente studio sono stati inclusi 39 pazienti di età compresa tra gli 11 e i 65 anni. La scelta del tipo di trattamento chirurgico per ciascun paziente è stata randomizzata.

Su prelievi ottenuti da ciascun gruppo di pazienti sono state effettuate tre tipi di analisi: analisi istologica, analisi biologica, analisi biomolecolare.

### RISULTATI E CONCLUSIONE

La semplicità di esecuzione della tecnica, la maggiore visibilità del campo operatorio, il rispetto di strutture sensibili, la massima precisione nel taglio e il minimo danno ai tessuti permettono una riduzione del disagio del paziente

e una riduzione dei tempi di guarigione. Tali considerazioni e i risultati ottenuti suggeriscono che lo strumento piezoelettrico, rispetto a quello rotante, sia più efficace e largamente indicato per molteplici utilizzi nella chirurgia oromaxillofacciale.

### AIM OF THE WORK

The study analyzes the effects on bone tissue of two different osteotomy techniques, performed with the piezoelectric instrument and with rotary instruments.

### MATERIALS AND METHODS

In this study, 39 patients aged between 11 and 65 years were included. The choice of the surgical treatment for each patient was randomized. On samples obtained from each group three types of analysis were carried out: histological analysis, biological analysis, and biomolecular analysis.

### RESULTS AND CONCLUSION

The technique resulted to be easy to perform, it enabled a better view of the surgical site, the respect of sensitive structures, the high cutting precision and the minimal damage to surrounding tissue enable a reduction in patient's discomfort and healing times. These considerations together with the results obtained suggest that the piezoelectric instrument, seems to be more effective and indicated for several purposes in oromaxillofacial surgery than the rotary one.

OSTEOTOMIA /  
TESSUTO OSSEO /  
TERMINALE  
PIEZOELETRICO /  
OSTEOTOMY /  
BONE TISSUE /  
PIEZO-ELECTRIC  
DEVICE

### INTRODUZIONE



La chirurgia con terminale piezoelettrico è stata ideata come risposta all'esigenza di superare i limiti legati all'uso degli strumenti tradizionali in chirurgia ossea. Lo strumento piezoelettrico Easy Surgery® della BioSAFin è ampiamente utilizzato nella chirurgia di tessuti ossei soprattutto quando la superficie ossea risulta essere molto sottile e a contatto con strutture nervose, vascolari o con la membrana del seno mascellare (fig. 1). In chirurgia orale, lo strumento piezoelettrico è utilizzato ampiamente nei rialzi di seno mascellare, nell'espansione di creste atrofiche, nella preparazione preimpianto, nella distrazione ossea e nel prelievo di osso. Numerose ricerche sono state effettuate per valutare non solo i vantaggi che questo strumento può presentare dal punto di vista clinico, ma anche l'influenza che esso può avere sulla guarigione ossea in seguito ad osteotomia. Tuttavia sono state eseguite soprattutto valutazioni istologiche ma scarsi sono stati gli studi di tipo biomolecolare.





Il nostro studio si propone di valutare la risposta ossea in seguito ad osteotomia effettuata con frese rotanti o con terminale piezoelettrico. L'influenza esercitata sull'osso dall'una o dall'altra tecnica chirurgica viene valutata attraverso:

- › uno studio istologico, allo scopo di valutare, per mezzo di colorazioni istologiche sopravitali, l'estensione dell'area di necrosi lungo le linee marginali di taglio;
- › uno studio di biologia cellulare, che si basa sull'osservazione della velocità di crescita degli osteoblasti provenienti da biopsie prelevate con entrambe le tecniche;
- › uno studio biomolecolare, attraverso l'analisi della variazione dell'espressione di marcatori molecolari di osteoblasti quali l'osteoprotegerina (OPG) e l'osteopontina (OPN).

L'OPG fa parte della famiglia dei recettori delle Tumor Necrosis Factor il cui

ruolo è quello di inibire la differenziazione dei macrofagi in osteoclasti regolando la funzione del riassorbimento osseo. L'OPN è una delle più abbondanti proteine non collageniche del tessuto osseo, appartiene al gruppo delle sialoproteine, è prodotta sia dagli osteoblasti che dagli osteoclasti e potrebbe avere un ruolo nella regolazione della matrice mineralizzata perché sembra essere capace di promuovere l'adesione delle cellule ossee alla superficie ossea.

### MATERIALI E METODI

In questo studio sperimentale sono stati selezionati:

- › per lo studio istologico, 20 pazienti (10 uomini e 10 donne), di età compresa tra i 22 ed i 65 anni, selezionati presso il Dipartimento di Chirurgia Orale del San Raffaele di Milano,

che necessitavano interventi di chirurgia orale;

- › per lo studio di biologia cellulare, 19 pazienti (10 uomini e 9 donne), di età compresa tra gli 11 ed i 65 anni selezionati presso lo stesso Dipartimento, che necessitavano interventi di chirurgia orale.

I criteri di scelta sono stati: per le donne la necessità di non essere in gravidanza, per tutti la necessità di essere in buona salute ed assenza di patologie sistemiche.

L'età media dei pazienti trattati con lo strumento piezoelettrico si aggirava intorno ai 40 anni mentre il gruppo trattato con strumenti rotanti presentava una età media di 46,5 anni, differenza, questa, risultata non statisticamente rilevante.

Nessuna caratteristica morfologica ossea era richiesta per la selezione dei pazienti.



FIG. 1

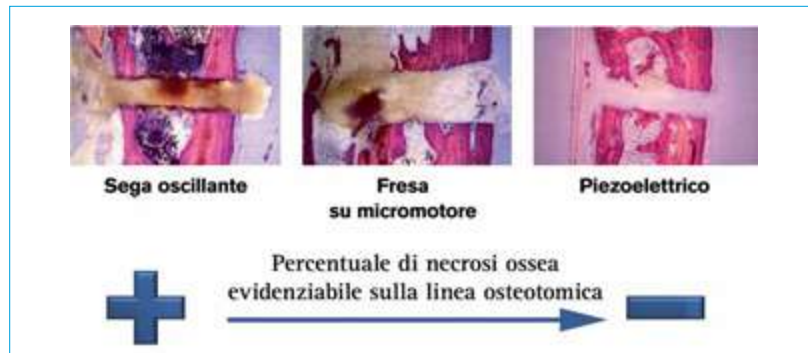


FIG. 2

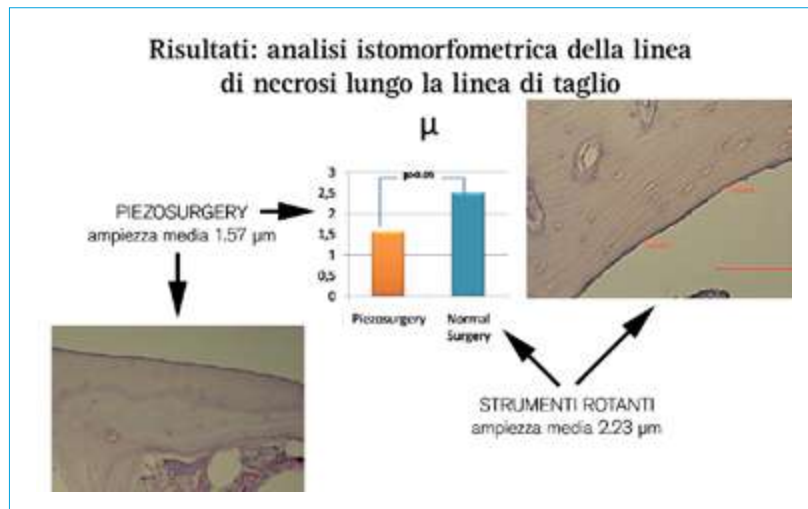


FIG. 3



### Risultati: osservazione del tasso di crescita delle cellule osteoblastiche in vitro

Tempo medio per l'inizio della crescita cellulare in vitro

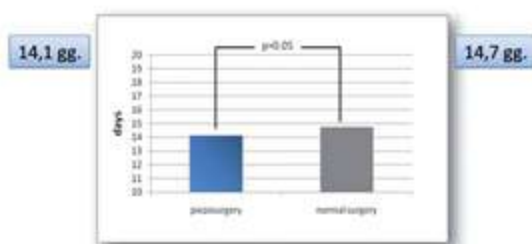


FIG. 4

### Risultati: tempo medio per il raggiungimento della confluenza cellulare

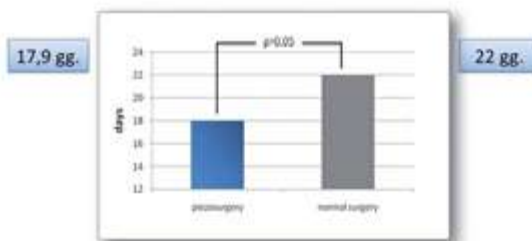


FIG. 5

Ai pazienti sono stati casualmente assegnati i trattamenti con terminale piezoelettrico o con frese rotanti. Le biopsie sono state effettuate attraverso l'utilizzo di frese rotanti o attraverso il terminale piezoelettrico. Le procedure chirurgiche sono state effettuate in anestesia locale. È stata effettuata un'incisione muco-periosteale con bisturi convenzionale e si è successivamente proceduto alla scheletrizzazione del sito anatomico interessato. Quale che fosse l'intervento da eseguirsi è stato prelevato un campione di tessuto osseo sia con terminale piezoelettrico sia con

strumenti convenzionali. Dopo il prelievo, i campioni sono stati posti in formolina 10% per 3 giorni, trattati e successivamente decalcificati e tagliati in fette da 6 micrometri analizzate al microscopio.

Per lo studio dell'espressione genica, le biopsie sono state poste processate al fine di selezionarne gli elementi cellulari ed indurle la proliferazione. Indipendentemente dalla rapidità di crescita, ogni quindici giorni circa sono state sostituite le flask per evitare contaminazioni. Le cellule arrivate a confluenza sono state staccate con tripsina e tra-

sferite in flask di crescenti dimensioni. Una volta ottenuta una quantità sufficiente di cellule, queste sono state staccate attraverso un cell scraper e si è proceduto all'estrazione dell'RNA. 4 µg di RNA totale sono stati retrotrascritti usando il kit Superscript First-Strand Synthesis System per l'analisi RT-PCR delle proteine OPG e OPN (fig. 2).

## RISULTATI

### Studio Istomorfometrico

Macroscopicamente l'osservazione dei campioni ha mostrato che le linee osteotomiche determinate dallo strumento piezoelettrico erano meglio definite rispetto a quelle dello strumento rotante. Nel primo caso con spessore 1,57 micrometri nel secondo caso 2,23 micrometri (fig. 3).

### Studio Cellulare

A livello di biologia cellulare, tenendo conto del fatto che uno studio effettuato in vitro presenta inevitabilmente dei limiti, possiamo affermare che i due tipi di osteotomia non sembrano influenzare significativamente la velocità di proliferazione degli osteoblasti.

Analizzando le velocità di crescita è emerso che il tempo medio di crescita era di 14,1 giorni per la crescita cellulare nei campioni ottenuti con lo strumento piezoelettrico, con confluenza cellulare a 17,9 giorni e di 14,7 giorni per la crescita cellulare per i campioni ottenuti con strumenti rotanti e confluenza cellulare a 22 giorni. Le differenze comunque non sono statisticamente significative  $p > 0,05$  (figg. 4, 5).

### Studio Biomolecolare

L'induzione dell'RNA per OPG e OPN è risultata essere estremamente variabile e probabilmente condizionata dall'età del paziente (fig. 6).

## DISCUSSIONE

Il vantaggio dello strumento piezoelettrico sta nel miglioramento della guarigione del tessuto osseo che vede ridotta o eliminata l'infiammazione. L'unico limite dello strumento piezoelettrico sembra essere il suo utilizzo in regioni di difficile accesso e nel taglio di osso compatto.

Le sezioni istologiche ottenute con lo strumento piezoelettrico mostrano assenza di necrosi e normale vitalità del

RICERCA

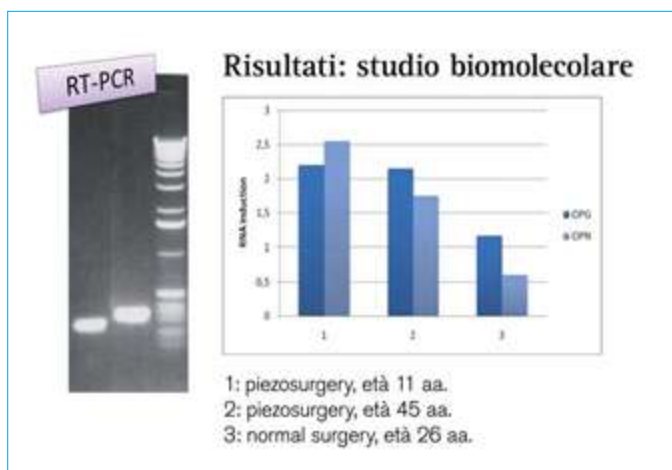


FIG. 6

tessuto osseo, elemento probabilmente dovuto alle microvibrazioni che causano il minimo trauma.

La presenza di linee di necrosi nella zona del taglio sembra comunque essere fisiologica e dovuta al fatto che determinate cellule sono state interessate dal taglio stesso.

Si è notato che esiste una significativa relazione tra l'età del paziente e la rigenerazione del tessuto osseo.

Dopo RT-PCR si è visto che l'espressione dei markers ossei tipici OPG e OPN non era correlata alla tecnica operatoria ma al genotipo del paziente; questo dato richiede una valutazione ulteriore.

In conclusione il processo di guarigione dei tessuti e la rigenerazione ossea risulta essere correlata a due fattori principali:

- » la risposta del soggetto all'intervento chirurgico;
- » la tecnica utilizzata.

Il primo fattore è biologico e dipende da:

- » età e relativo numero di cellule staminali disponibili per il processo di guarigione;
- » efficienza della vascolarizzazione;
- » eventuale tabagismo;
- » presenza di microangiopatie;
- » caratteristiche locali del tessuto del sito dell'intervento. L'edentulia infatti è un fattore che influenza sia il tessuto osseo che quello gengivale.

Il secondo fattore dipende da:

- » esperienza e capacità del chirurgo;

» strumento utilizzato: un intervento meno invasivo e cruento determina una migliore guarigione postoperatoria, quindi lo strumento piezoelettrico è da considerarsi preferibile.

La valutazione critica dei risultati ottenuti, correlati alla semplicità di esecuzione della tecnica operatoria, alla maggiore visibilità del campo operatorio, al rispetto di strutture sensibili quali vasi e nervi, la massima precisione nel taglio, il minimo danno ai tessuti che permette una riduzione del disagio del paziente e la sensibile riduzione dei tempi di guarigione, suggeriscono che lo strumento piezoelettrico, rispetto a quello rotante, sia più efficace e largamente indicato per molteplici utilizzi nella chirurgia oromaxillofaciale.

## BIBLIOGRAFIA

- 1) Aro H, Kallioniemi H, Aho AJ, Kellokumpu-Lehtinen P. Ultrasonic device in bone cutting. A histological and scanning electron microscopical study. *Acta Orthop Scand* 1981;52(1):5-10.
- 2) Horton JE, Tarpley TM Jr, Wood LD. The healing of surgical defects in alveolar bone produced with ultrasonic instrumentation, chisel, and rotary bur. *Oral Surg Oral Med Oral Pathol* 1975;39(4):536-46.
- 3) Morgan TA, Fridrich KL. Effects of the multiple-piece maxillary osteotomy on the periodontium. *Int J Adult Orthodon Orthognath Surg* 2001;16(4):255-65.
- 4) Pallensen L SS, Aaboe M, Hjorting Hansen E, Nattestad A, Melsen F. Influence of particle size of autogenous bone grafts on the early stages of bone regeneration: a histologic and stereologic study in rabbit calvarium. *Int J Oral Maxillofac Implants* 2002(17):498-506.
- 5) Robiony M, Polini F, Costa F, Vercellotti T, Polti M. Piezoelectric bone cutting in multipiece maxillary osteotomies. *J Oral Maxillofac Surg* 2004;62(6):759-61.
- 6) Tete S, Vinci R, Zizzari V, Cingano L, Bollero R, D'Apolito G, Benzo L, Dolci A, Mortellaro C, Gherlone E. Evaluation of effects on bone tissue of different osteotomy techniques. *J Craniofac Surg* 2009 Sep;20(5):1424-9.
- 7) Torrella F, Pitaroh J, Cabanes G, Anitua E. Ultrasonic osteotomy for the surgical approach of the maxillary sinus: a technical note. *Int J Oral Maxillofac Implants* 1998;13(5):697-700.
- 8) Vercellotti T. Piezoelectric surgery in implantology: a case report--a new piezoelectric ridge expansion technique. *Int J Periodontics Restorative Dent* 2000;20(4):358-65.
- 9) Vercellotti T, Giannotti S. A new piezoelectric ridge expansion technique in the lower arch: a case report *World dent* 2003;14(2):1-3.
- 10) Vercellotti T, Corvace A, Palermo A, Molfetta A. The piezoelectric osteotomy in orthopedics: clinical and histological evaluations (pilot study in animals). *Mediterranean Journal of surg med* 2001(9):89-95.
- 11) Vercellotti T, De Paoli S, Nevins M. The piezoelectric bony window osteotomy and sinus membrane elevation: introduction of a new technique for simplification of the sinus augmentation procedure. *Int J Periodontics Restorative Dent* 2001;21(6):561-7.
- 12) Vercellotti T, Nevins ML, Kim DM, Nevins M, Wada K, Schenk RK, et al. Osseous response following resective therapy with piezosurgery. *Int J Periodontics Restorative Dent* 2005;25(6):543-9.

## SUPPLEMENTO DOCTOR OS

<sup>1</sup> S. Zandonella Necca,  
<sup>1</sup> F. Bova,  
<sup>1</sup> E. F. Gherlone

## Analisi retrospettiva a quattro anni degli esiti di trattamento implanto-protesico eseguiti con sistemica Winsix®

<sup>1</sup> Università Vita-Salute San Raffaele (MI)  
 Facoltà di Medicina e Chirurgia  
 Corso di Laurea in Igiene Dentale  
 Presidente: Prof. E. F. Gherlone

I.R.C.C.S. San Raffaele (MI)  
 Unità Operativa di Odontoiatria  
 Direttore: Prof. E. F. Gherlone

**S**ono stati considerati 409 pazienti che nel periodo compreso tra marzo 2006 e marzo 2010 si sono sottoposti a riabilitazione implanto-protesica presso l'Unità Operativa di Odontoiatria dell'I.R.C.C.S. San Raffaele di Milano. Complessivamente in questi pazienti sono stati posizionati 1438 impianti Winsix® tutti a superficie BioActive Covering SLA®. Parte di questi pazienti (209), successivamente al carico degli impianti, sono afferiti al programma di mantenimento implantare attivato presso il Centro di Igiene Orale e Prevenzione attivato presso la stessa U.O. di Odontoiatria. Per ciascun paziente si è proceduto ad analizzare i livelli di esposizione ai fattori di rischio noti per la malattia perimplantare (pregressa parodontite, scarsa igiene orale, diabete, tabagismo, assunzione di bevande alcoliche). Nei pazienti sottoposti a mantenimento è stato possibile rilevare, per ogni impianto, l'insieme dei parametri clinici e tecnici atti a determinare lo stato di salute del sito implantare (profondità di sondaggio, sanguinamento al sondaggio, segni radiografici di riassorbimento dell'osso di supporto, mobilità).

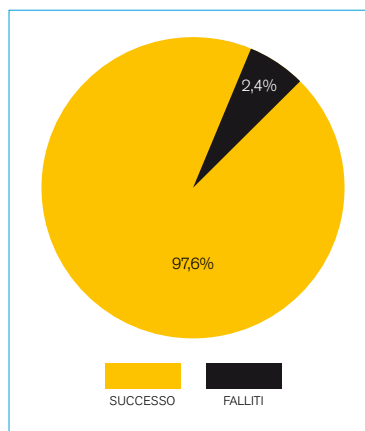


fig. 1

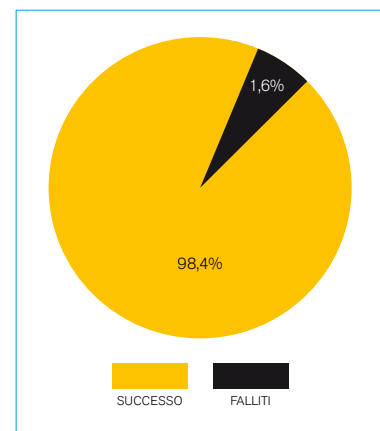


fig. 2

### ANALISI DEI DATI

Su 1438 impianti posizionati, 32 sono andati incontro a fallimento, fermando al 2,4% l'incidenza di fallimento (fig. 1). In 6 casi il fallimento si è verificato in pazienti dediti al tabagismo ed in altri 12 in pazienti con storia di pregressa parodontite. Restringendo l'analisi ai pazienti sottoposti a programma di mantenimento (209 pazienti e 682 impianti), l'incidenza di fallimento scende all'1,6% (11 im-

pianti falliti) (fig. 2). Il sondaggio in 6 punti di questi siti implantari ha permesso di valutare che solo il 15% di essi presentano PPD  $\geq$  4mm (fig. 3). Inoltre, su 682 impianti in mantenimento, in 33 casi è presente perimplantite, in 309 mucosite ed i restanti 340 siti sono in condizione di salute perimplantare (fig. 4). Analizzando infine i dati relativi ai valori medi di indice di placca (PI) e di sanguina-

fig. 1  
 Incidenza di fallimento nell'intero campione.

fig. 2  
 Incidenza di fallimento nel gruppo dei pazienti in mantenimento.

## SUPPLEMENTO DOCTOR OS

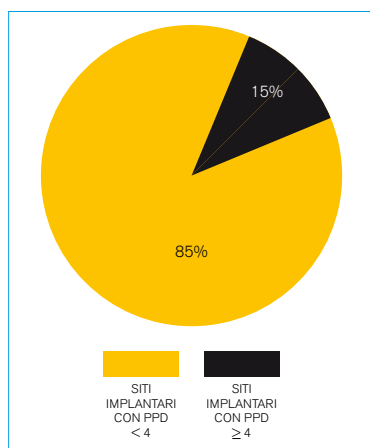


fig. 3

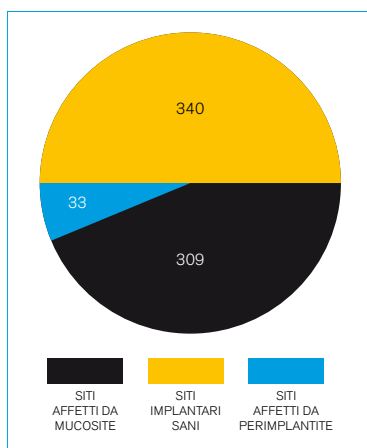


fig. 4

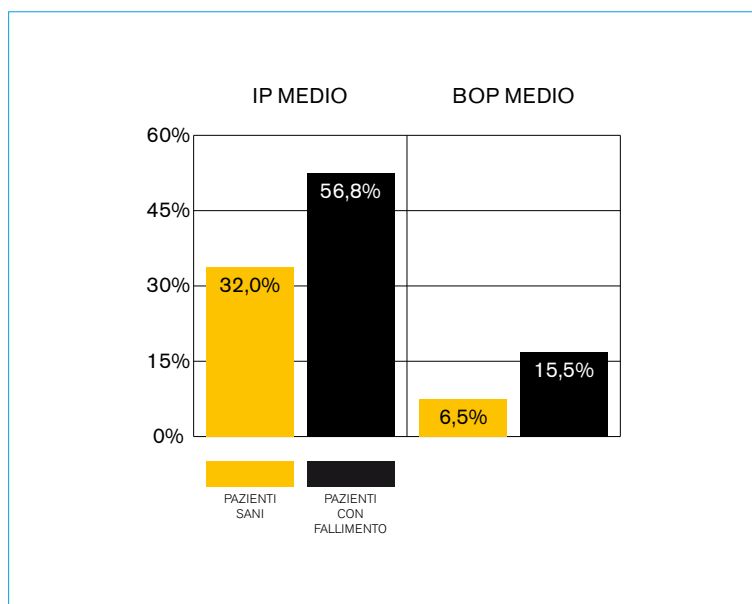


fig. 5

mento (BOP) secondo O'Leary, sono state individuate sostanziali differenze tra i pazienti in mantenimento che hanno sofferto fallimento implantare e non. I primi mostrano valori medi di PI e BOP rispettivamente maggiori del 24,8% e del 9% (fig. 5).

## CONCLUSIONI

Il trattamento della malattia perimplantare non è risolutivo nel caso in cui si manifesti in forma di perimplantite. Inoltre, i tessuti perimplantari sono più suscettibili alla lesione infiammatoria rispetto ai tessuti parodontali. Sulla scorta di queste considerazioni appare quindi evidente l'importanza di inserire i pazienti riabilitati con impianto-protesi in un programma di mantenimento che sia occasione utile a prevenire ed intercettare tempestivamente la comparsa di fenomeni infiammatori dei tessuti perimplantari e parimenti l'insorgenza di problematiche meccaniche localizzabili ai dispositivi implantari e/o protesici. L'abbattimento del tasso di incidenza di fallimento osservato nell'ambito di questo studio, benchè non siano stati indagati i fenomeni microbiologici alla base di questo risultato, può essere ritenuto probatorio dell'efficacia di un simile atteggiamento clinico.

fig. 3  
PPD negli impianti sottoposti a mantenimento.

fig. 4  
Mucosite e perimplantite nel gruppo dei pazienti in mantenimento.

fig. 5  
Valori medi di PI e BOP tra i pazienti in mantenimento andati incontro a fallimento implantare e non.

## BIBLIOGRAFIA

- Lindhe J, Berglundh T, Ericsson I, Liljenberg B, Marinello CP. Experimental breakdown of perimplant and periodontal tissues. A study in beagle dog. *Clinical Oral Implants Research* 1992; 3: 9-16
- Lang NP, Bragger U, Walter D, Beamer B, Kornman KS. Ligature-induced peri-implant infection in cynomolgus monkeys. *Clinical Oral Implants Research* 1993; 4: 2-11
- Schou S, Holmstrup P, Stoltze K, Hjorting-Hansen E, Kornman KS. Ligature-induced marginal inflammation around osseointegrated implants and ankylosed teeth. Clinical and radiographic observation in cynomolgus monkeys. *Clinical Oral Implants Research* 1993; 4: 12-22
- Marinello CP, Berglundh T, Ericsson I, Klinge B, Glantz PO, Lindhe J. Resolution of ligature-induced peri-implantitis lesion in the dog. *Journal of Clinical Periodontology* 1995; 22: 475-480
- Ericsson I, Persson LG, Berglundh T, Edlund T, Lindhe J. The effects of antimicrobial therapy on peri-implantitis lesion. An experimental study in dog. *Clinical Oral Implants Research* 1996; 7: 320-328
- Persson LG, Ericsson I, Berglundh T, Lindhe J. Guided bone regeneration in the treatment of periimplantitis. *Clinical Oral Implants Research* 1996; 7: 366-372
- Gottfredsen K, Berglundh T, Lindhe J. Bone reactions at implants subjected to experimental peri-implantitis and static load. An experimental study in the dog. *Journal of Clinical Periodontology* 2002; 29: 144-151
- Berglundh T, Claffey N, De Bruyn H, Heltz-Mayfield N, Karoussis I, Könönen E, Lindhe J, Meyle J, Mombelli A, Renvert S, van Winkelhoff A, Winkel E, Zitzmann N. Peri-implant diseases: consensus report of the sixth european workshop on periodontology. *Journal of Clinical Periodontology* 2008 Sep; 35(8 Suppl): 282-285



di M. Manacorda, R. Vinci  
M. Pasi, E. F. Gherlone

## TEETH JUST ON SIX

### Riabilitazione implantoprotesica nei casi edentulia completa un approccio diagnostico-terapeutico integrato

Dipartimento di Odontoiatria (Dir. Prof. E. F. Gherlone)  
Univ. Vita-Salute, IRCCS San Raffaele, Milano

Levoni scientifici

#### DALLA DIAGNOSTICA PER IMMAGINI ALLA PROTESIZZAZIONE

La riabilitazione del paziente totalmente edentulo tramite protesi fissa implantosupportata presenta numerosi problemi riguardanti l'approccio chirurgico, la funzione e l'estetica. Ciò appare particolarmente evidente qualora il trattamento si presenti particolarmente complesso a causa del grado di atrofia delle strutture ossee residue in relazione al tipo di chirurgia che verrà utilizzata, oppure ai problemi psicologici che inevitabilmente si accompagnano al decadimento dell'estetica dei tessuti periorali che si modificano in modo drammatico nell'edentulo, influenzando quindi significativamente le aspettative riposte dal paziente nei confronti del trattamento riabilitativo. Nell'affrontare casi di questa complessità è lo studio del caso, supportato dalle tecniche di diagnostica clinica, strumentale, clinica strumentalmente assistita e per immagini dell'apparato stomatognatico che risul-

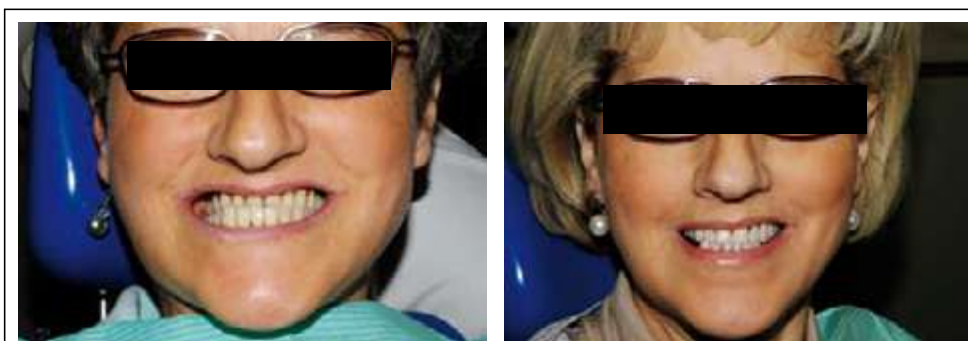ta decisivo ai fini del raggiungimento di un risultato predicibile e soddisfacente.

#### OBIETTIVI DEL TRATTAMENTO

La pianificazione del trattamento, da un punto di vista teorico, presuppone l'impiego di tecniche e strumenti innovativi che abbiamo selezionato e integrato nel seguente approccio diagnostico e terapeutico.

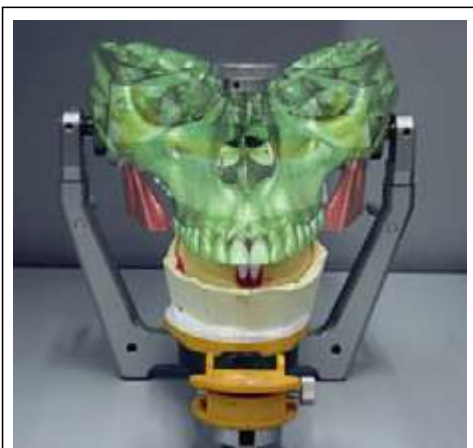Il protocollo è variabile e modificabile a seconda delle esigenze del singolo paziente e trova la sua indicazione specifica nei casi di riabilitazione implantoprotesica più complessi, dove alla **ricostruzione dento-alveolare** dei mascellari completamente edentuli si accompagna un'evidente necessità di riabilitazione funzionale ed estetica che coinvolge il terzo inferiore e medio del volto nelle sue proporzioni e nella sua armonia. (Fig. 1) e esistono ma anche mostrare il modo in cui trattarle.

L'obiettivo non è quindi limitato a garantire la stabilità della protesi sugli impianti, ma è rivolto alla ricerca di



**Fig. 1** Esempio di edentulia superiore con grave compromissione della funzionalità e dell'estetica. A destra, il risultato dopo l'intervento riabilitativo

247



**Fig. 2** L'articolatore e il modello virtuale 3D: una volta definite le coordinate spaziali comuni le soluzioni proposte con un metodo diagnostico possono essere trasferite agli altri strumenti di indagine (A. Busato)



**Fig. 3** L'articolatore con i valli diagnostici in resina che montano elementi dentari radiopachi. Uno studio cefalometrico in 2D sulla teleradiografia analizza i parametri del montaggio e ne conferma la correttezza dopo la prova nel cavo orale

una restitutio ad integrum delle funzioni del cavo orale e dell'estetica del terzo inferiore del volto.

In sintesi, gli argomenti che affrontiamo nello studio e nella programmazione del caso si riassumono nei seguenti passaggi:

- 1) definire, tramite i dati che riguardano la struttura specifica del paziente, un percorso diagnostico individuale ed elaborare un modello virtuale nel quale identificare e simulare le soluzioni terapeutiche possibili
- 2) definire sistemi di coordinate che facciano convergere i dati comuni alle diverse metodiche di indagine, per consentire l'allestimento di un modello virtuale del paziente (Fig. 2)
- 3) definire un sistema di coordinate che siano comuni al modello virtuale realizzato e al paziente
- 4) elaborare strumenti che consentano di simulare reversibilmente nel paziente gli obiettivi annunciati
- 5) elaborare strumenti che consentano di trasferire i contenuti programmati dal modello virtuale al paziente

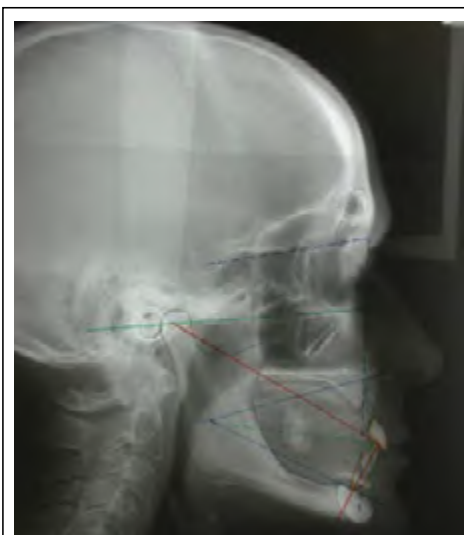#### LO STUDIO DEL CASO

Da un punto di vista pratico, gli strumenti e i passaggi operativi impiegati nel trattamento del paziente sono l'esame clinico obiettivo, la diagnostica strumentale dell'occlusione, la diagnostica per immagini dei tessuti intra ed extraorali, la diagnostica clinica strumentalmente assistita e la programmazione integrata del percorso riabilitativo.

Clinicamente, l'iter diagnostico passa attraverso le seguenti fasi:

- 1) rilievo delle impronte e montaggio dei modelli in articolatore a valori medi (Fig. 3)
- 2) realizzazione di valli di registrazione oclusale di prova in resina con elementi radiopachi
- 3) teleradiografia del cranio in proiezione laterale con i valli ed esame cefalometrico in 2D (Fig. 4)

- 4) realizzazione della protesi provvisoria diagnostica
- 5) valutazione strumentale e per immagini della congruità del provvisorio diagnostico: RMN, assio-grafia elettronica, fotografie diagnostiche, esame facciale e cefalometria delle parti molli
- 6) costruzione della protesi radiopaca, copia identica della protesi provvisoria diagnostica, o preparazione della protesi diagnostica per la TC
- 7) TC del massiccio facciale con la protesi radiologica in situ



**Fig. 4** Teleradiografia con studio cefalometrico, la valutazione comprende importanti parametri proposti dal montaggio, quali il sostegno delle labbra, la dimensione verticale, l'inclinazione del piano oclusale e il conseguente rimodellamento del terzo inferiore del volto

- 8) progettazione dell'intervento chirurgico implantare sul software dedicato all'implantologia
- 9) trasformazione della dima radiologica in dima chirurgica, o sua costruzione con tecnica CAD/CAM
- 10) intervento chirurgico, generalmente effettuato con tecnica "flapless" per carico immediato degli impianti
- 11) montaggio della protesi passivizzata, se è programmata la protesizzazione immediata

### DAI MODELLI STUDIO ALLA PROTESI DIAGNOSTICA

La raccolta di dati, ottenuti con tecniche di indagine molto diverse tra loro, rende necessaria la disponibilità di metodiche affidabili per la loro integrazione e il loro confronto. Una delle necessità più evidenti riguarda la definizione di un sistema di coordinate comuni tra tecniche di immagine come le radiografie e l'articolatore su cui vengono montati i modelli dell'arcata edentula.

Si tratta di definire un tramite semplice ed immediato tra la teleradiografia del cranio in proiezione latero-laterale e l'articolatore sul quale vengono realizzate le protesi totali. Questo si ottiene ponendo sulla cute del paziente tre reperi radiopachi: due in corrispondenza delle emergenze dell'asse cerniera e una in corrispondenza della proiezione cutanea sull'ala del naso del punto orbitale inferiore. Il piano asse-orbitario così definito permette di effettuare sulla radiografia latero-laterale un'analisi quantitativa di parametri quali la classe scheletrica di appartenenza, l'orientamento del piano occlusale, la posizione e l'inclinazione dell'incisivo inferiore rispetto al piano mandibolare,

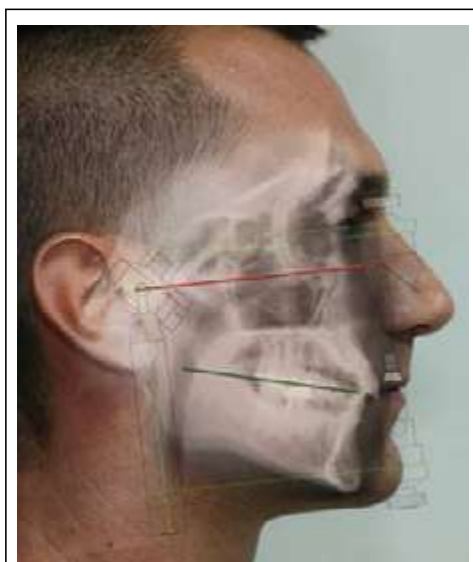la dimensione verticale totale, i rapporti del terzo inferiore del volto.

I dati, verificati e corretti, vengono trasferiti sull'articolatore, che grazie all'uso dell'arco facciale ha in comune con la teleradiografia il piano asse-orbitario. I parametri del montaggio dei denti vengono quindi trasferiti al cavo orale tramite la protesi diagnostica. Questo sistema permette inoltre un'analisi precisa degli effetti che il progetto riabilitativo determina sul sostegno delle parti molli e sulle relazioni funzionali e spaziali delle componenti dello scheletro facciale. (Fig. 5)


In sintesi: i dati ottenuti dalle prove con i valli di registrazione in cera sono verificati grazie a specifici valli di prova in resina. Il controllo radiografico viene quindi effettuato sulla teleradiografia latero-laterale (Fig. 4) e l'esame facciale delle parti molli con l'esame obiettivo e le foto diagnostiche. (Fig. 6)

Il passaggio successivo prevede la finalizzazione della **protesi diagnostica** che replica le caratteristiche dei valli diagnostici, con le opportune correzioni funzionali ed estetiche. Con la protesi diagnostica si è in grado di valutare in quale misura siano stati raggiunti gli obiettivi estetici e funzionali progettati.

Strumenti propri della diagnostica clinica strumentalmente assistita (Assiografia Elettronica) e della diagnostica per immagini (RMN) si possono integrare in questa fase sia a scopo di pianificazione che per il monitoraggio funzionale, in pazienti con conclamate disfunzioni articolari. Le disarmonie del viso riscontrate nei pazienti edentuli sono spesso drammaticamente evidenti all'esame



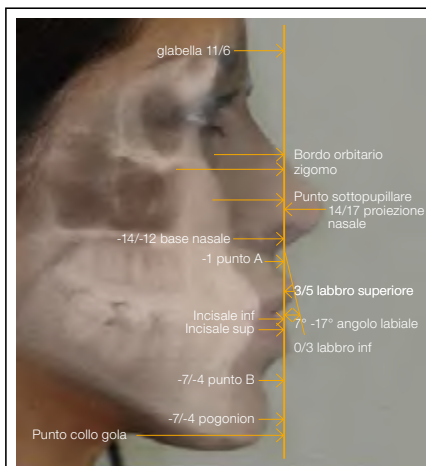
**Fig. 5** I dati ottenuti sul tracciato cefalometrico, grazie alla coincidenza del piano asse-orbitario, sono trasferiti al montaggio in articolatore e guidano la costruzione della protesi diagnostica



**Fig. 6** L'esame facciale sulle foto cliniche convalida il progetto protesico in fase diagnostica sia da un punto di vista soggettivo, sia in modo oggettivo, in quanto utilizza "indici facciali" considerati corretti per ottenere un risultato estetico proporzionato (G. W. Arnett).

clinico a causa di un decadimento dell'estetica del terzo medio ed inferiore del volto molto marcato.

La correzione del dismorfismo facciale affidata al senso estetico e alla sensibilità degli operatori è molto utile, ma si ritiene più valido l'impiego di un metodo che fornisca elementi di misurazione oggettivi delle strutture anatomiche



**Fig. 7** L'esame cefalometrico delle parti molli (ACTM secondo G.V. Arnett) permette di avere un riscontro quantitativo delle variazioni nell'equilibrio del viso. Introducendo i valori dell'esame facciale ottenuti portando la protesi diagnostica si è in grado di misurare i parametri relativi all'armonia facciale. In pratica si può quantificare oggettivamente un inestetismo facciale misurandone le componenti e identificandone le cause anatomiche. Con questo studio si è in grado di valutare oggettivamente il miglioramento ottenuto sull'estetica facciale, grazie alla protesi diagnostica. È possibile cioè, grazie alla ACTM, apportare modifiche all'estetica del viso ricercando parametri numerici e angolari considerati normali. Affetti spesso da un grave decadimento dell'estetica indotto dall'edentulia, i pazienti sono in grado di apprezzare il notevole miglioramento del loro aspetto già dalla fase progettuale dell'intervento ricostruttivo.

che, quale l'analisi cefalometrica delle parti molli (ACTM) proposta da Arnett e Mc Laughlin. (Fig. 7)

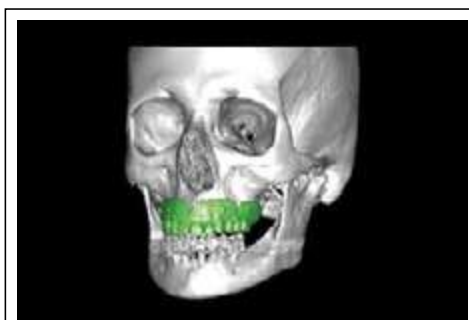#### LA TC E LA SUA ELABORAZIONE CON SOFTWARE DEDICATI

Terminata la fase di test della protesi diagnostica e confermata la sua validità, si costruisce una copia esatta della protesi in materiale radiopaco: la dima radiologica. Con la dima il paziente effettua l'esame tomografico che può essere una TC o una CBTC, nel secondo caso con notevole risparmio di esposizione ai Raggi X.

Nuovi software e tecniche di sovrapposizione digitale delle immagini scansionate evitano oggi di costruire una replica radiopaca della protesi diagnostica. Utilizzando la tecnica "double scan" il paziente può effettuare l'esame direttamente con la protesi diagnostica inserita, con notevole risparmio di tempo e di ulteriori fasi di laboratorio. Inoltre, evitando la costruzione di un nuovo manufatto, diminuiscono eventuali errori di

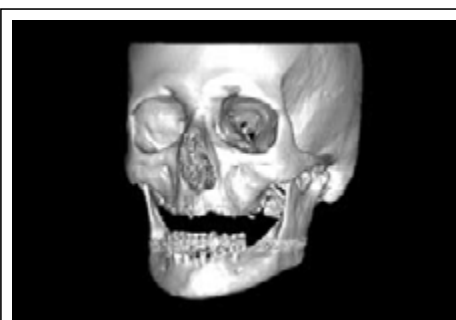posizione e difetti di scansione dovuti allo scattering del materiale bariato radiopaco. La protesi diagnostica viene in questo caso fornita di reperi radiopachi che permettono la creazione di un secondo sistema di coordinate spaziali comuni sia al paziente che alla ricostruzione tridimensionale delle immagini TC. (Figg. 8, 9)

Il software permette all'implantologo di pianificare l'intervento chirurgico e di effettuarlo in modo virtuale: localizzazione, numero e dimensioni delle *fixture* vengono selezionate e quindi posizionate nelle sedi prescelte. In seguito è possibile visualizzare gli *abutment* e verificarne i rapporti con la protesi diagnostica. Nel contempo il programma di **Computer Aided Implantology** memorizza le coordinate spaziali degli impianti e trasferisce i dati ad un fresatore da laboratorio che replica il progetto dell'intervento virtuale al modello di lavoro in articolatore. Questa tecnica, impiegata da molte sistematiche oggi in commercio, è definita *Model Based*.



**Fig. 8** Immagine della ricostruzione 3D della TC con la protesi diagnostica inserita effettuata con tecnica "double scan". Si notino i corretti rapporti interarcata.

La scelta e il posizionamento degli impianti tengono conto non solo della disponibilità ossea residua, ma anche del montaggio programmato degli elementi dentari e del tipo di ricostruzione protesica prescelta



**Fig. 9** Immagine 3D delle arcate edentule ottenute dalla TC. Da queste ricostruzioni appare evidente come l'atrofia alveolare comporti importanti alterazioni della morfologia scheletrica dell'edentulo e dei rapporti intermasscellari. Una quantificazione del dismorfismo nel progetto ricostruttivo rende spesso evidente la necessità di una sostituzione protesica della porzione alveolare atrofica o di un intervento chirurgico additivo rigenerativo

Nel caso invece di software di *Imaging 3D* come il *Simplant* di *Materialise*, i dati del progetto vengono inviati a un centro specializzato in stereo litografia, dove viene costruita una guida chirurgica chiamata *Surgiguide*, il cui compito è quello di guidare le frese nelle sedi programmate dall'operatore sul software. È possibile inoltre costruire repliche stereolitografiche del modello anatomico con gli analoghi e gli abutment già inseriti, per la costruzione di un provvisorio immediato (*Immediate Smile*<sup>®</sup>, *Materialise*).

La protesi diagnostica ad appoggio mucoso viene quindi replicata in stereolitografia per essere impiegata come dima chirurgica, necessaria per inserire gli impianti nel cavo orale esattamente nelle posizioni programmate, grazie all'impiego di cilindri-guida e riduttori per adattare le frese di diverso diametro.

Ad oggi la sistematica di programmazione prechirurgica con tecnica *Model Baseo* di *Imaging 3D* e il suo impiego per la costruzione di guide chirurgiche ha un *follow up* di oltre vent'anni e con la sua continua evoluzione ha dato risultati confortanti anche in termini di affidabilità e precisione. Studi pubblicati da Benjamin e Sarment e poi da Valente riportano il buon grado di precisione della metodica nel trasferire i dati informativi alla sala operatoria.

Il grado di affidabilità del sistema è mediamente costante e il margine di errore si attesta su 4,5 gradi in termini di discrepanza angolare sull'asse lungo degli impianti e di circa un millimetro misurando il centro della parte coronale dell'impianto virtuale e il centro dell'osteotomia in vivo (Sarment 2003).

#### PIANIFICAZIONE IMPLANTARE PROTESICAMENTE E FUNZIONALMENTE GUIDATA

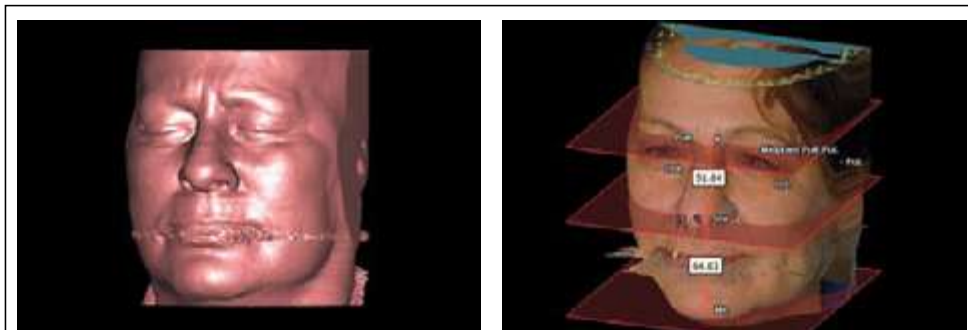
I software dedicati all'implantologia guidata sono un'evoluzione del primo *Denta Scan* e fondamentalmente permettono di interagire con i dati Rx sia sulla componente 2D che sulla loro ricostruzione tridimen-

sionale. Siamo in grado di effettuare misurazioni, selezionare visioni di tessuti specifici, ottenere immagini di endoscopia virtuale, calcolare la densità ossea per impiantare e soprattutto posizionare virtualmente gli impianti seguendo le indicazioni fornite dalla protesi scansionata. In sintesi, possiamo ottenere una pianificazione chirurgica realmente guidata dal progetto protesico.

Un'ulteriore opportunità dell'elaborazione dei dati TC riguarda la possibilità di sovrapporre fotografie del paziente all'elaborato 3D della cute. Con questa applicazione possiamo riprodurre l'aspetto estetico del volto ottenuto con il progetto implantoprotesico e misurarne nel dettaglio le diverse componenti. Un approccio diagnostico-terapeutico che si avvalga di un cefalometria 3D realizzata sulle immagini tomografiche, denominato *Total Face Approach*<sup>®</sup> è in corso di validazione e approfondimento con uno studio multicentrico dei dottori T. Testori e G. Perrotti (Como).

L'importanza di un approccio globale alla diagnostica 3D è di facile comprensione, basti pensare al suo potenziale impiego in chirurgia ortognatodontica o nella pianificazione di interventi di chirurgia maxillo-facciale. Nell'ambito implantoprotesico, uno studio cefalometrico basato sull'esame delle immagini 3D può facilmente sostituire l'analisi bidimensionale delle precedenti metodiche di indagine e permette di riunire in un unico esame i dati confluenti da precedenti tecniche strumentali e di imaging scisse tra loro.

Nella figura 10 si vede la ricostruzione 3D dei tessuti molli ottenuta elaborando i dati *Dicom* della TC mediante il software *Simplant 13* (*Materialise*) e, accanto, l'immagine tridimensionale del volto del paziente ottenuta con la sovrapposizione di una foto frontale sul 3D tomografico, reso possibile con l'impiego del modulo OMS dello stesso programma. In corso di studio è l'applicazione della fotogrammetria 3D che permetterebbe di visualizzare effetti di *morphing* facciale sulle correzioni operate dal progetto chirurgico e protesico.



**Fig. 10** Immagine di una foto frontale del paziente in "matching" sulla ricostruzione tridimensionale dei tessuti molli della TAC. Ad ulteriore verifica, anche in 3D, della validità funzionale ed estetica della terapia ricostruttiva proposta mediante la protesizzazione diagnostica.



## CASO CLINICO

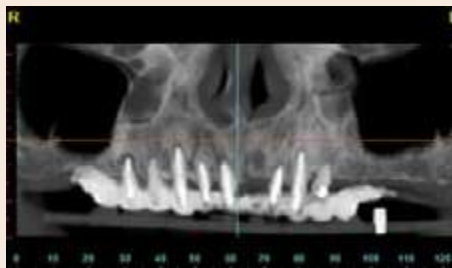### RICOSTRUZIONE DENTOALVEOLARE "TEETH JUST ON SIX" MAXILLARE GUIDATA

Paziente donna di 75 anni, in buona salute, necessita di bonifica all'arcata superiore a causa delle condizioni ormai irrecuperabili degli elementi dentari naturali, già pilastri di una protesi fissa. L'arcata protesica non è più stabile a causa delle gravi recessioni ossee da parodontopatia dei pilastri e fratture radicolari (Fig. 11). Dopo la bonifica e la protesizzazione immediata mediante protesi totale, si eseguono le valutazioni per la costruzione di una protesi diagnostica che soddisfi i criteri estetici e funzionali come descritto nei paragrafi precedenti. Inoltre la paziente desidera un miglioramento estetico che corregga la grave seconda classe dentale, il *deep bite* e l'*overjet* del gruppo frontale, oltre all'aspetto senescen-

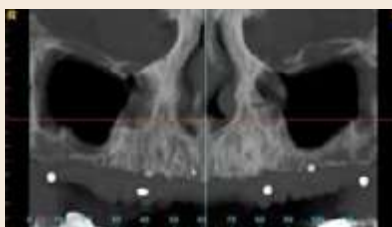te dei denti dell'arcata superiore. Lo scopo della protesi diagnostica è quindi quello di verificare la congruità del progetto protesico pianificato prima dell'inserimento delle fixture, che a loro volta saranno guidate protesicamente. Con la prova del montaggio diagnostico si testano i risultati estetico-funzionali apportati con le modifiche occlusali.

Completata la protesi diagnostica, si procede con l'esame tomografico in doppia scansione che viene eseguito con la protesi *in situ* munita di reperi radiopachi (Fig. 12). Per lo studio e l'elaborazione delle immagini assiali, ottenute in questo caso con una TAC spirale 16 strati, è stato impiegato il software *Simplant 13®* (Materialise).

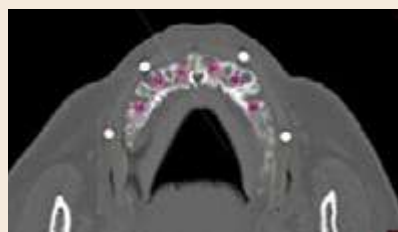
**Fig. 11** aspetto della paziente prima della bonifica e panoramica del mascellare estratta dalla elaborazione dei dati TAC: è già possibile una programmazione di massima degli impianti da utilizzare.



**Fig. 12** Il mascellare edentulo nella visione pseudo panoramica della TC. Le informazioni inerenti l'ampiezza ossea residua sono bidimensionali e statiche, inoltre mancano le indicazioni sullo spessore osseo e non si evincono dati sull'inclinazione degli impianti, né i loro futuri rapporti con la protesi progettata



**Fig. 13** Proiezione assiale e cross-section con progettazione del posizionamento degli impianti. Si notino gli alveoli delle recenti estrazioni e il progetto chirurgico per l'inserimento di sei impianti Winsix 3.8x13 k postestrattivi differiti.



### PROGETTAZIONE IMPLANTARE VIRTUALE IN 3D

L'utilità nell'impiego in studio dei software per la gestione delle immagini TC risiede nella possibilità di analizzare, oltre alle normali proiezioni assiali native, anche immagini tridimensionali ricreate dal programma partendo da tutte le scansioni. Si può quindi interagire con le immagini in 3D e lavorare su sezioni diverse comprese nel volume indagato.

Si possono visualizzare immagini simil-panoramiche, sezioni sagittali, *cross-section* ortogonali alla curva panoramica oltre alle proiezioni assiali native, l'anatomia topografica viene studiata in ogni sito impiantare prescelto per l'inserimento degli impianti. Lo studio dell'anatomia chirurgica risulta dunque estremamente chiaro e intuitivo. (Fig. 13)

La fase successiva prevede il posizionamento degli impianti, scelti dalla libreria del software, nelle sedi più idonee. Lunghezza e diametro delle *fixture* sono decise valutando il volume osseo residuo, ma anche la qualità ossea misurata dal software in base alla scala Hounsfield della zona da impiantare. A posizionamento avvenuto si applicano gli *abutment*, presenti nella libreria del programma per ogni sistemica di impianti, valutando l'emergenza, lo spessore mucoso e soprattutto il rapporto ottenuto tra gli impianti e gli elementi di protesi previsti per il manufatto definitivo. Si ottiene così una grafica precisa e attendibile della struttura impiantare e protesica. In seguito si possono apportare modifiche nel posizionamento delle *fixture* per rendere più semplice la connessione tra impianti e protesi programmata, compatibilmente con le basi ossee residue ma anche nel rispetto dei carichi occlusali previsti, dell'estensione del *cantilever* e dell'estetica.

Nel caso descritto è evidente (Fig. 14) come l'asse di inserzione degli impianti debba essere necessariamente vestibolarizzato al fine di sfruttare al massimo chirurgicamente la cresta ossea residua.

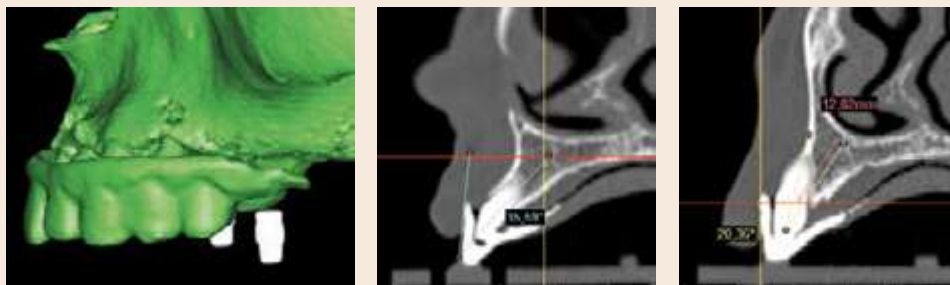
Un tentativo di ridurre l'*overjet* degli impianti si scontrerebbe con la regola fondamentale di sfruttare il più possibile le basi ossee come sedi per gli impianti, sa-

crificando la lunghezza e il diametro delle *fixture*. In questo caso inoltre ci si troverebbe di fronte ad aree crestali ossee ancora non riparate in conseguenza delle recenti estrazioni. A rendere ancora più complesso il problema, va ricordata la necessità di correggere la seconda classe dentale della paziente, proposta come obiettivo primario della riabilitazione. Come è possibile notare nella figura 14, vi sono discrepanze angolari fino a 35° nella zona degli incisivi centrali.

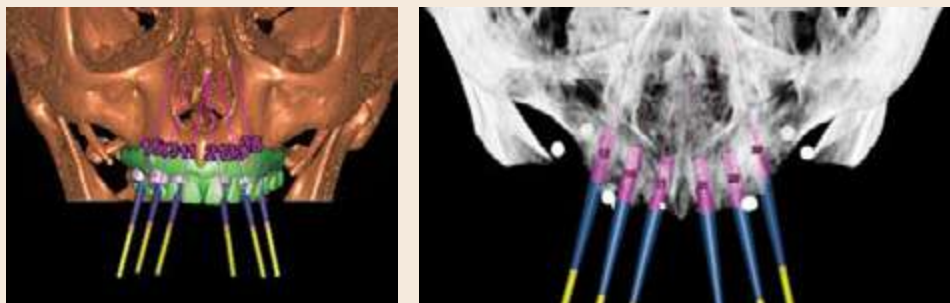
È a questo livello che le esigenze del chirurgo, del protesista e del tecnico in laboratorio devono interfacciarsi per ottenere un progetto realmente interdisciplinare e volto alla risoluzione delle difficoltà realizzative già in fase prechirurgica.

Si è così deciso di programmare una ricostruzione protesica tipo "Toronto", avvitata grazie alla possibilità di utilizzare *abutment* di connessione che compensino discrepanze anche notevoli tra l'asse maggiore delle *fixture* e l'asse di avvitamento della sovrastruttura (*Extreme Abutment, Winsix*).

Una volta definita la progettazione si salva il file contenente le coordinate spaziali degli impianti in modo che sia non più modificabile e lo si invia al laboratorio di stereolitografia per la costruzione della dima chirurgica, schematizzata nella figura 15.



**Fig. 14** Cross-section di due elementi prima della bonifica, pilastri di protesi da sostituire con due impianti. Si noti l'angolazione sfavorevole tra l'asse maggiore degli impianti e l'inclinazione dei denti della protesi pianificata con un mock-up radiopaco



**Fig. 15** Immagini in 3D del progetto di sei impianti e i rapporti con la protesi progettata. È evidente la difficoltà nella scelta di connessioni protesiche che garantiscano l'estetica della porzione vestibolare della nuova arcata avvitata tipo "Toronto bridge". Nell'immagine di sinistra, una preview della dima chirurgica che viene realizzata per l'intervento chirurgico guidato

### L'INTERVENTO CHIRURGICO FLAPLESS GUIDATO

Quando si riceve la dima chirurgica, copia identica della diagnostica, si può passare alla fase chirurgica che prevede la disinfezione a freddo della dima e la preparazione dei riduttori di calibro dei cilindri-guida e delle frese necessarie.

Le frese alesano i siti implantari attraversando prima il cilindro guida dotato del riduttore idoneo al loro diametro e poi la mucosa gengivale prima di eseguire l'osteotomia. (Fig. 16a)

La profondità di lavoro della fresa deve quindi comprendere la lunghezza del cilindro, solitamente di 5 mm, e lo spessore della mucosa misurato precedentemente sulla *cross-section* corrispondente della TC, oltre alla lunghezza dell'impianto.

Apposite frese da 28 mm sono a disposizione per impianti di maggiore lunghezza.

Normalmente la profondità di lavoro viene raggiunta mediante la scala millimetrica contrassegnata sulle frese, ma è anche possibile utilizzare frese dedicate all'implantologia guidata, dotate di stop di profondità applicabili agli steli delle frese. Questo sistema, denominato "Safe System", permette al chirurgo di non doversi occupare della profondità di lavoro durante l'alesatura dell'osso, in quanto lo stop garantisce una fedeltà di perforazione che replica quella

del progetto realizzato sul software.

Solitamente l'intervento si compie in anestesia loco-regionale e non necessita di ribaltamento del lembo muco periostale.

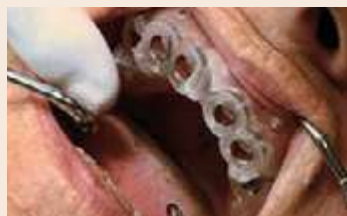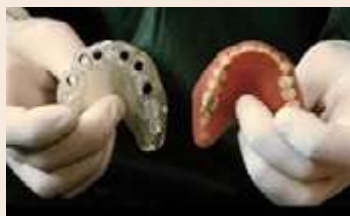Nel caso fosse necessaria una stabilizzazione della dima, come nel caso di arcate mandibolari con carente cresta alveolare residua, la guida chirurgica può essere fissata nel cavo orale mediante "pin" di fissazione alla cresta alveolare.

Questa tecnica impedisce tuttavia di poter rimuovere la dima con facilità durante l'intervento qualora fosse necessario per controllare, ad esempio, i neoalveoli prima di inserire gli impianti.

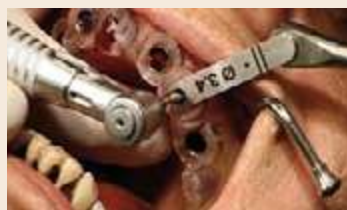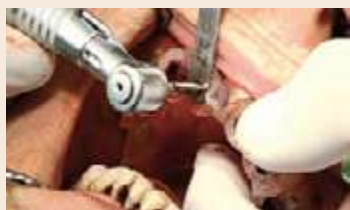L'inserimento delle *fixture* avviene attraverso i cilindri-guida e facilitato da appositi *mounter* con indicatori di profondità che permettono di fermare l'avvitamento una volta che l'impianto abbia raggiunto la cresta ossea, non visibile a cielo coperto. (Fig. 16b)

L'intervento termina con l'avvitamento di viti di guarigione e senza la necessità di suturare. (Fig.17)

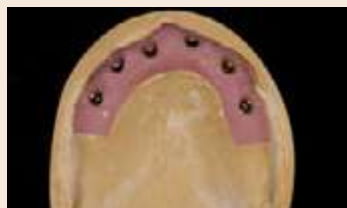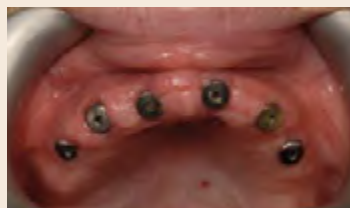Generalmente i postumi dell'intervento sono limitati a un lieve e transitorio dolore comparabile a quello che si presenta dopo una opercolectomia. Rarissimi sanguinamento e edema postoperatorio.



**Fig. 16a** La protesi diagnostica replicata in stereolitografia e fornita di sei cilindri-guida per l'inserimento degli impianti per via trans mucosa. La dima chirurgica garantisce una posizione stabile e precisa grazie alla fedele riproduzione ottenuta con la tecnica della doppia scansione.



**Fig. 16b** La sequenza di fresaggio è assistita da riduttori del diametro dei cilindri guida che evitano lo sbandieramento delle frese. La componentistica fa parte del sistema Universal Surgiguide System di Materialise, mentre le frese sono quelle standard della sistemica Winsix per l'implantologia guidata.



**Fig. 17** le viti di guarigione e il modello master pronti per la costruzione e il montaggio della protesi.

### TORONTO BRIDGE

Oggi in implantoprotesi le strutture denominate "Toronto Bridge" si propongono come valida alternativa alle soluzioni più tradizionali di ricostruzione protesica. L'efficacia e la validità della componentistica protesica attualmente disponibile diventano fondamentali per la corretta costruzione di manufatti da un punto di vista meccanico, funzionale ed estetico.

Agli albori dell'implantologia il motto era *restitutio ad usum* ma non *ad integrum*: attualmente, invece, l'armonia estetica e le proporzioni tra bianco e rosa sono fondamentali per il benessere dei nostri pazienti sotto un profilo non soltanto funzionale, ma anche psicologico.

Le fasi operative di laboratorio nascono da un *mock-up* in cera per una prima verifica oclusale ed estetica, confezionato sul modello master. L'Odontotecnico seleziona poi il materiale da rivestimento, secondo le precise indicazioni dell'Odontoiatra, al fine di ottimizzare i parametri estetici del cavo orale.

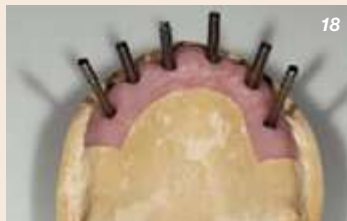
In Laboratorio, con l'ausilio di mascherine in silicone vengono controllati spazi e volumi a disposizione,

per la scelta mirata degli abutment di sostegno. Lo scopo è semplificare le fasi di lavoro al banco per procedere ai successivi e complessi passaggi di costruzione del manufatto.

Nel caso clinico illustrato, una linea protesica appositamente studiata (Winsix EA-Extreme Abutment) per l'avvitamento risolve il problema degli assi degli impianti e delle rispettive viti protesiche di fissaggio che risultavano disparalleli e vestibolarizzati. (Figg. 18, 19)

L'inclinazione sfavorevole per la realizzazione del manufatto porterebbe i fori di avvitamento sulle superfici vestibolari, ma i monconi angolati consentono una soluzione efficace sia per stabilità di avvitamento che per estetica. (Fig. 20)

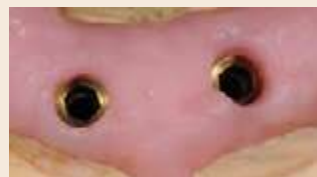Dopo aver preparato con estrema cura dei particolari morfologici e cromatici una gengiva in resina morbida sfilabile, si selezionano tre monconi EA angolati a 20° e altri tre monconi EA angolati a 30°, da avvitare in posizione sul modello nei rispettivi analoghi degli impianti. (Fig.21)



**Figg. 18 e 19** Il modello master conferma l'inclinazione sfavorevole delle viti di fissaggio. Il disparallelismo tra i monconi, previsto nel progetto sul software Simplant, viene compensato con i monconi angolati Extreme Abutment



**Fig. 20** I componenti protesici Winsix scelti per la costruzione del manufatto protesico Teeth Just On Six



**Fig. 21** I monconi angolati a 20° e 30° (Winsix) posizionati e correttamente accoppiati sugli analoghi da laboratorio. Notare l'importanza della gengiva in resina sfilabile per una verifica veloce e affidabile dell'avvitamento dei componenti sugli analoghi e per il controllo dei reali margini gengivali.



Quindi si accoppiano i monconi conici lisci fino ad ottenere un corretto asse di inserzione della struttura di supporto. (Figg. 22, 23)

I monconi conici vengono modificati e sezionati; tramite una modellazione in cera, si ottiene il design della struttura morfologicamente congrua a supportare il rivestimento estetico, che viene ulteriormente verificata con il controllo della mascherina siliconica. (Fig. 24)


La struttura in cera viene fusa in lega Co Cr Mo (Bredent), viene poi fissata sui monconi conici preventivamente sabbiati con biossido di alluminio (250 micron) mediante cemento composito da fissaggio

anaerobico (Nimetic Cem 3M ESPE).

Nell'ultima fase di lavoro si procede all'incollaggio delle faccette in composito (Bredent) con il composito per fissaggio combo lign (Bredent) sulla superficie metallica sabbiata, trattata con silano pen (Bredent) e pennellata con primer adesivo.

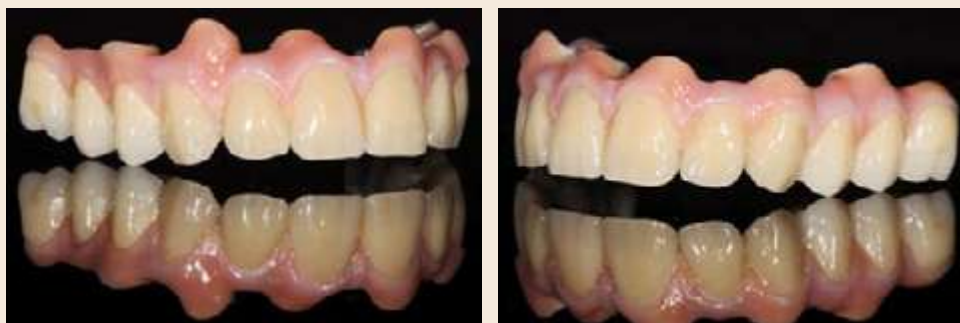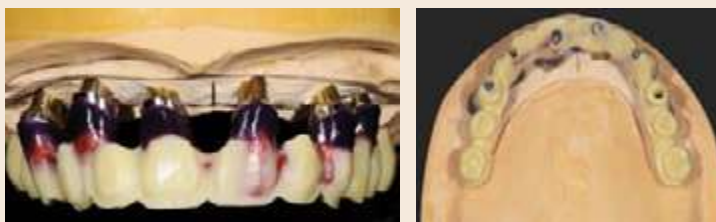
Tutto viene sigillato, rifinito e lucidato nelle zone cervicali e interprossimali degli elementi coronali con masse *dentin* e *incisal crea lign* (Bredent).

La costruzione della gengiva in composito per il ripristino dei tessuti molli viene realizzata con masse *gum crea lign* (Bredent), ideale per valorizzare il risultato finale. (Fig. 25)



**Fig. 22 e 23** I monconi angolati e i monconi ritentivi Extreme Abutment (Winsix), pronti per essere inglobati nella struttura portante con la modellazione in cera

**Fig. 24** Il modellato in cera completato e pronto per la fusione rispetta un design della struttura anatomicamente congruo per alloggiare correttamente le faccette.



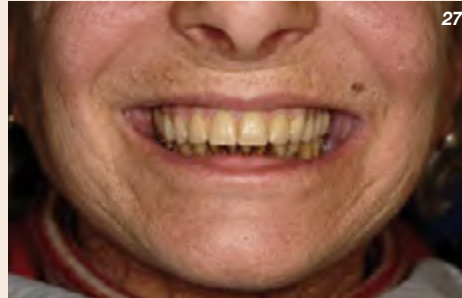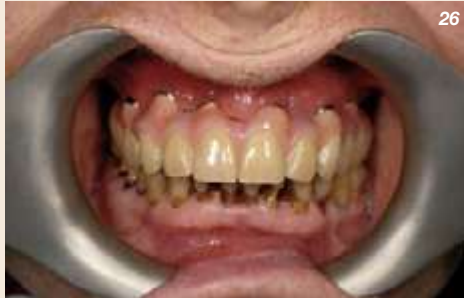**Fig. 25** L'importanza della cura dei dettagli, del colore, della forma e delle proporzioni porta ad un risultato caratterizzato da una grande armonia estetica, anche in implantoprotesi dove alla protesi dentaria spesso si aggiunge la ricostruzione alveolare.



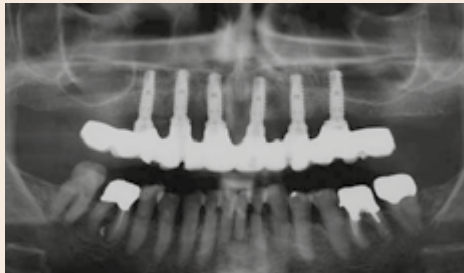Curare anche il minimo dettaglio è fondamentale per garantire il successo finale, arrivando a soddisfare le aspettative della paziente.

Deve essere ricordato come la sinergia fra Odontoiatra e Odontotecnico e, in casi complessi come quello descritto, l'intesa professionale di tutto il team risulta-

no essenziali per il corretto svolgimento delle procedure pianificate. La ricerca di materiali all'avanguardia e di tecniche sempre più precise e affidabili, oltre alla meticolosa applicazione dei protocolli di lavoro permettono di ottenere risultati sempre più predicibili ed esteticamente soddisfacenti. (Figg. 26-28)



**Fig. 26 e 27** La protesi finita avvitata sugli abutment



**Fig. 28** Controllo radiografico a protesizzazione completata

### RINGRAZIAMENTO

Si ringrazia il signor Antonio Lazetera del Laboratorio Odontotecnico Antonio Lazetera di Savona

per la collaborazione tecnica e la realizzazione dei manufatti protesici mostrati nel presente lavoro.

### BIBLIOGRAFIA

- Ganz Scott D., "Use of stereolithographic models as diagnostic and restorative aids for predictable immediate loading of implants", *Practical Procedures & Aesthetic Dentistry (Pract Proced Aesthet Dent, PPAD)*, Volume 15, 10, pp. 763-772, 2003
- Jacobs R., "Preoperative radiologic planning of implant surgery in compromised patients.", *Periodontology 2000 (Periodontol 2000)*, Volume 33, pp. 12-25, 2003
- Sarment David P., Al-Shammari K., Kazor Christopher E., "Stereolithographic surgical templates for placement of dental implants in complex cases", *The International Journal of Periodontics & Restorative Dentistry (Int J Periodontics Restorative Dent)*, Volume 23, 3, pp. 287-295, 2003
- Sammartino G., Della Valle A., Marenzi G., Gerbino S., Martorelli M., Esposito di Lauro A., di Lauro F., "Stereolithography in Oral Implantology: A Comparison of Surgical Guides", *Implant Dentistry (Implant Dent)*, Volume 13, 2, pp. 133-136, 2004
- Valente Francesco, "L'utilizzo di SimPlant e SurgiGuides per una corretta osteotomia implantare in chirurgia flapless", *Il Dentista Moderno (DM)*, Volume 4 (aprile), pp. 101-109, 2005
- Valente F., Buoni C., Scartò B., Mascolo A., Parducci F., "Precisione delle guide stereolitografiche CAD-CAM ad appoggio mucoso nel posizionamento degli impianti senza sollevamento del lembo", *European Journal of Implant Prosthodontics (Europ J Impl Prost)*, Volume 1, 2, pp. 15-25, 2006
- Tardieu Philippe, "Computer-guided implantology in aesthetic cases", *Clinical Oral Implants Research (Clin Oral Implant Res)*, Volume 19, 9, pp. 839, 2008
- L.G. Farkas, I.R. Munro: *Anthropometric Facial proportion in medicine*; C.C. Thomas Pub.England. 1986
- D. N. Sutton e al.: *Anthropometric study in oral bone atrophy*. *International Journal of Oral and Maxillofacial Surgery*, Vol 33, Issue 7: 676-682, Oct 2004
- G. Perotti, L. De Vecchi, T. Weinstein. A. Motroni, T. Testori, M. Del Fabbro: *La telerradiografia latero-laterale in implantologia e riabilitazione orale: dall'analisi bidimensionale alla diagnostica 3D*. *Dental Cadmos* Giugno 2010, (78-88)
- Sorrentino R, Gherlone EF, Calesini G, Zarone F. Effect of implant angulation, connection length, and impression material on the dimensional accuracy of implant impressions: an in vitro comparative study. *Clin Implant Dent Relat Res*. 2010 May;12 Suppl 1:e63-76. Epub 2009 May 8
- Arnett G;W.; Mc Laughlin R.P. *Facial and Dental Planning for Orthodontists and for Oral Surgeons*. St Louis (Mo): Mosby, Elsevier 2004
- Downs W B *Analysis of the dentofacial profile*. *Angle Orthodontist* 26:191-212, 1956
- Park Y C, Burstone C J *Soft tissue profile – fallacies of hard tissue standards in treatment planning*. *American Journal of Orthodontic and Dentofacial Orthopedics* 90:52-62, 1986
- Crespi R, Capparè P, Gherlone E. Radiographic evaluation of marginal bone levels around platform-switched and non-platform-switched implants used in an immediate loading protocol. *Int J Oral Maxillofac Implants*. Sep-Oct;24(5):920-6, 2009

Vinci R., Pasi M., Tetè S.\*, Gherlone E. F.

Lavori scientifici

## TECNICHE CHIRURGICHE PIEZOELETRICHE in implantologia

Dip. di Odontoiatria (Dir. Prof. EF Gherlone),  
Ateneo Vita-Salute San Raffaele, Milano

\* Cattedra di Ch. Speciale Odontostomatologica,  
Università G. D'Annunzio, Chieti

**G**li ultrasuoni sono utilizzati da decenni in medicina, sia in campo diagnostico sia in campo terapeutico. L'esempio paradigmatico di tale impiego è rappresentato dall'ecografia che, basandosi sul principio dell'emissione di eco e della trasmissione delle onde sonore, viene oggi utilizzata routinariamente in ambito radiologico, internistico e chirurgico. Con modalità curative essi sono impiegati per la litotripsia sia in urologia che in otorinolaringoiatria ed inoltre in neurochirurgia, ortopedia, dermatologia ed oculistica.

Già nel 1975 Horton pubblicava uno studio per valutare la guarigione di difetti ossei prodotti con strumenti ultrasonici e negli anni successivi, sono apparse altre sporadiche pubblicazioni su questo argomento. Il vero fiorire del numero degli articoli si registra nell'ultimo decennio, successivamente alle prime pubblicazioni di Vercellotti, dal 2000 in poi, nelle quali è stato introdotto a tutti gli effetti uno strumentario chirurgico dedicato alla chirur-

gia piezoelettrica. Con questa tecnologia gli ultrasuoni vengono generati applicando una differenza di potenziale che attraversa particolari cristalli che presentano la proprietà fisica di espandersi e contrarsi se attraversati da una corrente elettrica (effetto piezoelettrico inverso).

La frequenza di vibrazione utilizzata è di 25-29 kHz perché le vibrazioni prodotte, 60-210 micrometri, mostrano efficacia di taglio soltanto con i tessuti mineralizzati; per tagliare anche i tessuti molli le frequenze di lavoro devono superare i 50 kHz. Le caratteristiche del taglio piezoelettrico possono essere così sintetizzate. Le microvibrazioni sviluppate dall'apparecchio piezoelettrico si trovano in un intervallo compreso tra 27.000 e 29.500 Hz; l'ampiezza della vibrazione, sia sul piano orizzontale (60/200  $\mu\text{m}$ ) sia sul piano verticale (20/60  $\mu\text{m}$ ), varia in rapporto alla forma e al tipo di inserto. Grazie alla presenza della soluzione fisiologica necessaria per il raffreddamento, si produce il fenomeno fisico della cavitazione,

253

caratterizzato dalla formazione di bolle di vapore a bassissima pressione che, implodendo, hanno un'azione meccanica di pulizia e rendono il campo operatorio esangue. L'alternarsi di vibrazione con lunghezze d'onda diverse permette di mantenere gli inserti utilizzati costantemente puliti dai detriti ossei, garantendo una costante efficacia di taglio (hammering action). Le peculiarità appena descritte hanno importanti risvolti clinici. Il taglio è selettivo, preciso e sicuro perché limitato ai tessuti duri: è oggi possibile operare con maggiore sicurezza aree anatomiche ad alto rischio di lesioni iatrogene potenzialmente gravi/fatali, come il sistema nervoso centrale, le aree limitrofe al fascio carotideo, etc... Il taglio è micrometrico, quindi ben controllabile ed il sito è esangue grazie all'effetto cavitazione. Gli studi istomorfometrici eseguiti suggeriscono come la qualità dell'osteotomia piezoelettrica sia migliore se comparata a quella eseguita con strumenti rotanti, in termini sia di precisione sia di rispetto delle strutture ossee. Sezioni istologiche di biopsie eseguite successivamente a procedure chirurgiche effettuate con il terminale piezoelettrico testimoniano una maggiore crescita ossea rispetto a quella riscontrata in seguito all'utilizzo di frese rotanti. Questo è probabilmente dovuto alla presenza di una minor percentuale di necrosi evidenziabile sulla linea osteotomica. Allo stesso modo la biologia molecolare evidenzia, nel confronto fra tecniche piezoelettriche e tecniche tradizionali, un maggior rispetto dell'osso prelevato con le prime rispetto alle seconde. Si osserva una miglior risposta ossea anche in termini di rigenerazione, come emerso in studi che hanno valutato i livelli di riassorbimento e rigenerazione ossea dopo chirurgia resettiva effettuata con entrambe le metodiche. Allo stesso modo le sedi donatrici di prelievi ossei sembrano andare incontro ad una migliore guarigione. Traducendo quanto affermato in termini numerici, il margine di necrosi del taglio piezoelettrico ha uno spessore di 1,57  $\mu\text{m}$ , contro 2,23  $\mu\text{m}$  delle frese convenzionali. Nella preparazione dei siti implantari è stata valutata la concentrazione di proteine morfogenetiche (BMP-4), fattore di crescita trasformante (TGF- $\beta$  2), fattore di necrosi tumorale alfa e delle interleuchine- $1\beta$  e -10 intorno ai campioni di osso perimplantari. L'analisi ha mostrato una neo osteogenesi decisamente più attiva nei campioni preparati con la chirurgia piezoelettrica, una più rapida espressione di BMP-4 e TGF- $\beta$  2 ed una minore espressione di citochine pro infiammatorie.

In conclusione i risultati ottenuti sembrano indicare di aver raggiunto un'ottimizzazione di impiego degli ultrasuoni nella chirurgia dei tessuti duri;

l'eventuale ulteriore implementazione potrà essere forse ottenuta attraverso l'impiego in associazione di gas medicali e/o onde luminose.

I campi di applicazione nella chirurgia odontostomatologica e maxillo-facciale sono vari.

#### **Parodontologia.**

In chirurgia parodontale resettiva gli inserti permettono di operare con relativa facilità anche in spazi ridotti o di difficile accesso come i settori posteriori o gli spazi interdentali consentendo l'asportazione di tessuto osseo o di struttura dentale mineralizzata. Rispetto all'uso di strumenti rotanti la chirurgia piezoelettrica riduce il rischio di lacerare i tessuti molli, è più delicata nei confronti del tessuto osseo ed, inoltre, grazie all'effetto cavitazionale garantisce un campo operatorio molto deterso e quindi migliore visibilità.

#### **Chirurgia endodontica.**

Con specifici inserti dedicati è possibile sezionare gli apici radicolari con un taglio netto e preciso, per poi penetrare nel canale radicolare per via retrograda per alcuni millimetri rispettandone l'anatomia (procedura non praticabile con strumenti rotanti). Si ottiene una cavità a quattro pareti favorevole al contenimento ed alla compattazione dei materiali come l'MTA che, a fronte di eccellenti potenzialità riparative, è poco maneggevole. Mediante l'azione ultrasonica è possibile rimuovere materiale endodontico, nonché tentare la rimozione di strumenti fratturati.

#### **Germectomie ed avulsione di elementi dentari disodontiasici.**

L'estrazione di germi ed elementi dentari in parziale o totale inclusione ossea solitamente è eseguita in pazienti molto giovani, spesso ansiosi e non sempre collaboranti. Il manipolo piezoelettrico, per le caratteristiche di rispetto dei tessuti molli vicini, può essere impiegato in sicurezza anche quando l'angolo di visuale non è ottimale. Le caratteristiche proprie della chirurgia piezoelettrica (sito esangue e ben deterso) consentono di individuare ed asportare i tessuti dentari che non vengono mai confusi con le pareti ossee. Qualora sia concomitante la presenza di una cisti follicolare o comunque nelle enucleazioni di lesioni osteolitiche benigne è possibile rimuovere, conservandola, la parete ossea di accesso senza lederne la parete cistica; talora è possibile riposizionare l'opercolo osseo con il duplice vantaggio di offrire sostegno ai tessuti molli sovrastanti e nel contempo ridurre e delimitare la cavità ossea offrendo stabilità al coagulo osseo e garantendo quindi una pronta riparazione ossea.

**Estrazione di denti anchilosati.**

Il terminale piezoelettrico può utilizzare inserti appositamente progettati, simili a sindesmomi, che lavorano all'interfaccia dente-alveolo riducendo al minimo la quantità di osso asportato. Questa tipologia di estrazioni, specie per la vicinanza di altri elementi dentari, è una procedura particolarmente indaginosa: molto spesso il trauma estrattivo può condizionare in maniera determinante l'inserimento di un successivo impianto, a causa dei danni causati dagli strumenti rotanti o dalle leve.

**Chirurgia preimplantare e implantare.**

La tecnica dello split crest permette di espandere creste alveolari il cui diametro trasverso sia insufficiente ad accogliere correttamente impianti osteointegrati; i vantaggi dell'utilizzo di questa tecnologia risiedono nel fatto che il taglio osteotomico sia altamente ergonomico avendo uno spessore inferiore al millimetro e possa essere adeguatamente eseguito: con le frese questa possibilità è inferiore non tralasciando che l'esecuzione con scalpello e martello provochi grande discomfort per il paziente. Non da ultimo è da enfatizzare che le temperature di lavoro del terminale ultrasonico non superino mai i 31° centigradi garantendo una preservazione della integrità cellulare che equivale a processi riparativi migliori e più rapidi.

È possibile affermare che la chirurgia piezoelettrica si sia diffusa grazie alla sua applicazione nelle tecniche di sinus lift; l'elevazione della membrana sinusale attraverso l'apertura di un accesso osseo laterale con manipolo ultrasonico riduce sensibilmente la possibilità di perforazioni della membrana schneideriana. Con terminali introdotti recentemente è possibile scollare la membrana sinusale anche per via transcrestale mediante l'utilizzo di un getto d'acqua di potenza controllata: in questo modo si ottiene uno scollamento e contemporaneo sollevamento di un'area piuttosto ampia, e non solo limitata al diametro dell'impianto come invece avviene con la classica tecnica di Summer.

In chirurgia rigenerativa l'impiego di osso autologo, particolato o in blocchi, è ancora ad oggi da considerarsi come gold standard soprattutto nei difetti estesi delle creste alveolari.

Mediante l'utilizzo di specifici terminali è possibile collezionare anche grandi quantità di particolato osseo utile sia nelle tecniche rigenerative che prevedono l'impiego di mem-

brane che in associazione a blocchi ossei a zeppaggio degli spazi residui.

Il disegno dei tagli osteotomici al fine di eseguire un prelievo di blocco osseo dal corpo o dalla branca montante mandibolare utilizzando un terminale ultrasonico consente:

- ottima visibilità operatoria essendo il sito esangue e costantemente deterso
- sicurezza legata al rispetto delle strutture anatomiche viciniore
- in relazione all'estrema sicurezza ed al minor ingombro del terminale ultrasonico è possibile effettuare un minor scollamento dei tessuti molli circostanti a tutto vantaggio del sanguinamento, dolore ed edema post-operatorio
- corretta esecuzione delle osteotomie anche in sedi meno favorevoli come l'osteotomia basale laterale eseguibile con terminali a doppia angolazione e sagomati ad hoc per il lato destro e sinistro
- preservazione della integrità cellulare attraverso basse temperature di esercizio.

Nell'ambito della chirurgia maxillofaciale può essere utilizzato per eseguire osteotomie segmentarie per facilitare movimenti ortodontici o espansioni rapide palatali: la vitalità degli elementi dentari viene mantenuta ed analisi microscopiche non hanno mostrato segni di necrosi coagulativa; parimenti, per correggere alterazioni di sviluppo, è possibile mobilizzare il mascellare superiore con osteotomie tipo Le Fort I utilizzando strumenti ultrasonici.

Durante la separazione della sindesmomi dei processi pterigoidei si riducono i rischi di lesione di strutture anatomiche rilevanti, quali l'arteria palatina maggiore mentre l'interruzione delle pareti del mascellare può essere eseguita con totale risparmio osseo e volendo con la conservazione della membrana sinusale che può essere contestualmente elevata per rigenerazioni ossee verticali.

Sempre nell'ambito della chirurgia ortopedica dei mascellari anche le diverse osteotomie mandibolari possono essere eseguite con manipolo ultrasonico riducendo sensibilmente la possibilità di insulto dei tessuti molli adiacenti e garantendo nel contempo l'esecuzione di linee osteotomiche ben definite, con ampio risparmio di tessuto osseo e con un'ottima visione del campo operatorio ben deterso.

Attraverso le medesime prerogative, il manipolo piezoelettrico è altresì utilizzabile nell'esecuzione di osteotomie per asportazione di lesioni benigne dei mascellari.

### CASO CLINICO N. 1: Split crest con terminale piezoelettrico

In implantoprotesi è fondamentale il concetto di posizionamento implantare protesicamente guidato al fine di inserire delle fixture di forma e dimensioni adeguate ai denti da sostituire ottenendo validi profili di emergenza, nella giusta posizione mesio-distale e vestibolo-linguale, in modo che le forze masticatorie possano essere scaricate lungo l'asse dell'impianto.

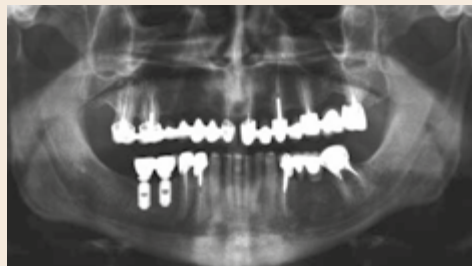
Una delle limitazioni anatomiche più frequenti è il riassorbimento osseo orizzontale che si verifica in modo esuberante dopo i primi tre mesi ed entro due anni dall'estrazione di un dente.

In effetti in alcuni casi, anche se apparentemente la quota ossea in senso vestibolo-palatale sembrerebbe permetterci l'inserzione della fixture senza dover effettuare alcuna manovra rigenerativa, tale riassorbi-

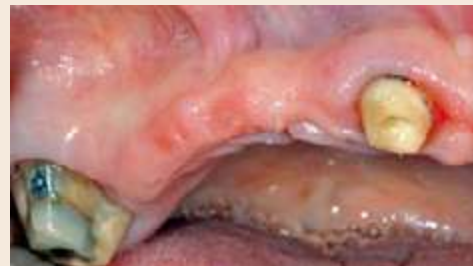mento orizzontale sposta il centro della cresta ossea rispettivamente in posizione più palatale o linguale a seconda che l'edentulia sia a carico del mascellare superiore o mandibolare.

Una delle tecniche ricostruttive più predicibili per aumentare la quota ossea vestibolare è l'osteotomia sagittale della cresta. Tale tecnica in mani esperte ha un'altissima percentuale di successo e mostra la minor contrazione volumetrica a lungo termine poiché viene lasciato in situ il piatto osseo vestibolare con una irradiazione sia endostale che periostale che ne limita notevolmente il riassorbimento secondario.

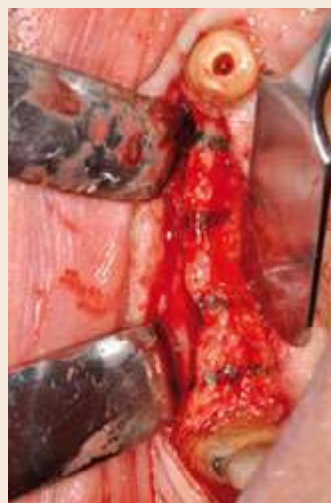Nel caso in esame il paziente necessitava dell'inserimento di impianti endosseici nel 1° quadrante; i denti erano stati estratti due anni prima per motivi parodontali.



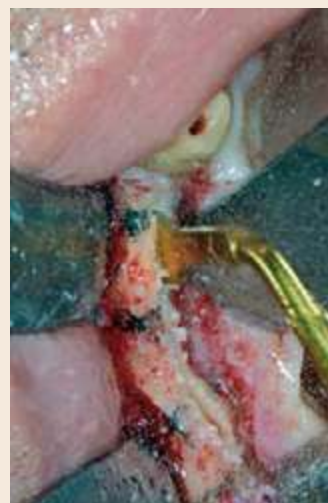**Fig. 1** OPT iniziale del caso. Il paziente presenta numerosi restauri incongrui. A livello del primo quadrante la protesizzazione parziale fissa è ancorata sugli elementi 1.1, 1.6 e 1.7.



**Fig. 2** Visione iniziale intraorale. Viene rimossa la protesizzazione fissa su dentatura naturale. L'area edentula presenta un marcato riassorbimento orizzontale e rapporti verticali mantenuti.

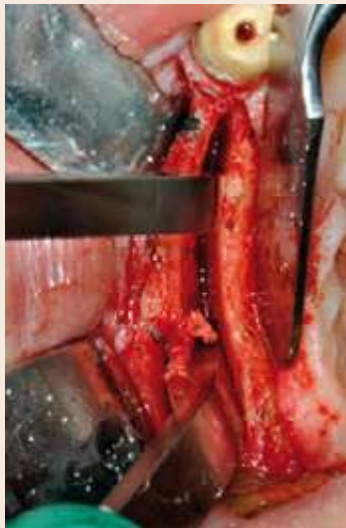

**Fig. 3** Lembo a spessore totale senza incisioni di scarico verticali. Lo scollamento prosegue solo per alcuni millimetri in direzione vestibolare. Viene marcato il centro dei futuri elementi protesici secondo ceratura diagnostica.

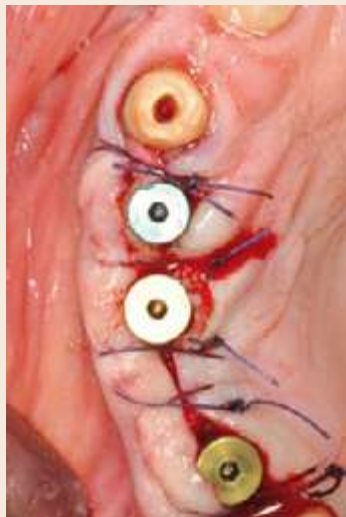

**Fig. 4** Azione dell'insero osteotomico piezoelettrico (Silfradent®). L'irrigazione continua e l'effetto cavitazionale mantengono l'area di lavoro esangue. Il taglio viene esteso in direzione apicale per circa 10 mm.



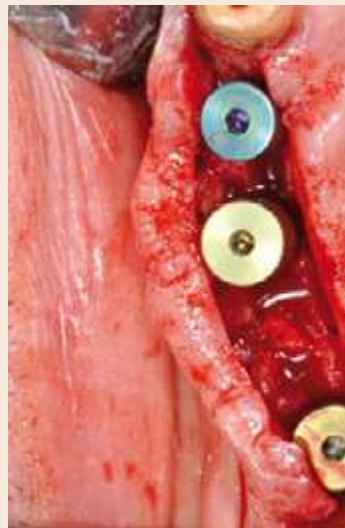


**Fig. 5** Inserimento degli scalpelli per espandere il diametro della cresta. Questa fase va eseguita lentamente, distribuendo il carico uniformemente lungo la linea di taglio.

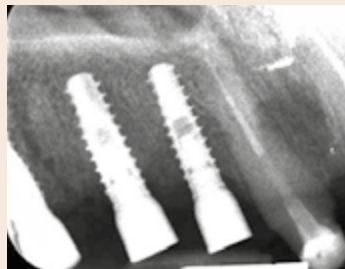


**Fig. 7** Sutura completata. È apprezzabile l'entità di espansione ottenuta, fino al ripristino di un profilo alveolare armonico.

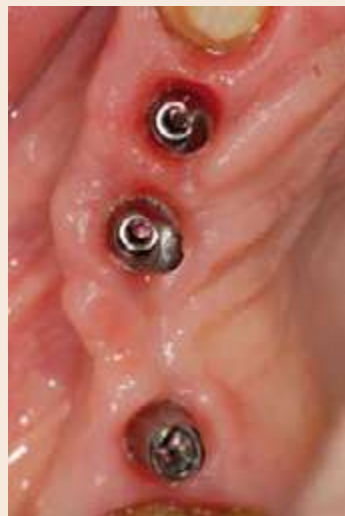**Fig. 6** Inserzione di 3 impianti di diametro 3,3 mm su 1.2, 3,8 mm su 1.3 e 3,8 mm su 1.5 (Winsix® K) e viti di guarigione.



**Fig. 8** Radiografia di controllo.

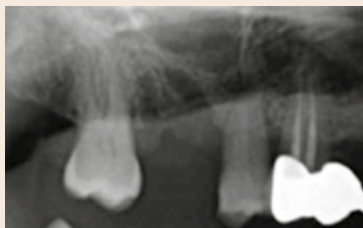

**Fig. 9** Visione occlusale dei tessuti condizionati: la quota di mucosa cheratinizzata è ottimale per una corretta integrazione estetica del restauro.

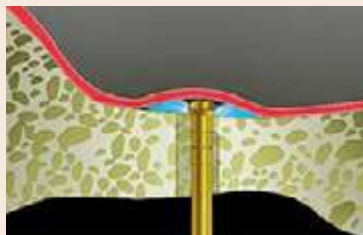


### CASO CLINICO N. 2: Elevazione transcrestale della membrana sinusale e contestuale posizionamento di un impianto

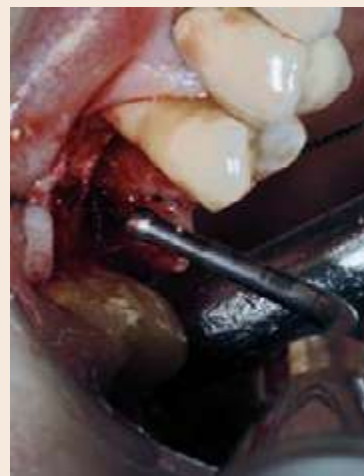Il paziente presentato necessitava dell'inserimento di un impianto endosseale in sede 1.6 precedentemente estratto per motivi parodontali.



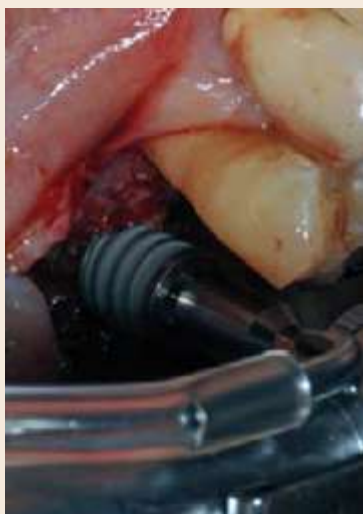
**Fig. 10** Radiografia pre operatoria dell'area edentula.



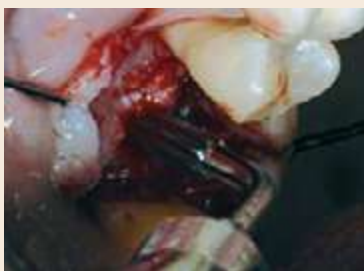**Fig. 12** Schema della modalità d'azione dell'inserto: l'irrigazione fuoriesce da aperture laterali.



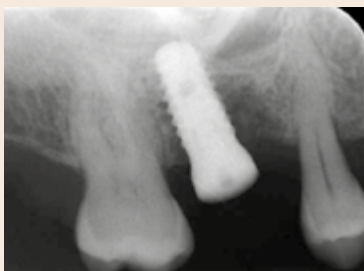**Fig. 11** L'inserto progettato per l'elevazione della membrana transcrestale (Silfradent®) viene inserito nel primo foro osteotomico. La punta arrotondata riduce la possibilità di perforazioni.



**Fig. 14** Inserimento dell'impianto (Winsix® K).



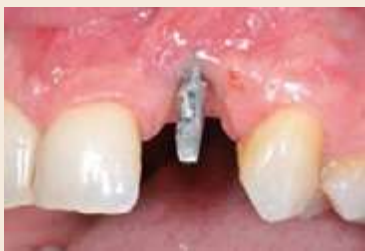**Fig. 13** L'osteotomia implantare viene allargata con inserto dedicato (Silfradent®).



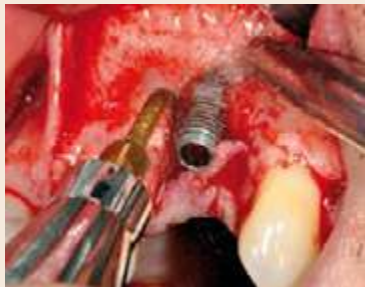**Fig. 15** Radiografia postoperatoria con impianto inserito.

**CASO CLINICO N. 3:  
Elevazione transcrestale della membrana sinusale  
e contestuale posizionamento di un impianto**

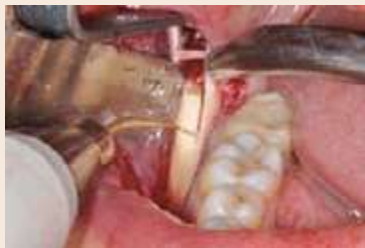Nel caso in esame viene inviato in esame un paziente maschio di 37 anni per rimuovere un impianto osteointegrato inserito cinque anni prima in sede 22.



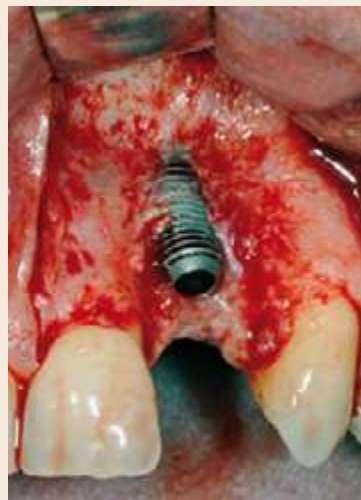**Fig. 16** Visione iniziale intraorale: l'impianto in posizione 2.2 è stato inserito con un errato asse in senso apico-coronale, causando disarmonia delle paraboliche gengivali.



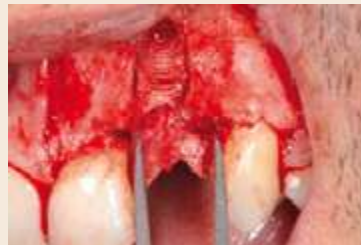**Fig. 18** Impianto rimosso con tecnica piezoelettrica. La quantità di osso nativo asportata è minima.



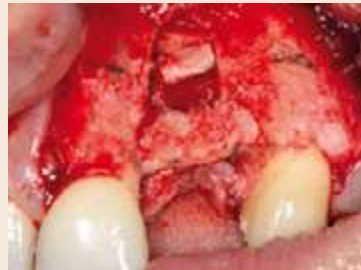**Fig. 20** Prelievo di osso autologo a livello della branca montante della mandibola. Anche per questa procedura gli inserti piezoelettrici offrono indubbi vantaggi rispetto agli strumenti rotanti.



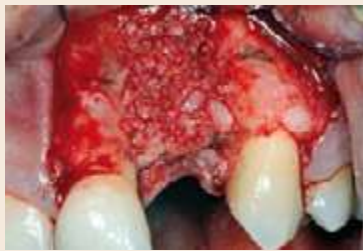**Fig. 17** Dopo aver elevato un lembo trapezoidale a spessore totale si apprezza una completa deiscenza della superficie implantare vestibolare.



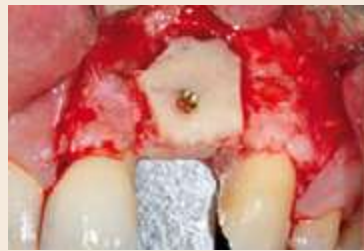**Fig. 19** Il difetto residuo viene misurato nelle tre dimensioni dello spazio prima di effettuare il prelievo.



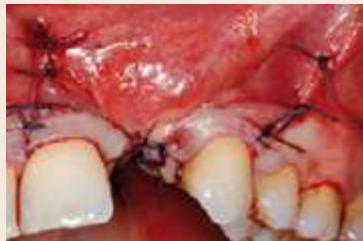**Fig. 21** Il difetto viene ricostruito tridimensionalmente con più blocchi iniziando dalla parete palatale (indispensabile è ricercare una stabilità primaria dell'innesto).



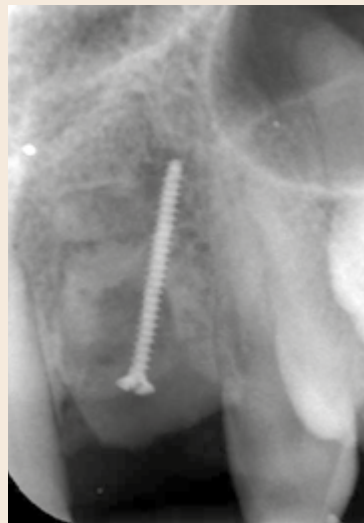
**Fig. 22** Negli spazi residui si compattano frammenti di piccole dimensioni e osso particolato recuperato durante il prelievo.



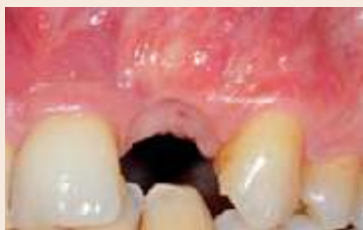**Fig. 23** La ricostruzione è ultimata con il posizionamento di un blocco osseo a ricostruzione della parete vestibolare stabilizzato con tecnica lag-screw.



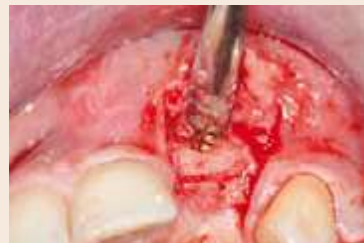**Fig. 24** Chiusura del lembo mucosa a totale copertura dell' area rigenerata ed in assenza di trazioni.



**Fig. 25** Radiografia di controllo con vite da osteosintesi.

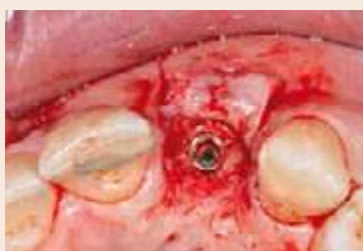

**Fig. 26** Guarigione dei tessuti molli a 3 mesi di distanza.

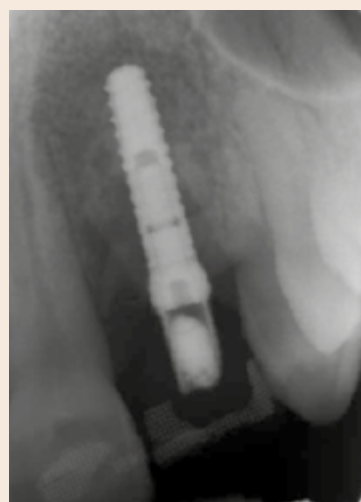


**Fig. 27** Viene allestito un lembo di dimensioni ridotte per non interrompere la neovascolarizzazione periostale.





**Fig. 28** *Visione occlusale dell'impianto inserito (Winsix® K): vestibolarmente sono presenti circa 3,5 mm di osso che riducono la possibilità di riassorbimenti e recessioni*



**Fig. 29** *Radiografia di controllo dell'impianto in posizione*

#### BIBLIOGRAFIA

- Horton JE, Tarpley TM, Wood LD. The healing of surgical defects in alveolar bone produced with ultrasonic instrumentation, chisel, and rotary bur: Oral Surg Oral Med Oral Patol 1975;39:536-46
- Horton JE, Tarpley TM, Jacoway JR. Clinical applications of ultrasonic instrumentation in the surgical removal of bone: Oral Surg Oral Med Oral Patol 1981;51:236-42
- Torrella F, Pitarch J, Cabanes G, Anita E. Ultrasonic osteotomy for the surgical approach of the maxillary sinus: a technical note. Int J oral Maxillofac Implants 1998; 13:697-700
- Sherman JA, Davies HT. Ultracision®: the harmonic scalpel and its possible uses in maxillofacial surgery. Br J Oral Maxillofac Surg 2000;38:530-2
- Vercellotti T. Piezoelectric surgery in implantology: a case report. A new piezoelectric ridge expansion technique. Int J Periodontics Restorative Dent 2000; 20 (4): 359 – 365
- Vercellotti T, De Paoli S., Nevins M. The Piezoelectric bony window osteotomy and sinus membrane elevation: introduction of a new technique for simplification of the sinus augmentation procedure. Int J Periodontics Restorative Dent 2001; 21 (6): 561 – 7
- Eggers G, Klein J, Blank J, Hasffeld S. Piezosurgery: an ultrasound device for cutting bone and its use and limitations in maxillofacial surgery. Br J Oral Maxillofac Surg 2004;42: 451-453
- Stubinger S., Kutenberger J., Filippi A., Sader R., Zellhofer H. F. Intraoral piezosurgery: preliminary results of a new technique. J Oral Maxillofac Surg 2005; 63 (9): 1283 – 7
- Schlee M., Steigmann M., Bratu E., Garg A. K. Piezosurgery: basics and possibilities. Implant Dent 2006; 15 (4): 334 – 40
- Kotrikova B., Wirtz R., Krempien R., Blank J., Eggers G., Samiotis A., Muehling J. Piezosurgery: a new safe technique in cranial osteoplasty? Int J Oral Maxillofac Surg 2006; 35 (5): 461 – 5
- Sohn D. S., Ahn M. R., Lee W. H., Yeo D. S., Lim S. Y. Piezoelectric osteotomy for intraoral harvesting of bone blocks. Int J Periodontics Restorative Dent 2007; 27 (2): 127 – 31
- Chiriac G., Herten M., Schwarz F., Rothamel D., Becker J. Autogenous bone chips: influence of a new piezoelectric device (Piezosurgery) on chip morphology, cell viability and differentiation. J Clin Periodontol 2005; 32 (9): 994–9
- Vercellotti T., Nevins M. L., Kim D. M., Nevins M., Wada K., Schenk R. K., Fiorellini J. P. Osseous response following resective therapy with piezosurgery. Int J Periodontics Restorative Dent 2005; 25 (6): 543 – 9
- Wallace S. S., Mazor Z., Forum S. J., Cho S. C., Tarnow D. P. Schneiderian membrane perforation rate during sinus elevation using piezosurgery: clinical results of 100 consecutive cases. Int J Periodontics Restorative Dent 2007; 27 (5): 413 – 9
- Vinci R. Bone grafts from calvaria: diagnosis, instrumentation, harvesting techniques and surgical procedures. In " Bone augmentation in oral implantology" di F. Khoury, H. Antoun, P. Missika . Quintessence Pub. 2007; Chapter 7: 213 – 240
- Preti G., Martinasso G., Peirone B., Navone R., Manzella C., Muzio G., Russo C., Canuto R. A., Schierano G. Cytokines and growth factors involved in the osseointegration of oral titanium implants positioned using piezoelectric bone surgery versus a drill technique: a pilot study in minipigs. J Periodontol 2007; 78 (4): 716 – 722
- Vercellotti T., Podestà A. Orthodontic microsurgery: a new surgically guided technique for dental movement. Int J Periodontics Restorative Dent 2007; 27: 325 – 331
- Barone A., Santini S., Marconcini S., Giacomelli L., Gherlone E., Covani U. Osteotomy and membrane elevation during the maxillary sinus augmentation procedure. A comparative study: piezoelectric device vs. conventional rotative instruments. Clin Oral Implants Res 2008; 19 (5): 511 – 5
- Labanca M, Azzola F, Vinci R, Rodella LF. Piezoelectric surgery: twenty years of use. Br J Oral Maxillofac Surg. 2008 Jun;46(4):265-9.
- Pasi M, Vinci R, Di Stefano D, Gherlone EF. La chirurgia Orale Piezoelettrica. It. Oral Surg. 2008;5:7-18
- Murphy KG, Wilcko MT, Wilcko WM, Ferguson DJ. Periodontal accelerated osteogenic orthodontics: a description of the surgical technique J Oral Maxillofac Surg. 2009 Oct;67(10):2160-6
- Tetè S, Vinci R, Zizzari V, Cingano L, Bollero R, D'Apolito G, Benzo L, L, Dolci A, Mortellaro C, Gherlone E. Evaluation of effects on bone tissue of different osteotomy techniques J Craniofac Surg. 2009 Sep;20(5):1424-9
- Bertossi D, Vercellotti T, Podesta A, Nocini PF. Orthodontic microsurgery for rapid dental repositioning in dental malpositions. J Oral Maxillofac Surg. 2010 Oct 8





**1 Influence of Novel Nano-Titanium Implant Surface on Human Osteoblast Behavior and growth**

S. Tetè, Filiberto Mastrangelo, Raimondo Quaresima, Raffaele Vinci, Gilberto Sammartino, Liborio Stuppia, E. F. Gherlone  
IMPLANT DENTISTRY / VOLUME 19, NUMBER 6 2010

---

**2 Osteosynthesis plates, screws, xenogenic graft and resorbable barriers for preimplant and peri- implant surgery**

G. M. Rauso, N. Nesi, L. Fragola, M. Santagata, V. Santillo, R. Rauso  
Minerva Stomatologica - 2010, 59:00-00

---

**3 Utilizzo del Mucotomo per il rialzo del seno mascellare con approccio crestale: Report preliminare  
Use of the circular soft-tissue punch in maxillary sinus lifts with a crestal approach: a preliminary report**

F. Vannini, M. Nardone  
Italian Oral Surgery 2010; 9 (6):1-14

---

**4 Chiave dinamometrica digitale: applicazioni in Implanto-protesi**

L. Prosper, M. Cappello, C. A. Cortella, T. D'Alicandro, E. F. Gherlone  
OI Quintessenza Internazionale anno 26 numero 1 Gennaio/Marzo 2010)

---

**5 Lembo di bolla di Bichat associato al lembo di Rehrmann nella correzione plastica di ampia fistola oro antrale in paziente trattata con bifosfonati:  
Case Report**

M. Del Brutto, G. Alfieri, G. Mariani, C. Vianale, R. Mazzanti, G. Sammartino  
Sessione Poster- Roma 18-19-20 Febbraio 2010

---

**6 Difetti di spessore crestali: Utilizzo della tecnica Split Crest**

B. Marcelli, A. Delli Carpini, E. Coccia, M. Procaccini  
Sessione Poster-Roma 18-19-20 Febbraio 2010

---

**7 CASE REPORT: Analisi retrospettiva a quattro anni degli esiti di trattamento implanto-protetico eseguiti con sistematica Winsix**

S. Zandonella Necca, F. Bova, E. F. Gherlone  
Università Vita-Salute San Raffaele (MI) Facoltà di Medicina e Chirurgia Corso di Laurea in Igiene Dentale Presidente:  
Prof. E. F. Gherlone  
I.R.C.C.S. San Raffaele (MI) Unità Operativa di Odontoiatria Direttore: Prof. E. F. Gherlone



## Influence of Novel Nano-Titanium Implant Surface on Human Osteoblast Behavior and Growth

AQ:1-2

AQ:3 Stefano Tetè, MD, DDS,\* Filiberto Mastrangelo, MD, DDS, PhD,† Raimondo Quaresima,‡ Raffaele Vinci, MD,§ Gilberto Sammartino, MD, DDS,|| Liborio Stuppia, MD,¶ and Enrico Gherlone, MD#

AQ:4

Long-term integration of endosseous implants in bone tissue is guaranteed by an intimate contact between the titanium surface and the host structure.<sup>1,2</sup> Recent *in vitro* and *in vivo* studies<sup>3-6</sup> have shown that physical and chemical characteristics, derived from surface coating treatment, have a central role during initial phases of bone to implant integration, conditioning the quality and quantity of cellular response and the time of healing processes.<sup>7,8</sup> In fact, during initial phases of machined and macroroughness coating endosseous integration, new bone formation was observed around the fixture only on host bone (distance growth osteogenesis), whereas during microroughness implant integration, it is possible to note a significant enhancement of new bone apposition on the host bone and on the titanium surface (contact growth osteogenesis), increasing stability and reduc-

**Purpose:** The aim of the study is to investigate human osteoblast-like cell behavior and growth in the presence of 3 different titanium implant surfaces.

**Materials:** Human stem cells were first obtained and then sorted by fluorescence-activated cell sorter from mesenchymal stem cell clusters of human dental papilla. The obtained human dental papilla stem cells were induced to differentiate into osteoblast-like cells and were then analyzed by reverse transcriptase polymerase chain reaction and Western blot analyses. The cells proliferated and were cultured onto 3 different titanium discs (sandblasted, sandblasted and large-grit acid-etched, and full contact coverage [FCC]) and analyzed by scanning electron microscope.

**Results:** In all analyses samples, a high cell activity was observed, with typical osteoblast mature morphostructural response on rough surface. The high number of osteoblast-like cells was found on titanium FCC discs. At the same time, scanning electron microscope analysis confirmed the high biocompatibility of this surface.

**Conclusion:** The rapid maturation of the osteoblast-like cells on FCC titanium surface suggests that this structure could play a central role during initial phases of bone healing processes. (Implant Dent 2010;19:1-000)

**Key Words:** human dental papilla stem cells, osteogenic differentiation, titanium surface, full contact coverage surface

\*Associate Professor of Oral Surgery, Department of Oral Science, University "G. d'Annunzio," Chieti, Italy.  
†Post Doctoral Fellow, Young Researcher, Department of Oral Science, University "G. d'Annunzio," Chieti, Italy.  
‡Associated Professor, Department of Biomaterials, University of Aquila, Italy.  
§Head of Advanced Oral Surgery Unit, Department of Oral Science, University "S. Raffaele," Ateneo Vita e Salute, Milan, Italy.  
¶Professor of Oral and Maxillofacial Surgery, Head of Department of Oral Surgery, Faculty of Medicine, University of Naples "Federico II," Naples, Italy.  
#Professor, Genetic Department of University "G. d'Annunzio," Chieti, Italy.  
#Chief Professor, Oral Science Department, University "S. Raffaele," Ateneo Vita e Salute, Milan, Italy.

AQ:9

Reprint requests and correspondence to: Stefano Tetè, MD, DDS, Dott. Filiberto Mastrangelo, Department of Oral Science, University "G. d'Annunzio," Via dei Vestini, Chieti 66013, Italy. Tel: +39 08713554095, E-mail: tete@unich.it/filibertomastrangelo@hotmail.com

ISSN 1056-6163/10/01906-001  
Implant Dentistry  
Volume 19 • Number 6  
Copyright © 2010 by Lippincott Williams & Wilkins  
DOI: 10.1097/ID.0b013e3182002eac

ing the healing period.<sup>9</sup> An essential role of osteogenesis processes is played by osteoblast progenitor stem cells during recruitment, adhesion, proliferation, differentiation, and mineralized matrix deposition during bone regeneration phases.<sup>10-12</sup> Adult human dental pulp and young human dental papilla cultured in osteogenic medium show cellular phenotypes and mineralizing capabilities similar to those of osteoblasts.<sup>15,16</sup> Numerous bone regenerative studies<sup>17-20</sup> have founded that human dental papilla stem cells (hDPaSCs), similar to adult stem cells, can differentiate into specialized cell types both *in vivo* and *in vitro* situations, confirming the feasibility of these cell line types for experimental regeneration and clinical application.<sup>12,21</sup>

In dental cell therapy, the technique for manipulation of the isolated dental progenitor/stem cell growth and induction of 3D tissue formation *in vitro* and *in vivo* needs to be developed.<sup>22,23</sup> The aim of our study is to analyze the physicochemical modification of new implant surfaces, the treatment modification of coating roughness, and their influence on osteoblast progenitor stem cell morphology, adhesion, and proliferation.

AQ:6

AQ:5

### MATERIALS AND METHODS

#### hDPaSCs Expansion and Mesenchymal Stem Cell Sorting

Six healthy patients (3 males and 3 females), in orthodontic treatment

## 2 INFLUENCE OF NANO-TITANIUM SURFACE • TETÈ ET AL

for Classes II and III malocclusion, hyperdivergence, and overcrowding, average age 16 years, were recruited at the Oral Science Department of "G. d'Annunzio" University, Chieti, for third molar germ extraction. In accordance with the Ethics Committee of the University of Chieti, all patients (or their parents in case of minors) expressed their informed written consent before surgery. Six impacted third molar buds were surgically removed, and the dental papillae were delicately removed and immediately were immersed in a digestive solution (4 mg/mL Dispase I [Roche, Basel, Switzerland]; 3 mg/mL collagenase [Sigma, St. Louis, MO]; 1% penicillin/streptomycin [Invitrogen]; 1% clarithromycin in 1.25 mL of minimum essential medium Eagle, alpha modification [ $\alpha$ -MEM; Sigma-Aldrich]) at 37°C, for 1 hour. After enzymatic digestion, cells were passed through a 70- $\mu$ m BD Falcon strainer (Becton Dickinson, Franklin Lakes, NJ), and the single-cell suspensions were seeded onto plates in standard growth medium ( $\alpha$ -MEM, 100  $\mu$ M 2-phospho-L-ascorbic acid, 2 mM L-glutamine [Sigma], 100  $\mu$ g/mL streptomycin, and 100 U/mL penicillin supplemented with 20% fetal bovine serum [Invitrogen], at 37°C in a 5% CO<sub>2</sub>). The medium was renewed every 3 days to remove cells debris. The adherent cells reached confluence after ~20 days. For mesenchymal cell sorting, an immunophenotypic analysis was performed on first-passage cells. Approximately  $1.5 \times 10^6$  cells were harvested, washed 3 times with phosphate-buffered saline (PBS), suspended in 0.7 mL PBS, and then incubated with 10  $\mu$ L fluorescein isothiocyanate- or phycoerythrin-labeled monoclonal antibodies against CD5, CD22, CD29, CD90, CD146, CD166, and STRO-1 and 2 mL fixative solution for 20 minutes at room temperature. Cells were centrifuged at 300g for 10 minutes, dissolved the pellet into 1 mL PBS, and then analyzed by using a fluorescence-activated cell sorter Vantage flow cytometer and CellQuest Software (Becton Dickinson). Cells positive for mesenchymal markers CD29, CD90, CD146, CDE166, and STRO-1 were sorted and collected for the osteogenic

differentiation. Nonsorted cells were used as controls.

#### **In Vitro Osteogenic Differentiation and Microscopic Observation**

For 40 days, sorted cells were collected and seeded under a controlled atmosphere (5% CO<sub>2</sub>, at 37°C) onto 10 mm dishes in Owen-modified osteogenic medium ( $\alpha$ -MEM, 15% fetal bovine serum [Invitrogen], 1% L-glutamine, 50  $\mu$ M 2-phospho-L-ascorbic acid trisodium salt [Sigma], 3 mM glycerol-2-phosphate disodium salt [Sigma], and 10 nM dexamethasone) at a density of no less than  $2 \times 10^7$ /mL.<sup>24</sup> Microscopic analyses (light microscope and electron microscope analyses) of differentiating cells were performed at day 7 (before the cell confluence) and at day 40 (after the cell confluence). For light microscope analysis, cells were stained with toluidine blue and observed under an AxioLab microscope (Zeiss, Oberkochen, Germany) connected to a digital camera, Fuji FinePixS2Pro (Fujifilm Corporation, Tokyo, Japan). The images were stored in RAF format with  $3032 \times 2035$  grid of pixels. The cells were then observed by electron microscope analysis with a scanning electron microscope (SEM) LEO 435 VP after being subjected to fixing procedure: the cells were treated with 3% glutaraldehyde in 0.15 M PBS (pH = 7.4) for 30 minutes and then washed in 0.15 M PBS for 15 minutes and post-fixed in 2% phosphate-buffered osmium with the addition of 0.15 M sucrose, at room temperature for 5 hours. The samples were gradually dehydrated in increasing concentrations of propylene oxide (from 50% to 100%, 10% steps), saturated with amyl acetate, carried through critical point drying according to standard procedure using liquid carbon dioxide, and sputtered with gold-palladium coating.

#### **Reverse Transcriptase Polymerase Chain Reaction and Western Blot Analyses**

To confirm that cells were differentiating toward an osteoblast-like pathway, the expression of typical markers was investigated. Reverse transcriptase polymerase chain reac-

tion (RT-PCR) and Western blot analyses were performed on days 3, 5, 10, and 40 from the beginning of culture in osteogenic conditions to evaluate alkaline phosphatase (ALP), osteocalcin (OCN), and matrix extracellular phosphoglycoprotein (MEPE) expression variations. For RT-PCR analysis, total RNA was extracted from differentiated cells on the established days, using 1 mL TRIzol (Life Technologies) and then amplified following the manufacturer's instructions. In brief, cDNA synthesis was performed with RNA by using RETROscript kit (Ambion, Inc.): 10  $\mu$ g purified RNA were incubated at 4°C for 1 hour with 10 mM Tris-HCl pH 8.3, 50 mM KCl, 1.5 mM MgCl<sub>2</sub>, 0.8 mM oligo-dT (Applied Biosystem), 5  $\mu$ M random primers, 0.5 U RNAsi inhibitor, and 5U reverse transcriptase. Then, 5  $\mu$ M of each specific oligonucleotide, 0.8 mM oligo-dT, 0.2 mM of each primer, and 2 U/50  $\mu$ L *Taq* polymerase (Applied Biosystem) were added to 2  $\mu$ L of the cDNA previously obtained. Samples underwent a preliminary 5-minute denaturation step at 94°C, followed by 35 cycles of 94°C for 1 minute, annealing at 55°C (ALP and MEPE) or 58°C (OCN and GAPDH) for 1 minute, and elongation at 72°C for 1 minute, with a final elongation step at 72°C for 10 minutes. The amplification products were subjected to electrophoresis on agarose gel, at room temperature, applying a potential difference of 1 to 3 V/cm. The identity of the products was confirmed by cycle sequencing the amplified cDNA.

For Western blot analysis, proteins were harvested at the indicated times, using 25 mM Tris buffer pH 7.4 (containing 150 mM NaCl, 100  $\mu$ M sodium orthovanadate, 1.5 mM MgCl<sub>2</sub>, 1.0 mM ethylenediamine tetraacetic acid, 1% NP40, 10% glycerol, 1 mM phenylmethylsulfonyl fluoride, 5  $\mu$ g/mL leupeptin, and 5  $\mu$ g/mL aprotinin) at 4°C. A part was taken from each sample to evaluate the total protein contents, according to the Bradford method.<sup>25</sup> Approximately 30  $\mu$ g/mL proteins were taken from the supernatant, loaded onto 12.5% to 15% polyacrylamide gel, and separated by electrophoresis. Proteins were

AQ:7

then moved to a polyvinylidene fluoride membrane, blocked with PBS/0.1% Tween20/5% nonfat milk (Bio-Rad Laboratories) for 2 hours at 4°C, incubated overnight at 4°C with specific primary antibodies (polyclonal rabbit anti-human ALP, dilution 1:10,000; anti-human OCN, dilution 1:200 [Abcam, Cambridge, United Kingdom]; and anti-human MEPE [1 µg/mL; R&D, Minneapolis, MN]), and then repeatedly washed and exposed to donkey anti-rabbit horseradish peroxidase-conjugated secondary antibody for 1 hour at room temperature (final dilution 1:5,000; GE Healthcare Life Sciences). To determine the equal loading of samples per lane, the blots were stripped and re-probed with an anti-β-actin antibody (dilution 1:100, incubation for 1 hour at room temperature; Santa Cruz Biotechnologies). Immunocomplexes were visualized using the enhancing chemiluminescence detection system (GE Healthcare Life Sciences) and quantified by densitometric analysis (Molecular Analyst System; Bio-Rad Laboratories).

#### Alizarin Red Staining

To assess the presence of mineralized depositions in the extracellular matrix (ECM), culture of differentiated cells were stained at days 5, 10, and 40 with Alizarin red S solution (Sigma-Aldrich, Milano, Italy), according to the method described by Gregory *et al.*<sup>26</sup>

AQ: 8

#### Description and Evaluation of Physicochemical Characteristics of Titanium Surfaces

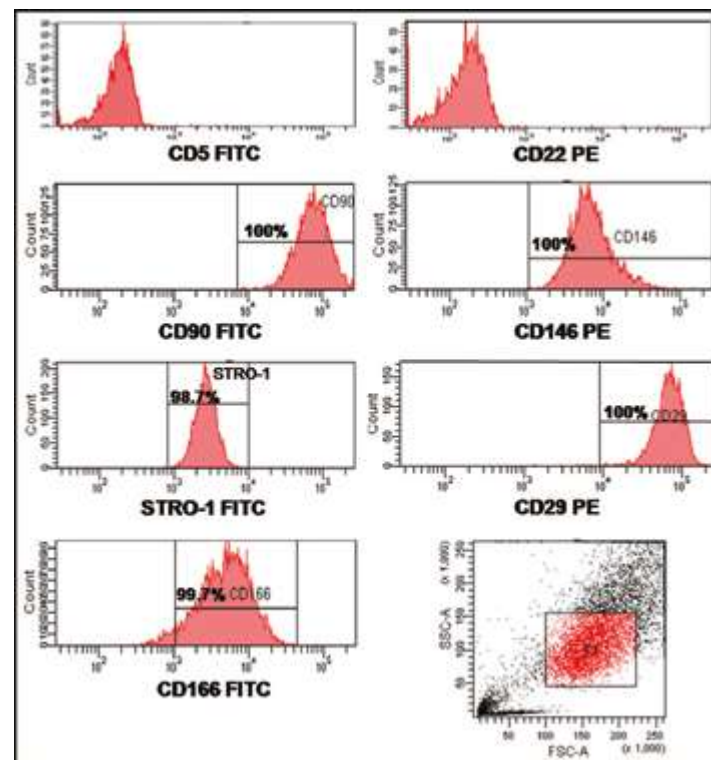
The titanium test discs to be used as scaffold for cell proliferation were provided by WinSix (BioSAF srl, London, United Kingdom). Sandblasted surface samples (SAB) were treated only with applied TiO<sub>2</sub> particles on the disc surface. The sandblasted and large-grit acid-etched (SLA) disc samples were obtained by 2 acid etching processes with fluoridric acid and sulfuric-hydrochloric acid (H<sub>2</sub>S-HCl) after one sandblasting TiO<sub>2</sub> process. The full contact coverage (FCC) surface samples were obtained by a galvanotactic anodizing process

in a phosphate-sulfate bath. All sample surface profilometry and morphology were analyzed with SEM LEO 420 (LEO Electron Microscopy, Ltd., Cambridge, United Kingdom) and commercial profilometer (Hommel T 20; Hommel GmbH, Villingen-Schwermingen, Germany), equipped with a 5-µm radius diamond tip and sensitive to vertical movements to an accuracy of 10.01 µm. All points of absolute values of average profile ( $R_a$ ), all points of values of root mean square ( $R_q$ ) and the average value of the absolute height of the 5 highest peaks, and the absolute depth of the 5 deepest valleys ( $R_v$ ) were taken. All surface samples were scanned at 5 different profilometric positions, and the data were automatically determined using software Statistica 8 (Stat Soft, srl, Italy),

and the variance was analyzed with *post hoc* turkey comparative test with the  $R_a$  roughness sample parameter. The chemical surface composition was evaluated by x-ray photoelectron spectroscopy (EDAX; Perkin Elmer PHI 5400 ESCA System) to analyze ~5 nm of the most external layer and expressed in atomic percentage.

#### Proliferation of Osteoblast-Like Cells Onto Titanium Surface

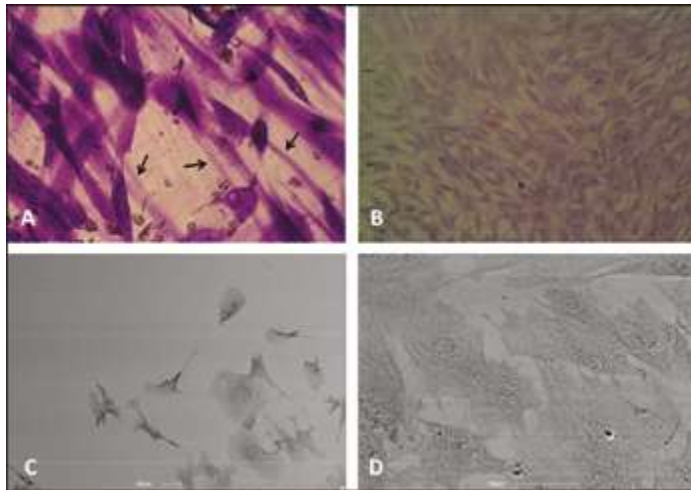
After the differentiation phase, osteoblast-like cells were replated onto the titanium test discs and The cells were selected into 3 groups, approximately  $3.7 \times 10^4$  cells were seeded onto each of the 3 different test discs and cultured in standard growth medium for a total of 20 days and were observed by SEM.



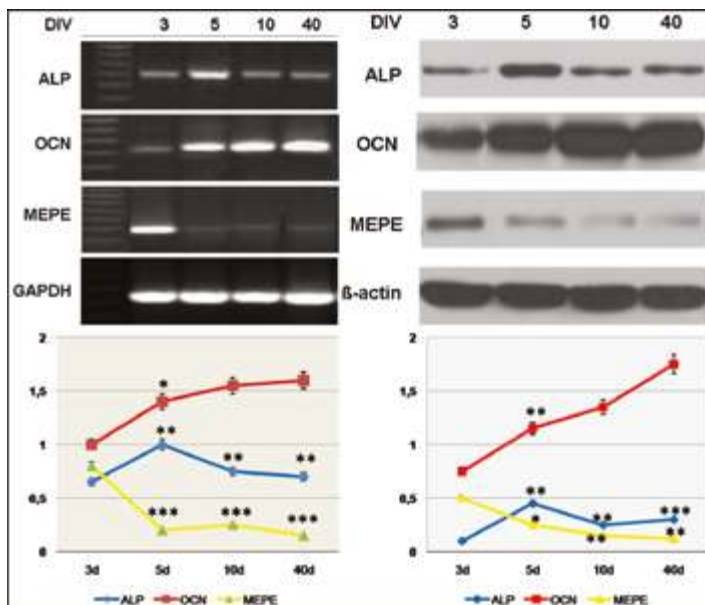
**Fig. 1.** Flow cytometric analysis of primary cultured hDPaSCs performed at day 20. Closed histograms, in red, represent staining for each marker expression. The hDPaSCs resulted negative for hematopoietic markers (CD5 and CD22) but positive for cell surface antigens exhibited by mesenchymal stem cells (CD29, CD90, CD146, CD166, and STRO-1).



## 4 INFLUENCE OF NANO-TITANIUM SURFACE • TETÈ ET AL



**Fig. 2.** Light (upper panel) and SEM (lower panel) observation of hDPaSCs after 7 (A and C) and 40 days (B and D) *in vitro*, under osteogenic conditions.



**Fig. 3.** Detection of ALP, OCN, and MEPE in hDPaSCs cultured under osteogenic differentiation condition by RT-PCR (left panel) and Western blot (right panel) at 3, 5, 10, and 40 days *in vitro*. Graphics represent the levels of ALP, OCN, and MEPE analyzed by scanning densitometry and normalized to GAPDH and to  $\beta$ -actin levels, respectively. In each panel, the values are expressed as mean  $\pm$  SEM (n = 3) versus values detected in cells at 3 days after seeding (\* $P$  < 0.05, \*\* $P$  < 0.01, \*\*\* $P$  < 0.001).

## RESULTS

Cell Sorting and Cell Behavior During *In Vitro* Osteogenic Differentiation

The hDPaSCs were isolated by enzymatic digestion. By day 1 and all through the first week in culture, cells were aggregated in groups with some cellular debris. At day 15, the cells were ~80% confluent. Immunophenotypic analysis by fluorescence-activated cell sorter allowed to discriminate a subpopulation of cells negative to hematopoietic markers CD5 and CD22 (hematopoietic stem/progenitor cells/endothelium) but positive to cell surface antigens exhibited by mesenchymal stem cells (CD29, CD90, CD146, CD166, and STRO-1; Fig. 1). The pattern of marker expression of the dental papillae obtained from different donors did not vary significantly.

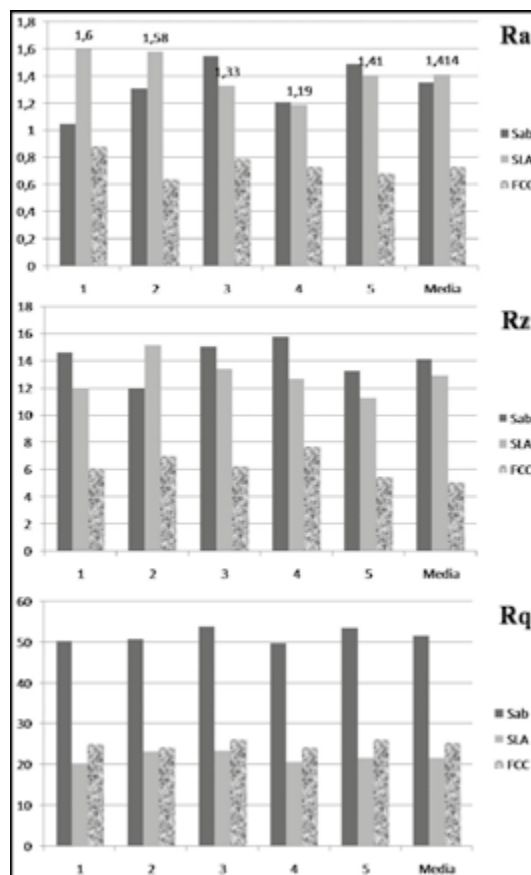
The cells were then induced to osteogenic differentiation by adding specific supplements to culture medium. Cells were observed by light and electron microscopes at day 7 (before the confluence) and at day 40 (after the confluence) to assess changes in cell morphology after cell differentiation. Moreover, to evaluate changes in typical osteoblastic marker expressions during the differentiation, cells were investigated at days 3, 5, 10, and 40 by RT-PCR and Western blot.

At light microscope observation after 7 days *in vitro*, cells from the initial aggregates started to expand, exhibiting a high proliferation rate and assuming a starry and a fibroblast-like morphology (Fig. 2, A). After 40 days, the samples were stained with toluidine blue, and at low light microscope magnification, the cells showed a diversified morphology and a thick net multilayer organization (Fig. 2, B). At SEM analysis, the cells showed a mesenchymal stem cell-like morphostructure with rounded nuclei. Long filopodia and lamellipodia surrounded the cell surfaces and formed a thick extracellular net by connecting the cells to each other. Fiber depositions could be observed on culture plates after cell confluence (Fig. 2, C and D).

Both RT-PCR and Western blot analyses on differentiating cells showed that the mRNA expression and the protein content of the investigated markers changes according to their specific be-



**Fig. 4.** Alizarin red staining of hDPASCs during osteogenic differentiation: **A**, day 5; **B**, day 10; and **C**, day 40.



**Fig. 5.** Graphic representation of the profilometric data on each surface of  $R_a$ ,  $R_z$ , and  $R_q$ .

havior. ALP increased to its maximum at day 5 and decreased during the following days, and its expression at day 40 was quite comparable with that during the first week. On the contrary, the analysis of OCN expression showed a significant, continuous increase during the experimental time. Finally, RT-PCR

and Western blot indicated that MEPE expression was downregulated, beginning from the fifth day after the addition of the osteogenic supplements (Fig. 3). Quantitative Alizarin red staining, on differentiating hDPaSCs at 5, 10, and 40 days confirmed cell differentiation into an osteoblast-like cell lineage (Fig. 4)

and revealed the increasing amount of mineralized nodule with high levels of calcium.

**Titanium Surface Observation**

Macroscopic and microscopic implant surfaces analysis showed typical specimens topography differences. At low ( $\times 300$ ) SEM analysis magnification, SAB implant surface showed a macroroughness morphology with irregularly distributed porosity. At higher ( $\times 5000$ ) magnification, irregular areas could be observed with elevated sharp crests alternated to deep valleys. SEM analysis of SLA implant surface at low ( $\times 1000$ ) magnification provided a microrough topography with regularly distributed cavities. At higher magnification, it was possible to observe more homogeneous surface porosity with bevelled peaks alternating with microvalleys. With FCC electrochemical treatment implant surface at low ( $\times 1000$ ) magnification SEM analysis, it was possible to notice more regular nanorough topography. At higher ( $\times 5000$ ) magnification, FCC surface showed specific morphology with regularly distributed crests similar to “volcanoes,” nanoporosities, and low valleys. Specimen profilometric evaluation confirmed different surface roughness with statistical parameters. SLA and FCC roughness surfaces exhibited statistically higher values ( $P = 0.0001$ ) than the SAB samples. The average roughness samples ( $R_a$ ) of the sandblasted titanium sample ( $1.35 \pm 0.16 \mu\text{m}$ ) was observed similar to the SLA specimen ( $1.41 \pm 0.20 \mu\text{m}$ ). FCC surface showed a lower  $R_a$  value ( $0.73 \pm 0.09 \mu\text{m}$ ; Fig. 5). In  $R_z$  analysis, it could be observed that the SAB specimens ( $14.11 \pm 1.09 \mu\text{m}$ ) showed very similar values to SLA ( $12.87 \pm 1.40 \mu\text{m}$ ). Moreover, the FCC titanium samples provided a significant lower  $R_z$  value ( $5.03 \pm 1.07 \mu\text{m}$ ), indicating a more regular surface (Fig. 5; Table 1) In accordance with the surface treatment process, the root mean square ( $R_q$ ) values showed the same range of roughness values for SLA ( $21.79 \pm 1.30 \mu\text{m}$ ) and FCC ( $25.37 \pm 0.95 \mu\text{m}$ ). Once again, in SAB implants, the  $R_q$  value ( $51.66 \pm 1.89 \mu\text{m}$ ) showed a

## 6 INFLUENCE OF NANO-TITANIUM SURFACE • TETÈ ET AL

higher difference (Table 1; Fig. 5), indicating an irregular surface. The sandblasting treatment left typical macroroughness on the surfaces, and SEM back scattered analysis of SAB surface specimens showed typical treatment morphology with different composition areas (gray colour), inclusions (particles of 10–20  $\mu\text{m}$ ) for higher sandblasted pressure, and broken border areas. In SLA specimens, it was possible to notice more homoge-

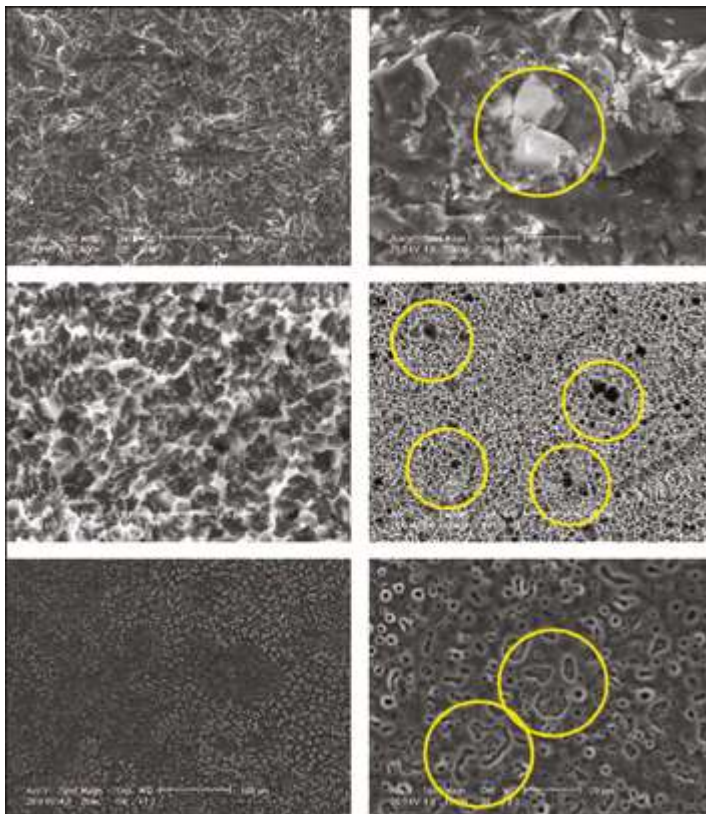
neous microroughness according to SLA treatment with more micro- and nanopores (2  $\mu\text{m}$ –150 nm), roughness crest (100–200 nm), and deep macropores (2–5  $\mu\text{m}$ ). SEM back scattered analysis of FCC specimens showed regular and plane surfaces with circular pores (10  $\mu\text{m}$ –700 nm), crests similar to volcanoes, and macrocircular pores (10  $\mu\text{m}$ ; Figs. 6A, 6B).

At EDAX analysis in all SAB samples, it was possible to observe

higher values of titanium (Ti), aluminium (Al), calcium (Ca), and oxygen ( $\text{O}_2$ ) and lower values of silicon (Si), sulphur (S), and chrome (Cr) residues of sandblasted treatment. The SLA implant group showed higher values only of Ti and lower value of  $\text{O}_2$ . EDAX analysis of all FCC specimens detected higher values of Ti and phosphorous (P), and lower values of  $\text{O}_2$  and Ca on the surfaces (Fig. 5).

**Table 1.** Mean Values of the Profilometric Analysis Lead on the Three Different Implant Samples

Specimens	$R_a$ ( $\mu\text{m}$ )	$R_z$ ( $\mu\text{m}$ )	$R_q$ ( $\mu\text{m}$ )
SAB	$1.35 \pm 0.15$	$14.11 \pm 1.08$	$51.66 \pm 1.89$
SLA	$1.41 \pm 0.19$	$12.87 \pm 1.39$	$21.91 \pm 1.30$
FCC	$0.75 \pm 0.09$	$6.23 \pm 1.06$	$25.37 \pm 0.94$

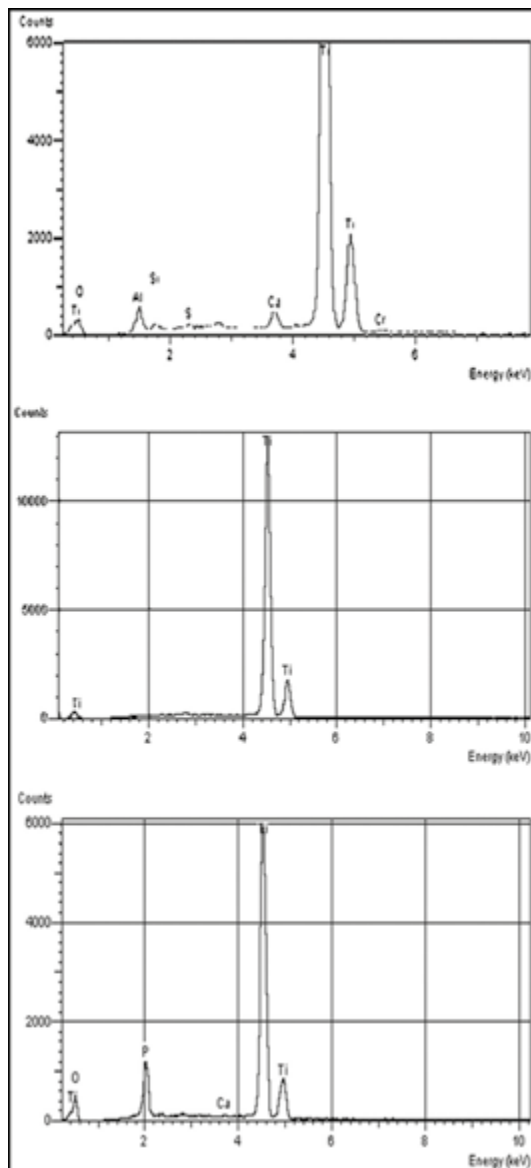


**Fig. 6A.** Upper panel: SEM and EDAX analysis of SAB implant surface. Middle panel: SEM and EDAX analysis of SLA implant surface. Lower panel: SEM and EDAX analysis of FCC implant surface.

#### Osteoblast-Like Cells Onto Titanium Surfaces

SEM analysis was used to evaluate cell morphology, cell distribution, and cell adhesion rate on different titanium coating. After culturing for 7 days onto SAB titanium coating, it is possible to notice a low number of osteoblast cells (200  $\mu\text{m}$ ), strongly adhering to the surface. At higher magnification (50–20  $\mu\text{m}$ ), the osteoblast cells appeared extremely flattened, with a typical shuttle morphology and long filopodia in close contact with each other and the material surface. After 7 days, SLA titanium specimens showed an increased number of cells on the coating (200  $\mu\text{m}$ ) with confluent monolayer cells in different small areas. At higher magnification in those areas, osteoblast-like cells showed an initial confluence phase and adherence onto the sample surfaces with an increased number of elongated filopodia and lamellipodia (50–10  $\mu\text{m}$ ). After 7 days, culturing onto FCC titanium coating was possible to evaluate a higher number of cells growing on the titanium surface, distributed around more samples areas, and the typical net morphology tended to form a confluent layer on the surface. At higher magnification (50–20  $\mu\text{m}$ ), the osteoblast cells network showed a great coating adhesion. A great number of filopodia and lamellipodia indicated a close contact to each other and is possible to observe an initial ECM deposition. At 20  $\mu\text{m}$  magnification, it was possible to evaluate the flattened cell morphology and strongly adhered osteoblast cell net on the nanostructure of the volcanoes FCC surface (Fig. 7).

F7



**Fig. 6B.** Upper Panel: SEM and EDAX analysis of SAB implant surface. Middle panel: SEM and EDAX analysis of SLA implant surface. Lower panel: SEM and EDAX analysis of FCC implant surface.

## DISCUSSION

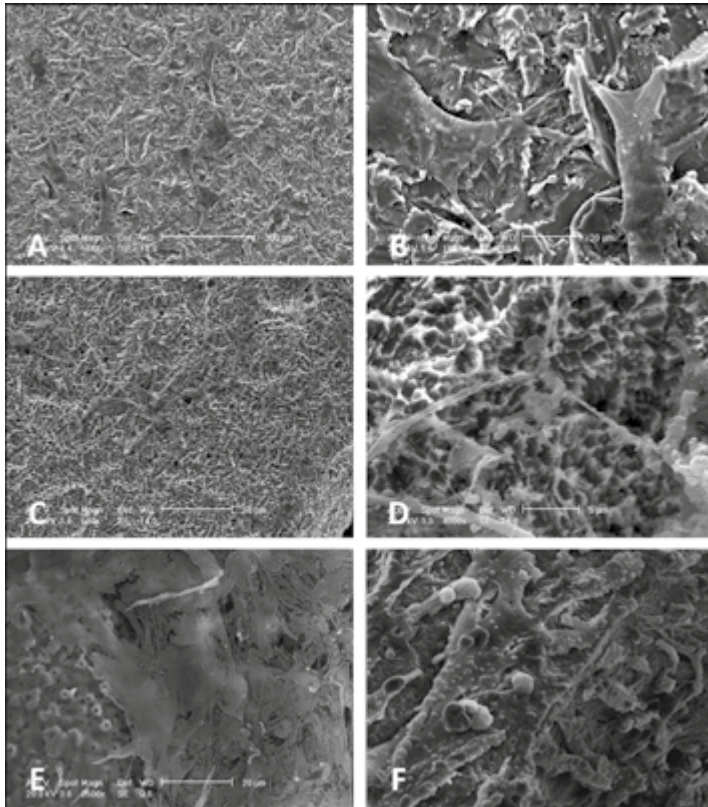
The osseointegration process is a complex mechanism for predictable clinical results of implant dentistry. Recent studies show that surface treat-

ment and macro- and microroughness morphology may direct the process of osseointegration by influencing important initial phases of differentiation of osteoblasts, cell adhesion onto the

surface, full cell proliferation, and ECM mineralized deposition to surfaces both *in vitro* and *in vivo*.<sup>3,8,27</sup> Some studies have shown that dental implants with a high nanoroughness value may promote bone formation around the implant fixture, maximize bone healing, and improve bone bonding for predictable clinical results.<sup>5,6</sup> The SEM and the profilometric Ti samples scans found a high roughness value in all the specimens examined. The  $R_q$  value of SAB implants confirmed the irregular macroroughness of the samples, with highest peaks and deepest valleys according to the specific surface treatment. The profilometric FCC and SLA average showed some  $R_q$  range values, with homogeneous microtopography with regular cavity distribution. In FCC samples, bevelled peaks appear alternated with microvalleys and nanoporosities. In this study, FCC testing demonstrated values of roughness ( $R_a$ ,  $R_z$ , and  $R_q$ ) of mostly regular surfaces comparable with values of sandblasted large-grit surfaces and sandblasted and acid-etched surfaces. Moreover, EDAX analysis showed the presence of a large number of residual molecules (Al, Ca, O<sub>2</sub>, Si, S, and Cr) of SAB treatment on the sample surfaces, whereas SLA and FCC surfaces were very clean and pure with the presence of residual products (Ca and P) more biocompatible with bone tissue. To test the ability of osteoblast-like cells obtained from hDPaSCs to proliferate onto surfaces commonly used for craniofacial implantology and to evaluate their usefulness for tissue engineering, we tested these cells on discs with SAB, SLA, and FCC titanium surfaces. SEM observation showed a good osteoblast-like cells growth and adherence on this latter surface. Osteoblast culture on titanium discs after 20 days found few cell colonies aggregated in a restricted areas of SAB coating and a lot of cell colonies onto SLA and FCC samples. With higher magnification, it was possible to note the presence of few cells nearer to the SAB specimens. Typical osteoblastic morphotype with poor lamellipodia



## 8 INFLUENCE OF NANO-TITANIUM SURFACE • TETÈ ET AL



**Fig. 7.** SEM observation of SAB (A and B), SLA (C and D), and FCC (E and F) implant surface after osteoblast-like cells culturing.

and long filopodia intracellular connections could be observed. After 20 days, the specimens, with high-magnification SEM analysis, showed areas with cell aggregates arranged almost uniformly and forming a cell culture layer on the disc with more intracellular connections. At the same time, high-magnification SEM analysis of FCC coating showed a great amount of cell proliferation adherent to the surface and many filopodia and lamellipodia connected to each other to form a thick net. At higher magnification SEM analysis, it is possible to observe the presence of typical exocytosis “bubbles,” evidence of large cellular activities, and, moreover, the presence of initial (ECM) matrix granule deposition onto the osteoblastic stem cell surfaces.

### CONCLUSION

Our research demonstrates that nanostructured surfaces can influence *in vitro* the early stage of osteogenesis with intense cellular reactivity. The FCC treatment eliminates surface contaminants and results in a consistent and reproducible Ti oxide surface layer with total biocompatible residues (Ca and P), which is characterized by unique nanopography. The interacting osteoblast-like cell coatings exhibit the typical morphology of migrating cells and adhesion with a big cell network, broad lamellar leading, and long filamentous training edges well supported by the cytoskeleton. However, biological osteoblast-like cell activity is clear for the comparison of the proliferation number, the closed adhesion behavior onto the surface, the cellular secretion

with numerous typical “bubbles” of exocytosis, and the presence of initial extracellular nodule of matrix deposition. The enhanced early cellular behavior and the surface nanostructure influence the kinetics of the initial phases of bone healing. Therefore, it will be interesting to follow-up the titanium nanostructure effects during formation and the later stage of *in vitro* osteogenesis and *in vivo* bone repair for a new generation of dental implants in which nanocoating, alone or with cells, can lead to faster and more predictable results of bone healing.

### Disclosure

The authors claim to have no financial interest in any company or in any of the products mentioned in this article.

### REFERENCES

1. Branemark PI, Adell R, Breine U, et al. Intra-osseous anchorage of dental prostheses. I. Experimental studies. *Scand J Plast Reconstr Surg.* 1969;3:81-100.
2. Branemark PI, Zarb GA, Albrektsson T, eds. *Tissue Integrated Prostheses: Osseointegration in Clinical Dentistry.* Chicago, IL: Quintessence Publishers; 1985:87-102.
3. Martin J, Schwartz Z, Hemmert T, et al. Effect of titanium surface roughness on proliferation, differentiation, and protein synthesis of human osteoblast-like cells (MG63). *J Biomed Mater Res.* 1995;29:389-401.
4. Wennerberg A, Albrektsson T, Johansson C, et al. Experimental study of turned and grit-blasted screw-shaped implants with special emphasis on effects of blasting material and surface topography. *Biomaterials.* 1996;17:15-22.
5. Cochran D, Schenk R, Lussi A, et al. Bone response to unloaded and loaded titanium implants with sandblasted and acid-etched surface: A histometric study in the canine mandible. *J Biomed Mater Res.* 1998;40:1-11.
6. Cooper LF. A role for surface topography in creating and maintaining bone at titanium endosseous implants. *J Prosthet Dent.* 2000;84:522-534.
7. Wen X, Wang X, Zhang N. Micro-rough surface of metallic biomaterials: A literature review. *Biomed Mater Eng.* 1996; 6:173-189.
8. Buser D. Titanium for dental applications (II): Implants with roughened surfaces. In: Brunette DM, Tengvall P, Textor M, et al, eds. *Titanium in Medicine.* Berlin, Germany: Springer; 2001:876-888.
9. Davies JE. Understanding peri-implant endosseous healing. *J Dent Educ.* 2003;67:932-949.



10. Smith DC. Surface characterization of implants: Biological implications. In: Davies JE, ed. *Bone Biomaterial Interface*. Toronto, Canada: Toronto University Press; 1991:9-17.
11. Bowers K, Keller J, Randolph B, et al. Optimization of surface micromorphology for enhanced osteoblast responses in vitro. *Int J Oral Maxillofac Implants*. 1992; 7:302-310.
12. Gronthos S, Brahimi J, Li W, et al. Stem cells properties of human dental pulp stem cells. *J Dent Res*. 2002;81:531-535.
13. Nakamura Y, Hammarström L, Matsumoto K, et al. The induction of reparative dentine by enamel proteins. *Int Endod J*. 2002;35:407-417.
14. De Coppi P, Bartsch G Jr, Siddiqui MM, et al. Isolation of amniotic stem cell lines with potential for therapy. *Nat Biotechnol*. 2007;25:100-106.
15. Antonucci I, Iezzi I, Morizio E, et al. Isolation of osteogenic progenitors from human amniotic fluid using a single step culture protocol. *BMC Biotechnol*. 2009;9:9.
16. Miura M, Gronthos S, Zhao M, et al. SHED: stem cells from human exfoliated deciduous teeth. *Proc Natl Acad Sci U S A*. 2003;100:5807-5812.
17. Kasugai S, Shibata S, Suzuki S, et al. Characterization of a system of mineralized-tissue formation by rat dental pulp cells in culture. *Arch Oral Biol*. 1993; 38:769-777.
18. Shi S, Robey PG, Gronthos S. Comparison of human dental pulp and bone marrow stromal stem cells by cDNA microarray analysis. *Bone*. 2001;29:532-539.
19. Tetè S, Nargi E, Mastrangelo F, et al. Changes in matrix extracellular phosphoglycoprotein expression before and during in vitro osteogenic differentiation of human dental papilla mesenchymal cells. *Int J Immunopathol Pharmacol*. 2008;21: 309-318.
20. Mastrangelo F, Nargi E, Carone E, et al. Tri-dimensional response of human dental follicular stem cells onto a synthetic hydroxyapatite scaffold. *J Health Sci*. 2007;20:819-826.
21. Laino G, D'Aquino R, Graziano A, et al. A new population of human adult dental pulp stem cells: An useful source of living autologous fibrous bone tissue (LAB). *J Bone Miner Res*. 2005;20:230-239.
22. Iohara K, Nakashima M, Ito M, et al. Dentin regeneration by dental pulp stem cell therapy with recombinant human bone morphogenetic protein 2. *J Dent Res*. 2004;83:590-595.
23. Owen TA, Aronow M, Shalhoub V, et al. Progressive development of the rat osteoblast phenotype in vitro: reciprocal relationships in expression of genes associated with osteoblast proliferation and differentiation during formation of the bone extracellular matrix. *J Cell Physiol*. 1990; 143:420-430.
24. Bradford MM. A rapid and sensitive method for the quantitation of microgram quantities of protein utilizing the principle of protein-dye binding. *Anal Biochem*. 1976; 72:248-254.
25. Gregory CA, Gunn WG, Peister A, et al. An Alizarin red-based assay of mineralization by adherent cells in culture: Comparison with cetylpyridinium chloride extraction. *Anal Biochem*. 2004;329: 77-84.
26. Buser D, Schenk R, Steinemann S, et al. Influence of surface characteristics on bone integration of titanium implants. A histomorphometric study in miniature pigs. *J Biomed Mater Res*. 1991;25:889-902.
27. Wennerberg A, Albrektsson T, Andersson B, et al. A histomorphometric and removal torque study of screw-shaped titanium implants with three different surface topographies. *Clin Oral Implants Res*. 1995; 6:24-30.



## Abstract Translations

### GERMAN / DEUTSCH

**AUTOR(EN):** Stefano Tetè, MD, DDS, Filiberto Mastrangelo, MD, DDS, PhD, Raimondo Quaresima, Raffaele Vinci, MD, Gilberto Sammartino, MD, DDS, Liborio Stupia, MD, and Enrico Gherlone, MD

**Einfluss einer neuartigen Nano-Titan-Implantat-Oberfläche auf das Verhalten und das Wachstum menschlicher Osteoblasten**

**ZUSAMMENFASSUNG: Zielsetzung:** Die vorliegende Studie zielt darauf ab, das Verhalten sowie das Wachstum menschlicher Osteoblastartiger Zellen bei Vorliegen dreier unterschiedlicher Titan-Implantat-Oberflächen zu untersuchen. **Materialien und Methoden:** Zuerst wurden menschliche Stammzellen entnommen, dann gemäß FACS aus mesenchymalen Stammzell-Clustern menschlicher Zahnpapillen aussortiert. Die so gewonnenen menschlichen Zahnpapillen-Stammzellen (hDPaSCs) wurden zur Ausdifferenzierung in Osteoblastartige Zellen gebracht und dann mittels RT-PCR und Western-Blot-Test analysiert. Die Zellen teilten sich und wurden auf drei unterschiedliche Titanscheiben (Sab, SLA, FCC) aufgetragen und mittels Rasterelektronenmikroskopie analysiert.

**Ergebnisse:** Bei allen Analyseproben konnte eine große Zellaktivität festgestellt werden. Dabei war eine für Osteoblasten typische reife morphostrukturelle Antwort auf rauen Oberflächen zu beobachten. Auf den Titan-FCC-Scheiben fand sich eine hohe Anzahl an Osteoblastartigen Zellen. Gleichzeitig erwies die Rasterelektronenanalyse eine große Biokompatibilität dieser Oberfläche. **Schlussfolgerung:** Die schnelle Reifung der Osteoblastartigen Zellen auf FCC-Titan-Oberflächen lassen den Schluss zu, dass diese Struktur eine zentrale Rolle bei den ersten Stufen des Knochenheilungsprozesses spielen könnte.

**SCHLÜSSELWÖRTER:** Menschliche Zahnpapillen-Stammzellen (hDPaSCs), Osteogenetische Differenzierung, Titanoberfläche, FCC-Oberfläche (Full Contact Coverage)

### SPANISH / ESPAÑOL

**AUTOR(ES):** Stefano Tetè, MD, DDS, Filiberto Mastrangelo, MD, DDS, PhD, Raimondo Quaresima, Raffaele Vinci, MD, Gilberto Sammartino, MD, DDS, Liborio Stupia, MD, y Enrico Gherlone, MD

**Influencia de la nano superficie de un novedoso implante de titanio en el comportamiento y crecimiento de osteoblastos humanos**

**ABSTRACTO:** *Propósito:* El objetivo de este estudio es investigar el comportamiento y crecimiento de células humanas parecidas a osteoblastos ante la presencia de tres superficies diferentes de implantes de titanio. *Materiales y Métodos:* Células humanas madre se obtuvieron primero y luego se organizaron por FACS grupos de células madre mesenquimales de la papila dental humana. Las células de la papila dental humana obtenidas (hDPaSCs) fueron inducidas a que se diferencien entre células parecidas a osteoblastos y luego analizadas por RT-PCR y Western blot. Las células proliferaron y fueron cultivadas en tres discos diferentes de titanio (Sab, SLA, FCC) y analizadas por SEM. *Resultados:* En todos los análisis, se observaron muestras de alta actividad celular, con la respuesta morfoestructural típica de osteoblastos maduros sobre una superficie áspera. El número alto de células parecidas a osteoblastos se encontró en discos de titanio FCC. Al mismo tiempo, el análisis SEM confirmó la alta biocompatibilidad de esta superficie. *Conclusión:* La rápida maduración de las células parecidas a osteoblastos en la superficie de titanio FCC sugiere que esta estructura podría jugar un papel central durante las fases iniciales de los procesos de curación del hueso.

**PALABRAS CLAVES:** Células madres de la papila dental humana (hDPaSCs), diferenciación osteogénica, superficie de titanio, superficie con cobertura completa de contacto (FCC)

**PORTUGUESE / PORTUGUÊS**

**AUTOR(ES):** Stefano Tetè Médico, Cirurgião-Dentista, Filiberto Mastrangelo, Médico, Cirurgião-Dentista, PhD, Raimondo Quaresima, Raffaele Vinci, Médico, Gilberto Sammartino, Médico, Cirurgião-Dentista, Liborio Stuppia, Médico e Enrico Gherlone, Médico

**Influência de Superfície Recente de Implante de Nano Titânio sobre o Comportamento e o Crescimento de Osteoblasto Humano**

**RESUMO:** *Objetivo:* O objetivo do estudo é investigar o comportamento e o crescimento de células tipo osteoblasto humano na presença de três diferentes superfícies de implante de titânio. *Material e Métodos:* Células-tronco humanas foram primeiro obtidas, então separadas por FACS a partir de agrupamentos de células-tronco mesenquimais de papilas dentárias humanas. As Células-Tronco de Papila Dentária humana obtidas (hDPaSCs) foram induzidas a diferenciar-se em células tipo osteoblasto e foram então analisadas por RT-PCR e Western blot. As células proliferaram e foram cultivadas em três diferentes discos de titânio (Sab, SLA, FCC) e analisadas por microscopia por varredura de elétrons. *Resultados:* Em todas as amostras de análise uma alta atividade celular foi observada, com típica resposta morfoestruc-

tural madura de osteoblasto em superfície áspera. O alto número de células tipo osteoblasto foi encontrado em discos de Titânio FCC. Ao mesmo tempo, a análise da microscopia por varredura de elétrons confirmou a alta biocompatibilidade desta superfície. *Conclusão:* A rápida maturação das células tipo osteoblasto em superfície de titânio FCC sugere que essa estrutura poderia desempenhar um papel central durante as fases iniciais de processos de cura do osso.

**PALAVRAS-CHAVE:** Células-Tronco de Papila Dentária Humana (hDPaSCs), diferenciação osteogénica, superfície de titânio, superfície de Cobertura de Contato Total (FCC)

**RUSSIAN / РУССКИЙ**

**АВТОРЫ:** Stefano Tetè, доктор медицины, доктор хирургической стоматологии, Filiberto Mastrangelo, доктор медицины, доктор хирургической стоматологии, доктор философии, Raimondo Quaresima, Raffaele Vinci, доктор медицины, Gilberto Sammartino, доктор медицины, доктор хирургической стоматологии, Liborio Stuppia, доктор медицины, и Enrico Gherlone, доктор медицины

**Влияние нового нанорельефа поверхности титанового имплантата на характер функционирования и рост человеческих остеобластов**

**РЕЗЮМЕ. Цель.** Целью данного исследования стало изучение характера функционирования и роста человеческих остеобластоподобных клеток при использовании трех разных видов поверхности титанового имплантата. **Материалы и методы.** Сначала были получены стволовые клетки человека, затем они были отсортированы с помощью клеточного сортера с флуоресцентной активацией (Fluorescence Activated Cell Sorter, FACS) из мезенхимных кластеров стволовых клеток сосочка зуба человека. Полученные стволовые клетки зубного сосочка человека (human Dental Papilla Stem Cells, hDPaSC) были посеяны, чтобы дифференцироваться в остеобластоподобные клетки, а затем был проведен анализ с помощью ПЦР-РВ и иммуноблоттинга. Клетки размножились, а затем подверглись выращиванию на трех титановых дисках различных типов (Sab, SLA, FCC), после чего был проведен их анализ с помощью сканирующего электронного микроскопа. **Результаты.** По результатам анализов всех видов наблюдалась высокая клеточная активность с типичной морфоструктурной реакцией зрелых остеобластов на неровную поверхность. Большое число остеобластоподобных клеток было обнаружено на титановых дисках FCC. Одновременно с этим, анализ с помощью сканирующего электронного микроскопа подтвердил высокую биосовместимость этой поверхности. **Вывод.** Быстрое развитие остеобластоподобных клеток на титановой поверхности FCC дает основание

предположить, что в период начальной фазы процессов заживления кости данная поверхность может играть основную роль.

**КЛЮЧЕВЫЕ СЛОВА:** стволовые клетки сосочка зуба человека (hDPaSC), остеогенная дифференциация, титановая поверхность, поверхность с покрытием полного контакта (Full Contact Coverage, FCC)

### TURKISH / TÜRKÇE

**YAZARLAR:** Stefano Tetè, MD, DDS, Filiberto Mastrangelo, MD, DDS, PhD, Raimondo Quaresima, Raffaele Vinci, MD, Gilberto Sammartino, MD, DDS, Liborio Stuppia, MD, and Enrico Gherlone, MD

**Yeni Nano Titanyum İmplant Yüzeyinin İnsan Osteoblastlarının Davranış ve Büyümesi Üzerine Etkisi**

**ÖZET: Amaç:** Bu çalışmanın amacı, üç adet değişik titanyum implant yüzeyinin varlığında insan osteoblastlarına benzer hücrelerin davranışlarını ve büyümesini araştırmaktır.

**Gereç ve Yöntem:** Önce insan kök hücreleri alındı ve ardından FACS yöntemi ile insan dental papillasındaki mezenkimal kök hücre kümelerinden sıralandı. Elde edilen insan Dental Papilla Kök Hücrelerinin (iDPKH) osteoblast-benzeri hücrelere farklılaşması sağlandıktan sonra bunlar RT-PCR ve Western blot yöntemleri ile analiz edildi. Hücreler çoğaldı ve üç değişik titanyum diskte (Sab, SLA, FCC) kültür yapıldı SEM ile analiz edildi. **Bulgular:** Tüm analiz örneklerinde pürüzlü yüzeyde tipik olgun osteoblast morfo-yapısal yanıt ile birlikte yüksek hücre aktivitesi görüldü. En yüksek sayıda osteoblast-benzeri hücreler, titanyum FCC disklerinde bulundu. Ayrıca, SEM analizi bu yüzeyin büyük ölçüde biyouyumlu olduğunu teyit etti. **Sonuç:** FCC titanyum yüzeyinde osteoblast-benzeri hücrelerin hızla olgunlaşması, bu yapının kemik iyileşme sürecinin başlangıç evrelerinde önemli bir rol oynayabileceğini düşündürmektedir.

**ANAHTAR KELİMELER:** İnsan Dental Papilla Kök Hücreleri (iDPKH), osteojenik ayrışma, titanyum yüzey, Full Contact Coverage (FCC) yüzey

F8-F10

### JAPANESE / 日本語

ヒト骨芽細胞の動態と増殖に影響するNovelナノチタン系インプラント表面

**共同研究者氏名:** ステファノ・テテ (Stefano Tetè) MD, DDS, フィリベルト・マストランジェロ (Filiberto Mastrangelo) MD, DDS, PhD, レイモンド・クアレシマ (Raimondo Quaresima), ラファエレ・ヴァンチ (Raffaele Vinci) MD, ジルベルト・サマルティノ (Gilberto Sammartino) MD, DDS, リボリオ・ステュピア (Liborio Stuppia) MD, エンリコ・ジェローネ (Enrico Gherlone) MD

#### 研究概要:

**目的:** 3種類の異なるチタン系インプラント表面に接したヒト骨芽細胞の動態と増殖の調査を当研究目的とした。

**素材と方法:** まずヒトの幹細胞を採取した。そしてヒト歯乳頭の間葉系幹細胞クラスターから FACSでソートし、採取したヒト歯乳頭幹細胞 (hDPaSCs) を誘導して骨芽細胞に分化した。続いて RT-PCRならびにウェスタンブロット法で分析した。次に細胞を増殖し3種類の異なるチタンディスク (Sab, SLA, FCC) に培養して SEMで分析した。

**結果:** 全ての分析サンプルには、粗い表面における骨芽細胞の確実な形成反応を特性とした高度な細胞活動が観察された。チタン FCC ディスクでは多数の骨芽細胞が観察され、同時に SEM 分析はこの表面での高度な生体適合性を確認した。

**結論:** FCC チタン表面における骨芽細胞の急速な増殖は、この構造が骨組織治癒プロセス初期段階において中心的な役割を果たす可能性を示唆している。

**キーワード:** ヒト歯乳頭幹細胞 (hDPaSCs), 骨芽細胞分化, チタン表面, フルコンタクト カバレッジ (FCC) 表面

3181-MST

MINERVA STOMATOL 2010;59:00-00

## Osteosynthesis plates, screws, xenogenic graft and resorbable barriers for preimplant and peri-implant surgery

G. M. RAUSO<sup>1</sup>, N. NESI<sup>2</sup>, L. FRAGOLA<sup>1</sup>, M. SANTAGATA<sup>2</sup>, V. SANTILLO<sup>3</sup>, R. RAUSO<sup>4</sup>

**Aim.** The guided bone regeneration (GBR) procedure allows the regeneration of bone in implant surgery. A variety of GBR procedures to provide the bony-support for implant placement have been described and a variety of devices to perform this procedures have been used. The authors have carried out a retrospective study on the use of osteosynthesis plates, screws, xenogenic bone grafting material and resorbable barriers for implant and preimplant surgery.

**Methods.** Fourteen partially edentulous patients were treated by a single surgeon in a private dental clinic in Italy. Patients age ranged between 28 and 52 years old. Every patients was treated with GBR technique performed with the use of osteosynthesis plate and screws, xenogenic bone grafting material and resorbable barriers in staged or simultaneous implant placement.

**Results.** Twenty-one implants were placed and no-one failed, all planned prostheses were delivered. In all the cases a complete bone regeneration was obtained.

**Conclusion.** The outcomes of the study allow to state that the GBR technique performed with osteosynthesis plates, screws, xenogenic graft and resorbable barriers is a safe alternative to the others well established GBR procedure.

**Key words:** Guided tissue regeneration - Dental implants - Bone regeneration.

Received on September 23, 2009.  
Accepted for publication on May 12, 2010.

Corresponding author: R. Rauso, MD, c/o Centro Polispécialistico Santa Apollonia, via Martiri del Dissenso 47, 81055, S. Maria C. V., Caserta, Italy.  
E-mail: raffaellerauso@virgilio.it

<sup>1</sup>Dentistry, Private Practitioner, Caserta, Italy

<sup>2</sup>Maxillo-Facial Surgery, Private Practitioner Cosenza, Italy

<sup>3</sup>Dentistry, Private Practitioner, Naples, Italy

<sup>4</sup>Maxillo-Facial Surgery, Private Practitioner Naples, Italy

A good amount of bone is an essential variable for a more favorable implant-crown ratio and better esthetics for implant surgery. Following the increase in the evolution of the dental implants, a multitude of surgical techniques have been developed to enhance the alveolar bone volume for implant placement.<sup>1-5</sup> The guided bone regeneration (GBR) procedure allows the regeneration of bone in staged or simultaneous approaches.<sup>6</sup> GBR is used during implant placement when stabilization of the implant in a optimal position is achieved, but part of the titanium surface is exposed. In this simultaneous application, GBR treatment is intended to cover the exposed implant surfaces with bone substance for functional reasons. When the bone amount does not allow to place an implant in an optimal position and primary stability is not achievable a GBR treatment should precede implant placement.

A variety of GBR procedures to provide the bony-support for implant placement have been described and a variety of devices to



RAUSO

OSTHEOSYNTHESIS PLATES, SCREWS, XENOGENIC GRAFT AND RESORBABLE BARRIERS

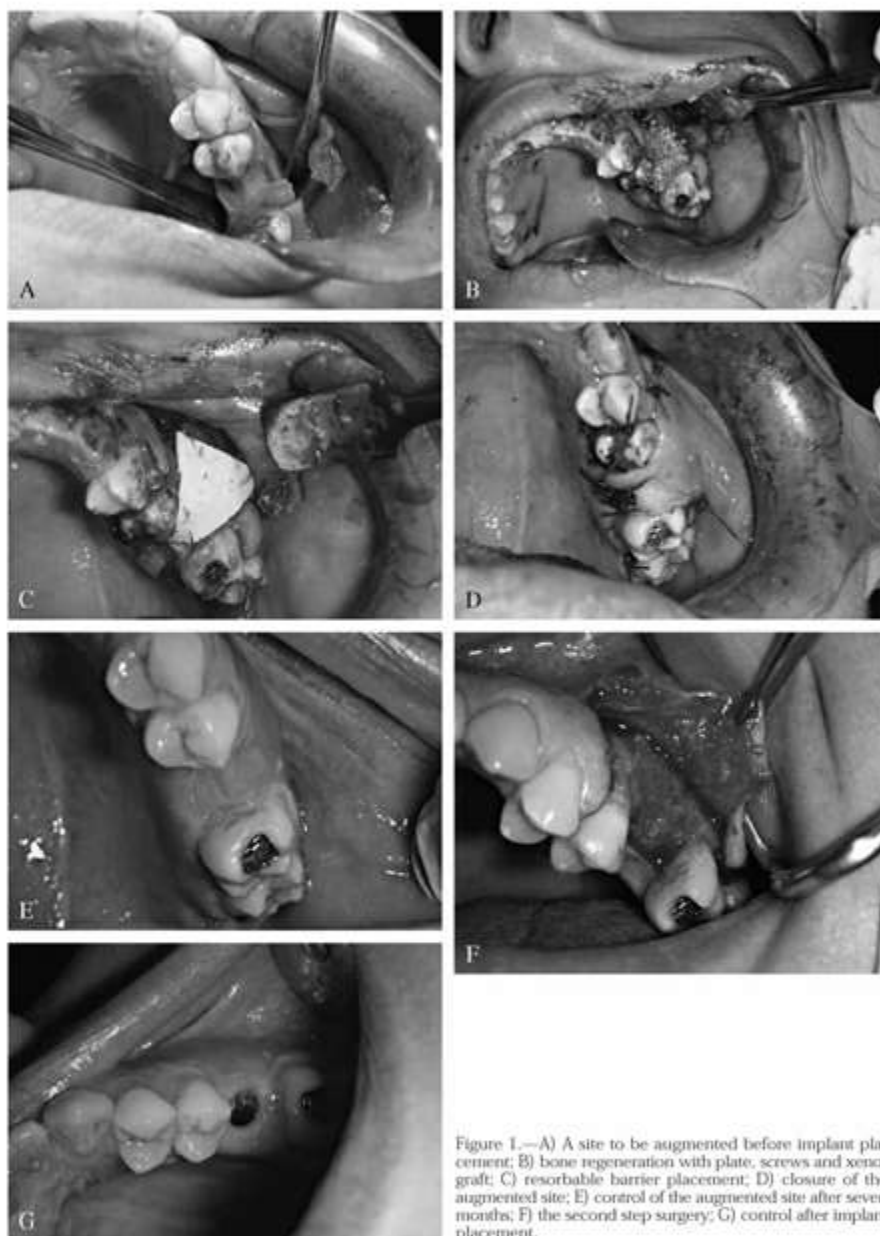


Figure 1.—A) A site to be augmented before implant placement; B) bone regeneration with plate, screws and xenograft; C) resorbable barrier placement; D) closure of the augmented site; E) control of the augmented site after seven months; F) the second step surgery; G) control after implant placement.



TABLE I.—Patients' characteristics.

Patient	Sex	Age (years)	Pathologies
1	M	36	—
2	M	52	Controlled hypertension
3	F	28	—
4	F	39	—
5	M	42	—
6	F	51	—
7	M	40	—
8	F	48	—
9	M	39	—
10	F	42	—
11	M	38	Controlled diabetes
12	M	41	Controlled hypertension
13	M	37	—
14	M	44	—

perform this procedures have been used: resorbable membranes, non resorbable membranes, pins, osteosynthesis plates, screws, etc.<sup>7</sup>

Autogenous bone grafts have most frequently been used in GBR procedure and are considered the gold standard for this technique.<sup>8,9</sup>

Otherwise, the introduction of new graft materials have provided alternatives to autogenous bone.

In literature, several studies regarding GBR procedure performed with different devices and using autogenous bone graft, allograft, xenograft or different mixtures of these materials, shows a high rate of success.

The authors have carried out a retrospective study on the use of osteosynthesis plates, screws, xenogenic bone grafting material and resorbable barriers for implant and pre-implant surgery.

### Material and methods

The study involved 14 subjects (9 males; 5 females) partially edentulous, treated by a single surgeon in a private dental clinic in

Italy. Patients age ranged between 28 and 52 years. Exclusion criteria were: general contraindication to implant surgery; irradiation in the head and neck area; poor oral hygiene and motivation; uncontrolled diabetes; pregnancy or lactation; substance abuse; smoking more than 10 cigarettes per die.

Every patient was treated with GBR technique performed with the use of osteosynthesis plate and screws, diameter 1.5 mm (Syntesis, Nuova GEASS S.r.l., Udine, Italy), xenogenic bone grafting material (Bio-Oss, Geistlich AG, Wolhussen, Switzerland) and resorbable barriers (Bio-Gide, Geistlich AG, Wolhussen, Switzerland) in staged or simultaneous implant (WINSIX Implant System, WINSIX L.T.D., London, UK) placement.

Features of the patients are listed in Table I.

Presurgical planning was conducted performing a CT dental scan using, when possible, a diagnostic plate built from study cast obtained with an individual face-bow.

All patients received prophylactic antibiotic therapy. Antibiotic therapy was performed with amoxicillin plus clavulanic acid (Augmentin, Glaxosmithkline S.p.a., Verona, Italy) *per os* twice a day for six days, starting 6 hours prior to surgery.

Local anesthesia was induced with articain and adrenalin (Septanest with Adrenalin 1/100.000, Septodont, Saint-Maur-des-Fossès Cedex, France).

Full-thickness flaps were raised to fully expose the area to be regenerated. Releasing incision were performed. The choice of the implant diameter and length was left up to the surgeon according to the pre-surgical planning. Implant were inserted according to the manufacturer's instruction. The implant diameters used ranged between 3.8 and 5.2 mm, whereas the lengths used were 7, 9, 11, 13, 15 mm. Features of the implant placed and their location are listed in Table II.

The surgeon cut and shaped 1 or 2 osteosynthesis plates in the desired form to maintain the amount of space to be regenerated and fixed the plates with screws. Bio-Oss was used as grafting material, mixing it with bisodic ceftriaxon (Rocefin, Roche S.p.a., Milan, Italy). The graft was modeled to com-

RAUSO

OSTHEOSYNTHESIS PLATES, SCREWS, XENOGENIC GRAFT AND RESORBABLE BARRIERS

TABLE II.—Number, feature, location of implants.

Patient	#of implant	Implant location	Features of implant (diameter x length, type)	Post-exercise placement	Pre-implant surgery
1	2	24-26	4.5x13 c; 5.2x7 KT	No	No
2	1	14	3.8x11 c	No	No
3	1	26	5.2x7 KT	No	Yes
4	1	36	4.5x13 c	No	No
5	2	13-15	4.5x13 KT; 4.5x13 c	13 Yes; 15 No	No
6	2	14-16	3.8x11 KT; 3.8x11 c	No	No
7	1	46	4.5x11 c	Yes	No
8	1	13-14	3.8x11 c; 3.8x11 c	No	No
9	1	16	4.5x11 KT	No	Yes
10	1	15	3.8x9 KT	No	No
11	3	44-45-46	4.5x11 c; 4.5x11 c; 5.2x9 KT	44-45 Yes; 46 No	No
12	3	43-44-45	4.5x15 c; 4.5x11 c; 4.5x9 c	43 Yes; 44-45 No	No
13	1	23	4.5x13 KT	No	No
14	1	24	3.8x11 c	No	Yes

C: cylindrical implant; KT: tapered implant.

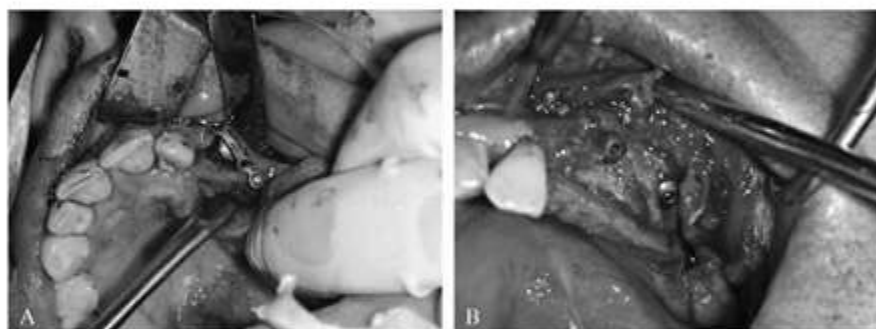


Figure 2.—A) A case of GBR and implant placement; B) the second step surgery.

pletely surround the implants or to fill the site to the desired height and shape where the implant would be placed in a staged surgery. Two resorbable collagen barriers (Bio-Gide) wet with bisodic ceftriaxon (Rocefin) were folded over the grafts. Barriers were shaped and positioned to avoid direct contact with the adjacent dentition.

Resorbable barriers were not fixed with miniscrews or pins but were laid on well-fixed osteosynthesis plates. Two resorbable barriers were placed 1 on the top of the other in a few sites. Periosteal incision were made to release the flaps as coronally as needed. Flap were sutured with horizontal mattress sutures modified sec. Laurell (5-0)

plus single sutures (5-0) (Vicryl rapid, Johnson and Johnson International, Belgium) until the incisions were perfectly sealed.

Patients were instructed to use delmopinol hydrochloride mouthwash 0.2% (Decapinol collut. 3000 MI, Dompè S.p.a., L'Aquila, Italy) and gel with a pool of aminoacids and sodium hyaluronate (Aminogam gel, Professional Dietetics S.r.l., Milan, Italy) three times per die for 20 days.

They were also instructed to avoid brushing and trauma to the surgical site and to avoid smoking for a few days post-surgery. Painkillers (Synflex forte 550 mg, Recordati S.p.a., Milan, Italy) were prescribed twice a day for four days and then as needed. Ice

OSTHEOSYNTHESIS PLATES, SCREWS, XENOGENIC GRAFT AND RESORBABLE BARRIERS

RAUSO

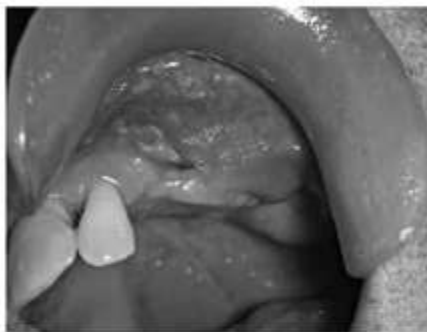

Figure 3.—A case where the osteosynthesis plate is seen through the mucosa.

packs were given to the patients. Suture were removed on average after 12 days. Patients were seen 2, 5, 8 and 12 days after surgery, then once every 15 days. After 15 days a Rx OPT was performed to control the correct placement of implant and/or osteosynthesis devices.

The second surgical step, to expose the implant or to place it after the right amount of bony-regeneration, was performed after seven months on average.

If the implant placement was performed after a primary GBR procedure, the prosthesis was performed as a non-regenerated site (three months for the jaw, six months for the maxilla).

### Results

No patients dropped out of the study. Twenty-one implants were placed and no-one failed, all planned prostheses were delivered. In all the cases a complete bone regeneration was obtained (Figures 1, 2). In all the cases plates and wires were removed at the surgery second step. In two cases dehiscence of the soft tissues was detected, and treated only with applications of chlorhexidine gel. It did not compromise the outcome of the regenerative procedure. In 10 out of 14 patients the osteosynthesis plate could be seen through the mucosa (Figure 3), no treatment was necessary, devices were left in

place until the second surgery without any problem.

### Discussion

The present study was designed to evaluate whether the GBR technique performed with osteosynthesis plates, screws, xenogenic graft and resorbable barriers is a safe and predictable technique. A same study was conducted by Merli *et al.* to evaluate the efficacy of vertical bone regeneration using particulated autogenous bone grafts protected by stable osteosynthesis plate and covered by resorbable barriers.<sup>14</sup> Merli *et al.* compared this technique with the GBR performed by using autogenous bone chips and titanium-reinforced nonresorbable barriers. No statistically significant differences for the amount of regenerated tissue or number of complications were observed between the two techniques.

Several studies demonstrated that the combination of deproteinized bovin bone mineral (DBBM) and collagen membrane may be used successfully for ridge augmentation of large bone defects.<sup>10, 15</sup> After seven months, quantitative and qualitative histology revealed no difference using DBBM with a resorbable collagen membrane or DBBM with a non-resorbable ePTFE membrane.<sup>16</sup>

In the present study, the time between augmentation and re-entry surgery is seven months on average. This is about three-four months longer compared with a human study using autogenous bone for ridge augmentation.<sup>17</sup> Clinical and histological studies using DBBM without autogenous bone have used healing times for different bone augmentation procedures ranging from 7 to 10 months.<sup>16, 18</sup> According to these studies, radiographic examination and clinical experiences, a healing time of seven months on average, was chosen for the present study.

One main advantage of the use of DBBM, *i.e.*, applying biomaterials to support resorbable membranes, is the avoidance of the morbidity associated with harvesting autogenic bone.<sup>20, 21</sup> This is of significant benefit for the patient and represents an

important step in the development of GBR procedures.

The use of osteosynthesis plate as space-maintainer, avoiding the use of non-resorbable ePTFE membrane titanium-reinforced, reduce the risk of infection. The published literature seems to indicate that problems with non-resorbable barriers are common. For instance, a retrospective trial including 32 patients treated for vertical ridge augmentation with autogenous bone chips and titanium-reinforced barriers showed that vertical augmentation could be considered a failure in terms of regenerated tissues in four of six patients whose barriers became exposed.<sup>22</sup> In another randomized clinical trial,<sup>23</sup> a group of 11 patients were treated with vertical ridge augmentation using autogenous bone chips and titanium-reinforced barriers. In three patients barriers were exposed. In two of these patients, the barriers had to be removed some weeks postoperatively, and the amount of regenerated bone was partially compromised. From the available scientific literature it can be estimated that 9% to 17% of the interventions<sup>22-24</sup> in patients treated for vertical ridge augmentation with autogenous bone chips and nonresorbable titanium-reinforced barriers will not be completely successful.

In the present study results differs from the outcomes of the investigation of Merli *et al.*<sup>14</sup> authors report a 100% success rate of complete regenerated bone, Merli *et al.* reported complete bone regenerated in the 81% of cases because of three abscesses. Probably this difference is due to the filled material used; Merli *et al.* used autogenous bone grafts that were always harvested using a bone trap on a dedicate suction device. In fact, in a recent Cochrane systematic review<sup>25</sup> evaluating the efficacy of various bone augmentation procedures, it was hypothesized that the collection of autogenous bone grafts with bone traps might be associated with increased infection rates. It is in fact known that considerable amounts of bacteria can be found in the particulated bone collected with bone traps also when dedicated suction devices are used.<sup>26</sup>

## Conclusions

From the outcomes of this study, however the number of patients was too low to detect a guideline, it is possible to affirm that the GBR technique performed with osteosynthesis plates, screws, xenogenic graft and resorbable barriers is a safe alternative to the others well established GBR procedure nowadays performed, avoiding the morbidity associated with harvesting autogenous bone and with no infection related problems, in fact even if in the 71% of cases the osteosynthesis plate could be seen through the mucosa and in the 14% of the cases the dehiscence of the soft tissues occurred, a correct amount of regenerated tissue was seen.

## References

1. Buser D, Dula K, Belser UC, Hirt HP, Berthold H. Localized ridge augmentation using guided bone regeneration. I. Surgical procedure in maxilla. *Int J Periodontics Restorative Dent* 1993;13:29-45.
2. Cordaro L, Sarzi AD, Cordaro M. Clinical results of alveolar ridge augmentation with mandibular block bone grafts in partially edentulous patients prior to implant placement. *Clin Oral Implants Res* 2002;13:103-11.
3. Donos N, Kostopoulos L, Karring T. Alveolar ridge augmentation by combining autogenous mandibular bone grafts and non-resorbable membranes. *Clin Oral Implants Res* 2002;13:185-91.
4. Donos N, Kostopoulos L, Karring T. Alveolar ridge augmentation using a resorbable copolymer membrane and autogenous bone grafts. *Clin Oral Implants Res* 2002;13:192-202.
5. Oda T, Sawaki Y, Ueda M. Experimental alveolar ridge augmentation by distraction osteogenesis using a simple device that permits secondary implant placement. *Int J Oral Maxillofac Implants* 2000;15:95-102.
6. Zitzmann NU, Scharer P, Marinello CP. Long-term results of implants treated with guided bone regeneration: a 5-year prospective study. *Int J Oral Maxillofac Implants* 2001;16:355-66.
7. Esposito M, Grusovin MG, Coulthard P, Worthington HV. The efficacy of various bone augmentation procedures for dental implants: A Cochrane Systematic Review of randomized controlled clinical trials. *Int J Oral Maxillofac Implants* 2006;21:696-710.
8. Von Arxt T, Cochran DL, Hermann JS, Schenk RK, Buser D. Lateral ridge augmentation using different bone fillers and barrier membrane application. *Clin Oral Implants Res* 2001;12:260-9.
9. Von Arxt T, Cochran DL, Hermann JS, Schenk RK, Higginbottom FL, Buser D. Lateral ridge augmentation and implant placement: an experimental study evaluating implant osseointegration in different augmentation materials in the canine mandible. *Int J Oral Maxillofac Implants* 2001;16:343-54.



10. Artzi Z, Dayan D, Alpern Y, Nencovsky CE. Vertical ridge augmentation using xenogenic material supported by a configured titanium mesh: clinicohistopathologic and histochemical study. *Int J Oral Maxillofac Implants* 2003;18:440-6.
11. Proussaefs P, Lozada J. Use of titanium mesh for staged localized alveolar ridge augmentation: clinical and histologic-histomorphometric evaluation. *J Oral Implantol* 2006;32:237-47.
12. Corinaldesi G, Pieri F, Marchetti C, Fini M, Aldini NN, Giardino R. Histologic and histomorphometric evaluation of alveolar ridge augmentation using bone grafts and titanium micromesh in humans. *J Periodontol* 2007;78:1477-84.
13. Pieri F, Corinaldesi G, Fini M, Aldini NN, Giardino R, Marchetti C. Alveolar ridge augmentation with titanium mesh and a combination of autogenous bone and anorganic bovine bone: a 2-year prospective study. *J Periodontol* 2008;79:2093-103.
14. Merli M, Migani M, Esposito M. Vertical ridge augmentation with autogenous bone grafts: resorbable barriers supported by osteosynthesis plate versus titanium-reinforced barriers. A preliminary report of a blinded, randomized controlled clinical trial. *Int J Oral Maxillofac Implants* 2007;22:373-82.
15. Hammerle CH, Jung RE, Yaman D, Lang NP. Ridge augmentation by applying bioresorbable membranes and deproteinized bovine bone mineral: a report of twelve consecutive cases. *Clin Oral Implants Res* 2008;19:19-25.
16. Friedmann A, Strietzel FP, Marezki B, Pitaru S, Bernimoulin JP. Histological assessment of augmented jaw bone utilizing a new collagen membrane compared to a standard barrier membrane to protect a granular bone substitute material. *Clin Oral Implants Res* 2002;13:587-94.
17. Antoun H, Sibon JM, Martinez H, Missika P. A prospective randomized study comparing two techniques of bone augmentation: onlay graft alone or associated with a membrane. *Biochin Oral Implants Res* 2001;12:632-9.
18. Valentini P, Abensur DJ. Maxillary sinus grafting with anorganic bovine bone : a clinical report of long-term results. *Int J Oral Maxillofac Implants* 2003;18:566-70.
19. Wallace SS, Froum SJ, Cho SC, Elian N, Monteiro D, Kim BS, Tarnow DP. Sinus augmentation utilizing anorganic bovine bone (Bio-Oss) with adsorbable and nonadsorbable membranes placed over the lateral window: histomorphometric and clinical analyses. *Int J Periodontics Restorative Dent* 2005;25:551-9.
20. Nkenke E, Schultze-Mosgau S, Radespiel-Troger M, Kloss F, Neukam FW. Morbidity of harvesting of chin grafts: a prospective study. *Clin Oral Implants Res* 2001;12:495-502.
21. Von Arx T, Hafliger J, Chappuis V. Neurosensory disturbances following bone harvesting in the symphysis: a prospective clinical study. *Clin Oral Implants Res* 2005;16:432-9.
22. Simion M, Jovanovic SA, Tinti C, Benfenati SP. Long-term evaluation of osseointegrated implants inserted at the time or after vertical ridge augmentation. A retrospective study on 123 implants with 1-5 year follow-up. *Clin Oral Implants Res* 2001;12:35-45.
23. Chiapasco M, Romeo E, Casentini P, Rimondini L. Alveolar distraction osteogenesis vs. vertical guided bone regeneration for the correction of vertically deficient edentulous ridge: A 1-3 year prospective study on humans. *Clin Oral Implants Res* 2004;15:82-95.
24. Merli M, Migani M, Bernardelli F, Esposito M. Vertical bone augmentation with dental implant placement: Efficacy and complications associated with two different techniques. A retrospective cohort study. *Int J Oral Maxillofac Implants* 2006;21:600-6.
25. Esposito M, Grusovin MG, Worthington HC, Coulthard P. Interventions for replacing missing teeth: Bone augmentation techniques for dental implant treatment. *Cochrane Database Syst Rev* 2006. Chichester, UK: John Wiley & Sons; 2006.
26. Young MP, Carter DH, Worthington H, Korachi M, Drucker DB. Microbial analysis of bone collected during implant surgery: A clinical and laboratory study. *Clin Oral Implants Res* 2001;12:95-103.

## L'utilizzo di placche da osteosintesi, viti, innesti xenogenici e membrane riassorbibili nella rigenerazione ossea guidata

Una corretta quantità d'osso è un requisito necessario per una favorevole correlazione impianto/corona, nonché per il raggiungimento di un risultato estetico ottimale. L'evoluzione delle tecniche in chirurgia implantare ha portato allo sviluppo di diverse metodiche atte al ripristino del volume osseo finalizzato per l'inserimento degli impianti<sup>1-5</sup>. La rigenerazione ossea guidata (*guided bone regeneration*, GBR) è una procedura che permette la rigenerazione di osso in chirurgia implantare<sup>6</sup>. La GBR viene effettuata contestualmente all'inserimento degli impianti solo quando la stabilità primaria, e la corretta collocazione dell'impianto stesso, sono effettuabili ma parte della superficie in titanio rimane esposta. In questi contesti il fine della GBR è quello di coprire la

superficie implantare esposta con materiali ossei per ragioni funzionali. Quando la quantità d'osso non permette la preparazione di un corretto sito implantare e la stabilità primaria non è raggiungibile, la GBR deve precedere la seconda chirurgia che prevederà l'inserimento dell'impianto.

Diverse tecniche di GBR in chirurgia implantare sono state descritte, nonché numerosi device atti a questo scopo: membrane riassorbibili, membrane non riassorbibili, chiodi, placche da osteosintesi, viti, ecc.<sup>7</sup>.

L'osso autologo viene considerato il gold standard per effettuare la GBR<sup>8,9</sup>.

Ad ogni modo, l'introduzione di nuovi materiali da innesto ha dato alternative all'uso dell'osso autologo.



RAUSO

OSTHEOSYNTHESIS PLATES, SCREWS, XENOGENIC GRAFT AND RESORBABLE BARRIERS

In letteratura diversi studi sulla GBR mostrano un'alta percentuale di successo utilizzando innesti autologhi, alle genici, xenogenici, o differenti misture di questi<sup>10-13</sup>.

Gli autori conducono uno studio retrospettivo sulla GBR effettuata previo placche da osteosintesi, viti, innesti xenogenici e membrane riassorbibili.

### Materiali e metodi

Il campione di studio è stato di 14 pazienti (9 di sesso maschile, 5 di sesso femminile) parzialmente edentuli trattati tutti dallo stesso chirurgo presso una clinica odontoiatrica privata in Italia. L'età dei pazienti oscillava tra i 28 e i 52 anni. I criteri di esclusione sono stati: controindicazioni generali alla chirurgia implantare, pregressa irradiazione del distretto cervico-cefalico, scarsa igiene orale e/o motivazione, diabete incontrollato, gravidanza o lattazione, abuso di droghe o farmaci, fumatore di più di 10 sigarette al giorno.

In ogni caso è stata effettuata una procedura di GBR, durante l'inserimento degli impianti (WINSIX Implant System, WINSIX L.T.D., Londra, UK) o in una chirurgia preimplantare, previo l'utilizzo di placche da osteosintesi e viti dal diametro di 1,5 mm (Syntesis, Nuova GEASS S.r.l., Udine, Italia), materiale da innesto xenogenico (Bio-Oss, Geistlich AG, Wollhusen, Svizzera) e membrane riassorbibili (Bio-Gide, Geistlich AG, Wollhusen, Svizzera).

Le caratteristiche dei pazienti sono riassunte nella Tabella I.

La programmazione prechirurgica è stata effettuata previo una TC Dental Scan facendo indossare al paziente, quando possibile, una dima diagnostica costruita sul modello di studio montato dopo la rilevazione dell'arco facciale.

Tutti i pazienti hanno ricevuto una terapia antibiotica profilattica con amoxicillina e acido clavulanico (Augmentin, GLAXOSMITHKLINE S.p.a., Verona, Italia) somministrati per via orale, due volte al giorno per sei giorni, partendo sei ore prima dell'intervento.

L'anestesia loco-regionale è stata indotta con articaina ed adrenalina (Septanest with Adrenalin 1/100 000, Septodont, Saint-Maur-des-Fossés, Francia).

Un lembo muco-periosteale a tutto spessore è stato scolpito per esporre l'area da rigenerare. Sono state effettuate incisioni di rilascio laterali. La scelta della lunghezza e del diametro dell'impianto da utilizzare sono state lasciate al chirurgo in accordo alla programmazione prechirurgica. Gli impianti sono stati inseriti seguendo le indicazioni dell'azienda manifatturiera. Il diametro degli impianti usati andava da 3,8 a 5,2 mm, le lunghezze erano di 7, 9, 11, 13 e 15 mm. Le caratteristiche degli impianti utilizzati e l'area d'inserimento sono riassunte nella Tabella II.

Il chirurgo ha tagliato e modellato nella forma desiderata 1 o 2 placche da osteosintesi, per sorreggere l'area da rigenerare, le placche sono state fissa-

te con delle viti. Il Bio-Oss miscelato con ceftriaxone bisodico (Rocefin, Roche S.p.a., Milano, Italia) è stato usato come materiale da innesto.

L'innesto è stato modellato per coprire completamente l'impianto inserito o per riempire il sito nell'altezza e larghezza desiderata per il successivo inserimento implantare in un secondo tempo chirurgico. Due membrane riassorbibili bagnate con ceftriaxone bisodico hanno coperto l'innesto. Le membrane sono state modellate e posizionate in maniera tale da evitare il contatto con la dentatura adiacente.

Le membrane riassorbibili non sono state fissate con miniviti o chiodi ma sono state lasciate giacere sulle placche da osteosintesi ben stabilizzate. Le due membrane sono state applicate l'una sull'altra. Incisioni di rilascio periostale sono state effettuate per garantire una corretta chiusura dei lembi d'accesso. I lembi sono stati suturati con dei punti tipo materasso orizzontale modificato sec. Laurell (5-0) e suture singole intercalate (5-0) (Vicryl rapid, Johnson & Johnson International, Belgio) fino al corretto sigillo dei lembi d'accesso.

I pazienti sono stati istruiti sull'uso di sciacqui orali con collutorio a base di delmopinolo idrocloride (Decapinol collut. 3000 Ml, Dompè S.p.a., L'Aquila, Italia) e l'applicazione di un gel a base di aminoacidi e sodio ialuronato (Aminogam gel, Professional Dietetics S.r.l., Milano, Italia) per tre volte al giorno, per 20 giorni.

Sono anche stati istruiti sulle modalità di igiene orale da effettuare a casa, evitando spazzolamento sui siti chirurgici, de evitando di fumare per qualche giorno nel post-operatorio. Sono stati prescritti farmaci anti-dolorifici (Synflex forte 550 mg, Recordati S.p.a., Milano, Italia), due volte al giorno per i primi quattro giorni postoperatori e poi solo al bisogno. Impacchi di ghiaccio sono stati dati al paziente, nel post-operatorio, da appoggiare sulla zona trattata. Le suture sono state rimosse in media dopo 12 giorni. I pazienti sono giunti a controllo in seconda, quinta, ottava e dodicesima giornata nel post-chirurgico, dopo di che una volta ogni 15 giorni. Dopo 15 giorni dall'intervento è stata effettuata un'OPT per il controllo del corretto inserimento degli impianti e/o delle placche da osteosintesi.

Il secondo tempo chirurgico, per esporre la testa degli impianti o per l'inserimento degli stessi dopo l'ottenimento dell'incremento osseo programmato, è stato effettuato in media sette mesi dopo.

Se l'inserimento dell'impianto era stato effettuato dopo una GBR preimplantare, il carico è stato effettuato considerandolo un sito non-rigenerato (tre mesi per la mandibola, sei mesi per il mascellare superiore).

### Risultati

Nessun paziente è uscito dal campione di studio. Ventuno impianti sono stati inseriti e nessuno è falli-

to, tutte le protesi progettate sono state applicate. In tutti i casi una completa rigenerazione ossea è stata ottenuta (Figure 1, 2). In tutti i casi le placche e le viti sono state rimosse nel ri-entro chirurgico. La deiscenza della ferita chirurgica è stata notata in due casi; è stata trattata solo previo applicazioni di gel di clorexidina e il risultato della rigenerazione ossea non è stato compromesso. In 10 casi su 14 si è verificata esposizione delle placche di osteosintesi (Figura 3), nessun trattamento è stato necessario; questi device sono stati lasciati *in situ* fino al secondo tempo chirurgico senza alcun problema.

### Discussione

Questo studio è stato effettuato per valutare l'efficacia della GBR effettuata con placche da osteosintesi, viti, innesti xenogenici e membrane riassorbibili. Uno studio simile fu condotto da Merli *et al.* per valutare l'efficacia della rigenerazione ossea verticale usando bone chip autologhi coperti da placche da osteosintesi e membrane riassorbibili <sup>14</sup>.

Merli *et al.* nel loro studio, hanno comparato questa tecnica di GBR con quella effettuata previo l'utilizzo di bone chip autologhi e membrane non-riassorbibili rinforzate in titanio. Nessuna differenza statistica in termini di quantità d'osso rigenerato e numero di complicanze è stato registrato tra le due tecniche.

Diversi studi hanno dimostrato che la combinazione di osso bovino de-proteinizzato (DBBM) e membrane di collagene esitano in successo nella rigenerazione ossea di difetti ossei anche ampi <sup>10, 15</sup>. Dopo sette mesi di guarigione, l'analisi istologica qualitativa e quantitativa non rileva differenze usando DBBM coperte da membrane in collagene o DBBM coperte da membrane non-riassorbibili <sup>16</sup>.

In questo studio, il tempo trascorso tra la rigenerazione e il rientro chirurgico è stato di sette mesi in media. Questo periodo è circa tre-quattro mesi più lungo comparandolo a uno studio umano usando osso autologo per la rigenerazione ossea <sup>17</sup>. Studi clinici e istologici sull'uso di DBBM senza osso autologo hanno mostrato tempi di guarigione più lunghi, tra i 7 e i 10 mesi <sup>16, 18, 19</sup>. In accordo con questi studi, con gli esami radiografici e con l'evidenza clinica, un periodo di guarigione di sette mesi in media, è stato scelto per questo studio.

Uno dei maggiori vantaggi nell'uso di DBBM, *i.e.*, applicando biomateriali per supportare le membrane riassorbibili, sta nell'evitare la morbidità associata nell'allestire un secondo sito chirurgico per il prelievo di osso autologo <sup>20, 21</sup>. Questo è un beneficio significativo per il paziente e rappresenta un importante passo per lo sviluppo delle tecniche di GBR.

L'uso delle placche da osteosintesi come mantentori di spazio, evitando così l'uso di membrane non-riassorbibili rinforzate in titanio, riduce il rischio di infezione. La letteratura a riguardo sembra indica-

re che problemi infettivi siano comuni all'uso di membrane non riassorbibili.

Uno studio clinico retrospettivo su 32 pazienti trattati per rigenerazione ossea orizzontale e verticale previo l'utilizzo di bone chip autologhi e membrane non riassorbibili rinforzate in titanio ha dimostrato come la rigenerazione può essere considerata un fallimento in termini di quantità d'osso rigenerata in quattro pazienti su sei ove ci sia stata esposizione delle membrane <sup>22</sup>. In un altro trial clinico randomizzato <sup>23</sup>, un gruppo di 11 pazienti sono stati trattati per rigenerazione verticale ossea previo l'utilizzo di membrane rinforzate in titanio. In tre pazienti le membrane si sono espese. In due di questi le membrane sono state rimosse poche settimane dopo l'intervento, e la quantità d'osso rigenerata fu parzialmente compromessa. Dalla letteratura scientifica è possibile notare un insuccesso variabile tra il 9% e il 17% nei pazienti trattati per rigenerazione ossea verticale previo l'utilizzo di bone chip autologhi e membrane non riassorbibili rinforzate in titanio <sup>22-24</sup>.

Nel presente studio i risultati sono stati differenti da quelli riportati da Merli *et al.* <sup>14</sup>; gli autori riportano un successo del 100% in termini di osso rigenerato; Merli *et al.* hanno riportato una rigenerazione ossea completa nell'81% dei casi, a causa di tre ascessi. Probabilmente la differenza è legata dal materiale da innesto utilizzato; Merli *et al.* hanno utilizzato osso autologo prelevato previo l'utilizzo di un grattino per osso montato su aspiratore. In effetti, in una recente revisione sistematica della Cochrane <sup>25</sup>, dove si valutava l'efficacia delle diverse tecniche d'incremento osseo, si ipotizza che l'allestimento di bone chip autologhi previo grattini per osso possa essere associato ad un aumentato tasso d'infezione. Di fatti è noto che una considerevole quantità di batteri possono essere rinvenuti tra i bone chip allestiti con grattini per osso <sup>26</sup>.

### Conclusioni

Dai risultati di questo studio, sebbene il numero di pazienti sia troppo esiguo per dettare delle linee guida, è possibile affermare che la GBR eseguita con placche da osteosintesi, viti, innesti xenogenici e membrane riassorbibili sia una valida alternativa alle altre tecniche ben documentate, evitando la morbidità dell'allestimento di un secondo sito chirurgico per il prelievo di osso autologo e senza problemi legati alla contaminazione del sito chirurgico; in fatti, anche se nel 71% dei casi c'è stata una esposizione delle placche da osteosintesi, e nel 14% la deiscenza della ferita chirurgica, una corretta quantità di osso rigenerato è stata osservata in tutti i casi.

### Riassunto

**Obiettivi.** La rigenerazione ossea guidata (*guided bone regeneration*, GBR) è una procedura che per-

RAUSO

OSTHEOSYNTHESIS PLATES, SCREWS, XENOGENIC GRAFT AND RESORBABLE BARRIERS

mette la rigenerazione ossea in chirurgia implantare. Diverse tecniche di GBR sono state descritte e diversi devices sono stati usati per questo scopo. Gli autori conducono uno studio retrospettivo sull'uso di placche da osteosintesi, viti, innesti xenogenici e membrane riassorbibili per effettuare GBR.

*Metodi.* Quattordici pazienti parzialmente edentuli sono stati trattati da un singolo chirurgo in una clinica odontoiatrica privata in Italia. L'età dei pazienti era compresa tra i 28 ed i 52 anni. In ogni paziente è stato effettuato un trattamento di GBR previo l'utilizzo di placche da osteosintesi, viti, innesti xenogenici e membrane riassorbibili.

*Risultati.* Ventuno impianti sono stati inseriti, nessuno è fallito e le protesi programmate pre-operatoriamente sono state applicate con successo. In tutti i casi la rigenerazione ossea, pre-operatoriamente programmata, è stata ottenuta.

*Conclusioni.* Dai risultati dello studio è possibile affermare che la GBR effettuata previo placche da osteosintesi, viti, innesti xenogenici e membrane riassorbibili è una alternativa affidabile e sicura alle altre ben consolidate tecniche di GBR.

Parole chiave: Rigenerazione guidata dei tessuti - Impianti dentali - Rigenerazione ossea.

IOS 49 1-14

ARTICLE IN PRESS

Caso clinico



ELSEVIER

MASSON

## Ricevuto il:

13 novembre 2009

## Accettato il:

21 settembre 2010

## Disponibile online:

xx xx xxxx

## Utilizzo del mucotomo per il rialzo del seno mascellare con approccio crestale: report preliminare

### Use of the circular soft-tissue punch in maxillary sinus lifts with a crestal approach: a preliminary report

F. Vannini<sup>a,\*</sup>, M. Nardone<sup>b</sup><sup>a</sup> Specialista in Odontostomatologia, Libero professionista, Roma<sup>b</sup> Specialista in Chirurgia Odontostomatologica, Ministero della Salute, Roma

## Parole chiave:

Edentulia del mascellare  
Atrofia mascellare  
Rialzo del seno  
Mucotomo circolare  
Tecnica di Summers

## Key words:

Edentulous maxillary  
crest  
Maxillary atrophy  
Sinus lift  
Circular mucotome  
Summers technique

## Riassunto

**Obiettivi:** Lo scopo di questo lavoro è quello di presentare i vantaggi derivanti dall'utilizzo del mucotomo nella tecnica di rialzo del seno mascellare secondo Summers, in caso di considerevoli riduzioni verticali della cresta del mascellare edentulo normalmente non trattabili con un approccio crestale.

**Materiali e metodi:** Dopo aver analizzato la tecnica di Summers, vengono descritte le modalità delle varianti apportate e i vantaggi che tale metodica può offrire al chirurgo e al paziente. A dimostrazione si descrivono alcuni casi clinici relativi a una casistica annuale di 25 pazienti trattati per la riabilitazione implantoprotesica del mascellare posteriore edentulo.

**Risultati:** I casi clinici presentati mettono in evidenza come l'utilizzo del mucotomo nella tecnica di Summers permetta la riabilitazione di situazioni anatomiche normalmente non risolvibili con tale procedura.

**Conclusioni:** La tecnica proposta comporta la possibilità di ampliare il numero dei casi trattabili, con vantaggi sia per il paziente, in termini di ridotta morbilità, sia per l'operatore, in termini di gestione tecnica dell'intervento.

© 2010 Elsevier Srl. Tutti i diritti riservati.

## Abstract

**Objectives:** The aim of this paper is to examine the advantages associated with use of the circular soft-tissue punch or mucotome with the Summers sinus lift technique (crestal approach) in cases characterized by substantial vertical reduction of an edentulous maxillary crest, which are usually impossible to treat with a crestal approach.

**Materials and methods:** The authors describe the Summers technique performed with a mucotome and underline the advantages this method can offer for both the surgeon and the patient. These advantages are illustrated with descriptions of cases selected from a series of 25 patients managed with implant-based rehabilitation of the edentulous posterior maxillary crest.

**Results:** The cases presented highlight how use of this circular tissue punch with the Summers technique allows one to correct maxillary atrophy that is normally impossible to resolve with this procedure.

**Conclusions:** With the technique proposed by the authors, the possibility of treatment is extended to a larger number of patients. It offers advantages for the patient, in terms of reduced morbidity, and for the operator, in terms of technical management of the intervention.

© 2010 Elsevier Srl. All rights reserved.

## \*Autore di riferimento:

posta@francovannini.it

(F. Vannini)

F. Vannini, M. Nardone

**CLINICAL IMPLICATIONS**

L'impiego del mucotomo, in caso di considerevole riduzione verticale della cresta del mascellare, consente di ampliare il numero di casi clinici da riabilitare implantoprotesicamente.

*The circular mucotome, in cases of considerable vertical reduction of the edentulous maxillary crest, makes it possible to expand the number of clinical cases treatable by implants.*

**Introduzione**

L'insufficiente quantità di cresta ossea residua e la pneumatizzazione del seno mascellare rappresentano, nella pratica clinica, un impedimento oggettivo alla riabilitazione implantoprotesica dei settori posteriori mascellari edentuli.

La mancanza di altezza ossea è il risultato del riassorbimento alveolare che si manifesta quale conseguenza della scomparsa dello stimolo trofico prodotto dai denti e della concomitante pneumatizzazione dell'antra di Hignoro.

L'utilizzo di procedure chirurgiche di depiazzamento verso l'alto della membrana che riveste internamente il seno mascellare ("sinus lift") consente di ottenere un ampliamento significativo delle dimensioni verticali della cresta alveolare [1-5]. L'entità del rialzo del pavimento, però, non deve essere così eccessivo da interferire con la funzionalità dell'ostio naso-sinusale: è necessario, infatti, garantire una condizione anatomico-funzionale caratterizzata dalla presenza di un muco sinusale idoneo, un movimento ciliare efficiente e una pervietà dell'ostio sinusale [6].

La metodica di "sinus lift" può essere usata anche in associazione a tecniche rigenerative in senso vestibolo-palatale in modo tale da consentire cambiamenti favorevoli all'angolazione implantare e, pertanto, migliorare i rapporti tra le arcate dentarie [7]. Esistono diverse varianti tecniche del "sinus lift" differenziabili in base alle vie di accesso alla cavità sinusale e ai differenti materiali da innesto che vengono utilizzati [8-10]. In merito ai materiali da innesto (osso umano e sostituti di osso), non esiste un optimum a eccezione dell'osso autologo di cui sono universalmente riconosciute la capacità induttiva e conduttiva e la sua intrinseca osteogenicità [11,12].

A seconda dell'altezza ossea crestale residua ci sono indicazioni di massima (attualmente oggetto di revisione) per quanto riguarda le tecniche da utilizzare per ottenere il rialzo del seno (*tabella 1*). In particolare, viene indicata la via crestale transalveolare (tecnica di Summers mediante osteotomi anulari) associata al contestuale inserimento di impianti in caso di mascellare con altezza maggiore o uguale a 5 mm [13-20]; i dati presenti in letteratura indicano che l'utilizzo di tale metodica consente di elevare il pavimento del seno mascellare fino a circa 5 mm. Questa metodica "a cielo coperto" richiede strumentazioni dedicate quali frese, osteotomi e martello chirurgico.

In caso di osso residuo minore di 5 mm è indicata, invece, l'osteotomia di accesso mascellare anterolaterale (vestibolare) che consente, sotto controllo visivo diretto, lo scollamento della membrana di Schneider e il conseguente posizionamento di materiale da innesto al di sotto della stessa, nella porzione inferiore del seno (intervento di Caldwell-Luc modificato, definito "inverted lateral window") [21-23].

Il rialzo di seno con osteotomia vestibolare rappresenta una procedura chirurgica che consente cospicui guadagni verticali di tessuto osseo, ma non è esente da complicanze [24,25]. Queste possono

**TABELLA 1 – TECNICHE CHIRURGICHE PER IL RIALZO DEL SENO**

Altezza della cresta	Procedura chirurgica consigliata
≥5 mm	Accesso crestale + impianti immediati
<5 mm	Accesso vestibolare (Caldwell-Luc modificata) <ul style="list-style-type: none"> <li>• con impianti immediati</li> <li>• con impianti differiti (tecnica in due fasi)</li> </ul>



manifestarsi durante la seduta operatoria come pure a seguito dell'intervento comparando, in tal caso, immediatamente dopo oppure a distanza di tempo. La perforazione della membrana rappresenta la complicanza intraoperatoria più frequente con un'incidenza variabile tra il 10% e il 35% [26,27]. Importanti sono pure le complicanze vascolari di tipo emorragico, sostenute principalmente dalla recisione dell'anastomosi tra l'arteria alveolare posteriore superiore e l'arteria infraorbitaria (l'anastomosi si trova nello spessore della corticale ossea della parete laterale del seno mascellare a pochi millimetri dagli apici dei premolari-molari e nel contesto dei tessuti molli a circa 25 mm dal margine crestale dei settori latero-posteriori) [28].

In considerazione anche di quanto sopra, il "sinus lift" con approccio vestibolare va utilizzato in casi accuratamente selezionati tenendo in debita considerazione la regola secondo la quale va scelto l'approccio chirurgico il più possibile scevro di complicanze e sequele [29]. È in tale ottica che si propone, in tutte quelle condizioni cliniche di estrema riduzione in altezza dell'osso crestale, l'utilizzo di una chirurgia simile a quella di Summers, modificata però secondo le nostre indicazioni. La tecnica da noi proposta prevede l'utilizzo di un apposito mucotomo circolare, che permette di scolpire un tunnel osseo estremamente conservativo evitando l'uso di frese chirurgiche. Questa metodica permette, come viene evidenziato da alcuni casi clinici che verranno descritti, l'applicazione di impianti contestualmente all'esecuzione del rialzo anche in condizioni di atrofia estreme, dove normalmente la tecnica di Summers viene sconsigliata.

### Materiali e metodi

Nel periodo gennaio 2007-dicembre 2007 sono stati trattati 25 pazienti (18 maschi e 7 femmine, di età compresa tra 43 e 72 anni) che si sono presentati alla nostra osservazione con edentulia dei settori posteriori mascellari. I criteri di selezione hanno previsto pazienti con assenza di lesioni nel cavo orale, evidente deficit verticale osseo ovvero con un'altezza della cresta ossea residua inferiore a 5 mm, igiene orale controllata (indice di placca e di sanguinamento inferiore al 30%),

desiderio di riabilitare la propria edentulia con una protesi fissa.

Al fine di ottenere un aumento dei valori verticali della cresta ossea si è però deciso l'utilizzo della sola tecnica di Summers modificata nella modalità da noi proposta. La tecnica di Summers, conosciuta anche come "mini-rialzo", in antitesi al "grande rialzo" che indica l'alternativa per via vestibolare, è stata introdotta nella pratica clinica nel 1994. Prevede, dopo aver messo a nudo la cresta ossea edentula mediante l'elevazione di un lembo mucoperiosteale, la creazione mediante fresaggio di un tunnel osseo attraverso il quale, con appropriati osteotomi e un martello chirurgico, si determina la frattura parcellare del pavimento del seno.

Nei casi da noi presi in considerazione, a causa dell'esiguo spessore crestale, non era però consigliabile utilizzare frese ossivore per raggiungere il pavimento del seno mascellare e si è pertanto proceduto con la variante proposta in questo lavoro. Questa prevede l'utilizzo di un mucotomo circolare, normalmente fabbricato per essere utilizzato con un micromotore contrangolo sui tessuti molli, che viene invece montato su di un manico fatto costruire appositamente (fig. 1). Questo è fabbricato in modo tale che il mucotomo può essere inserito a un'estremità, fissato tramite una microvite di serraggio, mentre l'altra estremità può essere battuta agevolmente con un martello chirurgico.

Lo scopo è quello di poter usare il mucotomo come uno scalpello molto tagliente con il quale creare un tramite osseo in maniera controllata e precisa, cosa non altrimenti ottenibile con l'uso di frese montate su manico micromotore, data l'altezza ossea veramente ridotta.


L'utilizzo del mucotomo consente un maggior controllo della forza di penetrazione nella cresta e permette di ottenere un'osteotomia circolare ben definita e profonda per i pochi millimetri necessari. Inoltre, permette la conservazione di tutto l'osso osteotomizzato. Il tassello osseo ottenuto può, così, essere spinto apicalmente con un dislocatore circolare o, se rimane dentro la cava del mucotomo, essere tolto e utilizzato, comunque, come materiale rigenerativo per l'elevazione parziale del pavimento del seno mascellare. Con questa tecnica, quindi, non viene persa la benché minima quantità dello già scarso tessuto osseo presente.

IOS 49 1-14

## ARTICLE IN PRESS

F. Vannini, M. Nardone

Fig. 1  
Mucotomo.



Il diametro del mucotomo utilizzato è di 3,5 mm per permettere una buona stabilità primaria all'impianto inserito che è dotato di un nocciolo implantare di 3,85 mm. L'esiguità dello spessore crestale dei casi selezionati non permette, infatti, di poter fare affidamento, per quanto riguarda la stabilità, sulle sole spire implantari ma deve soprattutto contare sulla frizione del collo implantare nello spessore osseo. Gli impianti utilizzati (Z, linea SIM, Acerboni) sono di forma conica, automaschianti, con spire di larghezza 5 o 6 mm, distanziate tra di loro di 2 mm; sono tutti dotati di una cava con esagono interno che consente l'utilizzo di perni-moncone con viti di fissaggio.

Allo scopo di rendere meno traumatico il sostegno della membrana schneideriana da parte della testa dell'impianto, è stato usato del materiale da innesto costituito da collagene eterologo (Condress, Cura-prox) frammisto a granuli di tessuto osseo deantigenato equino (BioBone Osteoconductor 0,5-1 mm, BioSAF IN) anche con lo scopo di rendere radiograficamente più visibile, già in sede intraoperatoria, l'entità del rialzo ottenuto. Il tutto amalgamato e imbibito in soluzione fisiologica.

A tal proposito è bene sottolineare che il collagene determina una rigenerazione ossea radiografica paragonabile a quella che si ottiene con altri biomateriali, mentre materiali da innesto o osso autologo, a livello del seno mascellare,

sono significativamente utili soltanto per abbreviare i tempi di guarigione senza influire minimamente sulla qualità del risultato [30].

Le valutazioni cliniche e radiografiche sono state effettuate in team, come pure la riabilitazione protesica, mentre le procedure chirurgiche sono state effettuate da un singolo operatore, Franco Vannini, ideatore di questa tecnica.

Dopo esame clinico, radiografico e uno studio dei modelli diagnostici per la determinazione della relazione interarcata, della dimensione verticale, della posizione ideale degli impianti, del rapporto corona-radice, è stata eseguita una ceratura diagnostica.

Si è provveduto, in sede preliminare, a informare i pazienti sulle procedure attuate, sia verbalmente sia con modulo scritto per il consenso informato. È stata, quindi, prescritta una terapia antibiotica per os (amoxicillina, cps 1 g per 2 g die) da iniziare un giorno prima dell'intervento e fino a 7 giorni dopo e una terapia analgesica-antinfiammatoria (naprossene sodico, cps 550 mg) subito dopo l'intervento e da seguire in caso di persistenza della sintomatologia dolorosa.

Gli autori dichiarano che lo studio presentato è stato realizzato in accordo con gli standard etici stabiliti nella Dichiarazione di Helsinki e che il consenso informato è stato ottenuto da tutti i partecipanti prima del loro arruolamento allo studio.

## Risultati

Nei 25 pazienti trattati sono stati inseriti, dopo sollevamento della membrana sinusale con approccio crestale mediante mucotomo, 68 impianti, tutti con spire di diametro minimo di 5 mm e lunghezza da 10 a 14 mm.

Nell'arco di tempo compreso tra 1 mese e 3 mesi dall'intervento è sorta la necessità di rimuovere tre impianti (due per presenza di mucosite con successiva perimplantite ortograde, uno per riferito continuo dolore); gli impianti con mucosite, comparsa in contemporanea alla rimozione delle suture, erano stati inseriti nello stesso paziente in zona 2.6 e 2.7 in assenza di controindicazioni assolute e relative per riabilitazione implanto-protesica. Altri due impianti, invece, sono stati rimossi in occasione dello svitamento delle viti di guarigione dopo 4 mesi, poiché non osteointegrati (tabella II).

La percentuale cumulativa di successo implantare è stata del 92,64% considerando criteri di successo: l'assenza di mobilità implantare clinicamente rilevabile, l'assenza di dolore e di qualunque sensazione riferita dal paziente, l'assenza di infezioni perimplantari ricorrenti, l'assenza di radio-trasparenza intorno all'impianto. A circa 1 anno dal carico protesico, il tasso di successo per le protesi inserite è stato del 100%.

TABELLA II – DESCRIZIONE DELLA CASISTICA

	Totale
Pazienti trattati	25
• maschi (18)	
• femmine (7)	
Impianti inseriti	68
Siti di utilizzo del mucotomo	68
Impianti rimossi	
• entro 3 mesi	3
• dopo 4 mesi	2

## Casi clinici

### Primo caso clinico

Paziente di sesso maschile, di anni 65, bruxista, con edentulia nel settore posteriore sinistro e mancanza di 1.6 e 1.7 (figg. 2 e 3). Si procede con la riabilitazione del quadrante destro, poiché, vista la presenza dell'1.8, è questa la zona che maggiormente viene sfruttata dal punto di vista masticatorio.

Dopo aver eseguito un lembo a tutto spessore della mucosa, si procede all'incisione circolare dell'osso crestale tramite delicato martellamento del mandrino su cui è montato il mucotomo, in zona

Fig. 2

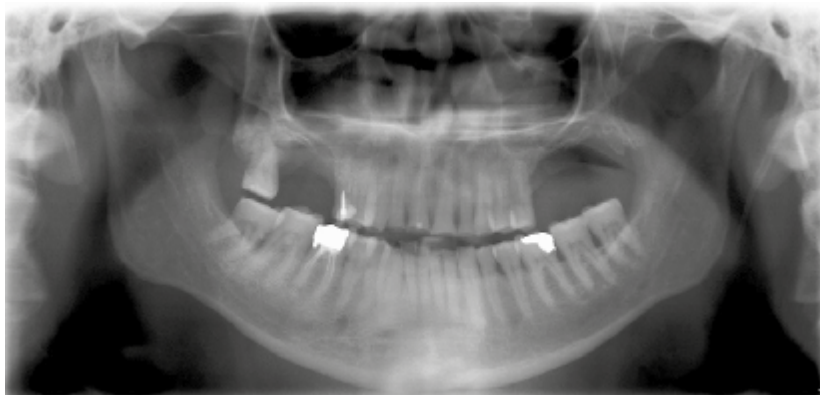


Fig. 2

Caso clinico 1:  
Rx ortopantomica  
alla prima visita.

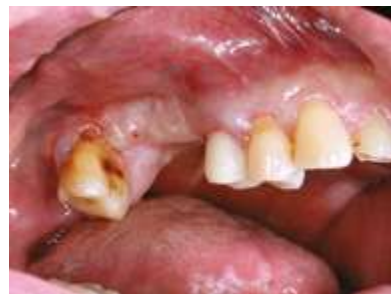IOS 49 1-14

## ARTICLE IN PRESS

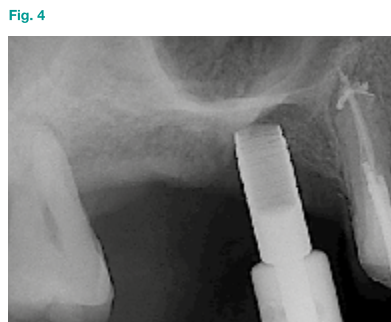
F. Vannini, M. Nardone

1.6 e 1.7 (fig. 4). Sul taglio osseo eseguito viene, quindi, appoggiato uno scalpello da mini-rialzo e viene operata la frattura della teca ossea sinusale, con distacco e sollevamento, all'interno della cavità sinusale, dell'opercolo osseo (fig. 5).

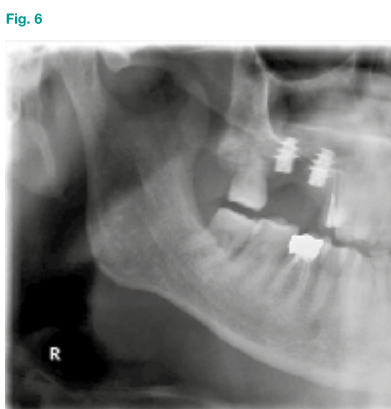
**Fig. 3**  
Caso clinico 1: Edentulia di 1.6 e 1.7.



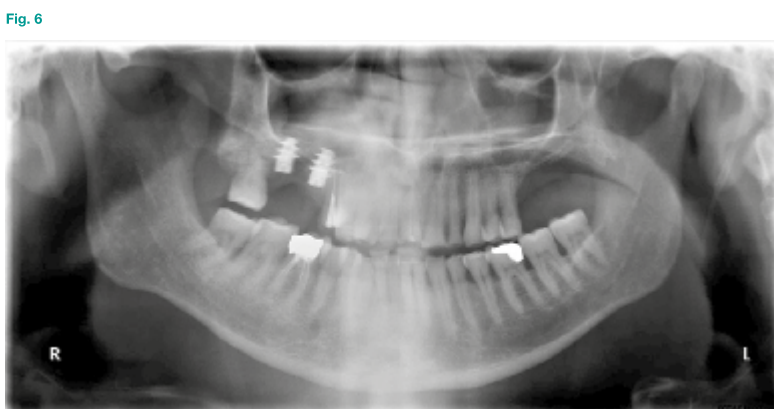**Fig. 4**  
Caso clinico 1: Rx endorale con mucotomo.



**Fig. 5**  
Caso clinico 1: Rx endorale con dislocatore.



**Fig. 6**  
Caso clinico 1: Rx ortopantomica di controllo con impianti inseriti.



Dopo aver verificato l'integrità della membrana di Schneider, tramite manovra di Valsalva, si inserisce del collagene nel foro praticato, spingendolo apicalmente a sostenere il rialzo eseguito e per mantenere un certo distacco tra questo e l'impianto. Si avvita, quindi, manualmente e con una certa lentezza gli impianti, di diametro 6 mm e lunghezza 12 mm il mesiale e 10 mm il distale (fig. 6).

La stabilità primaria viene garantita dalle prime spire ed è così elevata da permettere l'applicazione immediata di due viti di guarigione transmucose (fig. 7). Le due viti guideranno la mucosa crestale nel processo di guarigione ed eserciteranno uno stimolo funzionale alla rigenerazione ossea perimplantare.

A distanza di 40 giorni dall'intervento è possibile evidenziare il buono stato della mucosa perimplantare (fig. 8); dopo 5 mesi si procede alla riabilitazione

**Fig. 5**

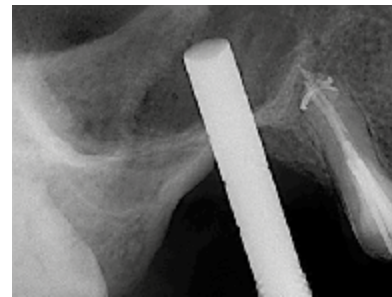


Fig. 7

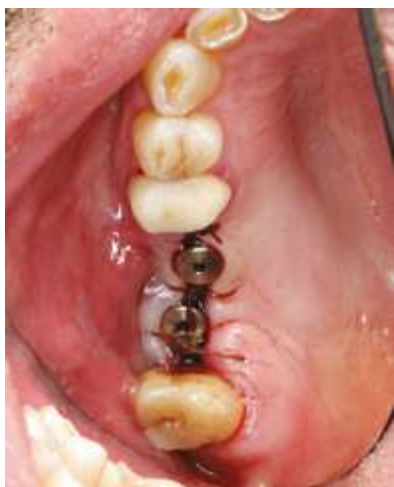

Fig. 8

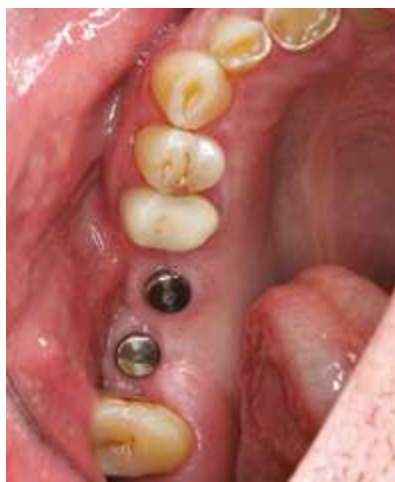

Fig. 7

Caso clinico 1:  
Viti di guarigione.

Fig. 8

Caso clinico 1:  
Stato della mucosa  
perimplantare a 40 giorni  
dall'intervento.

protesica del quadrante 1 con una struttura in metallo-resina (fig. 9).

La scelta di questo materiale è stata dettata dalla necessità di non poter utilizzare la ceramica, che ha un indice di resistenza all'abrasione maggiore dello smalto dentario, in un paziente bruxista.

Dopo 6 mesi dall'avvenuta protesizzazione viene eseguita un'ortopantomografia di controllo (fig. 10) in concomitanza con l'applicazione di impianti anche nel settore superiore sinistro. Quest'ultimo intervento, richiesto dal paziente che era rimasto molto soddisfatto dall'esito del primo, per il percorso terapeutico assolutamente privo di sintomatologia, è stato eseguito con la stessa tecnica.

### Secondo caso clinico

Paziente di sesso femminile, di anni 52, con edentulia del settore posteriore superiore destro e presenza di elementi protesici in metallo-ceramica sugli elementi 1.3 e 1.4 con 1.5 "a bandiera".

L'ortopantomografia (fig. 11) evidenzia la ridotta altezza ossea residua a livello del mascellare posteriore destro, mentre l'esame obiettivo locale permette di apprezzare anche un ridotto spessore vestibolo-palatale della cresta (fig. 12).

Fig. 9

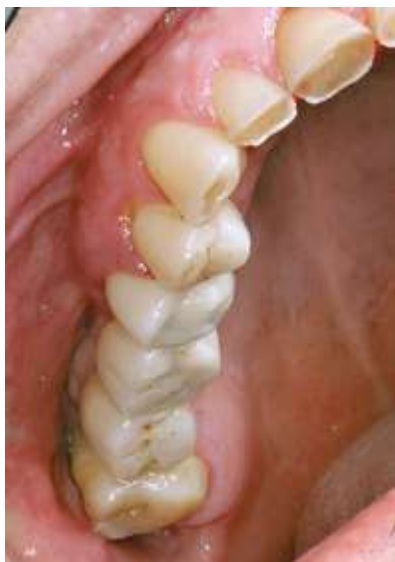

Fig. 9

Caso clinico 1: Elementi  
protesici 1.6 e 1.7.

Si provvede a elevare un lembo a tutto spessore tramite un'incisione crestale a partire dall'1.4 fino al tuber maxillae. Come da procedura, si utilizza



IOS 49 1-14

## ARTICLE IN PRESS

F. Vannini, M. Nardone

Fig. 10

Caso clinico 1:  
Rx ortopantomica  
a 6 mesi dalla  
protesizzazione.

Fig. 10

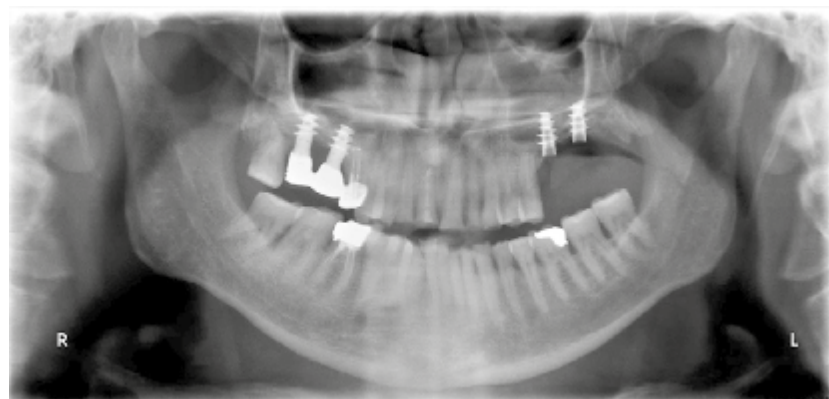


Fig. 11

Caso clinico 2:  
Rx ortopantomica  
alla prima visita.

Fig. 11

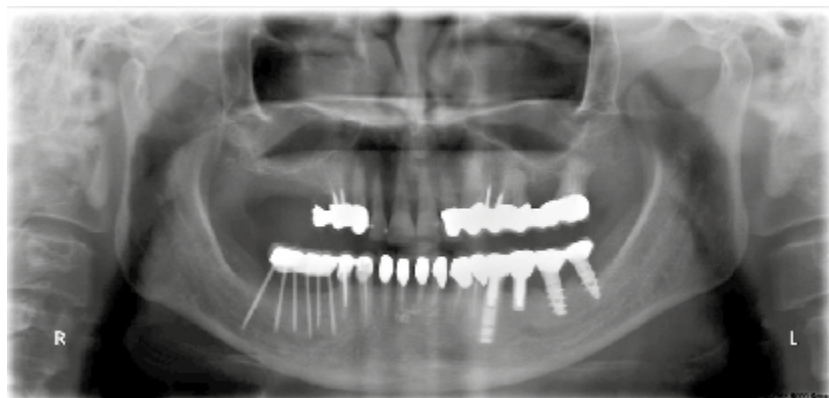
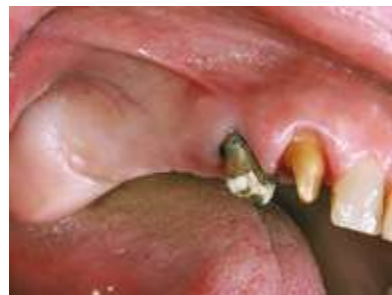

Fig. 12

Caso clinico 2:  
Situazione della cresta  
edentula.

Fig. 12



un mucotomo circolare che consente, mediante delicata ma decisa percussione, di ottenere sia l'incisione della superficie ossea sia la frattura parcel-lare del pavimento sinusale senza dover ricorrere, data l'esiguità dello spessore osseo, agli scalpelli da mini-rialzo (figg. 13 e 14).

Il raggiungimento controllato del pavimento del seno e la sua frattura sono caratterizzati, come sempre, da un cambiamento sia della resistenza al tragitto dello strumento sia del suono che si produce con la percussione tramite il martello chirurgico. Vengono, quindi, inseriti gli impianti (fig. 15), non senza prima

IOS 49 1-14

## ARTICLE IN PRESS

Chirurgia orale

Fig. 13

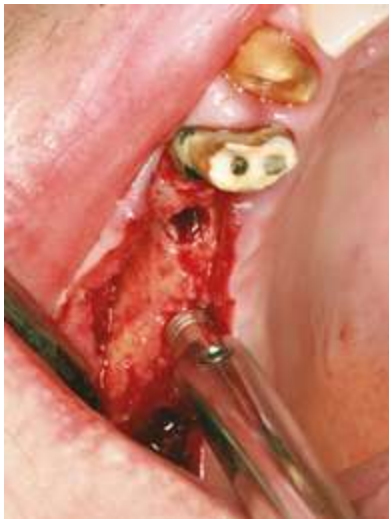

Fig. 14

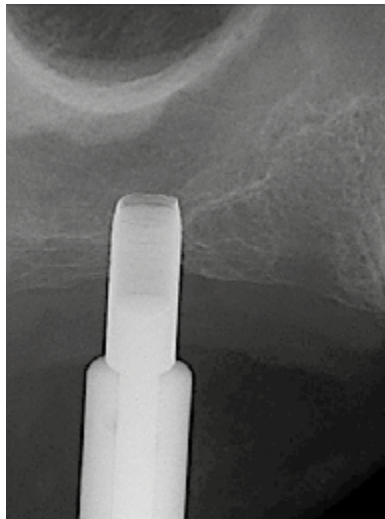


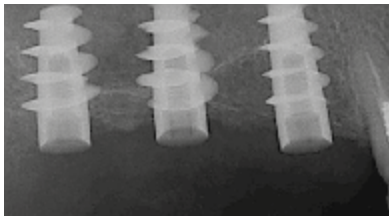
Fig. 13

Caso clinico 2: Utilizzo del mucotomo.

Fig. 14

Caso clinico 2: Rx endorale con mucotomo.

Fig. 15



aver fatto eseguire una delicata manovra di Valsalva per verificare l'integrità della membrana. L'applicazione implantare viene come sempre preceduta dall'inserimento di materiale collagene frammito a granuli di tessuto osseo deantigenato che, come già precedentemente detto, forniscono un appoggio "morbido" alla membrana del seno sollevata ed evidenziano, radiograficamente, l'entità del rialzo ottenuto (fig. 16).

Fig. 15

Caso clinico 2: Rx endorale impianti 1.5-1.6-1.7.

Fig. 16

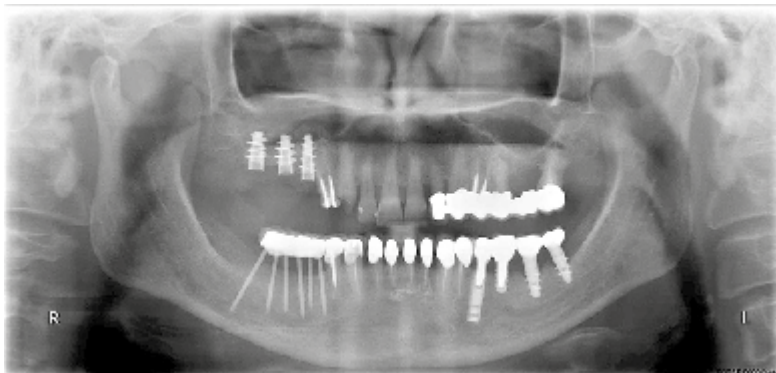


Fig. 16

Caso clinico 2: Rx ortopantomica di controllo.

IOS 49 1-14

## ARTICLE IN PRESS

F. Vannini, M. Nardone

Nell'ortopantomografia, infatti, utilizzando come termine di riferimento la ben visibile linea delimitante il pavimento del seno, è apprezzabile lo spostamento verso l'alto dello stesso con conseguente incremento in altezza della cresta. Tale modificazione anatomica ha consentito, sia pure con un modesto spessore osseo di partenza, il posizionamento di tre impianti di lunghezza e diametro adeguati per poter procedere a una soddisfacente protesizzazione del quadrante edentulo (fig. 17).

**Terzo caso clinico**

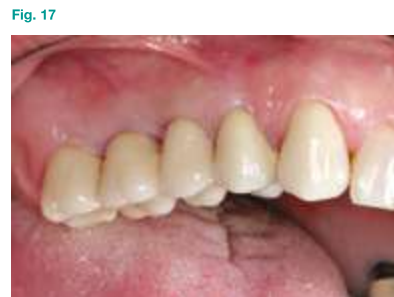Paziente di sesso maschile, di 48 anni, con edentulia superiore dei settori posteriori (figg. 18 e 19). In un primo tempo, su richiesta del paziente, si provvede al posizionamento di impianti solo nella zona di 1.4 e

1.5, tramite contestuale rialzo del pavimento del seno mascellare con la tecnica del mini-rialzo modificata secondo il nostro protocollo chirurgico. Si utilizzano due viti di lunghezza 16 mm e diametro 4 mm per l'1.4 e 14 mm e diametro 5 mm per il 15 (fig. 20).

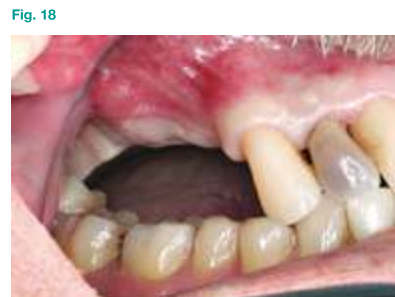Dopo circa 6 mesi e dopo aver caricato gli impianti con dei provvisori, vengono posizionati gli altri due impianti in zona 1.6 e 1.7. Anche in questo caso l'esiguità dello spessore osseo permette che con il mucotomo sia possibile eseguire sia l'incisione della cresta che la frattura del pavimento del seno: queste due corticali sono, infatti, a stretto contatto nella zona interessata dall'applicazione del mucotomo (fig. 21).

Come da protocollo operativo viene inserito del materiale collagene e tessuto osseo deantigenato nei fori praticati e vengono, infine, inseriti un

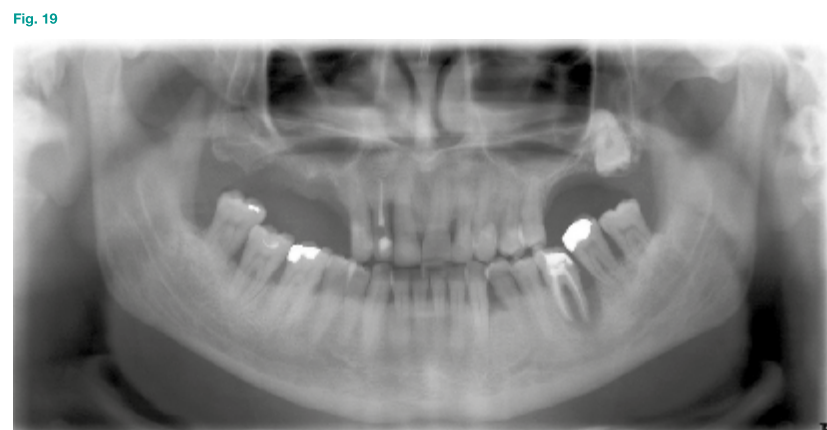**Fig. 17**  
Caso clinico 2: Elementi protesici definitivi.



**Fig. 18**  
Caso clinico 3: Edentulia mascellare superiore destra.



**Fig. 19**  
Caso clinico 3:  
Rx ortopantomica  
alla prima visita.



IOS 49 1-14

ARTICLE IN PRESS

Chirurgia orale

Fig. 20

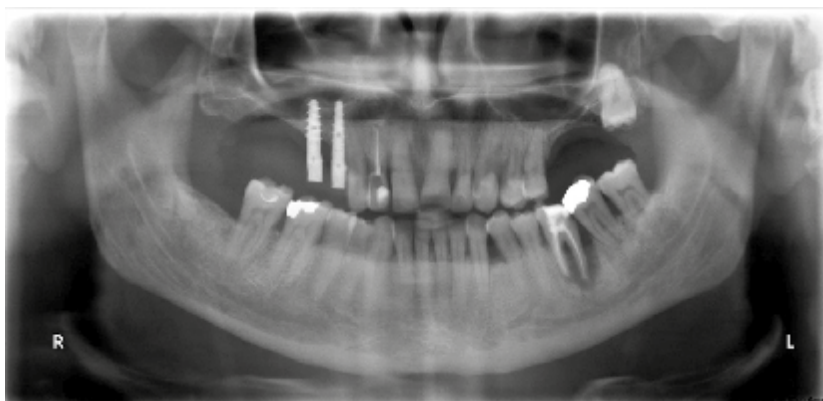


Fig. 20

Caso clinico 3:  
Impianti 1.4 e 1.5.

Fig. 21

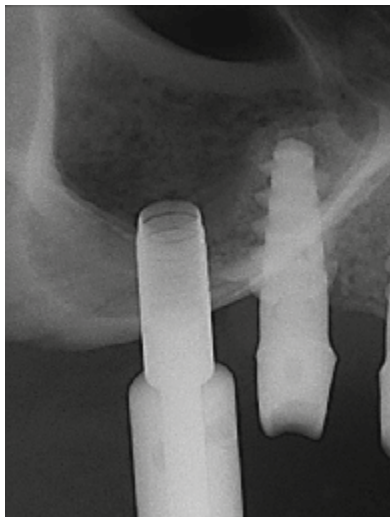


Fig. 21

Caso clinico 3:  
Rx endorale  
con mucotomo.

A distanza di 5 mesi dall'intervento, si procede alla riabilitazione protesica definitiva in metal-ceramica di tutto il settore (figg. 23 e 24).

### Conclusioni

I casi clinici presentati mettono in evidenza come, nel rialzo del seno mascellare per via crestale, l'utilizzo del mucotomo consenta la riabilitazione di situazioni anatomiche con osso verticale disponibile inferiore a 5 mm. L'uso del mucotomo permette, infatti, di evitare l'utilizzo di frese, che risulta comunque impraticabile in presenza di spessori ossei molto modesti, offrendo contemporaneamente la possibilità di non perdere, nella procedura chirurgica, la benché minima quantità di tessuto osseo. La presenza eventuale di stop di profondità permette, inoltre, di operare in sicurezza specie per operatori non particolarmente esperti.

Con tale strumento, infine, è possibile praticare fori nella corticale molto precisi tanto da poter offrire stabilità anche al solo collo implantare, vantaggio questo che si somma a quello di usare impianti con spire di particolare ampiezza che consentono un maggior ingaggio osseo.

Per sfruttare appieno questi vantaggi è importante che l'impianto venga inserito con procedura auto-maschiante e in maniera decisa, senza movimenti di va e vieni o di lateralità, per non perdere la

impianto di diametro 6 mm e lunghezza 10 mm a livello dell'1.6 e un impianto di diametro 6 mm e lunghezza 12 a livello dell'1.7.

Grazie alla precisione del foro praticato con il mucotomo, che risulta essere sottodimensionato rispetto al collo dell'impianto, la stabilità primaria degli impianti inseriti è garantita anche in presenza di una corticale molto esile (fig. 22).

ITALIAN ORAL SURGERY 6/2010 | 11

Per citare quest'articolo : Vannini F, Nardone M. Utilizzo del mucotomo per il rialzo del seno mascellare con approccio crestale: report preliminare. Ital Oral Surg (2010), doi:10.1016/j.ios.2010.10.001



IOS 49 1-14

## ARTICLE IN PRESS

F. Vannini, M. Nardone

Fig. 22

Caso clinico 3:  
Rx ortopantomica  
con impianti 1.6 e 1.7.

Fig. 22

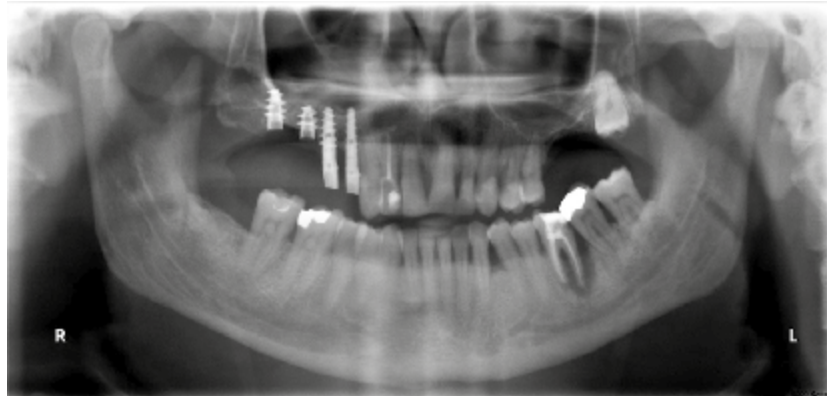
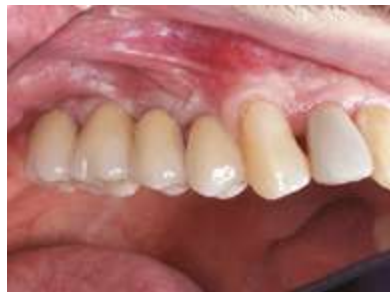

Fig. 23

Caso clinico 3: Elementi  
protetici definitivi.

Fig. 23



massima frizione e, quindi, la massima stabilità primaria raggiungibile [31].

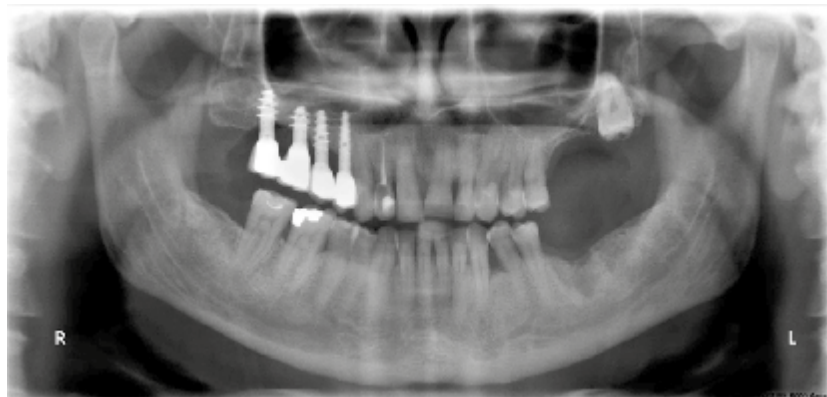
È, altresì, importante che l'applicazione degli impianti venga preceduta dall'inserimento, nel foro praticato, di materiale collagene al fine di rendere meno pericoloso, per l'integrità della membrana, il suo sollevamento; questo si completerà, con la spinta esercitata anche dall'impianto, se si ha l'accortezza di avvertirlo molto lentamente.

È da sottolineare l'ampiezza dell'aumento di spessore osseo ottenibile con questa tecnica, del tutto paragonabile a quello raggiunto con il grande rialzo

Fig. 24

Caso clinico 3:  
Rx ortopantomica  
di controllo.

Fig. 24





IOS 49 1-14

## ARTICLE IN PRESS

Chirurgia orale

del pavimento del seno praticato con accesso vestibolare, come si è evidenziato con le ortopantomografie presentate.

La procedura proposta comporta una considerevole riduzione della morbilità rispetto alle situazioni in cui si utilizza l'approccio vestibolare al seno; si riducono drasticamente, infatti, le complicanze che potrebbero insorgere a seguito di un'osteotomia laterale, indubbiamente più invasiva, come pure si riducono i tempi di intervento nonché lo stress sia per l'operatore sia per il paziente.

Tutto quanto sopra descritto è ben in linea con l'attuale tendenza chirurgica di affidarsi a tecniche il meno invasive possibili. L'approccio crestale infatti, anche in condizioni di cospicui riassorbimenti del mascellare posteriore, minimizza l'edema e il dolore post-intervento, comporta una drastica diminuzione della morbilità postoperatoria e al contempo promuove una veloce e ottimale guarigione.

### Conflitto di interessi

Gli autori dichiarano di non aver nessun conflitto di interessi.

### Finanziamento allo studio

Gli autori dichiarano di non aver ricevuto finanziamenti istituzionali per il presente studio.

### Bibliografia

1. Brånemark PI, Adell R, Albrektsson T, Lekholm U, Lindström J, Rockler B. An experimental and clinic study of osseointegrated implants penetrating the nasal cavity and maxillary sinus. *J Oral Maxillofac Surg* 1984;42:497-505.
2. Boyne P, James R. Grafting of the maxillary floor with autogenous bone and marrow. *J Oral Surg* 1980;38:613-6.
3. Reiser GM, Rabinovitz Z, Bruno J, Damoulis PD, Griffin TJ. Evaluation of maxillary sinus membrane response following elevation with the crestal osteotome technique in human cadavers. *Int J Oral Maxillofac Implants* 2001;16:833-40.
4. Rossi A, Maccarini L, Pozzobon L, Chiapasco M. Il rialzo del seno a scopo implantologico. *Dental Cadmos* 2007;5: I-XLIII.
5. Smiler DG, Johnson PW, Lozada JL, Misch C, Rosenlicht JL, Tatum Jr OH, et al. Sinus lift grafts and endosseous implants-treatment of atrophic posterior maxilla. *Dent Clin North Am* 1992;36:151-86.
6. Coatoam GW, Krieger JT. A four-year study examining the results of indirect sinus augmentation procedures. *J Oral Implantol* 1997;23:117-27.
7. Fugazzotto PA, Vlassis J. Long-term success of sinus augmentation using various surgical approaches and grafting materials. *Int J Oral Maxillofac Implants* 1998;13:52-8.
8. Rossi A, Chiapasco M. Il rialzo del seno mascellare a scopo implantologico: classificazione del deficit osseo, tecniche di trattamento e biomateriali impiegabili. *Implantologia* 2004;1:41-57.
9. Small SA, Zinner ID, Panno FV, Shapiro HJ, Stein JL. Augmenting the maxillary sinus for implants: report of 27 patients. *Int J Oral Maxillofac Implants* 1993;8:523-8.
10. Wheeler SL, Holmes FE, Calhoun C. Six year clinical and histologic study of sinus-lift grafts. *Int J Oral Maxillofac Implants* 1996;11:26-34.
11. Jensen J, Simonsen EK, Sinet-Pederson S. Reconstruction of severely resorbed maxilla with bone grafting and osseointegrated implants. *J Oral Maxillofac Surg* 1990;48:27-32.
12. Raghoebar GM, Brouwer ThJ, Reintsema H, Van Cort RP. Augmentation of the maxillary sinus floor with autogenous bone for the placement of endosseous implants: a preliminary report. *J Oral Maxillofac Surg* 1993;51:1198-203.
13. Toffler M. Minimally invasive sinus floor elevation procedures for simultaneous and staged implant placement. *N Y State Dent J* 2004;70:38-44.
14. Kang T. Sinus elevation using a staged osteotome technique for site development prior to implant placement in sites with less than 5mm of native bone: a case report. *Int J Periodontics Restorative Dent* 2008;28:73-81.
15. Horowitz RA. The use of osteotomes for sinus augmentation at the time of implant placement. *Compend Contin Educ Dent* 1997;18:441-7.
16. Summers RB. The osteotome technique: Part 3 - Less invasive methods of elevating the sinus floor. *Compendium* 1994;15:698.
17. Summers RB. A new concept in maxillary implant surgery: the osteotome technique. *Compendium* 1994;15:152.
18. Corrente G, Abundo R, Perelli M. Rialzo del seno mascellare per via crestale mediante osteotomi: tecnica

ITALIAN ORAL SURGERY 6/2010 | 13

Per citare quest'articolo : Vannini F, Nardone M. Utilizzo del mucotomo per il rialzo del seno mascellare con approccio crestale: report preliminare. *Ital Oral Surg* (2010), doi:10.1016/j.ios.2010.10.001

F. Vannini, M. Nardone

chirurgica. Associazione Amici di Brugg. Odontoiatria 2005, marzo. Milano: RC Libri Editore; 2003.

19. Draener GF, Eisenmenger W. A new technique for the transcrestal sinus floor elevation and alveolar ridge augmentation with press-fit bone cylinders: a technical note. *J Craniomaxillofac Surg* 2007;35:201-6.

20. Trombelli L, Minenna P, Franceschetti G, Minenna L, Farina R. Transcrestal sinus floor elevation with a minimally invasive technique. *J Periodontol* 2010;81(1):158-66.

21. Cho SC, Wallace SS, Froum SJ, Tarnow DP. Influence of anatomy on Schneiderian membrane perforations during sinus elevation surgery: three dimensional analysis. *Pract Proced Aesthet Dent* 2001;13:160-3.

22. Zitzmann NU, Schärer P. Sinus elevation procedures in the resorbed posterior maxilla. Comparison of the crestal and lateral approaches. *Oral SurgOral Med Oral Pathol Oral Radiol Endod* 1998;85:8-17.

23. Regev E, Smith RA, Perrott DH, Progel MA. Maxillary sinus complications related endosseous implants. *Int J Oral Maxillofac Implants* 1995;10:613-6.

24. Barone A, Santini S, Sbordone L, Crespi R, Covani U. A clinical study of the outcomes and complications associated with maxillary sinus augmentation. *Int J Oral Maxillofac Implants* 2006;21:81-5.

25. Monteverdi R, Gianni AB, Baj A. Complicanze post-operative immediate e a distanza del sinus lift.

In: Testori T, Weinstein R, Wallace S, editors. *La chirurgia del seno mascellare e le alternative terapeutiche*. Viterbo: Edizioni Acme; 2006.

26. Sholomi B, Horowitz I, Kahn A, Dobriyan A, Chaushu G. The effect of sinus membrane perforation and repair with lambone on the outcome of maxillary sinus floor augmentation: a radiographic assessment. *Int J Oral Maxillofac Implants* 2004;19:559-62.

27. Becker ST, Terheyden H, Steinriede A, Behrens E, Springer I, Wiltfang J. Prospective observation of 41 perforations of Schneiderian membrane during sinus floor elevation. *Clin Oral Implants Res* 2008;19:1285-9.

28. Rosano G, Taschieri S, Gaudy JF, Del Fabbro M. Maxillary sinus vascularization: a cadaveric study. *J Craniofac Surg* 2009;20:940-3.

29. D'Amato S, Borriello C, Tartaro G, Itrò A. Maxillary sinus surgical lift. Summers' technique versus lateral surgical approach. *Minerva Stomat* 2000;49:369-81.

30. Cacaci C. Materiali sostitutivi dell'osso per indicazioni implantologiche. *Team Work Clinic* 2007;3:74-81.

31. O'Sullivan D, Sennerby L, Meredith N. Measurements comparing the initial stability of five designs dental implants: a human cadaver study. *Clin Implant Dent Relat Res* 2000;2:85-92.

Loris Prosper\*, Marco Cappello\*\*, Carlo Alberto Cortella\*\*\*,  
Tonino D'Alicandro\*\*\*\*, Enrico Felice Gherlone\*\*\*\*\*

## Chiave dinamometrica digitale: applicazioni in impianto-protesi

Obiettivo di questo studio è quello di presentare l'utilizzo di un'innovativa chiave dinamometrica digitale in ambito impianto-protetico.

Tale sistema computerizzato risulta estremamente utile durante la fase chirurgica di inserimento degli impianti nell'osso e in particolar modo nelle riabilitazioni a carico immediato: la visualizzazione e il controllo diretto al computer del torque di inserimento impiantare ci permettono di definire con precisione la stabilità primaria dell'impianto e procedere all'eventuale carico protesico immediato.

L'innovativo cricchetto digitale risulta particolarmente utile anche durante la fase protesica per programmare e controllare il torque di serraggio delle viti relative alla componentistica protesica ed evitarne lo svitamento o la frattura.

La memorizzazione e la raccolta dei dati registrati dal sistema permette di creare una banca dati indispensabile a livello clinico e utile anche come documentazione medico-legale.

**Parole chiave:** Chiave dinamometrica digitale, Carico immediato, Stabilità primaria.

### INTRODUZIONE

La riabilitazione protesica di una mandibola completamente edentula, mediante la realizzazione di una overdenture ancorata a impianti inseriti nella zona inter-foraminale, rappresenta una tecnica ormai consolidata da diversi anni e largamente approvata in Letteratura<sup>1-6</sup>.

Il presupposto di Brånemark per il quale il processo di osteointegrazione richiede l'assenza di carico masticatorio dai 3 ai 6 mesi è stato riconsiderato all'interno di precisi protocolli impianto-protetici.

Esistono infatti numerosi studi prospettici che confermano la possibilità di riabilitare una mandibola completamente edentula con l'inserimento di impianti endosseï caricati immediatamente<sup>10-24</sup>.

\* Medico chirurgo, odontoiatra, Responsabile Riparto di Odontoiatria Estetica, Dipartimento di Odontoiatria San Raffaele, Milano; titolare dell'Insegnamento di Materiali Dentari per il C.I.D., Ateneo Vita-Salute San Raffaele Milano.

\*\* Odontoiatra libero professionista, collaboratore Dipartimento di Odontoiatria, San Raffaele, Milano.

\*\*\* Medico chirurgo, odontoiatra, Titolare dell'insegnamento di Parodontologia per il C.I.D., Ateneo Vita-Salute San Raffaele, Milano.

\*\*\*\* Odontotecnico, Francavilla Al Mare (PC).

\*\*\*\*\* Direttore Dipartimento di Odontoiatria, Ospedale San Raffaele, Milano; Direttore C.I.D., Ateneo Vita-Salute San Raffaele, Milano.

#### Indirizzo per la corrispondenza:

Marco Cappello  
Via Maspero, 5 - 21100 Varese  
Tel. 0332766000  
E-mail: mmcappello@yahoo.it

## IMPLANTOLOGIA

I protocolli protesici prevedono, in breve tempo, la realizzazione di protesi fisse o protesi rimovibili con ritenzioni a barra.

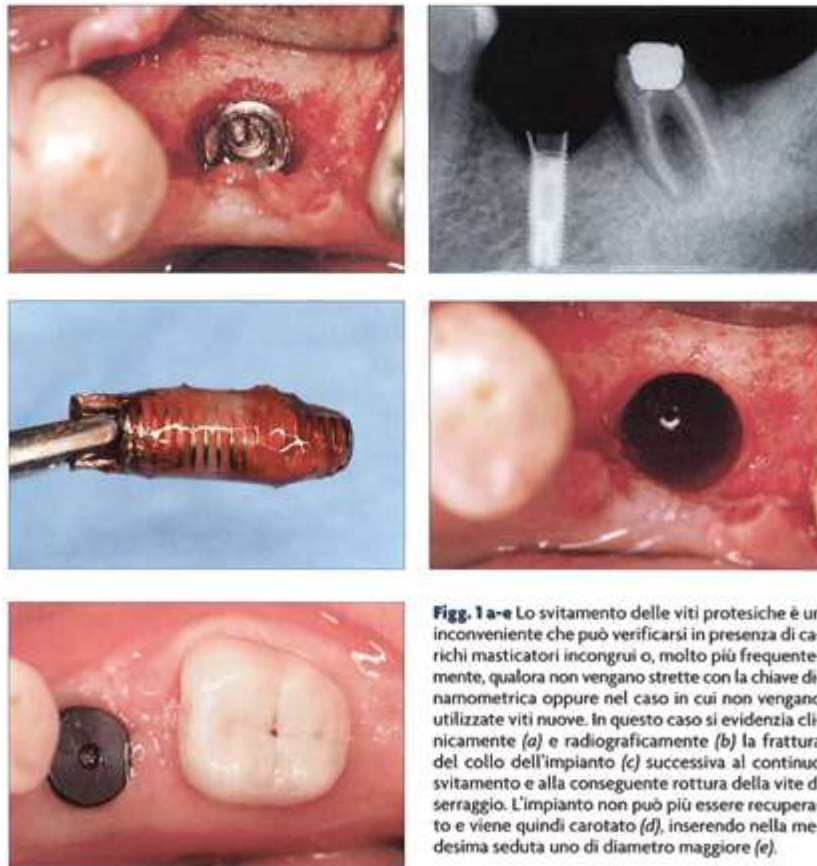
Lo scopo di questo articolo è la presentazione in ambito clinico di una chiave dinamometrica digitale. Attraverso il suo utilizzo è possibile controllare il torque di inserimento degli impianti nella fase chirurgica e il serraggio dei monconi nella successiva fase protesica.

Il controllo del torque di inserimento permette di riferire la stabilità primaria ottimale necessaria per il carico immediato a un valore numerico predeterminato, riducendo al minimo lo stress sulle pareti ossee

dell'alveolo implantare e favorendo quindi il processo di osteointegrazione.

Tale sistema di serraggio risulta essere anche indispensabile nella fase di avvitamento della componentistica protesica, fase molto delicata, causa spesso di rotture di viti e svitamento dei monconi. Tutto ciò crea disagio al medico e al paziente oltre che a influire negativamente sul successo a lungo termine della riabilitazione implanto-protesica (Figg. 1a-e).

Il sistema dinamometrico computer assistito per il controllo del torque di inserimento di impianti, denominato "QuattroTi DT" (Precision Digital Dental Torque, QuattroTi - Cislago), è inserito in un protocollo



**Figg. 1 a-e** Lo svitamento delle viti protesiche è un inconveniente che può verificarsi in presenza di carichi masticatori incongrui o, molto più frequentemente, qualora non vengano strette con la chiave dinamometrica oppure nel caso in cui non vengano utilizzate viti nuove. In questo caso si evidenzia clinicamente (a) e radiograficamente (b) la frattura del collo dell'impianto (c) successiva al continuo svitamento e alla conseguente rottura della vite di serraggio. L'impianto non può più essere recuperato e viene quindi carotato (d), inserendo nella medesima seduta uno di diametro maggiore (e).



## Chiave dinamometrica digitale: applicazioni in impianto-protesi

impianto-protetico illustrato nel caso clinico qui di seguito riportato.

### MATERIALI E METODI

Il caso clinico trattato riguarda un paziente di sesso maschile, di anni 74, non fumatore, in buone condizioni di salute generale, portatore di una protesi parziale rimovibile con ganci a livello dell'arcata inferiore e di una protesi totale superiore ancorata a ritenzioni sferiche (Ball-attachment).

Il paziente, lamentando l'inefficienza funzionale di tali riabilitazioni, viene sottoposto a una visita accurata con raccolta dei dati anamnestici e a una valutazione delle indagini radiologiche specifiche (Ortopantomografia e Tac mandibolare) (Fig. 2).

Viene eseguito uno "studio del caso" attraverso la documentazione fotografica intra- ed extra-orale, il rilievo delle impronte delle due arcate in materiale idrocolloide e la registrazione della relazione centrica con valli in cera. Il conseguente montaggio in articolatore e la documentazione raccolta permettono al clinico di impostare il piano di trattamento.

Il progetto protesico prevede per l'arcata mandibolare la realizzazione di una protesi rimovibile con chavistelli ancorata a una barra fresata a due gradi e per il mascellare superiore, il rifacimento della protesi totale ancorata a ritenzioni sferiche. La barra viene realizzata caricando immediatamente quattro impianti inseriti in regione inter-foraminale.

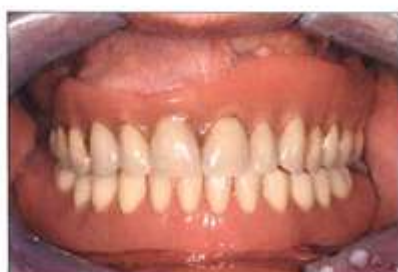La fase chirurgica prevede, inizialmente, l'esecuzione di un'incisione crestale e il

sollevamento di un lembo muco-periosteo per scheletrizzare la regione mediana mandibolare. Una volta isolati bilateralmente i forami mentonieri si procede all'inserimento di 4 impianti Winsix Kt (Winsix® Implant system, Biosafin, Ancona) da 3,8 mm di diametro e 11 mm di lunghezza secondo il protocollo fornito dalla casa produttrice. Applicando l'apposito terminale compatibile della chiave dinamometrica digitale, è possibile completare la fase di avvitamento manuale dell'impianto e visualizzare direttamente a monitor il grafico inerente il torque di inserimento implantare. Ciò fornisce un immediato riscontro sulla tenuta dell'impianto all'interno dell'alveolo chirurgico al momento del suo inserimento nell'osso e di conseguenza la valutazione della possibile protesizzazione immediata provvisoria (Figg. 3a,b).

Dopo aver fissato i transfert da impronta, il lembo è stato suturato. I transfert sono stati inoltre solidarizzati tra loro con della resina Pattern (GC, Giappone) (Fig. 4).

Il rilievo della successiva impronta di posizione degli impianti avviene così senza distorsioni e si procede alla realizzazione di una barra provvisoria preconfezionata tipo Dolder in titanio P.B.F. (Protempory-Bridge Faster, Winsix®) (Fig. 5).

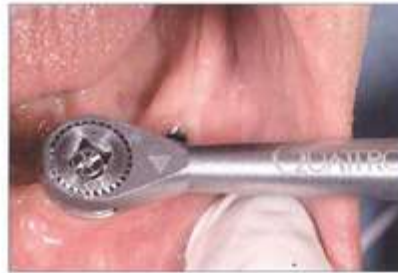Questa metodica utilizza monconi conici specifici avvitati agli impianti (Free Tense, Winsix®) che rappresentano la base sul cui, poche ore dopo, viene fissata la barra provvisoria fresata. I monconi conici utilizzati nella fase protesica provvisoria sono gli stessi su cui verrà posizionata la barra de-



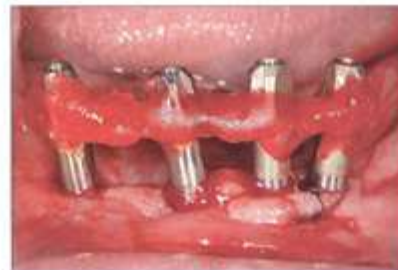**Fig. 2** Caso clinico iniziale: il paziente lamenta l'inefficienza funzionale delle vecchie protesi, ormai non più in grado di garantire un'adeguata ritenzione e stabilità, statica e dinamica. La diagnosi clinica e radiologica permette di definire un piano di trattamento che prevede il rifacimento della protesi totale superiore e la realizzazione di una protesi inferiore ancorata con chavistelli a una barra in titanio con 4 impianti inseriti in regione intra-foraminale.



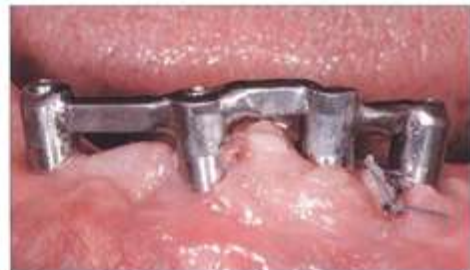## IMPLANTOLOGIA



**Fig. 3** L'utilizzo della chiave dinamometrica digitale è indicato fin dalla prima fase chirurgica di inserimento degli impianti. Applicando al cricchetto il terminale dedicato in funzione della sistematica implantare adottata è possibile valutare con precisione il torque di inserimento degli impianti. La visualizzazione al computer del grafico inerente i valori di torque dei singoli impianti ci permette di impostare la riabilitazione protesica più opportuna per il singolo caso clinico, consentendo anche un eventuale carico protesico immediato.



**Fig. 4** Dopo aver posizionato gli impianti nella regione intra-foraminale, vengono avvitati i transfer e solidarizzati con della resina Pattern (GC), in modo tale da rilevare un'impronta di posizione precisa; l'odontotecnico provvederà quindi a realizzare una barra provvisoria in titanio che verrà avvitata in bocca al paziente solo poche ore dopo l'intervento chirurgico.



**Fig. 5** La barra provvisoria in titanio, viene realizzata in laboratorio saldando delle barrette preformate in titanio a cilindri rotazionali avvitati agli analoghi; solo dopo poche ore di lavorazione la barra viene fissata ai monconi conici nella bocca del paziente e su di essa verrà ribasata con la resina a freddo la protesi provvisoria del paziente opportunamente modificata.

finitiva: ciò comporta un indubbio vantaggio per quanto riguarda la guarigione e la maturazione dei tessuti mucosi peri-implantari, venendosi a formare un'ampiezza biologica "stabile" e senza dover successivamente modificare il profilo di emergenza della struttura protesica (Fig. 6)<sup>25-29</sup>.

Come protesi provvisoria è stata riadattata quella del paziente: una volta svuotata a livello del settore anteriore è stata ribasata immediatamente con una resina per ribasatura a freddo (Sofreliner - Tokuyama, Giappone).

Al termine del trattamento sono state eseguite radiografie endorali per verificare il corretto adattamento della barra provvisoria sui monconi conici (Fig. 7).

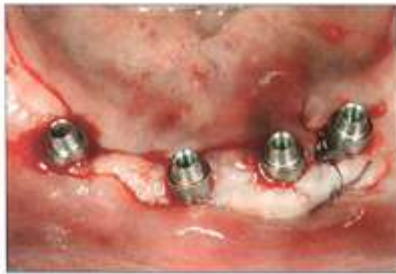Il paziente viene controllato periodicamente, a distanza di uno, tre, sette giorni dall'intervento, una volta alla settimana per il

primo mese e ogni due settimane nei due mesi successivi, per verificare che non subentrino complicanze di ordine chirurgico o protesico. Vengono fornite inoltre le norme igieniche per garantire un corretto mantenimento della protesi e della salute implantare.


Si attendono tre mesi per favorire il completamento del processo di osteointegrazione e la completa guarigione dei tessuti molli peri-implantari, quindi si procede alla realizzazione dei manufatti definitivi.

Per la costruzione delle protesi definitive sono state rilevate due impronte di precisione in poliuretano (Impregum, 3M ESPE, U.S.A.) dell'arcata superiore e dell'arcata inferiore con i transfer solidarizzati con la resina Pattern (Figg. 8a-c). L'odontotecnico provvede quindi a costruire delle basi in

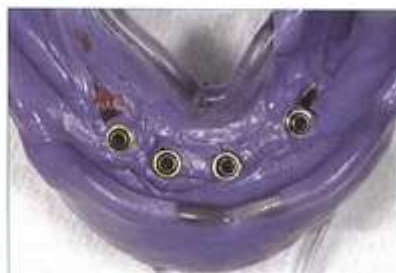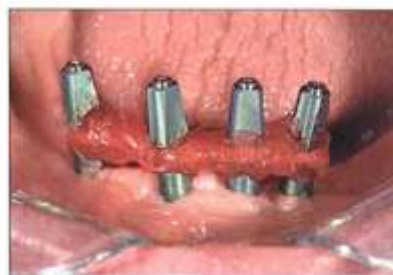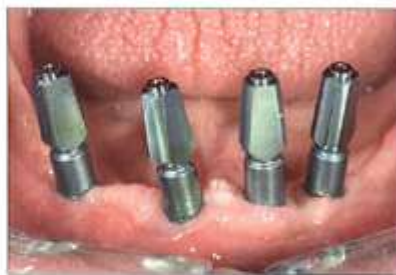## Chiave dinamometrica digitale: applicazioni in impianto-protesi



**Fig. 6** La metodica adoperata prevede l'utilizzo di specifici monconi conici avvitati agli impianti ("Free-tense", Winsix): l'utilizzo degli stessi monconi conici fin dalla fase provvisoria favorisce una migliore guarigione e maturazione dei tessuti molli peri-implanetari ed evita inoltre di dover modificare successivamente il profilo d'emergenza della struttura protesica definitiva.



**Fig. 7** La radiografia post-operatoria evidenzia la barra provvisoria avvitata agli impianti. Anche per la soluzione protesica a carico immediato si è deciso di utilizzare monconi conici sottodimensionati rispetto al diametro del collo dell'impianto, perché il nostro protocollo protesico prevede l'applicazione della metodica "platform switching" anche sulle protesi a barra.



**Figg. 8 a-c** Trascorsi 3 mesi dall'intervento per garantire un processo di osteointegrazione ottimale degli impianti, viene rilevata l'impronta definitiva: vengono avvitati i transfer (a) e, per impedire eventuali movimenti e rotazioni degli stessi durante la rimozione dell'impronta dal cavo orale, vengono solidarizzati con della resina Pattern (GC) (b); l'utilizzo di un materiale da impronta estremamente preciso e con minima deformazione elastica (Impregum, 3M ESPE) (c), associato alla resina per legare i transfer, garantisce una precisione ottimale per le successive fasi di laboratorio e cliniche (utile ricordare che l'impronta in polttere deve essere colata dopo 48 ore per permettere al materiale di recuperare la deformazione generata).

resina con valli in cera per registrare l'occlusione in relazione centrica.

Per rilevare i rapporti intermascellari ed eseguire il montaggio in articolatore è stata utilizzata la metodica di Gerber, che richiede l'utilizzo di specifici strumenti quali l'arco facciale dinamico.

La tecnica di Gerber prevede due fasi: una extra-orale e una intra-orale. Nella prima fase i rapporti spaziali tra la mandibola e il cranio vengono rilevati insieme alla registrazione grafica dei tragitti condilari sul piano sagittale, mediante l'ausilio di un asiografo (Figg. 9a-c).

## IMPLANTOLOGIA

La fase intraorale prevede invece la registrazione grafica dei movimenti mandibolari sul piano orizzontale mediante il rilevamento dell'arco gotico (Figg. 10a,b).

Le informazioni così ricavate permettono all'odontotecnico di eseguire il montaggio degli elementi dentali secondo i canoni estetici e funzionali di tale metodica anche personalizzandola.

Nel caso specifico sono state utilizzate delle faccette in composito per il settore anteriore (Novo.lign - Bredent Medical GmbH, Germania) ed elementi in resina composita nei settori posteriori (Condyloform - Candulor, Germania).


La prima prova è stata eseguita per la protesi totale superiore montando i denti del solo gruppo frontale per valutarne l'estetica e la fonetica.

Successivamente è stato completato, su entrambe le basi in resina (arcata superiore e inferiore), il montaggio dei denti, fissati in cera per eseguire tutte le eventuali modifi-

che estetiche, fonetiche e funzionali da apportare alle due nuove protesi (Fig. 11).

Utilizzando il sistema CAD/CAM Procebra (Nobel Biocare, Goteborg, Svezia) è stata realizzata la barra in titanio definitiva fresata a due gradi. Durante la fase di realizzazione il tecnico controlla in modo accurato l'eventuale presenza di tensioni nell'avvitamento della barra ai monconi conici implantari (prova di Sheffield), dal momento che la barra deve essere del tutto passiva, onde evitare tensioni a carico degli impianti (spostamenti sul piano verticale e orizzontale) che porterebbero a un sovraccarico funzionale con conseguente maggiore rischio di perdita dell'impianto<sup>20-18</sup>.

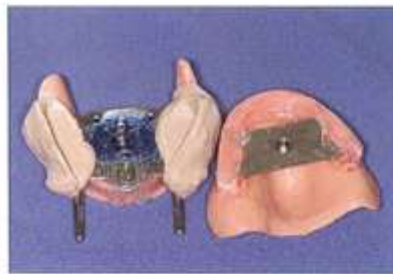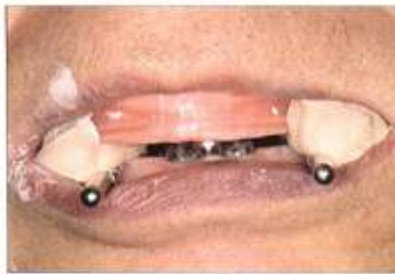Il test di Sheffield consiste nell'avvitamento di una sola vite all'estremità della struttura: se questa non subisce alcun movimento, vuol dire che la struttura è passiva, intimamente e simultaneamente in contatto con tutti gli altri impianti di supporto, in caso contrario la protesi subisce un ef-



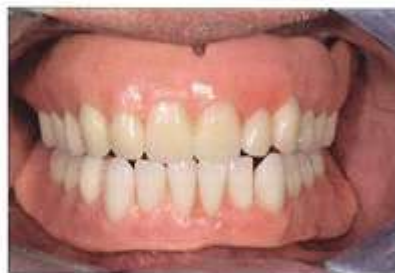**Figg. 9 a-c** La registrazione extraorale dei movimenti condilari viene effettuata con l'ausilio dell'assigrafo (a); questo dispositivo ci permette di registrare graficamente (b) i tragitti condilari e i rapporti tra mandibola e cranio sul piano sagittale, individuando l'asse cerniera individuale del paziente (c). Questo permetterà al tecnico di impostare correttamente l'articolatore a valori semi-individuali: il movimento di protrusione stabilirà la forma e l'angolo dell'eminenza articolare, quello di mediotrusione permetterà invece di definire il movimento e l'angolo di Bennet, ovvero la forma e l'entità dello spostamento del condilo lavorante verso la linea mediana durante i movimenti di lateralità. La valutazione della dinamica mandibolare su piano sagittale evidenzierà anche eventuali asimmetrie tra il lato destro e quello sinistro.



## Chiave dinamometrica digitale: applicazioni in implanto-protesi



**Fig. 10 a,b** La metodica di Gerber prevede una fase intraorale in cui vengono registrati i movimenti mandibolari sul piano orizzontale mediante il rilevamento dell'arco gotico e l'individuazione del rapporto intermascellare sullo stesso piano (a). Si realizzano placche di registrazione in resina con valli di occlusione in cera, con un pin metallico per l'arcata superiore e una base liscia per quella inferiore. Vengono fatti eseguire al paziente movimenti di lateralità destra e sinistra e di protrusione, che rimarranno impressi sulla placchetta metallica inferiore colorata (arco gotico) (b). La ricerca della relazione centrica e la registrazione dei movimenti mandibolari individuali con l'arco facciale dinamico consentono al tecnico di ricreare con le protesi montate in articolatore un'occlusione statica e dinamica ottimale.



**Fig. 11** Dopo aver eseguito la prova del montaggio dei denti anteriori, viene ultimato il montaggio di tutti gli elementi in resina della protesi superiore e inferiore per ricercare la posizione ideale spaziale ed occlusale. I denti antagonisti possono essere montati ricercando un rapporto di occlusione di tipo "dente a due denti" o "dente a dente", con contatti stabilizzanti cuspidi-fossa. I contatti masticatori vengono provati prima in articolatore, eseguendo tutti i contatti funzionali quali la centrica, la lateralità destra e sinistra, la protrusiva ed eliminando eventuali contatti interferenti con un molaggio selettivo. La prova intraorale delle protesi sarà incentrata sulla valutazione della statica e dei parametri estetici e fonetici.

fetto "molla" alzandosi nella parte opposta a quella dove è stata avvitata la vite.

Sia la barra in titanio, sia i monconi conici di connessione sono stati avvitati alle relative strutture con una forza pari a 35 Newton. Proprio in questa fase è stato particolarmente utile e importante il monitoraggio del serraggio della componentistica prote-

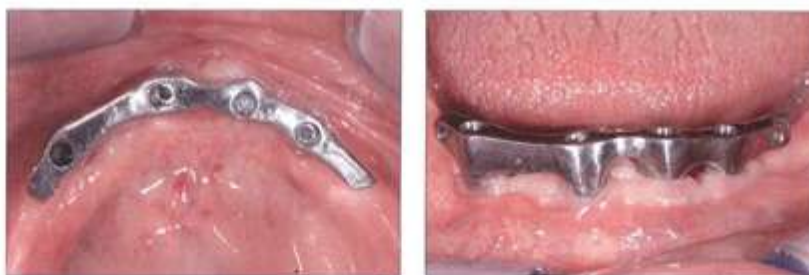

**Fig. 12** Per garantire la stabilità della protesi verso le forze dislocanti che tenderebbero a farla ribaltare verso l'avanti, sono stati inseriti dei chiavistelli che si fissano nei settori posteriori della meso-struttura e della barra sottostante. L'utilizzo di tali dispositivi con dei "bottoni a scatto" vestibolari, permette al paziente una facile rimozione della protesi per consentire le adeguate manovre di igiene orale e di pulizia della protesi stessa.

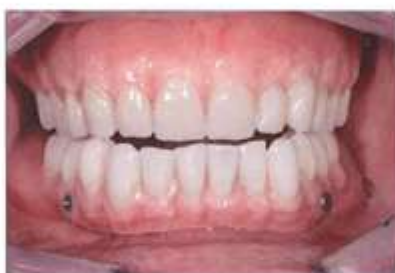sica mediante la chiave dinamometrica computerizzata Quattro TIDT.

La ritenzione della protesi inferiore è garantita da specifici chiavistelli con bottone a scatto (Bredent) e da due "spinette", inserite sulla barra. I chiavistelli hanno la funzione di bloccare la mesostruttura protesica alla barra in corrispondenza dei settori po-

## IMPLANTOLOGIA



**Fig. 13 a,b** il progetto terapeutico di questo caso prevede la realizzazione di una barra in titanio fresata a due gradi con il sistema CAD/CAM Procera (Nobel Biocare), avvitata a quattro impianti intra-foraminali (a). L'inserimento di due "spinette" anteriori nella mesostruttura e di chiavistelli con bottone a scatto nella regione posteriore garantisce una ritenzione e una stabilità adeguata alla protesi. È importante che la barra sia più bassa nella zona tra un impianto e l'altro, per facilitare una detersione della stessa e dei pilastri implantari con l'utilizzo di scovolini e superfloss e il corretto mantenimento dei tessuti molli peri-implantari (b). Proprio per questo all'odontotecnico vengono forniti scovolini di varia misura che verranno utilizzati nelle diverse fasi di laboratorio per il confezionamento della barra.



**Fig. 14** Immagine di controllo a distanza di 2 mesi dalla consegna delle protesi definitive. È possibile apprezzare l'armonico montaggio degli elementi protesici e l'ottimale riproduzione dei dettagli anatomici; sono state utilizzate faccette in composito per gli elementi anteriori ed elementi in resina composita per quelli posteriori, opportunamente caratterizzati per conferire un aspetto più naturale. La personalizzazione nella stratificazione della resina e l'utilizzo di supercolori ed intensivi permette di realizzare flange protesiche del tutto simili ai tessuti gengivali naturali.

steriori vestibolari e impedire il ribaltamento della protesi verso l'avanti (Fig. 12).

I manufatti protesici ultimati vengono quindi provati, avvitando la nuova barra fresata in titanio sui quattro impianti inseriti in regione inter-foraminale (Figg. 13a,b).

Si procede al controllo di eventuali punti di pressione avvalendosi di materiali quali il Fit-Checker (Gc, Giappone), e alla verifica dell'occlusione statica e dinamica, preferendo una disclusione con funzione di gruppo per garantire la corretta stabilità alla protesi superiore (Fig. 14).

#### QUATTROTI DT (PRECISION DIGITAL DENTAL TORQUE)

L'innovativo sistema di avvitamento elettronico digitale QuattroTiDT, presentato in questa

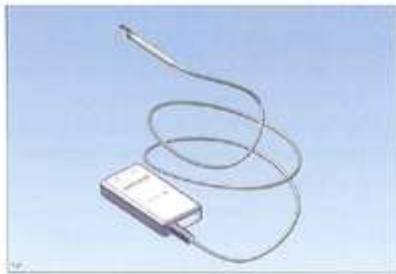
trattazione è costituito da una chiave a cricchetto autoclavabile, con scatto libero per torsione in un solo senso, da una sonda per la lettura della torsione applicata collegata al cricchetto e dal modulo elettronico bluetooth per la ricezione e l'invio dei dati a un computer.

La chiave a cricchetto, compatibile con tutte le sistematiche implantari tramite l'utilizzo di specifici terminali dedicati, permette di effettuare le esatte misure della torsione applicata dall'operatore al momento dell'inserimento dell'impianto all'interno della cavità ossea e del serraggio della vite dell'abutment protesico alla fixture. Peculiarità dello strumento è quella di consentire l'impugnatura lungo l'intero manico senza ottenere errori nella coppia di forza rilevata.

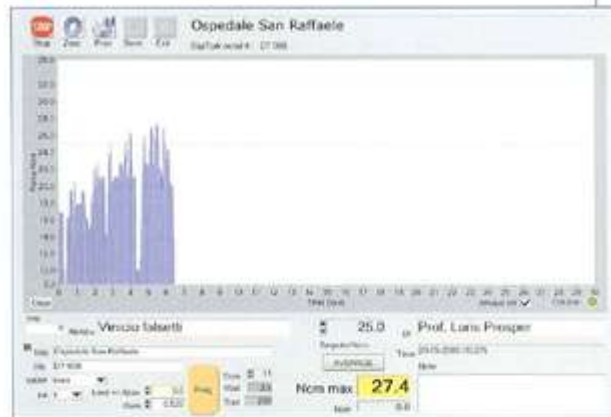
In altre parole la coppia letta a monitor risulterà sempre quella corretta anche tirando il manico della chiave da diverse posizioni.



## Chiave dinamometrica digitale: applicazioni in impianto-protesi



**Fig. 15 a,b** L'innovativa chiave dinamometrica digitale QuattroTIDT è costituita da un cricchetto con terminali dedicati a cui è collegata una sonda elettronica e da un modulo elettronico bluetooth per la ricezione e l'invio dei dati a un computer (a). La chiave dinamometrica digitale permette di effettuare con precisione le misurazioni della torsione applicata sia durante l'inserimento degli impianti, sia durante il serraggio della vite protesica alla fixture, controllando i valori raggiunti sul grafico che appare sul computer (b). La memorizzazione e archiviazione dei dati consente di creare una banca dati utile per il clinico nelle diverse fasi operative e, inoltre, un prezioso "documento certificante", anche con validità medico-legali. L'utilizzo del cricchetto dinamometrico digitale dovrebbe entrare come protocollo operativo anche nelle fasi di laboratorio; per esempio, risulta fondamentale serrare a più di 35 Newton i monconi implantari durante il fresaggio, in quanto le vibrazioni generate comporterebbero uno svitamento della vite di fissaggio. Il clinico deve poi essere a conoscenza del torque applicato alle viti in fase di lavorazione, in quanto dovrà essere il medesimo utilizzato per fissare definitivamente il manufatto protesico con viti nuove, che si "impastano" alla filettatura, cosa che invece non si verifica nel caso in cui vengano utilizzate viti già adoperate in laboratorio e quindi snervate.



La lettura del valore della coppia applicata passa dalla sonda al modulo bluetooth tramite un cavo molto sottile e flessibile. Da qui il segnale è trasmesso a una stazione ricevente (computer o palmare) e, una volta installato e avviato il software fornito con la sistemica, è possibile visualizzare, a monitor e in tempo reale, con quale modalità è stata applicata la coppia di serraggio e il valore massimo raggiunto.

Con l'aiuto di un grafico visualizzato sul monitor potremo quindi controllare facilmente e in modo affidabile, il momento di forza applicato fino al raggiungimento del valore impostato (da 0 a 150 Ncm) (Fig. 15).

Durante la fase di avvitamento un allarme acustico comincerà a suonare a intermittenza, fino a diventare un suono continuo al raggiungimento del valore impostato.

Il software in dotazione permette di programmare il momento torcente in funzione delle caratteristiche del singolo caso clinico, come la qualità dell'osso, la posizione, la lunghezza e il diametro dell'impianto.

È possibile memorizzare i dati del paziente e il grafico del torque raggiunto, con l'impostazione di eventuali limiti di accettazione. La memorizzazione dei dati e dei diagrammi relativi sia alla fase chirurgica che protesica permette di ottenere una sorta di "documento certificante" con una validità anche dal punto di vista medico-legale.

## DISCUSSIONE E CONCLUSIONI

La stabilità primaria dell'impianto al momento del suo inserimento nell'alveolo implantare e l'assenza di carico masticatorio per un periodo di tempo variabile sono considerati ancora oggi principi validi e determinanti in moltissimi casi al fine di garantire il processo di osteointegrazione e la sopravvivenza a lungo termine della riabilitazione impianto-protetica<sup>39-46</sup>.

## IMPLANTOLOGIA

Se da un lato sulla stabilità primaria dell'impianto esiste un'uniformità di vedute in Letteratura, per quanto riguarda i tempi di protesizzazione si sono registrati progressi tali da ridimensionare in alcuni casi i dettami proposti da Brånemark<sup>47-54</sup>.

La scuola di Brånemark, imponeva un periodo di tre mesi per la mandibola e di sei mesi per il mascellare superiore al fine di garantire un corretto processo di osteointegrazione.

Ad oggi, grazie al miglioramento delle geometrie e delle superfici implantari, è stato ampiamente dimostrato come impianti singoli o multipli solidarizzati rigidamente tra loro, presentino un'adeguata osteointegrazione anche quando protesizzati precocemente o nell'immediato post-operatorio.

La stabilità primaria rappresenta, comunque, la condizione indispensabile e imprescindibile per il carico immediato degli impianti endossei.

Dalla Letteratura emerge come siano necessari almeno 40/45 newton di torque al momento dell'inserimento dell'impianto nel sito estrattivo. Valori inferiori potrebbero non essere sufficienti per garantire un'adeguata stabilità della protesi e soprattutto i micro-movimenti correlati comprometterebbero la corretta integrazione impiantare mediante la formazione di tessuto fibroso all'interfaccia osso-impianto (osteo-fibro-integrazione).

I motori chirurgici presenti sul mercato permettono di impostare e visualizzare direttamente i parametri fondamentali quali il numero di giri delle frese e il valore di torque nel manipolo<sup>55-57</sup>. Pur essendo affidabili dal punto di vista meccanico, risultano tuttavia essere molto "operatore-dipendenti", essendo legati alla sensibilità del singolo clinico e alla libera interpretazione che viene data dallo stesso riguardo alle condizioni anatomiche riscontrate (per esempio la qualità dell'osso).

Allo stesso modo le chiavi dinamometriche manuali e i cricchetti calibrati fino a oggi in commercio permettono di impostare valori di torque utilizzabili sia al momento dell'inserimento manuale dell'impianto, sia

nella fase di avvitamento della componentistica protesica e in particolare per il serraggio della vite dell'abutment alla fixture.

Tuttavia tali sistemi, che "scattano" al raggiungimento del valore impostato (Ncm), risultano essere ancora una volta troppo sensibili al singolo operatore e potrebbero non essere in grado di garantire una precisione assoluta e costante nel tempo a causa di usure ed eventuali assestamenti interni delle componenti meccaniche, legati all'utilizzo e ai processi di disinfezione e sterilizzazione.

Da qualche anno esiste in commercio un dispositivo elettronico chiamato "Osstell" (Osstell™ Mentor, Integration Diagnostics AB, Göteborg, Svezia), che ci permette di valutare l'osteointegrazione degli impianti attraverso l'analisi della "frequenza di risonanza" (RFA)<sup>58-61</sup>.

Si compone di un trasduttore fissato all'impianto o all'abutment che trasmette vibrazioni di tipo sinusoidale, le quali vengono poi raccolte da un secondo elemento analizzatore di frequenza. I valori riscontrati vengono espressi in ISQ (Implant Stability Quotient). Tale sistema permette una precisa valutazione del grado di osteointegrazione impiantare nelle diverse fasi di lavoro e risulta estremamente valido come controllo a distanza di tempo dalla protesizzazione, tanto che tale sistematica è diventata lo standard di riferimento per la valutazione della stabilità impiantare.

Tuttavia il sistema "Osstell" non permette di controllare il valore del torque di inserimento dell'impianto e non presenta uno specifico utilizzo per quanto concerne l'avvitamento della componentistica protesica.

E proprio l'innovativo sistema di avvitamento elettronico QuattroTIDT rappresenta, a nostro parere, un notevole progresso nell'ambito delle riabilitazioni implantoprotesiche, in particolar modo in quelle a carico immediato.

La costituzione di uno specifico protocollo che includa l'utilizzo sistematico della chiave dinamometrica digitale nelle differenti fasi riabilitative assume rilevanza mag-

## Chiave dinamometrica digitale: applicazioni in impianto-protesi

giore in strutture sanitarie complesse, quali ospedali e cliniche, strutture in cui operano più operatori, dove la conoscenza, l'archiviazione e l'immediata accessibilità a tutti i dati clinici e tecnici di ogni singolo paziente garantiscono a tutta l'equipe un lavoro ottimale, evitando inutili perdite di tempo.

La creazione di una banca dati con l'archiviazione digitale di tutti i dati favorisce il lavoro in team nelle differenti fasi riabilitative e rappresenta un valido strumento di confronto e controllo a distanza di tempo dei valori iniziali rispetto a quelli riscontrati a ogni controllo.

Da non sottovalutare l'utilità dello strumento anche ai fini medico-legali, in quanto la raccolta delle registrazioni relative ai valori di torque chirurgici e protesici costituisce un vero e proprio documento di lavoro e una vera e propria certificazione che, conservata in cartella clinica in formato cartaceo e/o digitale, ci preserva maggiormente da eventuali contenziosi giuridici, purtroppo sempre più diffusi negli ultimi anni.

È possibile inoltre fornire al paziente una copia cartacea dei dati raccolti, utile da aggiungere alla "carta di identità" degli impianti: tale documentazione fornisce al paziente una sorta di "certificato di garanzia" per il lavoro eseguito, rappresentando inoltre un utile supporto qualora l'operatore che ha eseguito il lavoro iniziale non fosse più il medesimo.

In aggiunta al protocollo riteniamo doveroso sottolineare come non bisogna esimersi dal bloccare tutti gli abutment implantari con viti protesiche nuove, regola valida per qualsiasi sistemazione implantare, ma troppo spesso trascurata, poiché le viti di serraggio, nel momento in cui vengono utilizzate per la prima volta, si "impastano" a livello della filettatura, creando un accoppiamento stabile che non si verificherebbe qualora si svitasse e si riavvitasse più volte la stessa vite. Un piccolo accorgimento, per molti scontato e già consolidato, ma indispensabile per garantire un lavoro ottimale ed evitare inconvenienti e inutili perdite di tempo per il clinico e per il paziente, vero protagonista di tutto il nostro operato.

## RINGRAZIAMENTI

Per la parte odontotecnica si ringrazia il laboratorio del sig. Tonino D'Alcandro di Francavilla al Mare (PE) e i suoi collaboratori: Sig. Fabio Leonzio, Sig. Paolo Piattelli, Sig. Danilo Di Casimiro.

## BIBLIOGRAFIA

1. Inversini M. Prosthetic implant treatment of the edentulous maxilla with overdenture. *Minerva Stomatol.* 2006 Oct;55(10):567-586.
2. Chiapasco M, Gatti C. Implant-retained mandibular overdentures with immediate loading: a 3- to 8-year prospective study on 328 implants. *Clin Implant Dent Relat Res.* 2003; 5(1):29-38.
3. Romeo E, Chiapasco M, Lanza A, Casentini P, Ghisolfi M, Iorio M, Vogel G. Implant-retained mandibular overdentures with ITI implants. *Clin Oral Implants Res.* 2002 Oct;13(5):495-501.
4. Wolfinger GJ, Bahshi TJ, Rangert B. Immediate functional loading of Brånemark System implants in edentulous mandibles: Clinical report of the results of developmental and simplified protocols. *Int J Oral Maxillofac Implants* 2003;18:250-257.
5. Testori T, Meltzer A, Del Fabbro M. Immediate occlusal loading of Osseotite implants in the lower edentulous jaw. A multicenter prospective study. *Clin Oral Implants Res.* 2004;15:278-284.
6. Maló P, Rangert B, Eng M, Nobre M. "All-on-four" immediate function concept with Brånemark system implants for completely edentulous mandibles: a retrospective clinical study. *Clin Implant Dent Relat Res* 2003;5:2-9.
7. Misch CE, Degidi M. Five-year prospective study of immediate/early loading of fixed prostheses in completely edentulous jaws with a bone quality-based implant system. *Clin Implant Dent Relat Res* 2003; 5:17-28.
8. Bedrossian E, Sullivan RM, Fortin Y, Maló P, Indresano T. Fixed-prosthetic implant restoration of the edentulous maxilla: systematic pretreatment evaluation method. *J Oral Maxillofac Surg.* 2008 Jan;66(1):112-122.
9. Alshabeeha N, Aziz M, Payne AG. Loading Protocols for Mandibular Implant Overdentures: a Systematic Review with Meta-Analysis. *Clin Implant Dent Relat Res.* 2009 Apr 23.
10. Lazzaro RJ, Testori T, Meltzer A, Misch C, Porter S, del Castillo R, Goené RJ. Immediate Occlusal Loading (IOL) of dental implants: predictable results through DIEM guidelines. *Pract Proced Aesthet Dent.* 2004 May;16(4):3-15.
11. Crespi R, Cappari P, Gherlone E, Romanos GE. Immediate versus delayed loading of dental implants placed in fresh extraction sockets in the maxillary esthetic zone: a clinical comparative study. *Int J Oral Maxillofac Implants.* 2008 Jul-Aug;23(4):753-758.



12. Esposito M, Grusovin MG, Willings M, Coulthard P, Worthington HV. The effectiveness of immediate, early, and conventional loading of dental implants: a Cochrane systematic review of randomized controlled clinical trials. *Int J Oral Maxillofac Implants*. 2007 Nov-Dec;22(6):893-904.
13. Wang HL, Ormianer Z, Palti A, Perel ML, Trisi P, Sammartino G. Consensus conference on immediate loading: the single tooth and partial edentulous areas. *Implant Dent*. 2006 Dec;15(4):324-333.
14. Prosper L, Redaelli S, Pasi M, Zarone F, Redaelli G, Gherlone EF. A randomized prospective multicenter trial evaluating the platform-switching technique for the prevention of postrestorative crestal bone loss. *Int J Oral Maxillofac Implants*. 2009 Mar-Apr;24(2):299-308.
15. Chiapasco M. Early and immediate restoration and loading of implants in completely edentulous patients. *Int J Oral Maxillofac Implants*. 2004;19 Suppl:76-91.
16. Misch CE, Hahn J, Judy KW, Lemons JE, Linkow LJ, Lozada JL, Mills E, Misch CM, Salama H, Sharawy M, Testori T, Wang HL. Immediate Function Consensus Conference. Workshop guidelines on immediate loading in implant dentistry. *J Oral Implantol*. 2004;30(5):283-288.
17. Cochran DL. The evidence for immediate loading of implants. *J Evid Based Dent Pract*. 2006 Jun;6(2):155-163.
18. Degidi M, Piattelli A. Immediate functional and non-functional loading of dental implants: A 2 to 60-month follow-up study of 646 titanium implants. *J Periodontol* 2003;74:225-241.
19. Maló P, de Araujo Nobre M, Rangert B. Implants placed in immediate function in periodontally compromised sites: a five-year retrospective and one-year prospective study. *J Prosthet Dent*. 2007 Jun;97(6 Suppl):586-95.
20. Pleri F, Aldini NN, Fini M, Corinaldesi G. Immediate occlusal loading of immediately placed implants supporting fixed restorations in completely edentulous arches: a 1-year prospective pilot study. *J Periodontol*. 2009; Mar;80(3):411-421.
21. Del Fabbro M, Testori T, Francetti L, Taschieri S, Weinstein R. Systematic review of survival rates for immediately loaded dental implants. *Int J Periodontics Restorative Dent*. 2006; 26: 249-263.
22. Romanos GE, Testori T, Degidi M, Piattelli A. Histologic and histomorphometric findings from retrieved, immediately occlusally loaded implants in humans. *J Periodontol*. 2005; 76: 1823-32.
23. Lang NP, Tonetti MS, Suvan JE. Immediate implant placement with transmucosal healing in areas of aesthetic priority. A multicentre randomized-controlled clinical trial I. Surgical outcomes. *Clin Oral Implants Res*. 2007; 18(2): 188-196.
24. Chen ST, Wilson TG Jr, Hammerle CH. Immediate or early placement of implants following tooth extraction: review of biologic basis, clinical procedures, and outcomes. *Int J Oral Maxillofac Implants*. 2004;19 Suppl:12-25.
25. Al-Khayatt AS, Elyas S. Soft tissue handling during implant placement. *Evid Based Dent*. 2008;9(3):77.
26. Sarment DP, Meraw SJ. Biological space adaptation to implant dimensions. *Int J Oral Maxillofac Implants*. 2008 Jan-Feb;23(1):99-104.
27. Van Assche N, Collaert B, Coucke W, Quirynen M. Correlation between early perforation of cover screws and marginal bone loss: a retrospective study. *J Clin Periodontol*. 2008 Jan;35(1):76-79.
28. Esposito M, Grusovin MG, Maghazreh H, Coulthard P, Worthington HV. Interventions for replacing missing teeth: management of soft tissues for dental implants. *Cochrane Database Syst Rev*. 2007 Jul 18;(3):CD006697.
29. De Kok U, Chang SS, Moriarty JD, Cooper LF. A retrospective analysis of peri-implant tissue responses at immediate load/provisionalized microthreaded implants. *Int J Oral Maxillofac Implants*. 2006 May-Jun;21(3):405-412.
30. Prosper L, Redaelli S, D'Alicandro T, D'Addona A, Gherlone EF. Passivazione nella protesi implanta supportata. *Implantologia Orale Nov*. 2005 (5):9-28.
31. Jemt T, Lekholm U. Implant treatment in edentulous maxillae. A 5-year follow-up report on patients with different degrees of jaw resorption. *Int J Oral Maxillofac Implants* 1995;10:303-311.
32. Adell R, Lekholm U, Rockler B, Brånemark P-LA. 15-year study of osseointegrated implants in the treatment of the edentulous jaw. *Int J Oral Surg* 1981 10:387-416.
33. Skalak R. Biomechanical considerations on osseointegrated prostheses. *J Prosthet Dent* 1983; 49:843-848.
34. Weinberg LA. The biomechanics of force distribution in implant-supported prostheses. *Int J Oral Maxillofac Impl* 1993;8:19-31.
35. Jemt T, Lekholm U. Measurements of bone and framework deformations induced by misfit of implant superstructures. A pilot study in rabbits. *Clin Oral Implants Res* 1998; 9:272-280.
36. Jemt T, Book K. Prosthesis misfit and marginal bone loss in edentulous implant patients. *Int J Oral Maxillofac Implants* 1996; 11:620-625.
37. Clelland NL, Carr AB, Glat A. Comparison of strains transferred to a bone stimulant between as-cast and postsoldered implant frameworks for five implant-supported fixed prosthesis. *J Prosthodont* 1996; 5:193-200.
38. Tan KB, Rubenstein JE, Nicholls JL, Youdelis RA. Three-dimensional analysis of the casting accuracy of one piece, osseointegrated implant-retained prostheses. *Int J Prosthodont* 1993;6:346-363.
39. Esposito M, Grusovin MG, Chew YS, Coulthard P, Worthington HV. Interventions for replacing missing teeth: 1- versus 2-stage implant placement. *Cochrane Database Syst Rev*. 2009 Jul 8;(3):CD006698.
40. Elyas S, Al-Khayatt AS. No difference between failure rates of early and conventionally loaded implants. *Evid Based Dent*. 2008;9(2):50.
41. Turkyilmaz I, Sennerby L, McGlumphy EA, Tözüm TF. Biomechanical aspects of primary implant stability: a human cadaver study. *Clin Implant Dent Relat Res*. 2009 Jun; 11(2): 113-9. Epub 2008 Apr 16.

## Chiave dinamometrica digitale: applicazioni in impianto-protesi

42. Turkylina L, McGlumphy EA. Influence of bone density on implant stability parameters and implant success: a retrospective clinical study. *BMC Oral Health*. 2008 Nov 24;8:32.
43. Meredith N. Assessment of implant stability as a prognostic determinant. *Int J Prosthodont*. 1998 Sep-Oct;11(5):491-501.
44. Bryant SR. The effects of age, jaw site, and bone condition on oral implant outcomes. *Int J Prosthodont*. 1998 Sep-Oct;11(5):470-90.
45. Molly L. Bone density and primary stability in implant therapy. *Clin Oral Implants Res*. 2006 Oct;17 Suppl 2:124-35.
46. Renaud F, Nisand D. Impact of implant length and diameter on survival rates. *Clin Oral Implants Res*. 2006 Oct;17 Suppl 2:35-51.
47. Esposito M, Worthington HV, Thomson P, Coulthard P. Interventions for replacing missing teeth: Different times for loading dental implants. *Cochrane Database Syst Rev* 2004; 3:CD003878.
48. Kawai Y, Taylor JA. Effect of loading time on the success of complete mandibular titanium implant retained overdentures: a systematic review. *Clin Oral Implants Res*. 2007 Aug;18(4):399-408.
49. Bakaeen L, Quinlan P, Schoolfield J, Lang NP, Cochran DL. The biologic width around titanium implants: histometric analysis of the implantogingival junction around immediately and early loaded implants. *Int J Periodontics Restorative Dent*. 2009 Jun;29(3):297-305.
50. Esposito M, Grusovin MG, Achille H, Coulthard P, Worthington HV. Interventions for replacing missing teeth: different times for loading dental implants. *Cochrane Database Syst Rev*. 2009 Jan 21;1:CD003878.
51. Hermann JS, Buser D, Schank RC, Cochran DL. Crestal bone changes around titanium implants. A histometric evaluation of unloaded non-submerged and submerged implants in the canine mandible. *J Periodontol*. 2000 Sep;71(9):1412-24.
52. Quirynen M, Van Assche N, Botticelli D, Berglundh T. How does the timing of implant placement to extraction affect outcome? *Int J Oral Maxillofac Implants*. 2007;22 Suppl:203-23.
53. Jøkstad A, Carr AB. What is the effect on outcomes of time-to-loading of a fixed or removable prosthesis placed on implants? *Int J Oral Maxillofac Implants*. 2007;22 Suppl:19-48.
54. Den Hartog L, Slater JJ, Vissink A, Meijer HJ, Raghoebar GM. Treatment outcome of immediate, early and conventional single-tooth implants in the aesthetic zone: a systematic review to survival, bone level, soft-tissue, aesthetics and patient satisfaction. *J Clin Periodontol*. 2008 Dec;35(12):1073-86.
55. Neugebauer J, Scheer M, Mischkowski RA, An SH, Karapetian VE, Tutenburg H, Zoeller JE. Comparison of torque measurements and clinical handling of various surgical motors. *Int J Oral Maxillofac Implants*. 2009; May-Jun;24(3):469-476.
56. Trisi P, Peretti G, Baldoni E, Berardi D, Colagiovanni M, Scogna G. Implant micromotion is related to peak insertion torque and bone density. *Clin Oral Implants Res*. 2009 May; 20(5):467-471.
57. Tan BR, Tan KB, Nicholls JJ. Critical bending moment of implant-abutment screw joint interfaces: effect of torque levels and implant diameter. *Int J Oral Maxillofac Implants*. 2004; Sep-Oct;19(5):648-658.
58. Bilbao A, Hernández-De Oliveira M, Varela-Centelles PI, Seoane J. Assessment of dental implant stability in osseodistraction-generated bone: a resonance frequency analysis. *Clin Oral Implants Res*. 2009 Apr 28. [Epub ahead of print].
59. Song YD, Jun SH, Kwon JJ. Correlation between bone quality evaluated by cone-beam computerized tomography and implant primary stability. *Int J Oral Maxillofac Implants*. 2009 Jan-Feb;24(1):59-64.
60. Oh JS, Kim SG, Lim SC, Ong JL. A comparative study of two noninvasive techniques to evaluate implant stability: Periotest and Osstell Mentor. *Oral Surg Oral Med Oral Pathol Oral Radiol Endod*. 2009 Apr;107(4):513-8.
61. J Hug S, Kessler-Liechti G, Mericske-Stern R. Measurement of dental implant stability by resonance frequency analysis and damping capacity assessment: comparison of both techniques in a clinical trial. *Int J Oral Maxillofac Implants*. 2008 May-Jun;23(3):525-530.
62. Brouwers JE, Lobbezoo F, Visscher CM, Wismeijer D, Naeije M. Reliability and validity of the instrumental assessment of implant stability in dry human mandible. *J Oral Rehabil*. 2009 Apr;36(4):279-283.

The purpose of this study is to present a new digital torque wrench and its implantological and prosthetics applications.

This new computerized system is extremely useful during the surgical placement of the implant in the alveolar bone. In particular in immediate-loading rehabilitations: direct visualization on the computer and digital control of implant torque allow the clinician to check the primary stability of implants and the potential immediate loading with temporary prosthetic restoration. Digital torque wrench is very important also during the following step, to set and check torque tapping of prosthetics screws, in order to avoid unscrewing or breaking. Memorization and collection of data allow to create an indispensable clinical database and an important medical-legal documentation.

**Parole chiave:** Digital dental torque, Immediate loading, Implant stability.



# 1° INCONTRO DELLE SCUOLE DI CHIRURGIA ORALE ROMA 18-20 FEBBRAIO 2010



**SAPIENZA**  
UNIVERSITÀ DI ROMA  
Magnifico Rettore: Luigi Frati

## LEMBO DI BOLLA DI BICHAT ASSOCIATO AL LEMBO DI REHRMANN NELLA CORREZIONE PLASTICA DI AMPIA FISTOLA ORO ANTRALE IN PAZIENTE TRATTATA CON BIFOSFONATI: CASE REPORT.

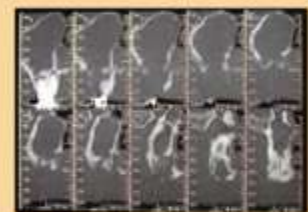
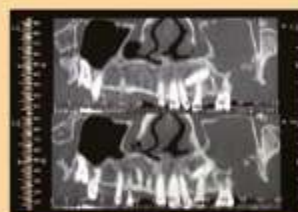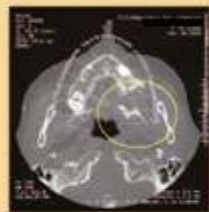
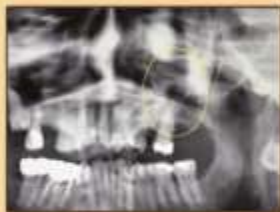**DEL BRUTTO M.\*°, ALFIERI G.\*°, MARIANI G.\*°, VIANALE C.\*°, MAZZANTI R.\*° e SAMMARTINO G.\*°**

\* Università degli Studi di Napoli "Federico II", Dipartimento di Scienze Odontostomatologiche e Maxillo-Facciali, Scuola di Specializzazione in Chirurgia Odontostomatologica - Direttore: Prof. Gilberto Sammartino.

ASUR Marche ZT6- Direttore: Dr. Guido Papiri, Ospedale di Rete "E. Profili" Fabriano (An), DSO - Direttore: Dr.ssa Stefania Mancinelli, Dipartimento Chirurgico - Direttore: Dr. Franco Tobaldi;

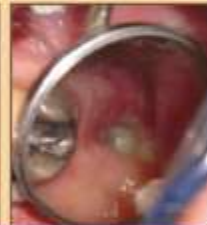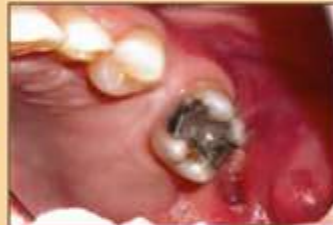\* U.O. di Otorinolaringoiatria- Responsabile: Dr. Geniale Mariani.

\* U.O.C. di Chirurgia Orale e Odontostomatologia- Direttore: Dr. Roberto Mazzanti.



In alto - La documentazione radiografica OPT + TAC mostra ampia comunicazione oro - antrale successiva ad estrazione di secondo molare superiore sinistro.

A destra - Documentazione clinica che mostra la comunicazione oro - antrale produttiva in sede 27. Nell'ultima immagine è visibile una notevole riduzione della fistola dopo 14 giorni di terapia medica pur con persistenza esudativa, la cui risoluzione ha reso pertanto necessario l'intervento di chirurgia plastica.



Bibliografia  
1) Shukron A, Gurev A, Pomeroy SA, et Mariani G. Histologic evaluation of different techniques for maxillofacial communication repair of 113 cases. *Int J Oral Maxillofac Surg* 2009;38(12):1313-4. <http://dx.doi.org/10.1016/j.ijom.2009.06.014>  
2) Eguchi H. Utilization of the buccal fat pad for closure of palatal and/or nasal communication. *J Maxillofac Surg* 1975;33:40-4  
3) Suda K. Use of buccal fat pad for palate. *Int J Surg (Lond Engl)* 2003;1(1):24-8  
4) Takahashi H, Shimoguchi A, Suda K. Use of the buccal fat pad as a pedicle flap. *J Oral Maxillofac Surg* 1995;53:443-6  
5) Sammartino G, Sammartino G, Sammartino G, Sammartino G. The use of the buccal fat pad for reconstruction of oral defects. *Review of the literature and report of 11 cases.* *Crit Rev Oral Biol Med* 2009;40:114-20.  
6) Sammartino G. Buccal fat pad. *Arch Otolaryngol* 2007;133:103-10  
7) Sammartino G. Buccal fat pad. *Arch Otolaryngol* 2007;133:103-10  
8) Sammartino G, Sammartino G, Sammartino G, Sammartino G. The buccal fat pad in oral reconstruction. *Head Neck* 2007;29:203-10  
9) Sammartino G, Sammartino G, Sammartino G, Sammartino G. Use of the buccal fat pad in the reconstruction of oral defects. *Reconstruction of maxillofacial defects.* *Int J Oral Maxillofac Surg* 2005;34:148-53.  
10) Sammartino G. Buccal fat pad. *Arch Otolaryngol* 2007;133:103-10  
11) Sammartino G. Buccal fat pad. *Arch Otolaryngol* 2007;133:103-10

Le Fistole Oro Antrali (Oro Antral Communication) costituiscono una complicanza di difficile diagnosi in chirurgia odontostomatologica, le cui cause riguardano prevalentemente l'endodonzia nei settori lateroposteriori. Tutto ciò tende a una notevole riduzione nei fattori anatomici predisponenti come l'innalzamento della gamma masticatoria dell'antro di Higdon, la naturale conformazione anatomica tra apice molare e seno maxillare e una maggiore nei settori parodontopatia maxillare. Il riscontro clinico viene associato nei casi con un sintomo parodontopatia. Da una studio retrospettivo di Shukron et al (1) effettuato su un campione di 113 pazienti affetti da GOC, il 61% dei casi di fistola oro antrale è stato associato ad un'operazione di estrazione del secondo molare superiore sinistro.

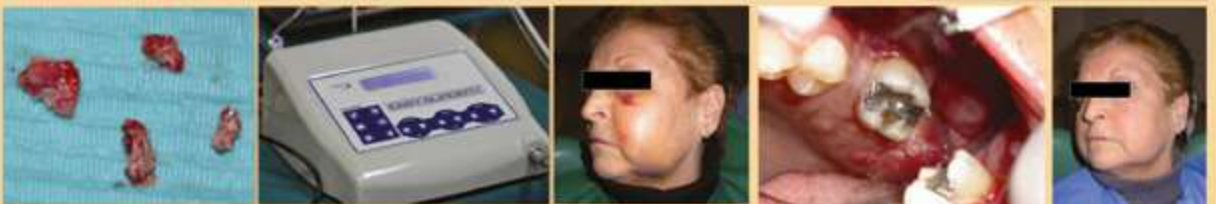Quando la GOC risulta di modesta dimensione la tecnica di Rehrmann, o lembo peduncolato buccale, può risultare una valida soluzione terapeutica, anche se i risultati clinici determinano spesso un appiattimento del fornice vestibolare con necessità di un riporto per ottenere un effondimento tramite innesti liberi. Nelle situazioni in cui la GOC risulta localizzata in una sede alta, l'impiego di lembi peduncolati di tessuto palatale associato come limitazione la necessità di guarigione per seconda intenzione di un lembo superiore come potrebbe da parte di un GOC (impacciati rispetto di gara indifferente una placca di occlusione).

Nel trattamento di ampia fistola oro-antrale la posizione di sistema vestibolarizzazione, con l'impiego di lembi di replezione palatale sono considerati per il rischio di lesione e conseguente necrosi ischemica del polmone maxillare, l'uso del lembo di Bolla del Bichat costituisce una valida soluzione terapeutica.

Il lembo peduncolato di Bolla di Bichat (BUCCAL FAT PAD) è stato descritto per la prima volta nel 1917 da Eguchi (2) per la chiusura di comunicazione oro-antrale secondarie a processi odontologici. Nel 1985, Suda (3) utilizza la Bolla di Bichat come un lembo libero nella cavità orale. Nel 1986, Tidman et al, (4) dimostrano che il lembo BFP si applica all'istmo della 2a e si fissa con una sutura alforale all'osso maxillare per la ricostruzione post-odontologica. Rapolla et al, (5), Kim, (6) e Sam et al, (7) hanno utilizzato il lembo peduncolato BFP per la ricostruzione di difetti ossei di varie dimensioni post-odontologici. Nel 2005, Amin (8) ha dimostrato come il lembo BFP può essere utilizzato efficacemente nei difetti parietali post-odontologici.

Una paziente di anni 71 in trattamento odontologico per osteoporosi medicata ha richiesto un quadro clinico di ampia fistola oro-antrale post-odontologica complicata da sinusite produttiva, in considerazione del quadro radiologico, dopo la coltura (OPT + TAC) viene impostata un piano di trattamento GOC, a base di Clodroglicone 375 mg/giorno in base, terapia corticosteroidica e protettiva per un periodo di 14 giorni. Il primo tentativo di chiusura della fistola (chirurgia) secondo il protocollo di Marz (9) si è conclusa con un'operazione di 30 giorni per un post-chirurgico con terapia antibiotica temporanea a base di cefalosporina D. Si è scelto di non effettuare lembi di replezione palatale per ridurre al minimo l'esposizione ossea. La plastica correttiva ha previsto l'impiego di una tecnica combinata mediante l'innalzamento di un lembo di Bolla (10) completamente ricucito e associato ad un lembo di Bolla di Bichat. Tale tecnica ha permesso di effettuare la chiusura della comunicazione oro-antrale e di coprire la comunicazione oro-antrale associata ad un lembo di Bolla di Bichat. Tale tecnica ha permesso di effettuare la chiusura della comunicazione oro-antrale e di coprire la comunicazione oro-antrale associata ad un lembo di Bolla di Bichat.

La risoluzione del quadro patologico in assenza di complicazioni intraoperatorie ha decretato il successo della scelta metodologica.



In alto - Le varie fasi dell'intervento chirurgico di correzione plastica di ampia fistola oro - antrale mostra un confortante risultato clinico durante il controllo a 45 giorni. Il dislocamento della Bolla del Bichat a copertura della comunicazione oro - antrale associata ad un corretto management osseo realizzato mediante l'utilizzo di strumento Easy Surgery (Bioxin, Ancona) ci ha permesso di ottenere una corretta guarigione dei tessuti molli che altrimenti era risultata impossibile con la sola terapia medica.

## SESSIONE POSTER



### DIFETTI DI SPESSORE CRESTALI: UTILIZZO DELLA TECNICA SPLIT CREST

Marcelli B., Delli Carpini A., Coccia E., Procaccini M. (*Università Politecnica delle Marche, Istituto di Scienze Odontostomatologiche - Direttore Prof. M. Procaccini*)

#### INTRODUZIONE

Il posizionamento di impianti in zone edentule è, in alcuni casi, condizionato da insufficiente spessore delle creste ossee. In presenza di tali atrofie, il ridotto volume osseo in senso vestibolo-palatale riduce la possibilità di un corretto posizionamento degli impianti. Con lo split crest si espande lo spazio compreso tra le due corticali; si inseriscono, così,

impianti di più largo diametro con indubbi vantaggi di tipo biomeccanico e funzionale. Inoltre, inserire impianti di diametro vicino a quello del dente naturale favorisce anche l'estetica nella successiva fase di protesizzazione. Nel caso di creste molto esili, è alto il rischio di fenestrazioni e deiscenze durante la preparazione del sito, con conseguente esposizione delle spire implantari, che richiederebbe il ricorso a tecniche chirurgiche rigenerative per la copertura di queste zone che aumentano i tempi di intervento e le complicanze.

#### OBBIETTIVI

Con la tecnica dello split crest la correzione del difetto è finalizzato all'aumento preventivo della cresta ossea, in modo che l'inserimento degli impianti avvenga in condizioni favorevoli. È indicata principalmente per la correzione di difetti di ampiezza in cui lo spessore osseo è tra 1,5 e 3,5 mm. La tecnica dello split crest richiede molta manualità da parte dell'operatore e tempi lunghi di guarigione; durante l'esecuzione dell'intervento è fondamentale evitare la frattura secca della corticale che esporrebbe il frammento a necrosi.

#### MATERIALI E METODI

Scopo del lavoro è effettuare una review dei casi clinici di 10 pazienti adulti che presentavano marcata atrofia delle creste alveolari (spessore variabile da 1,5 a 2,5mm) confermata da esami radiografici dedicati (TC) e edentulia di 1-3 elementi. In totale sono stati inseriti, con l'aiuto di un dispositivo piezoelettrico (Easy Surgery®) 25 impianti Winsix®.

a superficie SLA, 12 superiori e 13 inferiori, tutti nella zona dei premolari e molari. I pazienti sono stati sottoposti ad anamnesi medica e odontoiatrica per escludere malattie sistemiche importanti e informati sulle procedure e le possibili complicanze e alternative. Sulla base delle cerature diagnostiche, sono state ricavate le mascherine chirurgiche che hanno permesso di valutare l'entità della dislocazione della corticale vestibolare, in modo da ottenere il posizionamento e l'emergenza ottimali delle fixture implantari in rapporto ai futuri elementi protesici. Dopo l'intervento i pazienti hanno assunto terapia con FANS associati all'assunzione ogni 12 ore per 5 giorni di 1 g di amoxicillina e acido clavulanico e istruiti sull'igiene domiciliare, da effettuare con detersione accurata della zona d'intervento e sciacqui con clorexidina allo 0,2% per 7 giorni. I controlli erano programmati una volta al mese, fino alla scoperta degli impianti, a 4 mesi e alla protesizzazione definitiva, dopo ulteriori 2 mesi. In nessun caso ci sono state complicanze intra e postoperatorie. Al controllo a 3 anni il riassorbimento osseo intorno agli impianti inseriti nella zona trattata era valutabile, radiograficamente, in media, in 1 mm, equivalente a quello di impianti inseriti in osso maturo. L'adattamento dei tessuti

mollì soddisfaceva le richieste estetiche. In nessuno dei casi di era verificata perdita di impianti.

#### RISULTATI E CONCLUSIONI

La tecnica piezoelettrica ha consentito un'espansione più sicura e meno traumatica, grazie al taglio micrometrico. La riparazione ossea e l'osteointegrazione degli impianti si sono dimostrati ampiamente soddisfacenti; nelle fasi di rientro il guadagno osseo in ampiezza era evidente e le creste ossee apparivano rimineralizzate. Anche le condizioni dei tessuti mollì sono risultate ottimali. Tutto questo ha permesso una eccellente prognosi della riabilitazione implantoprotesica, confermata dalla stabilità del risultato a tre anni e dal successo dell'integrazione pari al 100%.



Università Vita-Salute San Raffaele (MI)  
Facoltà di Medicina e Chirurgia  
Corso di Laurea in Igiene Dentale  
Presidente: Prof. E. F. Gherlone



I.R.C.C.S. San Raffaele (MI)  
Unità Operativa di Odontoiatria  
Direttore: Prof. E. F. Gherlone

## Analisi retrospettiva a quattro anni degli esiti di trattamento implanto-protetico eseguiti con sistemica Winsix®

S. Zandonella Necca, F. Bova, E. F. Gherlone

Sono stati considerati 409 pazienti che nel periodo compreso tra marzo 2006 e marzo 2010 si sono sottoposti a riabilitazione implanto-protetica presso l'Unità Operativa di Odontoiatria dell'I.R.C.C.S. San Raffaele di Milano. Complessivamente in questi pazienti sono stati posizionati 1438 impianti Winsix® tutti a superficie BioActive Covering SLA®. Parte di questi pazienti (209), successivamente al carico degli impianti, sono afferiti al programma di mantenimento implantare attivato presso il Centro di Igiene Orale e Prevenzione attivato presso la stessa U.O. di Odontoiatria.

Per ciascun paziente si è proceduto ad analizzare i livelli di esposizione ai fattori di rischio noti per la malattia perimplantare (pregressa parodontite, scarsa igiene orale, diabete, tabagismo, assunzione di bevande alcoliche).

Nei pazienti sottoposti a mantenimento è stato possibile rilevare, per ogni impianto, l'insieme dei parametri clinici e tecnici atti a determinare lo stato di salute del sito implantare (profondità di sondaggio, sanguinamento al sondaggio, segni radiografici di riassorbimento dell'osso di supporto, mobilità).

**Analisi dei dati.** Su 1438 impianti posizionati, 32 sono andati incontro a fallimento, fermando al 2,4% l'incidenza di fallimento (Grafico 1). In 6 casi il fallimento si è



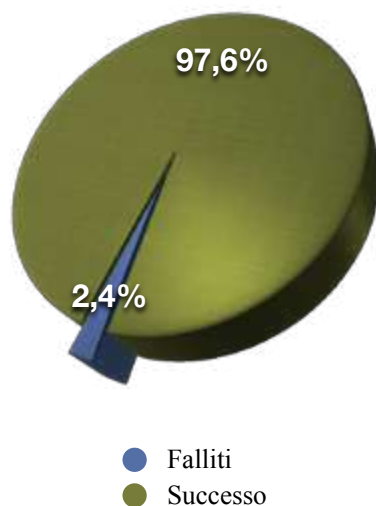
verificato in pazienti dediti al tabagismo ed in altri 12 in pazienti con storia di pregressa parodontite.

Restringendo l'analisi ai pazienti sottoposti a programma di mantenimento (209 pazienti e 682 impianti), l'incidenza di fallimento scende all'1,6% (11 impianti falliti) (Grafico 2). Il sondaggio in 6 punti di questi siti implantari ha permesso di valutare che solo il 15% di essi presentano  $PPD \geq 4mm$  (Grafico 3).

Inoltre, su 682 impianti in mantenimento, in 33 casi è presente perimplantite, in 309 mucosite ed i restanti 340 siti sono in condizione di salute perimplantare (Grafico 4).

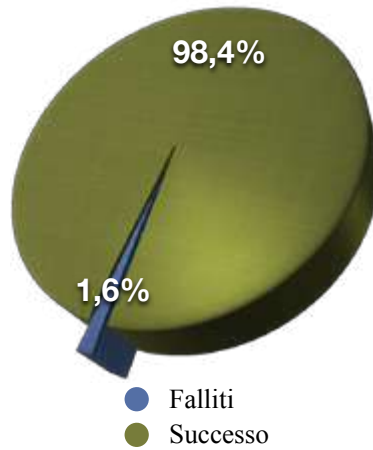
Analizzando infine i dati relativi ai valori medi di indice di placca (PI) e di sanguinamento (BOP) secondo O'Leary, sono state individuate sostanziali differenze tra i pazienti in mantenimento che hanno sofferto fallimento implantare e non. I primi mostrano valori medi di PI e BOP rispettivamente maggiori del 24,8% e del 9% (Grafico 5).

**Grafico 1.** Incidenza di fallimento nell'intero campione

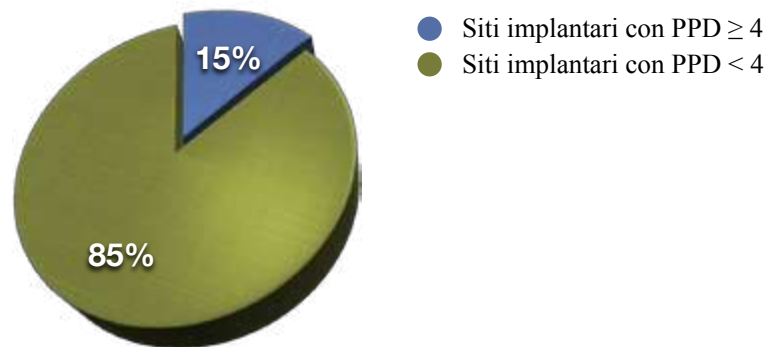


CASE REPORT

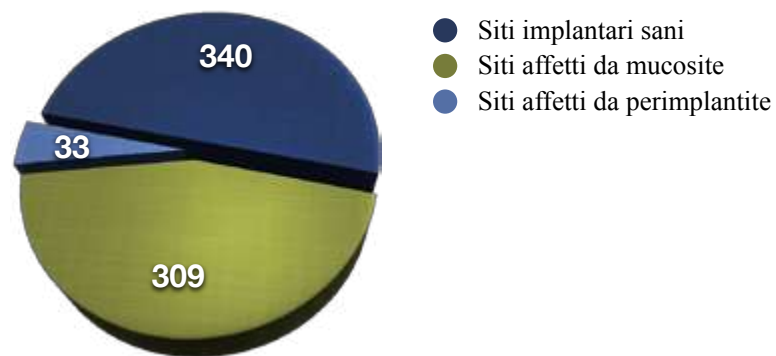
**Grafico 2.** Incidenza di fallimento nei gruppo dei pazienti in mantenimento



**Grafico 3.** PPD negli impianti sottoposti a mantenimento

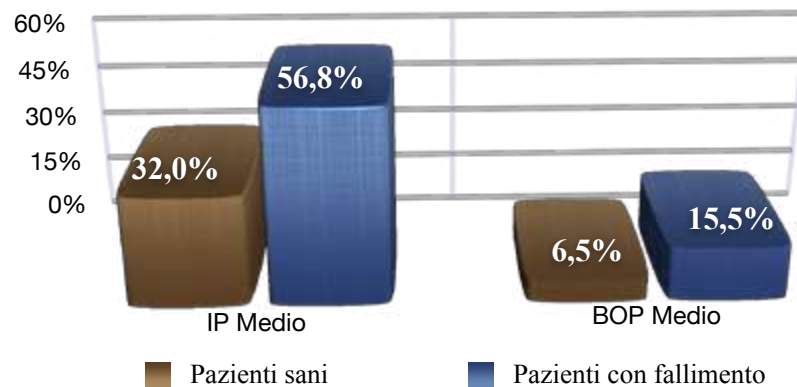


**Grafico 4.** Mucosite e perimplantite nel gruppo dei pazienti in mantenimento





**Grafico 5.** Valori medi di PI e BOP tra i pazienti in mantenimento andati incontro a fallimento implantare e non



**Conclusioni.** Il trattamento della malattia perimplantare non è risolutivo nel caso in cui si manifesti in forma di perimplantite. Inoltre, i tessuti perimplantari sono più suscettibili alla lesione infiammatoria rispetto ai tessuti parodontali. Sulla scorta di queste considerazioni appare quindi evidente l'importanza di inserire i pazienti riabilitati con implanto-protesi in un programma di mantenimento che sia occasione utile a prevenire ed intercettare tempestivamente la comparsa di fenomeni infiammatori dei tessuti perimplantari e parimenti l'insorgenza di problematiche meccaniche localizzabili ai dispositivi implantari e/o protesici. L'abbattimento del tasso di incidenza di fallimento osservato nell'ambito di questo studio, benchè non siano stati indagati i fenomeni microbiologici alla base di questo risultato, può essere ritenuto probatorio dell'efficacia di un simile atteggiamento clinico.

#### Bibliografia

**Lindhe J, Berglundh T, Ericsson I, Liljenberg B, Marinello CP.** Experimental breakdown of periimplant and periodontal tissues. A study in beagle dog. *Clinical Oral Implants Research* 1992; 3: 9-16

**Lang NP, Bragger U, Walter D, Beamer B, Kornman KS.** Ligature-induced peri-implant infection in cynomolgus monkeys. *Clinical Oral Implants Research* 1993; 4: 2-11

**Schou S, Holmstrup P, Stoltze K, Hjorting-Hansen E, Kornman KS.** Ligature-induced marginal inflammation around osseointegrated implants and ankylosed teeth. Clinical and radiographic observation in cynomolgus monkeys *Clinical Oral Implants Research* 1993; 4: 12-22

**Marinello CP, Berglundh T, Ericsson I, Klinge B, Glantz PO, Lindhe J.** Resolution of ligature-induced peri-implantitis lesion in the dog. *Journal of Clinical Periodontology* 1995; 22: 475-480

**Ericsson I, Persson LG, Berglundh T, Edlund T, Lindhe J.** The effects of antimicrobial therapy on peri-implantitis lesion. An experimental study in dog. *Clinical Oral Implants Research* 1996; 7: 320-328

**Persson LG, Ericsson I, Berglundh T, Lindhe J.** Guided bone regeneration in the treatment of perimplantitis. *Clinical Oral Implants Research* 1996; 7: 366-372

**Gotfredsen K, Berghlundh T, Lindhe J.** Bone reactions at implants subjected to experimental peri-implantitis and static load. An experimental study in the dog. IV. *Journal of Clinical Periodontology* 2002; 29: 144-151

**Berglundh T, Claffey N, De Bruyn H, Heitz-Mayfield N, Karoussis I, Könönen E, Lindhe J, Meyle J, Mombelli A, Renvert S, van Winkelhoff A, Winkel E, Zitzmann N.** Peri-implant diseases: consensus report of the sixth european workshop on periodontology. *Journal of Clinical Periodontology* 2008 Sep; 35(8 Suppl): 282-285

- 1 L'Impiego della teca cranica a scopo implantoprotesico**  
E. F. Gherlone, R. Vinci, L. D'Aversa  
(Oral & Implantology Anno II n° 2/2009)

---
- 2 Effect of Implant Angulation, Connection Length, And Impression Material on the Dimensional Accuracy of Implant Impressions: An In Vitro Comparative Study**  
R. Sorrentino, E. F. Gherlone, G. Calesini, F. Zarone

---
- 3 A Randomized Prospective Multicenter Trial Evaluating the Platform-Switching Technique for Prevention of Postrestorative Crestal Bone Loss**  
L. Prosper, S. Redaelli, M. Pasi, F. Zarone, G. Radaelli, E. F. Gherlone  
(JOMI - The international Journal of Oral & Maxillofacial Implants - volume 24 numero 2)

---
- 4 Isolation of osteogenic progenitors from human amniotic fluid using a single step culture protocol**  
I. Antonucci, I. Iezzi, E. Morizio, F. Mastrangelo, A. Pantalone, M. Mattioli Belmonte, A. Gigante, V. Salini, G. Calabrese, S. Tetè, G. Palka, L. Stuppia  
(SILENCE a Journal of RNA regulation)

---
- 5 Experimental in vitro study for the implementation of air polishing during treatment of implanted surfaces in patients with mucositis/peri-implantitis**  
P. Paganin, C. Cortella, E. M. Polizzi, E. F. Gherlone

---
- 6 In vitro behaviour onto different titanium supeface of osteoblast-like cells obtained from human dental pulp**  
S. Tetè, F. Mastrangelo, V. Zizzari, G. D'Apolito, N. Fiorentino, U. Desiato, MT. Sberna, R. Quaresima, L. Stuppia, R. Vinci, E. F. Gherlone  
(atti del 7TH annual meeting of isscr INTERNATIONAL SOCIETY OF STEM CELL RESEARCH) Barcellona JULY

---
- 7 Novel Protocol of osteogenic differentiation from amniotic fluid cells**  
S. Tetè, F. Mastrangelo, M. Tranasi, V. Zizzari, I. Antonucci, G. D'Apolito, T. Marchese, R. Vinci, L. Stuppia, E. F. Gherlone  
(atti del 7TH annual meeting of isscr INTERNATIONAL SOCIETY OF STEM CELL RESEARCH) Barcellona JULY

---
- 8 Interfaccia osso impianto nei differenti tipi di carico degli impianti dentali**  
S. Tetè, G. D'Apolito, F. Mastrangelo, R. Vinci, E. F. Gherlone  
(atti III Expo di Autunno università della Lombardia 27-28 Novembre)

---
- 9 Valutazione della capacità osteogenica di hafscs ottenute da liquido amniotico**  
S. Tetè, U. Di Tore, V. Zizzari, L. Stuppia, F. Zarone, E. F. Gherlone  
(atti III Expo di Autunno università della Lombardia 27-28 Novembre)

---

20  
09

**10 Analisi Morfostrutturale di Pams umane sulla superficie a deposizione elettrochimica FCC**

S. Tetè, A. De Carlo, E. Nargi, V. Zizzari, I. D'Alimonte, R. Ciccarelli, R. Vinci, E. F. Gherlone  
atti III Expo di Autunno università della Lombardia 27-28 Novembre

---

**11 L'innesto onlay autologo nelle atrofie localizzate**

B. Marcelli, M. Procaccini, E. Coccia  
QI Quintessenza Internazionale anno 25 numero X

---

**12 Evaluation of Effects on bone Tissue of Different Osteotomy Techniques**

S. Tetè, R. Vinci, V. Zizzari, L. Cingano, R. Bollero, G. D'Apolito, L. Benzo, A. Dolci, C. Mortellaro, E. F. Gherlone  
The Journal of Craniofacial Surgery volume 20 number 5 - September 2009

---

**13 Osteotomie eseguite con Piezosurgery:  
analisi biomolecolare degli effetti sul tessuto osseo**

S. Tetè, R. Vinci, F. Mastrangelo, U. Desiato, V. Zizzari, N. Fiorentino, L. Renzo, E. F. Gherlone  
Atti III Expo di Autunno università della Lombardia 27-28 Novembre

## L'IMPIEGO DELLA TECA CRANICA A SCOPO IMPLANTOPROTESICO

E.F. GHERLONE, R. VINCI, L. D'AVERSA\*

Dipartimento di Odontoiatria (Dir.: Prof. E. F. Gherlone)  
Università Vita-Salute S. Raffaele Milano  
\* Università Campus Biomedico Roma

### RIASSUNTO

#### *L'impiego della teca cranica a scopo implantoprotesico*

L'imporsi dell'implantologia osteointegrata come soluzione di prima scelta nel trattamento degli edentulismi comporta spesso il suo utilizzo in situazioni anatomiche di volumetria ossea insufficiente per il posizionamento corretto degli impianti. In ottemperanza ai concetti d'implantologia protesicamente guidata, si rendono spesso necessarie tecniche di incremento trasversale e verticale. Alcune di queste tecniche (*sinus lifting*, innesti *onlay-inlay*) richiedono la disponibilità di un quantitativo più o meno abbondante di osso autologo, che rappresenta il *gold standard* di riferimento per queste tecniche. Il caso che viene presentato è stato trattato mediante ricostruzione delle sedi atrofiche con innesto di teca parietale cui è seguita riabilitazione impianto-protesica di entrambi i mascellari. La finalità di quanto presentato è sottolineare l'importanza del trattamento multidisciplinare, unica e vera garanzia per l'ottimizzazione dei risultati.

**Parole chiave:** atrofie mascellari, innesto di teca cranica, riabilitazione impianto-protesica.

### SUMMARY

#### *Autologous parietal grafts in preprosthetic surgery*

Edentulous patients usually request implant supported/ fixed rehabilitation. Ridge resorption after teeth loss usually affect three-dimensional implant position. Vertical and/or horizontal bone augmentation procedures are often the only choice the clinician has to deliver prosthetic guided restoration. Gold standard for augmentation procedures such as sinus lift, onlay or inlay grafts, is still autologous bone. The patient in this report underwent a pre-prosthetic reconstruction of the jaws with parietal bone, followed by fixtures insertion and fixed prosthetic rehabilitation. This clinical report aims to underline the importance of multidisciplinary treatment to optimize the results of the rehabilitation.

**Key words:** maxillary atrophy, calvarial grafts, oral rehabilitation.

## Introduzione

Il requisito principale per l'osteointegrazione è la qualità e la quantità di tessuto osseo disponibile: il suo volume deve garantire la stabilità primaria delle *fixtures* e la possibilità di un adeguato *remodeling* alle modificazioni biomeccaniche relative ai successivi carichi protesici.

La moderna implantologia, d'altronde, non si pone solo come unico obiettivo sfruttare la volumetria della cresta residua, ma anche considerare un corretto posizionamento delle *fixtures* affinché la loro posizione ed inclinazione possa ottemperare ai criteri di

implantologia protesicamente orientata per un obiettivo che miri all'eccellenza clinica in termini di funzionalità, estetica e durata nel tempo (1).

Dal punto di vista dimensionale verificiamo che mentre l'utilizzo di impianti corti in mandibole atrofiche costituisce una procedura altamente predicibile, la ridotta valenza meccanica dell'osso mascellare consiglia l'inserimento di impianti di ampia superficie. D'altronde, le caratteristiche del riassorbimento osseo nel paziente edentulo causano un depauperamento della volumetria disponibile in altezza e spessore con conseguenze diverse.

**L'atrofia di tipo verticale**, con riduzione dell'altezza della cresta residua, può determinare l'impossibilità di inserire *fixtures*, così come un eccessivo aumen-



## lavoro originale

to della distanza interarcata la realizzazione di manufatti protesici con rapporto corona-impianto sfavorevole, antiestetici e difficilmente gestibili dal punto di vista dell'igiene orale domiciliare.

**L'atrofia di tipo orizzontale**, con riduzione dello spessore della cresta residua, molto frequente soprattutto all'arcata superiore, comporta l'inserimento di impianti molto inclinati con il conseguente utilizzo di abutments angolati che limitano l'esecuzione di un corretto profilo di emergenza ed un adeguato mimetismo del margine protesico (1, 2).

Allo scopo di ricostruire un volume osseo adeguato alle diverse esigenze chirurgico-protesiche, si sono sviluppate tecniche di rigenerazione ossea, classificabili come orizzontali o verticali, eventualmente associabili tra di loro.

Il ricorso ad una di queste tecniche od a una loro associazione deve essere mirato alla correzione specifica del difetto riscontrato con un protocollo diagnostico (1).

Nei casi di grave atrofia dei mascellari, quando ci si pone dinanzi ad un paziente con la necessità ed il desiderio di essere riabilitato con protesi di tipo implantosupportato, una delle tecniche di elezione utilizzate nel Dipartimento di Odontoiatria dell'Istituto Scientifico Universitario San Raffaele di Milano è quella del prelievo di teca cranica.

### Materiali e metodi

La ricostruzione dei processi alveolari, associata o meno a quella dell'osso basale, da sempre si caratterizza per numerose problematiche ed i risultati ottenibili non sempre sono soddisfacenti o predicibili (3).

Estesi difetti ossei classe V e VI nella classificazione di Cawood e Howell (4) richiedono il più delle volte per il loro trattamento il prelievo di osso autologo. In questi casi le sedi donatrici intraorali come la branca montante, il trigono retromolare o il corpo mandibolare solitamente non forniscono quantità sufficienti di osso, per cui si rende necessario un prelievo extraorale: quello dalla cresta iliaca è il più comunemente usato, anche se sono numerosi gli svantaggi che ad esso si possono accompagnare. Fra

questi perdita parziale o totale dell'innesto osseo per riassorbimento già a breve o medio termine. È inoltre di frequente comparsa una spiccata sintomatologia algica nella sede donatrice accompagnata a notevole limitazione funzionale (5).

In alternativa è possibile prelevare importanti quantità di osso cortico-midollare dalle pareti craniche (6). Paul Tessier nel 1982 (7) ha illustrato le varie possibilità di impiego della volta parietale nelle ricostruzioni cranio-facciali descrivendo la tecnica, sia per il prelievo della teca a tutto spessore (*splitting on table calvarial graft*) che per l'asportazione della sola parete cranica esterna (*splitting in situ calvarial graft*). Quest'ultima, se da un lato riduce la quantità di osso asportabile, dall'altro permette di abbreviare e semplificare notevolmente l'intervento, riducendo al minimo le complicanze.

L'impiego degli innesti ossei intramembranosi prelevati dalla teca cranica rappresenta una metodica predicibile ed affidabile, sia per la relativa facilità di prelievo, che per le proprietà intrinseche della struttura ossea di per sé (8).

L'area interessata al prelievo si trova sulla verticale passante al davanti del foro uditivo, non più vicino di due centimetri dal vertice (evitando in questo modo il coinvolgimento nell'area di prelievo del seno sagittale che qui sotto decorre), lateralmente al di fuori dell'inserzione del muscolo temporale, anteriormente al di dietro della sutura coronale; non esistono limiti posteriori potendosi estendere l'area donatrice sino all'osso occipitale.

La scheletrizzazione della volta cranica permette di evidenziare la sutura coronale, dietro alla quale viene eseguito il prelievo e posteriormente la sutura lambdoidea; è altresì reperibile la fascia temporale superficiale per la tenace inserzione sul tavolato osseo nel punto in cui si sdoppia dal periostio (9).

È possibile eseguire i tagli osteotomici, oltre che con una fresa rotante, anche mediante un terminale piezoelettrico riducendo così ogni rischio di lesione della dura madre sottostante (10).

Le dimensioni e la forma delle stecche sono predefinite in relazione alle sedi ossee da ricostruire, così come la quantità di particolato prelevato con appositi recuperatori d'osso.

Qualora fosse stata asportata un'abbondante quantità di tessuto osseo, onde prevenire l'insorgenza di raccolte sierose ematiche nella sede del prelievo, può

essere posizionato un drenaggio a caduta da rimuovere entro le prime 24 ore.

È poi confezionato un bendaggio compressivo e nelle prime ore dopo l'intervento deve essere applicata una borsa di ghiaccio in corrispondenza della zona del prelievo.

Al paziente viene prescritta una copertura antibiotica a largo spettro che mantiene per otto giorni. A scopo antiedemigeno, immediatamente prima dell'intervento viene somministrato desametasone (9).

### Caso clinico

Il caso presentato si riferisce ad una paziente di sesso femminile in buone condizioni di salute, non fumatrice con diffuse note parodontiche agli elementi dentari residui a carico di entrambe le arcate dentarie (Figg. 1 a, b, c; 2 a, b, c).

Nella pianificazione e progettazione del caso si è eseguita una ceratura diagnostica ed è stata stabilita la conservazione e protesizzazione degli elementi naturali da 13 a 23; tutti i restanti elementi dentari all'arcata superiore ed il 47 sono stati rimossi circa due mesi prima della ricostruzione ossea onde permettere una completa guarigione dai processi parodontici nonché dei piani mucosi; contestualmente è sta-

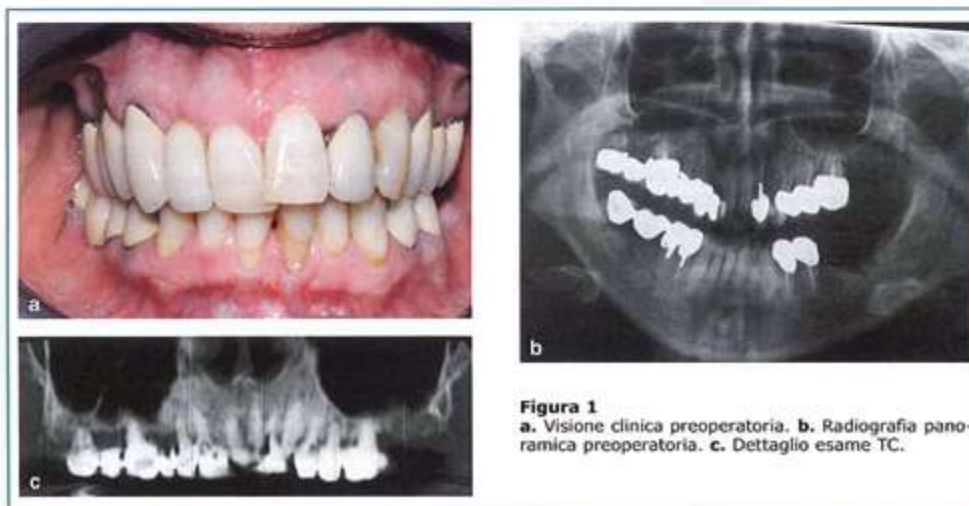
ta posizionata protesi provvisoria con rinforzo metallico.

La programmazione chirurgica preimplantare ha previsto l'esecuzione di:

- grande rialzo di seno bilaterale;
- alveoplastica con innesti occlusali al quadrante due (a correzione della discrepanza verticale);
- innesto mandibolare sinistro di apposizione mediante tecnica a tunnel (correzione di atrofia di classe IV di Caewood non suscettibile di espansione orizzontale).

La ricostruzione del pavimento del seno è stata eseguita mediante un approccio come originariamente descritto da Boyne attraverso un'incisione della mucosa vestibolare. Lo sportello osseo è stato ribaltato nella cavità sinusale e rialzato superiormente insieme con la membrana di Schneider (Fig. 3 a, b). Dopo aver misurato la lunghezza e profondità della cavità sinusale, nonché le dimensioni degli innesti ossei, si è proceduto al prelievo delle stecche e *chips* dalla volta cranica (Figg. 4 a, b; 5 a, b, c, d; 6 a).

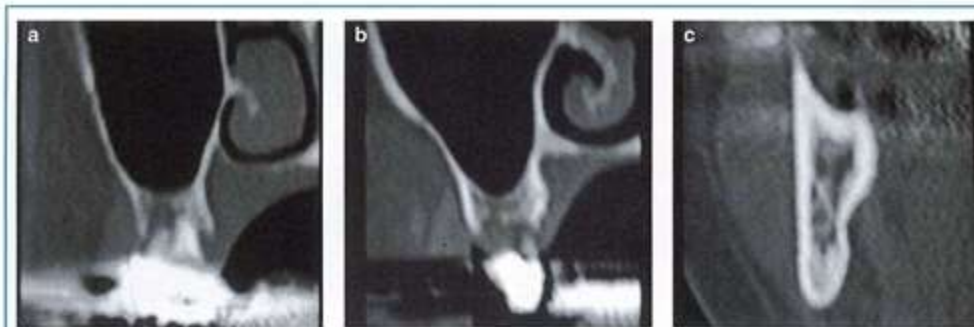
Due *slots* sono stati eseguiti nei pilastri nasale e zigomatico in corrispondenza della parete esterna del mascellare, a sostegno e stabilizzazione del nuovo pavimento antrale (Fig. 6 b). Sempre con il terminale piezoelettrico è stata scolpita una piccola osteotomia sulla parete laterale del naso, conferendo ulteriore stabilità al neopavimento sinusale. L'innesto osseo, po-



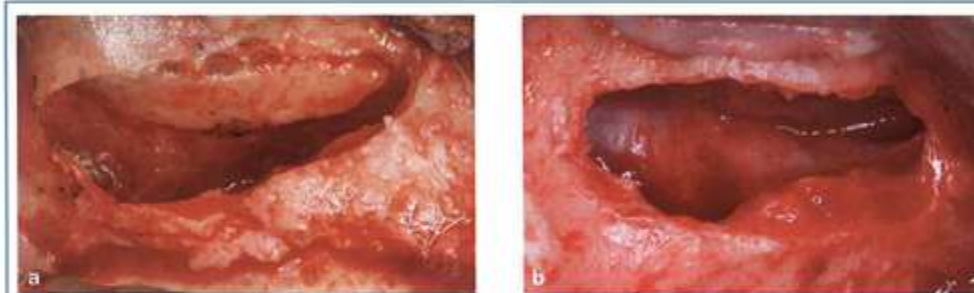
**Figura 1**  
a. Visione clinica preoperatoria. b. Radiografia panoramica preoperatoria. c. Dettaglio esame TC.



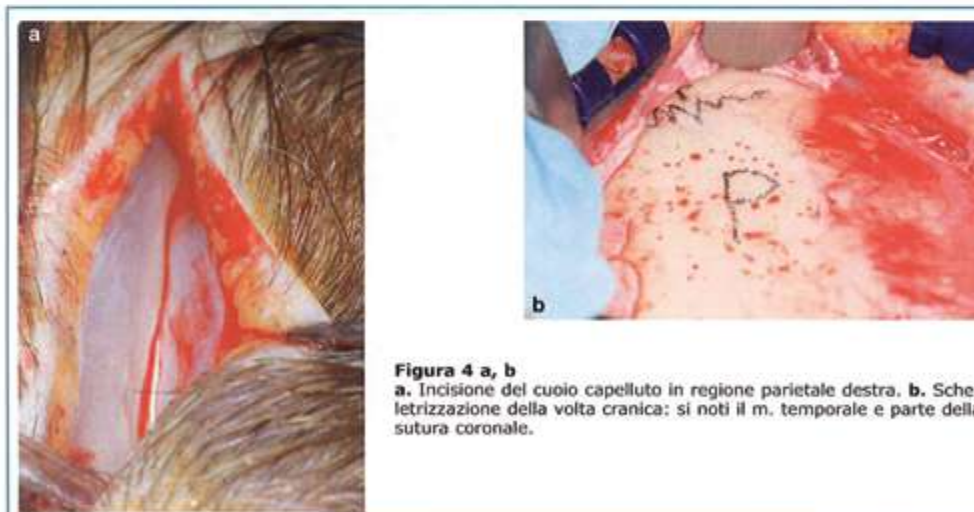
*lavoro originale*



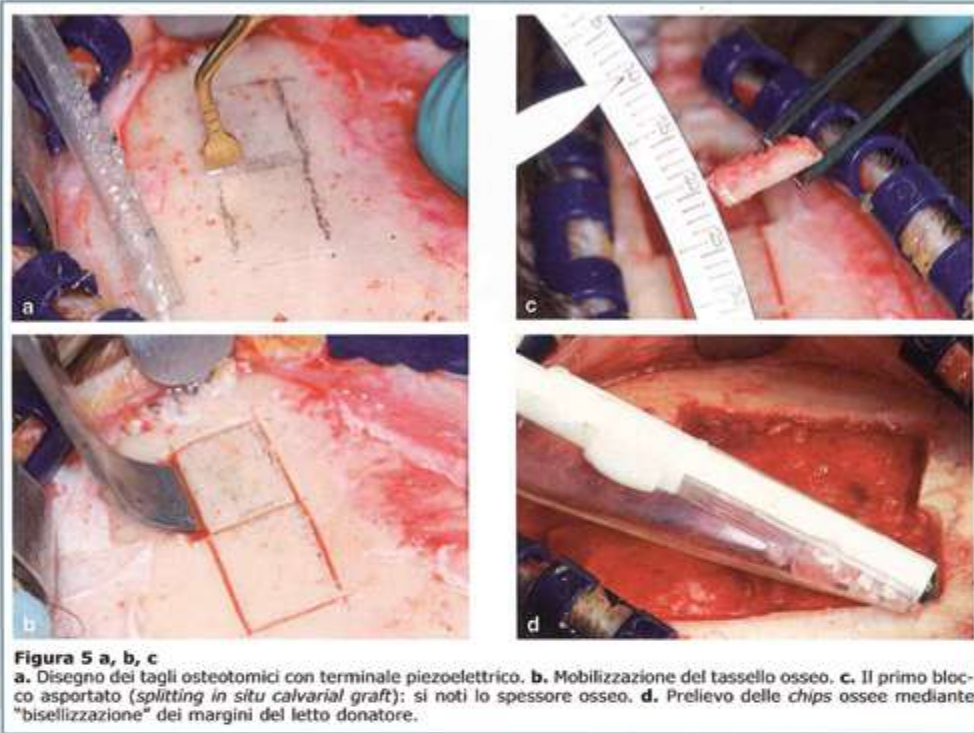
**Figura 2 a, b, c**  
 Dettaglio esame TC: si noti l'estrema atrofia ossea.



**Figura 3 a, b**  
 Apertura dei lembi, scheletrizzazione delle pareti sinusali, disegno e ribaltamento delle botole ossee.



**Figura 4 a, b**  
**a.** Incisione del cuoio capelluto in regione parietale destra. **b.** Scheletrizzazione della volta cranica: si noti il m. temporale e parte della sutura coronale.

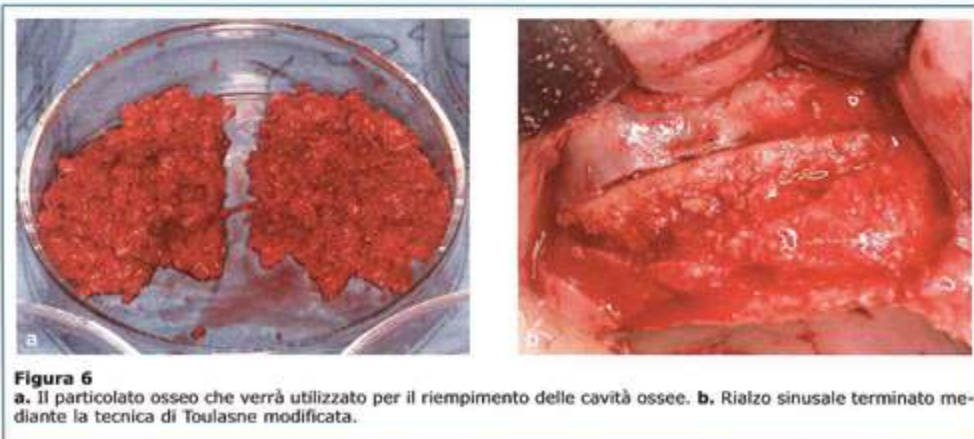

**Figura 5 a, b, c**

**a.** Disegno dei tagli osteotomici con terminale piezoelettrico. **b.** Mobilizzazione del tassello osseo. **c.** Il primo blocco asportato (*splitting in situ calvarial graft*): si noti lo spessore osseo. **d.** Prelievo delle *chips* ossee mediante "bisellizzazione" dei margini del letto donatore.

sizionato con la superficie corticale verso l'alto, offre un buon supporto alla mucosa sinusale (11). La scatola ossea al di sotto del nuovo pavimento è sta-

ta riempita con le *chips* ossee precedentemente prelevate, le quali forniscono una migliore e più rapida angiogenesi rispetto ad innesti in blocco (12, 13).

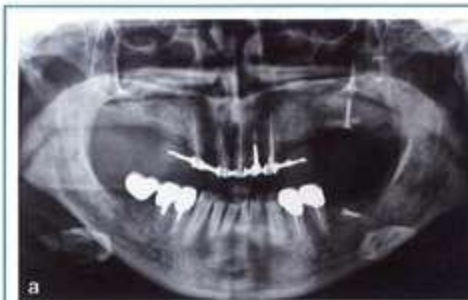

**Figura 6**

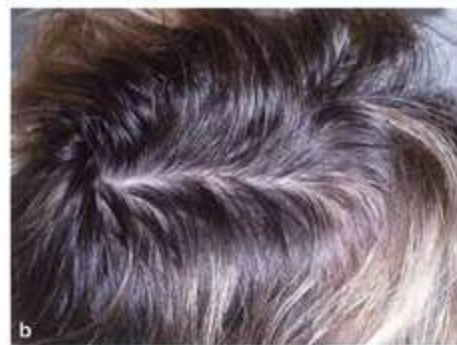**a.** Il particolato osseo che verrà utilizzato per il riempimento delle cavità ossee. **b.** Rialzo sinusale terminato mediante la tecnica di Tulasne modificata.



## lavoro originale



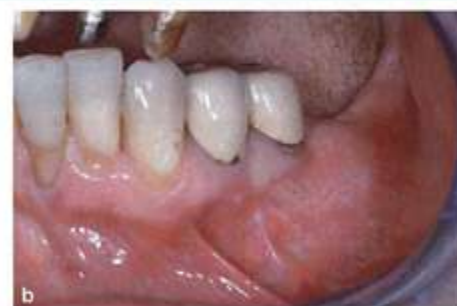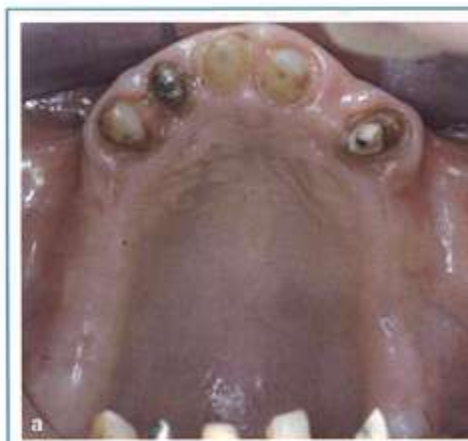
**Figura 7**  
**a.** Controllo radiografico a 4 mesi dall'intervento chirurgico: si noti il doppio rialzo sinusale ed il buon trofismo degli innesti ossei. **b.** Assenza di cicatrici chirurgiche o alopecia al cuoio capelluto nel controllo post-operatorio.



Gli innesti ossei al quadrante II e III sono stati stabilizzati in compressione-fissazione mediante la tecnica *lag screw*, che riduce la fase precoce di riassorbimento (*creeping substitution*) e stimola il rimodellamento diretto intracorticale e la produzione di osso lamellare. La guarigione ossea avviene attraverso una competizione fra osteogenesi e fibrosi. Maggiore è lo spazio fra le superfici, maggiore è la formazione di fibrosi dal tessuto connettivo. La fissazione in compressione fra due superfici ossee, riducendone la distanza, produce una migliore e più rapida guarigione attraverso una ridotta necessità di osteogenesi (14-16) (Figg. 8 a, b).

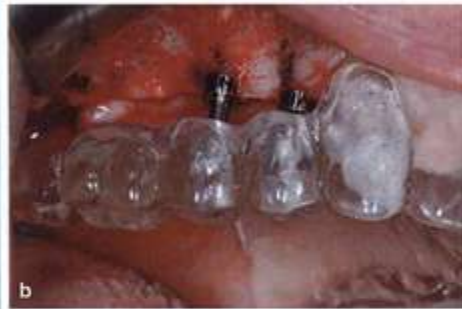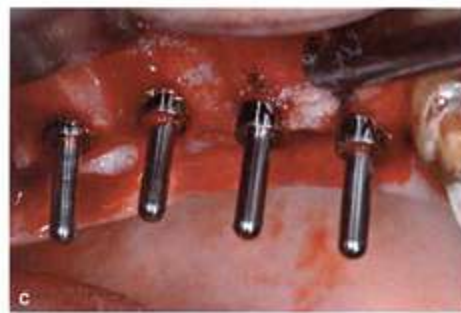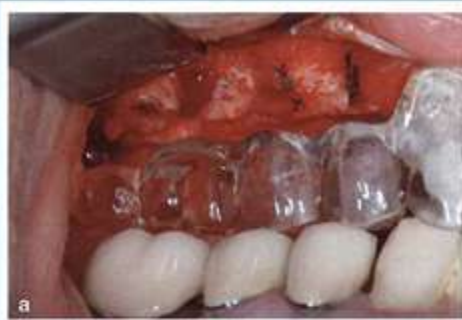Gli impianti Win Six prodotti da BIOSAF con superficie SLA, sono stati posizionati a quattro mesi dalla rigenerazione ossea con tecnica bifasica (17) (Figg. 9 a, b, c; 10 a, b, c; 11 a, b, c; 12 a, b, c). La mascherina chirurgica utilizzata durante questa fase è sempre la medesima, impiegata già durante la ricostruzione ossea e confezionata ancora in fase diagnostica dopo la ceratura.

Ad osteointegrazione avvenuta, la paziente si presenta all'operatività protesica dopo il rientro dalla seconda fase chirurgica e l'inserimento delle cover di guarigione per il condizionamento dei canali transmucosi.

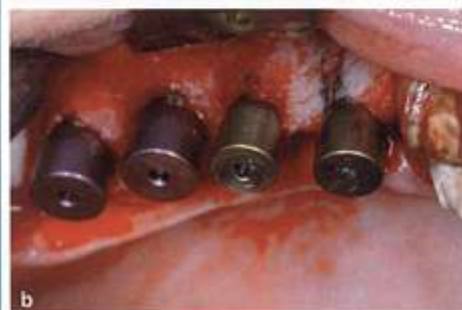
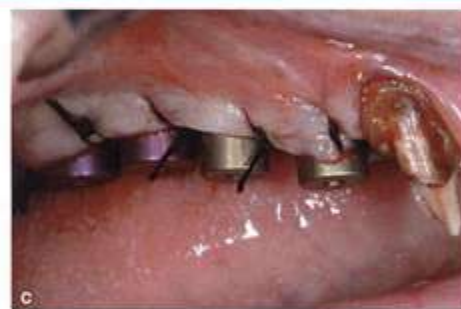
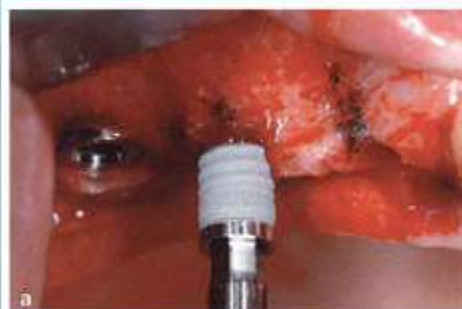**Figura 8**  
**a.** Aspetto della cresta alveolare al momento della riapertura. **b.** Aspetto della cresta mandibolare dopo ricostruzione ossea mediante tecnica a tunnel; si noti la cicatrice verticale in corrispondenza dell'elemento 34.



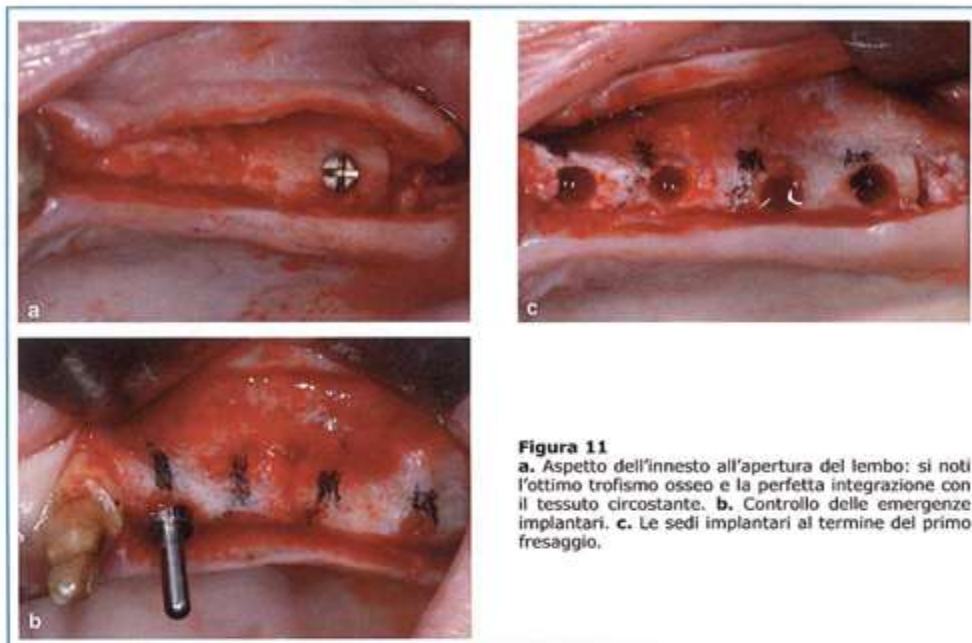


**Figura 9**  
**a.** Elevazione del lembo e controllo delle emergenze implantari; la mascherina chirurgica utilizzata è la stessa impiegata durante la fase chirurgica. **b.** Controllo delle emergenze implantari. **c.** Le emergenze implantari al termine del primo fresaggio.

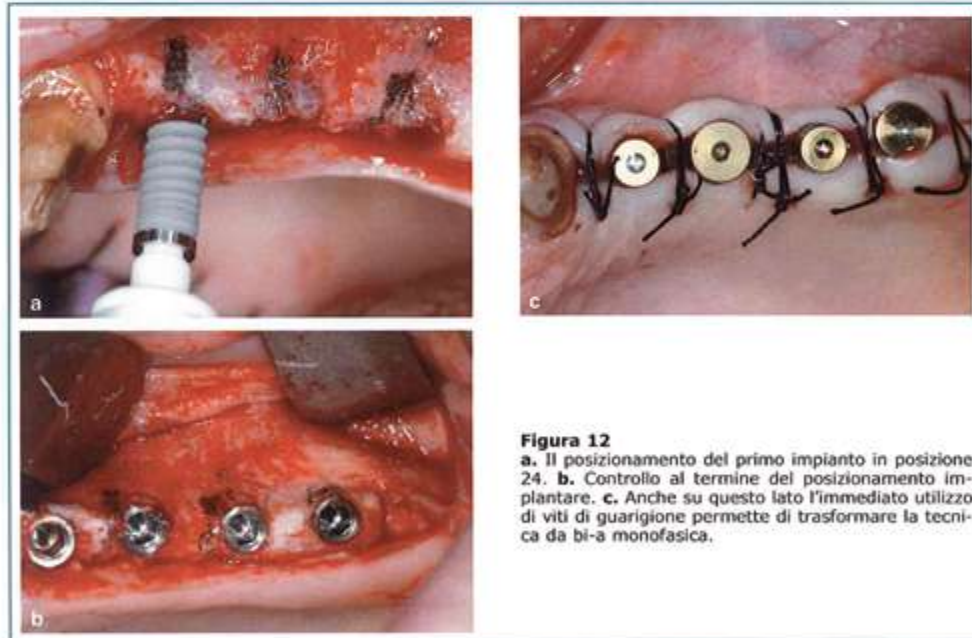


**Figura 10**  
**a.** Il posizionamento degli impianti. **b.** Mediante l'impiego immediato di viti di guarigione si è utilizzata una tecnica monofasica. **c.** Aspetto clinico alla chiusura dei lembi.

*lavoro originale*



**Figura 11**  
**a.** Aspetto dell'innesto all'apertura del lembo: si noti l'ottimo trofismo osseo e la perfetta integrazione con il tessuto circostante. **b.** Controllo delle emergenze implantari. **c.** Le sedi implantari al termine del primo fresaggio.



**Figura 12**  
**a.** Il posizionamento del primo impianto in posizione 24. **b.** Controllo al termine del posizionamento implantare. **c.** Anche su questo lato l'immediato utilizzo di viti di guarigione permette di trasformare la tecnica da bi-a monofasica.

ORAL  
IMPLANTOLOGY

Nella prima seduta protesica si è proceduto alla preparazione degli elementi con inserimento di provvisori ricavati dal *wax-up* ed impronta di precisione atta al trasferimento della posizione degli impianti su di un *master-model* tramite appositi transfer (Figg. 13 a, b, c, d).

Il passaggio successivo del protocollo ha comportato il pre-fresaggio individuale degli abutments utilizzando mascherina siliconica derivante dalla ceratura (Figg. 14 a, b, c, d, e).

I pilastri implantari prefresati sono stati provati nel cavo orale ponendo particolare attenzione agli spazi *interabutment* e con le arcate antagoniste e nella stessa seduta si è rilevata l'impronta di precisione sugli elementi naturali ed il trasferimento della posizione tridimensionale degli *abutments* provati, mediante *copying transfer* realizzati in laboratorio.

Le strutture metalliche riguardanti gli elementi naturali ed implantari e gli abutments ottimizzati in maniera definitiva si sono provati nel cavo orale e si è

quindi rilevata un'impronta di posizione per la realizzazione della ceramica grezza.

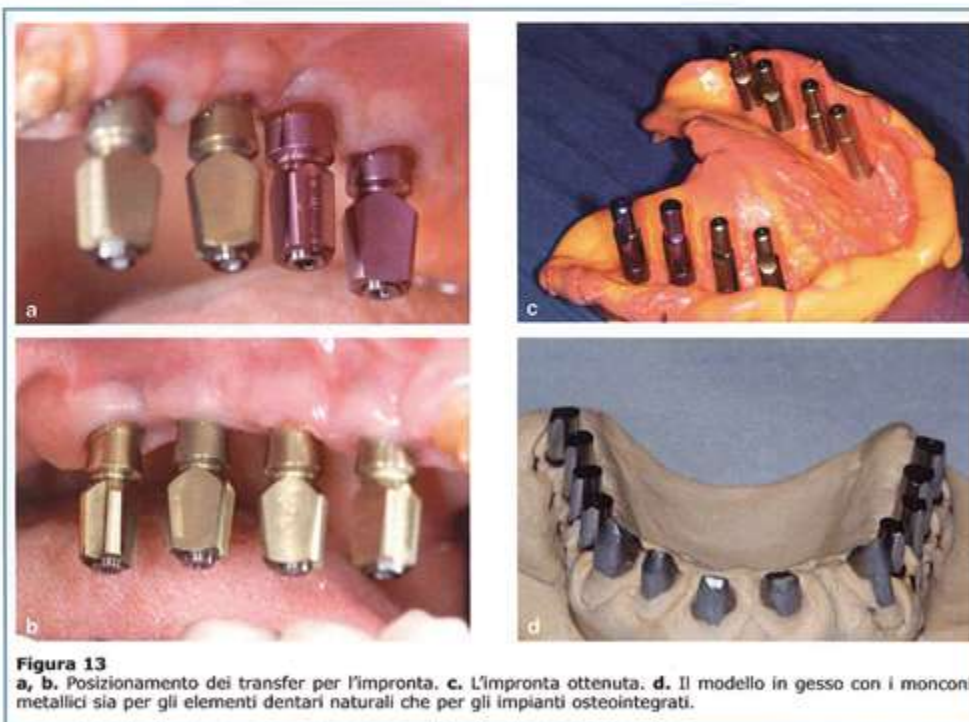
Si è quindi effettuata la prova biscotto ponendo particolare attenzione alla congruità funzionale ed estetica del manufatto.

Con un controllo accurato dell'occlusione sia in statica che in dinamica; essendo presenti elementi naturali a livello dei canini si è proceduto alla realizzazione di guide canine in lateralità come da protocollo in protesi implanto-supportata.

Dopo che il manufatto è stato finalizzato in laboratorio si è provveduto alla messa in posa con apposito cemento intermedio per il fissaggio di protesi su impianto (Figg. 15; 16 a, b, c, d).

## Conclusioni

Nella riabilitazione protesica di pazienti con gravi forme di atrofia ossea a carico dei mascellari l'in-

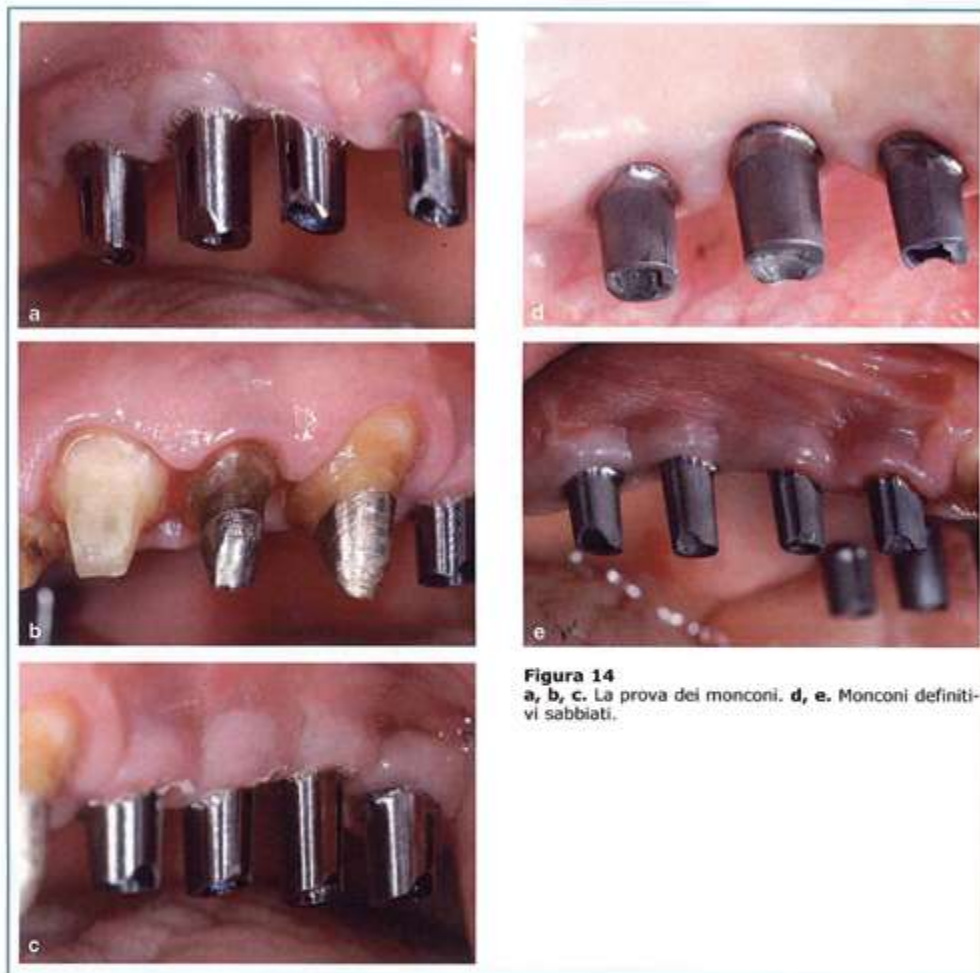

**Figura 13**

**a, b.** Posizionamento dei transfer per l'impronta. **c.** L'impronta ottenuta. **d.** Il modello in gesso con i monconi metallici sia per gli elementi dentari naturali che per gli impianti osteointegrati.



## lavoro originale



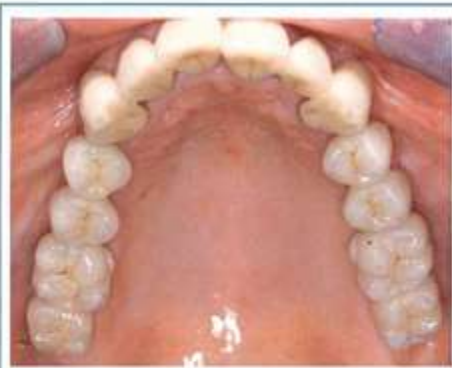**Figura 14**  
**a, b, c.** La prova dei monconi. **d, e.** Monconi definitivi sabbiati.

nesto di osso autologo può essere ancora considerato come il gold standard (2).

Tra le varie sedi di prelievo extraorale, la calvaria si è rilevata nella nostra esperienza quella che ha fornito risultati migliori a medio e lungo termine. In relazione alle caratteristiche cellulari e morfostutturali ed alla grande quantità di osso disponibile sotto forma di blocchi e di particolato, riteniamo che gli innesti autologhi di osso membranoso, fissati con viti compressive (*lag screw*), rappresentino ancora la soluzione ot-

timale per la ricostruzione della maggior parte dei difetti ossei dei mascellari, ogni qual volta il sito ricevente sia vascolarizzato ed il difetto stesso possa essere ermeticamente coperto con i tessuti circostanti (14, 18, 19).

Naturalmente il protocollo protesico per la realizzazione del manufatto deve essere rigoroso ed una particolare attenzione, come sempre in protesi impianto-supportate deve essere posta oltre che alla precisione, alle emergenze, alla distribuzione dei pilastri



**Figura 15**  
Il manufatto protesico al momento della cementazione.

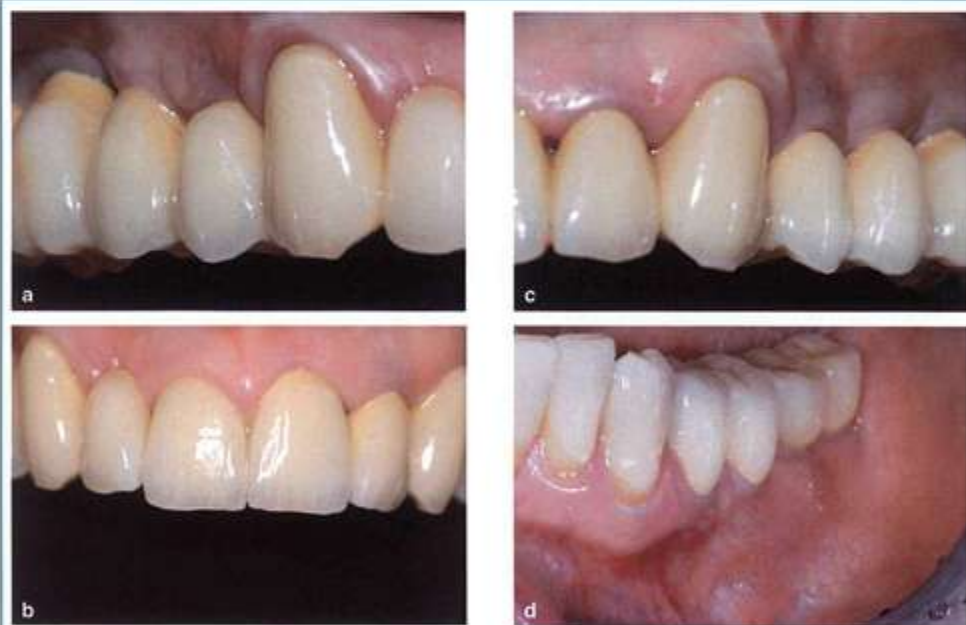e dei carichi, all'occlusione sia statica che dinamica.

Per ottenere ciò, momento fondamentale è quello del-

la pianificazione terapeutica, dove chirurgo protesista ed odontotecnico, in sinergia, progettano quella che sarà poi la realizzazione finale destinata a durare nel tempo.

### Bibliografia

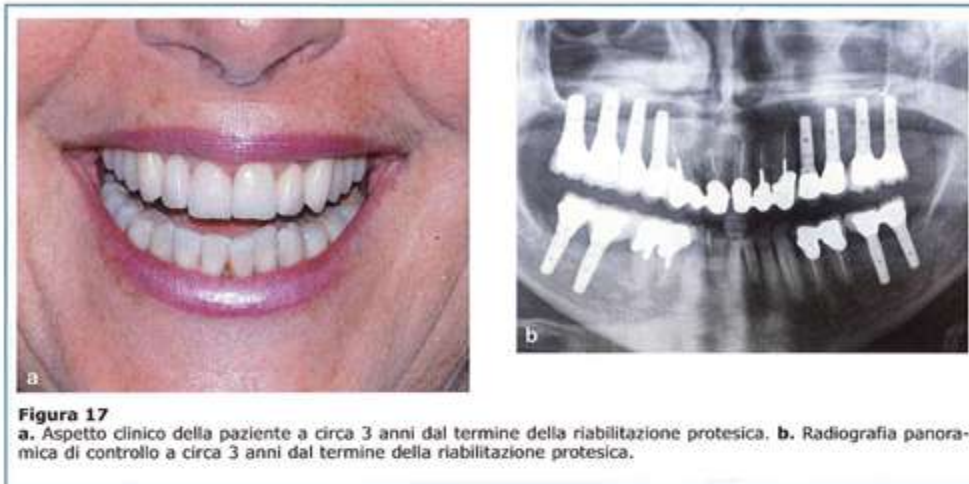1. Gherlone EF. La protesi su impianti osteointegrati - procedure cliniche. Masson 2004.
2. Gherlone EF. L'impronta in protesi dentaria. Seconda ed. Masson 2005.
3. Tong L, Buchman SR. Facial bone grafts: contemporary science and thought. J Craniomaxillofac Trauma 2000; 6: 31-36.
4. Cawood JJ, Howell RA. A classification of the edentulous jaws. Int J Oral Maxillofac Surg 1998; 17(4): 232-236.
5. Carinci F, Farina A, Zanetti U, Vinci R, Negrini S, Calura G, Laino G, Piattelli A. Alveolar ridge augmentation: a comparative longitudinal study between calvaria and iliac crest bone grafts. J Oral Implantology Vol. XXXI, No. 1, 2005.



**Figura 16 a, b, c, d**  
Il controllo dei manufatti protesici ad un anno dalla consegna.



## lavoro originale



**Figura 17**  
**a.** Aspetto clinico della paziente a circa 3 anni dal termine della riabilitazione protesica. **b.** Radiografia panoramica di controllo a circa 3 anni dal termine della riabilitazione protesica.

6. Hwang K, Hollinger JO, Chung RS, Lee SI. Histomorphometry of parietal bones vs age and race. *J Craniofacial Surg* 2000; 11 (1): 17-23.
7. Tessier P. Autogenous bone grafts taken from the calvarium for facial and cranial applications. *Clin Plast Surg* 1982; 9: 531-538.
8. Tessier P, Kawamoto H, Matthews D, Posnick J, Raulo Y, Tulasne JF, Wolfe SA. Taking calvarial grafts, either split in situ or splitting of the parietal bone flap ex vivo-tools and techniques: V. A 9650-Case experience in Maxillofacial and Craniofacial Surgery. *Plast Reconstr Surg* 2005; 116 (5 suppl): 54S-71S.
9. Vinci R, Di Stefano D, Gherlone EF. Il prelievo della teca cranica. *Italian Oral Surgery* 4/2005, 37-43.
10. Labanca M, Vinci R, Azzola F, Rodella LF. Piezoelectric surgery: twenty years of use. *Br J Oral Maxillofac Surg* 2008 Jun; 46(4): 265-9.
11. Le Lorc'h-Bukiet I, Tulasne JF, Llorens A, Lesclous P. Parietal bone as graft material for maxillary sinus floor elevation: structure and remodelling of the donor and of recipient sites. *Clin Oral Impl Res* 2005; 16: 244-249.
12. Pallesen L, Schou S, Aaboe M, Hjorting-Hansen E, Natestad A, Melsen F. Influence of particle size of autogenous bone grafts on the early stages of bone regeneration: a histologic and stereologic study in rabbit calvarium. *Int J Oral Maxillofacial Imp* 2002; 17: 498-506.
13. Orsini G, Bianchi AE, Vinci R, Piattelli A. Histologic evaluation of calvarial bone in maxillary onlay bone grafts: a report of 2 cases. *Int J Oral and Maxillofac Implants* 2003; 18(4): 594-8.
14. Vinci R. Bone grafts from the calvaria: Diagnosis, instrumentation, harvesting techniques and surgical procedures. In: *Bone augmentation in oral implantology*. Quintessence books 2007; 7: 213-240.
15. Bianchi AE, Vinci R, Sanfilippo F, Torti S. Possibilità terapeutiche e risultati a lungo termine di innesti di apposizione verticale. *Implantologia Orale* 2003; 4: 61-65.
16. Bianchi AE, Vinci R, Torti S, Sanfilippo F. Atrophic mandible reconstruction using calvarial bone grafts and implant-supported overdentures: radiographic assessment of autograft healing and adaptation. *Int J Period Restor Dent* 2004; 24(4): 335-43.
17. Tetè S, Mastrangelo F, Traini T, Vinci R, Sammartino G, Marenzi G, Gherlone E. A macro- and nanostructure evaluation of a novel dental implant. *Implant Dent* 2008 Sep; 17(3): 309-20.
18. Raghoobar GM, Batenburg RH, Vissink A, Reintsema H. Morbidity and complications of bone grafting of the floor of the maxillary sinus for the placement of endosseous implants. *Mund Kiefer Gesichtschir* 1999; 3 (1): 65-69.
19. Crespi R, Vinci R, Cappare P, Gherlone E, Romanos GE. Calvarial vs iliac crest autologous bone grafted material for sinus lift procedure. A histomorphologic study. *Int J Oral Maxillofacial Implants* 2007; 22: 527-532.

*Corrispondenza:*  
 Dott. Raffaele Vinci  
 E-mail: raffaelevinci@libero.it

# Effect of Implant Angulation, Connection Length, and Impression Material on the Dimensional Accuracy of Implant Impressions: An In Vitro Comparative Study

Roberto Sorrentino, DDS, MSc, PhD;\* Enrico Felice Gherlone, MD, DDS;† Gaetano Calesini, MD, DDS;‡  
Fernando Zarone, MD, DDS§

---

## ABSTRACT

**Background:** With regard to implant-supported prostheses, to date no technique has been proven to guarantee a completely passive fit of prosthetic frameworks. Several clinical variables may affect the precision of impressions, particularly in the presence of implants.

**Purpose:** To compare the accuracy of implant impressions made with different materials, lengths of impression coping connections, and not parallel position of the implants.

**Materials and Methods:** A calibrated testing device allowing reproducible standardized positions was used. Two control groups of master models and eight experimental groups with predetermined undercuts were used to make addition silicon and polyether implant impressions by means of the open-tray pick-up technique. Four reference distances were evaluated on each study cast by using a profile projector and a standardized measurement protocol. The data were statistically analyzed by means of three-factor analysis of variance.

**Results:** The impressions made in the presence of angulated implants were significantly less accurate than the ones made with parallel implants. The tested addition silicon resulted advantageous in presence of nonparallel implants whereas the polyether achieved the best results with parallel implants and standard impression copings.

**Conclusions:** The angulation of the implants may cause strains of impressions, probably because of the higher forces required for the impression removal. Moreover, undercuts negatively affected the impression accuracy. More accurate casts were obtained using the tested addition silicon in the presence of nonparallel implants and using a standard length connection of the copings in the presence of parallel implants, respectively.

**KEY WORDS:** dimensional accuracy, implant, implant angulation, impression, impression accuracy, impression coping, impression material, impression technique, parallel implants, prosthodontics

---

## INTRODUCTION

Impression making is a critical clinical step to record accurately the three-dimensional intraoral relationships among implants, teeth, and adjacent structures.<sup>1-4</sup> Inaccuracies during impressions inevitably lead to labora-

tory errors resulting in lack of precision and misfit of prostheses, particularly in fixed and implant-supported prosthodontics.<sup>4-6</sup>

Differently from natural teeth, osseointegrated implants have no periodontal ligament to compensate for any inaccuracy, only showing a minimal mobility caused by the elasticity of bone tissues.<sup>3,5</sup> Consequently, recording the intraoral three-dimensional position of implants is a more critical task in the realization of

---

\*Doctor, Department of Prosthodontics, University "Federico II," Naples, Italy; †professor, Department of Dentistry, University "Vita Salute San Raffaele," Milan, Italy; ‡private practice, Rome, Italy; §professor, Department of Prosthodontics, University "Federico II," Naples, Italy

Reprint requests: Prof. Fernando Zarone, A.O.U. "Federico II," Dipartimento di Scienze Odontostomatologiche e Maxillo-Facciali, Ed. 14, Via S. Panisni, 5, 80131 Napoli, Italy; e-mail: zarone@tin.it

---

© 2009, Copyright the Authors  
Journal Compilation © 2009, Wiley Periodicals, Inc.

DOI 10.1111/j.1708-8208.2009.00167.x

implant-supported than in tooth-supported prostheses to ensure an accurate relationship on the master cast.<sup>2,4,7</sup>

Although it is not possible to be clinically highlighted, the fit of a restoration can be considered "passive" if it does not create static loads within the prosthetic system or in the surrounding bone tissue.<sup>2,6</sup> It is nowadays accepted that prosthetic misfit is likely to increase the incidence of mechanical complications, just like occlusal discrepancies, screw, and abutment loosening and fracture of the prosthetic or implant components.<sup>2,8-11</sup> Moreover, marginal discrepancies caused by the misfit might enhance plaque accumulation, affecting soft and/or hard tissues around the implants.<sup>12,13</sup> As to biologic complications, the effect of misfit on the bone tissue around the implants is still controversial.<sup>14,15</sup> To date, most of the authors are prone to consider the passive fit of the prostheses as an advantageous factor for the long-term serviceability of the restorations; as a consequence, the importance of an accurate impression is paramount.<sup>4,16-20</sup>

Several studies investigated the variables affecting the accuracy of impression procedures in implant prosthodontics, such as the different direct or indirect impression techniques, the use of different impression materials, splinting or surface treatment of impression copings, the relative implant angulation, the die material accuracy, and master cast realization.<sup>21-31</sup> As regards framework making, to date, no method has been described in the literature to achieve consistent results in terms of a completely passive fit.<sup>14,15,32</sup> Distortions could be partially compensated using intraoral luting procedures.<sup>33</sup> Furthermore, several techniques have been proposed to reduce the distortion of the implant-supported frameworks, such as the electric discharge machining, the laser welding procedures, the computer numeric-controlled milled titanium frameworks and the computer-aided design-computer-aided manufacturing technologies.<sup>32-40</sup> As to the impression procedures, most of the researchers reported the open-tray pick-up technique to be more precise and predictable than the closed tray technique using repositionable copings.<sup>9,23,41,42</sup> Nonetheless, the open tray technique may present some disadvantages, like the possible imprecise positioning of the copings caused by, for example, vertical or rotational discrepancies.<sup>43-45</sup>

Most of the *in vitro* studies evaluated how to improve the impression accuracy in ideal conditions,

with parallel implants,<sup>1,22,41,42,46,47</sup> whereas fewer investigations were performed to assess the effect of nonparallel implants on the final precision of the impression<sup>21,45,48</sup> and the influence of subgingival implant placement on the dimensional accuracy of casts.<sup>4</sup>

As to the impression materials, both polyethers<sup>9,41,45,49-56</sup> and addition silicones (vinyl polysiloxanes [VPSs])<sup>1,42,52,53,57</sup> have been addressed to be suitable as impression materials for multiple implant restorations, keeping the thickness of such elastomeric materials as uniform as possible<sup>48</sup> and, at the same time, using more rigid trays to reduce the risk of impression distortions.<sup>16,50,58,59</sup>

The purpose of the present *in vitro* study was to analyze the effect on the pick-up impression accuracy of two different variables: the length of the internal hex connections of the impression copings, and the angulations of the implants. At the same time, a comparison between two elastomeric impression materials (i.e., a polyether and a VPS) was done.

Three null hypotheses were tested:

- (1) There would be no significant differences in the accuracy of the implant impressions among the groups with different impression materials.
- (2) There would be no significant differences in the accuracy of the implant impressions among the groups with different lengths of the coping internal hex connection.
- (3) There would be no significant differences in the accuracy of the implant impressions among the groups with different angulation of implants.

## MATERIALS AND METHODS

### Testing Device Construction

A stainless steel testing device previously developed by Sedda and colleagues<sup>60</sup> was used. It was made up of four parts: a base, a master model, an impression carrier, and a pouring carrier. The device was easily and consistently assembled and disassembled because of an accurate mechanical coupling system.

The base was a stainless steel quadrangular block on which three pins were welded to precisely couple into three holes drilled on each stainless steel standard tray with a numerical control machine (accuracy  $\pm 0.01$  mm). On such a base, four studs allowed the carrier holding the master model to slide onto the impression trays. To leave a thickness of 3 mm of

impression material between the top of the impression copings and the tray, four stainless steel spacers were machined and positioned on the studs of the base.

The impression carrier consisted of a stainless steel quadrangular plate on which the master model was secured by means of three screws (Figure 1). The spatial position of the master model was designed in order to match the corresponding impression tray on the base of the testing machine.

The pouring carrier consisted of a stainless steel quadrangular plate on the surface facing the base of which four trapezoidal grooves were realized. Such grooves aimed at maintaining the cast obtained from the impression in a stable and repeatable position.

At the corners of both the impression and the pouring carriers, four holes were drilled with a numerical control machine (accuracy  $\pm 0.01$  mm) in order to match the studs of the base and allow the master model to slide onto the impression trays in a constant and reproducible standardized position.

#### Typodont Construction

Two master models were realized following the same laboratory procedures. Each master model was obtained by duplicating an ideal maxillary arch (AG-3 DA Standard Typodont, Frasco, Greenville, NC, USA) from which all teeth but the second premolars, the first, and the second molars had been removed. The residual



**Figure 1** The master model screwed onto the impression carrier of the testing device.

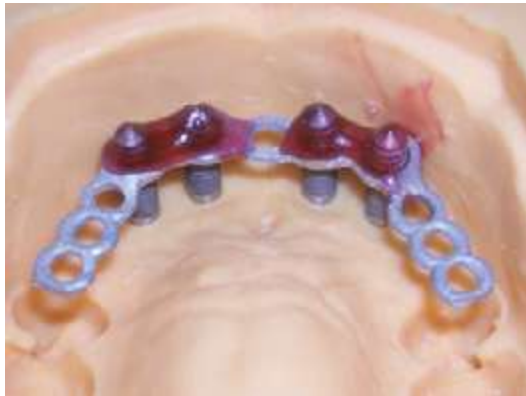sockets were filled with wax so that an anterior partially edentulous ridge was obtained; then an impression with an addition silicon (Elite® Double 22 Fast, Zhermack, Badia Polesine, Italy) was taken to duplicate each master model, and a first working cast was made by pouring into a preformed mold a type III dental stone (Elite® Model Fast, Zhermack), which was vacuum mixed using a mechanical spatulator (Whip Mix Combination Unit, Whip Mix Corporation, Louisville, KY, USA), and was allowed to set according to the manufacturer's instructions. Using a dedicated machine provided with screws blocking a stainless steel probe, the standardized positions of four implant analogues were defined. By means of a vertical milling machine (Alliant vertical milling machine, Alliant, Cincinnati, OH, USA), four holes were cut on both the master models matching the diameter and the length of four  $3.3 \times 13$ -mm standard implant steel analogues (Winsix Implant System, BioSAF, Assago, Italy). The holes were drilled at the top of the edentulous ridge, two with the mesial margin at 2.5 mm from the midline, the other two with their mesial margins at 7 mm from the distal margin of the first ones. The four implant analogues were then secured with cyanoacrylate (910 Metal Bonding General Purpose, Permabond, Pottstown, PA, USA) to each model.

Silicon indexes were used to duplicate each master model and create a second working cast per model as previously described. A gold-alloy cast framework was fabricated for each model and secured to the apical portion of the implants by means of small amounts of pattern resin (Pattern Resin LS, GC Corporation, Tokyo, Japan), in order to block the implant analogues as rigidly as possible minimizing any micromovement during the laboratory procedures (Figure 2).

In the next step, some anatomical undercuts were simulated in the experimental models: the interproximal embrasures between the second premolars and the first and the second molars had been created with a diamond bur; at the same time, a ball-shaped diamond bur with a diameter of 6 mm was used to create a ridge undercut at a distance of 5 mm from the top of the maxillary crest extended from the mesial aspect of tooth 16 to the mesial aspect of tooth 26 and 3-mm deep, breaking the ball-shaped bur through the dental stone for half of its diameter (Figure 3).

The orientations of the holes holding the implant analogues were different in the two master models: in the master model named CTR1, the longitudinal axes of




4 *Clinical Implant Dentistry and Related Research, Volume \*, Number \*, 2009*

**Figure 2** The gold cast framework secured by means of pattern resin rigidly blocking the implants.

implant analogues were parallel to each other and perpendicular to the edentulous plane of the typodont (Figure 4). Conversely, in the master model named CTR2, the longitudinal axes of the anterior implant analogues had 5° convergence toward the midline whereas the longitudinal axes of the posterior implant analogues had 5° divergence away from the midline (Figure 5), thus simulating a less than ideal clinical implant positioning. The differing angle holes were cut with a precision angle block placed in the vice holding the casts.

After checking the correct position and angulation of implant analogues, two definitive casts were fabricated by duplication of the second working models



**Figure 3** Bone undercut (red arrows) at a distance of 5 mm from the top of the maxillary crest extended from the mesial aspect of tooth 15 to the mesial aspect of tooth 25 and 3-mm deep created by means of a ball-shaped diamond bur with a diameter of 6 mm.



**Figure 4** The master model CTR1: the longitudinal axes of implants were parallel to each other and perpendicular to the edentulous plane of the typodont.

using a fast heat-curing transparent acrylic resin (Prothyl Gnathus, Zhermack) whose elastic modulus was the average between those of cortical and spongy bone. In the definitive casts no more implant analogues but 3.3 × 13 mm non-submerged standard implants with an internal hex connection (Winsix Implant System, BioSAF) were used. The four implants in each model were sequentially numbered 1 through 4 from left to right.

The two final master models were labeled and prepared for impressions.

#### Impression Tray Design

A total of 80 stainless steel standard stock trays were used for the study.<sup>58,59</sup> In each tray, seven holes were



**Figure 5** The master model CTR2: the longitudinal axes of the anterior implants had 5° convergence toward the midline whereas the longitudinal axes of the posterior implants had 5° divergence away from the midline.



drilled with the aid of a numerical control machine (accuracy  $\pm 0.01$  mm). Three holes out of seven were realized to perfectly match the pins welded on the base of the testing machine to secure the impression trays in a unique and repeatable position. The other four holes were opened above the impression copings of the master model in order to allow an access to the corresponding coping screws; the position of such holes was determined using silicon indexes. Each hole was 2 mm wider than the impression coping screw diameter.

Each tray was measured and a performance test was rendered to ensure full coupling of the mechanical components.

#### Impression Procedure

On the basis of the type of impression material used, of the connection length and of the implant reciprocal angulation, two control groups and eight experimental groups were considered as shown in Table 1. A sample size of 10 was used in groups 3 to 10, yielding a total of 80 impressions, as described in the following discussion.

As to the impression materials, a polyether<sup>9,41,45,49,51-56</sup> (Impregum Penta™, 3M ESPE, Seefeld, Germany) and an addition silicon<sup>1,42,52,53,57</sup> (Elite® Implant, Zhermack) were selected for the test; both of them were medium consistency (55 shore-A). The impression materials had been stored at  $23 \pm 1^\circ\text{C}$  and  $50 \pm 10\%$  relative humidity in a temperature-controlled room until the tests were performed;<sup>60</sup> all the procedures were carried out in the same experimental conditions.

The impression protocol was standardized as follows. Each tray was locked on the base of the testing machine and was coated with the dedicated adhesive for



**Figure 6** Left panel: the 2-mm standard length impression coping (the same height of the coupling part of the definitive abutments). Right panel: the 1-mm shortened length impression coping.

the polyether (polyether adhesive, 3M ESPE) or for the addition silicon (Universal Tray Adhesive, Zhermack) 1 hour before each impression was made. Each control model, in turn, was screwed on the impression carrier. Eighty sets of four 15-mm metal squared pick-up copings (Winsix Implant System, BioSAF) were used to make the impressions. Two different lengths of the hex connection part of the coping were used (Figure 6): one-half of the sets were provided with the 2-mm standard connection part (the same height of the coupling part of definitive abutments) whereas in the other group the copings were custom-made with a shorter insertion connection, 1-mm long, as recommended by the manufacturer. All impression copings were secured with 22 mm flat-head screws on the implants using a torque wrench calibrated at 15 Ncm; then, the copings were coated with the adhesive dedicated to the impression material used for each set of copings as previously described. Particular care was dedicated to ensure that all components were properly oriented and completely seated.

A stop clock was used to record the necessary time to load and level the impression material in the tray, load a disposable syringe (Ultradent Products, South Jordan, UT, USA), inject the impression material around the copings, seat the tray on the base of the testing machine, and allow for full setting of the impression material.

Forty medium-consistency polyether impressions and forty medium-consistency addition silicon

**TABLE 1** Description of the Experimental Groups

Group	Axis	Transfer	Material
1	Parallel		CTR1
2	Nonparallel		CTR2
3	Parallel	Shortened	Impregum
4	Parallel	Standard	Impregum
5	Nonparallel	Shortened	Impregum
6	Nonparallel	Standard	Impregum
7	Parallel	Shortened	Elite Implant
8	Parallel	Standard	Elite Implant
9	Nonparallel	Shortened	Elite Implant
10	Nonparallel	Standard	Elite Implant

impressions were made in accordance to the manufacturer's directions.

The polyether was machine-mixed (Pentamix™ 2, 3M ESPE) whereas the addition silicon was dispensed by means of the respective auto-mixing cartridge. For each impression, 12 mL of the material were meticulously syringed around and over the copings to ensure a complete coverage of the copings themselves; 35 mL of the same material were used to load and level the impression tray. A whole cartridge of the addition silicon was used (i.e., 50 mL); similarly, the same amount of polyether was calculated by marking the level indicator of the mixing machine.

The impression carrier of the testing machine was lowered over the impression tray until it was completely seated on the spacers positioned on the studs of the base and the tips of the copings protruded through the tray holes. A circular piece of steel weighing 1.5 kg was placed onto the impression carrier to standardize the seating load for each impression.<sup>61,62</sup> The materials were allowed to polymerize for 12 minutes after the start of mix, twice the manufacturer's recommended setting times to compensate for room temperature (23°C), always lower than the intraoral temperature.<sup>16</sup>

Once set, the impression material was trimmed at the border of the tray before the removal to allow boxing of the impressions during pouring. The master model was gently separated from the impression and the latter from the base of the testing machine. Despite the type of impression material, the copings were exposed by means of a blade and removed after the material was completely set, so that they remained in the impression when the tray was gently separated from the model.

The impressions were inspected by means of a stereomicroscope (OPMI PROergo, Carl Zeiss, Aresa, Italy) under  $\times 2.5$  magnification: if any inaccuracy was identified, such as nonhomogeneous mix of the impression materials or air voids, the impression was repeated.

#### Cast Production Procedure

Six hours after the impression, they were rinsed under tap water for 10 seconds, gently dried, and then coated with disinfectant (Sterigum, Zhermack) and surfactant (Tensilab, Zhermack), following the manufacturer's instructions. Then, the screws were placed back into the impression copings from the top of the tray; an implant analogue was connected and tightened to the copings by

means of a calibrated driver. Finally, each impression was locked again on the base of the testing machine.

Block-out material (Wonderfill, Dental Creations Ltd., Waco, TX, USA) was used to block out the junction between the impression copings and implant analogues, in order to easily remove the cast.<sup>4</sup>

Then, 115 g of type III gypsum powder (Elite® Model Fast, Zhermack) were mixed with 35 mL of distilled water using an electronic vacuum mixing machine (Twister Evolution Pro, Renfert GmbH, Hilzingen, Germany) at 250 rpm for 30 seconds and poured into the impression. The impressions were boxed and filled to form a 2-mm thick base. The pouring carrier of the testing machine was placed and maintained in position for the setting time indicated by the manufacturer. After allowing the stone to set for 1 hour, the block-out material was eliminated, the pouring carrier was gently removed, and the cast was carefully separated from the impression. The impression copings were not unscrewed, as they were used as references during measurements. Any debris on the copings was removed.

The casts were trimmed and marked with a code for the measurements; this information was recorded on a sheet and subsequently placed in a sealed envelope. Finally, all models were stored for 48 hours at 23°C and 50% relative humidity prior to measuring.<sup>60</sup>

All clinical and laboratory procedures were performed by the same operator.

#### Measurement Procedure

The study was designed as single blind: all measurements were made by a single calibrated examiner who ignored the previously described information about the code of each cast.

A profile projector (HB 350, Starrett Sigma, North Yorkshire, England) was used to measure linear distances<sup>25,29</sup> (Figure 7). The pouring carrier was secured in the holder of the device and its posterior corner was set parallel to the axis movement of the machine. Each cast was placed on it and maintained in position by means of the four reference grooves previously described.<sup>60</sup> Such a profile projector was provided with a screen with horizontal and vertical reference lines to allow to adjust all models to identical standardized positions, in order to assure that the copings of all casts were at the same level during the measurements. The light source of the device projected a  $\times 10$  magnified image of the cast to be



Figure 7 The profile projector used for the measurements.

measured onto a screen in the form of a shadow, so that the sharp edges of the projected silhouetted of the transfer copings were used as the reference points of measurement.<sup>25,29</sup> The profile projector was provided with an integrated digital readout counter and calibrated to an accuracy of  $\pm 0.5 \mu\text{m}$ .

Four distances were measured on the control acrylic resin models and on the definitive study casts (Figure 8):

- (1) D1 – the distance between the external sharp edges of the projected silhouetted form of the most anterior and the most posterior right impression copings (1 and 2).
- (2) D2 – the distance between the internal sharp edges of the projected silhouetted form of the most anterior left and right impression copings (2 and 3).

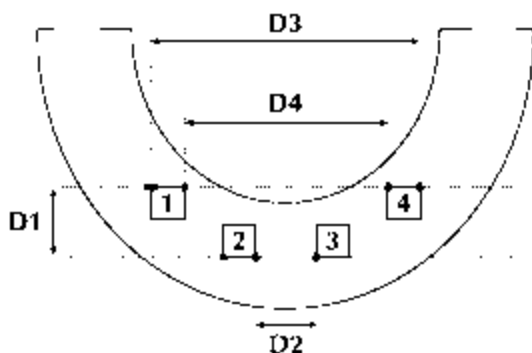


Figure 8 The reference points used to measure the distances D1, D2, D3, and D4 (as described in the text).

- (3) D3 – the distance between the external sharp edges of the projected silhouetted form of the most posterior left and right impression copings (1 and 4).
- (4) D4 – the distance between the internal sharp edges of the projected silhouetted form of the most posterior left and right impression copings (1 and 4).

In the present study, distortion values were determined measuring the absolute values of such distances between the master models and the study casts.

Each dimension was measured three times and the mean was used for the sample value. A 45-minute time limit was observed for each measurement session to prevent eye fatigue.<sup>2,63,64</sup>

In order to assess the intraoperator error variability and to test the reproducibility of the measurements, one experimental model per group was randomly selected and the measurement of D1, D2, D3, and D4 were repeated 2 days later. The envelope containing the meaning of the codes labeled on each cast was opened only after the measurements and relative controls had been completed.<sup>16,50</sup>

### Statistical Analysis

The mean values previously described were considered for the statistical analysis. The Kolmogorov–Smirnov test was used to verify the normality of the data distribution. A three-factor analysis of variance (ANOVA) was used to analyze the recorded data. The considered variables were the type of impression material (polyether vs addition silicon), the angulation of the implants (parallel vs nonparallel), and the length of the connection of the impression copings (2-mm standard vs 1-mm shortened); the interactions between such variables were considered as well. Because there were only two groups within each factor, there was no need to perform post hoc tests for mean differences as any significant main effect would indicate a statistically significant difference between the two groups.<sup>50</sup>

All data were statistically analyzed with a dedicated software (SPSS 16 for MAC OS X, SPSS Inc., Chicago, IL, USA). For all the statistical tests, the level of significance was set at  $p < 0.05$ .

### RESULTS

As to the intraoperator error variability, the standard deviations of the randomly repeated measurements for the distance between the most anterior and the

8 *Clinical Implant Dentistry and Related Research, Volume \*, Number \*, 2009***TABLE 2 Mean Values ( $\pm$ SD) of the Recorded Measurements in Millimeters**

Group	D1 (Anterior–Posterior Distance)	D2 (Mesial Inner Distance)	D3 (Outer Distance)	D4 (Distal Inner Distance)
1	7.37*	8.65*	28.92*	21.38*
2	7.34*	8.72*	29.13*	21.26*
3	7.15 $\pm$ 0.17	9.01 $\pm$ 0.29	28.76 $\pm$ 0.37	20.84 $\pm$ 0.38
4	7.15 $\pm$ 0.17	8.61 $\pm$ 0.16	28.96 $\pm$ 0.21	21.16 $\pm$ 0.15
5	9.11 $\pm$ 0.14	8.99 $\pm$ 0.23	31.97 $\pm$ 0.24	24.37 $\pm$ 0.26
6	9.37 $\pm$ 0.42	8.85 $\pm$ 0.32	32.37 $\pm$ 0.24	24.64 $\pm$ 0.30
7	7.41 $\pm$ 0.22	8.69 $\pm$ 0.25	28.92 $\pm$ 0.30	21.17 $\pm$ 0.37
8	7.31 $\pm$ 0.14	8.69 $\pm$ 0.03	29.19 $\pm$ 0.26	21.40 $\pm$ 0.24
9	9.06 $\pm$ 0.02	8.77 $\pm$ 0.17	32.07 $\pm$ 0.14	24.80 $\pm$ 0.09
10	9.21 $\pm$ 0.11	8.70 $\pm$ 0.18	32.31 $\pm$ 0.34	24.62 $\pm$ 0.30

\*Absolute control values.

most posterior impression copings were  $\pm 0.9 \mu\text{m}$  and  $\pm 1.3 \mu\text{m}$ , respectively.

The absolute control values obtained on the control models and the mean linear measurements and standard deviations of the position of impression copings on the experimental casts are reported in Table 2.

The Kolmogorov–Smirnov test confirmed the normality of the data distribution ( $p > 0.05$ ). The three-way ANOVA revealed significant differences for the angulation of the implants in D1 ( $p < 0.0001$ ), D3 ( $p < 0.0001$ ), and D4 measurements ( $p < 0.0001$ ); no significant differences were evidenced in D2 (Tables 3–6). This dem-

onstrates that the impressions made in the presence of angulated implants were significantly less accurate than the ones made with parallel implants.

As to the interaction effects, statistically significant differences were recorded for angulation/material ( $p = 0.014$ ) and angulation/coping ( $p = 0.048$ ) in D1, material/coping ( $p = 0.015$ ) in D2, and material/coping ( $p = 0.028$ ) in D4 (see Tables 3–6). In the presence of the angulated implants, the impressions made by means of the addition silicon resulted slightly more accurate than those made using the polyether. When the implants were parallel to each other, a standard length of the

**TABLE 3 Results of the Three-Factor Analysis of Variance for D1 Measurements**

Source	Tests of Between-Subjects Effects				
	Type III Sum of Squares	df	Mean Square	F	Sig.
Corrected model	43.164*	11	3,924	151.594	0.000
Intercept	3,251.508	1	3,251.508	12,5614.962	0.000
Material	0.037	2	0.018	0.706	0.500
Angulation	42.676	1	42.676	1,648.710	0.000
Coping	0.030	1	0.030	1.159	0.289
Material/angulation	0.249	2	0.125	4.810	0.014
Material/coping	0.038	2	0.019	0.736	0.486
Angulation/coping	0.108	1	0.108	4.184	0.048
Material/angulation/coping	0.025	2	0.013	0.490	0.617
Error	0.932	36	0.026		
Total	3,295.604	48			
Corrected total	44.096	47			

\* $R^2 = 0.979$  (adjusted  $R^2 = 0.972$ ).

**TABLE 4 Results of the Three-Factor Analysis of Variance for D2 Measurements**

Source	Tests of Between-Subjects Effects				
	Type III Sum of Squares	df	Mean Square	F	Sig.
Corrected model	0.754*	11	0.069	2,125	0.044
Intercept	3,686.384	1	3,686.384	114,235.139	0.000
Material	0.250	2	0.125	3.878	0.996
Angulation	0.060	1	0.060	1.844	0.183
Coping	0.049	1	0.049	1.511	0.227
Material/angulation	0.009	2	0.005	0.146	0.865
Material/coping	0.305	2	0.152	4.725	0.015
Angulation/coping	0.028	1	0.028	0.854	0.362
Material/angulation/coping	0.054	2	0.027	0.831	0.444
Error	1.162	36	0.032		
Total	3,688.300	48			
Corrected total	1.916	47			

\* $R^2 = 0.394$  (adjusted  $R^2 = 0.208$ ).

impression coping internal connection resulted in more precise casts, whereas, in case of tilted implants, shortened length impression copings performed better. As to the material/coping interactions, no significant differences were found using the addition silicon whereas the impressions made by the polyether resulted in more accurate using standard length impression copings.

## DISCUSSION

On the basis of the recorded data, the null hypotheses 1 and 2 were accepted. Conversely, the null hypothesis 3

was rejected as the implant reciprocal angulation had a significant effect on the accuracy of the experimental casts compared with the master models.

As to the intraoperator error variability, the small standard deviations were indicative of the reliability and consistency of the measurement method.

In implant prosthodontics, making a cast reproducing the intraoral position of implants and abutments as accurately as possible is paramount, in order to limit discrepancies in fit, including those not clinically detectable by visual inspection.<sup>1-7,16-20</sup>

**TABLE 5 Results of the Three-Factor Analysis of Variance for D3 Measurements**

Source	Tests of Between-Subjects Effects				
	Type III Sum of Squares	df	Mean square	F	Sig.
Corrected model	125.246*	11	11,386	228,380	0.000
Intercept	44,902.450	1	44,902.450	900,650.884	0.000
Material	0.125	2	0.063	1.258	0.296
Angulation	124.035	1	124.035	2,487.881	0.000
Coping	0.952	1	0.952	19.096	0.933
Material/angulation	0.065	2	0.033	0.656	0.525
Material/coping	0.005	2	0.002	0.046	0.955
Angulation/coping	0.037	1	0.037	0.750	0.392
Material/angulation/coping	0.026	2	0.013	0.265	0.769
Error	1.795	36	0.050		
Total	45,029.491	48			
Corrected total	127.041	47			

\* $R^2 = 0.986$  (adjusted  $R^2 = 0.982$ ).



10 *Clinical Implant Dentistry and Related Research, Volume \*, Number \*, 2009***TABLE 6 Results of the Three-Factor Analysis of Variance for D4 Measurements**

Source	Tests of Between-Subjects Effects				
	Type III Sum of Squares	df	Mean square	F	Sig.
Corrected model	148.064*	11	13.460	259.661	0.000
Intercept	25,285.851	1	25,285.851	487,784.180	0.000
Material	1.022	2	0.511	9.860	0.969
Angulation	146.336	1	146.336	2,822.933	0.000
Coping	0.053	1	0.053	1.016	0.320
Material/angulation	0.044	2	0.022	0.420	0.660
Material/coping	0.412	2	0.206	3.976	0.028
Angulation/coping	0.105	1	0.105	2.035	0.162
Material/angulation/coping	0.092	2	0.046	0.890	0.420
Error	1.866	36	0.052		
Total	25,435.782	48			
Corrected total	149.930	47			

\* $R^2 = 0.988$  (adjusted  $R^2 = 0.984$ ).

Some errors may be introduced during any of the several clinical procedures required, like an improper connection of the components, excessive dimensional changes of the impression materials, minor movements caused by unscrewing of the impression copings, and by the following screwing of the implant analogues.<sup>4,16-20</sup> The clinical significance of the distortion magnitude remains controversial. It is worth highlighting that throughout this study, an exact reproduction of the implant position as recorded on the control models was only once achieved (i.e., D3 in group 7). Clinically, this could mean that completely passive fit of an implant-supported prosthetic superstructure is not attainable yet, despite the impression technique and the laboratory procedures.<sup>4,14-20,32</sup> The clinical experience and skill of the operator still remain the most important variables to be involved.

The proper use of surfactants and disinfectants did not influence the accuracy of the impressions. The application of an adhesive agent between the impression materials and the copings probably had an important role in reducing minor movements during both clinical and laboratory procedures.<sup>25</sup> Both the physical retention to the impression tray and the use of adhesives play an important role in the performance of impression materials. As described in previous studies,<sup>16,50,58,59</sup> in the present investigation stainless steel rigid trays were used to limit impression distortions. Such stock trays were coated with the dedicated adhe-

sive for the polyether or for the addition silicon. It is questionable if both adhesives would perform better in the presence of acrylic resin trays; nevertheless, the purpose of the present investigation was to limit and equalize the multiple variables affecting the precision of impressions.

The mechanical properties of an impression material, such as accuracy and rigidity, may influence the precision of the impression, the cast, and, consequently, final framework.<sup>1,2,41,44,45,49,51</sup> In this study, both polyethers and addition silicones produced similarly accurate casts, as recorded in previous papers.<sup>1,9,41,42,45,49,51-55,57</sup> A parallel positioning of the implants, a condition that is not always clinically achievable because of possible anatomical limitations, eased the removal of impressions, probably reducing the distortions of the material.<sup>1,22,41,42,46,47</sup>

Regarding the direct technique, an impression material should be provided with a sufficient rigidity, in order to hold the copings in their position during the removal force application, thus preventing incidental displacements and ensuring a minimal positional distortion between the laboratory components. Similar to other studies, both the medium body consistency polyether and the addition silicones were found to meet such a requirement. In the literature, the addition silicones showed higher yield strength and modulus of elasticity compared with the polyethers.<sup>1,2,41,44,45,49,51</sup> Some authors described the latter as the first choice for completely

edentulous multi-implant impressions, because of their rigidity, providing resistance to an incidental displacement of the impression copings. Nevertheless, the use of the polyethers in a partially edentulous arch could lead to an increased difficulty for an intraoral removal of the impression.<sup>9,41,45,49,51-55</sup> The addition silicones, because of the more favorable, lower modulus of elasticity, could be considered as a viable alternative allowing for the easy removal of the impression and reducing the permanent deformations caused by the stress between the impression material and the copings,<sup>1,42,52,53,57</sup> particularly when nonparallel implants are present and implants with deep internal connection are used.

The choice of an impression material should be based on the consideration of several variables, like the material accuracy, the amount of intraoral undercuts, the length of time before the impression is poured, and the experience of the clinician.

Anatomical undercuts, which are not infrequent in the clinical reality, require in the clinical practice high impression removal forces, so they were introduced in the experimental models of the present study to simulate a more realistic condition, compared with the use of test smooth, undercut-free models as used in other previous studies. Some criticism, in fact, has been moved to some research models<sup>65,66</sup> in that the removal forces and the consequent impression distortions in the clinical practice were to be considered much higher than the ones applied in the experimental condition, because of the absence of dental or crestal undercuts in the smooth edentulous models.

The design of the coping has to be considered another relevant factor for the impression accuracy.<sup>25</sup> The 1-mm shortened connection length was designed to ease the removal of the copings from the internal connection of the implants, avoiding a deep engagement of the component, a condition that is highly advisable, on the contrary, in the implant/abutment connection design. In this study, the use of a shorter internal connection of the copings resulted advantageous only when using the addition silicon in the presence of nonparallel implants, probably because the shortened connection length compensated for the higher removal stress induced by the implant angulation. On the contrary, in the presence of parallel implants or when polyether was used, the casts resulted more accurate by using standard length copings. This was probably caused by a higher stiffness of the impression materials providing higher

resistance against deformations during implant analogue tightening.<sup>9,41,45,49,51-55</sup>

The extent of the coping length inside the impression material is another factor that seems to play an important role in terms of additional retention and resistance against displacement.<sup>25</sup> Nonetheless, in order to avoid additional sources of measurement error and to ensure a better data reproducibility, the present investigation did not consider the effect of subgingival depth of the implant placement on the accuracy of impressions. Such a topic was recently investigated by authors who did not show any effect of the implant depth on the accuracy of VPSs whereas less accurate impressions were made by means of medium-body polyethers in the presence of deeper implants. As it is not possible to access the subgingival part of the copings, these findings were probably because of the more limited area of the copings embedded in the impression material.<sup>4</sup>

The distortion of the impression is a concern inherent, in a three-dimensional way, in all of the procedures involved in the indirect dental restorations.<sup>50,63,64</sup> It can be regarded as absolute or relative, depending on the point of reference from which it is measured: the absolute distortion is considered when the point of reference is external, whereas a relative distortion is measured from a point that is located internal to the system.<sup>1,9,21,42,47,51,63,64</sup> According to several studies,<sup>9,21,42,47,51</sup> in the present investigation, the relative distortion was considered as a study parameter, as the resultant translational distance was measured from one coping to another. This kind of measurement can be considered more clinically relevant than the absolute distortion, as an implant-supported prosthesis usually connects all the abutments to each other.

Distortion may be negatively affected by the nonparallel positioning of implants as well as by the presence of physical undercuts (i.e., tooth embrasures, bone deformities), as a higher removal strength is needed, affecting the precision of the impressions.

Although not specifically considered in the present investigation, the machining tolerance, defined as the difference in rest positions between the components when they are held in place by their respective fastening screws, might represent another mechanical factor playing an important role in the distortion phenomenon.<sup>67</sup>

Possible limitations of the present study design were that the measured distortions did not completely evaluate the actual three-dimensional distortion of the impressions and the axial rotations of the components were not detected. Moreover, the results of the present investigation were limited to a number of four implants and may not be relevant for impressions made in the presence of higher or lower numbers of implants. Third, only internal connection implants were used, whereas external connections, like the hexagon ones, were not considered.

### CONCLUSIONS

Within the limitations of this study, the following conclusions can be drawn:

- (1) The presence of undercuts negatively affected the precision of the impressions.
- (2) The angulation of the implants may cause strains of impressions, probably because of the higher forces required for the impression removal.
- (3) In the presence of nonparallel implants, the use of addition silicones resulted in more accurate casts, particularly together with a shortened length of the connection part of the copings.
- (4) In the presence of parallel implants or when the polyether was used, a standard length connection of the copings produced more accurate casts.

Further clinical investigations will be necessary to confirm the clinical results of the present *in vitro* study.

### REFERENCES

1. Barrett MG, de Rijk WG, Burgess JO. The accuracy of six impression techniques for osseointegrated implants. *J Prosthodont* 1993; 2:75–82.
2. Wee AG, Aquilino SA, Schneider RL. Strategies to achieve fit in implant prosthodontics: a review of the literature. *Int J Prosthodont* 1999; 12:167–178.
3. Conrad HJ, Pesun IJ, DeLong R, Hodges JS. Accuracy of two impression techniques with angulated implants. *J Prosthet Dent* 2007; 97:349–356.
4. Lee H, Ercoli C, Funkenbusch PD, Feng C. Effect of subgingival depth of implant placement on the dimensional accuracy of the implant impression: an *in vitro* study. *J Prosthet Dent* 2008; 99:107–113.
5. Jemt T. *In vivo* measurements of precision of fit involving implant-supported prostheses in the edentulous jaw. *Int J Oral Maxillofac Implants* 1996; 11:151–158.
6. Jemt T, Rubenstein JE, Carlsson L, Lang BR. Measuring fit at the implant prosthodontic interface. *J Prosthet Dent* 1996; 75:314–325.
7. Pesun IJ. Intrusion of teeth in the combination implant-to-natural-tooth fixed partial denture: a review of the theories. *J Prosthodont* 1997; 6:268–277.
8. Tan KB, Rubenstein JE, Nicholls JI, Yuodelis RA. Three-dimensional analysis of the casting accuracy of one-piece, osseointegrated implant-retained prostheses. *Int J Prosthodont* 1993; 6:346–363.
9. Phillips KM, Nicholls JI, Ma T, Rubenstein JE. The accuracy of three implant impression techniques: a 3-dimensional analysis. *Int J Oral Maxillofac Implants* 1994; 9:533–540.
10. Sahin S, Cehreli MC. The significance of passive framework fit in implant prosthodontics: current status. *Implant Dent* 2001; 10:85–92.
11. Heckmann SM, Karl M, Wichmann MG, Winter W, Graef F, Taylor TD. Cement fixation and screw retention: parameters of passive fit. An *in vitro* study of three-unit implant-supported fixed partial dentures. *Clin Oral Implants Res* 2004; 15:466–473.
12. Ericsson I, Persson LG, Berglundh T, Marinello CP, Lindhe J, Klinge B. Different types of inflammatory reactions in peri-implant soft tissues. *J Clin Periodontol* 1995; 22:255–261.
13. Leonhardt A, Renvert S, Dahlen G. Microbial findings at failing implants. *Clin Oral Implants Res* 1999; 10:339–345.
14. Jemt T, Book K. Prosthesis misfit and marginal bone loss in edentulous implant patients. *Int J Oral Maxillofac Implants* 1996; 11:620–625.
15. Jemt T, Lekholm U, Johansson CB. Bone response to implant-supported frameworks with differing degrees of misfit preload: *in vivo* study in rabbits. *Clin Implant Dent Relat Res* 2000; 2:129–137.
16. Burns J, Palmer R, Howe L, Wilson R. Accuracy of open tray implant impressions: an *in vitro* comparison of stock versus custom trays. *J Prosthet Dent* 2003; 89:250–255.
17. Kohavi D. Complications in the tissue integrated prostheses components: clinical and mechanical evaluation. *J Oral Rehabil* 1993; 20:413–422.
18. Jemt T, Linden B, Lekholm U. Failures and complications in 127 consecutively placed fixed partial prostheses supported by Branemark implants: from prosthetic treatment to first annual checkup. *Int J Oral Maxillofac Implants* 1992; 7:40–44.
19. Kallus T, Bessing C. Loose gold screws frequently occur in full-arch fixed prostheses supported by osseointegrated implants after 5 years. *Int J Oral Maxillofac Implants* 1994; 9:169–178.
20. Tolman DE, Laney WR. Tissue-integrated prosthesis complications. *Int J Oral Maxillofac Implants* 1992; 7:477–484.
21. Carr AB, Master J. The accuracy of implant verification casts compared with casts produced from a rigid transfer coping technique. *J Prosthodont* 1996; 5:248–252.

22. Assif D, Nissan J, Varsano I, Singer A. Accuracy of implant impression splinted techniques: effect of splinting material. *Int J Oral Maxillofac Implants* 1999; 14:885–888.
23. Vigolo P, Majzoub Z, Cordioli G. In vitro comparison of master cast accuracy for single-tooth implant replacement. *J Prosthet Dent* 2000; 83:562–566.
24. Daoudi MF, Setchell DJ, Searson LJ. A laboratory investigation of the accuracy of two impression techniques for single-tooth implants. *Int J Prosthodont* 2001; 14:152–158.
25. Vigolo P, Majzoub Z, Cordioli G. Evaluation of the accuracy of three techniques used for multiple implant abutment impressions. *J Prosthet Dent* 2003; 89:186–192.
26. Akca K, Cehreli MC. Accuracy of 2 impression techniques for ITI implants. *Int J Oral Maxillofac Implants* 2004; 19:517–523.
27. Assuncao WG, Filho HG, Zaniquelli O. Evaluation of transfer impressions for osseointegrated implants at various angulations. *Implant Dent* 2004; 13:358–366.
28. Naconey MM, Teixeira ER, Shinkai RS, Frasca LC, Cervieri A. Evaluation of the accuracy of 3 transfer techniques for implant-supported prostheses with multiple abutments. *Int J Oral Maxillofac Implants* 2004; 19:192–198.
29. Vigolo P, Fonzi F, Majzoub Z, Cordioli G. An evaluation of impression techniques for multiple internal connection implant prostheses. *J Prosthet Dent* 2004; 92:470–476.
30. Vigolo P, Fonzi F, Majzoub Z, Cordioli G. Master cast accuracy in single-tooth implant replacement cases: an in vitro comparison. A technical note. *Int J Oral Maxillofac Implants* 2005; 20:455–460.
31. Cehreli MC, Akca K. Impression techniques and misfit-induced strains on implant-supported superstructures: an in vitro study. *Int J Periodontics Restorative Dent* 2006; 26:379–385.
32. Kan JY, Rungcharassaeng K, Bohsali K, Goodacre CJ, Lang BR. Clinical methods for evaluating implant framework fit. *J Prosthet Dent* 1999; 81:7–13.
33. Jung RE, Pjetursson BE, Glauser R, Zembic A, Zwahlen M, Lang NP. A systematic review of the 5-year survival and complication rates of implant-supported single crowns. *Clin Oral Implants Res* 2008; 19:119–130.
34. Riedy SJ, Lang BR, Lang BE. Fit of implant frameworks fabricated by different techniques. *J Prosthet Dent* 1997; 78:596–604.
35. Jemt T, Linden B. Fixed implant-supported prostheses with welded titanium frameworks. *Int J Periodontics Restorative Dent* 1992; 12:177–184.
36. Schmitt SM, Chance DA. Fabrication of titanium implant-retained restorations with non traditional machining techniques. *Int J Prosthodont* 1995; 8:332–336.
37. Linehan AD, Windeler AS. Passive fit of implant-retained prosthetic superstructures improved by electric discharge machining. *J Prosthodont* 1994; 3:88–95.
38. LaBarge KW. Electrical discharge machining. *J Dent Technol* 1997; 14:19–22.
39. Ortorp A, Jemt T, Bäck T, Jälevik T. Comparisons of precision of fit between cast and CNC-milled titanium implant frameworks for the edentulous mandible. *Int J Prosthodont* 2003; 16:194–200.
40. Kelly JR. Developing meaningful systematic review of CAD/CAM reconstructions and fiber-reinforced composites. *Clin Oral Implants Res* 2007; 18(Suppl 3):205–217.
41. Hsu CC, Millstein PL, Stein RS. A comparative analysis of the accuracy of implant transfer techniques. *J Prosthet Dent* 1993; 69:588–593.
42. Humphries RM, Yaman P, Bloem TJ. The accuracy of implant master casts constructed from transfer impressions. *Int J Oral Maxillofac Implants* 1990; 5:331–336.
43. Daoudi MF, Setchell DJ, Searson LJ. A laboratory investigation of the accuracy of the repositioning impression coping technique at the implant level for single-tooth implants. *Eur J Prosthodont Restor Dent* 2003; 11:23–28.
44. Liou AD, Nicholls JI, Yuodelis RA, Brudvik JS. Accuracy of replacing three tapered transfer impression copings in two elastomeric impression materials. *Int J Prosthodont* 1993; 6:377–383.
45. Carr AB. Comparison of impression techniques for a five-implant mandibular model. *Int J Oral Maxillofac Implants* 1991; 6:448–455.
46. Herbst D, Nel JC, Driessen CH, Becker PJ. Evaluation of impression accuracy for osseointegrated implant supported superstructures. *J Prosthet Dent* 2000; 83:555–561.
47. Spector MR, Donovan TE, Nicholls JI. An evaluation of impression techniques for osseointegrated implants. *J Prosthet Dent* 1990; 63:444–447.
48. Eames WB, Sieweke JC, Wallace SW, Rogers LB. Elastomeric impression materials: effect of bulk on accuracy. *J Prosthet Dent* 1979; 41:304–307.
49. Carr AB. Comparison of impression techniques for a two-implant 15-degree divergent model. *Int J Oral Maxillofac Implants* 1992; 7:468–475.
50. Ceyhan JA, Johnson GH, Lepe X. The effect of tray selection, viscosity of impression material, and sequence of pour on the accuracy of dies made from dual-arch impressions. *J Prosthet Dent* 2003; 90:143–149.
51. Wee AG. Comparison of impression materials for direct multi-implant impressions. *J Prosthet Dent* 2000; 83:323–331.
52. Berg JC, Johnson GH, Lepe X, Adán-Plaza S. Temperature effects on the rheological properties of current polyether and polysiloxane impression materials during setting. *J Prosthet Dent* 2003; 90:150–161.
53. Lu H, Nguyen B, Powers JM. Mechanical properties of 3 hydrophilic addition silicon and polyether elastomeric impression materials. *J Prosthet Dent* 2004; 92:151–154.

14 *Clinical Implant Dentistry and Related Research, Volume \*, Number \*, 2009*

54. Assif D, Fenton A, Zarb G, Schmitt A. Comparative accuracy of implant impression procedures. *Int J Periodontics Restorative Dent* 1992; 12:112–121.
55. Assif D, Marshak B, Schmidt A. Accuracy of implant impression techniques. *Int J Oral Maxillofac Implants* 1996; 11:216–222.
56. Inturregui JA, Aquilino SA, Ryther JS, Lund PS. Evaluation of three impression techniques for osseointegrated oral implants. *J Prosthet Dent* 1993; 69:503–509.
57. Schneider RL, Wee AG. Fabricating low-fusing metal casts for more accurate implant prosthodontics. *J Prosthodont* 1996; 5:301–303.
58. Millstein P, Maya A, Segura C. Determining the accuracy of stock and custom tray impression/casts. *J Oral Rehabil* 1998; 25:645–648.
59. Rueda LJ, Sy-Munoz JT, Naylor WP, Goodacre CJ, Swartz ML. The effect of using custom or stock trays on the accuracy of gypsum casts. *Int J Prosthodont* 1996; 9:367–373.
60. Sedda M, Casarotto A, Raustia A, Borracchini A. Effect of storage time on the accuracy of casts made from different irreversible hydrocolloids. *J Contemp Dent Pract* 2008; 9:59–66.
61. Davis R, Schwartz R, Hilton T. Marginal adaptation of castings made with dual-arch and custom trays. *Am J Dent* 1992; 5:253–254.
62. Davis RD, Schwartz RS. Dual-arch and custom tray impression accuracy. *Am J Dent* 1991; 4:89–92.
63. Nicholls JI. The measurement of distortion: theoretical considerations. *J Prosthet Dent* 1977; 37:578–586.
64. Nicholls JL. The measurement of distortion: concluding remarks. *J Prosthet Dent* 1980; 43:218–223.
65. Dixon DL, Breeding LC, Moseley JP. Custom impression trays. Part II: removal forces. *J Prosthet Dent* 1994; 71:316–318.
66. Sotiriu M, Hobkirk JA. An in vivo investigation of seating and removal forces associated with recording impressions in dentate patients. *J Prosthet Dent* 1995; 74:455–462.
67. Kim S, Nicholls JI, Han CH, Lee KW. Displacement of implant components from impressions to definitive casts. *Int J Oral Maxillofac Implants* 2006; 21:747–755.



Special reprint from

Volume 24 Number 2 2009

# JOMI

The International Journal of  
**ORAL & MAXILLOFACIAL IMPLANTS**

**A Randomized Prospective Multicenter Trial  
Evaluating the Platform-Switching  
Technique for the Prevention of  
Postrestorative Crestal Bone Loss**

Loris Prosper, DMD/Sara Redaelli, DMD/Massimo Pasi, DMD/  
Fernando Zarone, MD, DMD/Giovanni Radaelli, PhD/Enrico F. Gherlone, MD, DMD

**OFFICIAL JOURNAL OF THE ACADEMY OF OSSEointegration**

©2009 Quintessence Publishing Co, Inc.  
[www.quintpub.com](http://www.quintpub.com)

## A Randomized Prospective Multicenter Trial Evaluating the Platform-Switching Technique for the Prevention of Postrestorative Crestal Bone Loss

Loris Prosper, DMD<sup>1</sup>/Sara Redaelli, DMD<sup>2</sup>/Massimo Pasi, DMD<sup>1</sup>/Fernando Zarone, MD, DMD<sup>3</sup>/  
Giovanni Radaelli, PhD<sup>4</sup>/Enrico F. Gherlone, MD, DMD<sup>5</sup>

**Purpose:** The purpose of this study was to evaluate the effectiveness of the platform-switching technique to prevent crestal bone loss following the restoration of dental implants. **Materials and Methods:** This randomized prospective multicenter trial analyzed 60 partially edentulous adults recruited at 12 professional dental centers. Subjects were randomly selected to receive either platform-enlarged or control cylindrical implants in three different surgical procedures: conventional nonsubmerged, submerged, and submerged with a reduced abutment. The primary outcome measure was the change in crestal bone level assessed radiographically 12 and 24 months following placement. Nonparametric analysis of variance for repeated measures (the Friedman test) was used to assess the overall significance over time of the differences among implants in changes in crestal bone levels. Comparisons among and between groups of implants were performed by the nonparametric Friedman and Wilcoxon tests, respectively. In all the analyses an  $\alpha = .05$  was considered significant. **Results:** A total of 360 implants were placed (60 for each group). Three control implants failed during the 2nd year following placement. All submerged and 92% of nonsubmerged platform-enlarged implants exhibited no bone loss. Control implants with an abutment as large as the implant platform exhibited more bone loss than their platform-enlarged counterparts ( $P < .001$ ) or control implants with a reduced abutment ( $P < .001$ ). Submerged implants with an enlarged platform showed better crestal bone preservation than submerged control implants with a reduced abutment ( $P = .06$ ). **Conclusions:** The findings of the current trial indicated that the use of implants with an enlarged platform can result in better preservation of crestal bone as compared with conventional cylindrical implants when a reduced abutment is mounted. *INT J ORAL MAXILLOFACIAL IMPLANTS 2009;24:299-308*

**Key words:** bone loss, crestal bone, dental implants, platform-switching technique

One reference criterion to evaluate implant success includes the assessment of changes in crestal bone level over time.<sup>1-4</sup> This has been the primary diagnostic tool used to characterize peri-implant conditions.<sup>5,6</sup> The etiologic factors asso-

ciated with crestal bone loss have not been comprehensively clarified. The main factors hypothesized to be involved in the process of bone loss include surgical trauma to the periosteum and bone,<sup>7</sup> biomechanical imbalance related to loading,<sup>8</sup> the size of the microgap between the implant and the abutment,<sup>9</sup> bacterial colonization of the implant sulcus,<sup>10</sup> biologic width,<sup>11</sup> and imbalance in the host parasite equilibrium.<sup>12</sup> However, small changes in the crestal bone level following implant placement may not negatively influence implant success.<sup>1,11,13</sup>

Usually, dental implants have been restored using a matched abutment and implant platform. Radiographic bone level measurements have identified a mean bone loss for conventional submerged (two-stage) implants of approximately 2 mm.<sup>1,2,9,10,13</sup> Similar results have been found for nonsubmerged (one-stage) implants.<sup>11,14,15</sup>

The platform-switching effect was first observed in the mid-1980s. At the time, larger-diameter implants

<sup>1</sup>Professor, Department of Dentistry, Vita-Salute University, IRCCS San Raffaele, Milan, Italy.

<sup>2</sup>Assistant, Department of Dentistry, Vita-Salute University, IRCCS San Raffaele, Milan, Italy.

<sup>3</sup>Professor and Head, Department of Fixed Prosthodontics, University of Napoli "Federico II," Napoli, Milan, Italy.

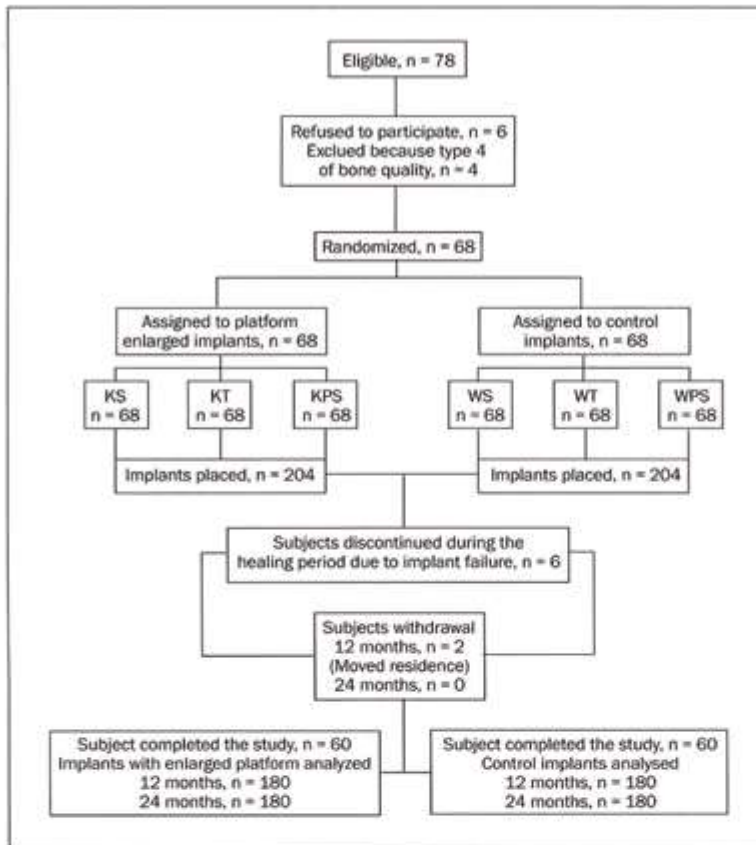
<sup>4</sup>Physicist and Statistician, Unit of Medical Statistics, San Paolo Hospital, University of Milan, Milan, Italy.

<sup>5</sup>Professor and Head, Department of Dentistry, Vita-Salute University, IRCCS San Raffaele, Milan, Italy.

**Correspondence to:** Prof Loris Prosper, Via San Gottardo 84, 20152 Monza (MI), Italy. Fax: +390-39-362766. Email: loris@studioproper.it



Prosper et al



**Fig 1** Progress of participants during the study period. Test implants (enlarged platform): KS = submerged with an abutment matching the implant platform; KT = nonsubmerged; KPS = submerged with a reduced abutment. Control implants: WS = submerged with an abutment matching the implant platform; WT = nonsubmerged; WPS = submerged with a reduced abutment.

were often restored with narrower abutments because congruent abutments were often unavailable. As it later turned out, this was a remarkable coincidence.

In recent years there has been an increase in the use of the so-called "platform-switching" technique in dental practice for esthetic purposes.<sup>16,17</sup> Furthermore, new implants have been purposely designed to include this concept in the implant shape.<sup>18,19</sup>

Recently, Lazzara and Porter<sup>20</sup> conducted a long-term observational analysis. By examining implant radiographs over time, these authors found that the placement of platform-switched implants resulted in a smaller vertical change in the crestal bone level than was typically seen when restoring conventional implants with abutments of matching diameter. However, there is still a lack of literature assessing the platform-switching technique. There is a particular need for randomized prospective trials to objectively evaluate the usefulness of the platform-switching technique in dental implants.

The primary aim of the current prospective study was to evaluate changes in crestal bone levels that occurred during the first 2 years following the placement of implants with enlarged platforms and inserted in the posterior segments of the dentition in three different surgical procedures: submerged and nonsubmerged with matched abutment and implant platform, and submerged with a reduced abutment compared to the implant platform.

## MATERIALS AND METHODS

This randomized prospective clinical study was initially designed to include 78 subjects, all candidates for implant surgery and consecutively admitted, during the period from January 1, 2003, to June 30, 2004, in 12 professional dental centers located in the five major geographic areas of Italy (Fig 1). Each center had to recruit a minimum of six subjects. Inclusion

criteria were: age 25 to 70 years, lack of six posterior teeth (at least one tooth in each posterior quadrant), natural antagonists still present, type 2 or 3 bone quality, no smoking habit, and no alcohol addiction. Exclusion criteria were: previous dental implant surgery, signs or symptoms of temporomandibular disorders, signs of untreated periodontitis or other mucosal and bone tissue lesions, a habit of heavy clenching and/or bruxing, bone defects, poor oral hygiene, neither good nor adequate plaque control, and/or chronic systemic disease. Eligibility criteria were checked at admission and at a presurgical clinical visit performed 7 to 10 days prior to placement of implants. At that time, additional information was collected regarding sociodemographic characteristics and general health. An investigators' meeting was arranged prior to the recruitment of subjects.

Two independent examiners assessed bone quality; each site was evaluated twice on the basis of the Lekholm and Zarb method and classification.<sup>21</sup> If the four evaluations agreed 75% or more of the time, the corresponding bone quality was assumed. If agreement was only 50%, a third independent examiner re-evaluated the site once, and his or her judgment was considered. If agreement was less than 50%, or if at least one of the four evaluations judged the bone quality as type 4, the subject was not included in the trial. The presence of temporomandibular disorders was evaluated in accordance with Wallace and Klineberg.<sup>22</sup> Poor oral hygiene was defined as the subject not brushing the teeth at least once daily and no or only occasional use of floss. Plaque control was assessed with the Mombelli and Lang Index (score 0 to 3).<sup>23</sup>

The study protocol was designed in accordance with the revised Declaration of Helsinki (1998) and approved by the research ethics committee at San Raffaele Hospital, Milan, Italy. The protocol was explained to all participants, who signed an informed consent document.

Subjects were randomly (same chance) assigned to receive each of the six different implant treatments; that is, they received either a platform-enlarged implant or a control implant in one of three different surgical procedures: conventional submerged, conventional nonsubmerged, or submerged with a reduced abutment.

Randomization was done with sealed opaque envelopes containing designations based on within-patient allocation lists randomly computer generated at the permuted block size of 6 and stratified according to center. Participants in the trial were blinded to the assignment, and the statistician analyzing the data was unaware of assignment until the code was broken after the completion of the data analysis.



**Fig 2** (Left) A control implant (length 13 mm, diameter 3.8 mm); (right) a platform-enlarged implant (length 13 mm, platform/screw diameter ratio 4.5/3.8 mm) (magnification 10:1).

### Implants

All implants were manufactured and provided by Winsix Ltd (London, United Kingdom). Control implants consisted of a slightly conical body surrounded by spiral coils. The coils are not of uniform size and therefore have the effect of making the implants cylindrical. Their depth and thickness diminish progressively from the apex to the cervical third, which has no coils and culminates in a circular platform (Fig 2). The implant diameters are 3.3 mm, 3.8 mm, or 4.5 mm.

Implants with an enlarged platform incorporate the platform-switching concept in their geometric shape. These implants consist of a conical body surrounded by progressive coils, which have the effect of making the implants less conical. In addition, they differ at the convex cervical third, which culminates in a larger platform that can move the implant-to-abutment junction medially (Fig 2). In these implants the dimensions of body and neck, respectively, are 3.3 mm/3.8 mm, 3.8 mm/4.5 mm, and 4.5 mm/5.2 mm. In all submerged implants with a reduced abutment, the mismatch between the abutment and the implant platform was, respectively, 3.3 mm/3.8 mm, 3.8 mm/4.5 mm, and 4.5 mm/5.2 mm.

All implants had a sandblasted and acid-etched surface (BioActive Covering SLA, Winsix Ltd). In addition, on the submerged implants the neck was treated and then roughened, whereas on nonsubmerged implants, the collar was machined.



Prosper et al

### Surgical Protocol

The involved centers used the same surgical protocol for each of the six implant treatments. Twelve experienced (> 10 years of surgical practice) practitioners (one at each center) placed implants and restorative abutments. Surgical treatment was carried out under local anesthesia. One hour before surgery, subjects received 2 g of amoxicillin (Augmentin, GlaxoSmithKline, Verona, Italy). Six hours after the completion of implant placement, another 1 g of amoxicillin was administered.

All implants were inserted in healed sites, whether edentulous areas of long standing or postextraction sockets that had healed for at least 3 months. No regenerative procedures were performed in any sites and no countersinking was used because the bone was not too hard (bone quality 2 or 3) and the implants had a threaded shape.

In the submerged (two-stage) procedure, the implants were placed and cover screws mounted. The coronal end of the implant was located at the buccal level of the bone crest. The mucosal flaps were sutured and implants were fully submerged during the healing period. The sutures were removed after 7 to 10 days. At the second stage, abutment connection was performed. The center of a submerged cover screw was detected with a probe, and a 4.0-mm mucosal punch (Astra Tech, Zoetermeer, The Netherlands) was used to remove the covering mucosa. Following surgery, subjects received 15 mL of 12% chlorhexidine gluconate mouthwash (Ebuos, Dentsply Italia, Roma, Italy). Before being discharged, patients were instructed to rinse with the antiseptic twice daily for 1 minute for 15 days.

In the nonsubmerged (one-stage) procedure, the implants were placed with the smooth neck coronal to the alveolar ridge. The soft tissue flaps were adjusted to the implant and sutured. The sutures were removed after 7 to 10 days. The abutment-connecting portion of the implant was exposed to the oral cavity during healing.

In both procedures, abutments were connected to the implants after a healing period of 3 months (mandible) or 6 months (maxilla), in accordance with standard recommendations.<sup>5,24,25</sup>

### Follow-up

Clinical examinations, including evaluation of crestal bone levels, dental history, general health, mobility, oral hygiene, pain, any presence of peri-implant infection, and soft tissue conditions, were clinically assessed at the time of implant placement and 12 and 24 months following placement ( $\pm$  5 days). The success of each implant was further assessed in accordance with Albrektsson and Isidor,<sup>4</sup> Albrektsson et al,<sup>1</sup> and Albrektsson and Zarb.<sup>26</sup>

Crestal bone levels were measured by direct measurements on standardized digital periapical radiographs using a digital radiographic sensor (Digora fmx, Soredex, Tuusula, Finland) with a modified Rinn device (Rinn Corp, Elgin, IL). The distance between the observed crestal bone level and the implant-abutment interface was measured at the distal and mesial surfaces. Additionally, the length (mm) of the implant was measured on the digital radiographs from the implant/abutment interface to the apex of the implant. All measurements were made under 8 $\times$  magnification to the nearest 0.1 mm by the same calibrated examiner, who was blinded to the subjects, using a Digimatic caliper (Mitutoyo, Tokyo, Japan). To adjust the measurements for possible magnification and caliper error, a linear correction was used: (corrected crestal bone level)  $\div$  (measured crestal bone level) = (actual implant length)  $\div$  (measured implant length). The corrected values and the mean of mesial and distal bone levels were used for the analysis. Mucosal inflammation was assessed by the Sulcus Bleeding Index, evaluated in accordance with Mombelli and Lang.<sup>23</sup> Plaque was evaluated by the Mombelli and Lang Index.<sup>23</sup> Percussion and manual manipulation of each implant were also performed, and the implant stability quotient was recorded for each implant as described by Meredith et al.<sup>27</sup> Pain experienced by the subject was evaluated on a 10-cm visual analog scale that ranged from 0 (no pain) to 10 (maximum pain). This method has been used by other authors.<sup>28-30</sup>

### Outcome Measures

The primary outcome measure was the change in mean mesiodistal crestal bone level, as observed at 12 and 24 months after placement of implants. Change was measured in millimeters by arithmetic difference by comparing baseline radiographs to radiographs obtained 12 and 24 months after placement. A negative difference indicated bone loss over time, whereas no negative difference suggested no bone loss over time. The secondary outcome measure was a dichotomized variable defined as bone loss or no bone loss.

### Statistical Analysis

Descriptive data are reported as means and standard deviations or number of cases and percentages. Non-parametric analysis of variance for repeated measures (the Friedman test), including implant treatment as factor and age and sex as covariates, was used to assess the overall significance over time of the differences among implants in changes of crestal bone levels. The changes were categorized as: no change, change between 0.1 and 0.5 mm, change of



**Table 1** Distribution (No. and % Within Groups of Implants) of Implants According to Location

Dental area	Platform-enlarged implants				Control implants			
	KS (n = 60)	KT (n = 60)	KPS (n = 60)	Total (n = 180)	WS (n = 60)	WT (n = 60)	WPS (n = 60)	Total (n = 180)
Maxilla	29 (48.3%)	28 (46.7%)	29 (48.3%)	86 (47.8%)	29 (48.3%)	29 (48.3%)	29 (48.3%)	87 (48.3%)
Right	15 (25.0%)	14 (23.3%)	15 (25.0%)	44 (24.4%)	14 (23.3%)	15 (25.0%)	14 (23.3%)	43 (23.9%)
Left	14 (23.3%)	14 (23.3%)	14 (23.3%)	42 (23.3%)	15 (25.0%)	14 (23.3%)	15 (25.0%)	44 (24.4%)
Mandible	31 (51.7%)	32 (53.3%)	31 (51.7%)	94 (52.2%)	31 (51.7%)	31 (51.7%)	31 (51.7%)	93 (51.7%)
Left	15 (25.0%)	16 (26.7%)	16 (26.7%)	47 (26.1)	15 (25.0%)	15 (25.0%)	16 (26.7%)	46 (25.6%)
Right	16 (26.7%)	16 (26.7%)	15 (25.0%)	47 (26.1)	16 (26.7%)	16 (26.7%)	15 (25.0%)	47 (26.1%)

Platform-enlarged implants: KS = submerged with an abutment matching the implant platform; KT = nonsubmerged; KPS = submerged with a reduced abutment. Control implants: WS = submerged with an abutment matching the implant platform; WT = nonsubmerged; WPS = submerged with a reduced abutment.

No significant differences were seen between platform-enlarged and control implants in the distribution of the number of implants with respect to location for any restorative procedure ( $P = .783$ ).

**Table 2** Distribution (No. and % Within Groups) of Implants According to Diameter and Length

Dental area	Platform-enlarged implants				Control implants			
	KS (n = 60)	KT (n = 60)	KPS (n = 60)	Total (n = 180)	WS (n = 60)	WT (n = 60)	WPS (n = 60)	Total (n = 180)
Diameter (mm)								
3.3	16 (26.7%)	15 (25.0%)	—	31 (17.2%)	15 (25.0%)	15 (25.0%)	—	30 (16.7%)
3.8	27 (45.0%)	16 (26.7%)	30 (50.0%)	73 (40.6%)	26 (43.3%)	27 (45.0%)	30 (50.0%)	83 (46.1%)
4.5	17 (28.3%)	29 (48.3%)	30 (50.0%)	76 (42.2%)	19 (31.7%)	18 (30.0%)	30 (50.0%)	67 (37.2%)
Length (mm)								
11	25 (41.7%)	22 (36.7%)	24 (40.0%)	71 (39.4%)	26 (43.3%)	22 (36.7%)	26 (43.3%)	74 (41.1%)
13	29 (48.3%)	24 (40.0%)	36 (60.0%)	89 (49.9%)	29 (48.3%)	30 (50.0%)	34 (56.7%)	93 (51.7%)
15	6 (10.0%)	14 (23.3%)	—	20 (11.1%)	5 (8.3%)	8 (13.3%)	—	13 (7.2%)

Platform-enlarged implants: KS = submerged with an abutment matching the implant platform; KT = nonsubmerged; KPS = submerged with a reduced abutment. Control implants: WS = submerged with an abutment matching the implant platform; WT = nonsubmerged; WPS = submerged with a reduced abutment.

No significant differences were seen between platform-enlarged and control implants in the distribution of implants with respect to diameter ( $P > .821$ ) or length ( $P > .316$ ) in any restorative procedure.

0.6 to 1 mm, change of 1.1 to 1.5 mm, and change of more than 1.6 mm. Comparisons among and between groups of implants were performed by the nonparametric Friedman and Wilcoxon tests, respectively. Association between confounding factors was assessed by means of the chi-square test. Sample size was determined to guarantee an approximate power of 0.80 and a significance of  $\alpha = .05$  for the Wilcoxon test.<sup>31,32</sup> Significance of multiple comparisons was adjusted by means of the Bonferroni method. SPSS software, version 14.0 (SPSS Inc, Chicago, IL), was used for the statistical analyses.

## RESULTS

Of the 78 eligible subjects, six (two women, four men) declined to participate, and four subjects (all women) were excluded during surgery because their bone quality was determined to be type 4. Thus, a total of 68 subjects were randomized and entered the trial,

receiving a total of 408 implants. Six subjects discontinued the study during the healing period following the failure of six implants (two submerged implants with enlarged platforms, two conventional submerged implants, and two nonsubmerged control implants) and they were excluded from the 2-year analyses to remove possible biases related to re-intervention. This low percentage of early failures is within the range of findings from previous studies.<sup>33-35</sup> Another two subjects withdrew prior to 12 months of follow-up. Therefore, a total of 60 subjects were analyzed, with 360 implants (Fig 1).

Among the analyzed subjects, 28 (46.7%) were women and 32 (53.3%) were men. The mean patient age was 53.9 years (SD 6.8), with 11.66% of patients  $\leq 40$  years of age, 20% of patients 41 to 50, 38.33% of patients 51 to 60, and 30% of patients  $\geq 61$ .

The distribution of the 360 implants by location is shown in Table 1. One hundred seventy-three (48.1%) implants were placed in the maxilla (86 with enlarged platforms and 87 controls), and 187 (51.9%)

Prosper et al

**Table 3** Differences in Postrestorative Crestal Bone Loss with Respect to Gender and Age

Time	12 mo		24 mo	
	P (gender)*	P (age)*	P (gender)*	P (age)*
Platform-enlarged implants				
KS	1.000	1.000	1.000	1.000
KT	.616	.300	.357	.732
KPS	1.000	1.000	1.000	1.000
Control implants				
WS	.789	.953	.789	.849
WT	.372	.411	.905	.934
WPS	.493	.759	.662	.656

Platform-enlarged implants: KS = submerged with an abutment matching the implant platform; KT = nonsubmerged; KPS = submerged with a reduced abutment. Control implants: WS = submerged with an abutment matching the implant platform; WT = nonsubmerged; WPS = submerged with a reduced abutment.

\*Dependence of postrestorative crestal bone loss on gender and age. Significance was assessed by means of the Wilcoxon test, and *P* values are reported for each condition considered separately. No significant differences were seen between platform-enlarged and control implants in the distribution of implants with respect to diameter ( $P > .921$ ) or length ( $P > .316$ ) in any restorative procedure.

were placed in the mandible (94 with enlarged platform and 93 controls). With respect to bone quality, 46.7% of the implants were placed in type 2 bone and 53.3% were placed in type 3 bone. The block randomization resulted in a similar distribution of implants with respect to the dental area of placement ( $P = .783$ ) and bone quality ( $P = .531$ ). Table 2 shows the distribution of the implants according to diameter and length. No significant difference was observed between platform-enlarged implants and control implants ( $P = .316$ ). There was no evidence of an association between crestal bone loss and either sex or age distribution (Table 3).

No significant difference between changes in mesial or distal bone level occurred at any time for any group of implants ( $P = .310$ ). Table 4 reports the mean mesiodistal changes in crestal bone levels observed at 12 and 24 months after placement, according to type of implant and surgical procedure. Twenty-four months after placement, crestal bone loss was greater than 1.5 mm around three (0.8%) implants (losses of 1.8 mm and 2.3 mm around two conventional submerged control implants and 1.8 mm around one nonsubmerged control implant). During the second year following placement, these implants showed additional bone loss of, respectively, 0.9, 1.5, and 0.4 mm and were considered as failures according to standard criteria.<sup>1-4,26</sup> In addition, the two failed submerged implants showed reduced implant stability, but they continued functioning without pain or inflammation. The increased

bone loss probably was a result of overloading caused by minor premature contact.

During the second year following placement, none of the remaining implants showed a bone loss of more than 0.2 mm. At 12 and 24 months after placement, none of submerged implants with the enlarged platform showed any bone loss. Mean ( $\pm$  SD) bone loss in nonsubmerged implants with the enlarged platform was  $0.021 \pm 0.110$  mm at 12 months and  $0.055 \pm 0.234$  mm at 24 months. In control implants, mean ( $\pm$  SD) crestal bone loss at 12 and 24 months was  $0.272 \pm 0.367$  mm and  $0.275 \pm 0.467$  mm,  $0.013 \pm 0.091$  mm and  $0.045 \pm 0.227$  mm, and  $0.101 \pm 0.274$  mm and  $0.193 \pm 0.474$  mm, respectively, for submerged implants, submerged implants with a reduced abutment, and nonsubmerged implants. The large standard deviations in control implants suggest wide intersubject variability.

Univariate analysis revealed no statistically significant differences in bone loss levels between genders and ages in all the implants considered at either 12 or 24 months. Analysis of variance for repeated measures, including implant group as a factor, showed a significant difference among groups in bone level change over time ( $P < .001$ ). Crestal bone loss was greater in control submerged or nonsubmerged implants than in the corresponding enlarged-platform implants at both 12 and 24 months after placement ( $P = .01$ ). No significant difference was found between platform-enlarged implants and control implants with a reduced abutment placed using the submerged procedure. An analysis of the platform-enlarged implants showed that in these implants, no increase in bone loss occurred from 12 to 24 months following placement ( $P = .117$ ). Moreover, no significant difference in bone loss occurred among surgical procedures at 12 months. At 24 months, bone loss was slightly greater in nonsubmerged than in submerged implants (crude  $P = .038$ ), but the difference was not significant after adjusting for multiple comparisons ( $P = .111$ ). In control implants, crestal bone loss was significantly lower in submerged implants with the reduced abutment than in submerged or nonsubmerged implants at 12 months and 24 months ( $P = .01$ ) after placement. A statistical but clinically irrelevant increase in bone loss was observed from 12 to 24 months after placement in conventional submerged and nonsubmerged implants ( $P = .05$ ). The change was not significant in submerged implants with a reduced abutment.

The percentage of implants with no crestal bone loss was higher for platform-enlarged implants than for control implants at both 12 (98.3% vs 66.1%;  $P < .001$ ) and 24 months (97.2 vs 53.3%;  $P < .001$ ) following placement. The rate of no bone loss was 100% for



**Table 4** Comparison of Crestal Bone Loss (No. and % of Implants) and Surgical Procedures

Implant type/ bone loss (mm)	12 mo				24 mo			
	S	T	PS	P <sup>†</sup>	S	T	PS	P <sup>†</sup>
<b>Platform-enlarged implants</b>								
≤ 0	60 (100%)	57 (95.0%)	60 (100%)		60 (100%)	55 (91.7%)	60 (100%)	
0.1-0.5	—	3 (5.0%)	—		—	3 (5.5%)	—	
0.6-1.0	—	—	—	.050	—	2 (3.3%)	—	.007
1.1-1.5	—	—	—		—	—	—	
≥ 1.6	—	—	—		—	—	—	
<b>Control implants</b>								
≤ 0	28 (46.7%)	36 (60.0%)	58 (96.7%)		24 (40.0%)	26 (43.3%)	56 (93.3%)	
0.1-0.5	17 (28.3%)	13 (21.7%)	2 (3.3%)		17 (28.3%)	12 (20.0%)	2 (3.3%)	
0.6-1.0	15 (25.0%)	—	—	<.0001	15 (25.0%)	11 (18.3%)	2 (3.3%)	<.0001
1.1-1.5	—	1 (1.7%)	—		2 (3.3%)	—	—	
≥ 1.6	—	—	—		2 (3.3%)	1	—	
P <sup>†</sup>	.0006	.0180	.9420		.0006	.0006	.3540	

S = submerged with an abutment matching the implant platform; T = nonsubmerged; PS = submerged with a reduced abutment.

<sup>†</sup>Differences among surgical procedures in platform-enlarged and control implants (Friedman test). Significant difference between control PS and S and T at 12 and 24 months ( $P < .01$ ) and between control S and T at 12 months ( $P < .05$ ); no other significant difference between subgroups in platform-enlarged implants or controls (Wilcoxon test and Bonferroni adjustment).

<sup>†</sup>Differences between platform-enlarged and control implants (Wilcoxon test and Bonferroni adjustment).

submerged platform-enlarged implants, and it was 100% at 12 months for submerged control implants with a reduced abutment (93.3% at 24 months). At 12 and 24 months for control conventional submerged implants and for nonsubmerged implants, the rate of no bone loss was around 40% to 60%, significantly lower than in platform-switched implants ( $P < .001$ ). Twenty-four months following placement, the difference between platform-enlarged implants and control implants with a reduced abutment was borderline statistically significant ( $P = .06$ ).

Finally, in the whole sample of implants, the mean values for the Mombelli Plaque Index were 0.17, 0.22, and 0.16 at the presurgical visit and at 12 and 24 months after placement, respectively. The modified Sulcus Bleeding Index did not change significantly throughout the study period. Mean values for implant stability quotients and pain did not differ among groups of implants throughout the study period, ranging from  $57.4 \pm 6.7$  to  $59.8 \pm 7.1$  and from  $1.2 \pm 0.8$  to  $1.5 \pm 1.1$ , respectively.

## DISCUSSION

This is the first randomized prospective study investigating whether the platform-switching technique may be used to prevent crestal bone loss around dental implants during the first 2 years following placement. The trial recruited adult subjects through 12 professional dental centers in Italy. Eligibility was

strictly assessed by criteria currently used in dental research. Presurgical, surgical, and clinical examinations were performed in accordance with predefined standardized protocols, and internationally accepted procedures were used. The participation rate was acceptably high (92.3%), and only 2.9% of the analyzed subjects withdrew.

A total of 360 implants were placed (60 for each group). Three control implants failed during the second year following placement. All submerged implants and 92% of the nonsubmerged platform-enlarged implants exhibited no bone loss. Control implants with an abutment that matched the implant platform exhibited more bone loss than their platform-enlarged counterparts ( $P < .001$ ) or control implants with a reduced abutment ( $P < .001$ ). Submerged implants with the enlarged platform showed better crestal bone preservation than submerged control implants with a reduced abutment ( $P = .06$ ).

Regarding bone classification, considered very important for the present study, Shapurian et al<sup>36</sup> showed that, when bone loss quality is assessed based on the Lekholm and Zarb classification, intraexaminer variability is small and the judgment of different examiners is moderately correlated, although examiners may disagree significantly. The procedure adopted in the present study allowed for a further reduction in possible misclassifications and was felt to be sufficient for the trial. Moreover, subjective evaluations based on the Lekholm and Zarb classification are commonly used in clinical practice.<sup>37-39</sup>

Prosper et al

The main findings of the current trial demonstrated that the platform-switching technique, in comparison to conventional surgical protocols that restore implants with abutments of matching diameter, results in significantly less crestal bone loss ( $P < .001$ ). The present study additionally disclosed two other major results. First, irrespective of surgical placement protocol (two-stage or one-stage), implants with an enlarged platform that incorporated the platform-switching concept in their shape exhibited little to no bone loss during the first 2 years following placement ( $\leq 0.6$  mm); furthermore, 2 years after placement implants with an enlarged platform that were placed with the submerged procedure performed slightly better than controls with a reduced abutment mounted (no loss vs 0.4 mm of loss). Second, the lower intersubject variability observed in platform-enlarged implants compared to controls suggests a more homogeneous response of the bone to platform-enlarged implants than conventional cylindrical implants.

Concerning implants with an enlarged platform, an additional important result from the present study was that none of the submerged implants showed any peri-implant crestal bone loss during the 2-year study, whether the implants had a matching widened platform or a reduced abutment. This may suggest that the positive effect of the platform-switching technique is mostly related to the implant shape. This conclusion is further supported by the observation that in control (cylindric) implants, the effect of using an abutment smaller than the implant diameter in preserving the crestal bone level was considerable but not as pronounced as that seen in platform-enlarged implants: the rates of no bone loss 24 months following submerged placement of platform-enlarged or control implants were 100% and 93%, respectively. In addition, a recent report<sup>40</sup> showed that the use of tapered implants could reduce peak stresses in both cortical and trabecular bone. This has not been associated with restorative bone resorption, but a relationship between these factors could be realistically hypothesized.

Nonsubmerged implants exhibited a high rate of no bone loss (92% at 2 years), and none of these implants showed a bone loss greater than 1 mm. Lastly, both submerged and nonsubmerged platform-enlarged implants showed stable marginal bone levels. This finding is in accordance with data from previous studies conducted with conventional implants.<sup>35,41-44</sup>

With regard to the control (cylindric) implants, the most important observation was the positive significant effect on bone levels of mounting an abutment that is reduced with respect to platform diameter. This result supports the validity of the observational data of Lazzara and Porter<sup>20</sup> and further stresses the importance of the platform-switching technique for standard cylindrical implants. The other findings of the current study and concerning conventionally restored control implants are in accordance with the current literature. Mean values for bone loss were within the range of commonly reported values,<sup>35,41-48</sup> as was the rate of no bone loss.<sup>41,46</sup> However, in the current study conventional submerged control implants showed slightly greater bone loss than nonsubmerged implants at 12 months following placement (0.27 vs 0.10 mm), and this differed in part from previous data.<sup>41,49</sup> However, it should be noted that this difference was clinically insignificant and had disappeared by 24 months (0.27 vs 0.23 mm).

Recent literature<sup>17,20</sup> has shown that many parameters are important in preserving crestal bone loss around dental implants. Among these factors are the platform-switching concept and surface topography (microstructure and nanostructure). There is also some evidence from these studies that the rough surface of the implant neck in submerged implants might positively affect postrestorative bone resorption. Future studies should account for these factors, and further prospective randomized trials must also evaluate the long-term effectiveness of the platform-switching technique in preventing crestal bone loss and its effectiveness in the general population, including subjects with low bone quality and/or who exhibit potentially unfavorable factors such as temporomandibular disorders, bruxism, or smoking.

## CONCLUSION

This randomized prospective study revealed that the use of the platform-switching concept and of implants with an enlarged platform, as compared to cylindrical implants inserted with conventional surgical protocols and with abutments of matching diameter, significantly reduced postrestorative crestal bone loss when placed in both two-stage and one-stage techniques. Moreover, it seemed that the positive effect of the platform-switching concept was stronger when implemented on implants with an enlarged platform.



## REFERENCES

- Albrektsson T, Zarb GA, Worthington P, Eriksson AR. The long-term efficacy of currently used dental implants: A review and proposed criteria for success. *Int J Oral Maxillofac Implants* 1986;1:11–25.
- Smith DE, Zarb GA. Criteria for success osseointegrated endosseous implants. *J Prosthet Dent* 1989;62:567–572.
- Buser D, Weber HP, Lang NP. Tissue integration of non-submerged implants. 1-year results of a prospective study with 100 ITI hollow-cylinder-screw implants. *Clin Oral Implants Res* 1990;1:33–40.
- Albrektsson T, Isidor F. Consensus report: Implant therapy. In: Lang NP, Karring T (eds). *Proceedings of the 1<sup>st</sup> European Workshop on Periodontology*. Berlin: Quintessence, 1993: 365–369.
- Brånemark P-I, Hansson BO, Adell R, et al. Osseointegrated implants in the treatment of the edentulous jaw. Experience from a 10-year period. *Scand J Plast Reconstr Surg* 1977;16 (suppl):1–132.
- Adell R, Lekholm U, Rockler B, Brånemark P-I. A 15-year study of osseointegrated implants in the treatment of the edentulous jaw. *Int J Oral Surg* 1981;10:387–416.
- Gomez-Roman G. Influence of flap design on peri-implant interproximal crestal bone loss around single-tooth implants. *Int J Oral Maxillofac Implants* 2001;16:61–67.
- Rangert B, Jemt T, Journeus L. Forces and moments on Brånemark implants. *Int J Oral Maxillofac Implants* 1989;4:241–247.
- Hermann JS, Schoolfield JD, Buser D, Schenk RK, Cochran DL. Influence of the size of the microgap on crestal bone changes around titanium implants: A histometric evaluation of unloaded non-submerged implants in the canine mandible. *J Periodontol* 2001;72:1372–1383.
- Eriksson I, Persson LG, Berglundh T, Marinello CP, Lindhe J, Klinge B. Different types of inflammatory reactions in peri-implant soft tissues. *J Clin Periodontol* 1995;22:255–261.
- Cochran DL, Hermann JS, Schenk RK, Higginbottom FL, Buser D. Biologic width around titanium implants: A histometric analysis of the implant-to-gingival junction around unloaded and loaded non-submerged implants in the canine mandible. *J Periodontol* 1997;68:186–198.
- Mombelli A, Lang NP. The diagnosis and treatment of peri-implantitis. *Periodontology* 2000 1998;17:63–76.
- Hermann JS, Schoolfield JD, Nummikoski PV, Buser D, Schenk RK, Cochran DL. Crestal bone changes around titanium implants: A methodologic study comparing linear radiographic with histometric measurements. *Int J Oral Maxillofac Implants* 2001;16:475–485.
- Hermann JS, Buser D, Schenk RK, Schoolfield JD, Cochran DL. Biologic width around one- and two-piece titanium implants. A histometric evaluation of unloaded nonsubmerged and submerged implants in the canine mandible. *Clin Oral Implants Res* 2001;12:559–571.
- Karoussis IK, Brägger U, Salvi GE, Bürgin W, Lang NP. Effect of implant design on survival and success rates of titanium oral implants: A 10-year prospective cohort study of the ITIs Dental Implant System. *Clin Oral Implants Res* 2004;15:8–17.
- Gardner DM. Platform-switching as a means to achieving implant esthetics. *N Y State Dent J* 2005;71:34–37.
- Herrmann F, Lerner H, Palti A. Factors influencing the preservation of the periimplant marginal bone. *Implant Dent* 2007;16: 165–175.
- Baumgarten H, Cocchetto R, Testori T, Meltzer A, Porter S. New implant design for crestal bone preservation: Initial observations and case report. *Pract Proced Aesthet Dent* 2005;17:735–740.
- Carpentieri JR. Introducing the Certain PREVAIL Implant: Designed for preservation of crestal bone. *The 3innovations Enewsletter* 2006;1:5. Available at <http://www.3i-online.com>.
- Lazzara RJ, Porter SS. Platform-switching: A new concept in implant dentistry for controlling postrestorative crestal bone levels. *Int J Periodontics Restorative Dent* 2006;26:9–17.
- Lekholm U, Zarb GA. Patient selection and preparation. In: Brånemark P-I, Zarb GA, Albrektsson T (eds). *Tissue-Integrated Prostheses: Osseointegration in Clinical Dentistry*. Chicago: Quintessence, 1985:199–209.
- Wallace C, Klineberg UJ. Management of craniomandibular disorders. Part II: Clinical assessment of patients with craniocervical dysfunction. *J Orofac Pain* 1994;8:42–54.
- Mombelli A, Lang NP. Clinical parameters for the evaluation of dental implants. *Periodontology* 2000 1994;4:81–86.
- Brånemark P-I, Adell R, Breine U, Hansson BO, Lindström J, Ohlsson A. Intraosseous anchorage of dental prostheses. I. Experimental studies. *Scand J Plast Reconstr Surg* 1969;3:81–100.
- Schroeder A, van den Zypen E, Stich H, Sutter F. The reaction of bone, connective tissue and epithelium to endosteal implants with titanium-sprayed surfaces. *J Maxillofac Surg* 1981;9:15–25.
- Albrektsson T, Zarb GA. Current interpretations of the osseointegrated response: Clinical significance. *Int J Prosthodont* 1993;6:95–105.
- Meredith N, Book K, Friberg B, Jemt T, Sennerby L. Resonance frequency measurements of implant stability in vivo. A cross-sectional and longitudinal study of resonance frequency measurements on implants in the edentulous and partially dentate maxilla. *Clin Oral Implants Res* 1997;8:226–233.
- Eli I, Bath R, Kozlovsky A, Simon H. Effect of gender on accurate pain prediction and memory periodontal surgery. *Eur J Oral Sci* 2000;108:99–103.
- Eli I, Schwartz-Arad D, Bath R, Ben-Tuvim H. Effect of anxiety on the experience of pain in implant insertion. *Clin Oral Implants Res* 2003;14:115–118.
- Fortin T, Bosson JL, Isidori M, Blanchet E. Effect of flapless surgery on pain experienced in implant placement using an image-guided system. *Int J Oral Maxillofac Implants* 2006;21:298–304.
- Noether GE. Sample size determination for some common nonparametric tests. *J Am Stat Assoc* 1987;82:645–647.
- Shieh G, Jan SL, Randles H. On power and sample size determinations for the Wilcoxon–Mann-Whitney test. *Nonparametric Stat* 2006;18:33–43.
- Adell R, Eriksson B, Lekholm U, Brånemark P-I, Jemt T. Long-term follow-up study of osseointegrated implants in the treatment of totally edentulous jaws. *Int J Oral Maxillofac Implants* 1990;5:347–359.
- Friberg B, Jemt T, Lekholm U. Early failures in 4,641 consecutively placed Brånemark dental implants: A study from stage 1 surgery to the connection of completed prostheses. *Int J Oral Maxillofac Implants* 1991;6:142–146.
- Becker W, Becker BE, Israelson H, et al. One-step surgical placement of Brånemark implants: A prospective multicenter clinical study. *Int J Oral Maxillofac Implants* 1997;12:454–462.
- Shapurian T, Damoullis PD, Reiser GM, Griffin TJ, Rand WM. Quantitative evaluation of bone density using the Hounsfield Index. *Int J Oral Maxillofac Implants* 2006;21:290–297.
- Jaffin RA, Berman CL. The excessive loss of Brånemark fixtures in type IV bone: A 5-year analysis. *J Periodontol* 1991;62:2–4.



Prosper et al

38. Trisi P, Rao W. Bone classification: Clinical-histomorphometric comparison. *Clin Oral Implants Res* 1999;10:1-7.
39. Engquist B, Bergendal T, Kallus T, Linden U. A retrospective multicenter evaluation of osseointegrated implants supporting overdentures. *Int J Oral Maxillofac Implants* 1988;3:129-134.
40. Huang HL, Chang CH, Hsu JT, Fallgatter AM, Ko CC. Comparison of implant body designs and threaded designs of dental implants: A 3-dimensional finite element analysis. *Int J Oral Maxillofac Implants* 2007;22:551-562.
41. Cecchinato D, Olsson C, Lindhe J. Submerged or non-submerged healing of endosseous implants to be used in the rehabilitation of partially dentate patients. *J Clin Periodontol* 2004;31:299-308.
42. Bernard JP, Belser UC, Martinet JP, Borgis SA. Osseointegration of Brånemark fixtures using a single-step operating technique. A preliminary prospective 1-year study in the edentulous mandible. *Clin Oral Implants Res* 1995;6:122-129.
43. Becker W, Becker BE, Ricci A, et al. A prospective multicenter clinical trial comparing one- and two-stage titanium screw-shaped fixtures with one-stage plasma-sprayed solid-screw fixtures. *Clin Implant Dent Relat Res* 2000;2:159-165.
44. Engquist B, Åstrand P, Dahlgren S, Engquist E, Feldmann H, Grondahl K. Marginal bone reaction to oral implants: A prospective comparative study of Astra Tech and Brånemark System implants. *Clin Oral Implants Res* 2002;13:30-37.
45. Becker W, Goldstein M, Becker BE, Sennerby L. Minimally invasive flapless implant surgery: A prospective multicenter study. *Clin Implant Dent Relat Res* 2005;7(suppl 1):S21-S27.
46. Hellden L, Ericson G, Elliot A, et al. A prospective 5-year multicenter study of the Cresco implantology concept. *Int J Prosthodont* 2003;16:554-562.
47. Davarpanah M, Martinez H, Etienne D, et al. A prospective multicenter evaluation of 1,583 3i implants: 1- to 5-year data. *Int J Oral Maxillofac Implants* 2002;17:820-828.
48. Weber HP, Crohin CC, Fiorellini JR. A 5-year prospective clinical and radiographic study of non-submerged dental implants. *Clin Oral Implants Res* 2000;11:144-153.
49. Abrahamsson I, Berglundh T, Moon IS, Lindhe J. Peri-implant tissues at submerged and non-submerged titanium implants. *J Clin Periodontol* 1999;26:600-607.



### Conical implant

- Submerged with 0.5mm aesthetic collar
- Apical convergences of the roots
- Tapered bony crests
- Reduced tailspin turns

### Cylindrical implant

- Submerged with 0.5mm aesthetic collar
- Slot on the crest with micro rough surface to promote bone healing
- Differentiated depth coil for modulating the primary stability in surgical phase
- Semispherical apex ideal for maxillary sinus lift

### KT Implant

- One-stage Cylindrical system with 1.3 mm neck.
- Prosthetic platform switched the following diameter
- Self-tapping coil with differentiated depth and thickness, modulating the primary stability in the surgical phase and obtaining, in any type of bone, an optimal primary stability.
- Excellent for immediate loading.
- Semispherical apex ideal for maxillary sinus lift

### K Implant

- 0.3 mm aesthetic collar
- Microslot to increase bone stability.
- Self-tapping coil with differentiated depth and thickness, modulating the primary stability in surgical phase and obtaining, in any type of bone, an optimal primary stability.
- Excellent for immediate loading.
- Semispherical apex ideal for maxillary sinus lift

### PLUS WINSIX

- Innovation and reliability
- Convenience and simplicity
- Wide range of surgical and prosthetic solutions in a single implant system
- Constant scientific research
- Wide range of diameters and lengths
- Single prosthetic connection for all implants (deep 3 mm)
- 2 mm fixing screw diameter
- Adjustable primary stability
- Unified hexagon for all diameters
- Prosthetic components show a unified hexagon, in order to use them with only one prosthetic key
- In order to simplify clinical and laboratory procedures, all components associated to the implant show a color code
- Free Tense System® (System of direct passivation)
- Winsix BioActive Covering SLA® (SLA Surface)
- Winsix FCC® - Full Contact Covering (Electrochemical Surface)

	KT	KT-K-CIL-CON.	KT-K-CIL-CON.	KT-K-CIL-CON.	KT-K-CIL-CON.	CIL
KT-K-CIL-CON. 3,3	7	9	11	13	15	17
KT-K-CIL-CON. 3,8	7	9	11	13	15	17
KT-K-CIL-CON. 4,5	7	9	11	13	15	17
KT-K 5,2	7	9	11	13	15	
KT-CIL 5,9	7	9	11	13		

Diameters and lengths in mm

# winsix®

## Implant System

distributed by  
**BioSAFTN**

BioSAFIN S.r.l.  
via Azzogno, 15 | 60122 Ancona (AN) | Italy  
tel. +39 071 2071897 (na) | fax +39 071 203261  
e-mail: internazionale@bio-saf.com | web: www.bio-saf.com

**Silence**  
A journal of RNA regulation  
A new open access journal launching soon

BMC Biotechnology  
Open Access  
Log on / register  
Feedback | Support | My details

### Isolation of osteogenic progenitors from human amniotic fluid using a single step culture protocol

Ivana Antonacci<sup>1,2</sup>, Irene Izzi<sup>3</sup>, Elisena Marzio<sup>3</sup>, Filiberto Mastrangelo<sup>4</sup>, Andrea Pantalone<sup>5</sup>, Monica Mattioli-Belmonte<sup>6</sup>, Antonio Gigante<sup>6</sup>, Vincenzo Salini<sup>6</sup>, Giuseppe Calabrese<sup>1,7</sup>, Stefane Tete<sup>1</sup>, Gianfrancesco Palka<sup>1,7</sup> and Liborio Stivala<sup>1,2,7</sup>

- 1 Department of Biomedical Sciences, "G. d'Annunzio" University, Chieti-Pescara, Italy
- 2 Aging Research Center (CERS-I), "G. d'Annunzio" University Foundation, Chieti-Pescara, Italy
- 3 Herman Genetics Division, Pescara Hospital, Pescara, Italy
- 4 Department of Oral Sciences "G. d'Annunzio" University, Chieti-Pescara, Italy
- 5 Orthopedic and Traumatologic Division, "G. d'Annunzio" University, Chieti-Pescara, Italy
- 6 Department of Molecular Pathology and Innovative Therapies, Polytechnic University of Marche, Ancona, Italy
- 7 Institute for Molecular Genetics, National Research Council (CNR), Bologna, Italy

author email corresponding author email

BMC Biotechnology 2009, 9:9 doi:10.1186/1472-6750-9-9

The electronic version of this article is the complete one and can be found online at: <http://www.biomedcentral.com/1472-6750/9/9>

Received: 23 April 2008  
Accepted: 16 February 2009  
Published: 16 February 2009

© 2009 Antonacci et al; licensee BioMed Central Ltd.  
This is an Open Access article distributed under the terms of the Creative Commons Attribution License (<http://creativecommons.org/licenses/by/2.0>), which permits unrestricted use, distribution, and reproduction in any medium, provided the original work is properly cited.

**Abstract**

**Background**

Stem cells isolated from amniotic fluid are known to be able to differentiate into different cell types, being thus considered as a potential tool for cellular therapy of different human diseases. In the present study, we report a novel single step protocol for the osteoblastic differentiation of human amniotic fluid cells.

**Results**

The described protocol is able to provide osteoblastic cells producing nodules of calcium mineralization within 18 days from withdrawal of amniotic fluid samples. These cells display a complete expression of osteogenic markers (COL1, ONC, OPM, OCN, OFC, BSP, Runx2) within 30 days from withdrawal. In order to test the ability of these cells to proliferate on surfaces commonly used in oral osteointegrated implantology, we carried out cultures onto different test disks, namely smooth copper, machined titanium and Sandblasted and Acid Etching titanium (SLA titanium). Electron microscopy analysis evidenced the best cell growth on this latter surface.

**Conclusion**

The described protocol provides an efficient and time-saving tool for the production of osteogenic cells from amniotic fluid that in the future could be used in oral osteointegrated implantology.

**Background**

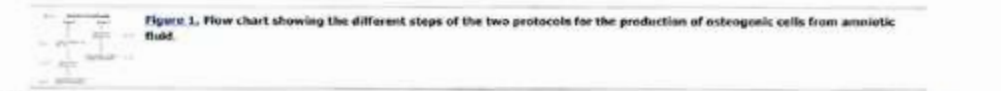
Amniotic Fluid Cells (AFCs) can be classified in epitheloid E-type cells, amniotic fluid specific AF-type cells and fibroblastic F-type cells [1]. In recent years, different reports have demonstrated that presence in human amniotic fluid of stem cells (AFS) able to differentiate into multiple lineages [1-6]. Very recently, the ability of clonal AFS to produce cell types inclusive of all embryonic germ layers was demonstrated [9,10]. Unlike embryonic stem cells, AFS have been showed to be not tumorigenic after transplantation in mice [9]. As a consequence, several studies have suggested the usefulness of these cells for therapeutic purposes [11-16]. Osteoblastic cells derived from AFS could be useful for bone regeneration after traumatic or degenerative damage [17,18]. In fact, osteoblastic progenitors obtained from amniotic fluid could be used to engineer the craniofacial structures whose natural development is regulated by mesenchymal cells originating from the neural crest, avoiding long and difficult therapies of bone augmentation with intra-oral or extra oral donor site [19,20]. In order to obtain the best results in craniofacial tissue engineering, great relevance is assumed by the use of scaffolds able to accommodate cell growth and tissue genesis. To date, implants with different surface treatments are investigated to define the best surface morphology for a good osteoblastic cell proliferation and osseointegration around implant [21-25].

The aim of the present study is to evaluate the ability of human AFS to differentiate into osteogenic cells using a novel single-step culture protocol, and to test their growth ability on different implant surfaces.

**Results**

Osteoblastic differentiation was obtained in the present study using two different culture protocols of amniotic fluid cells. In the first protocol (Protocol 1), Amniotic Fluid Mesenchymal Stem Cells (AFMSCs) were transferred in osteogenic medium at passage 6, while in the second protocol (Protocol 2), pellets of amniotic fluid samples were directly resuspended in osteogenic medium without the selection of AFMSCs.

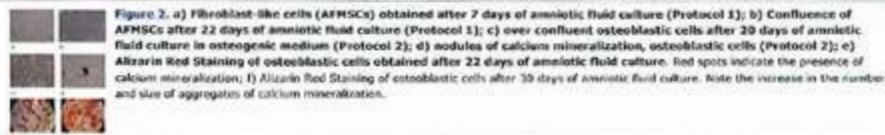
A flow chart describing the different timing of the two protocols used in this study is reported in Figure 1.



In Protocol 1, seven days after the initiation of the primary culture, fibroblast-like cells appeared both isolated and as colonies in the culture flask (Figure 2a). After 20-22 days of culture, at 70-80% confluence (Figure 2b), cells were treated with trypsin and EDTA and collected. RT-PCR analysis, carried out on RNA extracted



from the cells at this stage, evidenced the presence of genes previously reported as expressed in AFMSCs [26], namely SDF1, CXCR4, Oct-4, SCF, GATA-4, Vm, FGF-5, Pax-6, NCAM, AFP, BMP-2 (Figure 3). Cells collected at day 20–22 were transferred and cultured in the osteogenic medium. After 18 days of culture in osteogenic medium (day 40 from withdrawal), the cells showed 70–75% confluence, and the presence of aggregates or nodules of calcium mineralization was appreciable. The number and size of these aggregates increased in the following days. Cells directly cultured in osteogenic medium (Protocol 2) reached 70–75% confluence after 18 days from withdrawal, and became over confluent in the following days (Figure 2c). In the following days the appearance of the first aggregates of calcium mineralization was observed (Figure 2). Alizarin Red staining confirmed the presence of biomineralization (Fig. 2e). An increase in the number and size of aggregates during the time was observed also in these cultures (Figure 2f). Cell count carried out on 5 cultures performed with protocol 2 at day 30 from withdrawal demonstrated the presence of cell number ranging from  $8,9 \times 10^5$  to  $9,7 \times 10^6$  cells.



**Figure 2.** RT-PCR analysis of AFMSCs at day 20 of culture (protocol 1).



RT-PCR analysis carried out at day 50 (protocol 1) or 30 (Protocol 2) from withdrawal, showed expression of COL1, ONC, OPN, OCN, OPG, BSP and Runx2, typical markers of the osteogenic differentiation (Figure 4). The same genes were not expressed in fresh amniotic fluid samples, analyzed as negative control (not showed).



**Figure 4.** RT-PCR analysis of osteoblastic cells at 30 days of culture (protocol 2). Line 1 = OCN; Line 2 = Runx2; Line 3 = OCN; Line 4 = ISP; Line 5 = OPN; Line 6 = COL1; Line 7 = OPG; Line 8 = GAPDH; Line 9 = 100 bp molecular weight marker.

In order to evaluate the growth ability of osteoblastic cells obtained by Protocol 2 on different surfaces commonly used in oral implantology, cultures were carried out on smooth copper, machined titanium and Sandblasted and Acid Etching titanium (SLA titanium) test disks, and evaluated using Electro Scanning Microscopy. Titanium is universally considered as the first-rate material for oral osseointegrated implantology. Additional treatments on commercially pure (c.p.) titanium surface provide further enhancement of bone-to-implant contact, thus reducing the osseointegration period, improving treatment outcome and increasing applicability to poor bone quality. The investigation of implants with different surface treatments, both in vitro and in vivo, is a crucial point in order to define the surface morphology which could permit a good osteoblastic cell proliferation and osseointegration around implant. In our experiments, adherent cells were not detected on smooth copper surface (negative control) at day 3, while different behaviour of osteoblastic-like cells were observed on machined titanium and SLA titanium surfaces. On machined titanium surfaces, few adherent cells were observed around the titanium disk. On the contrary, adherent cells were found to cover the whole surface of SLA titanium disk (Figure 5a). Cell aggregates were arranged almost uniformly and formed a single layer cell culture on the disk surface (Figure 5b). At high magnification photomicrographs surrounding cell surfaces were clearly visible (Figure 5c–d).



**Figure 5.** Scanning Electron Microscope analysis of osteoblastic cells cultured on SLA titanium disks. a) 22x; b) 500x: adherent cells covering the whole surface of SLA titanium disk; c) 1250x; d) 1250x: evidence of filopodia surrounding cell surfaces.

In order to evaluate the mitotic stability of cells, cytogenetic investigation was carried out on Protocol 2 cultures at day 30, showing normal diploid karyotype in all the investigated metaphases.

## Discussion

Different protocols have been reported in literature for the differentiation of osteogenic cells starting from amniotic fluid. Some authors reported the use of immunoselection with c-Kit specific antibodies in order to isolate AFS starting from confluent human amniocentesis cultures, followed by proliferation of AFMSCs under appropriate culture conditions, and finally osteoblastic differentiation after several days of culture [8,9]. On the other hand, other groups cultured unselected amniotic fluid cells in media allowing the proliferation of AFMSCs, and subsequently induced their differentiation in osteoblastic cells [1,4,5].

In the present study, we demonstrated the ability of human AFS to differentiate into osteogenic cells using a single step culture procedure, allowing a 20 days reduction of the culture time as compared to previously reported protocols. This could represent an important point in the view of a possible therapeutic application of these cells. Amniotic fluid samples, directly resuspended in osteogenic medium without the selection of AFMSCs, were able to produce osteogenic cells after 18 days from the withdrawal as demonstrated by Alizarin Red staining. RT-PCR analysis showed the full expression of all osteogenic markers typical of late stage osteoblasts after 30 days of culture, while the same expression pattern is showed after 50 days from withdrawal by cells obtained using conventional protocols. Cytogenetic investigation, carried out at day 30 on cells obtained by the single step protocol, showed normal diploid karyotype in all the investigated samples, thus confirming the mitotic stability of cells obtained using this procedure. Cell count performed on cultures carried out with protocol 2 showed the presence at day 30 from withdrawal of about  $9,7 \times 10^6$  cells starting from as little as 2–3 ml of amniotic fluid. Although the direct culture of AFS cells in osteogenic medium likely induces a complete cell differentiation within 30 days, with arrest of cell proliferation, the amount of cells obtained with this protocol fits well with the cell number required for preclinical studies in animal models and for local transplant in human. Since this latter approach would likely represent the gold standard for a future clinical application in odontologic and orthopaedic implantology, the cell number obtained using our direct protocol appears to be sufficient for future local therapeutic purposes.

In order to test the ability of osteoblastic cells obtained from amniotic fluid to proliferate on surfaces commonly used for craniofacial implantology, and to evaluate their usefulness for tissue engineering, we tested these cells on disks with machined titanium and SLA titanium surfaces. Electron microscopy observation showed a good growth and adherence of osteoblastic cells on this latter surface. This result indicates the excellent biocompatibility of osteoblastic cells obtained from amniotic fluid with SLA titanium scaffolds currently utilized in dental implant.

## Conclusion

The protocol described in the present study shows the ability of producing osteoblastic cells from amniotic fluid samples in a very short time, being these cells fully differentiated within one month from withdrawal. Although osteoblastic progenitors can be successfully obtained from bone marrow stromal cells, the use of amniotic fluid as a source of these cells is of relevance since AFS can be easily obtained from routine clinical amniocentesis specimens that would otherwise be discarded. Thus, it is possible to suggest that banking of these stem cells will provide in the future a relevant source both for autologous therapy in the adulthood and for the transplant in HLA matched recipients.

## Methods

### Isolation and culture of mesenchymal stem cells from amniotic fluid (AFMSCs)

## BioMed Central | Full text | Isolation of osteogenic progenitors from human amniotic f... Page 3 of 5

Amniotic fluid samples were obtained from 11 women undergoing amniocentesis for prenatal diagnosis at 16–19 weeks of pregnancy after written informed consent. The study has been approved by the Ethics Committee for Biomedical Research of the "G. d'Annunzio" University, Chieti. For each sample, 2–3 ml of amniotic fluid, corresponding to a cell number ranging from  $2 \times 10^3$  to  $2 \times 10^6$  [1] were centrifuged for 10 minutes at 1800 rpm. Pellets were resuspended in Iscove's modified Dulbecco's medium supplemented with 20% FBS, 100 IU/ml penicillin, 100 µg/ml streptomycin (Sigma), 2 mM L-glutamine, 5 ng/ml basic fibroblast growth factor (FGF2) and incubated at 37°C with 5% humidified CO<sub>2</sub>. After 7 days, non-adherent cells were removed and the adherent cells allowed to grow in the same medium, which was changed each 4 days. When culture reached confluence (about 20 days after the primary culture), cells were treated with 0.65% trypsin and 0.02% EDTA, then counted and replated in 25 cm<sup>2</sup> culture flasks.

#### Osteogenic differentiation

Two different culture protocols were used for osteogenic differentiation of amniotic fluid cells. In the first protocol (Protocol 1), AFMSCs cells at passage 6 were transferred in osteogenic medium consisting of the above described medium with the addition of 150 µg/ml β-Glycerolphosphate, 50 µg/ml ascorbic acid, and 10<sup>-8</sup> M dexamethasone. In the second protocol (Protocol 2), pellets of amniotic fluid samples were directly resuspended in osteogenic medium in 75 cm<sup>2</sup> flasks without the selection of AFMSCs. At day 8 from withdrawal, colony forming cells were counted, showing a number ranging from 20 to 20,000 in the different cultures. To visualize calcium sediments, cells treated with Protocol 2 were stained at different times (19, 22 and 30 days from withdrawal) with Alizarin Red S solution, according to Gregory et al. [27]. Mineralization was demonstrated by the presence of red depositations. All reagents used for cells culture and staining were purchased by Sigma-Aldrich (Milano, Italy).

#### Culture on different surfaces

Three test disks (diameter 10 mm, thickness 5 mm) for each different surface, namely smooth copper, machined titanium and Sandblasted and Acid Etching titanium (SLA titanium), were used in this study. Geometric surface morphology of Machined Titanium test disks was obtained with turning machined treatment with formation of titanium micro-parallel walls. Sandblasted and Acid Etching titanium (SLA titanium) test disks were obtained by TiO<sub>2</sub> particles being applied to the surface and two phases of etching with fluoridric acid followed by a second acid attack by sulphuric-hydrochloric acid with irregular distributed porosity structure of micro-deep valleys alternated to elevated sharp crests. To preliminary characterize the surface morphology, test disks have been evaluated by means of Scanning Electron Microscopy (SEM) imaging (LEO 435 VP, Cambridge, UK) at about 15–20 kV, high vacuum mode. The surface roughness of the specimens were measured with a stylus profilometer (ARSLIASHE D46.1 1–2002) and a gloss meter (45°–90° sensor angle, 1–10 range, DIN 16537). Differences between treatment groups were evaluated using an analysis of variance at the 95% confidence level and parametric Newman-Kuels multiple comparison test at  $p = 0.05$  significance level. After differentiation, at day 15, osteoblastic cells obtained using protocol 2 were divided in three groups and  $3.7 \times 10^4$  cells were seeded onto each of the three different test disks. When 70% confluence was observed (after 2–3 days of culture), cells were prepared and analysed by SEM. The entire culture protocol on test disks was repeated two times.

#### Scanning Electron microscopy

For SEM analysis, specimens cells were fixed in 2% glutaraldehyde in 0.1 M cacodylate buffer (pH 7.4). To preserve the lipid structures, specimens were gently washed in 0.2 M cacodylate buffer (pH 7.4) with the addition of 0.15 M saccharose for three changes every 20 minutes, post-fixed in 1% osmium tetroxide at room temperature for 1 hour, then given two quick changes of the previous buffer and gradually dehydrated in increasing ethanol concentrations (from 25 to 100%, 15% steps). Samples were then carried through critical point drying (CPD) according to standard procedure using liquid carbon dioxide, mounted on aluminium stubs, gold-sputtered and observed with a Philips XL20 Scanning Electron Microscope (SEM Philips XL20; FEI, Lindhoven, The Netherlands) at 20 KV, high vacuum mode. Images were stored in TIF format with 1024 × 768 Grid of Pixels.

#### RT-PCR

Total RNA was isolated using the SV Total RNA Isolation System Kit (Promega, Milano, Italy) from: a) AFMSCs cells after 20 days culture in standard medium (protocol 1); b) differentiated cells after 30 days in osteogenic medium (protocols 1 and 2). RNA from fresh amniotic fluid was also used as a control. One µg of total RNA was reverse transcribed using RETROscript Kit (Ambion, Milano, Italy).

Amplification was performed with specific primers for two classes of genes (Table 1): a) genes expressed in mesenchymal cells (SOX1, CXCR4, Oct-4, SCF, GATA-6, VEGF, FGF-5, Fox-6, NCAM, AFP, BMP-2) (26, 28); b) genes expressed during osteogenic differentiation (COL1, ONC, OPN, OCN, OPG, RSP and Runx2) (29–31). Amplifications were carried out using 35 cycles of 95°C, 1 min; variable annealing temperature (see Table 1), 1 min; 72°C, 1 min. RT-PCR products were separated in a 2% agarose gel and visualized by Ethidium Bromide staining. Images were captured using a Gel Doc 2000 (BioRad, CA, USA).

Table 1. Genes analyzed in RT-PCR experiments, primer sequences and annealing temperature.

#### Cytogenetic investigation

For cytogenetic analysis, cultures carried out using protocol 2 were treated at day 30 with trypsin and 36–48 hours colcemid. Metaphase chromosomes were stained with GTG-banding and Giemsa. At least 20 metaphases were examined for each sample.

#### Authors' contributions

IA carried out cell cultures and osteoblastic differentiation, performed molecular genetics experiments, participated to the design of the study and to the drafting of the manuscript. IE carried out cytogenetic investigation. EM participated to AF cultures. FM participated to AF cells cultures on sample disks. AP prepared osteoblastic cells for SEM analysis. NMB participated in osteoblastic cells analysis by SEM. AG carried out osteoblastic cells analysis by SEM. VS participated in the design of the study. GC provided human AF samples. ST participated to the design of the study and to the drafting of the manuscript. GP participated in the design of the study and performed genetic counselling on women undergoing amniocentesis. LS coordinated the study and participated to the drafting of the manuscript. All authors read and approved the final manuscript.

#### Acknowledgements

Authors wish to thank Daniela Di Tizio and Tonka B. Giovacchino for their technical assistance.

This study has been supported by a grant of the G. d'Annunzio University to LS and GP.

#### References

1. Priso AR, Hengstschlager M: Amniotic fluid cells and human stem cell research: a new connection. *Med Sci Monit* 2002, **8**(11):RA253-RA257. PubMed Abstract | Publisher Full Text  
Return to text
2. Priso AR, Marton E, Rosner M, Bernaschek G, Hengstschlager M: Oct-4-expressing cells in human amniotic fluid: a new source for stem cell research? *Hum Reprod* 2003, **18**:1409-1493. PubMed Abstract | Publisher Full Text  
Return to text
3. In T Arker PS, Scherjon SA, Kieburg-van der Keur C, Nook WA, Claas FH, Willemze R, Fibbe WE, Kanhai HH: Amniotic fluid as a novel source of mesenchymal stem cells for therapeutic transplantation. *Blood* 2003, **102**:1548-1549. PubMed Abstract | Publisher Full Text



[Return to text](#)

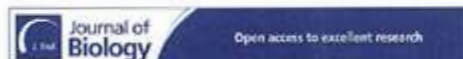
4. Fauza D: **Amniotic fluid and placental stem cells.**  
*Best Pract Res Clin Obstet Gynaecol* 2004, **18**:877-891. [PubMed Abstract](#) | [Publisher Full Text](#)  
[Return to text](#)
5. Tsai MS, Lee JL, Chang YJ, Hwang SM: **Isolation of human multipotent mesenchymal stem cells from second-trimester amniotic fluid using a novel two-stage culture protocol.**  
*Hum Reprod* 2004, **19**:1450-1456. [PubMed Abstract](#) | [Publisher Full Text](#)  
[Return to text](#)
6. Tsai MS, Hwang SM, Tsai YL, Cheng FC, Lee JL, Chang YJ: **Clonal amniotic fluid-derived stem cells express characteristics of both mesenchymal and neural stem cells.**  
*Biol Reprod* 2006, **74**:545-551. [PubMed Abstract](#) | [Publisher Full Text](#)  
[Return to text](#)
7. McLaughlin D, Tsimoneolis E, Vailanatos G, Sakellaris N, Chatzistamatiou T, Stavropoulos-Gioka C, Tsezou A, Messinis I, Manjoura D: **Stable expression of a neuronal dopaminergic progenitor phenotype in cell lines derived from human amniotic fluid cells.**  
*J Neurosci Res* 2006, **83**:1150-2006. [PubMed Abstract](#) | [Publisher Full Text](#)  
[Return to text](#)
8. Cipriani S, Bonini D, Marchina E, Balgkouraidou I, Calmi L, Grassi Zucconi G, Barlati S: **Mesenchymal cells from human amniotic fluid survive and migrate after transplantation into adult rat brain.**  
*Cell Biol Int* 2007, **31**:845-850. [PubMed Abstract](#) | [Publisher Full Text](#)  
[Return to text](#)
9. De Coppi P, Bartsch G Jr, Siddiqui MM, Xu T, Santos CC, Perin L, Mostoslavsky G, Serre AC, Snyder EY, Yoo JJ, Furth ME, Soker S, Atala A: **Isolation of amniotic stem cell lines with potential for therapy.**  
*Nat Biotechnol* 2007, **25**:100-106. [PubMed Abstract](#) | [Publisher Full Text](#)  
[Return to text](#)
10. Trounstein A: **A fluid means of stem cell generation.**  
*Nat Biotechnol* 2007, **25**:62-63. [PubMed Abstract](#) | [Publisher Full Text](#)  
[Return to text](#)
11. Holden C: **Stem cells. Versatile stem cells without the ethical baggage?**  
*Science* 2007, **315**:170. [PubMed Abstract](#) | [Publisher Full Text](#)  
[Return to text](#)
12. Kaviani A, Perry TE, Dzakovic A, Jennings RW, Ziegler MM, Fauza DO: **The amniotic fluid as a source of cells for fetal tissue engineering.**  
*J Pediatr Surg* 2001, **36**:1662-1665. [PubMed Abstract](#) | [Publisher Full Text](#)  
[Return to text](#)
13. Kaviani A, Guleserian K, Perry TE, Jennings RW, Ziegler MM, Fauza DO: **Fetal tissue engineering from amniotic fluid.**  
*J Am Coll Surg* 2003, **196**:592-597. [PubMed Abstract](#) | [Publisher Full Text](#)  
[Return to text](#)
14. Fuchs JR, Kaviani A, Oh JT, LaVan D, Udagawa T, Jennings RW, Wilson JM, Fauza DO: **Diaphragmatic reconstruction with autologous tendon engineered from mesenchymal amniocytes.**  
*J Pediatr Surg* 2004, **39**:834-8. [PubMed Abstract](#) | [Publisher Full Text](#)  
[Return to text](#)
15. Kassisid SM, Fuchs JR, Kaviani A, Oh JT, LaVan DA, Vacanti JP, Wilson JM, Fauza DO: **Diaphragmatic repair through fetal tissue engineering: a comparison between mesenchymal amniocyte- and myoblast-based constructs.**  
*J Pediatr Surg* 2006, **41**:34-9. [Publisher Full Text](#)  
[Return to text](#)
16. Kassisid SM, Freedman DA, Fauza DO: **Fetal tracheal reconstruction with cartilaginous grafts engineered from mesenchymal amniocytes.**  
*J Pediatr Surg* 2006, **41**:675-82. [PubMed Abstract](#) | [Publisher Full Text](#)  
[Return to text](#)
17. Kassem M, Kristjansen H, Abdallah RM: **Mesenchymal stem cells: cell biology and potential use in therapy.**  
*Basic Clin Pharmacol Toxicol* 2004, **95**:209-214. [PubMed Abstract](#) | [Publisher Full Text](#)  
[Return to text](#)
18. Mao JJ, Gannobile WV, Helms JA, Hollister SJ, Krebsbach PH, Longaker MT, Shi S: **Craniofacial tissue engineering by stem cells.**  
*J Dent Res* 2006, **85**:966-979. [PubMed Abstract](#) | [Publisher Full Text](#) | [PubMed Central Full Text](#)  
[Return to text](#)
19. Chiappasco M, Gatti C, Gatti F: **Immediate loading of dental implants placed in severely resorbed edentulous mandibles reconstructed with autogenous calvarial grafts.**  
*Clin Oral Implants Res* 2007, **18**(1):13-20. [PubMed Abstract](#) | [Publisher Full Text](#)  
[Return to text](#)
20. Sun W, Lal P: **Recent development on computer aided tissue engineering - a review.**  
*Computer Methods and Programs in Biomedicine* 2002, **67**:85-103. [Publisher Full Text](#)  
[Return to text](#)
21. Branemark PI, Svensson B, van Steenberghe D: **Ten-year survival rates of fixed prostheses on four or six implants ad modum Branemark in full edentulism.**  
*Clin Oral Implants Res* 1995, **6**:227-231. [PubMed Abstract](#) | [Publisher Full Text](#)  
[Return to text](#)
22. Lekholm U, Zarb GA: *Tissue integrated prostheses: osseointegration in clinical dentistry.* Chicago: Branemark, Zarb & Albrektsson 1985; 1985.  
[Return to text](#)
23. Ericsson I, Johansson CB, Bystedt H, Norton MR: **A histomorphometric evaluation of bone-to-implant contact on machine-prepared and roughed titanium dental implants. A pilot study in the dog.**

*Clin Oral Implants Res* 1994, **5**:202-206. [Publisher Full Text](#)

[Return to text](#)

24. Wennerberg A, Albrektsson T, Andersson B: **Bone tissue response to commercially pure titanium implants blasted with fine and coarse particles of aluminium oxide.**  
*Int J Oral Maxillofac Implants* 1996, **11**(1):38-45. [PubMed Abstract](#) | [Publisher Full Text](#)  
[Return to text](#)
25. Piatelli A, Scarano A, Piatelli M, Calabrese L: **Direct bone formation on sandblasted titanium implant: an experimental study.**  
*Biomaterials* 1996, **17**:1015-1018. [PubMed Abstract](#) | [Publisher Full Text](#)  
[Return to text](#)
26. Kim J, Lee Y, Kim H, Hwang KJ, Kwon H, Kim SK, Cho DJ, Kang SG, You J: **Human amniotic fluid-derived stem cells have characteristics of multipotent stem cells.**  
*Cell Prolif* 2007, **40**:75-90. [PubMed Abstract](#) | [Publisher Full Text](#)  
[Return to text](#)
27. Gregory CA, Gunt WG, Peister A, Prockop DJ: **An Alizarin red-based assay of mineralization by adherent cells in culture: comparison with centylpyridinium chloride extraction.**  
*Anal Biochem* 2004, **329**:77-84. [PubMed Abstract](#) | [Publisher Full Text](#)  
[Return to text](#)
28. Kortesidis A, Zambetti A, Isenmann S, Shi S, Lapicket T, Gronthos S: **Stromal-derived factor-1 promotes the growth, survival, and development of human bone marrow stromal stem cells.**  
*Blood* 2005, **105**:3793-3801. [PubMed Abstract](#) | [Publisher Full Text](#)  
[Return to text](#)
29. Gronthos S, Maekani M, Ibrahim J, Robey PG, Shi S: **(Postnatal human dental pulp stem cells (DPSCs) in vitro and in vivo.**  
*Proc Natl Acad Sci USA* 2000, **97**:13625-13630. [PubMed Abstract](#) | [Publisher Full Text](#) | [PubMed Central Full Text](#)  
[Return to text](#)
30. Celetti A, Testa D, Stallano S, Merolla F, Guarino V, Castellone MD, Iovine R, Matsueto G, Somma P, De Rosa G, Galli V, Melillo RM, Scafaro M: **Overexpression of the cytokine osteopontin identifies aggressive laryngeal squamous cell carcinomas and enhances carcinoma cell proliferation and invasiveness.**  
*Clin Cancer Res* 2005, **11**:8019-8027. [PubMed Abstract](#) | [Publisher Full Text](#)  
[Return to text](#)
31. Hucija M, Maracka B, Yoshizaki K, Fukumoto S, Nakashima M, Aikawa A, Nomaka K, Oishi M: **TGF-beta3 induces ectopic mineralization in fetal mouse dental pulp during tooth germ development.**  
*Dev Growth Differ* 2005, **47**:141-152. [PubMed Abstract](#) | [Publisher Full Text](#)  
[Return to text](#)

Have something to say? Post a comment on this article!



[Terms and Conditions](#) [Privacy statement](#) [Information for advertisers](#) [Jobs at BMC](#) [Contact Us](#)  
© 1999-2009 BioMed Central Ltd unless otherwise stated. Part of Springer Science+Business Media.



## EXPERIMENTAL IN VITRO STUDY FOR THE IMPLEMENTATION OF AIRPOLISHING DURING TREATMENT OF IMPLANTED SURFACES IN PATIENTS WITH MUCOSITIS/PERI-IMPLANTITIS

C.A. Cortella - P. P. Paganin\* - E.M. Polizzi



### AIM

The aim of this research is to evaluate in vitro effects on different implant **rough surfaces** and with different AirPolishing treatments with different powders: **glycine powder 120 nm on FCC and SLA** and **glycine powder 63 nm on FCC and SLA** for **SPT** for implant surfaces.

### MATERIALS & METHODS

For the study we have used an AP device "AIR-FLOW MASTER" with the highest setup (made by E.M.S. Electro Medical Systems, Nyon, Switzerland). For the study, the device has been applied under a working pressure of 5 bar (air) and 4.5 bar (water). Additionally, 12 non sterile titanium disks and 4 teeth have been used.



- No. 6 disk (2 test groups CALLED 1A; 2A; 3A & 1B; 2B; 3B) represent FCC surface treatment (Full Contact Covering)
- No. 6 disk in titanium (2 test groups CALLED 1C; 2C; 3C & 1D; 2D; 3D); represent SLA surface treatment (Sand-blasted, Large[grit], Acidetched)
- No. 4 teeth (fifth test group CALLED 1E; 2E; 3E; 4E)
- 16 surfaces (implant and root) were treated in **FIVE TEST GROUPS** with one additional group as **CONTROL** (implants).
- A) FIRST TEST GROUP** (3 FCC implant surfaces: **SOFT Glycine Powder 120 nm**,) 1 A; 2 A; 3A, were exposed to 3 time-differentiated single air polishing treatments with EMS SOFT Powder respectively for 5" for the disc 1 A, 10" for the disc 2 A, 20" for the disc 3 A
- B) SECOND TEST GROUP** (3 FCC implant surfaces: **PERIO Glycine Powder 63nm**,) 1 B; 2 B; 3B, were exposed to 3 time-differentiated single air polishing treatments with EMS PERIO Powder respectively for 5" for the diskette 1 B, 10" for the diskette 2 B, 20" for the diskette 3 B
- C) THIRD TEST GROUP** (3 SLA implant surfaces: **SOFT Glycine Powder 120 nm**,) 1C; 2 C; 3C, were exposed to 3 time-differentiated single air polishing treatments with EMS SOFT Powder respectively for 5" for the diskette 1 C, 10" for the diskette 2 C, 20" for the diskette 3 C
- D) FOURTH TEST GROUP** (3 SLA implant surfaces: **PERIO Glycine Powder 63 nm**,) 1D; 2D; 3D, were exposed to 3 time-differentiated single air polishing treatments with EMS PERIO Powder respectively for 5" for the diskette 1 D, 10" for the diskette 2 D, 20" for the diskette 3 D
- E) FIFTH TEST GROUP** (4 TEETH ROOT surfaces: **PERIO Glycine Powder 63 nm**,) 1E; 2E; 3E; 4E, were exposed to 3 time-differentiated single air polishing treatments with EMS PERIO Powder respectively for 5" for the ROOTS SURFACES 1E-2E, 10" for the ROOT 3E, 20" for the ROOT 4E

SEM MORPHOLOGICAL ANALYSIS

PARAMETER:  
EHT = Potential speed of electron  
WD = Working Distance  
MAG = Magnification

MAGNIFICATION IMPLANT SURFACE: 500; 2000; 5000; 7500 (X)  
MAGNIFICATION TEETH: 100; 500; 2000; 5000 (X)  
NOBIL BIO RICERCHE s.r.l. - LABORATORY (ASTI).

ALL THE DISC AND TEETH HAVE BEEN TREATED BY THE SAME OPERATOR AND SUBJECT TO AIR POLISHING FROM A DISTANCE OF AROUND 5 mm.

### RESULTS

TIME	FCC	FCC	SLA	SLA	ROOTS
5"	+	-	+	-	-
10"	++	+	+	+	++
20"	+++	+++	+++	+++	+++

Legend: SOFT (blue), PERIO (pink), + DAMAGE, - NO DAMAGE

TREATMENT	SOFT POWDER	5"	10"	20"
FCC 1A	✓			
FCC 2A		✓		
FCC 3A			✓	

TREATMENT	PERIO POWDER	5"	10"	20"
FCC 1B	✓			
FCC 2B		✓		
FCC 3B			✓	

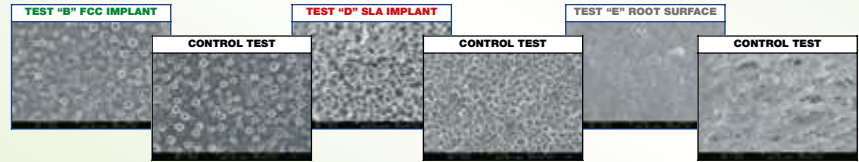
TREATMENT	SOFT POWDER	5"	10"	20"
SLA 1C	✓			
SLA 2C		✓		
SLA 3C			✓	

TREATMENT	PERIO POWDER	5"	10"	20"
ROOT 1E	✓			
ROOT 2E		✓		
ROOT 3E			✓	

TREATMENT	PERIO POWDER	5"	10"	20"
SLA 1D	✓			
SLA 2D		✓		
SLA 3D			✓	

#### AIR POLISHING WITH PERIO GLYCINE POWDER

Summarizing, 5" air polishing with PERIO powder has shown to be the least aggressive and least abrasive on implant and root surfaces.



### CONCLUSION

**AIR POLISHING:** Air polishing has shown to be very effective on patients in SPT (Support Periodontal Therapy) <sup>(1)</sup> when Sodium Bicarbonate powder or Perio powder is applied. <sup>(2-4-9)</sup> The SEM analysis of the titanium surface morphology has shown that Air Polishing using Perio Powder is significantly less abrasive than the same treatment with Sodium Bicarbonate based Powder. After the Air Polishing treatment, evident iatrogenic damages coded 3 (see table 1) have appeared independently from both the type of powder and the type of sample used (FCC, SLA or teeth). It is also important to notice that under identical treatment time, the FCC implant surface proved to be more sensitive to Air Polishing compared to SLA implant surface. <sup>(2)</sup>

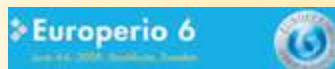**PERIO POWDER (GLYCINE):** Perio Powder applied in 5" exposure per surface has shown to be the least aggressive and abrasive on implant and root surfaces in the Air Polishing treatment. The results obtained in this "in vitro" study will be confirmed by a "in vivo" clinical study on implant surfaces by peri-implantitis and on root surfaces by patients affected by periodontitis.

**Key words:** abrasion; air polishing; dental implant; implant surface.

#### Bibliography

1. M. E. Gutierrez - Air polishing a comprehensive review of the literature. Journal of Dental Hygiene Vol. 72, No. 3, Summer 1998
2. Augthun M.; Tinschert J.; Huber A. (1998) In Vitro Studies on Effect of Cleaning Method on different Implant Surface J. Periodontology 8, Vol. 69 857-864.
3. Petersilka et al. 2002 Root defects after air polishing J Clin Periodontol 2002; 29: 000
4. Petersilka G.J., et al: in vitro evaluation of novel low abrasive air polishing powders. J Clin Periodontol 2003; 30: 9-13. C Blackwell Munksgaard 2003.
5. Petersilka G.J., et al: effect of glycine powder air-polishing on the gingiva. J Clin Periodontol 2008; 35:324-332.

PIER PAOLO PAGANIN  
DENTAL HYGIENIST  
e-mail: uhsrighienedentale@hsr.it



Ref no: EUABS065616

**Experimental in vitro study for the implementation of air polishing during treatment of implanted surfaces in patients with mucositis/periimplantitis**

P. PAGANIN, C. CORTELLA\*, E. POLIZZI AND E. GHERLONE

*Univ. "Vita Salute" San Raffaele Milano, Italy*

Removal of bacterial deposits from such surfaces can lead to greater difficulties. All instrumentation and plaque removal procedures can bring about alterations to the morpho-topographical surface.

**Aim:** The aim of this research is to evaluate certain in vitro effects on different rough surfaces and with different air polishing treatments with different glycine powders (particle size 63 and 120 nm) glycine powder 120 nm on FCC and SLA; 63 nm glycine powder on FCC and SLA for PST for implant surfaces. In context, the root surfaces of four newly-extracted teeth have been treated with AP and Perio glycine powder alone, observing exposure criteria of the surfaces B and D. For the study we used a new air polishing device made by EMS SA – Nyon with the highest setup.

Bruno Marcelli\*, Maurizio Procaccini\*\*, Erminia Coccia\*\*\*

## L'innesto onlay autologo nelle atrofie localizzate

Le cause di riassorbimento osseo possono essere molteplici. I fattori infiammatori possono causare difetti molto estesi, con la conseguente difficoltà per la terapia implantoprotesica. Le tecniche di innesto autologo, consentono di rigenerare l'osso in questi siti. Vengono presentati e discussi una serie di casi clinici di autograft, prelevato con dispositivo piezoelettrico (Easy Surgery® Biosaf), nella zona degli incisivi inferiori, in cui l'innesto e l'impianto hanno consentito sia il recupero estetico e funzionale sia della zona edentula ma anche quello degli elementi vicini.

**Parole chiave:** Innesto osseo, Atrofia dei mascellari, Chirurgia piezoelettrica.

### INTRODUZIONE

Uno dei requisiti per una riabilitazione implantoprotesica predicibile, è la presenza di una buona qualità e quantità ossea<sup>1</sup>.

La perdita di osso è spesso disomogenea, minore dove gli elementi si sono mantenuti più a lungo, maggiore laddove la perdita sia più datata e abbia sostenuto una protesi rimovibile<sup>2</sup>.

Negli ultimi anni, poi, la maggior parte dei pazienti sono parzialmente o monodentuli e l'implantoprotesi rappresenta, oggi, la terapia di scelta<sup>3</sup>.

Presupposto all'atrofia dei mascellari è la perdita dei denti, fatto che riconosce come principale causa la patologia parodontale, lesioni periapicali e i traumi, con la creazione di difetti ossei più o meno estesi<sup>4</sup>. Il grave riassorbimento osseo verticale, orizzontale o com-

\* prof. a.c. Università Politecnica delle Marche, C.L.O.P.D., dir. Prof. M. Procaccini.

\*\* Università Politecnica delle Marche. Istituto di scienze Odontostomatologiche. Dir. Prof. M. Procaccini.

\*\*\* Università Politecnica delle Marche. Istituto di scienze Odontostomatologiche. Dir. Prof. M. Procaccini.

#### Indirizzo per la corrispondenza:

Bruno Marcelli  
Via Lucio Papirio 116 – 00174 Roma  
tel. 328 6906864  
E-mail: bmarcelli@libero.it



## IMPLANTOLOGIA

binato, che ne può esitare potrebbe escludere tali pazienti da questa procedura, quindi si rende necessario rigenerare l'osso perduto. L'innesto di osso autologo è considerato il più predicibile<sup>5-7</sup>. Per quanto attiene agli innesti autologhi in blocco, argomento di questo lavoro, i siti intraorali di prelievo preferiti sono: la zona retromolare, il tuber, la sinfisi mentoniera e le zone edentule<sup>6,8-11</sup>. In alternativa, siti extraorali, come la cresta iliaca, la calvaria e la tibia<sup>12</sup>, sono utilizzati per prelievi consistenti, ma con inevitabile esposizione di un secondo sito e conseguenze anatomiche e funzionali imprevedibili. La sinfisi è un sito donatore ben accettato per gli innesti, poiché è facilmente accessibile, fornisce una buona quantità di osso, e può essere ottenuto senza o con limitate conseguenze estetiche<sup>8,13</sup>. Paragonato a quello della cresta iliaca, mostra poco riassorbimento<sup>14,15</sup>, inoltre periodo di guarigione per gli innesti ossei di origine endocondrale è, di solito, 6-9 mesi<sup>5</sup>. Comunque, un periodo di guarigione di 4 mesi, secondo gli studi clinici, è adeguato negli innesti a prelievo mandibolare<sup>22</sup>. Il periodo di guarigione più corto era basato sull'ipotesi che l'innesto membranoso rivascularizza prima dell'innesto endocondrale<sup>23,24</sup>.

## MATERIALI E METODI

Questo lavoro, è stato considerato il settore anteriore inferiore, dove uno degli incisivi inferiori era irrecuperabile e il difetto residuo ampio con necessità di un innesto a blocco per aumentare l'ampiezza nonché l'altezza della cresta mancante (Fig. 1)<sup>16</sup>. Sono stati presi in considerazione 6 casi clinici, selezionati con difetti in altezza e ampiezza tali da non rendere possibile l'inserzione di un impianto immediato. I pazienti, in buona salute, sono stati informati sulle procedure e preparati con scaling e root planning. Per 2 settimane prima e per 1 mese dopo l'innesto è stato proscritto il fumo e raccomandata una accurata igiene orale.

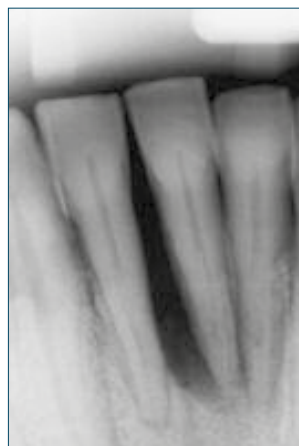


Fig. 1 Rx preoperatoria.

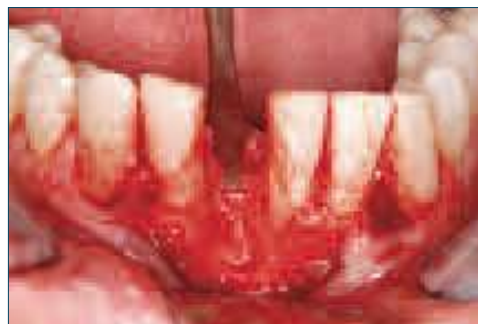

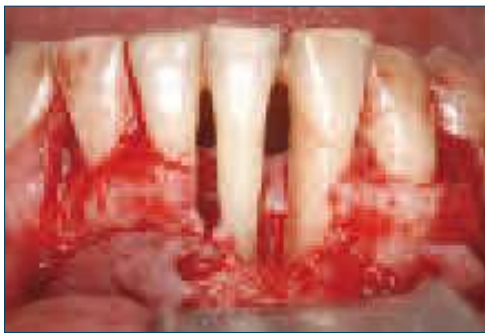Fig. 2 Lembo senza tagli di rilascio.

La procedura chirurgica ha un'alta predicibilità<sup>17</sup> e comporta tre fasi:

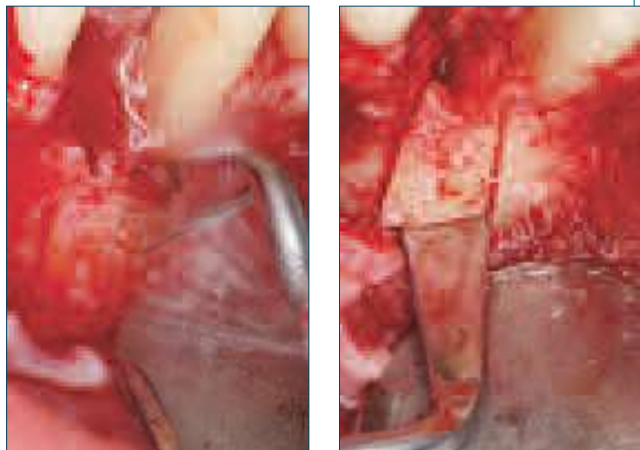
1. esposizione del sito ricevente;
2. prelievo ed inserimento dell'innesto;
3. sutura del sito seguita dalla gestione post-operatoria.

Previa anestesia locale con Articaina con v.c. 1:200.000, viene scolpito il lembo. Il disegno del lembo, senza (Fig. 2), o con incisioni di rilascio (Fig. 3), è stato esteso ai due elementi distali al difetto. Non abbiamo notato differenze nella guarigione dei due tipi di lembo. L'esposizione del sito ricevente dà informazioni circa le dimensioni del difetto e quindi della misura del prelie-

## L'innesto onlay autologo nelle atrofie localizzate



**Fig. 3** Lembo con tagli di rilascio.



**Fig. 4,5** Il taglio piezoelettrico è preciso e il sito esangue, per l'effetto cavitazionale.

vo. Il deficit della cresta residua era sempre a becco di flauto, a maggior altezza linguale. Inoltre gli elementi adiacenti risultavano con una mobilità di vario grado, per la perdita di osso in corrispondenza delle superfici prossimali.

Il sito ricevente è stato esposto al minimo per mantenere un'eccellente vascolarizzazione: se il difetto è sul versante vestibolare è inutile preparare un lembo anche sul versante opposto e viceversa. Questo garantisce la vitalità dei sottili margini del letto ricevente e interferisce al minimo con la vitalità del periostio non scollato vicino all'innesto, dove si prevede che inizi la riparazione. Scollando il lembo a spessore totale col suo periostio, lo strato cellulare potenzialmente osteogenetico viene distrutto e conseguentemente il lembo che copre l'innesto perde qualsiasi potenziale osteogenetico<sup>18</sup>. La rigenerazione del tessuto periosteo deve iniziare nella sede del periostio indisturbato. Più questo tessuto intatto è vicino al sito ricevente, più rapida sarà la formazione di un callo stabilizzante di osso immaturo. Fatte queste considerazioni si passa al prelievo dal sito donatore.

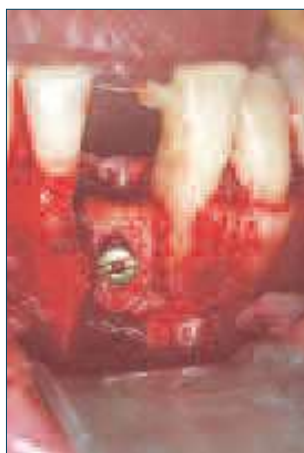In questo studio, per la regione del difetto e per la quantità di osso disponibile, il prelievo è avvenuto nella zona apicale al riassorbimento. Questo ha limitato il sito di intervento a uno solo, con diminuzione della morbilità dovuta all'apertura di un secondo sito e al conseguente aumento del comfort postoperatorio. I prelievi sono tutti stati effettuati con chirurgia piezoelettrica tramite Easy Surgery® Biosaf. I vantaggi sono di vario tipo: il taglio è netto, poco traumatico e, grazie all'effetto cavitazionale degli ultrasuoni, che limita il sanguinamento, la visibilità è ottima (Figg. 4,5).

Come suggerito da alcuni AA, per migliorare il potenziale osteogenetico, il sito ricevente deve essere decorticato con perforazioni attraverso il periostio nello spazio midollare<sup>19</sup>. Secondo alcuni AA<sup>17</sup> ciò favorisce la riparazione tramite riassorbimento di osso non vitale e facilita la vascolarizzazione al letto osseo. L'osso danneggiato attrae la formazione e la migrazione degli osteoclasti, delle cellule endoteliali che li accompagnano e delle cellule precursori osteoblastiche perivascolari. Al contrario degli osteoclasti, che hanno origine

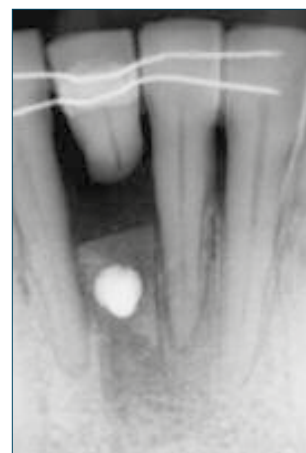## IMPLANTOLOGIA



**Fig. 6** Il foro passante dell'innesto prima del prelievo.



**Fig. 7** L'innesto in sede.



**Fig. 8** Rx di controllo.

localmente dal periostio e dalle cellule perivascolari dell'osso, gli osteoblasti originano da granulociti o cellule progenitrici dei macrofagi dal midollo e si spostano tramite la circolazione<sup>20</sup>. Le cellule di rivestimento dell'endostio possono partecipare all'attivazione degli osteoclasti che si scavano la strada verso l'osso danneggiato tramite la contrazione attiva dei processi cellulari degli osteociti nei canalicoli dopo l'insulto.

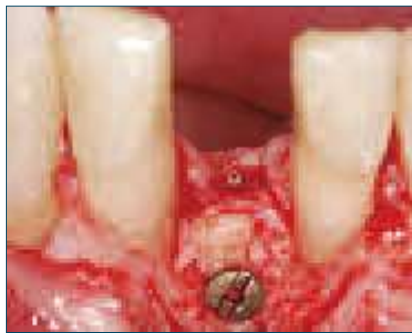Una attenzione particolare va data affinché i margini del prelievo osseo cadano entro il limite della regione edentula, per non danneggiare le radici dei denti contigui al sito donatore.

Prima di staccare completamente l'innesto è bene forarlo per favorire il passaggio della vite da osteosintesi (Fig. 6). Il frammento viene prelevato con l'aiuto di uno scalpello molto sottile e posizionato quindi con la parte midollare verso la corticale del sito ricevente, rifinito e adattato. Eventuali gap di osso vanno colmati con bone chips ricavate dalla rifinitura dell'innesto o dalla midollare del sito donatore in quanto qualsiasi divario fra l'innesto e il letto ricevente potrebbe interferire con la vascolarizzazione dell'innesto da parte del sito rice-

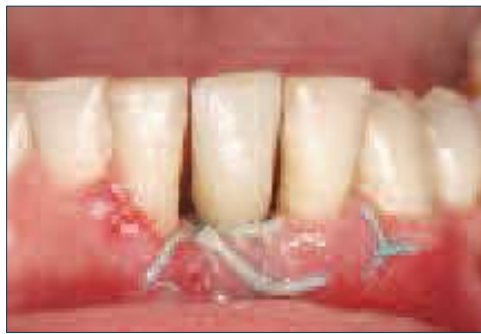vente. Infatti, una ragione di insuccesso può essere dovuta all'invasione di tessuto fibroso che isola l'innesto dal sito ricevente: in tale evenienza gli osteoclasti non potranno raggiungere il blocco.

Tramite la vite di osteosintesi in titanio è stato, quindi, solidarizzato l'innesto all'osso ricevente (Fig. 7). L'immobilizzazione tra le due parti ossee, perfettamente affrontate, è fondamentale per il successo, fa sì che la guarigione avvenga in modo simile a quello una frattura fissata. In questo momento è stata misurata l'ampiezza del margine crestale. Il sito donatore è stato riempito con materiale allo plastico sintetico riassorbibile. I lembi, affrontati in maniera passiva, senza tensioni, tra di loro, sono stati suturati senza il posizionamento di membrana e suturati con Poliestere 4,0. Un dente provvisorio è stato sempre splintato agli elementi adiacenti, opportunamente tagliato per non interferire in nessuna maniera con i processi di guarigione. Per il post-operatorio, sono stati prescritti Amoxicillina e ac. Clavulanico alla dose di 1 g ogni 12 ore e Nimesulide, 100 mg 2 volte al dì per 6 gg e sciacqui di clorexidina 0,20% per 7 gg 2 volte al dì, oltre a una accurata igiene

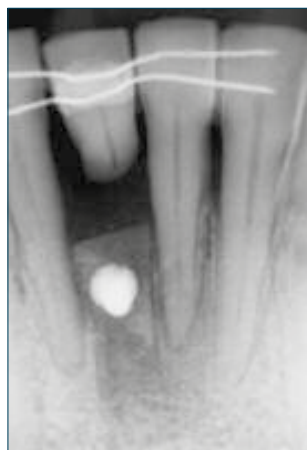
## L'innesto onlay autologo nelle atrofie localizzate



**Fig. 9** Il rientro a 3 mesi.



**Fig. 10** L'impianto funzionalizzato immediatamente.



**Fig. 11** Rx di controllo del caso illustrato.

to con la giunzione amelocementizia dei denti adiacenti (Fig. 9), requisito fondamentale al recupero anche di questi elementi. Nella stessa seduta, sono stati inseriti gli impianti di  $\varnothing$  3,3 mm lunghezza 13 mm con superficie in titanio SLA. Tutti gli impianti sono stati immediatamente funzionalizzati (Fig. 10) e, 4 mesi dopo, protesizzati in maniera definitiva con corone in metallo ceramica. Le radiografia, eseguite a distanza di 6 mesi, dimostrano la stabilizzazione dell'innesto e il buon supporto osseo sugli elementi vicini (Fig. 11).

orale. Dopo 15 giorni sono state rimosse le suture. Durante il periodo di guarigione, non è stata osservata alcuna complicanza.

Con il tempo, tra i due piani ossei affrontati, si forma un callo osseo immaturo che viene rimodellato, grazie anche alla presenza di proteine morfogenetiche incluse nell'innesto<sup>20</sup>, l'innesto riassorbito e sostituito da nuovo tessuto osseo.

A distanza di 3 mesi, la Rx di controllo rivela l'innesto ben integrato (Fig. 8) è stato programmato il rientro, scolpito un lembo a spessore totale, per svitare la vite usata per il fissaggio e valutata la quantità ossea ottenuta misurando l'ampiezza in cresta. In tutti i casi l'altezza della cresta era in buon rappor-

## RISULTATI

Lo spessore osseo raggiunto è stato in tutti i casi compatibile con l'inserzione degli impianti (Tab. 1).

La media dell'ampiezza ossea ottenuta al momento dell'innesto era di 5,1 mm (max 5,5 – min 5,0 mm), mentre al rientro a 3 mesi la media di ampiezza ottenuta nei 6 casi era di 4,3 mm (max 4,5–min 4,0).

## DISCUSSIONE E CONCLUSIONI

Misch e Coll.<sup>19</sup> hanno indicato che le dimensioni minime di un osso alveolare deve

## IMPLANTOLOGIA

Tabella I.

Paziente sesso ed età	Spessore iniziale	Spessore a 3 mesi
M 52 aa	5 mm	4,5 mm
M 58 aa	5,5 mm	4,5 mm
F 62 aa	5,2 mm	4,4 mm
F 35 aa	5,2 mm	4 mm
M 46 aa	5,0 mm	4,2 mm
M 49 aa	5,1 mm	4,3 mm

essere minimo 5 mm in ampiezza e 7-10 mm in altezza allo scopo di posizionare un impianto con risultati predicibili. L'osso spongioso si riassorbe rapidamente e la corteccia labiale e linguale si avvicinano, causando una concavità labiale quando un'estrazione è causata da un'infezione periapicale o da un'infezione parodontale distruttiva o come esito di un trama. Il ramo mandibolare, la sinfisi, siti estrattivi e le zone retromolari sono le aree di scelta per il prelievo di innesti ossei da siti intraorali. Gli innesti ossei autologhi si rivascolarizzano velocemente, hanno un periodo di guarigione breve e hanno poco riassorbimento. La formazione di nuovo osso dall'innesto autologo aumenta le possibilità di osteointegrazione dell'impianto, pertanto forniscono una migliore interfaccia alla trasmissione dello stress per il carico implantare<sup>4,8,21</sup>. L'innesto a onlay con prelievo mandibolare è ormai un intervento con un'alta predicibilità. Gli studi fisiopatologici e la tecnica chirurgica su questa metodica hanno fornito un protocollo che, se rispettato, si conclude con il successo. In questo caso il prelievo apicale al difetto ha consentito un intervento poco traumatico e senza l'interessamento di altri siti. L'uso della chirurgia piezoelettrica (Easy Surgery® Biosaf), ha certamente contribuito alla buona riuscita della procedura di prelievo, in quanto il taglio micro metrico e l'assenza di sanguinamento, grazie all'effetto cavitazionale, danno una migliore visibilità senza compromettere la vitalità dell'innesto<sup>26</sup>. La buona riuscita della procedura e il buon volume osseo ottenuto idoneo all'inserzione dell'impianto ha evitato procedure puramente protesiche, ma è anche importante la rigenerazione ossea in corri-

spondenza degli elementi vicini che ne ha favorito la stabilizzazione, requisito necessario al loro completo recupero.

## BIBLIOGRAFIA

1. Buser D, von Arx T, ten Bruggenkate C, Weingart D. Basic surgical principles with ITI implants. *Clin Oral Implants Res* 2000;11(Suppl.):59-68.
2. Tallgren A. The continuing reduction of the residual alveolar ridges in complete denture wearers. A mixed-longitudinal study covering 25 years. *J Prosthet Dent* 1972.
3. Belser UC, Mericske-Stern R, Bernard JP, Taylor TD. Rosthetic management of the partially dentate patient with fixed implant. *Clin Oral Implants Res* 2000;11(Suppl.):126-45.
4. Cho JY. The periodontist and the edentulous area-localized ridge augmentation. *Int Dent J* 1998;48(Suppl. 1):326-9.
5. Listrom RD & Symington JS. Osseointegrated dental implants in conjunction with bone grafts. *International Journal of Oral and Maxillofacial Surgery* 1988;17: 116-118.
6. Jensen J & Sindet-Pedersen S. Autogenous mandibular bone grafts and osseointegrated implants for reconstruction of the severely atrophied maxilla: a preliminary report. *Journal of Oral and Maxillofacial Surgery* 1991;49:1277-1287.
7. Block MS & Kent JN. Sinus augmentation for dental implants: the use of autogenous bone. *Journal of Maxillofacial Surgery* 1997;55:1281-1286.
8. Misch CM. Comparison of intraoral donor sites for onlay grafting prior to implant placement. *International Journal of Oral & Maxillofacial Implants* 1997;12:767-776.
9. Mellonig JT et al. Comparison of bone graft materials. *J Periodontol* 1981;52:297-302.
10. Hunt DR & Jovanovic SA. Autologous bone harvesting: a chin graft technique for particulate and monocortical bone blocks. *The International Journal of Periodontics and Restorative Dentistry* 1999;19:165-174.
11. Montazem A, Varauri DV, St-Hilaire H & Buchbinder D. The mandibular symphysis as a donor site in maxillofacial bone grafting: a quantitative anatomic study. *Journal of Oral and Maxillofacial Surgery* 2000;58:1368-1371.
12. Block MS & Kent JN. Sinus augmentation for dental implants: the use of autogenous bone. *Journal of Maxillofacial Surgery* 1997;55:1281-1286.
13. Devlin H, Sloan P & Luther F. Alveolar bone resorption: a histologic study comparing bone turnover in the edentulous mandible and iliac crest. *Journal of Prosthetic Dentistry* 1994;71:478-481.
14. Koole R. Ectomesenchymal mandibular symphysis bone graft: an improvement in alveolar cleft grafting? *Cleft Palate-Craniofacial Journal* 1994;31:217-223.
15. Lundgren S, Moy P, Johansson C, & Nilsson, H. (1996) Augmentation of the maxillary sinus floor with particulate mandible: a histologic and histomorphometric study. *International Journal of Oral & Maxillofacial Implants* 1996;11:760-766.



## L'innesto onlay autologo nelle atrofie localizzate

16. Perel ML. Facilitating implant placement with isithes with chin grafts for maxillary bone augmentation. Part II. Dent Implantol Update 1996;6(12):1-4.
17. Zeiter DJ et al. L'uso di un innesto di un blocco osseo prelevato dal mento per l'aumento della cresta alveolare. Riv Int Parodontol e Odont Ricostr 2000;6(20):619-27.
18. Roberts WE et al. Implants: bone Physiology and metabolism. Calif Dent J 1987;15(10):54-61.
19. Buser D et al. Guided tissue rigeneration in implant dentistry. Chicago: Quintessence, 1994.
20. Baron R. Anatomy and ultrastructure of bone. In: Favus MJ (ed). Primer on the metabolic Bone Diseases and Disorder of Mineral Metabolism, ed 2. New York: Raven, 1993:3-10.
21. Lustmann J, Lewinstein I. Interpositional bone grafting technique to widen narrow maxillary ridge. Int J Oral Maxillofac Implants 1995;10:568-77.
22. Misch CM, Misch C, Resnik RR, Ismail YH. Reconstruction of maxillary alveolar defects with mandibular symphysis grafts for dental implants: a preliminary procedural report. Int J Oral Maxillofac Implants 1992;7:360-6.
23. Kusiak JF, Zins JE, Whitaker LA. The early revascularization of membranous bone. Plast Reconstr Surg 1985;76:510-4.
24. Philips JH, Rahn BA. Fixation effects on membranous and endochondral onlay bone graft revascularization and bone deposition. Plast Reconstr Surg 1990;85:891-7.
25. Spampata R, Werther JR, Hauschka PV. Accelerated endochondral osteoinduction in the absence of bone matrix particles in a rat model system. J Oral Maxillofac Surg 1992;50:140-51.
26. Chiriac G, Herten M, Schwarz F, Rothamel D, Becker J. Autogenous bone chips: influence of a new piezoelectric device (Piezosurgery) on chip morphology, cell viability and differentiation. J Clin Periodontol. 2005 Sep; 32(9):994-9.

There are various causes of osseous resorption. The inflammatory factors may cause very extensive defect with resulting difficult implantoprothetic therapy. The autograft technique allow restore bone in these site. A series of clinical cases of autograft are presented and siscussed. Autograft has been drawn with piezoelectric device (Easy Surgery® Biosaf ) from the site of the inferior incisors.were the graft and dental implant have permitted an aesthetic and funtional recovery of the edentolous site of the next element as well.

**Parole chiave:** Bone graft, Maxillary atrophy, Piezoelectrical surgery.

Copyeditor: Karlyn Cabrera

## ORIGINAL ARTICLE

## Evaluation of Effects on Bone Tissue of Different Osteotomy Techniques

Stefano Tetè, MD, DDS,\* Raffaele Vinci, MD, DDS,† Vincenzo Zizzari, DDS,\*  
Luciano Cingano, MD, DDS,‡ Raffaele Bollero, DDS,† Giuseppe D'Apolito, DDS,\* Luisa Benzo, MD,†  
Alessandro Dolci, DDS,\* Carmen Mortellaro, MD, DDS,§ and Enrico Gherlone, MD, DDS†

**Abstract:** The aim of this study is to evaluate and compare the response of bone tissue after osteotomy carried out with either rotating cutters or with piezoelectric terminals.

Biopsic samples of bone tissue were taken during operations with rotating burs and piezoelectric terminals to increase bone volume before implantology. Samples first underwent histomorphometric analysis. Subsequently, osteoblastic cells, obtained from different samples, were placed in culture and allowed to proliferate to in vitro evaluate the time to initiate growth and to reach confluence. Finally, a molecular biologic study by reverse transcription polymerase chain reaction was performed to evaluate the expression of typical osteoblastic molecular markers, such as osteoprotegerin and osteopontin.

Histomorphometric analysis showed that the width of necrotic line on the osteotomic margins from samples taken using different techniques did not vary significantly. Moreover, the times of initial growth and of confluence in cells from the 2 groups did not show any statistically significant differences. However, a highly significant correlation was revealed between the age of the patient and the initial growth time and the confluence. Similarly, reverse transcription polymerase chain reaction showed that the osteoprotegerin and osteopontin expression levels did not change significantly according to the surgical technique used.

In conclusion, osteotomies carried out with either instrument do not seem to substantially influence the vitality of the bone tissue. The variability of the expression levels of typical osteoblastic markers seems to be linked more to other factors than to the surgical technique used.

**Key Words:** Piezoelectric terminal, osteotomy, histomorphometry, osteoprotegerin (OPG), osteopontin (OPN)

(*J Craniofac Surg* 2009;20: 00–00)

The introduction of the piezoelectric terminal and its rapid widespread use in bone tissue surgery came about because of the need to surpass the limits enforced by use of traditional instruments.<sup>1</sup> One of the main characteristics of this instrument is its capacity to make a selective cut on mineralized tissues<sup>2</sup>; this is due to the surgical action ceasing as soon as the working tip of the instrument comes into contact with nonmineralized tissue.<sup>3,4</sup>

For this reason, the piezoelectric terminal is extremely useful in cases of close contact and is therefore appropriate to protect structures defined as "sensitive," such as blood vessels and nerves, or in cases where a slight traumatic effect of the bone structure is necessary.<sup>2,5–7</sup> Nowadays the piezoelectric terminal is applied in numerous medical circles for oromaxillofacial, surgery, and, above all, in preimplant surgical procedures, in expansion of atrophic alveolar crests,<sup>7</sup> in bone distraction,<sup>8</sup> in sinus grafting, and in taking bone samples for grafting.<sup>9,10</sup>

Clinical studies and histologic evaluations have shown that the use of ultrasound in bone surgery allows to obtain higher precision cuts with, from a morphologic point of view, extremely clean porous surfaces without fragments, able to permit an immediate bond with the fibrin, and a quicker clinical recovery.<sup>11</sup> Recent works show the validity of piezoelectric surgery in treating mineralized bone tissue.<sup>12,13</sup>

Our study evaluates the response of the bone tissue after osteotomic cuts made with rotating cutters or piezoelectric terminal. The influence on the bone from both these surgical techniques was evaluated by:

- a histologic analysis, using supravital staining by which it was possible to estimate the quantity of necrosis along the marginal lines of the cut;
- a biologic cellular analysis based on the observation of the growth rate of the osteoblasts from the biopsies taken using both techniques; and
- a biomolecular analysis that analyzes the variation of the expression of molecular markers of osteoblasts such as osteoprotegerin (OPG) and osteopontin (OPN).

The activity of the bone tissue can in fact be analyzed, measuring the specific protein expression of the osteoblasts. In this study, the variations of the expression of OPN and OPG were analyzed. Osteoprotegerin is a member of the superfamily of the tumor necrosis factor receptors, whose role is to inhibit the differentiation of the macrophages in osteoclasts, thereby regulating the function of bone reabsorption mediated by the osteoclasts in vitro and in vivo.<sup>14,15</sup> Osteopontin is one of the most abundant noncollagenic

From the \*Department of Oral Science, University "G. d'Annunzio," Chieti, Italy; †Department of Oral Science, University "Ateneo Vita-Salute San Raffaele," Milan, Italy; ‡Department of Medical and Oral Science and Biophysical Technology (DISTBIMO), University of Genova, Genova, Italy; and §Department of Medical Science, University of Eastern Piedmont, Novara, Italy.

Received March 24, 2009.

Accepted for publication April 8, 2009.

Address correspondence and reprint requests to Stefano Tetè, MD, DDS, Department of Oral Surgery, University "G. d'Annunzio," Chieti, Via dei Vestini, 31-66100 Chieti, Italy; E-mail: tete@unich.it

This work was supported by MIUR, 60% of the grant 2007 was provided to Prof S. Tetè, and by Programma di Ricerca Scientifica di Rilevante Interesse Nazionale 2007/2008 (prot. 2007M9YTFJ\_005) promoted by the Italian Ministero dell'Università e della Ricerca.

Copyright © 2009 by Mutaz B. Habal, MD

ISSN: 1049-2275

DOI: 10.1097/SCS.0b013e3181aee3d3

AQ1  
AQ2

proteins of bone tissue. It belongs to the group of bone sialoproteins, is produced by both osteoblasts and osteoclasts, and could have a role in the regulation of mineralization of the matrix because it seems to be capable of promoting adhesion of the bone cells to the bone surface.<sup>16,17</sup>

**MATERIALS AND METHODS**

**Selection of Patients**

Twenty patients (10 men, 10 women) aged between 22 and 65 years who had to undergo oral surgery were selected at the Oral Surgery Department of San Raffaele Hospital, Milan. Twenty bioptic samples were taken for histologic studies.

At the same department, a total of 19 patients (9 women, 10 men) aged from 11 to 65 years who had to undergo oral surgery were selected, from whom 19 mandibular bone biopsies were collected for cellular and molecular biologic studies.

Patients for both groups were selected according to the following criteria:

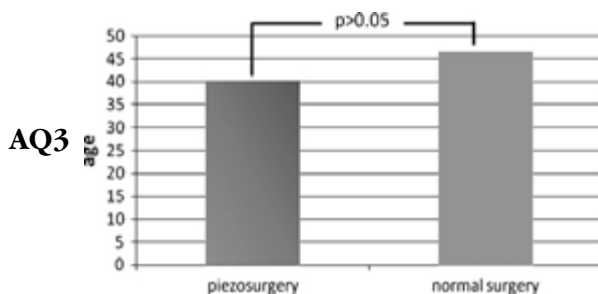
- good general health,
- absence of systemic pathologies, and
- not pregnant.

No particular morphologic bone characteristics were necessary for selecting the patients. The patients were randomly chosen to undergo treatment with piezoelectric terminal or rotating cutter.

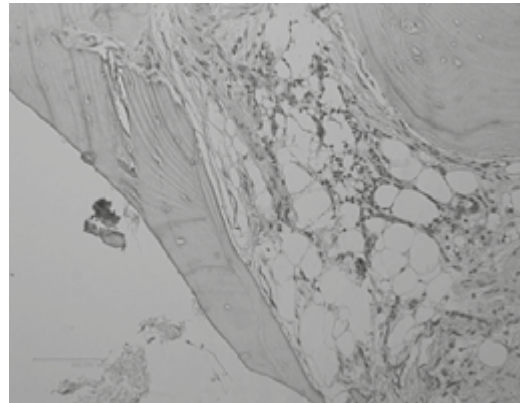
The medium age of the patients selected for the 2 experimental groups was calculated for the cellular and molecular biologic studies. The medium age of the 2 groups was compared to ascertain that there would be no variation between the samples. The medium age of the group treated with piezoelectric terminal was 40 years, whereas that of the group operated with the rotating cutter was 46.5 years (Fig. 1). This difference is not statistically significant. All the patients gave their informed consent according to the ethics regulations of the "Ateneo Vita-Salute San Raffaele," University of Milan.

**Surgical Procedure**

The biopsies were taken by using rotating cutters or piezoelectric terminals while the patients were undergoing oral surgery carried out under local anesthetic (articain with adrenaline 1:100,000 infiltration). A mucoperiosteal incision was made with conventional scalpels, after which the skeletonization of the relevant anatomic site was carried out. No matter what surgery had to be performed, a sample of 3 × 3 mm was taken from a bone tissue, using either piezoelectric terminal or conventional scalpels. All the samples were taken by the same technician.



**FIGURE 1.** Medium age of the patients chosen for the molecular and biologic study. The differences are not statistically significant ( $P > 0.05$ ).

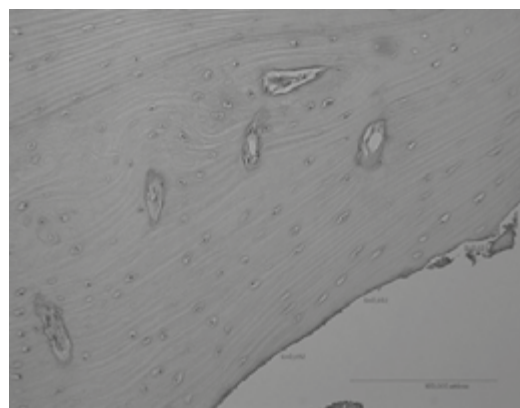


**FIGURE 2.** Osteotomy performed using a piezoelectric terminal. On histomorphometric examination, the necrosis line along the osteotomy edge had an average width of 1.57  $\mu\text{m}$ .

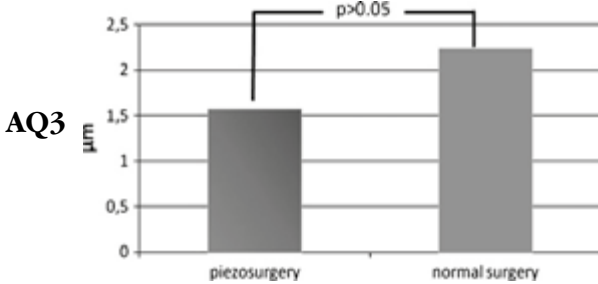
**Collection and Treatment of the Biopsies for Histological Study**

Immediately after taking the bioptic bone samples, they were fixed in a solution of neutral formalin buffer at 10% for 3 days. They were then treated with decalcifying solution (formic acid and chloridic acid 50:50) in a way that the proportions resulted in sample/solution = 1:3 o/n.

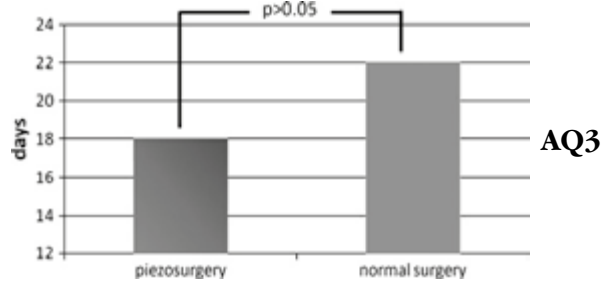
After decalcification, the samples were washed 3 times for 15 minutes under running water and were then placed in an automatic processor for 12 hours. After placing in paraffin, the samples were cut into 6  $\mu\text{m}$  using a rotating microtome. The slices were adhered to the slide by passing in a dry oven at 37°C o/n. The sections were then deparaffinated in ethanol by decreasing cycles until they became water (xyole, 2 cycles; EtOH 100%, 2 cycles; EtOH 96%, 1 cycle; EtOH 70%, 1 cycle; EtOH 50%, 1 cycle; EtOH 30%, 1 cycle; tap water, 3 cycles; 1 cycle = 3 minutes), followed by ematossilin-eosin staining: Mayer hemalum, 5-minute washing under running water until staining changed color; eosin Y, 1 minute;



**FIGURE 3.** Osteotomy carried out with a conventional rotating instrument. The necrosis line measured an average width of 2.23  $\mu\text{m}$ .



**FIGURE 4.** Comparison between the average width of the necrosis lines measured along the samples taken using the different methods, which was not statistically significant ( $P > 0.05$ ).



**FIGURE 6.** Average time necessary for reaching cell confluence in vitro. The difference is not statistically significant ( $P > 0.05$ ).

**AQ6** washing in distilled water for 5 minutes. The sections were dehydrated in increasing solutions of EtOH until 100% xyole. DPX was used as mounting for the coverslip. The sections were examined and photographed with an Axioplan2 imaging microscope (ZEISS, Oberkochen, Germany), and the morphometric measures were evaluated with X-pro software.

**Collection and Treatment of the Biopsies to Study the Cell Proliferation In Vitro and Genic Expression**

After collection, the biopsies were placed in empty sterile containers and immediately processed according to the following procedure. The samples were placed in 10- to 13-mL physiologic solution. The bone was broken into small pieces using tweezers and scalpels, the physiologic solution was suctioned off, and the pieces were washed 3 times with jocklik + SPA pH 7.25. The biopic samples were then placed in 5 mL of jocklik and 250 µL collagenase (type IV S C1889) previously defrosted and agitated for 30 minutes in a thermostatic bath at 37°C, after which 5 mL of 10% Iscove was added. The liquid was suctioned off, and the samples were washed with 7- to 8-mL of the same solution. The bone was then transferred to flasks, cultured in Iscove's modified Dulbecco's medium + 1% P/S + 10% fetal bovine serum + 0.2% Fungizone + 0.1% gentamicin, and incubated at 37°C with 5% CO<sub>2</sub>. Independently of the rapidity of growth, every 15 days, the flasks were changed to avoid contamination. The cells that reached confluence were removed with trypsin and transferred to flasks of increasing size (having passed through a cell strainer at the first stage to eliminate bone fragments). Once a sufficient quantity of cells was

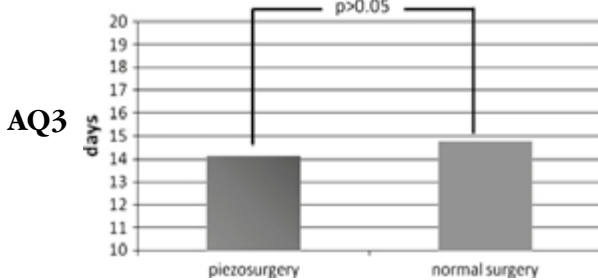
obtained, they were removed with a cell scraper and RNA extraction was carried out.

**RNA Extraction**

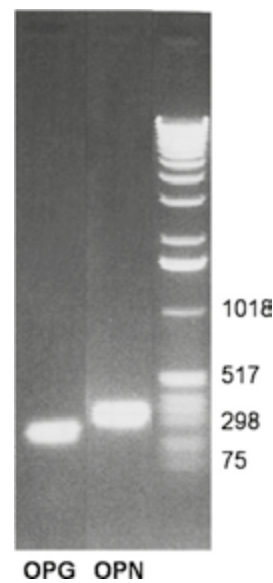
The RNA of the osteoblast plate culture was extracted using RNeasy Mini Kit (QIAGEN) following the manufacturer's instructions, and the samples were previously homogenized by centrifuge on QIAshredder (QIAGEN) columns according to the manufacturer's instructions. Briefly, 4 µg of total RNA was reverse transcribed using the Superscript First-Strand Synthesis System kit for reverse transcription polymerase chain reaction (RT-PCR; Invitrogen, Milan, Italy) according to the manufacturer's instructions, using oligo(dT) and random hexamers to initiate the RT at a total volume of 20 µL and digesting the DNA with DNaseI in column. The product of each RT was diluted 1:5 in water, and 4 µL of samples was used for the RT-PCR reaction.

**AQ11**

**AQ12**

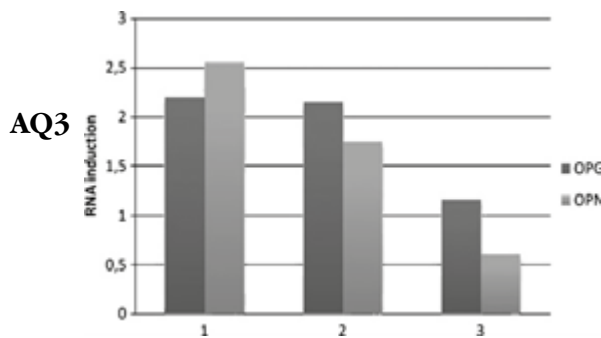


**FIGURE 5.** Average timing for the beginning of the in vitro cell growth of the 2 samples. The difference is not statistically significant ( $P > 0.05$ ).



**FIGURE 7.** RT-PCR analyses carried out to evaluate the expression OPG and OPN in the various samples of bone tissue.

**AQ3**



**FIGURE 8.** Summary graph of the RT-PCR analysis to find the level of OPG and OPN gene expression, carried out on bone tissue samples taken with the different methods (1: piezosurgery, age 45 years; 2: piezosurgery, age 11 years; 3: normal surgery, age 26 years).

**Reverse Transcriptase Polymerase Chain Reaction**

The reaction mix, for a total volume of 10  $\mu$ L, contains 5  $\mu$ L of LightCycler 480 SYBR green Master (Roche, Monza, Italy), 4  $\mu$ L of template, and 1  $\mu$ L of primer (forward and reverse) at a concentration of 10  $\mu$ M. Amplifications were performed with the Light Cycler 480 (Roche); each sample was examined 3 times according to the following protocol:

Preincubation	95°C/5 min
Amplification (55 cycles)	95°C/10 s
	61°C/0 s
	72°C/20 s
Melting curve	95°C/5 s
	65°C/1 min
Cooling	40°C/10 min

The quantification of each sample of PCR was calculated from the standard curve relative to each couple of primers and standardized for the gene housekeeping (GAPDH). The primer sequences used for the RT-PCR are as follows:

HOPG5 FW 5'TGGCACCAAAGTAAACGCAGAGAG 3'  
 HOPG5 RW 5'GGTCACTGGGTTTGCATGCCTTIA 3'  
 HOPN2 FW 5'TGGCCGAGGTGATAGTGTGGTTTA 3'  
 HOPN2 RW 5'TGTGGAATTCACGGCTGACTTTGG 3'

HGAPDH FW 5'GGAGTCAACGGATTGGT 3'  
 HGAPDH RW 5'GTGATGGGATTCCATTGAT 3'

**Statistical Analyses**

The statistical processing of the results was carried out using the Shapiro-Wilk test, for the analyses of the distribution variables. The significance of the results was evaluated using the *t*-test and the linear regression test, with  $P = 0.05$ .

**RESULTS**

**Histomorphometric Study**

Macroscopically, observation of the histologic specimens showed that the osteotomy lines at the edge of the samples taken with the piezoelectric terminal were better defined than those osteotomy edges observed on samples taken using a rotating instrument (Figs. 2 and 3). Histomorphometric measurement showed that the necrotic line on the osteotomy edges of the samples taken with the piezoelectric terminal was on average 1.57  $\mu$ m thick, whereas on the samples taken with the rotating cutter, it was on average 2.23  $\mu$ m thick. This difference was not shown to be statistically significant ( $P > 0.05$ ; Fig. 4).

**Cell Study**

The osteoblastic cells, obtained as previously described from the samples of bone tissue taken using both methods, were placed in culture to analyze the proliferation response and the speed of growth, by observing the average time for proliferation and reaching a confluence of the cells. These were on average 14.1 days in the osteoblast cultures obtained from samples taken with the piezoelectric terminal, with the cell confluence reaching at 17.9 and 14.7 days for the samples taken with the rotating instrument, with them reaching cell confluence after 22 days (Figs. 5 and 6). These differences are not statistically significant ( $P > 0.05$ ).

**Biomolecular Study**

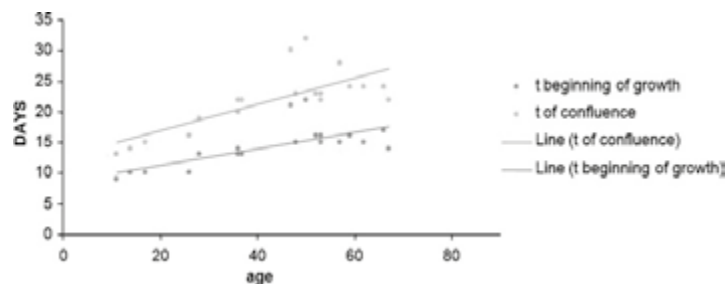
After the evaluation of the gene expression of the OPG and of the OPN in 5 samples (standardized according to gene housekeeping, GAPDH), it was seen how the induction of the RNA of OPG and OPN genes was highly variable. It is interesting to note the presence of a strong correlation in the levels of expression of OPG and OPN (Figs. 7 and 8).

**DISCUSSION**

Previous studies have analyzed the impact on bone tissue of the rotating cutter with respect to the piezoelectric terminal. A histologic comparison of the effect of a standard ultrasonic insertion with the rotating cutter and the surgical drill was made in 1975. This

AQ13

AQ3



**FIGURE 9.** Bivariate study: beginning of growth and confluence times in relationship to the subjects from whom the samples were taken (beginning of growth  $t: P = 0.00096, R^2 = 0.48$ ; confluence  $t: P = 0.00021, R^2 = 0.56$ ).



work demonstrated how the ultrasonic insertion was able to cut without burning the bone and allowed for a higher percentage of healing.<sup>12</sup>

Many studies have been carried out to evaluate the advantages of these instruments from a clinical point of view as well as the influence they can have on the healing of the bone tissue and the effects on the bone cells along the osteotomy line.

Studies carried out on animal models have mainly been addressed to the evaluation of the healing characteristics of the bone tissue after osteotomy carried out by piezosurgery. Such studies have highlighted the various advantages connected with the use of this instrument in respect to the traditional cutting instruments, such as the bone cutter and saw. The advantages include an improvement in the healing of the bone tissue, mainly due to an extremely favorable condition that reduces or eliminates the inflammation of the bone before the beginning of the regeneration phase.<sup>11</sup> The more favorable response of the bone after piezosurgery may also be evaluated on the basis of the percentage of postsurgery bone reabsorption/regeneration.<sup>11</sup> The only limitations of the piezoelectric terminal seem to be those connected to the difficulty in using it in regions with limited access and in cutting thick bones.<sup>26</sup>

On the basis of previous studies, the histologic sections obtained with the piezoelectric terminal, differently from those obtained with the traditional rotating instruments, show a total absence of necrosis, vital osteocytes of normal morphology and size, and no cell suffering.<sup>18</sup>

In this study, the histologic preparations obtained from samples taken with the piezoelectric terminal showed cleaner osteotomic lines than those on the samples obtained with the rotating cutter. This phenomenon is probably due to the characteristics of the piezoelectric terminal that, as previously stated, allows for extreme precision, thanks to the microvibration, causing minimum trauma.

No statistically significant differences were found in this study between the margin of necrosis measured in samples taken with the piezoelectric terminal (average width, 1.57  $\mu\text{m}$ ) and those obtained with the conventional cutter (average width, 2.23  $\mu\text{m}$ ). The presence of a thin necrotic line seemed to be physiological, which is correlated to a fissure of a cut near which it is normal to find a margin of inevitably necrotic cells in that they are affected by the cut. Notwithstanding this, the samples taken with the cutter showed a margin of necrotic tissue generally smaller than those reported in previous studies.<sup>19</sup> It is also probable that a cut affected with a good irrigation that stops the temperature from rising, together with a clean cut by the surgeon, may avoid wide edges of necrosis even in those biopsies done with a rotating cutter.

However, few studies have been done on a biomolecular level. A study carried out on bone chips taken with various techniques and placed in cultures in the absence of growth factors shows a lack of correlation between the methodology of taking the samples and the speed of growth and osteoblastic growth marker expression.<sup>20</sup> One factor that seems to influence quickness of growth is the size of the bone chip, which, however, in the current study was the same for the various methods used for taking the samples.<sup>11,21</sup> The cells deriving from the samples taken with the piezoelectric terminal showed an initial growth on average at day 14.1 and reached on average a confluence at day 17.95. In the cultures of cells obtained with samples taken with the rotating cutter, instead, the cells showed an average initial growth at day 14.27, whereas around day 22, they reached a cell confluence. Even in this case, the lack of statistical significance in the comparisons of the growth and confluence times in the biopsies taken with the piezoelectric terminal and with the cutter probably means that the different types of instruments used for the osteotomy do not significantly influence the time of the beginning of growth nor the confluence time, but it is not to be excluded that other factors determine the differences.

With regard to this, a bivariate analysis was carried out that showed a relationship between the in vitro cell growth time and cell confluence with the age of the subject participating in the study. It was noticed that there was a significant relationship between the beginning of growth time and the age of the donor and an even more significant one between the confluence time and the age (Fig. 9).<sup>F9</sup> It can therefore be concluded that more than the type of instrument used for the surgery, it seems that the age of the patient is the discriminating factor to obtain a better and quicker regeneration of the bone tissue.

Although there have been many studies to evaluate the histologic characteristics, on human as well as animal preparations, obtained with various instruments, there are very few that are aimed at analyzing the existence of differences in the expression of different bone makers on a level of the edges of the cut.

After the evaluation of the induction of the OPG and OPN RNA, carried out by RT-PCR, it was noted that the expression of these bone tissue markers does not seem to be correlated with the surgical techniques used but more with the genotype characteristics of the patient. Given the limited number of samples available in this study, however, this parameter requires further evaluation.

In conclusion, the healing process of the tissues and bone regeneration results in being correlated to 2 main factors: the response of the host to the surgical intervention and the technique used.

The first factor, which is biologic, depends on:

- the general characteristics of the host, such as the biologic age and relative number of stem cells available for the healing, the efficiency of the vascularization of the surgical wound, eventual tabagism, and/or the presence of microangiopathies and other specific factors<sup>22</sup>;
- the local characteristics of the tissue site of the intervention. These vary according to the facial and tissue biotype and the degree of atrophy that has affected the site of the defect.<sup>23</sup> The atrophy, for example, of an edentate area involves the mineralized tissues (modifying the quality and the quantity of the residual bone crest) as well as the soft tissue (reducing the thickness and the degree of vascularization of the mucous).

The second factor depends on the expertise and ability of the surgeon. The instruments used also have an influence on the results of the intervention: a lesser traumatic and evasive intervention that determines a better postoperative course, such as the piezoelectric technique, is certainly to be considered preferable.<sup>24,25</sup>

The critical evaluation of the results obtained correlated with the simplicity of the operative technique, the improved intraoperative visibility, the respect for the nerve and vascular structures (thanks to the modulated and selective ultrasonic frequency on the mineralized tissue), and the maximum precision in cutting and the minimum damage to the tissue that allows for a reduction of the postoperative discomfort of the patient all make the piezoelectric technique, in respect to that of the osteotomy with the rotating cutter, efficacious and indicated a wide use in oral and maxillofacial surgery.

## REFERENCES

1. Vercellotti T. La chirurgia ossea piezoelettrica. *Dent Mod* 2003;1:21-55
2. Robiony M, Polini F, Costa F, et al. Endoscopically assisted intraoral vertical ramus osteotomy and piezoelectric surgery in mandibular prognathism. *J Oral Maxillofac Surg* 2007;65:2119-2124
3. Vercellotti T. Technological characteristics and clinical indications of piezoelectric bone surgery. *Minerva Stomatol* 2004;53:207-214
4. Robiony M, Polini F, Costa F, et al. Piezoelectric bone cutting in multiple maxillary osteotomies. *J Oral Maxillofac Surg* 2004;62:759-761
5. Morgan TA, Fridrich KL. Effects of the multiple-piece maxillary osteotomy on the periodontium. *Int J Adult Orthod Orthognath Surg* 2001;16:255-265

6. Vercellotti T. Piezoelectric surgery in implantology: a case report—a new piezoelectric ridge expansion technique. *Int J Periodontics Restorative Dent* 2000;20:358–365
7. Kerawala CJ, Martin IC, Allan W, et al. The effect of operator technique and bur design on temperature during osseous preparation for osteosynthesis self-tapping screws. *Oral Surg Oral Med Oral Pathol Oral Radiol Endod* 1999;88:145
8. Politi M, Vercellotti T, Polini F, et al. Piezoelectric surgery: a new method of bone cutting. Preliminary experience in osteogenesis distraction. Presented at II International Meeting on Distraction Osteogenesis of the Facial Skeleton; Italy, Bologna; September 26–28, 2002
9. Torrella F, Pitarch J, Cabanes G, et al. Ultrasonic osteotomy for the surgical approach of the maxillary sinus: a technical note. *Int J Oral Maxillofac Implants* 1998;13:697–700
10. Vercellotti T, De Paoli S, Nevins M. The piezoelectric bony window osteotomy and sinus membrane elevation: introduction of a new technique for simplification of the sinus augmentation procedure. *Int J Periodontics Restorative Dent* 2001;21:561–567
11. Horton JE, Tarpley TM, Jr., Wood LD. The healing of surgical defects in alveolar bone produced with ultrasonic instrumentation, chisel, and rotary bur. *Oral Surg Oral Med Oral Pathol* 1975;39:536–546
12. Vercellotti T, Nevins ML, Kim DM, et al. Osseous response following resective therapy with piezosurgery. *Int J Periodontics Restorative Dent* 2005;25:543–549
13. Vercellotti T, Russo C, Giannotti S. A new piezoelectric ridge expansion technique in the lower arch—a case report. *World Dent* 2003;14:1–3
14. Simonet WS, Lacey DL, Dunstan CR, et al. Osteoprotegerin: a novel secreted protein involved in the regulation of bone density. *Cell* 1997;89:309–319
15. Schoppert M, Preissner KT, Hofbauer LC. RANK ligand and osteoprotegerin: paracrine regulators of bone metabolism and vascular function. *Arterioscler Thromb Vasc Biol* 2002;22:549–553
16. Carolina W, Sara B, Annika H, et al. Osteopontin: a rapid and sensitive response to dioxin exposure in the osteoblastic cell line UMR-106. *Biochem Biophys Res Commun* 2006;341:116–200
17. Gordon JA, Tye CE, Sampaio AV, et al. Bone sialoprotein expression enhances osteoblast differentiation and matrix mineralization in vitro. *Bone* 2007;41:462–473
18. Aro H, Kallioniemi H, Aho AJ, et al. Ultrasonic device in bone cutting. A histological and scanning electron microscopical study. *Acta Orthop Scand* 1981;52:5–10
19. Vercellotti T, Corvace A, Palermo A, et al. The piezoelectric osteotomy in orthopedics: clinical and histological evaluations (pilot study in animals). *Mediterr J Surg Med* 2001;9:89–95
20. Chiriac G, Herten M, Schwarz F, et al. Autogenous bone chips: influence of a new piezoelectric device (Piezosurgery) on chip morphology, cell viability and differentiation. *J Clin Periodontol* 2005;32:994–999
21. Pallensen L, Schou S, Aaboe M, et al. Influence of particle size of autogenous bone grafts on the early stages of bone regeneration: a histologic and stereologic study in rabbit calvarium. *Int J Oral Maxillofac Implants* 2002;17:498–506
22. Lu C, Hansen E, Sapozhnikova A, et al. Effect of age on vascularization during fracture repair. *J Orthop Res* 2008;26:1384–1389
23. Marx RE. Bone and bone graft healing. *Oral Maxillofac Surg Clin N Am* 2007;19:455–466
24. Landes CA, Stübinger S, Rieger J, et al. Critical evaluation of piezoelectric osteotomy in orthognathic surgery: operative technique, blood loss, time requirement, nerve and vessel integrity. *J Oral Maxillofac Surg* 2008;66:657–674
25. Landes CA, Stübinger S, Laudemann K, et al. Bone harvesting at the anterior iliac crest using piezoosteotomy versus conventional open harvesting: a pilot study. *Oral Surg Oral Med Oral Pathol Oral Radiol Endod* 2008;105:19–28
26. Eggers G, Klein J, Blank J, et al. Piezosurgery: an ultrasound device for cutting bone and its use and limitations in maxillofacial surgery. *Br J Oral Maxillofac Surg*. 2004;42:451–453
27. Beziat JL, Bera JC, Lavandier B, et al. Ultrasonic osteotomy as a new technique in craniomaxillofacial surgery. *Int J Oral Maxillofac Surg* 2007;36:493–500

**1 La chirurgia orale piezoelettrica**

M. Pasi, R. Vinci, D. Di Stefano, E. F. Gherlone  
IOS Italian Oral Surgery 5/2008

---

**2 In vitro evaluation of osteoblast-like cells from different sources**

F. Mastrangelo, M. Tranasi, V. Zizzari, D. Farronato, T. Traini, R. F. Grassi, L. Stuppia, S. Tetè  
atti del 86TH general session of international association of dental research (I.A.D.R.) Toronto 2-5 Giugno

---

**3 A macro-and nanostructure evaluation of a Novel Dental Implant**

S. Tetè, F. Mastrangelo, T. Traini, R. Vinci, G. Sammartino, G. Marenzi, E. F. Gherlone  
(Implant Dent. 2008 Sep)

20  
08

IOS

## La chirurgia orale piezoelettrica

POSITION PAPER (7-14)

M. PASI, R. VINCI, D. DI STEFANO, E.F. GHERLONE

Ateneo Vita-Salute San Raffaele di Milano  
Corso di Laurea in Igiene Dentale  
Unità Operativa di Odontoiatria  
Direttore: prof. E.F. Gherlone

### Punti chiave

1. Gli ultrasuoni sono usati da decenni in numerose branche della medicina diagnostica e terapeutica.
2. Pur essendo stati usati in chirurgia orale fin dagli anni Settanta, è solo con l'avvento del terzo Millennio che vengono condotti studi che confermano i vantaggi dell'utilizzo del terminale piezoelettrico in chirurgia orale e maxillo-facciale.
3. Gli interventi eseguiti con l'utilizzo del manipolo piezoelettrico non solo permettono un minor danno dei tessuti duri interessati (in particolare l'osso) e l'assoluto rispetto dei tessuti molli, ma danno un maggior confort al paziente sia durante l'intervento sia nel decorso postoperatorio, dove anche la guarigione è più rapida.
4. L'accusa di eccessiva lunghezza dell'intervento eseguito con il metodo piezoelettrico rispetto all'uso di strumenti rotanti è oggi superata dal miglioramento delle apparecchiature e dei materiali di costruzione delle punte. Il poco tempo in più che si impiega è ampiamente ripagato dai vantaggi in termini di sicurezza, diminuito stress per il paziente, minor tempo di guarigione e di osteointegrazione degli impianti.
5. Alla luce di queste considerazioni riteniamo oggi la chirurgia piezoelettrica non più una semplice alternativa all'utilizzo di strumenti tradizionali, ma una nuova tecnica che deve sostituire frese e scalpelli in molte applicazioni cliniche, in particolare gremectomie, estrazioni di denti inclusi o anchilosati, rialzo del seno mascellare per via laterale o crestale, espansione ossea crestale (split-crest), prelievi in blocco o di chips intra ed extra-orali.

### Key points

#### ***The oral piezosurgery***

1. *Ultrasonic waves have been used for many years in medicine for several diagnostic and therapeutical purposes*
2. *Modulated ultrasonic frequency are used in oral surgery since the 70ies, but only in recent years histomorphometric studies have confirmed their advantages in oral and maxillo-facial surgery.*
3. *Piezosurgery handpieces allow highly precise and safe cutting of hard tissue (in particular bone), without harming nerves, vessels and soft tissues. The comfort for the patient is better during and after surgical treatment, with a more rapid healing.*
4. *The difference in time required for surgical procedures between piezosurgery and conventional technique is negligible today. The little more time necessary is repaid by excellent wound healing, reduced patient stress and no soft tissue injuries.*
5. *The piezosurgery technique is not only a simple alternative to traditional rotating instruments, but also a new technique for gremectomy, impacted or ankylosed teeth, maxillary sinus floor lift, crestal bone splitting, intra and extra oral bone grafting (blocks or chips).*

M. Pasi, et al.

## Introduzione

■ Gli ultrasuoni sono utilizzati da decenni in medicina, in campo sia diagnostico sia terapeutico. L'ecografia è utilizzata per una ricerca tridimensionale non invasiva, mentre da un punto di vista curativo essi sono impiegati per la litotripsia sia in urologia sia in otorinolaringoiatria, e inoltre in neurochirurgia, ortopedia, dermatologia e oculistica.

In odontoiatria sono stati utilizzati per la prima volta negli anni Settanta (1); quindi altri Autori hanno accennato a un loro uso in chirurgia ossea nel decennio successivo (2), ma solo sul finire del secolo scorso sono stati pubblicati sempre più numerosi lavori clinici sull'utilizzo del terminale piezoelettrico nel rialzo del pavimento del seno mascellare (3) e nell'espansione alveolare (4).

Con l'avvento del terzo Millennio la chirurgia piezoelettrica ha preso sempre più piede in odontoiatria, anche grazie alla messa a punto di apparecchiature più performanti e di punte di materiali e forme più adatte a ogni esigenza. In particolare questa tecnica chirurgica trova oggi applicazione nelle estrazioni di germi dentari (in pazienti anche molto giovani) e in quelle di denti inclusi in contiguità con strutture delicate, come il nervo mandibolare, il seno mascellare, le radici di denti adiacenti, nell'asportazione di cisti dei mascellari. Nella chirurgia endodontica: nel rialzo del pavimento del seno mascellare, nell'espansione della cresta alveolare, nelle biopsie ossee, nei prelievi di osso dalla branca montante e dal corpo della mandibola, ma anche dalla teca cranica parietale, nella rimozione di impianti e mezzi di osteosintesi.

In chirurgia ortodontica e in tutti i casi di osteoplastica o osteotomia dei mascellari e nella preparazione dei siti implantari.

## Caratteristiche del taglio piezoelettrico

■ Gli ultrasuoni sono un particolare tipo di onde meccaniche tridimensionali "elastiche", caratterizzate da una frequenza superiore a 25.000 Hz. Gli ultrasuoni vengono prodotti in due modi differenti: per magnetostrizione (un fascio di lamelle di metallo oscilla in una bobina attraversata da corrente alternata), come nei primi ablatori del tartaro, oppure sfruttando il fenomeno della piezoelettricità, caratteristico di materiali a struttura cristallina definiti "trasduttori" (inizialmente cristalli di

quarzo che modificano le proprie dimensioni quando vengono attraversati da una carica elettrica, successivamente sostituiti da ceramiche a struttura cristallina). L'effetto piezoelettrico può essere *diretto* (variazione di potenziale generata producendo modifiche dimensionali sul trasduttore: da *Piezein*: comprimere, pressare). Ma per praticità nelle apparecchiature medicali si utilizza l'*effetto piezoelettrico inverso*, in cui si ottiene una variazione dimensionale del trasduttore applicando una differenza di potenziale ai suoi estremi.

Le caratteristiche fisiche del taglio piezoelettrico sono:

- **Microvibrazione:** le microvibrazioni sviluppate dall'apparecchio piezoelettrico si trovano in un intervallo compreso tra 27.000 e 29.500 Hz; l'ampiezza della vibrazione, sia sul piano orizzontale (60/200  $\mu\text{m}$ ) sia sul piano verticale (20/60  $\mu\text{m}$ ), varia in rapporto alla forma e al tipo di inserto.

- **Hammering action:** deriva dall'alternarsi di due tipi di onde ultrasoniche con  $\lambda$  differente, una corta e una lunga, e consente di mantenere l'inserto costantemente pulito (diversamente il tessuto osseo, accumulandosi, verrebbe letto dallo strumento come tessuto non mineralizzato e tutta l'energia cinetica presente verrebbe trasformata in calore generando necrosi dei tessuti limitrofi).

- **Effetto di cavitazione:** grazie alla presenza della soluzione fisiologica necessaria per il raffreddamento, si produce questo fenomeno fisico caratterizzato dalla formazione di bolle di vapore a bassissima pressione che, implodendo, danno origine a un'azione meccanica di pulizia, rendendo il campo operatorio esangue.

Le principali caratteristiche cliniche del terminale piezoelettrico sono:

- **Taglio selettivo:** permette un taglio preciso e sicuro dei tessuti duri, permettendo di operare in campi operatori ad alto rischio anatomico (mucose, membrane, vasi sanguigni, SNC e SNP), come conseguenza della bassa frequenza ultrasonica modulata (5).

- **Taglio micrometrico:** conferisce allo strumento un alto controllo chirurgico, una maggiore precisione, una maggiore sicurezza intraoperatoria, limitando nel contempo il danno tissutale, in particolar modo agli osteociti (6).

- **Sito esangue:** è una conseguenza dell'effetto di cavitazione già descritto.



L'uso del terminale piezoelettrico presuppone un periodo di apprendistato per l'operatore. Infatti, è necessario guidare lo strumento lungo la linea osteotomica prefissata senza praticare alcuna pressione, in quanto questa impedirebbe la corretta vibrazione della punta, provocando contemporaneamente surriscaldamento dell'osso e la possibile frattura dell'inserto.

Con l'utilizzo corretto dello strumento si è potuta valutare clinicamente la migliore accettazione dei pazienti nei confronti degli strumenti rotanti: infatti la vibrazione non è quasi apprezzabile. Inoltre, l'atraumaticità verso i tessuti molli, permette di effettuare tagli e scollamenti dei tessuti più ridotti e minori divaricazioni degli stessi anche dove la visibilità non è ottimale. Questa riduzione delle manovre, associata alle caratteristiche di taglio dello strumento, riduce poi di molto l'edema postoperatorio, migliorando quindi il "gradimento" del paziente verso questo tipo di approccio chirurgico, come già affermato da altri Autori (7).

Oltre alla valutazione clinica, si stanno conducendo studi istomorfologici sui tessuti trattati con il terminale piezoelettrico, in confronto agli strumenti rotanti. Sono state studiate la quantità di osso necrotico sulla superficie di taglio, la velocità di crescita degli osteoblasti, l'espressione genica di marker degli stessi osteoblasti. La qualità dell'osteotomia piezoelettrica è migliore se comparata a quella eseguita con strumenti rotanti sia in termini di precisione sia in termini di rispetto del tessuto osseo. Biopsie eseguite successivamente a procedure chirurgiche effettuate con terminale piezoelettrico indicano una maggior crescita ossea rispetto a quella riscontrata in seguito all'utilizzo di frese rotanti. Dai risultati preliminari si ritiene che ciò possa essere dovuto alla minore percentuale di necrosi evidenziabile sulla linea osteotomica (fig. 1). Allo stesso modo la biologia molecolare evidenzia un maggior rispetto dell'osso prelevato con la tecnica piezoelettrica, confrontata con qualunque tipo di strumento rotante. La chirurgia piezoelettrica fornisce una migliore risposta ossea anche in termini di rigenerazione, in accordo con altri studi che hanno confrontato i livelli di riassorbimento e rigenerazione ossea dopo chirurgia resettiva effettuate con differenti metodiche (8, 9). Anche le sedi donatrici di prelievi ossei vanno incontro a una miglior guarigione con una più precoce e matura ricostituzione ossea.

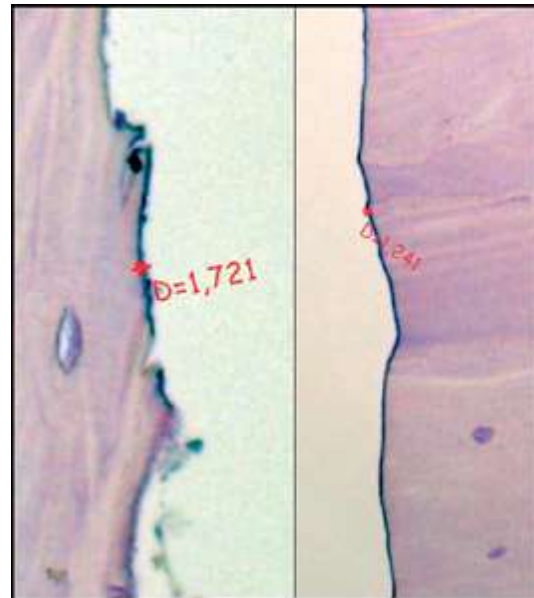


Fig. 1 - Spessore della linea di necrosi sul margine osteotomico con frese rotanti (a sinistra) e con terminale piezoelettrico

Riassumendo, il margine di necrosi ha uno spessore medio di  $1,57 \mu\text{m}$  nei campioni prelevati con terminale piezoelettrico e uno spessore di  $2,23 \mu\text{m}$  in quelli prelevati con frese convenzionali. I campioni prelevati con terminale piezoelettrico in media presentano un'iniziale crescita al giorno 14,1 e giungono in media a confluenza al giorno 17,95, mentre i campioni prelevati con fresa rotante presentano in media un'iniziale crescita al giorno 14,27 ma giungono a confluenza mediamente al giorno 22. Ulteriori studi saranno necessari per valutare gli effetti biologici del terminale piezoelettrico e degli strumenti rotanti sulla guarigione ossea nel lungo termine.

### Ambiti di applicazione e casi clinici

- L'uso del terminale piezoelettrico è ormai entrato nella nostra routine quotidiana, considerati gli innumerevoli vantaggi che ha portato in termini di sicurezza e di tranquillità del paziente, oltre a quelli biologici esposti sopra. Vediamo quali sono i campi di applicazione più comuni.
- **Germectomie:** l'estrazione di germi dentari, generalmente dei denti del giudizio inferiori o di soprannumerari, viene quasi sempre effettuata su pazienti molto giovani, con tutte le implicazioni di

M. Pasi, et al.

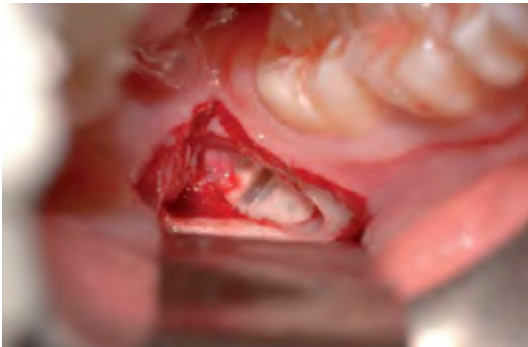


Fig. 2 - Coronotomia del germe dell'ottavo

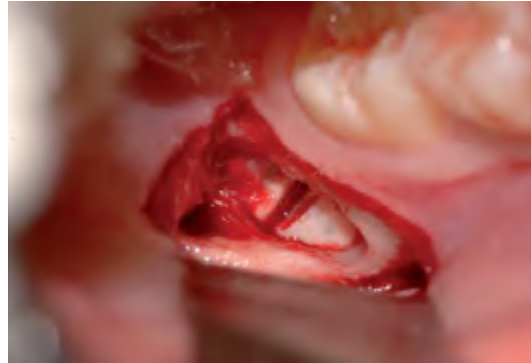

Fig. 3 - La divisione completa del germe

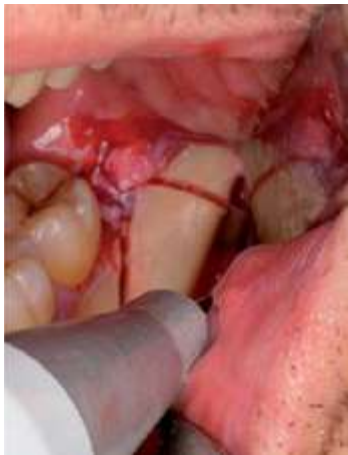

Fig. 4 - Apertura dello sportello osseo per visualizzare e isolare 3.8 con apici a contatto con il canale mandibolare

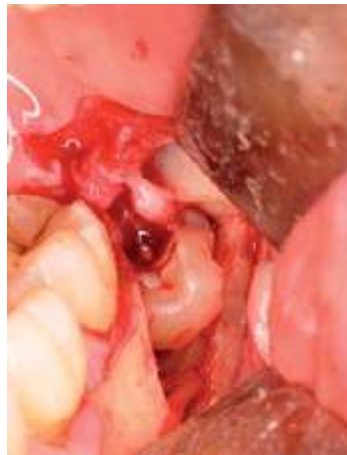

Fig. 5 - Odontotomia

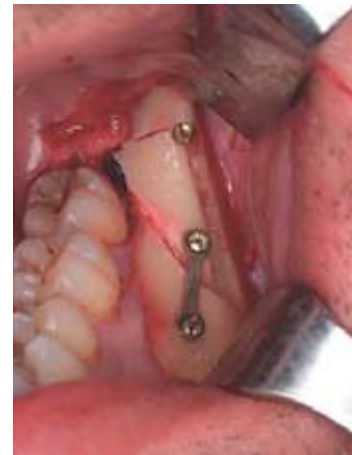

Fig. 6 - Osteosintesi: si nota il perfetto adattamento dei margini dell'osso asportato al sito di origine, grazie al taglio micrometrico del terminale piezoelettrico

tipo ansioso e quindi di scarsa collaborazione che ne conseguono. Inoltre, proprio per la giovane età dei pazienti, è ancora più importante rispettare il più possibile le strutture anatomiche interessate dall'intervento. Si cerca di rendere il meno traumatico possibile l'intervento già dalla fase dell'anestesia, utilizzando un iniettore elettronico (SleeperOne - DHT/MC Italia, Lainate) e aghi atraumatici (DHT), un altro ausilio alla moderna chirurgia orale. Con le più moderne apparecchiature piezoelettriche è possibile eseguire anche l'odontotomia, dividendo il germe in modo da estrarlo da una minima breccia ossea, senza assolutamente ricorrere a strumenti rotanti (figg. 2, 3).

• **Estrazione di denti inclusi o anchilosati:** l'avulsione di denti inclusi, anchilosati o addossati a denti contigui, può metterci in difficoltà proprio

per il rischio di ledere le strutture vicine al dente da estrarre con l'utilizzo di frese in zone dove la visibilità è compromessa. Il terminale piezoelettrico, mediante l'uso combinato di punte taglienti e di punte diamantate (più adatte a "consumare" l'osso, senza una vera e propria capacità di taglio), permette di agire con maggiore sicurezza. Inoltre, l'incisione ossea conservativa permessa dal terminale piezoelettrico e il danno osseo molto contenuto permettono di riposizionare lo sportello al termine dell'intervento: questo favorirà ancora di più la guarigione, in termini sia di rapidità sia di qualità, creando una cavità chiusa che conterrà il coagulo che darà origine all'ossificazione (figg. 4-6).

In caso di denti voluminosi, se lo spazio è sufficiente, si può ricorrere all'uso di strumenti rotanti per separare la corona dalle radici, al fine di ridur-

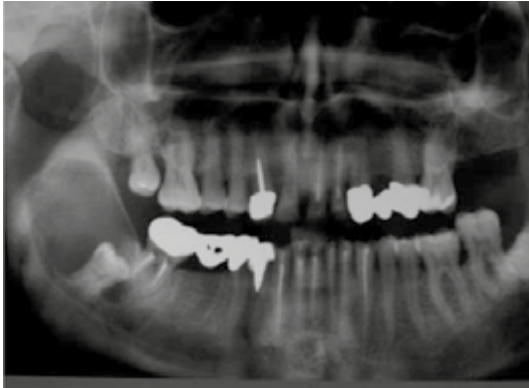

Fig. 7 - Cisti follicolare a carico di 48 ritenuto

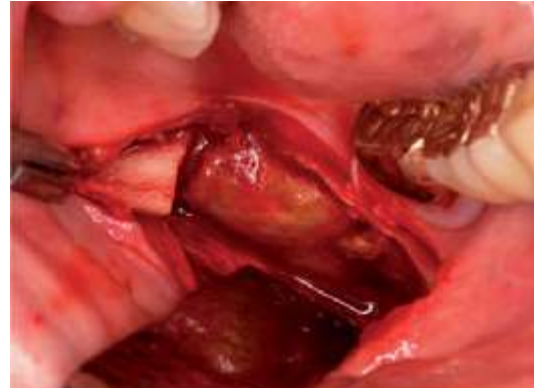

Fig. 8 - La parete cistica intatta dopo asportazione della parete ossea con punta diamantata del manipolo piezoelettrico

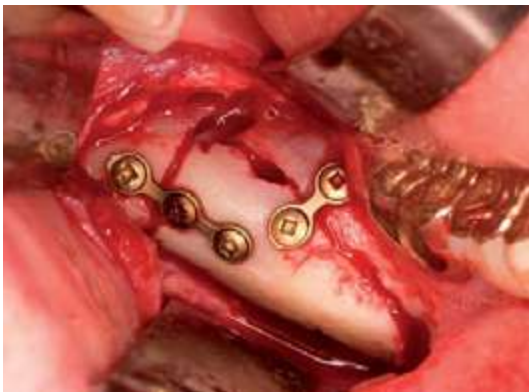

Fig. 9 - L'osteosintesi

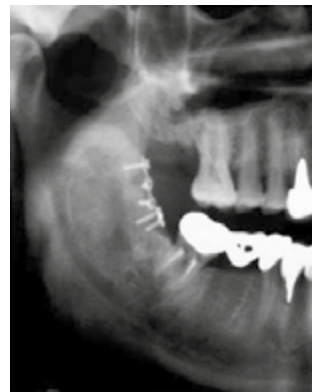

Fig. 10 - Controllo radiografico a 6 mesi: si noti la completa ricostituzione del tetto del canale mandibolare

re la durata dell'intervento, senza compromettere l'osteotomia e senza avvicinarsi alle strutture più delicate.

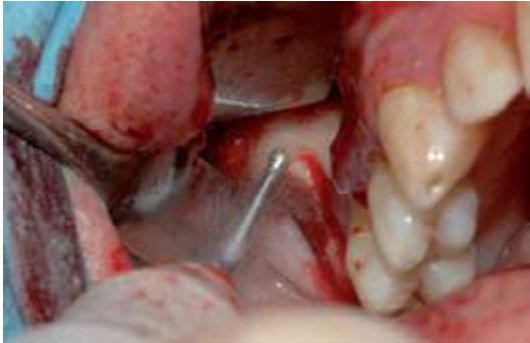- **Asportazione di cisti dei mascellari:** allo stesso modo, l'utilizzo del terminale piezoelettrico si rivela molto utile negli interventi di enucleazione di cisti di qualunque origine. Utilizzando una punta diamantata è possibile rimuovere l'osso sovrastante senza ledere la parete cistica, facilitandone quindi l'asportazione (*figg. 7, 8*). Anche in questo caso è possibile richiudere la cavità utilizzando il tassello di osso asportato (*fig. 9*). La guarigione, anche in caso di grandi cavità, è molto rapida (*fig. 10*).

- **Chirurgia endodontica:** per gli stessi motivi esposti nei paragrafi precedenti, l'apicectomia e l'asportazione di lesioni periapicali presentano

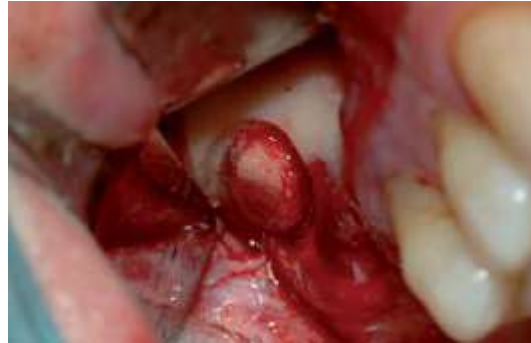notevoli vantaggi, a fronte di ridotti rischi per le radici e le strutture adiacenti (seno mascellare, forame mandibolare, ...).

- **Rialzo del pavimento del seno mascellare:** il rialzo della membrana del seno mascellare è stato, insieme all'espansione crestale, l'intervento che ha fatto conoscere e apprezzare la tecnica chirurgica piezoelettrica (3, 10). L'utilizzo di un inserto diamantato a media potenza e media frequenza permette di erodere l'osso fino alla membrana di Schneider, senza correre il rischio di lederla (*figg. 11, 12*) (11). Dopo aver visualizzato la membrana del seno con la punta diamantata, utilizzando un inserto liscio a cono rovesciato, usato a bassa potenza e bassa frequenza, si inizia a scollare la membrana stessa dal pavimento osseo; quindi, sempre a bassa potenza, con degli scollatori smussi

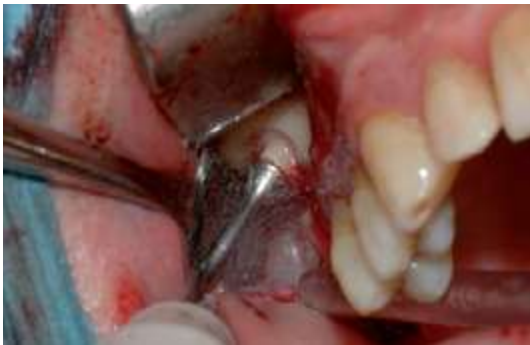M. Pasi, et al.



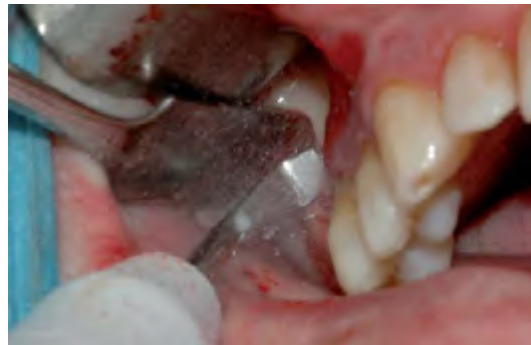**Fig. 11** - Realizzazione finestra di accesso al seno mascellare di osteotomia piezoelettrica



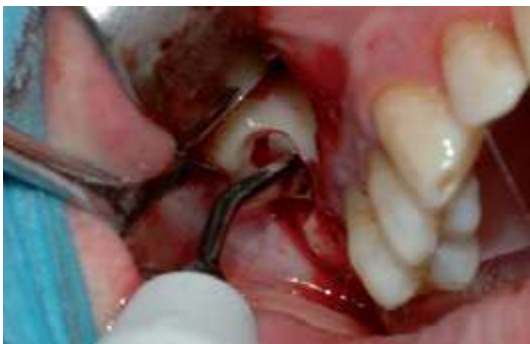**Fig. 12** - Finestra ultimata. Da notare l'importante spessore corticale



**Fig. 13** - Con apposito inserto si ultima il distacco della finestra



**Fig. 14** - Con apposito inserto si inizia lo scollamento della membrana sinusale



**Fig. 15** - Prosegue in sicurezza la delicata manovra

non taglienti, si può terminare la mobilizzazione della membrana (*figg. 13-15*).

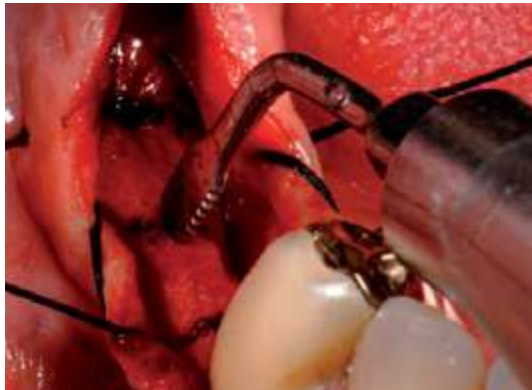Altri Autori ritengono invece che la percentuale di perforazioni della membrana di Schneider non presenti significative differenze con l'utilizzo della tecnica piezoelettrica in alternativa agli strumenti rotanti (12), ma bisogna considerare che la perforazione può intervenire anche in un secondo

momento, durante il ribaltamento della finestra ossea o lo scollamento della membrana stessa.

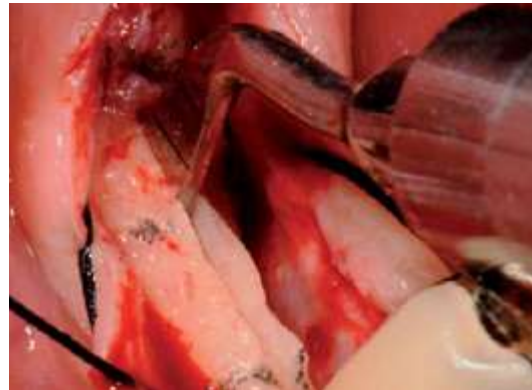Anche il rialzo del seno per via transcrestale può essere effettuato con tecnica piezoelettrica, utilizzando le punte per la preparazione del sito implantare: anche se gli studi sono ancora in fase preliminare, rispetto all'uso degli osteotomi, il rischio di perforazione è nettamente inferiore e il comfort per il paziente largamente superiore, eliminando inoltre la possibilità di labirintite che si manifesta in un certo numero di casi dopo l'uso di osteotomi e martello.

• **Espansione della cresta ossea:** come già detto, questa tecnica di chirurgia orale è stata, insieme alla precedente, quella che ha tratto maggior giovamento dalla diffusione dell'utilizzo delle apparecchiature piezoelettriche. In caso di creste estremamente sottili o affilate può essere utile iniziare l'intervento separando le due corticali, per il primo millimetro, con uno scalpello estremamente sottile o con una lama da bisturi tipo Beaver: questo facilita l'uso successivo di una punta tagliente

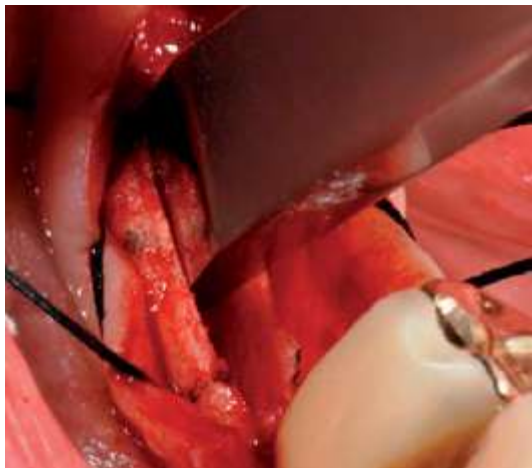




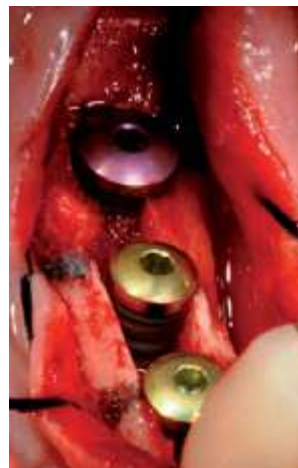**Fig. 16** - Separazione delle due corticali con inserto tagliente sui tre margini



**Fig. 17** - Approfondimento dell'osteotomia



**Fig. 18** - Divaricazione delicata tramite scalpello



**Fig. 19** - Inserimento degli impianti

che deve essere fatta penetrare al centro della cresta (*fig. 16*). Successivamente si può utilizzare un inserto non tagliente sui margini mesiale e distale, in modo da limitarsi ad approfondire il taglio, marcato con tacche millimetriche, che ci permettono di conoscere esattamente la profondità della nostra osteotomia (*fig. 17*). Lo scalpello verrà quindi introdotto delicatamente nel taglio, senza necessità di colpi di martello, in quanto non deve ulteriormente tagliare, ma solo divaricare le pareti ossee (*fig. 18*). Infine, con l'uso di osteotomi o frese o, meglio ancora, degli appositi inserti piezoelettrici, si rifinisce la sede implantare e si inseriscono gli impianti (*figg. 19*).

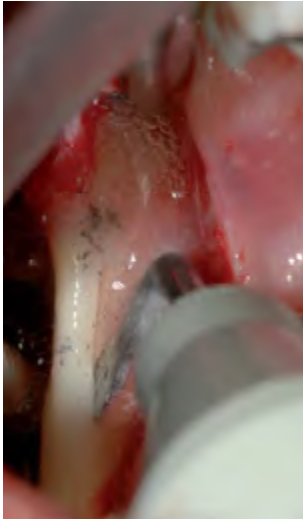• **Biopsie ossee:** per tutte le caratteristiche positive del taglio piezoelettrico menzionate nei para-

grafi precedenti, le biopsie ossee effettuate con questa tecnica permettono l'esame anche dei margini della lesione asportata, cosa indispensabile in caso di lesioni tumorali o comunque proliferative.

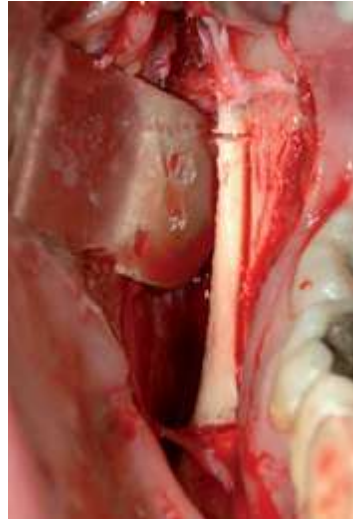
• **Prelievi ossei intraorali:** la progressiva diminuzione dell'utilizzo di membrane e materiali alloplastici, dopo le grandi speranze dei primi anni Novanta, unitamente alle sempre maggiori richieste di terapia implanto-protetica da parte dei pazienti, ha determinato una crescente necessità di innesti ossei al fine di ricostituire un'anatomia adeguata all'inserimento protesicamente guidato degli impianti. Questi, per poter dare un risultato esteticamente e funzionalmente adeguato e una certezza di risultati positivi a lungo termine, devono essere inseriti nella posizione e con un asse corret-



M. Pasi, et al.



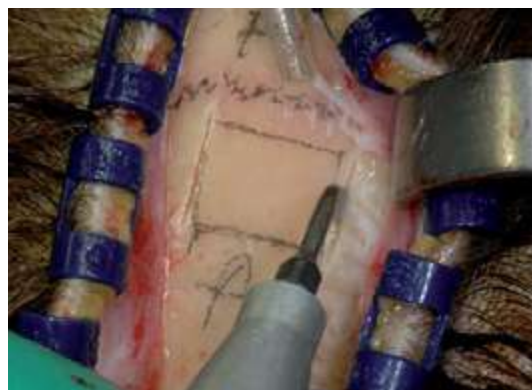**Fig. 20** - Prelievo dal ramo destro della mandibola



**Fig. 21** - Le osteotomie effettuate e il prelievo pronto per essere rimosso dal sito donatore



**Fig. 22** - L'inserto per il prelievo destro



**Fig. 23** - Prelievo dall'osso parietale destro (calvaria) effettuato con tecnica piezoelettrica

to e con un diametro adeguato all'elemento da sostituire. Tutto questo sarà dettato dal progetto della protesi che dovrà essere supportata.

Gli innesti di osso autologo prelevati da siti intraorali (preferibilmente ramo e corpo della mandibola) sono in grado di soddisfare gran parte delle esigenze ricostruttive. Sia in narcosi sia in anestesia locale, l'utilizzo della tecnica piezoelettrica ha permesso di effettuare lembi più piccoli, minori scollamenti dei tessuti molli, tagli più precisi con risparmio di tessuto osseo e migliori guarigioni (*figg. 20, 21*). Il taglio longitudinale, così come quelli mesiale e distale, vengono effettuati con un inserto tagliente utilizzato alla massima potenza e frequenza disponibili. Molto importante è il taglio inferiore che viene effettuato con appositi

inserti con la parte tagliente inclinata di 90° rispetto al manipolo (e quindi speculari per essere utilizzati a destra o a sinistra): questo taglio è molto difficile da effettuare con strumenti rotanti per la difficoltà di vedere e di tenere lontani i tessuti molli per non lederli gravemente (*fig. 22*). D'altra parte è molto importante discontinuare la corticale su tutti i quattro margini del prelievo, per evitare di fratturare il prelievo stesso o addirittura tutta la corticale fino al margine inferiore della mandibola (per insufficiente profondità del taglio inferiore). Grazie all'utilizzo del terminale piezoelettrico non si corre il rischio di ledere il nervo mandibolare, anche se a volte questo viene visualizzato dopo l'asportazione del prelievo. La guarigione del sito donatore e dell'innesto è

migliore e più rapida, in confronto a quella con strumenti rotanti (7).

- **Prelievi ossei extraorali:** nell'esperienza degli Autori, l'osso di origine membranosa (intraorale o da osso parietale ed occipitale) si è dimostrato il migliore per le ricostruzioni preimplantari dei mascellari (13).

Il terminale piezoelettrico si è dimostrato molto utile anche in questo caso (*fig. 23*). Effettuando il taglio della teca ossea con la tecnica piezoelettrica si ha la possibilità di accertare lo spessore della stessa senza alcun rischio di lesione della dura madre (14): l'esposizione della dura è un'evenienza che può occorrere con una certa frequenza, ma non è una complicanza se non si provocano lesioni della stessa.

- **Preparazione di siti implantari:** attualmente sono disponibili inserti per pochi tipi di impianti, di conseguenza la tecnica non può ancora avere una grande diffusione nemmeno tra gli utilizzatori della chirurgia piezoelettrica. Gli studi preliminari sono però molto incoraggianti, soprattutto per quanto riguarda la velocità di guarigione e di osteointegrazione degli impianti (15).

- **Altre applicazioni:** la chirurgia piezoelettrica viene usata anche per la rimozione dei mezzi da osteosintesi, ogni volta che sia necessario asportare l'osso che ha ricoperto placche o viti, limitando il più possibile la quantità di tessuto rimosso.

Allo stesso modo vengono utilizzati inserti diamantati molto sottili (simili a frese a fessura), per rimuovere impianti falliti, asportando pochissimo osso attorno all'impianto: in questo modo è spesso possibile reinserire un impianto anche immediato. Inoltre, analogamente a quanto avviene per i denti anchilosati, si evitano possibili danni alle strutture adiacenti.

Il terminale piezoelettrico viene utilizzato per l'osteotomia, necessaria per posizionare un distrattore verticale, con indubbi vantaggi in termini di sicurezza e rispetto del periostio del lato linguale.

Anche in chirurgia ortodontica la tecnica piezoelettrica è di ausilio, per esempio nella disgiunzione palatina o nel coadiuvare gli spostamenti dentali (16).

## Conclusioni

- La chirurgia orale, grazie all'introduzione e alla diffusione della tecnica piezoelettrica, ha compiuto un notevole passo in avanti, in termini di miglior qualità e rapidità di guarigione, ma anche di sicu-

rezza per operatore e paziente. Inoltre, durante gli interventi in anestesia locale, particolarmente in pazienti molto giovani oppure ansiosi, la tranquillità e il gradimento dimostrato dagli stessi, permettono di operare con maggiore attenzione rivolta all'intervento. Il postoperatorio, nei giorni immediatamente seguenti l'intervento, sia in anestesia locale sia in narcosi, si presenta generalmente più "confortevole" per il paziente, con edema più contenuto e minor dolenzia. La miglior qualità del taglio piezoelettrico, con più rapida guarigione delle osteotomie e dell'osteointegrazione, rendono migliore anche il postoperatorio a distanza di tempo.

L'accusa di eccessiva "lentezza" solitamente mossa alla tecnica piezoelettrica, è oggi caduta grazie alla potenza delle apparecchiature e alla varietà di inserti per ogni richiesta (5, 12): inoltre, la miglior visibilità dovuta al sito esangue, la maggiore collaborazione da parte del paziente, la sicurezza di non ledere tessuti delicati adiacenti, possono essere fattori che rendono l'intervento addirittura più rapido.

Riteniamo che oggi la tecnica chirurgica piezoelettrica debba affiancare e, dove ve ne siano le indicazioni, sostituire le tecniche tradizionali, in particolare ogni qual volta sia importante una maggiore qualità della guarigione ossea.

## Bibliografia

1. Horton JE, Tarpley TM, Wood LD. The healing of surgical defects in alveolar bone produced with ultrasonic instrumentation, chisel, and rotary bur. *Oral Surg Oral Med Oral Patol* 1975; 39: 536-46.
2. Horton JE, Tarpley TM, Jacoway JR. Clinical applications of ultrasonic instrumentation in the surgical removal of bone: *Oral Surg Oral Med Oral Patol* 1981; 51: 236-42.
3. Torrella F, Pitarch J, Cabanes G et al. Ultrasonic osteotomy for the surgical approach of the maxillary sinus: a technical note. *Int J Oral Maxillofac Impl* 1998; 13: 697-700.
4. Vercellotti T. Piezoelectric surgery in implantology: a case report. A new piezoelectric ridge expansion technique. *Int J Period Res Dent* 2000; 20(4): 359-65.
5. Stubinger S, Kutenberger J, Filippi A et al. Intraoral piezosurgery: preliminary results of a new technique. *J Oral Maxillofac Surg* 2005; 63(9): 1283-7.
6. Schlee M, Steigmann M, Bratu E et al. Piezosurgery: basics and possibilities. *Impl Dent* 2006; 15(4): 334-40.

M. Pasi, et al.

7. Sohn DS, Ahn MR, Lee WH et al. Piezoelectric osteotomy for intraoral harvesting of bone blocks. *Int J Period Res Dent* 2007; 27(2): 127-31.

8. Chiriac G, Hertzen M, Schwarz F et al. Autogenous bone chips: influence of a new piezoelectric device (Piezosurgery) on chip morphology, cell viability and differentiation. *J Clin Periodontol* 2005; 32(9): 994-9.

9. Vercellotti T, Nevins ML, Kim DM et al. Osseous response following resective therapy with piezosurgery. *Int J Period Res Dent* 2005; 25(6): 543-9.

10. Vercellotti T, De Paoli S, Nevins M. The piezoelectric bony window osteotomy and sinus membrane elevation: introduction of a new technique for simplification of the sinus augmentation procedure. *Int J Period Res Dent* 2001; 21(6): 561-7.

11. Wallace SS, Mazor Z, Forum SJ et al. Schneiderian membrane perforation rate during sinus elevation using piezosurgery: clinical results of 100 consecutive cases. *Int J Period Res Dent* 2007; 27(5): 413-9.

12. Barone A, Santini S, Marconcini S et al. Osteotomy and membrane elevation during the maxillary sinus augmentation procedure. A comparative study: piezoelectric device vs. conventional rotative instruments. *Clin Oral*

*Impl Res* 2008; 19(5): 511-5.

13. Vinci R. Bone grafts from calvaria. In: Bone augmentation in oral implantology, chap 7. Quintessence Publ 2007: 213-40.

14. Kotrikova B, Wirtz R, Krempien R et al. Piezosurgery: a new safe technique in cranial osteoplasty? *Int J Oral Maxillofac Surg* 2006; 35(5): 461-5.

15. Preti G, Martinasso G, Peirone B et al. Cytokines and growth factors involved in the osseointegration of oral titanium implants positioned using piezoelectric bone surgery versus a drill technique: a pilot study in minipigs. *J Periodontol* 2007; 78(4): 716-22.

16. Vercellotti T, Podestà A. Orthodontic microsurgery: a new surgically guided technique for dental movement. *Int J Period Res Dent* 2007; 27: 325-31.

Massimo Pasi

Unità Operativa di Odontoiatria

Istituto Scientifico San Raffaele di Milano

via Olgettina 48

20132 Milano

tel. 02 26432972

mpasi@massimopasi.it





## A Macro- and Nanostructure Evaluation of a Novel Dental Implant

Stefano Tetè, MD, DDS,\* Filiberto Mastrangelo, MD, DDS,† Tonino Traini, DDS,\* Raffaele Vinci, MD, DDS‡  
 Gilberto Sammartino, MD, DDS,\* Gaetano Marenzi, DDS,‡ and Enrico Gherlone, MD, DDS§

Success in implant dentistry lies in obtaining a good rate of integration between the implant and the host bone, that is a good osseointegration,<sup>1</sup> according to the principles introduced by Branemark *et al.*<sup>2-4</sup>

Great importance in getting success in implant dentistry comes from the implant shape and from the number, the step and the profile of the coils that cover the fixture.<sup>5,6</sup> Another critical factor for the achievement of osseointegration is the implant surface itself.<sup>7</sup> Though commercially pure (c.p.) titanium is universally considered the first-rate material for osseointegrated implant dentistry, its surface characteristics have been extensively investigated and many surface treatments proposed for dental implant applications.<sup>8</sup> The treated titanium implant surfaces achieve different purposes, such as to increase the contact area between the implant and the host bone and to improve the biological response of the osteogenic cells.<sup>3</sup> In fact, the implant surface that comes into direct contact with the host tissue and influences the cell and biochemical response<sup>9</sup> as well as the stability between the bone and the implant.<sup>10</sup> Many histomorphometric analysis report that a greater bone-to-implant contact (BIC) is obtained when rough surfaces are used.<sup>11,12</sup> Recent studies show that surface

Success in implant dentistry also comes from the implant macrodesign and nanostructure of its surface. Titanium implant surface treatments have been shown to enhance osseointegration, maximize bone healing, and bone-to-implant contact for predictable clinical results. The aim of the study, was to evaluate the geometric macrodesign and the surface nanostructure of a novel dental implant full contact covering (FCC) obtained by electrochemical procedures. FCC implants were analyzed by scanning electronic microscope, profilometer, and x-ray photoelectron spectroscopy and compared with commercial sandblasted and sandblasted, large-grit acid-etched dental implants. Sample analysis allowed to distinguish the different implant macrodesigns, the step and the profile of the coils that cover the fixture, and the surface characteristics. FCC implant showed novel macro-characteristic of crestal module,

coils, and apical zone compared with sandblasted and sandblasted and acid-etched dental implants. Moreover, the FCC nanostructure surface showed roughness values statistically higher than the 2 other surfaces, with a more homogeneity in a peaks and valleys arrangement. Finally, the x-ray photoelectron spectroscopy analysis detected differences between the examined surfaces, with the presence of several contaminants according to the different treatment procedures. Research on new macrostructures and nano morphology should result in a better qualitative and quantitative osseointegration response, with a predictability of the clinical results and long-term success of the implants. (*Implant Dent* 2008;17:309-320)

**Key Words:** dental implant, SEM, profilometric analysis, x-ray photoelectron spectroscopy, SLA implant, FCC implant

roughness may direct the process of osseointegration by influencing important cell mechanisms. In fact, the microrough design of the implant seems to favor the adhesion, the differentiation of the osteoblasts, and the production of a mineralized extracellular matrix, both *in vitro*<sup>13,14</sup> and *in vivo*.<sup>15</sup> Cells seem to be susceptible to surface micro-topography and are capable of using this morphology for orientating and migrating.<sup>16,17</sup> Actually, different production techniques produced a microrough topography to increase the BIC, that is the basic as-

pect to obtain osseointegration.<sup>12</sup> Moreover, titanium implants with a greater roughness are described as enhancing the BIC<sup>18,19</sup> and increasing removal torque forces.<sup>20,21</sup> Rough titanium implant surfaces can be obtained by means of addition, subtraction, or mixed technique. Microrough titanium surfaces have been produced using various procedures, including sandblasting, acid-etching or a combination of both (SLA—sandblasted, large-grit acid-etched), with different clinical results.<sup>22</sup> Sandblasting is a surface treatment that increases c.p. tita-

\*Associate Professor of Oral Surgery, Department of Oral Science, University "G. d'Annunzio," Chieti, Italy.  
 †Post Doctoral Fellow, Department of Oral Sciences, University "S. Raffaele" Ateneo Vita e Salute, Milano, Italy.  
 ‡Researcher, Department of Oral and Maxillofacial Science, University "Federico II," Napoli, Italy.  
 §Professor, Department of Oral Sciences, University "S. Raffaele" Ateneo Vita e Salute, Milano, Italy.

ISSN 1056-6163/08/01703-309  
 Implant Dentistry  
 Volume 17 • Number 3  
 Copyright © 2008 by Lippincott Williams & Wilkins  
 DOI: 10.1097/ID.0b013e3181829484



niun roughness and aims at improving the biomechanical features of the oral implants. Primary stability is also influenced by this treatment, as this rough surface was demonstrated to achieve macrophagic, epithelial, and osteoblast cell adhesion.<sup>1,23</sup> SLA dental implants, because of the presence of microroughness caused especially by acid-etching treatment, seem to favor the recovery and healing process of the bone, also thanks to the marked increase of osteogenic cytokine production such as  $E_2$  prostaglandin and the transformation and growth factor- $\beta 1$ . This cytokine is less sensitive to the rough surface than E prostaglandin.<sup>24,25</sup> Some researchers hold that treatment favors osseointegration, thanks to an increase in the initial cell anchorage of the osteoblasts.<sup>13</sup> In this study, a dental implant with a microporous surface, named full contact covering (FCC), obtained by an electrochemical technique is analyzed for its geometric macrostructure, surface topography, and chemical composition and compared with sandblasted and SLA implants.

#### MATERIALS AND METHODS

The dental implants used as experimental samples were provided by Win Six (BioSAF S.r.l., London, UK). In particular, implants belonged to 3 different groups, according to the respective surface treatment: sandblasted (Sab), Sand-blasted and large-grit acid etched (SLA), and full contact coverage (FCC). Sab implants had a cylindrical design, whereas the SLA implant examined had a conic design. FCC implant types showed a conic macrostructure, with coils becoming deeper from the cervical area to the apical zone, which gave the implant a cylindrical shape. Sandblasted implants were obtained by particles of  $TiO_2$  being applied to the surface (Bioactive Covering, Winsix Ltd., London, UK). The SLA implants underwent a preliminary sandblasting process and 2 phases of etching, the first with fluoridric acid, followed by a second acid attack by sulfuric-hydrochloric acid ( $H_2S-HCl$ ). The FCC implants were treated with a galvanostatic anodizing process in a phosphate-sulfate bath. After the treatment all implants were

washed and dried in a fan oven. When dry, the implants were decontaminated by plasma, packaged, and sterilized by ethylene oxide. The geometric macrodesign, the surface morphology and roughness, and the chemical composition of each type of implant were analyzed and compared.

#### Geometric Macrodesign, Surface Morphology, and Roughness Evaluation

The geometric macrodesign and the surface morphology of each implant were analyzed by scanning electronic microscope (SEM). The analyses were performed by a SEM LEO 420 (LEO Electron Microscopy Ltd., Cambridge, UK) on acid-etch and Ar decontaminated dishes. Electron acceleration potential was kept between 15 and 25 kV, the working distance was kept between 9 and 12 mm, according to the different requirements and nature of the samples. These different parameters are reported in the figures, with the magnification. 3D-SEM analysis allows to value roughness quantity, permitting to convert a conventional SEM image into a three-dimensional one. The SEM image magnification for this kind of analysis was 2000 $\times$ . The surface profilometric studies were performed using a commercial profilometer (Hommel T 20, Hommel GmbH, Villingen-Schwenningen, Germany), equipped with a diamond tip having a radius of 5  $\mu m$  and sensitive to vertical movements to an accuracy of  $\pm 0.01 \mu m$ . Profilometric scans were taken at 5 different positions on each surface, and the average of the absolute values of all points of the profile ( $R_a$ ), the root-mean-square of the values of all points ( $R_q$ ) and the average value of the absolute height of the 5 highest peaks, and the absolute depth of the 5 deepest valleys ( $R_v$ ) were automatically determined by means of the software Statistica 8 (StatSoft Italia S.r.l.). An analysis of variance was applied as well as the Turkey *post hoc* comparative test to the parameter  $R_a$  to study statistically the roughness differences between sample groups.

#### Chemical Surface Evaluation

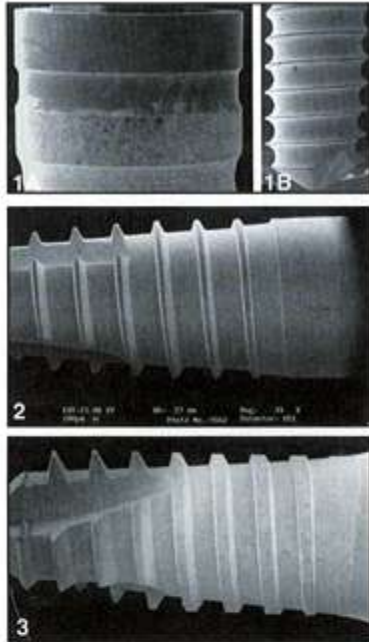
The chemical surface composition was evaluated by x-ray photoelectron spectroscopy (XPS) technique. XPS analysis was performed by a Perkin

Elmer PHI 5400 ESCA System. This instrument is equipped with an x-ray source with a Mg anode, kept to 20 kV with a 200 W power. The depth analyzed was about 5 nm; this can give direct information on the chemical composition of the most external layer of the implant surface, that is, the one facing the host bone tissue. The pressure inside the analysis room was about  $10^{-9}$  Torr. The analysis results were expressed in % atomic.

#### RESULTS

The analyses of the 3 dental implant design and surface topography showed the presence of significant macroscopic and microscopic differences. At low magnification, the macroscopic structure of each type of dental implant could be observed. As for the Sab cylindrical implants, the crestal module showed a geometric structure in which 3 different areas could be distinguished: from the top, an area (height 1.2 mm) with parallel walls and machined surface, a second zone (height 0.6 mm) with machined surface and reduced diameter, and a third area (height 1.2 mm) with parallel walls and rough surface (Fig. 1A). Along the fixture, the step of the coils remained unchanged; regular coils with squared form could be observed in the superior part, whereas V-shaped coils and little furrows of reflux were present at the apical zone (Fig. 1B). All the implant surface showed a uniform roughness. The conic implant design of the SLA group showed a crestal module with slightly divergent walls and machined surface. Such as, cylindrical Sab implant, SLA implant showed regular square coils in the superior part of the fixture, whereas V-shaped coils and high furrows of reflux could be observed at the apical zone. The reflux zone extension was equal to one third of the implant fixture (Fig. 2). In the FCC implant group, crestal module showed a geometric structure that could favor a wide connective seal distinguished into 2 different areas: a first zone (height 1.2 mm) with divergent walls and machined surface and a second zone (height 0.6 mm) with parallel walls and microrough surface. Also, FCC implants showed square coils at



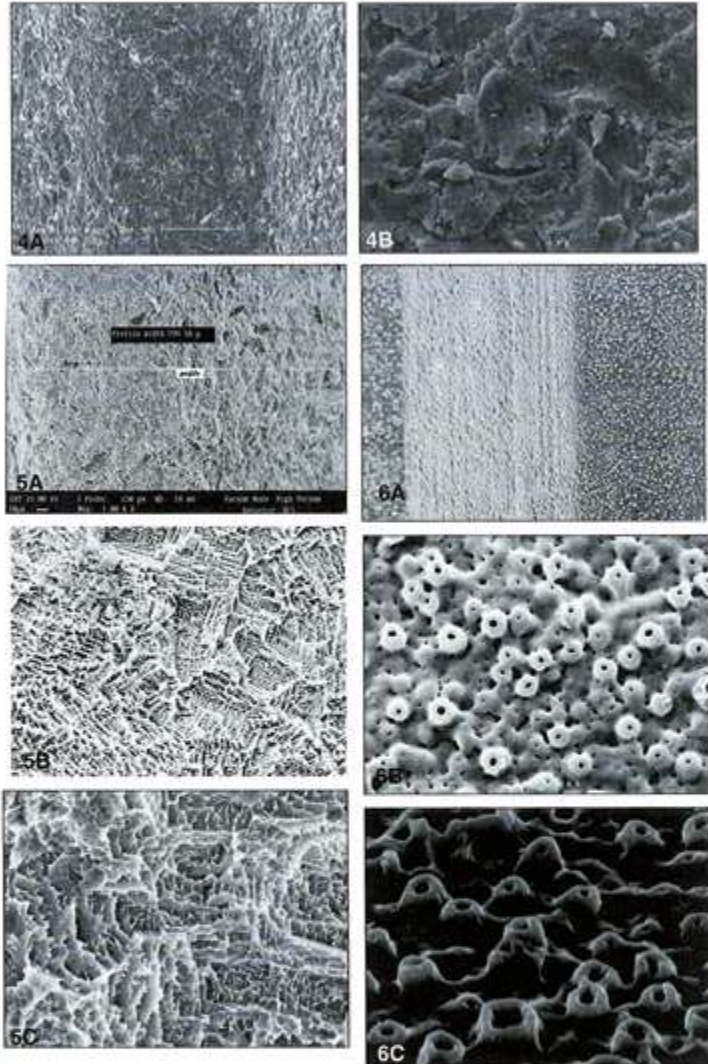


**Fig. 1.** A, Crestal module of a cylindrical sandblasted dental implant. Three different areas could be distinguished: from the top to the apex of the implant, a zone with parallel walls and machined surface, a second zone with machined surface and reduced diameter and a third area with parallel walls and rough surface (SEM). B, A SEM image representative of the body and the apical zone of a sandblasted dental implant.

**Fig. 2.** Geometric macrodesign of a conical SLA implant (SEM, magnification 39×). The crestal module shows slightly divergent walls and machined surface. Regular walls can be observed in the superior part of the fixture, whereas V-shaped ones are in the apical zone.

**Fig. 3.** Geometric macrodesign of a conical FCC implant (SEM, magnification 39×). The crestal module is made up of 2 different areas: a first zone with divergent walls and machined surface and a second zone with parallel walls.

the top of the implant and V-shaped coils gradually increased at the apical zone (Fig. 3). More implant surface differences, because of the applied surface treatment, could be observed at higher magnification. SEM analysis conducted on the Sab implant, permitted to highlight a well-defined geometry with typical macroroughness, due to the sandblasted treatment (300×) (Fig. 4A). At 5000× magnification, it was possible to notice an irregular distributed surface porosity, with deep



**Fig. 4.** Sandblasted surface at SEM. Deep valleys alternated to elevated sharp crests make up a surface with irregular distributed porosity. (A: 300× magnification; B: 5000× magnification).

**Fig. 5.** SEM analysis of the SLA (sandblasted, large grit acid-etched) surface; the sandblasted and acid-etched treatment leave a microrough surface morphology with cavities of prominent edges and a evenly distributed porosity. (A: 1000×; B: 5000×; C: 10,000×).

**Fig. 6.** SEM analysis of the FCC implant covering. FCC implant surface showed a more regular microrough morphology compared with Sab and SLA implant surfaces. Porosity with a typical morphology due to the electrochemical treatment can be detected (A: 1000×; B: 5000×; C: 12,000×).

valleys alternated to elevated sharp crests (Fig. 4B). At low magnification (1000×), the SLA conic implant samples showed a microrough surface morphology with cavities of prominent edges and a marked porosity evenly distributed, due to the action of the sandblasted and chemical acid-etched treatments (Fig. 5A). At higher

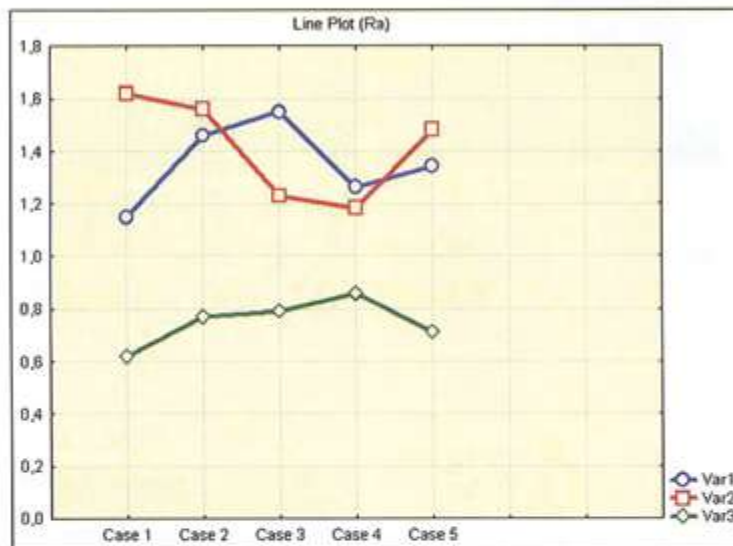
magnification, it was possible to notice a standard surface porosity with valleys alternating with regular and bevelled peaks (Fig. 5B, C). SEM analysis of FCC implant surface showed a more regular microrough morphology. At higher magnification (5000×), electrochemical treatment provided a typical morphology with



**Table 1.** Profilometric Scans Taken at 5 Different Positions on Each Surface, Mean and Standard Deviations of the Absolute Values of All Points of the Profile ( $R_a$ )

$R_a$	Sab	SLA	FCC
1	1.15	1.62	0.62
2	1.46	1.56	0.77
3	1.55	1.23	0.79
4	1.26	1.18	0.86
5	1.34	1.48	0.71
Mean	1.352	1.414	0.75
Standard deviation	0.1583351	0.1979394	0.0902774

The average roughness ( $R_a$ ) of the sandblasted titanium sample was equal to  $1.35 \pm 0.15 \mu\text{m}$ , similar to that reported for the SLA ( $1.41 \pm 0.19 \mu\text{m}$ ). FCC specimens showed a lower  $R_a$  value ( $0.75 \pm 0.09 \mu\text{m}$ ).



**Fig. 7.** Graphic representation of the profilometric data (reported in Table 1) on each surface of the absolute values of all point of the profile ( $R_a$ ). (Var1: Sab; Var2: SLA; Var3: FCC).

low valleys and crests similar to "volcanos" (Fig. 6). SEM profilometric evaluation and 3D-SEM reconstructions showed different surface morphologies and roughness statistical parameters. SLA and FCC implant batches had statistically significant rougher surfaces ( $P$  value: 0.0001) than the sandblasted one. Statistical SEM profilometric values showed the average roughness ( $R_a$ ) of the sandblasted titanium sample equal to  $1.35 \pm 0.15 \mu\text{m}$ , a value similar to that reported for the SLA ( $1.41 \pm 0.19 \mu\text{m}$ ). On the contrary, FCC specimens exhibited a lower  $R_a$  value ( $0.75 \pm 0.09 \mu\text{m}$ ) (Table 1; Fig. 7). The average value of the absolute heights of the 5 highest peaks and the depths of the 5 deepest valleys ( $R_z$ ) showed similar values for Sab sample ( $14.11 \pm 1.08$

$\mu\text{m}$ ) and SLA ( $12.87 \pm 1.39 \mu\text{m}$ ). Once again, the FCC titanium samples provided a significant lower  $R_z$  value ( $6.23 \pm 1.06 \mu\text{m}$ ), indicating a more regular surface (Table 2; Fig. 8). Root-mean-square ( $R_q$ ) confirmed the same range of roughness values for SLA ( $21.91 \pm 1.30 \mu\text{m}$ ) and FCC ( $25.37 \pm 0.94 \mu\text{m}$ ), according to the surface treatment processes. Moreover, the  $R_q$  value ( $51.66 \pm 1.89 \mu\text{m}$ ) of Sab implants presented a higher difference than the other groups (Table 3; Fig. 9). This value indicates a very irregular surface typical of sandblasted treatment. This feature suggests a large increase in surface area compared with the other specimens that had features in the scale of microns (Fig. 10A). The acid-etching treatment in the SLA implant samples increased microrough-

ness up to values over  $1 \mu\text{m}$  (Fig. 10B) with bevelled regular peaks and deep valleys (with high  $R_a$  and  $R_z$  values). The FCC implant group (Fig. 10C) had roughness values statistically higher than the other surfaces samples (Tukey comparative test,  $P$  value  $< 0.05$ ). FCC implant microroughness, because of the specific electrochemical treatment, resulted more homogeneous than the one recorded for the Sab and SLA implant groups (Table 4). The XPS analysis detected differences with presence of impurities on the sandblasted, SLA, and FCC implants which are mostly ascribed to the different surface treatments (Table 5). All specimens of Sab implant showed homogeneous value of C (carbon), O (oxygen) and Ti (titanium), higher value of N (azote) and Si (silicon) and lower value of Ca (calcium) and S (sulfur) on the surfaces. The XPS analysis described the presence of Al (aluminum) impurities residual of sandblasted treatment. SLA implant samples showed homogeneous value of C (carbon), O (oxygen), and Ti (titanium), higher value of S (sulfur), Ca (calcium), lower value of N (azote) compared with Sab specimens and absence of Al (aluminum) surface impurities. In FCC implant group, XPS analysis showed mean values of all elements and presence of P (phosphorous) on the surfaces.

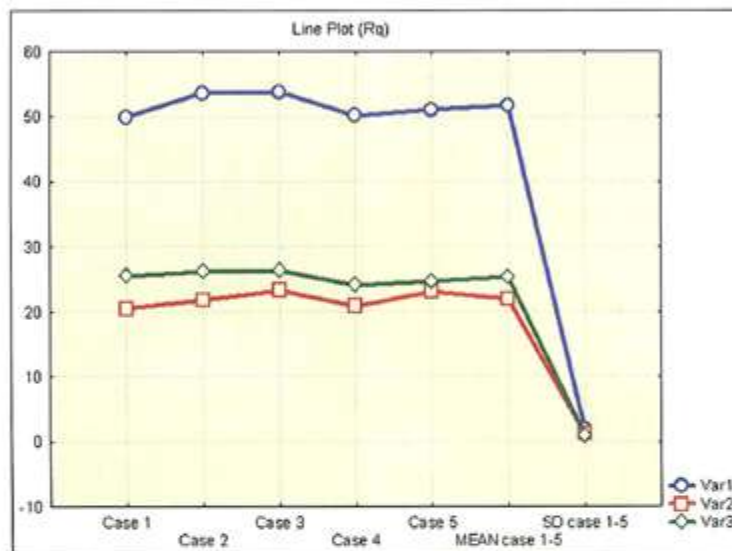
## DISCUSSION

Implant dentistry has become successful with the discovery of the biological properties of titanium. According to the literature, the macroscopic structure of a dental implant carries out a determining role in obtaining primary stability of the fixture and the gradual dissipating of the masticatory loading through the bone.<sup>26</sup> Great importance in obtaining success in implant dentistry comes from the implant shape and from the number, the step and the profile of the coils that cover the fixture.<sup>5,6</sup> The characterization of the 3 different dental implants, with both cylindrical and conic geometric macrodesign, demonstrated the good planning of the fixture in agreement with the various surgical techniques used and in perspective of the different quality of the receiving bone.

**Table 2.** Profilometric Scans Taken at 5 Different Positions on Each Surface, Mean and Standard Deviations of the Root-Mean-Square of the Values of All Points ( $R_q$ )

$R_q$	Sab	SLA	FCC
1	49.84	20.45	25.47
2	53.56	21.75	26.16
3	53.8	23.32	26.37
4	50.13	20.87	24.12
5	50.98	23.16	24.73
Mean	51.662	21.91	25.37
Standard deviation	1.8911161	1.3028239	0.9494999

Sab implants  $R_q$  value ( $51.66 \pm 1.89 \mu\text{m}$ ) presented a higher difference than the other groups, indicating a very irregular surface typical of sandblasted treatment.



**Fig. 8.** Graphic representation of the profilometric data (reports in Table 2) on each surface of the absolute values of the root-mean-square of the values of all point ( $R_q$ ). (Var1: Sab; Var2: SLA; Var3: FCC).

In particular, Sab cylindrical implants showed rounded and regular coils that may permit an equilibrate force dissipation if the implant is inserted in the posterior regions. Moreover, the geometric structure of the crestal module and the presence of 3 differently designed areas could favor a wide connective seal.<sup>27</sup> The SLA conic implant design, with regular square coils, may allow a good force dissipation in maxillary region where the bone quality is poor.<sup>28,29</sup> Furthermore, the crestal module is designed to grant a good primary stability during implant placement and its machined surface is compatible with cleaning procedures in the case of peri-implant bone resorption. According to literature, the square coils at the top of the FCC implant

grant a great mechanical strength dissipation<sup>30,31</sup> and V-shaped coils provide a good primary stability at the implant placement.<sup>32,33</sup> Many studies demonstrated that titanium rough surfaces may favor a more stable bone fixation and an increased percentage of BIC compared with machined c.p. titanium surface dental implants.<sup>34,35</sup> Recent clinical studies indicated that an implant with a textured surface may be loaded sooner than traditional healing protocols recommend.<sup>36,37</sup> Some studies showed that dental implants with a low roughness value, like those reported for the machined surface implant, may promote the formation of fibrous tissue around the implant, reduce the BIC and show a lower removal torque value than implants with

a rough surface.<sup>11,38</sup> However, mean roughness values of  $1 \mu\text{m}$  or above, like the values measured for different surface treatments, improve bone bonding to the dental implant.<sup>11,14</sup> The measured parameters were  $R_a$ , the arithmetic average of the absolute values of all points of the profile;  $R_q$ , the root-mean-square of the values of all points; and  $R_p$ , the average value of the absolute heights of the 5 highest peaks and the depths of the 5 deepest valleys. Profilometric and SEM analyses demonstrated that all the implants examined, although with different surface treatments, showed a surface texture with a very high value of roughness. The topographic maps showed qualitatively the difference in roughness between the 3 surfaces. The titanium electrolytically treated sample showed  $R_q$  equal to  $0.75 \mu\text{m}$ , a lower value than that measured for the other 2 surface conditions. The similar structure of microroughness between the sandblasted and acid-etching and the electrolytically coated specimens was also observed for the other 2 parameters ( $R_a$  and  $R_p$ ). Sandblasted specimens showed the highest values of  $R_a$  and  $R_p$ , indicating a very irregular surface, according to the specific surface treatment. The arithmetic average roughness ( $R_a$ ) for the FCC coated implant showed the same range of values in the scale of nanometers reported in the literature for the plasma-spraying process, according to Wong *et al.*<sup>39</sup> This feature suggests a large increase in the surface area compared with the other specimens. As already reported, the surface roughness could enhance the bone response around the implants, increase the BIC and even reduce the bone healing period, with the possibility of reducing the waiting time for loading and make implant treatment more predictable.<sup>34,37</sup> The role of implant surface contamination in the osseointegration process is not yet well understood, even if implant surface contaminants may be released from the surface and they may elicit an inflammatory response.<sup>40</sup> The XPS analysis suggested that all different manufacturing treatments allow to obtain from c.p. titanium, clean and sterilized dental implants with visualization and particle identification without contaminations.



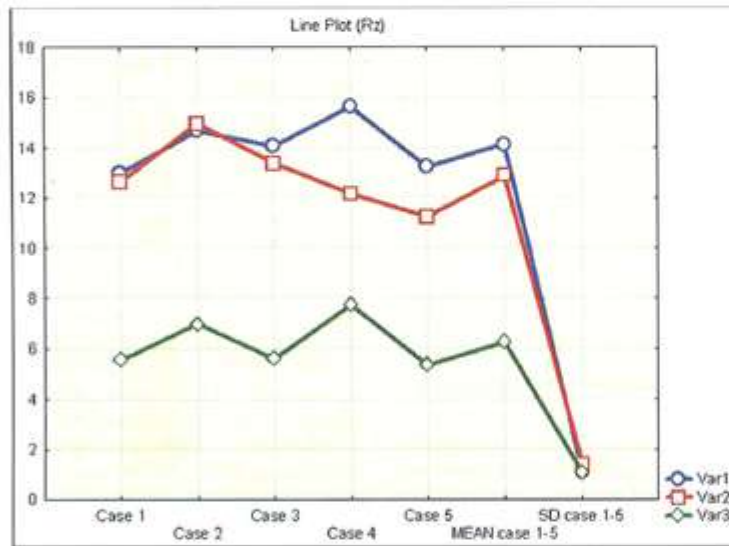
**Table 3.** Profilometric Scans Taken at 5 Different Positions on Each Surface. Mean and Standard Deviations of the Average Value of the Absolute Height of the 5 Highest Peaks and the Absolute Depth of the 5 Deepest Valleys ( $R_v$ )

	$R_p$	Sab	SLA	FCC
1		12.97	12.65	5.53
2		14.69	14.94	6.97
3		14.05	13.38	5.59
4		15.63	12.16	7.74
5		13.23	11.22	5.32
Mean		14.114	12.87	6.23
Standard deviation		1.086775	1.3982131	1.0671692

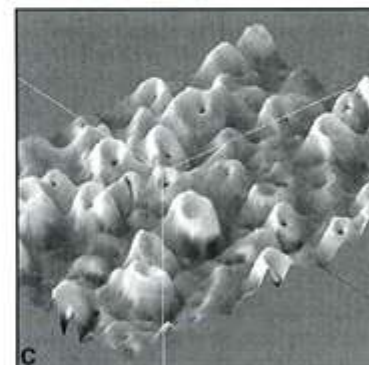
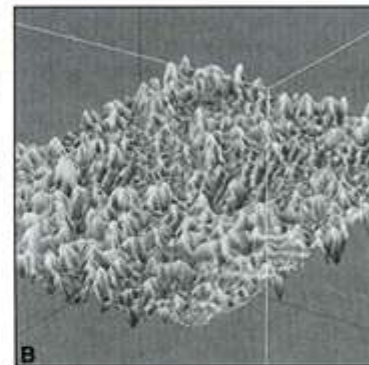
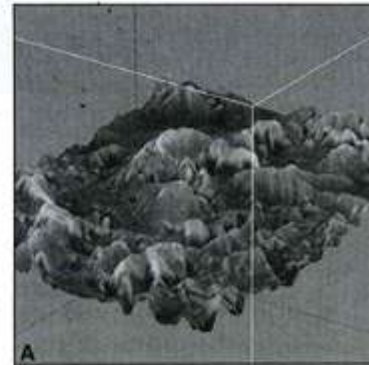
The average value of the absolute heights of the five highest peaks and the depths of the five deepest valleys ( $R_v$ ) showed similar values for Sab sample ( $14.11 \pm 1.06 \mu\text{m}$ ) and SLA ( $12.87 \pm 1.39 \mu\text{m}$ ). FCC titanium samples provided a more regular surface, with a significant lower  $R_v$  value ( $6.23 \pm 1.06 \mu\text{m}$ ).

**Table 4.** Mean Values of the Profilometric Analysis Lead on the 3 Different Implant Samples

Specimens	$R_p (\mu\text{m})$	$R_v (\mu\text{m})$	$R_q (\mu\text{m})$
Sab	$1.35 \pm 0.15$	$14.11 \pm 1.09$	$51.66 \pm 1.89$
SLA	$1.41 \pm 0.19$	$12.87 \pm 1.39$	$21.91 \pm 1.30$
FCC	$0.75 \pm 0.09$	$6.23 \pm 1.06$	$25.37 \pm 0.94$



**Fig. 9.** Graphic representation of the profilometric data (reported in Table 3) on each surface of the absolute height of the 5 highest peaks and the absolute depth of the 5 deepest valleys ( $R_v$ ). (Var1: Sab; Var2: SLA; Var3: FCC).



**Fig. 10.** StereoSEM 3D reconstruction of the 3 different implant surface. (A: Sab; B: SLA; C: FCC). FCC implant microroughness, due to the specific electrochemical treatment, resulted more homogeneous than the one recorded for the Sab and SLA implant groups.

Blasting the implant surface with particles other than the implant itself, such as  $\text{Al}_2\text{O}_3$ , may change the surface composition and the implant biocompatibility.<sup>12</sup> In sandblasted dental implants there could be a potential risk of the presence of remnants of blasting particles with dissolution of Al ions into the host tissue, which may interfere with the normal differentiation of osteoblasts and normal bone deposi-

tion and mineralization.<sup>41</sup> This risk seems to be reduced after the acid-etching treatment. Moreover, the presence of organic contamination, such as carbon, on every studied surface is unavoidable, as atmospheric hydrocarbons are readily adsorbed on exposed titanium surfaces. As already shown, the surface of titanium dental implants consists of a thin (2–6 nm) oxide (mainly  $\text{TiO}_2$ ) covered by a carbon-

dominated contamination layer and trace amounts of N, Ca, P, Cl, S, Na, and Si.<sup>42</sup> However, a high presence of carbon could signal the presence of a lubricant or other production contaminants. The presence of elements not related to the surface treatment, like sodium, chlorine, or silicon, is also an in-

**Table 5.** XPS Analysis Showed Differences With Presence of Impurities on the Sandblasted, SLA and FCC Implants, Ascribed to the Different Surface Treatments

Specimens	C	O	Ti	N	Si	Ca	S	P	Al
Sab	34.6	44.6	18.5	1.2	0.4	0.3	0.4	—	12.4
SLA	34.8	43.8	18.3	1.1	0.6	0.6	0.8	—	—
FCC	34.6	44.2	10.5	0.9	0.9	0.5	—	8.4	—

dication of the presence of remaining impurities after the cleaning process.

### CONCLUSIONS

In this study, FCC dental implants analyzed for both their macrostructure and microstructure, seem to have a design that could grant a good mechanical strength dissipation; in particular, the presence of V-shaped coils would provide a good primary stability at the implant placement. This might be also obtained by the wide surface area, because of the micro-roughness produced by the electrochemical treatment. Further *in vivo* studies are needed to assess if FCC dental implants may be successfully used in clinical practice, to obtain a more rapid and predictable osseointegration, and to reduce the healing period of the bone tissue around the fixture.

### Disclosure

The authors claim to have no financial interest, directly or indirectly, in any entity that is commercially related to the products mentioned in this article.

### REFERENCES

1. Brunette DM. The effects of implant surface topography on the behavior of cells. *Int J Oral Maxillofac Implants*. 1988; 3:231-246.
2. Branemark PI, Adell R, Breine U, et al. Intra-osseous anchorage of dental prostheses. I. *Exp Stud Scand J Plast Reconstr Surg*. 1969;3:81-100.
3. Branemark PI, Hansson BO, Adell R, et al. Osseointegrated implants in the treatment of the edentulous jaw. Experience from a 10-year period. *Scand J Plast Reconstr Surg Suppl*. 1977;16:1-132.
4. Branemark PI, Zarb GA, Albrektsson T, eds. *Tissue Integrated Prostheses: Osseointegration in Clinical Dentistry*.

Chicago: Quintessence Publ; 1985:87-102.

5. Siegle D, Soltesz U. Numerical investigations of the influence of implant shape on stress distribution in the jaw bone. *Int J Oral Maxillofac Implants*. 1989; 4:333-340.

6. Weindler M, Neugebauer J, Lekovic V, et al. Mechanical stability and histological analysis of immediate loaded implants with various surfaces and design [abstract]. *Clin Oral Implants Res*. 2003; 14:34.

7. Albrektsson T, Branemark PI, Hansson HA, et al. Osseointegrated titanium implants. Requirements for ensuring a long-lasting, direct bone-to-implant anchorage in man. *Acta Orthop Scand*. 1981;52:155-170.

8. Buser D. Titanium for dental applications (II): Implants with roughened surfaces. In: Brunette DM, Tengvall P, Textor M, Thomsen P, eds. *Titanium in Medicine*. Berlin: Springer; 2001:876-888.

9. Glantz PO. Biomaterial considerations for the optimized therapy for the edentulous predicament. *J Prosthet Dent*. 1998;79:90-92.

10. Wen X, Wang X, Zhang N. Micro-rough surface of metallic biomaterials: A literature review. *Biomed Mater Eng*. 1996; 6:173-189.

11. Buser D, Schenk R, Steinemann S, et al. Influence of surface characteristics on bone integration of titanium implants. A histomorphometric study in miniature pigs. *J Biomed Mater Res*. 1991;25:889-902.

12. Wennerberg A, Albrektsson T, Johansson C, et al. Experimental study of turned and grit-blasted screw-shaped implants with special emphasis on effects of blasting material and surface topography. *Biomaterials*. 1996;17:15-22.

13. Bowers K, Keller J, Randolph B, et al. Optimization of surface micromorphology for enhanced osteoblast responses *in vitro*. *Int J Oral Maxillofac Implants*. 1992; 7:302-310.

14. Martin J, Schwartz Z, Hemmert T, et al. Effect of titanium surface roughness on proliferation, differentiation, and protein synthesis of human osteoblast-like cells (MG63). *J Biomed Mater Res*. 1995;29: 389-401.

15. Cochran D, Schenk R, Lussi A, et al. Bone response to unloaded and loaded titanium implants with sandblasted and acid-etched surface: A histometric study in the canine mandible. *J Biomed Mater Res*. 1998;40:1-11.

16. Chehroudi B, Gould T, Brunette D. Effects of a grooved titanium-coated implant surface on epithelial cell behavior *in vitro*. *J Biomed Mater Res*. 1989;23:1067-1085.

17. Chehroudi B, Gould T, Brunette D. Titanium-coated micro machined grooves of different dimensions affect epithelial and connective-tissue cells differently *in vivo*. *J Biomed Mater Res*. 1990;24:1203-1219.

18. Goldberg VM, Jinno T. The bone-implant interface: A dynamic surface. *J Long Term Eff Med Implants*. 1999;9: 11-21.

19. Cooper LF. A role for surface topography in creating and maintaining bone at titanium endosseous implants. *J Prosthet Dent*. 2000;84:522-534.

20. Li D, Ferguson SJ, Beutler T, et al. Biomechanical comparison of the sandblasted and acid-etched and the machined and acid-etched titanium surface for dental implants. *J Biomed Mater Res*. 2002;60:325-332.

21. Klokkevold PR, Nishimura RD, Adachi M, et al. Osseointegration enhanced by chemical etching of the titanium surface: A torque removal study in the rabbit. *Clin Oral Implants Res*. 1997;8:442-447.

22. Wieland M, Sittig C, Brunette DM, et al. Measurement and evaluation of the chemical composition and topography of titanium implant surfaces. In: Davies JE, ed. *Bone Engineering*. Toronto: Em Squared; 2000:163-182.

23. Smith DC. Surface characterization of implants: Biological implications. In: Davies JE, ed. *Bone Biomaterial Interface*. Toronto: Toronto University Press; 1991: 9-17.

24. Cochran DL, Simpson J, Weber HP, et al. Attachment and growth of periodontal cells on smooth and rough titanium. *Int J Oral Maxillofac Implants*. 1994;9:289-297.



**1 Calvarial versus Iliac Crest for Autologous bone graft material for a Sinus lift procedure: A Histomorphometric Study**

R. Crespi, R. Vinci, P. Capparè, E. F. Gherlone, G. E. Romanos

JOMI The International Journal of Oral &amp; Maxillofacial Implants volume 22 - numero 4 - 2007

**2 A Randomized Prospective Multicenter Trial Evaluating the Platform-Switching Techique for Preventing Postrestorative Crestal Bone Loss**

L. Prosper, S. Redaelli, M. Pasi, F. Zarone, G. Radaelli, E. F. Gherlone - 2007

**3 CASO CLINICO:****Riabilitazione Implantoprotesica fissa su innesti prelevati da Calvaria**

R. Vinci, E. F. Gherlone, A. Lazetera

News Letter Biosaf - 2007

**4 CASO CLINICO: Rialzo di seno mascellare**

M. Pasi

News Letter Biosaf - 2007

**5 Le tecniche piezoelettriche, recentemente impiegate in chirurgia dei mascellari, consentono osteotomie precise e sicure nel rispetto delle strutture ossee**

R. Vinci

Dental Cube 2 - Marzo 2007

**6 Influenza del Desametasone nella germectomia piezoelettrica studio clinico controllato**

M. Del Brutto, C. Vianale, R. Mazzanti

Poster I° Expo di Autunno 1 Dicembre 2007

**7 Valutazione del comportamento di osteoblasti derivanti da cellule staminali di liquido amniotico su differenti superfici implantari**

A. Desiderio, A. D'Incecco, L. Stuppia, I. Antonucci, S. Tetè

atti I Expo di Autunno Università della Lombardia 1 Dicembre 2007

**8 Evaluation of surface nano-topographic effect on afscells growth**

A. Desiderio, F. Mastrangelo, T. Traini, L. Stuppia, G. Sammartino, S. Tetè)

atti dell'annual meeting del I.A.D.R. INTERNATIONAL ASSOCIATION OF DENTAL RESEARCH CONTINENTAL DIVISION THESSALONIKI 26-29 Settembre 2007

## Calvarial Versus Iliac Crest for Autologous Bone Graft Material for a Sinus Lift Procedure: A Histomorphometric Study

Roberto Crespi, MD, MS<sup>1</sup>/Raffaele Vinci, MD, DMD<sup>1</sup>/Paoli Capparè, MD<sup>1</sup>/  
Enrico Gherlone, MD, DDS, PhD<sup>2</sup>/George E. Romanos, DDS, DMD, PhD<sup>3</sup>

**Purpose:** The aim of this study was to compare, through histomorphometric analysis, the use of donor autogenous bone graft from calvarial or iliac sources for maxillary sinus lift procedures. **Materials and Methods:** Sixteen patients requiring maxillary sinus augmentation were included in this study. One group of 10 patients was alternatively selected to receive autologous calvarial bone particles, and another group of 6 patients received autologous iliac bone particles. Five months after surgery, bone biopsy specimens were obtained at the time of implant procedure and analyzed through histomorphometry. To compare mean values between the calvarial and iliac crest groups, the Student t test was performed. The level for statistical significance was set at  $P < .05$ . **Results:** All patients completed the healing period following sinus augmentation procedure without complications. In the calvarial group, an average total bone volume (BV) of  $73.4\% \pm 13.1\%$  was found. Nonvital bone constituted an average of  $5.5\% \pm 6.3\%$  of the total tissue volume. The percentage of vital bone (VB) showed an average of  $67.9\% \pm 16.1\%$ . In the iliac group, the average total bone volume was  $46.6\% \pm 17.4\%$ , with an average of  $12.6\% \pm 7.7\%$  of NVB and an average of  $34.0\% \pm 21.5\%$  of VB. A significant difference was observed between calvarial and iliac bone grafts with respect to BV, VB, and NVB ( $P < .05$ ). **Conclusion:** From this present histomorphologic study, it might be concluded that grafted bone obtained from calvarial sources for sinus lift procedure presented a significantly higher degree of bone volume and vital bone volume in contrast to bone harvested from the iliac crest. *INT J ORAL MAXILLOFAC IMPLANTS* 2007;22:527-532

**Key words:** autogenous bone, bone regeneration, maxillary sinus augmentation

Implant placement in the posterior maxilla is complicated by residual ridge resorption or sinus proximity.<sup>1</sup> The sinus augmentation technique was proposed<sup>2</sup> to restore vertical bone height, allowing the placement of implants. For this procedure, autologous bone is still considered the gold standard in sinus augmentation surgery,<sup>3</sup> since it improves the healing process by stimulating undifferentiated mesenchymal cells, osteoblasts, cytokines, and growth

factors<sup>4</sup> and promotes neoangiogenesis, a fundamental process for the revascularization<sup>5,6</sup> and remodeling<sup>7,8</sup> of the bone graft.

The iliac crest, which is endochondral, may be used as a donor site<sup>9-14</sup> when a large amount of autogenous cancellous bone is needed. Indeed, previous histomorphometric studies<sup>9</sup> of grafting with iliac crest bone have shown an increase in the median percentage of cancellous bone with a healing period of 4.5 months and little resorption of the graft. Other authors<sup>10</sup> evaluated the outcome of grafting with iliac bone clinically and radiologically; they found that iliac grafts could be used predictably in bone augmentation procedures, with a small amount of resorption. Barone et al<sup>11</sup> analyzed autologous iliac bone grafted in human maxillae with a histomorphometric study. After 5 months of healing, a total bone volume percentage of  $70\% \pm 19.9\%$  was found. Triplett and Schow<sup>12</sup> defined the iliac bone as the best autologous graft material for fast revascularization and integration.

<sup>1</sup>Department of Dentistry, Vita Salute University, San Raffaele Hospital, Milan, Italy.

<sup>2</sup>Full Professor and Chairman, Department of Dentistry, Vita Salute University, San Raffaele Hospital, Milan, Italy.

<sup>3</sup>Department of Periodontology and Implant Dentistry, New York University, College of Dentistry, New York, New York.

**Correspondence to:** Dr Roberto Crespi, Department of Dentistry, Vita Salute University, San Raffaele Hospital, Via Olgettina N.48, 20123 Milan, Italy. E-mail: robcrespi@libero.it

Crespi et al

Moreover, Iturrilaga and Ruiz<sup>15</sup> reported encouraging results with calvarial (membranous) bone grafts; they observed a high rate of bone remodeling, with no vital bone resorption and many large proliferative osteoblasts.<sup>16</sup> Lizuka et al<sup>17</sup> found that after a mean follow-up time of 19.6 months, bone resorption measured radiologically was minimal; endosseous dental implants were successfully placed and maintained, and satisfactory prosthetic rehabilitation was achieved in all patients. However, differences between iliac and calvarial bone when used as graft material were observed in animal studies. Kusiak et al<sup>18</sup> found faster revascularization for membranous bone, and Sullivan and Sz wajkun<sup>19</sup> observed enhanced revascularization by endochondral bone. Regarding volume maintenance, Ozaki and Buchman<sup>20</sup> demonstrated a good outcome with membranous bone grafts, probably because of their intrinsic microarchitecture rather than their embryologic origin.<sup>21</sup> The aim of this study was to compare histomorphometrically the use of autogenous bone graft from calvarial versus iliac bone for maxillary sinus augmentation procedures.

## MATERIALS AND METHODS

### Patient Selection

Between January 2004 and June 2005, patients with severe maxillary atrophy were treated with autogenous bone grafts harvested from extraoral sources at the Department of Dentistry, San Raffaele Scientific Institute, Milan, Italy.

Inclusion criteria were absence of systemic disease, aged between 35 and 70 years old, monolateral residual maxillary sinus floor of less than 2 mm (class V according to Cawood and Howell classification<sup>22</sup>), and partial or total edentulism. Exclusion criteria were presence of diabetes, presence of blood disorders, and smoking more than 10 cigarettes per day. A total of 16 patients met these criteria and thus were retrospectively studied.

Preoperative diagnosis was assessed through orthopantomography and CT scan.

All patients signed an informed consent form. Before positioning implants, after 5 months of healing, radiographic examinations (orthopantomography and computed tomography [CT]) were performed by a radiologist.

### Surgical Procedures

A single surgeon performed both graft harvesting and maxillary sinus augmentation with the patient under general anesthesia.<sup>23,24</sup> Vertical incisions were made in a palatal area of the alveolar crest anteriorly

and posteriorly. Mucoperiosteal flaps were elevated, and a bony window was created on the lateral wall of the maxillary sinus using a round diamond bur under irrigation with sterile saline solution. The Schneiderian membrane was carefully elevated, and the bony wall was gently pushed inside the sinus cavity, creating a cavity for bone augmentation. Donor bone was obtained from the anterior iliac crest and the parietal bone according to Tessier technique.<sup>25</sup>

One group of 10 patients alternately selected received autologous calvarial bone particles, and another group of 6 patients received autologous iliac bone particles. Larger particles of bone were reduced to fine chips by a bone grinder. A resorbable Bio-Gide membrane (Geistlich Biomaterials, Wolhusen, Switzerland) was used to cover the bony sinus windows; no fixation was used. The mucoperiosteal flap was sutured using nonresorbable 5.0 sutures (GTAM; W.L. Gore & Associates, Flagstaff, AZ). In the postsurgical procedures, patients received antibiotics (Augmentin, 500 mg 4 times daily; Beechman-Wulfing, Neuss, Germany). Sutures were removed after 1 week.

Five months after surgery, all patients received at least 2 implants on the grafted side of the maxilla. A full-thickness flap was raised, the bone was inspected, and samples for biopsy were obtained from the occlusal aspect of the alveolar ridge using a trephine drill under copious irrigation with sterile saline solution. One cylindrical biopsy specimen was taken from each patient, for a total of 16 biopsies. All the biopsy specimens were approximately 2 mm in diameter and 10 mm in length, and were marked on the occlusal sides for the orientation during the histologic process.

Titanium implants of 3.7 to 5 mm in diameter and 10 to 13 mm long (WINSIX; BioSAF, Milan, Italy) were placed at the same sites from which the biopsy specimens were obtained. A total of 45 implants were placed in posterior maxillary sites.

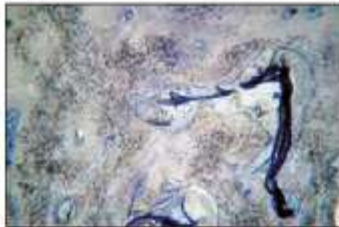
### Histomorphometry

The samples were fixed in 4% buffered formaldehyde, then dehydrated in graded series of alcohols from 50% to 100% and embedded in Epon (Hexion, Columbus, OH) according to a previously described procedure.<sup>26</sup>

Undecalcified, 30 ± 10 mm thick sections along the axis of the biopsy were obtained with Isomet Buehler microtome (Buehler, Lake Bluff, IL); the sections were stained with toluidine blue and observed with a microscope by Normasky differential interference contrast (DIC) (Fomi III; Carl Zeiss, Oberkochen, Germany).

A FOMI III microscope (Zeiss) connected to a computer and a Leica DC 280 digital camera (Leica

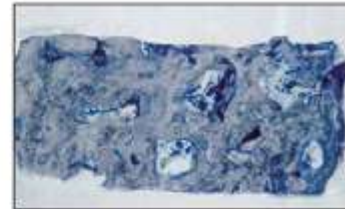




**Fig 1** Lines of osteoblasts and osteocytes around nonvital empty osteocyte lacunae in iliac autologous bone (toluidine blue; original magnification  $\times 32$ ).

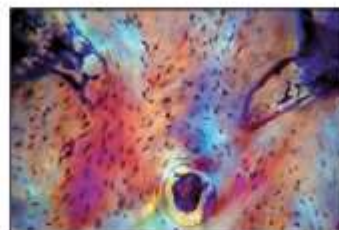

**Fig 2** Nonvital empty osteocyte lacunae delimited by osteoblasts and osteocytes in iliac crest autologous bone (DIC; original magnification  $\times 250$ ).



**Fig 3** Histologic section of grafted calvarial bone. A high density of vital lamellar bone and reduced medullary space can be observed (original magnification  $\times 10$ ).

**Fig 4 (left)** Histologic section of grafted calvarial bone. Vital bone containing osteoblasts, osteocytes, and many blood vessels (DIC; original magnification  $\times 160$ ).



**Fig 5 (right)** Histologic section from grafted calvarial bone. Vital mature lamellar bone with the presence of osteons (DIC; original magnification  $\times 160$ ).



Microsystem, Milan, Italy) were used for histomorphometric measurements. Histomorphometry was performed with Alexasoft software (Microcontrol, Milano, Italy). The percentage of mineralized tissue was calculated for all sections of the samples, and the measurements were performed at  $160\times$ .

Vital bone (VB) was calculated as the percentage of the total tissue volume (TTV) that consisted of mineralized and vascularized bone tissue. Mineralized bone tissue that contained empty osteocyte lacunae was defined as nonvital bone (NVB) and was expressed as a percentage of the TTV. The total amount of vital and nonvital bone was considered the total bone volume (TBV).

Comparison between the calvarial and the iliac group was performed with an independent Student *t* test ( $\alpha = .05$  or  $P < .05$  was considered the threshold for statistical significance). The Bonferroni correction was used for multiple comparisons.

## RESULTS

Sixteen systemically healthy patients (9 men and 7 women) were included in this study. The mean age was  $51.4 \pm 9.2$  years (range, 38 to 65 years). Three patients were totally edentulous, and the remaining 13 patients were partially edentulous in the posterior maxilla. In all patients, preoperative diagnosis was assessed through orthopantomography and CT scan.

All patients completed the healing period following the sinus augmentation procedure without com-

plications, and no clinical symptoms of maxillary sinusitis or other complications occurred.

Two of the 6 patients in whom iliac crest bone was used reported pain around the donor site 10 days after bone harvesting; there was no donor site morbidity in the calvarial group.

Before positioning implants, after 5 months of healing, radiographic examination (orthopantomography and CT) showed good integration of the bone graft in all patients. All implants placed became osseointegrated.

Histologic evaluation of all examined sections from iliac bone grafted revealed the presence of lamellar VB and some areas of woven bone surrounding NVB tissue, which consisted of fields of empty osteocyte lacunae, observed as incremental basophilic lines mixed with interposed reversion lines (Figs 1 and 2). In the specimens where calvarial bone grafts were used, the bone grafts appeared well-included and showed continuity with the new bone tissue in comparison to the specimens grafted with crestal bone (Fig 3). Moreover, well-developed Haversian and Volkmann canal systems confirmed the maturity of the bone. Osteons containing osteocytes and osteoblasts were observed (Figs 4 and 5).

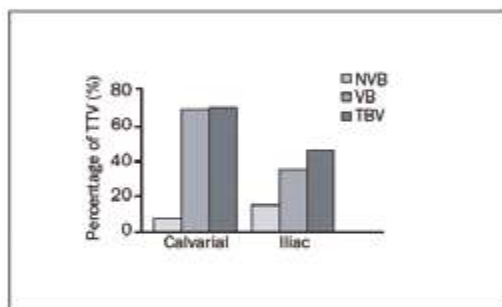
Osteoid formation was particularly prominent in highly vascularized tissue. All the tissues were free of inflammatory cells. The medullary spaces were almost always filled with well-vascularized connective tissue with no signs of inflammation.

Crespi et al

**Table 1** Histomorphometric Results

Patient	Age	Sex	Donor site	TBV (%)	VB (%)	NVB (%)
1	54	M	CAL	95.0	95.0	0.0
2	43	M	CAL	75.9	67.7	8.2
3	47	F	CAL	95.0	95.0	0.0
4	62	M	CAL	66.7	66.7	0.0
5	51	F	CAL	82.3	77.1	5.2
6	38	F	CAL	59.1	59.1	0.0
7	59	F	CAL	58.8	53.0	5.8
8	40	M	CAL	73.9	68.1	5.8
9	44	F	CAL	59.2	51.8	7.4
10	49	M	CAL	67.6	45.8	21.8
11	57	M	IL	30.4	21.5	8.9
12	39	F	IL	58.2	57.6	0.6
13	55	M	IL	32.5	6.6	25.9
14	65	F	IL	27.0	11.5	15.5
15	61	M	IL	58.2	48.1	10.1
16	58	M	IL	73.2	58.8	14.4

CAL= calvarial bone; IL= iliac bone.

**Fig 6** Histomorphometric results: calvarial versus iliac autologous bone.**Calvarial Group**

TBV ranged from 66.7% to 95%, with an overall average of  $73.4\% \pm 13.1\%$ . The percentage of NVB varied from 0% to 21.8%, with an overall average of  $5.5\% \pm 6.3\%$  of total tissue volume. The percentage of VB varied from 45.8% to 95%, with an average volume of  $67.9\% \pm 16.1\%$  (Table 1, Fig 6).

**Iliac Group**

The TBV ranged from 27% to 73.2%, with an overall average of  $46.6\% \pm 17.4\%$ . The percentage of NVB varied from 0.6% to 25.9%, with an overall average of  $12.6\% \pm 7.7\%$  of TTV. The percentage of VB varied from 11.5% to 58.8%, with an average VB volume of  $34.0\% \pm 21.5\%$  (Table 1, Fig 6).

Statistically significant differences ( $P < .05$ ) between calvarial and iliac bone grafts were found with respect to average TBV, VB, and NVB.

**DISCUSSION**

Ozaki and Buchman<sup>20</sup> observed the internal processes of bone graft remodeling. Cortical membranous and endochondral bone grafts were placed subperiosteally onto rabbit crania, and micro-CT scanning and histomorphometric analysis were performed to obtain detailed information regarding the microarchitecture of the cortical bone grafts. The results showed that there was no difference between the endochondral and membranous bone grafts for bone volume fraction; however, onlay cortical bone grafts developed a less dense, more trabecular, less organized internal superstructure. Furthermore, Peer<sup>27</sup> demonstrated clinically that membranous onlay bone grafts tended to resorb less over time than endochondral onlay bone grafts.

At histologic analysis the changes in the internal morphology of these bone grafts provided a structural framework consistent with the processes of osteoclastic resorption, bony remodeling, and new bone formation. Different authors<sup>20,21</sup> have suggested that the embryologic origin of a bone graft is irrelevant (ie, that cortical bone behaves like cortical bone, regardless of the source). The clinical superiority of membranous bone grafts can be explained by the fact that membranous and endochondral bone grafts are composite grafts made up of both cortical and cancellous components. Onlay membranous bone grafts, therefore, resorb less over time because they have a higher proportion of cortical bone than endochondral bone grafts and not because of some innate embryologic superiority.

Le Lorc'h-Bukiet et al<sup>16</sup> studied the structure and remodeling activities of parietal bone used for sinus grafting 10 months after grafting. The samples consisted solely of trabecular bone, which consisted of  $49.4\% \pm 18.4\%$  of total sample volume. Remnants of the graft particles were embedded within new bone and showed signs of intense resorption. Bone remodeling was highly active, as shown by the presence of numerous osteoclasts resorbing new bone, together with thick osteoid seams and large osteoblasts within mineralized material. This study offered insight into cortical and trabecular bone structure and showed the low-level remodeling activity of parietal bone. The solid structure of cortical bone may be one of the main reasons that cortical onlay bone grafts resorb more slowly and survive better over time compared with cancellous onlay



bone grafts. The trabeculation of the cortical only grafts may be an attempt by the body to incorporate the graft with simultaneous volume reduction through osteoclastic activity,<sup>20</sup> supported by improved revascularization. Chen et al<sup>5</sup> showed that cancellous bone revascularized faster than cortical bone regardless of its embryologic origin, with no difference in revascularization rate between cortical bone of different embryologic origins, supporting the concept that the trabeculation of cortical only bone grafts occurs concurrently and may even drive the process of revascularization. However, other studies<sup>28,29</sup> have shown that embryologic origin may play a key role in intramembranous and endochondral bone healing. In fact, in a study of mandibular bone grafting, Rabie et al<sup>30</sup> demonstrated that intramembranous bone requires different cytokines and growth factors for healing than endochondral bone. Subsequently, Chung et al<sup>31</sup> found that differences in molecular signaling pathways exist between intramembranous and endochondral osteogenesis. Wong and Rabie<sup>32</sup> demonstrated that endochondral and intramembranous bone do not undergo the same healing mechanism: demineralized intramembranous bone matrix induces bone without an intermediate cartilage stage and proceeds directly through an intramembranous ossification; the mesenchymal stem cells differentiate directly to bone cells. In a study of the rat mandible, Lu and Rabie<sup>33</sup> attributed the difference in calvarial and endochondral bone graft healing to the different origins of the bone grafts and the recipient bed.

## CONCLUSION

This histomorphologic study revealed that trabecular calvarial bone grafts used for sinus augmentation provided a significantly higher degree of bone volume and vital bone than iliac crest bone grafts. However, more studies are necessary to assess the relevance of trabecular bone arrangement to the bone healing process.

## REFERENCES

- Misch CE, Dietsch F. Autogenous bone grafts for endosteal implants—Indications and failures. *Int J Oral Implantol* 1991;8:13–20.
- Boyne PJ, James RA. Grafting of the maxillary sinus floor with autogenous marrow and bone. *J Oral Surg* 1980;38:613–616.
- Jensen OT, Shulman LB, Block MS, Iacono VJ. Report of the Sinus Consensus Conference of 1996. *Int J Oral Maxillofac Implants* 1998;13(suppl):11–45.
- Carano RAD, Filvaroff EH. Angiogenesis and bone repair. *Drug Discov Today* 2003;8:980–989.
- Chen NT, Glowacki J, Bucky LP, Hong HZ, Kim WK, Yaremchuk MJ. The roles of revascularization and resorption on endurance of craniofacial onlay bone grafts in the rabbit. *Plast Reconstr Surg* 1994;93:714.
- Cho BC, Chung HY, Shin DP, Park JW, Baik BS. Early revascularization of membranous inlay bone graft in canine mandible model. *J Craniofac Surg* 2002;13:251–257.
- Zerbo IR, deLange G, Joldersma M, Bronckers ALJJ, Burger EH. Fate of monocortical bone blocks grafted in the human maxilla: A histological and histomorphometric study. *Clin Oral Implants Res* 2003;14:759–766.
- Street J, Bao M, deGuzman L, et al. Vascular endothelial growth factor stimulates bone repair by promoting angiogenesis and bone turnover. *Proc Natl Acad Sci USA* 2002;99:9656–9661.
- Schultze-Mosgau S, Keweloh M, Wittfang J, Kessler P, Neukam FW. Histomorphometric and densitometric changes in bone volume and structure after avascular bone grafting in the extremely atrophic maxilla. *Brit J Oral Maxillofac Surg* 2001;39:439–447.
- Verhoeven JW, Cune MS, Terlouw M, Zoon MA, de Putter C. The combined use of endosteal implants and iliac crest onlay grafts in the severely atrophic mandible: A longitudinal study. *Int J Oral Maxillofac Implants* 1997;26:351–357.
- Barone A, Crespi R, Nicoli Aldini N, Fini M, Giordano R, Covani U. Maxillary sinus augmentation: Histologic and histomorphometric study. *Int J Oral Maxillofac Implants* 2005;20:519–525.
- Triplet RG, Schow SR. Autologous bone grafts and endosseous implants: Complementary techniques. *J Oral Maxillofac Surg* 1996;54:486–494.
- Acocella A, Nardi P, Tedesco A, Beninati F, Giannini D. Anterior iliac bone grafts: Techniques and sequelae. Report on 107 cases and review of the literature. *Minerva Stomatol* 2003;52:441–453.
- Triplet RG, Schow SR, Laskin DM. Oral and maxillofacial surgery advances in implant dentistry. *Int J Oral Maxillofac Implants* 2000;15:47–55.
- Iturriaga MTM, Ruiz CCC. Maxillary sinus reconstruction with calvarium bone grafts and endosseous implant. *J Oral Maxillofac Surg* 2004;62:344–347.
- Le Lorc'h-Bukiet I, Tulasne JF, Llorens A, Lesclous P. Parietal bone as graft material for maxillary sinus floor elevation: Structure and remodeling of the donor and of recipient sites. *Clin Oral Implants Res* 2005;16:244–249.
- Lizuka T, Smolka W, Hallermann W, Merickske-Stern R. Extensive augmentation of the alveolar ridge using autogenous calvarial split bone grafts for dental rehabilitation. *Clin Oral Implants Res* 2004;15:607–615.
- Kusiak JF, Zins JE, Whitaker LA. The early revascularization of membranous bone. *Plast Reconstr Surg* 1985;76:510–514.
- Sullivan WG, Szwajkun PR. Revascularization of cranial versus iliac crest bone grafts in the rat. *Plast Reconstr Surg* 1991;87:1105–1109.
- Ozaki W, Buchman SR. Volume maintenance of onlay bone grafts in the craniofacial skeleton: Micro-architecture versus embryologic origin. *Plast Reconstr Surg* 1998;102:291–299.
- Sullivan WG, Szwajkun P. Membranous vs endochondral bone. *Plast Reconstr Surg* 1991;87:1145.
- Cawood JJ, Howell A. Reconstructive preprosthesis surgery. I. Anatomical considerations. *J Oral Maxillofac Surg* 1991;20:75–82.
- Tatum H. Maxillary and sinus implant reconstruction. *Dent Clin North Am* 1986;30:207–229.

## Crespi et al

24. Misch CE. Maxillary sinus augmentation for endosteal implants: Organized alternative treatment plans. *Int J Oral Implantol* 1987;4:49-58.
25. Tessier P. Autogenous bone grafts taken from the calvarium for facial and cranial applications. *Clin Plast Surg* 1982;9:531-538.
26. Crespi R, Grossi SG. A method for histological examination of undecalcified teeth. *Biotechnic Histochem* 1992;67:202-206.
27. Peer LA. The fate of autogenous human bone grafts. *Br J Plast Surg* 1951;3:233-243.
28. Pinholt EM, Solheim E, Talsnes O, Larsen TB, Bang G, Kirkeby OJ. Revascularization of calvarial, mandibular, tibial, and iliac bone grafts in rats. *Ann Plast Surg* 1994;33:193-197.
29. Manson PN. Facial bone healing and bone grafts: A review of clinical psychology. *Clin Plast Surg* 1994;21:331-348.
30. Rabie ABM, Dan Z, Samman N. Ultrastructural identification of cells involved in the healing of intramembranous and endochondral bones. *Int J Oral Maxillofac Surg* 1996;25:383-388.
31. Chung U, Kawaguchi H, Takato T, Nakamura K. Distinct osteogenic mechanism of bones of distinct origins. *J Orthop Sci* 2004;9:410-414.
32. Wong RWK, Rabie ABM. A quantitative assessment of the healing of intramembranous and endochondral autogenous bone grafts. *Eur J Orthod* 1999;21:119-126.
33. Lu M, Rabie ABM. Quantitative assessment of early healing of intramembranous and endochondral autogenous bone grafts using micro-computed tomography and Q-win image analyzer. *Int J Oral Maxillofac Surg* 2004;33:369-376.

## CASO CLINICO: riabilitazione implantoprotetica fissa su innesti prelevati da calvaria

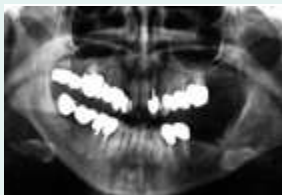

Fig. 1 • Panoramica preoperatoria

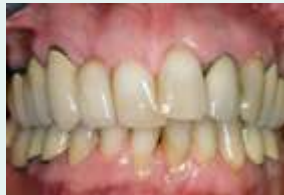

Fig. 2 • Visione clinica preoperatoria



Fig. 3 • Prelievo del primo innesto da osso parietale

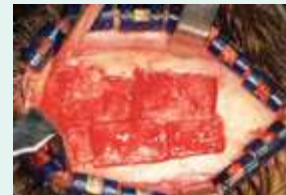


Fig. 4 • Visione dell'area donatrice a prelievo ultimato



Fig. 5 • Innesto posizionato nel seno mascellare destro

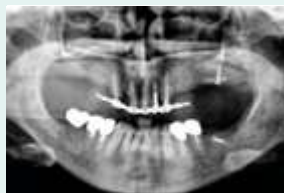

Fig. 6 • Panoramica postoperatoria a 4 mesi di guarigione. Si noti la radiopacità degli innesti posizionati a destra nel seno mascellare e a sinistra ad onlay occlusale

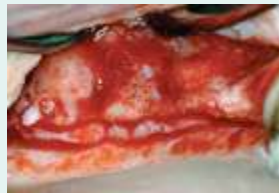

Fig. 7 • Guarigione clinica del grande rialzo di seno destro a 5 mesi di guarigione

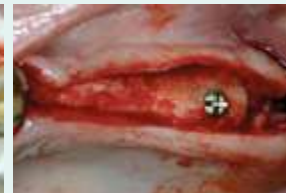

Fig. 8 • Guarigione clinica dell'innesto occlusale a 5 mesi di guarigione

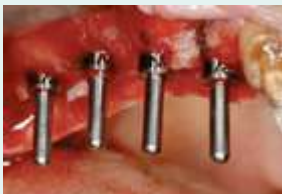

Fig. 9 • Pin di posizione inseriti nelle sedi implantari del mascellare destro con l'ausilio di dima chirurgica

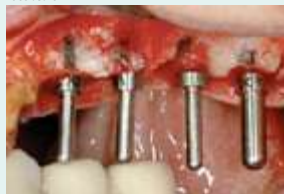

Fig. 10 • Pin di posizione inseriti nelle sedi implantari del mascellare sinistro con l'ausilio di dima chirurgica

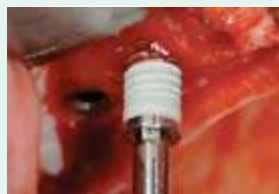

Fig. 11 • Particolare della fase di inserimento degli impianti Winsix

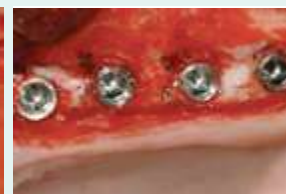

Fig. 12 • Visione occlusale degli impianti inseriti nel mascellare sinistro

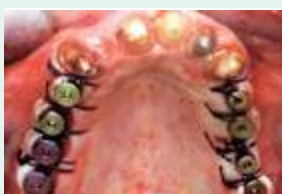

Fig. 13 • Visione occlusale della sutura e delle viti di guarigione

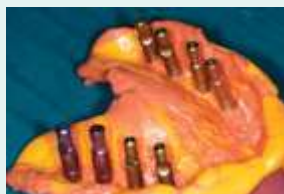

Fig. 14 • Impronta presa con tecnica pick-up con analoghi connessi ai transfer



Fig. 15 • Modello di lavoro con monconi personalizzati

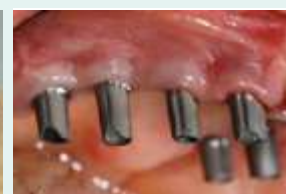

Fig. 16 • Monconi ottimizzati connessi nel cavo orale

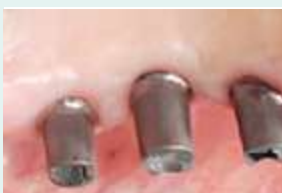

Fig. 17 • Particolare dei monconi ottimizzati in zona 10; si noti lo stato di salute dei tessuti perimplantari

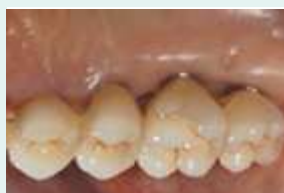

Fig. 18 • Visione interna della protesi fissa definitiva in zona 10

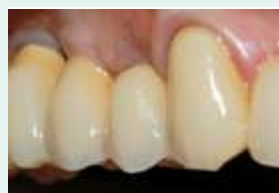

Fig. 19 • Visione frontale protesi definitiva destra

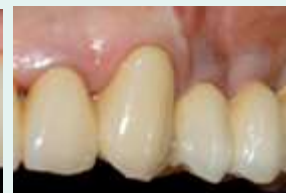

Fig. 20 • Visione frontale protesi definitiva sinistra

Si ringrazia per la gentile concessione il Prof. Enrico Gherlone



clinica

BioSAFin

## CASO CLINICO: rialzo di seno mascellare

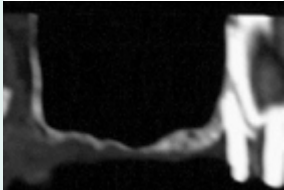


Fig. 1 • TAC preoperatoria. Si noti la grave atrofia ossea del settore posteriore mascellare destro

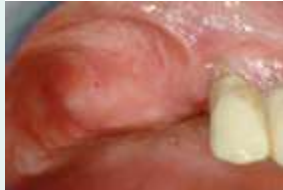

Fig. 2 • Visione oclusale della sella edentula

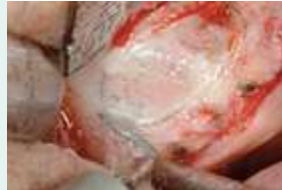

Fig. 3 • Incisione della botola con inserto a seghetto del manipolo piezoelettrico lungo i contorni disegnati con la matita demografica

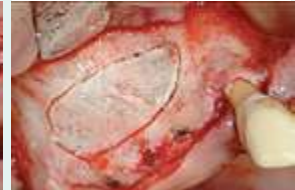

Fig. 4 • Incisione terminata lungo tutto il perimetro della botola

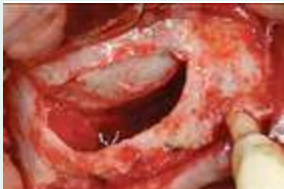

Fig. 5 • Sollevamento della botola a nuovo tetto del seno mascellare innalzato

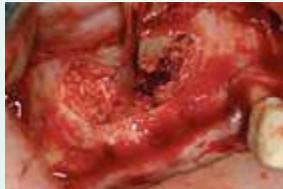

Fig. 6 • Innesto di bone-chips di osso autologo nella cavità mascellare

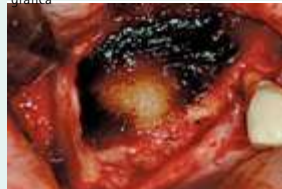

Fig. 7 • Posizionamento di una membrana riassorbibile a protezione del materiale innestato e a sostegno dei tessuti molli

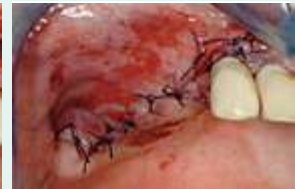

Fig. 8 • Sutura. Si noti anche in questo caso lo stato di salute dei tessuti molli

Si ringrazia per la gentile concessione il Prof. Enrico Gherlone

# PIEZO- CHIRURGIA IN ODONTOLATRIA

Le tecniche piezoelettriche, recentemente impiegate in chirurgia dei mascellari, consentono osteotomie precise e sicure nel rispetto delle strutture ossee

di Raffaele Vinci

Responsabile del reparto di Chirurgia orale avanzata, Dipartimento di Clinica odontoiatrica, Ospedale San Raffaele, Milano

La moderna odontoiatria si caratterizza per un costante rinnovamento, legato a una continua acquisizione di progressi e di innovazioni tecnologiche; l'incessante avanzamento terapeutico consente di ottenere una sempre miglior prognosi anche in situazioni che solo pochi lustri or sono apparivano difficilmente trattabili.

L'utilizzo degli ultrasuoni in medicina risale a parecchi anni fa; attualmente vengono impiegati in numerose discipline nell'ambito della chirurgia, convenzionale ed endoscopica, dei tessuti molli o, per esempio, in oftalmologia per la rimozione delle cataratte. Solo più recentemente le tecniche piezoelettriche sono state adottate in odontoiatria anche per l'esecuzione di osteoplastiche e osteotomie ai mascellari: attraverso queste tecniche nuove frontiere si sono aperte nell'ambito dell'odontologia, della parodontologia, dell'implantologia, della chirurgia ortodontica.

## VANTAGGI

In sintesi gli ultrasuoni risultano vantaggiosi perché, grazie alle loro caratteristiche fisiche, permettono di ottenere:

- tagli micrometrici, che conferiscono allo strumento un alto controllo chirurgico, una maggior precisione e una maggior sicurezza intraoperatoria;
- tagli selettivi, come conseguenza della particolare frequenza di lavoro dello strumento (27-29,5 kHz); questa caratteristica rende il taglio poco efficace sull'osso scarsamente mineralizzato e sui tessuti molli;

- sito essangue, come conseguenza dell'effetto di cavitazione (per cavitazione si intende la formazione di bolle di vapore a bassissima pressione che, implostando, danno origine a un'azione meccanica di pulizia, rendendo il campo operatorio essangue).

## STUDI DI EFFICACIA

Gli studi istomorfologici che stiamo eseguendo sembrano indicare come la qualità dell'osteotomia piezoelettrica sia migliore se comparata a quella eseguita con strumenti rotanti, in termini sia di precisione sia di rispetto delle strutture ossee. Sezioni istologiche di biopsie eseguite successivamente a procedure chirurgiche effettuate con il terminale piezoelettrico testimoniano, infatti, una maggior ossa ossea rispetto a quella riscontrata in seguito all'utilizzo di frese rotanti. Questo è dovuto probabilmente alla presenza di una minor percentuale di necrosi evidenziabile sulla linea osteotomica; purimenti la biologia molecolare evidenzia, nel confronto fra tecniche piezoelettriche e tecniche tradizionali, un maggior rispetto del

l'osso prelevato nel primo caso. La chirurgia piezoelettrica fornisce, inoltre, una miglior risposta ossea anche in termini di rigenerazione, come affermato in seguito a studi che hanno valutato i livelli di riassorbimento e rigenerazione ossea dopo chirurgia resettiva effettuata con entrambi le metodiche. Allo stesso modo le sedi donatrici di prelievi ossei sembrano andare incontro a una miglior guarigione: quando possibile, alla ripertura dopo quattro mesi per il posizionamento degli impianti, vengono eseguiti piccoli prelievi ossei che possono evidenziare una più precoce e matura ricostituzione.

Sono stati anche effettuati studi per valutare l'influenza del piezoelettrico nel coltellamento di chip ossei da siti intraorali: i tempi di proliferazione e di differenziazione delle cellule ottenuti in seguito all'impiego del piezoelettrico rispetto alle tecniche tra-

dizionali sono sovrapponibili. D'altro canto esistono studi che testimoniano una maggior vitalità delle chip ottenute mediante l'utilizzo della chirurgia piezoelettrica: i risultati sono probabilmente correlati sia alle dimensioni delle chip ossee prelevate sia all'atraumaticità del prelievo.

## AMBITI DI APPLICAZIONE

Proposto in chirurgia orale per rendere più ergonomica e sicura l'elevazione della mucosa sinusale e le espansioni crestali, l'apparecchio piezoelettrico viene attualmente utilizzato con maggiori potenze anche per l'asportazione di lesioni cistiche dei mascellari, l'excresi dei germi dentali, l'estrazione di elementi disodontiastici. In particolare, quando è necessario effettuare biopsie ossee od osteotomie in vicinanza a elementi dentali, è possibile eseguire tagli ossei molto precisi senza pericolo di produrre danni alle strutture circostanti.

Allo stesso modo la chirurgia piezoelettrica si è dimostrata estremamente utile nell'esecuzione di prelievi ossei sia intra- sia extrorali; l'eventuale esposizione del fascio vascolonervoso mandibolare durante il prelievo della corticale esterna del corpo e della branca montante avviene senza che vengano causate lesioni. Partimenti, quando è programmato un prelievo di teca parietale in pazienti che abbiano in precedenza riportato traumi cranici o si abbiano incrinazioni sullo spessore della teca, è indicato, durante il primo prelievo, utilizzare un terminale piezoelettrico, riducendo in questo modo significativamente ogni rischio di lesione della dura madre sottostante.

Nel corso di queste manovre è indispensabile un'abbondante irrigazione del sistema per prevenire il surriscaldamento dell'osso. Il terminale deve essere appoggiato fermamente, ma senza eccessiva pressione, sulla linea osteotomica, evitando così fratture dello strumento; la pressione esercitata, infatti, non deve mai interferire sulle possibilità di vibrazione del terminale che, in questo caso, cambia tono di frequenza.

La chirurgia piezoelettrica può essere utilizzata anche quindi, dopo un intervento di chirurgia ortodontica ►

“Da studi istomorfologici in corso sembra che la qualità dell'osteotomia piezoelettrica sia migliore di quella eseguita con strumenti rotanti”

## DOVE È POSSIBILE INTERVENIRE CON IL TERMINALE PIEZOELETTRICO

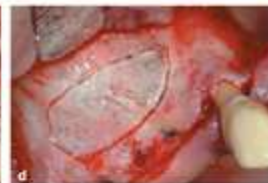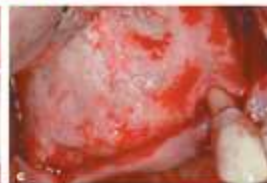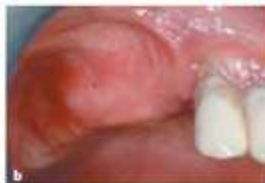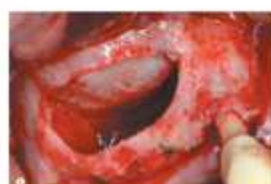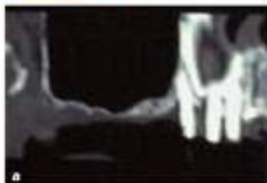- Elevazione della mucosa sinusale
- Espansioni crestali
- Asportazioni di lesioni cistiche dei mascellari
- Excresi dei germi dentali
- Estrazione di elementi disodontiastici
- Biopsie ossee
- Prelievo della corticale esterna del corpo e della branca montante
- Prelievo dalla teca parietale
- Dopo interventi di chirurgia ortodontica o preimplantare





## RIQUADRO 1

## SINUS LIFT



a. La scansione mediante tomografia computerizzata evidenzia un'insipiente pneumatizzazione del seno mascellare con scomparizione dell'osso basale residuo.

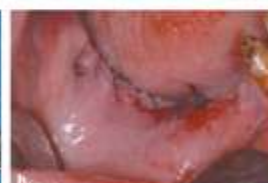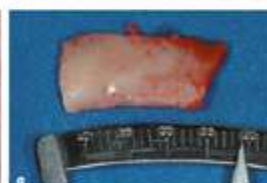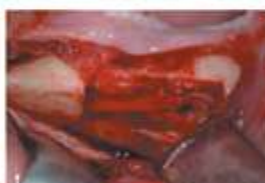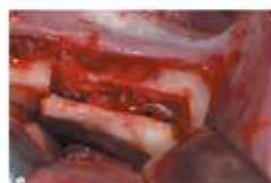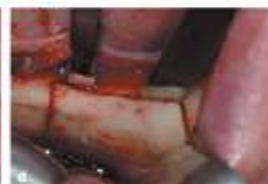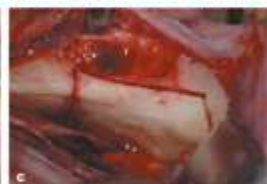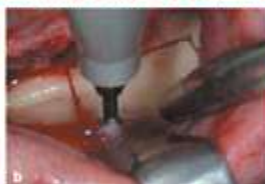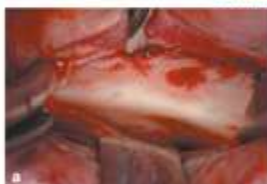b. Immagine intraorale.  
c. Scheletrizzazione mediante accesso crestale della parete anteriore sinusale.  
d. Disegno della botola ossea per l'accesso antrale.

si notino la precisione e le dimensioni estremamente ridotte dei tagli.  
e. Ribaltamento della botola ossea con totale conservazione dell'integrità della membrana.

f. Zappaggio della neocavità.  
g. Copertura dell'innesto con una falda emostatica.  
h. Riposizionamento e sutura dei tessuti molli.

## RIQUADRO 2

## PRELIEVO DAL CORPO E DALLA BRANCA MONTANTE MANDIBOLARE



a. Incisione e scollamento dei piani mucosi in corrispondenza del trigono ritromolare che viene scheletrizzato.  
b. Disegno dei tagli ossei

con il terminale piezoelettrico.  
c. Linee osteotoniche completate: si notino la precisione e le dimensioni estremamente ridotte dei tagli.

d. Mobilizzazione mediante scalpelli angolari del prelievo osseo.  
e. Prelievo mobilizzato: si noti l'esposizione del fascio vascolonervoso.

f. Letto donatore dopo il prelievo.  
g. Frammento asportato.  
h. Sutura dei tessuti molli.

o preimpianto, vengono rimossi i pezzi di sintesi precedentemente utilizzati: in questo modo è possibile liberare le teste delle viti e/o le placche di fissazione dalla parte esuberante di colla ossea che eventualmente le ha ricoperte.

## QUATTRO CASI CLINICI

In questo articolo vengono presentati alcuni casi clinici nei quali l'utilizzo della tecnica piezoelettrica, in

vari ambiti della chirurgia orale, ha dato buoni esiti: nel primo caso si è trattato di elevare la membrana sinusale, nel secondo è stato effettuato un prelievo osseo dal corpo e dalla membrana montante mandibolare, il terzo caso illustra un prelievo extraorale, con utilizzo di osso parietale, e il quarto un'exeresi di una cisti follicolare.



## Perdita di elementi dentali

La perdita degli elementi dentali induce un'involutione dei tessuti peridontali limitrofi, manifestando, nel corso del tempo, diversi gradi di riassorbimento a carico dei processi alveolari e dell'osso basale. I quadri clinici che si vengono a produrre posso-

no essere estremamente eterogenei, ma sono tutti caratterizzati dalla difficoltà o dall'impossibilità di una corretta riabilitazione implantoprotesica: l'assenza di substrato osseo impedisce, infatti, l'esatto posizionamento implantare, generando compromessi in fase riabilitativa che incidono sulla prognosi del risultato finale.

Caratteristicamente, nei settori anteriori e posteriori del mascellare l'assenza delle forze trasmesse dalle radici dentali all'osso determina un'eccessiva pneumatizzazione del seno mascellare verso il basso, con notevole perdita di osso basale e/o alveolare; per ovviare a ciò, è quasi sempre necessario eseguire un'elevazione della membrana sinusale (Riquadro 1).

Gli innesti di osso autologo nelle ricostruzioni tridimensionali, o comunque estese, dei processi alveola-

ri sono ancora oggi l'intervento d'elezione e, in relazione al grado di atrofia, vi è indicazione al prelievo intraorale, dal corpo e dalla branca montante mandibolare (Riquadro 2), o extraorale; fra questi ultimi interventi, grande rilievo occupa l'utilizzo di osso parietale (Riquadro 3), che fornisce sia qualitativamente sia quantitativamente materiale idoneo per una corretta ricostruzione delle basi ossee atrofizzate.



## Mancata eruzione di elementi dentali


Frequentemente la mancata eruzione di un elemento dentale disodontostico è accompagnata dall'insorgere di uno sviluppo abnorme del sacco follicolare.

## PIEZOELETRICO; ACCORGIMENTI D'USO

- Abbondante irrigazione
- Limitata pressione sulla linea osteotomica

**RIQUADRO 3**

**PRELIEVO DALLA TECA PARIETALE**



a. ???  
 b. Una volta scheletrizzata la teca parietale, viene disegnata una prima ansa donatrice, solitamente in una zona ben accessibile dietro alla sutura coronale.  
 c. Completamento dei tagli ossei.  
 d. Mobilizzazione mediante scalpello angolato del primo tassello osseo.  
 e. Spessore della stecca ossea: si noti l'evidente componente midollare sempre presente anche nei prelievi parietali.

f. Il prelievo dei blocchi successivi avviene molto più spedatamente, conoscendo la morfologia del tavolo osseo.  
 g. Ampia estensione del sito prelevato (esempio si di luce dell'inserzione del muscolo temporo-laterale e a 2 cm dalla linea mediana).  
 h. Bisellatura dei margini del prelievo con terminale piezoelettrico o con bone scraper; segue il posizionamento di chip osseo e/o taida emostatica all'interno del letto donatore.  
 i. Sutura dei tessuti molli.

Nel riquadro 4 è mostrato un caso clinico caratterizzato dalla presenza, in associazione alla ritenzione di 4,8, di una voluminosa lesione osteolitica occupante in toto l'angolo e buona parte

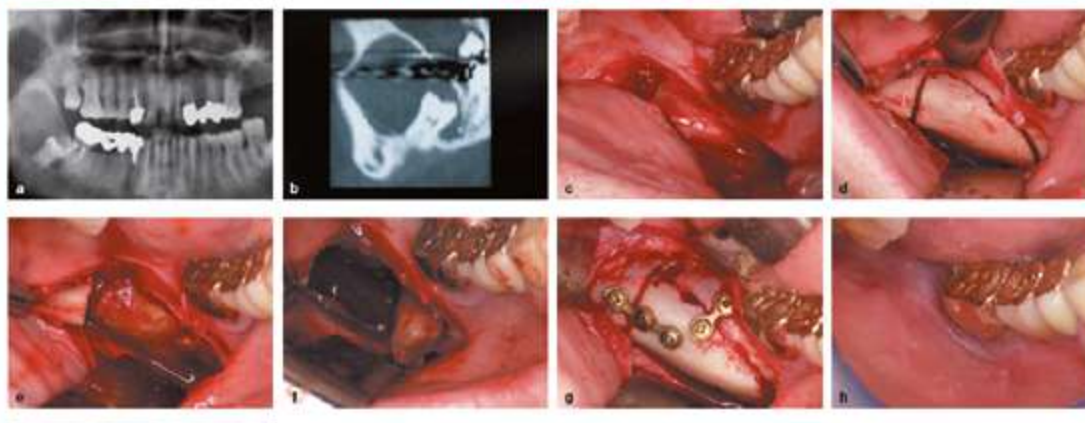
te della branca montante mandibolare, che risultano di molto indeboliti. Per una buona riuscita dell'intervento di excresi della cisti follicolare è indispensabile ridurre al minimo le perdi-

te di osso necessarie per l'asportazione della lesione, preservare l'integrità del fascio vascolonervoso mandibolare e mantenere il più possibile intatta la massa da asportare per avere una

buona garanzia di escissione. L'impegno del terminale piezoelettrico durante le varie fasi dell'intervento consente di ottemperare a tutte queste esigenze.

**RIQUADRO 4**

**EXERESI DELLA CISTI FOLLICOLARE**



a. L'indagine radiografica evidenzia una voluminosa cisti follicolare della branca mandibolare.  
 b. La scansione mediante tomografia computerizzata evidenzia l'estrema esiguità dell'osso residuo.  
 c. Incisione e scollamento dei piani mucosi in corrispondenza del trigono retroalveolare.  
 d. Tagli ossei in corrispondenza della lesione osteolitica.  
 e. Asportazione dello sportello osseo;

si noti l'integrità delle pareti della lesione cistica sottostante.  
 f. All'asportazione della lesione cistica segue quella del molare sottostante: si noti, sul fondo della lesione, il fascio vascolonervoso mandibolare.  
 g. Riposizionamento dell'opercolo osseo stabilizzato con miniplacche e viti.  
 h. Guarigione dei tessuti molli.  
 i. Controllo radiografico a un anno dall'intervento: si evidenzia la guarigione ossea.



**I° EXPO DI AUTUNNO**  
 Milano, Centro Congressi Milanofiori, 30 Novembre - 1 Dicembre 2007  
**ODONTOIATRIA DEL III MILLENNIO TRA PUBBLICO E PRIVATO**

**INFLUENZA DEL DESAMETASONE NELLA GERMECTOMIA PIEZOELETTRICA. STUDIO CLINICO CONTROLLATO.**

**M. DEL BRUTTO\*, C. VIANALE e R. MAZZANTI.**

U.O. di CHIRURGIA ORALE e ODONTOSTOMATOLOGIA. ASUR Marche - Z.T.6 - Fabriano (AN)  
 Responsabile: Dott. Roberto Mazzanti

**SCOPO DELLO STUDIO**

Scopo di questo studio è verificare, attraverso uno studio prospettivo, l'ipotesi associativa tra l'iniezione del Desametasone sodio fosfato in siti post-estrattivi ed i possibili effetti sull'immediato decorso post-operatorio di pazienti sottoposti a Germectomia degli ottavi inferiori.

**MATERIALE E METODI**

Il campione analizzato nello studio comprende 42 siti estrattivi in 21 soggetti (11 maschi e 10 femmine) di età compresa tra i 14 e i 16 anni sottoposti a Germectomia degli ottavi inferiori, in un'età in cui i settimi risultano erotti e gli ottavi presentano un'edificazione radicolare inferiore ai 2/3. Sono stati riportati dati anagrafici generali, elementi anamnestici, caratterizzazione clinica prima del ricovero, caratteristiche cliniche al follow-up ed alla dimissione. La tecnica chirurgica adottata è quella proposta da Clauser nel 1985 (Via Distale Alta), effettuata mediante l'ausilio di strumento piezochirurgico Easy Surgery® (Biosaf, Assago).

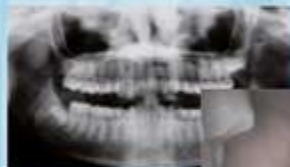

Foto n° 1 (in alto) e 2 (a destra) - Radiografia OPT preoperatoria del sito estrattivo secondo la Via Distale Alta.

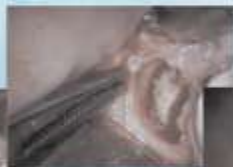

Foto n° 3 (in alto) e 4 (a destra) - Foto intraoperatoria con addeposizione ed espulsione del frammento dentario.



Foto n° 5 (in alto) e 6 (a destra) - Sutura e reperti sul terdoperatorio.

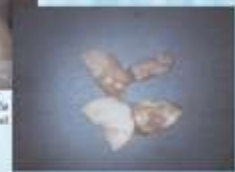
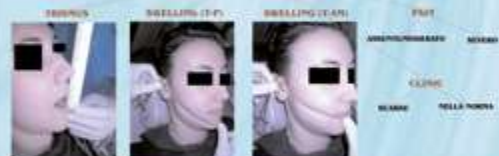
Foto n° 7 (in alto) - Strumento piezochirurgico Easy Surgery® (Biosaf, Assago) attraverso il quale sono stati effettuati gli interventi di germectomia.

**CRITERI DI INCLUSIONE NELLO STUDIO**

- Assenza di patologie sistemiche rilevanti.
- Assenza di sintomi clinici riferibili a disodontias degli ottavi.
- Assenza di trattamento cortisonico (locale e/o sistemico), FANS e antibiotici nei 60 giorni precedenti l'intervento.
- DMFT complessivo inferiore a 4
- Non fumatori
- Tolleranza alle penicilline e FANS
- Indice di placca = 0
- Assenza di tasche parodontali e sanguinamento al sondaggio (BOP) = 0

**VARIABILI CONSIDERATE:**



**RISULTATI E CONCLUSIONI**

La differenza fra il gruppo SPERIMENTALE e il gruppo CONTROLLO risulta significativa per  $P < 0.05$  per la variabile TUMEFAZIONE (con test di significatività chi-quadrato pari a 6,22) (Tab. 2) e per la variabile LIMITAZIONE FUNZIONALE (con test di significatività chi-quadrato pari a 6,11) (Tab. 3).

Non esistono differenze statisticamente significative per le variabili DOLORE e CONDIZIONI CLINICHE. A riguardo delle variabili nelle quali sono risultate differenze statisticamente significative, dobbiamo sottolineare che l'infiltrazione perioperatoria del farmaco ha contenuto la tumefazione in un range che noi abbiamo definito DISCRETA nel 76% dei siti trattati.

Nei siti placebo la tumefazione si è mantenuta discreta solo nel 38% dei casi ed è arrivata ad essere SEVERA nel 62% (Grafico 1).

La LIMITAZIONE FUNZIONALE si è mantenuta entro i limiti del 50% nel 72% dei siti trattati con il farmaco, mentre ha superato la soglia del 50% nel 67% dei siti trattati con placebo (Grafico 2).

L'uso dei corticosteroidi in chirurgia orale può rappresentare un valido ausilio per il controllo delle manifestazioni infiammatorie acute conseguenza dell'atto chirurgico o per diminuire la reattività delle guaine nervose a seguito di manovre chirurgiche in zone limitofe.

TABELLA 1 - Dati complessivi

	Pain AM	Pain S	Total Swell D	Swell S	Total Trismus M	Trismus S	Total Clinic S	Clinic M	Total			
Desametasone	8	13	21	18	8	21	8	21	8	38	21	
Placebo	9	12	21	9	13	21	7	14	21	4	17	21
<b>Totali</b>	<b>17</b>	<b>25</b>	<b>42</b>	<b>24</b>	<b>21</b>	<b>42</b>	<b>15</b>	<b>35</b>	<b>42</b>	<b>9</b>	<b>32</b>	<b>42</b>

TABELLA 2 - Test di significatività per la variabile Tumefazione

	Swell D	Swell S	Total	Chi-quadrato	5,22 SIGNIF. P<0,05
Desametasone	16	5	21 p		0,0126
Placebo	9	13	21 Corretto Yates		4,76 SIGNIF. P<0,05
<b>Totali</b>	<b>24</b>	<b>18</b>	<b>42 p</b>		<b>0,0291</b>

TABELLA 3 - Test di significatività per la variabile Limitazione Funzionale

	Trismus M	Trismus S	Total	Chi-quadrato	6,11 SIGNIF. P<0,05
Desametasone	15	6	21 p		0,0134
Placebo	7	14	21 Corretto Yates		4,68 SIGNIF. P<0,05
<b>Totali</b>	<b>22</b>	<b>20</b>	<b>42 p</b>		<b>0,0306</b>

GRAFICO 1 - Distribuzione di frequenza relativa alla variabile TUMEFAZIONE



GRAFICO 2 - Distribuzione di frequenza relativa alla variabile LIMITAZIONE FUNZIONALE





**1 Impianto troncoconico con componente protesica sottodimensionata per mantenere l'osso crestale**

L. Prosper, S. Redaelli, A. D'Addona, E. F. Gherlone

Poster 13° Congresso Nazionale del Collegio dei Docenti di Odontoiatria - Roma 5-8 Aprile 2006

---

20  
06





**13° CONGRESSO NAZIONALE DEL COLLEGIO DEI DOCENTI DI ODONTOIATRIA 5-8 APRILE 2006, ROMA**



**IMPIANTO TRONCOCONICO CON COMPONENTE PROTESICA SOTTODIMENSIONATA PER MANTENERE L'OSSO CRESTALE**



L. Prosper\*, S. Pedaelli, A. D'Addona, E. Gherlone (Primo Reparto Odontoiatria Prof. E. Gherlone, HSR, Università Vita e Salute, Milano)

**Background**

La conservazione del livello osseo creatale riduce la possibilità di infrazione infiammatoria e migliora la stabilità dei tessuti perimplantari<sup>1, 2</sup>.

**Obiettivo**

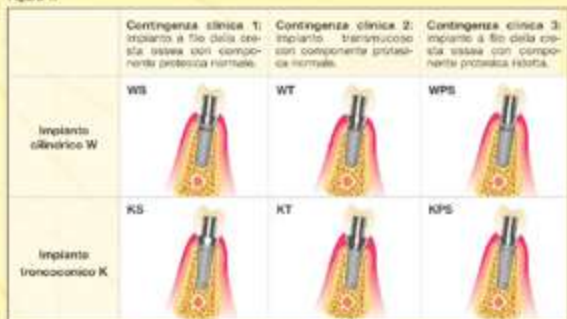Valutare l'efficacia del sottodimensionamento della componente protesica in un nuovo sistema impiantare con impianto troncoconico versus impianto cilindrico, per il mantenimento del livello osseo creatale.

**Materiali e Metodi**

**Design.** Studio randomizzato longitudinale comparativo multicentrico.  
**Soggetti.** 60 pazienti (età media [DS]: 56,9 [8,4] anni; 32 uomini; 28 donne) consecutivamente reclutati in 12 studi odontoiatrici (9 su in ciascuno studio) distribuiti sul territorio nazionale italiano, in accordo al seguente criteri di eleggibilità:  
 - Criteri di inclusione: età >18 e <70 anni, non fumatori (<3 sigarette/die), non consumatori di alcool (>3 bicchieri/die), edentolati occlusali in ciascun quadrante, assenza di edentulia frontale, inserimento di 6 impianti in unità dentali con antagonista in dentizione naturale, classe di densità ossea II.  
 - Criteri di esclusione: Presenza di alterazioni alle articolazioni ATM e/o disfunzioni temporomandibolari; presenza di neoplasie; presenza di difetti ossei; cattivo controllo della placca.  
**Sistemi impiantari.** Due sistemi impiantari formati, rispettivamente, da impianti test di forma troncoconica (Wimax® W) e impianti controllo di forma cilindrica (Wimax® W), in tre contingenze cliniche: 1) KS, WS; impianto a filo della cresta ossea con componente protesica normale; 2) KT, WT; impianto troncoconico con componente protesica norma-

le; 3) KPS, WPS; impianto a filo della cresta ossea con componente protesica a sezione di connessione ridotta (Figura 1).  
 I sistemi impiantari KS, KT, WS, WT presentano diametro dell'impianto e della sezione di connessione della componente protesica uguali (3,3 mm, 3,6 mm, 4,5 mm, e 5,9 mm). I sistemi impiantari KPS e WPS presentano diametro dell'impianto (3,9 mm, 4,5 mm, 5,2 mm o 6,6 mm) maggiore di quello della sezione di connessione della componente protesica (3,3 mm, 3,6 mm, 4,5 mm e 5,9 mm), con rapporto compreso tra 1,12 e 1,18 sia per gli impianti KPS che per gli impianti WPS.  
**Randomizzazione.** Randomizzazione semplice entro paziente delle diverse combinazioni impianto-moncone, a blocco di 6 pazienti rispetto alla zona dentale.  
**Variabile primaria di outcome.** Riasorbimento osseo (mm) valutato 12 e 24 mesi dopo l'inserimento dell'impianto, tramite sondaggio clinico e valutazione radiografica (con centobara, ed anche classificato come assente (nessun riassorbimento) o presente (riassorbimento >0 mm).  
**Analisi statistica.**  
 Test non parametrici di Wilcoxon e di Friedman.

**Figura 1.**



**Risultati**

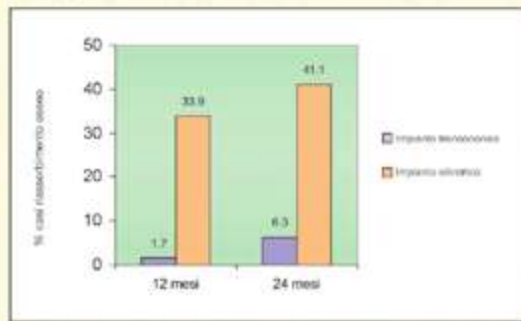
Tra i 60 pazienti, 40 (66,7%) presentavano classe scheletrica I, 9 (15%) classe II, 11 (18,3%) classe III. In totale sono stati inseriti 360 impianti (180 di tipo K, 30 KS, 30 KT, 30 KPS) e 180 di tipo W (30 WS, 30 WT, 30 WPS).  
 Nei 90% o più di pazienti, il periodo di guarigione è stato compreso tra 3 e 4 mesi per tutte le combinazioni impianto-moncone. In un paziente (6anni, età 75 anni) il periodo di guarigione è stato di 6 mesi per ciascun impianto.  
 L'assenza di riassorbimento osseo è significativamente maggiore negli impianti troncoconici rispetto agli impianti cilindrici sia 12 mesi dopo l'inseri-

mento dell'impianto (98,3% vs 66,1%; P<0,01) sia dopo 24 mesi (94% vs 58,9%; P<0,01) (Figura 2, Figura 3).  
 - Negli impianti con componente protesica a sezione di connessione ridotta, assenza di riassorbimento osseo è stata osservata nel 98,3% degli impianti dopo 12 mesi dall'inserimento nel 98,7%

dopo 24 mesi (Tabella 1, Figura 4).  
 - Assenza di riassorbimento osseo è stata osservata nel 100% degli impianti di forma troncoconica e componente protesica a sezione ridotta, sia 12 mesi sia 24 mesi dopo l'inserimento dell'impianto (Tabella 1, Figura 5).

dopo 24 mesi (Tabella 1, Figura 4).  
 - Assenza di riassorbimento osseo è stata osservata nel 100% degli impianti di forma troncoconica e componente protesica a sezione ridotta, sia 12 mesi sia 24 mesi dopo l'inserimento dell'impianto (Tabella 1, Figura 5).

**Figura 2.** Riasorbimento osseo in impianti troncoconici (Wimax® K) versus impianti cilindrici (Wimax® W).



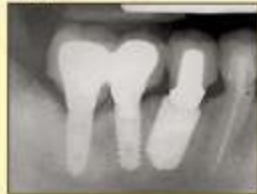Significatività della differenza tra impianto troncoconico e cilindrico: 12 mesi, P<0,0001; 24 mesi P<0,0001. Significatività della differenza tra 12 e 24 mesi: Impianto troncoconico, P=0,792; Impianto cilindrico, P=0,117.

**Tabella 1.** Riasorbimento osseo 12 e 24 mesi dopo l'inserimento dell'impianto, rispetto alla contingenza clinica.

	Impianto troncoconico	Impianto cilindrico	P-value*
<b>Assenza di riassorbimento osseo a 12 mesi (%)</b>			
Impianto a filo della cresta ossea con componente protesica normale	100	20	<0,0001*
Impianto troncoconico con componente protesica normale	98	76,7	0,003*
Impianto a filo della cresta ossea con componente protesica ridotta	100	98,7	0,157
<b>P-value*</b>	0,053	<0,001*	
<b>Assenza di riassorbimento osseo 24 mesi (%)</b>			
Impianto a filo della cresta ossea con componente protesica normale	100	0,7	<0,0001*
Impianto troncoconico con componente protesica normale	91,7	60,0	<0,0001*
Impianto a filo della cresta ossea con componente protesica ridotta	100	93,2	0,059
<b>P-value*</b>	0,097*	<0,0001*	

\* Significatività statistica del confronto tra sistemi impiantari Wimax® K and Wimax® W test di Wilcoxon. \*\* Significatività statistica del confronto tra le diverse componenti protesiche test di Friedman entro tipo d'impianto. Differenzia apud Wilcoxon differenza significativa (P<0,01) tra contingenze cliniche (contorno di Bonferroni).

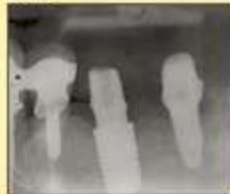**Figura 3.**



**Conclusioni**

Sistemi impiantari costituiti da impianto di forma troncoconica e componente protesica a sezione di connessione ridotta appaiono particolarmente

**Figura 4.**



**Figura 5.**



efficaci per il mantenimento dell'osso creatale nei primi 24 mesi dopo l'inserimento dell'impianto in area occlusale.

1 Baumgartner H, Cocchiello R, Tedori T, Meltzer A, Porter S. A new implant design for crestal bone preservation: initial observations and case report. *Pract Periodont Aesthet Dent* 2005;17:726-40.  
 2 Lazzaro RJ, Porter SS. Platform switching: A new concept in implant dentistry for controlling post-restorative bone levels. *Int J Peri Rest Dent* 2006;26:9-17.

**1 Passivazione nella protesi implanto-supportata**

L. Prosper, S. Redaelli, T. D'Alicandro, A. D'Addona, E. F. Gherlone  
Implantologia Orale: rivista di clinica, ricerca, qualità anno 8 numero 5

---

**2 Stabilizzazione della protesi mediante ancoraggio con mini impianti in pazienti con edentulia totale inferiore e atrofia del processo alveolare**

D. Perazzolo, E. Cavalieri, S. Piovan, E. Stellini, E. D'Andrea  
Poster 12° Congresso Nazionale - Collegio dei Docenti di Odontoiatria Roma - Palazzo dei Congressi 16-17-18-19  
Marzo 2005

20  
05

# IMPLANTOLOGIA ORALE

RIVISTA DI  
CLINICA  
RICERCA  
QUALITÀ  
ANNO 8 NUMERO 5

5  
/2005

Testata - Anno 8 - numero 5 - novembre 2005 - Piccola Italiana SpA - Specificazione in abbonamento postale - D.L. 353/2003 (conv. in L. 27/02/2004 n. 46) art. 1, comma 1, DCB Milano



MONOGRAFIA  
Passivazione della protesi  
implanto-supportata

edita da Piccola Italiana



IMPLANTOLOGIA ORALE NUMERO 5 NOVEMBRE 2005

## PASSIVAZIONE NELLA PROTESI IMPLANTO-SUPPORTATA

Loris Prosper, Sara Redaelli, Tonino D'Alicandro, Antonio D'Addona, Enrico Gherlone

*Ateneo Vita e Salute, San Raffaele, Milano, Dipartimento di Odontoiatria,  
Cattedra di Odontostomatologia, Direttore professor E. Gherlone*

### RIASSUNTO

Nonostante non sia ancora stato scientificamente appurato che il misfit protesico possa causare la perdita dell'osteointegrazione implantare, clinicamente si suppone che la mancata passivazione delle strutture protesiche possa potenzialmente determinare un fallimento della terapia impianto-protesica, o per distruzione dell'osso perimplantare o per svitamento o frattura delle componenti metalliche protesiche. Vengono qui descritte alcune tecniche che tentano di risolvere l'annoso problema della passivazione su impianti osteointegrati, legato alle imprecisioni accumulate nei vari passaggi di laboratorio, dall'impronta al gesso, allo sviluppo dei modelli, alla ceratura e alla fusione. Infatti, per mantenere l'osteointegrazione, è essenziale che l'adattamento della protesi sia del tutto passivo, in quanto la condizione di anchilosi funzionale che caratterizza gli impianti li rende incapaci di sopportare le tensioni derivanti da una travata non passiva.

### SUMMARY

Passivation of implant-supported prosthesis. Although misfitting prosthesis have not yet been demonstrated to cause failure of osseointegrated implants, clinically it must be assumed that misfits can potentially cause the failure of implant-supported restorations, either through destruction of peri-implant bone or loosening or mechanical failure of the implant-prosthesis complex. This article describes some implant-supported prosthesis passivation techniques aimed at solving impression, modeling, waxing and casting issues and inadequate handling in the dental laboratory that may originate stress forces around the implant. Indeed, for osseointegration to be maintained, full prosthesis passivation must be achieved since functional ankylosis makes the implant unable to withstand the stress originating from a non passive fit.

*Implantologia Orale 2005;5:9-28*



Loris Prosper

*Inizia l'attività pratica di odontotecnico negli anni Settanta lavorando presso lo studio del professor G. Hruska a Milano. Consegue la Laurea in Medicina e Chirurgia a pieni voti. Nel 1982 riveste il ruolo di insegnante nei seminari di protesi, consulente per problematiche gnatologiche e membro del reparto di ricerche in ceramica e metallurgia alla Scuola di Specializzazione in Odontostomatologia dell'Università degli Studi di Genova; consulente tecnico e scientifico della ditta Shofu di Kyoto in Giappone. Dal 1991 al 1994 è Professore a contratto della Cattedra di Protesi nel Corso di Laurea in Odontoiatria e Protesi Dentaria all'Università G. D'Annunzio di Chieti, Direttore professor M. Quaranta. Nel 1991 diventa Direttore Scientifico della rivista QDT Quintessence of Dental Technology, edizione italiana, e membro del Comitato di redazione scientifica della Rivista Internazionale di Odontotecnica e Odontoiatria Ricostruttiva Dental Labor, edizioni MEA. Nell'anno accademico 1995-1996 è Docente nel Corso di perfezionamento in Implantoprotesi orale Cattedra di Protesi Dentaria dell'Università degli Studi di Milano, IRCCS, Ospedale San Raffaele. Nel 1997 è membro del Comitato di redazione scientifica della Rivista Team Work, edizioni MEA. Nel 1999 è Docente nel Corso di Implantoprotesi presso l'Università La Sapienza di Roma, Direttore professor M. Quaranta. Lo stesso anno è Consulente Scientifico, responsabile della sezione di ricerca e sviluppo dei materiali di ultima generazione all'Istituto Scientifico San Raffaele, Milano, Università Ateneo Vita e Salute, Direttore professor E. Gherlone. Nel 2000 è Docente nel Corso di Protesi presso l'Università degli Studi di Milano e Membro del Comitato Scientifico della Rivista Internazionale di Odontoiatria Protesica. Nell'anno accademico 2001-2002 è Docente al Master Internazionale Biennale di Implantologia e Riabilitazioni Protesiche, Università La Sapienza, Roma. Dal 2002 è Professore a contratto all'Università Ateneo Vita e Salute dell'Istituto Scientifico San Raffaele, Milano, Responsabile del Reparto di Odontoiatria Estetica.*

**I**l principale obiettivo di chi si sottopone e di chi esegue una terapia implantare è la garanzia della longevità dell'impianto. Studi clinici riferiscono che le cause maggiori di perdita dell'impianto sono l'accumulo di placca batterica<sup>1</sup>, la presenza di osso di tipo IV<sup>2</sup> e il sovraccarico<sup>3,5</sup>, ossia l'esistenza di livelli di stress distruttivi in corrispondenza dell'osso perimplantare per il mancato controllo della distribuzione del carico masticatorio sugli impianti stessi.

Nonostante, in verità, alla domanda se l'incongruenza di una protesi possa o meno causare il fallimento dell'osteointegrazione non sia ancora stata data una risposta<sup>6</sup>, è ampiamente ipotizzabile che il misfit della restaurazione impianto-supportata abbia il potenziale intrinseco di causare un fallimento implantare, inteso sia come distruzione dell'interfaccia osso-impianto nel senso di microfratture e ischemie, sia come fallimento meccanico nel senso di svitamento o rottura di qualche componente protesica. Infatti, le viti che connettono le meso- e le sovrastrutture protesiche, se le loro interfacce non sono perfettamente accoppiate, possono introdurre intensi stress una volta serrate (stress statici), stress che sono di intensità notevolmente superiore a quelli generati durante la funzione masticatoria abituale del paziente (stress dinamici).

Questi carichi statici sono considerati potenzialmente più pericolosi dei carichi dinamici, poiché introducono tensioni permanenti e incessanti nel tessuto osseo perimplantare, il quale non è in grado di dissiparle mediante dei micromovimenti ortodontici dell'impianto, come avviene, invece, per i denti, vista l'anelasticità della connessione osso-impianto (anchilosi funzionale).

Quindi, sebbene gli effetti a lungo termine di tali tensioni sulla stabilità e sul successo degli impianti e delle protesi che essi supportano non siano stati ancora compresi appieno, senza dubbio si può ritenere che l'osso perimplantare non ne tragga beneficio.

Alcuni Autori<sup>7,8</sup> sostengono che i carichi funzionali al di sopra di una determinata soglia, che purtroppo non si conosce ancora precisamente, demoliscono proporzionalmente e progressivamente l'intimo contatto osso-impianto e che questa distruzione si arresterebbe solo quando il substrato osseo riuscisse ad adattarsi in senso depositivo, ossia quando una nuova omeostasi fosse raggiunta. Tuttavia questa riorganizzazione dei tessuti non comporterebbe la neoapposizione di osso, ma la formazione di tessuto connettivo fibroso, anche se clinicamente i tessuti perimplantari risulterebbero normostrutturati.

Nel 1996 Isidor<sup>9</sup>, in uno studio split-mouth nelle scimmie in cui comparava la perimplantite da legature al sovraccarico occlusale, concluse che il sovraccarico occlusale è il principale fattore di rischio per la perdita degli im-

pianti già osteointegrati, mentre l'accumulo di placca batterica determina, in genere, semplicemente una perdita ossea marginale.

Le variabili biomeccaniche che possono influire sulla distribuzione delle forze masticatorie sulle fixture sono: la qualità e la quantità dell'osso; la lunghezza dell'impianto, il suo diametro e la sua macro- e microtopografia; il numero e la posizione delle viti; la tipologia protesica prescelta, se fissa o mobile, parziale o totale; il tipo di materiale scelto per la sua esecuzione e come è stata connessa agli impianti; e, infine, il tipo di occlusione del paziente, se ci sono disfunzioni o parafunzioni, spasmi muscolari, precontatti o rapporti intermascellari corretti.

Per distribuire il più equamente possibile i carichi occlusali ed evitare le forze trasversali, il diametro e la lunghezza dell'impianto dovrebbero essere le maggiori auspicabili, così da trasferire meno stress all'osso perimplantare; il pilastro occlusale dovrebbe trovarsi al di sotto della cuspidi di centrica; l'impianto dovrebbe essere sulla stessa direzione del vettore di forza dell'antagonista<sup>10</sup>, ma soprattutto è fondamentale la finalizzazione della centrica con nessuna interferenza nei movimenti eccentrici di lateralità e protrusiva.

## CONCETTO DI PASSIVAZIONE

Uno dei fattori maggiormente responsabili della generazione di sollecitazioni statiche nelle strutture ossee perimplantari in assenza di carico occlusale è considerato essere la mancanza di adattamento passivo tra la sovrastruttura implantare e i pilastri. L'adattamento passivo è stato definito come "il contatto circonferenziale e simultaneo di tutti i monconi sui loro rispettivi impianti e di tutti i cilindri aurei della protesi sui loro rispettivi monconi"<sup>11</sup>, vale a dire l'eliminazione delle tensioni che si inseriscono quasi inevitabilmente quando si mettono in connessione due o più impianti.

Alcuni Autori<sup>12-17</sup> hanno descritto le complicanze, protesiche o implantari, dovute allo scarso accomodamento delle sovrastrutture sugli impianti, ossia l'allentamento o la frattura degli impianti e delle loro componenti protesiche (viti di fissazione e abutment), in particolare nelle protesi avvitate su impianti multipli, poiché in quelle cementate il cemento ricoprirebbe già in parte il ruolo di passivante. Tuttavia, solo pochissimi studi hanno documentato questo nesso di causalità in modo statistico, se si considera la complessità delle deformazioni esistenti all'interno delle strutture ossee che circondano impianti non completamente passivati, le quali derivano dalla combinazione di forze di tensione, flessione e avvitemento<sup>18</sup>.



IMPLANTOLOGIA ORALE NUMERO 5 NOVEMBRE 2005

Le maggiori difficoltà che impediscono il raggiungimento di un fit passivo sugli abutment sono rappresentate dalle tecniche di fusione e di saldatura per i mutamenti dimensionali della struttura metallica che ne derivano<sup>23-25</sup> e/o dalla presenza di impurità o di microdistorsioni che possono apparire sulle superfici di adattamento dopo la sovrapposizione dei cilindri aurei o dopo la fusione degli standard di plastica calcinabili<sup>24</sup>, tutte variabili difficilmente quantificabili e misurabili. Ne consegue che sono state eseguite poche indagini sugli effetti biologici a carico dell'osso perimplantare dei differenti gradi di adattamento marginale delle sovrastrutture, e che i limiti di imperfezione delle armature metalliche non sono universalmente accettati, variando da 30 a 150  $\mu\text{m}$ <sup>25</sup>.

Recentemente, Jemt e collaboratori<sup>26</sup>, in uno studio sperimentale su tibie di coniglio, hanno evidenziato che una discrepanza di 100  $\mu\text{m}$  tra 3 impianti può indurre una reazione di addensamento osseo nell'arco di poche settimane in assenza di carico occlusale. Lo stesso Autore<sup>27</sup>, valutando l'adattamento di strutture protesiche totali fisse in un follow-up di 5 anni, ha concluso che, nonostante nessuna di tali strutture fosse passiva, nessun impianto aveva subito una perdita ossea, ipotizzando che debba esistere un range di imprecisione delle sovrastrutture, tollerato dagli impianti, compatibile con un'elevata sopravvivenza a lungo termine.

Tuttavia, tenendo conto del fatto che l'interfaccia osso-impianto è un sistema rigido, privo di resilienza, che non permette alcun micro-adattamento meccanico del manufatto in situ, diventa imperativo cercare di raggiungere la massima precisione e passivazione della sovrastruttura quando si realizza una travata su impianti. Infatti, anche se le tensioni eccessive conseguenti a una mancata passivazione possono non causare effetti deleteri sull'osso perimplantare, la sommatoria di carichi eccessivi o eccentrici di origine occlusale potrebbe contribuire al superamento delle soglie di deformazione ossea. Nonostante a livello microscopico non sembra ci sia differenza circa la direzione del carico, clinicamente sembra probabile che il grado di carico occlusale sia più pericoloso della direzione.

Taylor<sup>28</sup> ritiene che la perdita di osso crestale perimplantare sia la conseguenza delle deformazioni plastiche ed elastiche delle componenti meccaniche sovraimplantari piuttosto che della direzione del carico. Per questo Autore il fattore limitante non è la percentuale di osteointegrazione, ma la configurazione dell'impianto e dei suoi elementi, soprattutto considerando i carichi ciclici a lungo termine. In una riabilitazione su impianti, quindi, il clinico dovrebbe avere come criterio discriminante della selezione della sistemazione implantare la resistenza delle componenti sovraimplantari.

Inoltre bisogna considerare che gli impianti osteointegrati sono più suscettibili al sovraccarico occlusale, vista l'assenza del legamento parodontale che si adatta con micromovimenti anche di 70-80  $\mu\text{m}$  alle forze occlusali (effetto naturale di "stress absorber"), e l'assenza dei propriocettori del legamento parodontale che sono in grado di avvisare immediatamente il sistema nervoso centrale della presenza di forze abnormi a livello dei denti<sup>29</sup>.

## DIFFERENZE TRA DENTI E IMPIANTI

Le differenze biofisiologiche tra un dente naturale e un impianto dentale endosseo sono ben note, come abbiamo appena accennato nel paragrafo precedente, ma le potenziali caratteristiche biomeccaniche derivate da queste differenze rimangono controverse<sup>28-33</sup>. La differenza intrinseca fondamentale tra un dente e un impianto è che l'impianto dentale è in diretto contatto con l'osso, mentre tra il dente e l'osso c'è l'interposizione del legamento parodontale, cosicché i valori medi di micromovimenti assiali del dente all'interno del suo alveolo si aggirano tra 25 e 100  $\mu\text{m}$ , mentre il range di mobilità di un impianto osteointegrato è stato dimostrato essere approssimativamente di 3-5  $\mu\text{m}$ <sup>29,34</sup>. Il legamento parodontale, infatti, è funzionalmente orientato perpendicolarmente ai carichi assiali, permettendo degli aggiustamenti funzionali fisiologici del dente rispetto agli stress occlusali lungo il suo asse e un adattamento funzionale ai cambiamenti delle condizioni di stress statico<sup>35</sup>. Inoltre, la mobilità data dal legamento parodontale al dente ne permette l'adattamento funzionale rispetto alle deformazioni che subisce l'osso mandibolare durante i movimenti di apertura o lateralità<sup>29</sup>, mentre l'impianto non possiede questi vantaggi vista l'assenza del legamento parodontale.

Sotto carico, i movimenti di un dente naturale cominciano con una fase iniziale non-lineare e complessa, che richiede la "collaborazione" parodontale, seguita da una fase secondaria che, invece, coinvolge l'osso alveolare<sup>36</sup>. Viceversa, un impianto caricato segue un modello di deflessione lineare ed elastico, dipendente dalla deformazione elastica dell'osso alveolare. Quindi, sotto carico, la compressibilità e la deformabilità del legamento parodontale nei denti naturali possono fare la differenza nell'adattamento alle forze occlusali statiche e dinamiche a confronto con gli impianti osteointegrati. Alcuni studi<sup>29,37</sup>, per risolvere questi svantaggi cinetici associati agli impianti, hanno suggerito un gradiente di carico. Un dente naturale, quando è sottoposto a un carico trasversale, riesce a muoversi rapidamente di 56-108  $\mu\text{m}$  e a ruotare nel terzo apicale della radice<sup>36</sup>, e la forza laterale a carico del dente

tende immediatamente a decrescere dalla cresta ossea lungo la radice. Dall'altra parte, invece, il movimento di un impianto sottoposto al medesimo carico laterale avviene gradualmente, raggiungendo al massimo 10-50  $\mu\text{m}$ , e la concentrazione di forze è maggiore a livello della cresta dell'osso perimplantare, senza alcuna possibilità di rotazione dell'impianto<sup>29</sup>. Richter<sup>30</sup> ha riportato che il carico trasversale e il serramento in centrica sviluppano gli stress più alti sull'osso crestale, e altri studi, similmente, affermano che i carichi maggiori gli impianti li sostengono in corrispondenza della cresta ossea marginale.

Jacobs e van Steenberghe<sup>30</sup>, in uno studio nel quale hanno valutato il grado di percezione oclusale di denti e impianti sfruttando delle interferenze oclusali, hanno concluso che il precontatto percepibile dai denti naturali e dagli impianti, entrambi in antagonismo con i denti naturali, è rispettivamente di 20 e 48  $\mu\text{m}$ . In un altro studio, Mericske-Stern e collaboratori<sup>31</sup>, misurando la sensibilità tattile orale con sottili lamine d'acciaio, hanno riscontrato che la soglia di pressione minima individuabile era significativamente più alta negli impianti che non nei denti naturali (3,2 vs 2,6 lamine). Risultati simili sono stati ottenuti anche da Hämmerle e collaboratori<sup>31</sup>, nel cui studio la soglia media di percezione per gli impianti era 100,6 g, mentre quella dei denti naturali era 11,5 g (8,75 volte inferiore).

#### COME NASCONO LE IMPREVISIONI DELLE MESOSTRUTTURE PROTESICHE

Per supplire all'inconveniente di avere una sovrastruttura protesica non perfettamente passivata sulle unità implantari, diversi gruppi di ricerca hanno studiato e stanno studiando nuove tecnologie che eliminino il più possibile le tensioni che possono essere presenti tra struttura protesica e impianti (multipli). Infatti, non si deve scordare che una delle cause delle imprecisioni tecniche dei manufatti (oltre alle variazioni dimensionali dei materiali durante i passaggi clinici, quali la presa delle impronte, e tecnici, quali la ceratura, la spinatura, la messa in rivestimento, la fusione e la saldatura) è rappresentata dalle tolleranze meccaniche della componentistica industriale. Così, ogniqualvolta che nelle varie fasi di laboratorio e cliniche si effettua l'accoppiamento di due o più componenti, la posizione reciproca può variare. Ad esempio, se l'abutment è modestamente inclinato rispetto alla fixture, le seppur piccole differenze di rotazione permesse dal sistema antirotazionale a esagono, esterno o interno indifferentemente, negli avvitiamenti successivi possono implicare disparallelismi apprezzabili tra i vari monconi implantari, che poi creeranno tensioni tra il

IMPLANTOLOGIA ORALE NUMERO 5 NOVEMBRE 2005

manufatto protesico e i supporti implantari, se non si ricorrerà ad appropriate strategie di passivazione.

Entrando nello specifico delle imprecisioni tecniche che possono nascere in laboratorio, le cause potrebbero attribuirsi a:

- impronte deformate;
- scarsa compatibilità tra i materiali da impronta e da sviluppo;
- esecuzione del modello senza rispetto delle corrette proporzioni dei materiali da sviluppo (gessi, resine epossidiche e resine poliuretatiche);
- espansione e/o contrazione dei materiali usati per lo sviluppo dei modelli, specialmente in strutture voluminose nelle zone curvilinee;
- utilizzo di materiali per impronta non idonei, come cappe in resina a contrazione non controllabile, mantelli in resina fotoindurente con residui di fase dispersa sulla superficie e/o parzialmente polimerizzata, materie termoplastiche stampate non sottovuoto o cere ad alto valore di retrazione;
- impiego di spaziatori chimicamente non compatibili con i materiali usati per il confezionamento delle cappe;
- modellazione e impernatura eseguite con materiali poco stabili;
- deformazioni durante la disinserzione del modellato dal modello;
- presenza di sottosquadri non rilevati;
- fasi di preriscaldamento del cilindro non idonee;
- rivestimento per fusione non idoneo;
- posizione del manufatto all'interno del cilindro non ottimale;
- surriscaldamento del metallo;
- raffreddamento troppo veloce del metallo;
- asportazione inadeguata del rivestimento dopo la fusione;
- eventuali saldature secondarie.

In particolare, per quanto concerne le fusioni, le imperfezioni possono nascere da errate lavorazioni durante il procedimento:

- le sbavature possono essere dovute a screpolature del rivestimento conseguenti, a loro volta, a un riscaldamento iniziato prima dell'idoneo indurimento del rivestimento stesso per un alterato rapporto acqua/polvere a favore del liquido;
- le colorazioni scure possono derivare dalla liberazione dei composti solforati del gesso per un preriscaldamento effettuato a una temperatura sproporzionata;
- i noduli superficiali possono essere legati alle bolle d'aria che permangono nella massa refrattaria; questo inconveniente sarebbe eliminabile utilizzando un tensioattivo, miscelando il rivestimento sottovuoto e vibrando durante il riempimento del cilindro;



IMPLANTOLOGIA ORALE NUMERO 5 NOVEMBRE 2005

- la ruvidità superficiale può conseguire alla disgregazione delle superfici interne della cavità per una troppo alta velocità di gitata o per surriscaldamento del rivestimento o del metallo;
- l'eccessiva lucidità superficiale può essere dovuta all'incompleta eliminazione della cera che libera monossido di carbonio con effetto riducente;
- l'incompletezza della fusione, ossia la presenza di porosità o di margini arrotondati, può sempre essere dovuta all'incompleta rimozione della cera, che, creando una forte pressione di gas nell'interno della cavità, rende difficoltoso l'ingresso del metallo fuso; importante in questo caso è aumentare l'intervallo di permanenza nella fase di preriscaldamento;
- la presenza di corpi estranei può risultare da penetrazioni accidentali attraverso il canale di colata oppure da minime rotture del rivestimento;
- le porosità possono essere conseguenti anche a perni sottili o a perni attaccati ad aree troppo piccole se sono localizzate nella zona di attacco dei perni; possono essere provocate da una temperatura di preriscaldamento eccessiva o da un surriscaldamento della lega se sono superficiali; e, infine, da una rallentata fuoriuscita di gas dalla cavità se sono nella zona posteriore all'attacco del perno.

La tecnica ideale di fusione dovrebbe essere la pressofusione, ossia in presenza di pressione con vuoto, per ridurre le variabili legate all'omogeneità della lega metallica allo stato fuso e per compensare la contrazione durante la fase di raffreddamento. Ottimale, quindi, sarebbe utilizzare metalli mono-componenti allo stato puro, come il titanio, oppure ridurre i componenti al minimo (stelliti).

## TECNICHE DI PASSIVAZIONE

Attualmente il mercato offre una vasta gamma di impianti che differiscono tra loro per macro- e microtopografia, e sede di connessione tra impianto e moncone e tra moncone e sovrastruttura protesica.

Vista l'ormai appurata biocompatibilità del titanio rispetto ai tessuti duri orali, la ricerca si sta dedicando al miglioramento delle caratteristiche funzionali e alla durata nel tempo degli impianti stessi.

Considerando che il complesso impianto-moncone-protesi ha una soluzione di continuità a due livelli, che possono essere situati sotto, sopra o a livello della cresta ossea, anche se solitamente la giunzione moncone-protesi risiede a livello iuxtagengivale, eccessivi carichi masticatori, impianti con geometria non corretta o errori nel posi-

zionamento da parte dell'odontoiatra possono portare, a breve o lungo termine, alla rottura di uno di questi livelli, con conseguente insuccesso della terapia impianto-protesica.

Tra gli argomenti più sviscerati a questo proposito, le prime posizioni sono occupate dal riassorbimento della cresta ossea e dalla distribuzione degli sforzi lungo l'intera superficie dell'impianto.

Negli studi condotti su impianti Brånemark si è riscontrato un riassorbimento osseo pari a 1 mm nel primo anno di funzionamento e, negli anni successivi, una perdita media annuale di 0,2 mm. Tutto questo può portare a considerevoli perdite ossee in tempi non molto lunghi, a infezioni locali e ad accumuli di placca batterica con conseguente mobilitazione protesica e con ricadute gravose sul paziente. In conclusione, la biomeccanica implantare ha un ruolo centralissimo nel mantenimento dell'osteointegrazione, soprattutto intesa come trasferimento dei carichi occlusali alle strutture ossee e come connessione impianto-abutment.

Sono nate svariate tecniche sviluppate per correggere il misfit delle protesi, quali la fusione di elementi singoli o il sezionamento della monofusione in unità separate, seguiti dall'adattamento e dall'unione delle singole parti sul modello di lavoro o direttamente nel cavo orale del paziente<sup>42</sup> ricorrendo a tecniche di brasatura per mesostrutture in lega aurea o a tecniche di saldatura laser per quelle in titanio. Infatti le tecniche di laboratorio convenzionali che portano al confezionamento di monofusioni in lega aurea o in titanio sono state giudicate imprecise per la distorsione che interessa la lega durante il suo raffreddamento o per errori che provengono da altre fasi di laboratorio precedenti.

Alla luce delle suddette affermazioni saranno elencate qui di seguito alcune delle tecniche attualmente a disposizione del clinico per realizzare strutture protesiche passive (ossia con assenza di tensioni ed eccessive frizioni tra le componenti di due sistemi in mutuo contatto): utilizzo del die-spacer, saldatura laser, elettroerosione, metodica Captek, metodica Cresco Ti, Procera All-in-One, elettrodeposizione galvanica e tecnica Free Tense System della Winsix.

## Utilizzo del die-spacer

È la tecnica di passivazione sicuramente più semplice e più diffusa<sup>43,44</sup>, permettendo, anche in protesi tradizionale, di ridurre le frizioni tra l'abutment e la sovrastruttura protesica mediante l'interposizione di una pellicola uniforme, sottile e compatta di vernice sui monconi del modello. Importante che questa lacca spaziatrice venga posizionata direttamente sui monconi del modello, a esclusione dei margini di chiusura, in modo e con spessori adeguati a seconda del-

le diverse aree del moncone così da creare un gap che dovrà permettere l'accoppiamento passivo delle fusioni sugli abutment stessi. Attenzione, però, allo spessore che, se fosse troppo consistente, rischierebbe di far perdere alla corona protesica ritenzione e stabilità.

È consigliabile utilizzare i die-spacer con i diluenti appositi, se si considera che, aprendo più volte la confezione, è inevitabile l'evaporazione dei componenti più volatili con conseguente addensamento del prodotto, e che i vari componenti tendono a separarsi e a non ricomporsi neanche con l'agitazione della bottiglietta.

### Saldatura laser

È una tecnologia recente, biocompatibile ed ergonomica, che è in grado di fondere due estremità metalliche attraverso la liquefazione simultanea del metallo sulle due superfici adiacenti e la loro successiva risolidificazione in un'unica struttura, così priva di tensioni<sup>45</sup>. Tale procedura, applicando ai manufatti una quota minore di energia, oltretutto localizzata solo nella zona di giunzione, ha il vantaggio di ridurre la loro possibile distorsione, assicurando una maggiore stabilità dimensionale e strutturale dei componenti saldati<sup>46</sup>.

Il laser, quindi, data la bassa quantità di calore che utilizza, può anche essere usato direttamente sul modello master garantendo una notevole precisione.

Un'ulteriore riduzione dei rischi di distorsione nasce anche dal fatto che le estremità metalliche da unire sono state preparate così da essere perfettamente combacianti per avere una saldatura accurata e precisa.

La resistenza della zona di saldatura risulta la stessa del metallo originale, in quanto viene preservata l'omogeneità dei materiali della travata, i quali possiedono solitamente una resistenza maggiore di quella del materiale utilizzato nelle saldature tradizionali (saldobrasatura, ossia con l'utilizzo, appunto, di un materiale da interposizione).

Altri vantaggi sono rappresentati dalla notevole riduzione dei tempi di lavoro, dall'assenza di fenomeni di corrosione o di porosità e dalla possibilità di eseguire riparazioni per lavori di recupero dei manufatti protesici (saldature secondarie, aggiunta di elementi protesici, saldature di attacchi, riparazione di ponti fratturati)<sup>47</sup>.

Possono essere saldate svariate tipologie di leghe metalliche con la saldatura laser, dato che il livello di penetrazione del suo fascio di luce può essere adattato al materiale scelto, anche se è preferibile che le leghe utilizzate siano omogenee per rendere più immediata la selezione della potenza da utilizzare. Per questo tale metodica è consigliabile specialmente quando le sovrastrutture protesiche sono in titanio, cosicché si realizza un'assoluta tollerabilità e un sicuro monometallismo (fixture, meso e sovrastruttura)<sup>48</sup>.

Perché si abbia una passivazione maggiore, è raccomandabile fondere le sovrastrutture per gli impianti e i manufatti protesici fissi in unità separate e poi saldarle mediante laser, dopo aver preso un'impronta di posizione per avere le corrette relazioni nel cavo orale (figura 1 a-d).

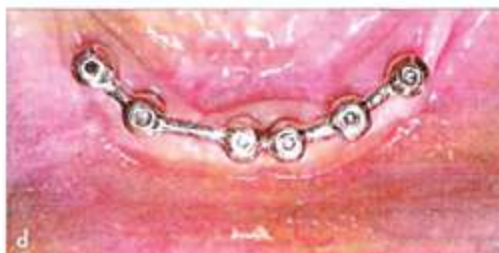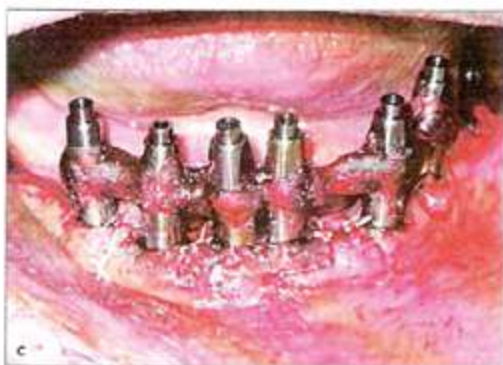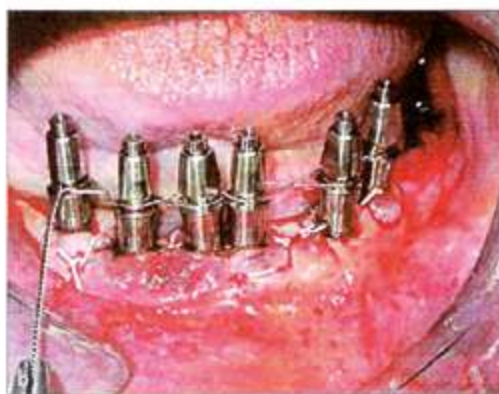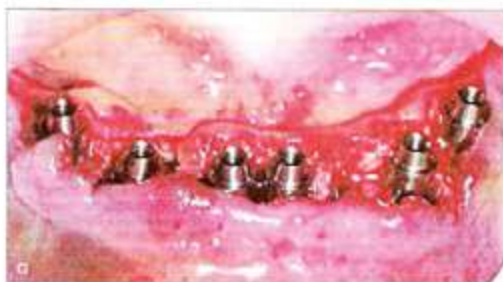### Elettroerosione

È un processo in uso nell'industria già da cinquant'anni, applicato in campo odontoiatrico nel 1982<sup>49</sup>. L'elettroerosione può essere definita come un processo di rimozione (erosione) del metallo che utilizza una serie di scintille per erodere materiale da un pezzo in lavorazione in un mezzo liquido, solitamente un olio fluido che viene chiamato fluido dielettrico, in condizioni accuratamente controllate. Il fluido dielettrico ha la funzione di isolante, conduttore e refrigerante e pulitore delle particelle metalliche asportate dalle scintille.

Per spiegare in che modo calore ed elettricità possano agire insieme per rimuovere particelle di metallo è stato proposto un modello termoelettrico, secondo il quale un singolo ciclo di elettroerosione inizia quando si applica un voltaggio crescente all'elettrodo mentre questo si avvicina al pezzo da lavorare. Si consideri che il campo è alla sua forza massima nel punto più vicino tra l'elettrodo e il pezzo da lavorare. Mentre il voltaggio aumenta, il fluido dielettrico inizia a decomporsi in particelle ionizzate che sono attratte verso la parte più intensa del campo elettrico, e al voltaggio massimo un numero crescente di particelle ionizzate si unisce creando uno stretto canale centrato nella parte dove il campo elettrico è più forte. Successivamente, quando si stabilizza la corrente e il voltaggio comincia a scendere, si ha un rapido accumulo di calore e tra l'elettrodo e il manufatto protesico da lavorare inizia a svilupparsi un canale di scarica, composto da fluido dielettrico termovaporizzato, attorno al quale si forma gradualmente una bolla a mano a mano che si accumula la quantità di materiale vaporizzato. Mentre la corrente continua ad aumentare, si crea nel canale di scarica un campo elettromagnetico molto intenso di ioni, che inibiscono l'espansione verso l'esterno della bolla di vapore. Intanto che la parte del metallo è vaporizzata dalla corrente intensa, la maggior parte del metallo che si trova al di sotto del canale di scarica resta allo stato fuso, tenuta in sede dalla pressione della bolla di vapore. Quando il ciclo è terminato e la corrente e il voltaggio scendono a zero, si ha una rapida diminuzione di temperatura che fa esplodere la bolla di vapore e consente l'espulsione del metallo fuso dal pezzo da lavorare, grazie all'azione del fluido dielettrico. Ciò che resta della bolla di vapore sale, quindi, alla superficie del fluido dielettrico mentre il metallo fuso espulso forma minuscole sfere solidificate disperse nell'olio.



IMPLANTOLOGIA ORALE NUMERO 5 NOVEMBRE 2005



1. Solidazione latera. Bara Decker costruita su 6 impianti Wörnick immediatamente caricati. **a.** Impianti appena inseriti con connetti dei monconi uniti, la cui altezza può essere scelta durante la fase chirurgica. **b.** Fase dell'imposta definitiva, in cui i transfer (anghi connessi ai monconi conet) vengono solidarizzati tra loro con un filo ortodontico a livello della loro scanalatura mediana. **c.** Fase dell'imposta definitiva, in cui la struttura metallica di solidificazione è coperta con la resina mediante la tecnica sale e pepe. **d.** Bara vista dall'alto. (Casistica: L. Presper, M. Chiarotadini, L. e R. Battaini, Udine)

Nel caso di protesi su impianti si deve sviluppare un modello particolare che consenta l'unione di tutti gli analoghi tramite un filo di rame che dovrebbe fuoriuscire dal modello e connettersi a un polo della macchina, mentre la parte protesica vera e propria verrà collegata all'altro polo. A questo punto, tramite un particolare programma computerizzato con potenze controllate, bisogna dare avvio al processo di elettroerosione, utilizzando al posto degli analoghi di lavoro speciali analoghi di rame. Così facendo, alla fine della lavorazione le femmine degli impianti avranno la loro sede ridefinita in una giusta posizione.

Questa tecnica è considerata di passivazione, perché permette di ottenere un accoppiamento di precisione tra le strutture metalliche di base e sovrastruttura, costituite da leghe e materiali di uso comune, purché siano buoni conduttori elettrici, correggendo le incongruenze presenti tra queste strutture protesiche che rischierebbero di portare a un disomogeneo e scorretto carico sulle fixture integrate<sup>30</sup>.

I vantaggi consistono nella possibilità di eseguire correzioni in caso di imprecisioni del modello master o dell'im-

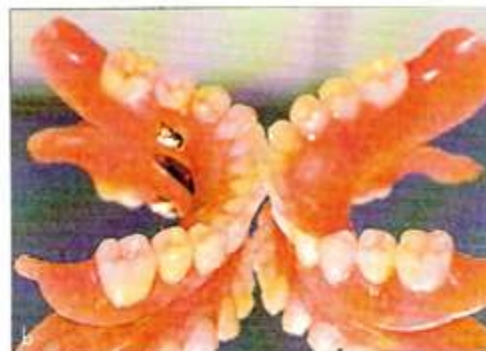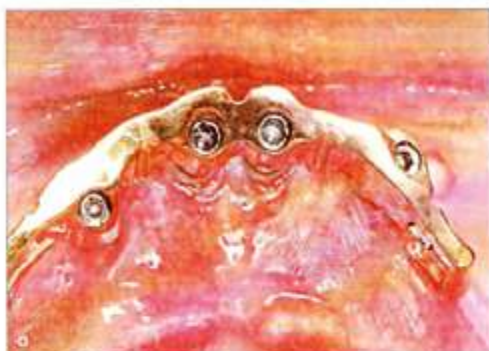pronta, nel poter effettuare correzioni in un secondo tempo dal rivestimento ceramico e nel non creare bimetallismo e corrosione tra metalli diversi (figura 2 a, b).

### Metodica Captek

Questa metodica è stata ideata e creata da Aharon White-man in collaborazione con Itzhak Shoher, rispettivamente odontotecnico e odontoiatra di Tel Aviv, dedicati alla ricerca nel settore dei metalli e delle ceramiche da oltre vent'anni. È una tecnologia che consente di realizzare elementi singoli o ponti estesi, sfruttando il principio dell'attrazione capillare chimica tra due diversi materiali metallici per produrre una struttura metallica estremamente precisa, con un'elevata resistenza alla corrosione, all'usura, agli stress e ai carichi, costituita da lega composita ad altissimo contenuto d'oro, addizionata a platino e palladio<sup>31</sup>.

Il processo di lavorazione è estremamente semplice, prevedendo l'applicazione di due strati per formare una cappetta; il primo strato (Captek P) è una lega a base di oro, platino e palladio che, dopo cottura, forma un reticolo molecolare microscopico; il secondo strato (Captek G), invece,





2. Elettrocoazione. a. Bona inferiore realizzata in elettrocoazione su 4 impianti Winix. La particolarità di questo caso è rappresentata dalla componentistica protesica Winix, appositamente realizzata per l'elettrocoazione (SAED). b. La protesi definitiva a disassibili non è altro che la replica della provvisoria, che soddisfa il paziente da un punto di vista funzionale, estetico e fonetico. (Casistica: L. Prosper, M. e S. Soncogni, Bergamo)

è una lega ad alto contenuto d'oro, che, una volta cotta, viene attratto nel primo strato per capillarità, formando una struttura unica, di colore giallo oro, costituita per l'88% da oro, per il 9% da platino e per il 2,3% da argento. Il metallo composito così ottenuto ha margini e spessori inferiori alle tradizionali leghe per ceramica<sup>32</sup>.

Alcuni studi<sup>33</sup> hanno dimostrato, tra le eccezionali caratteristiche chimico-fisiche del materiale, l'alta concentrazione d'oro (88%), la notevole resistenza alla frattura, l'elevata resistenza alla corrosione, nonché l'altissima biocompatibilità e la resistenza all'attecchimento batterico. Nei test eseguiti dopo che è stato comparato un impianto in titanio con uno in Captek, i risultati hanno dimostrato che l'osso con il Captek cresce direttamente sull'impianto senza alcuna interposizione di tessuto connettivo e che l'organismo non riconosce il Captek come elemento estraneo.

Il Captek si contraddistingue per avere due caratteristiche importanti per l'operatore: da un lato la facilità di utilizzo e dall'altra la possibilità di intervento sulla struttura metallica anche a fusione avvenuta. Permette facilmente tutti i passaggi di controllo usati di consuetudine nella metallo-ceramica e, se eseguito a regola d'arte, dà manufatti estremamente precisi anche dopo la ceramizzazione. Possiede un'estetica eccellente grazie al suo colore giallo oro. Infine, ha una coesione con la ceramica data non dagli ossidi (unione chimica), ma dalle forze di coesione presenti dopo la cottura, cosicché si annullano le tensioni che inevitabilmente si creano nella metallo-ceramica<sup>32</sup>.

Da un punto di vista metallurgico, le principali proprietà del Captek sono la maggiore stabilità rispetto agli altri metalli, intesa come resistenza alla distorsione dopo la cottura della ceramica; la possibilità di applicare sulla sua superficie qualunque spessore di ceramica, in quanto quest'ultima

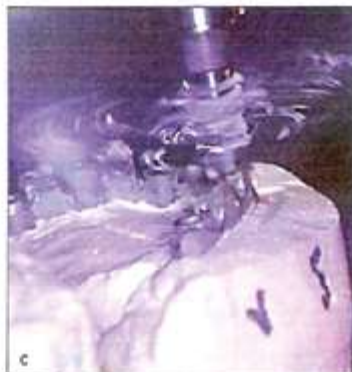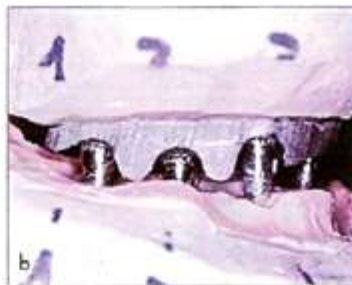non è messa in tensione dal metallo, ma al contrario ne viene messa in compressione; la possibilità di fare connessioni sempre in materiale Captek e non delle saldature, eliminando l'ulteriore rischio di distorsioni e retrazioni dimensionali; un'unione più forte della ceramica stessa grazie al legame metallo-ceramica non dato dagli ossidi; la resistenza ai carichi dei ponti fino a tre volte superiore rispetto ai tradizionali; l'altissima biocompatibilità, con valore INE addirittura superiore a quello dell'oro puro.

### Metodica Cresco-Ti

Questa metodica consiste in una tecnica computerizzata che passivizza la travata in titanio attraverso tagli della sovrastruttura protesica e successivo riassetto mediante saldature laser al fine di eliminare qualsiasi tensione all'interfaccia implantoprotesica<sup>32,34</sup>.

La procedura prevede dapprima la registrazione dell'arco facciale del paziente e la realizzazione del modello master con inserimento degli analoghi di laboratorio e la modellazione in cera della struttura. Successivamente, dopo la realizzazione della monofusione in titanio secondo la tradizionale tecnica della cera persa, la struttura metallica deve essere provvisoriamente posizionata sul modello master, avvitandola in due o tre punti agli analoghi degli impianti. In questa fase, in cui si potrebbero osservare le eventuali imprecisioni presenti, bisogna stabilizzare la struttura al modello master con della cera, rimuovere le viti di ritenzione e fissare con gesso il modello e la struttura metallica su un apposito verticalizzatore, in modo da mantenere costanti le relazioni verticale e orizzontale. Si procede, poi, separando il fissaggio in cera tra le diverse unità e la monofusione e avvitando strettamente dei cilindretti prefabbricati in titanio agli analoghi degli impianti. In questo mo-

IMPLANTOLOGIA ORALE NUMERO 5 NOVEMBRE 2005



3. Sistemistica Cresco a. Macchinario. b. Modelli fissati in verticale con i cilindretti prefabbricati in titanio connessi agli analoghi degli impianti. c. Taglio di precisione dei cilindretti implantari e della base della fusione della mesostruttura. (Per gentile concessione del dottor Calderini)

do la chiusura marginale delle strutture è determinata industrialmente.

Dopo la preparazione del modello bisogna procedere all'esecuzione del taglio di precisione dei "bridge support" implantari (cilindretti) e della base delle fusioni della mesostruttura per l'ottenimento di un corretto parallelismo degli assi di inserzione dei singoli impianti. Tale esecuzione è guidata da un apposito macchinario computerizzato in grado di valutare con precisione il corretto parallelismo che si desidera ottenere. In questo modo la protesi può essere posizionata passivamente sulle superfici tagliate dei cilindretti del modello master e successivamente saldata mediante laser, mantenendo sempre la stessa dimensione verticale inizialmente stabilita.

Le misure dei gap ottenute con le protesi tagliate con questa metodica di passivazione hanno dato valori prossimi allo zero (5 µm), dimostrando che non dovrebbero esserci tensioni statiche evidenti sulle protesi dopo il fissaggio delle viti<sup>55,56</sup>.

Questa metodica, che può essere utilizzata sia con protesi avvitate sia con strutture protesiche cementate, soddisfa i

requisiti di semplicità, accuratezza, efficienza, possibilità di correzione di misfit tra il framework in titanio sul modello e gli impianti dentali<sup>42</sup>.

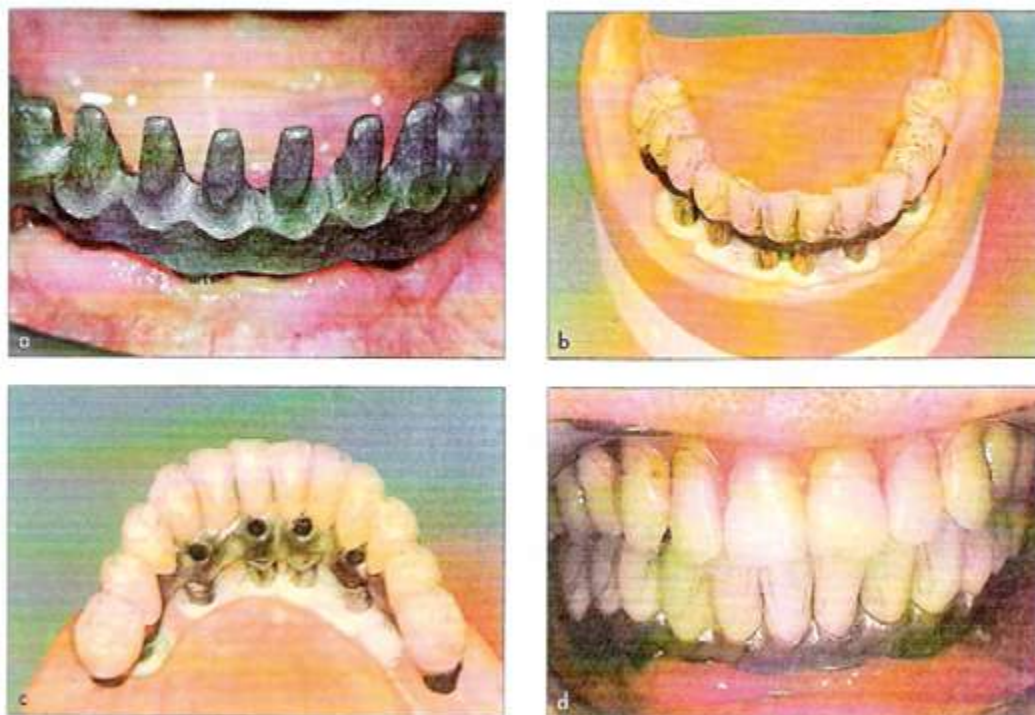Inoltre, il contatto diretto tra le superfici che devono essere assemblate offre un prerequisito ottimale per una saldatura ideale<sup>57</sup>. Si abbia presente, però, che la metodica Cresco-Ti Precision non riesce a compensare gli errori dovuti a rilevamenti alterati delle impronte nel cavo orale (figura 3 a-c).

### Procera All-in-One

È una sistemistica utilizzata per produrre travate metalliche parziali e totali mediante la tecnologia CAD-CAM, che rappresenta un'alternativa alla tecnica della fusione a cera persa. Comprende, quindi, i passaggi di:

1. lettura digitalizzata con uno scanner laser della travata in materiale acrilico confezionata dal tecnico, secondo le caratteristiche da noi richieste per risolvere il caso, e della posizione degli impianti sul modello in gesso realizzato con la gengiva morbida rimovibile (fase CAD, Computer Aided Design);





4. All-in-One. Metodica implant-bridge. a. Prova dell'armatura grezza. b, c. Toronto-bridge montata sui modelli. d. Prova estetica del lavoro superiore e inferiore nel cavo orale. (Caristica: L. Prosepe, T. D'Alcandro, Pescara).

2. fresaggio in materiale metallico ricavato dal pieno (solitamente lega di titanio o zirconio, fase CAM, Computer Aided Manufacturing) della copia della nostra struttura in resina accoppiata fedelmente alle fixtute del modello, dopo aver inviato la lettura in Svezia alla Produzione della Nobel Biocare tramite mail (Karlskoga/SWE).

Successivamente la travata All-in-One viene consegnata al laboratorio, dove già alla prima osservazione ci si può accorgere che la seduta è ottimale e che sono assenti attriti. Il produttore stesso garantisce un gap marginale intorno ai 20  $\mu\text{m}$  sul piano verticale e intorno ai 30  $\mu\text{m}$  sul piano orizzontale<sup>38,39</sup>.

La ripetibilità delle procedure e la semplicità con cui è possibile ottenere costantemente strutture dal fit assolutamente passivo consentono al professionista di razionalizzare i tempi del trattamento, ergonomizzare la terapia ed evitare la gestione di problematiche legate a strutture imprecise. Inoltre il manufatto protesico che si ottiene è estremamente solido per la mancanza di saldature, dovuta alla tecnica di sottrazione da un unico pezzo (figura 4 a-d).

### Elettrodeposizione galvanica

Questa tecnica, che permette di realizzare una sottostruttura metallica tramite processi di elettrodeposizione controllata di liquido di oro puro al 99%, nonostante sia in uso da diversi anni, solo di recente viene utilizzata in modo abituale in campo odontoiatrico, da quando è stato ritirato dal mercato il cianuro di potassio come elettrolita, un materiale altamente tossico sia per l'operatore che per il paziente<sup>40,41</sup>.

L'elettrodeposizione è effettuata sui modelli in gesso duplicati, ai quali è applicata una vernice argentata elettroconduttrice, mentre la galvanizzazione si esegue con un'apposita apparecchiatura elettronica che permette di ottenere cappette di spessore uniforme da 0,1 a 0,4 mm.

Inizialmente l'elettrodeposizione galvanica era nata per costruire semplici elementi singoli, mentre attualmente è impiegata per realizzare anche manufatti più complessi, quali corone eseguite direttamente su abutment, strutture portanti elementi mancanti, elementi ritenitivi su barre fresate e corone doppie frizionanti intermedie<sup>42,43</sup>.

I vantaggi della tecnica sono rappresentati dall'eccellente estetica dei manufatti protesici grazie al colore caldo della

IMPLANTOLOGIA ORALE NUMERO 5 NOVEMBRE 2005

sottostruttura metallica, dall'elevata precisione marginale, che prevede gap di 18  $\mu\text{m}$ <sup>64</sup> dalla realizzazione semplice e riproducibile, dall'elevato grado di biocompatibilità del materiale metallico utilizzato e dalla riduzione dei passaggi di lavoro; mentre gli svantaggi sono costituiti dalla difficoltà nella realizzazione di strutture estese e dagli alti costi iniziali dell'attrezzatura<sup>65</sup>.

L'esecuzione di sovrastrutture protesiche o di elementi di ponte con la galvanoplastica si può ottenere con diverse metodiche: la monogalvanizzazione, la sopragalvanizzazione, la cementazione o la tecnica IGB (*Intermediate Galvanocrown Bonding*).

La monogalvanizzazione fornisce come risultato un monoblocco galvanizzato, il cui spessore viene scelto dall'operatore che lo programma. I passaggi richiesti dalla tecnica sono: l'esecuzione di un modello master di precisione; il suo immediato sezionamento a livello degli abutment e della sella dell'elemento intermedio; la duplicazione del modello sezionato con un apposito silicone di precisione e un gesso specifico per l'esecuzione di galvanocrown, ossia con un'espansione estremamente ridotta rispetto ai gessi tradizionali; l'eliminazione degli eventuali sottosquadri; l'applicazione della lacca spaziatrice; la realizzazione di due modellini, uno per il passaggio di pregalvanizzazione su cui si modella l'elemento intermedio, collegandolo agli elementi pilastro tramite un anello di cera posto nel terzo medio, e uno per la galvanizzazione stessa; l'imperniatura, la fusione e la rifinitura della struttura, da realizzarsi con lega necessariamente ceramizzabile ad alto contenuto d'oro, sul primo modellino; una prima sabbatura, l'ossidazione e una seconda sabbatura; il trasferimento sul secondo modello, il cui zoccolo è stato ridotto al minimo per una più semplice lettura dell'apparecchio, e i cui spigoli taglienti sono stati corretti per evitare eventuali contaminazioni del bagno galvanico. È anche importante che questo secondo modello sia stato asciugato a temperatura ambiente per almeno due ore e che sul suo zoccolo si crei un canale lungo 2-3 mm, sul quale attaccare la barra di contatto in rame con cianacrilato. La barra in rame è sempre singola, anche se varia il numero degli elementi da galvanizzare.

A questo punto i monconi devono essere ricoperti con uno strato omogeneo di lacca conduttrice a base di argento e collegati alla barra di rame fino al limite della preparazione per poter essere introdotti nell'apparecchio per il processo di galvanizzazione. Si tenga conto che l'elemento intermedio, essendo di metallo, è già elettroconduttore. Il risultato finale della galvanizzazione, il cui spessore programmato dall'operatore è di circa 0,2 mm, è un monoblocco comprendente sia gli elementi pilastro che quelli intermedi. Gli step successivi della procedura com-

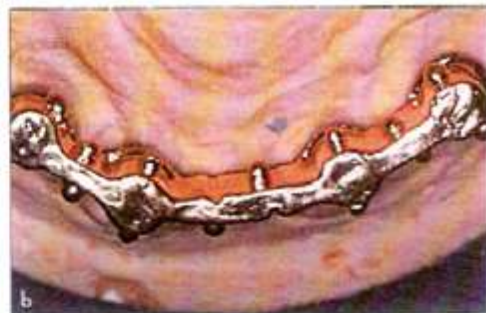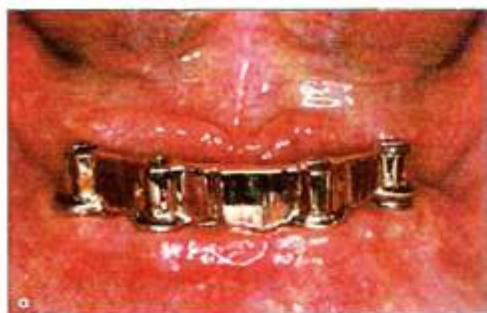prendono la pulitura del manufatto dal gesso e dalla lacca argentata, la riduzione del margine sovracontornato con gomme abrasive a ruota, la prova nel cavo orale, la sabbatura degli elementi galvanizzati, la cementazione della struttura ottenuta, la spennellatura della stessa con il bonder Auro-Galva-Crown (AGC) per creare un'adesione ottimale del metallo alla ceramica, una cottura dopo un periodo di asciugatura abbastanza lungo, e la ceramizzazione. Vantaggi di questa metodica sono l'estrema stabilità del manufatto, l'ottima resistenza durante le fasi di cottura della ceramica e la possibilità di modellazione di un'ottima struttura di sostegno per la ceramica; l'unico svantaggio è rappresentato dall'elevato costo delle attrezzature.

La sopragalvanizzazione, a differenza della precedente, prevede l'iniziale galvanizzazione solo degli elementi pilastro e poi, dopo la calzata sul modello master, la modellazione in cera della struttura comprendente l'elemento intermedio per la fusione a cera persa, a temperature che (ovviamente!) non danneggino le cappette elettrodepositate. Infatti, la maggior difficoltà di questa tecnica è legata alla particolare attenzione che il tecnico deve prestare in tutte le fasi della lavorazione, specialmente durante la fusione per non indebolire le galvano e durante la smuffatura del rivestimento per non deformare e compromettere i bordini. I vantaggi offerti da questa seconda possibilità di elettrodeposizione galvanica sono rappresentati dai costi ridotti e dalla relativa semplicità di esecuzione.

Anche la cementazione è simile alla sopragalvanizzazione, dalla quale si differenzia durante la fusione, nel senso che si procede alla fusione solo della struttura modellata e non più delle galvano precedentemente ottenute. Inoltre, la modellazione in cera della mesostruttura prevede non solo quella degli elementi intermedi, ma anche quella dei braccetti che avvolgono i pilastri forniti di un appoggio occlusale (tipo gancio fuso) al fine di ottenere una maggiore stabilità durante la cementazione successiva, che avverrà sul modello, tra le corone galvaniche e la fusione. Durante questo passaggio è importante usare cementi particolari, capaci di sopportare temperature fino a 970 °C, in modo tale da mantenere la stabilità della struttura protesica durante la fase di ceramizzazione. Tra i vantaggi di questa metodica sono da annoverare la facilità di esecuzione e i costi decisamente contenuti, mentre tra gli svantaggi le possibili distorsioni della struttura in fase di cementazione, comunque trascurabili se si seguono con scrupolosa attenzione i diversi passaggi tecnici durante la lavorazione.

Infine, tra le tecniche di elettrodeposizione galvanica c'è quella IGB o di Bush e Heckenopon<sup>66</sup>, molto utilizzata in impianto protesico, che prevede l'impiego di tre componenti, primaria, secondaria e terziaria, rappresentati rispetti-





5. Elettrodeposizione galvanica. a. Barra fresata in visione frontale. b. Controbarra elettrodeposta autogalvanica posizionata sulla barra fresata in visione occlusale.

vamente dall'abutment fresato in titanio, dalle AGC e dalla struttura metallica. La passivazione dell'impianto, ottenibile in questo caso con maggior sicurezza, è assicurata, oltre che dalla buona precisione di chiusura a livello coronale delle AGC, dalle loro caratteristiche di adattabilità strutturale, in quanto una volta cementate alla parte terziaria direttamente nel cavo orale saranno ulteriormente ridotte quelle tensioni ancora presenti in qualunque sistema già passivato sul modello.

Il principio tecnico dal quale prende spunto questa metodica è quello delle corone doppie che già da molto tempo vengono utilizzate nella protesi mobile sui denti naturali. Sono stati Buch e Heckendon<sup>6</sup>, nel 1995, con un lavoro dal titolo "la corona doppia frizionante intermedia nella protesi implantare" ad applicare il concetto anche all'implantoprotesi.

La procedura richiede la realizzazione degli abutment fresati in titanio, quindi la realizzazione di cappette galvaniche con uno spessore di 10 µm in oro puro 24 K al 99% con apparecchiatura elettroformatrice, la disposizione delle cappette ottenute sul modello master, il rivestimento delle stesse con un corretto spessore di die-spacer, la modellazione della sovrastruttura metallica che verrà fusa in monoblocco, la rifinitura della travata ottenuta in monoblocco, la rifinitura della travata ottenuta in modo tale che il suo rapporto con le galvano risulti privo di frizioni dannose e la cementazione delle galvano precedentemente realizzate alla terziaria direttamente nel cavo orale del paziente, con cementi compositi o vetroionomerici. Alla fine, dopo la detersione della protesi dalla glicerina utilizzata per la cementazione, tutta la struttura (travata metallica ceramizzata e AGC) è semplicemente riposizionata sui monconi, senza necessità di alcun mezzo di fissazione, in quanto la precisione delle cappe eseguite in elettrodeposizione garantisce una frizione ritentiva ottimale.

Da considerare che la travata metallica in lega nobile è cementata in modo da ottenere uno spazio virtuale tra cappa AGC e travata utile per la cementazione. L'esperienza clinica ha dimostrato che conviene eseguire una sola prova strutturale per evitare di danneggiare la cappa in fase di rimozione; sarà poi la protesi autoceramica a essere provata sopra i monconi portanti le autogalvaniche, una volta terminata la fase di laboratorio, per risolvere eventuali modifiche anatomiche o occlusali.

Si ricordi che questo tipo di protesi, rimovibile da parte del paziente, è mantenibile sostituendo ex novo, grazie alle procedure standardizzate appena descritte, le corone frizionanti quando andranno incontro a una perdita di resilienza.

La capacità di passivazione di questa tecnica dipende dall'elasticità e dalla possibilità di adattamento della struttura aurea (figura 5 a, b).

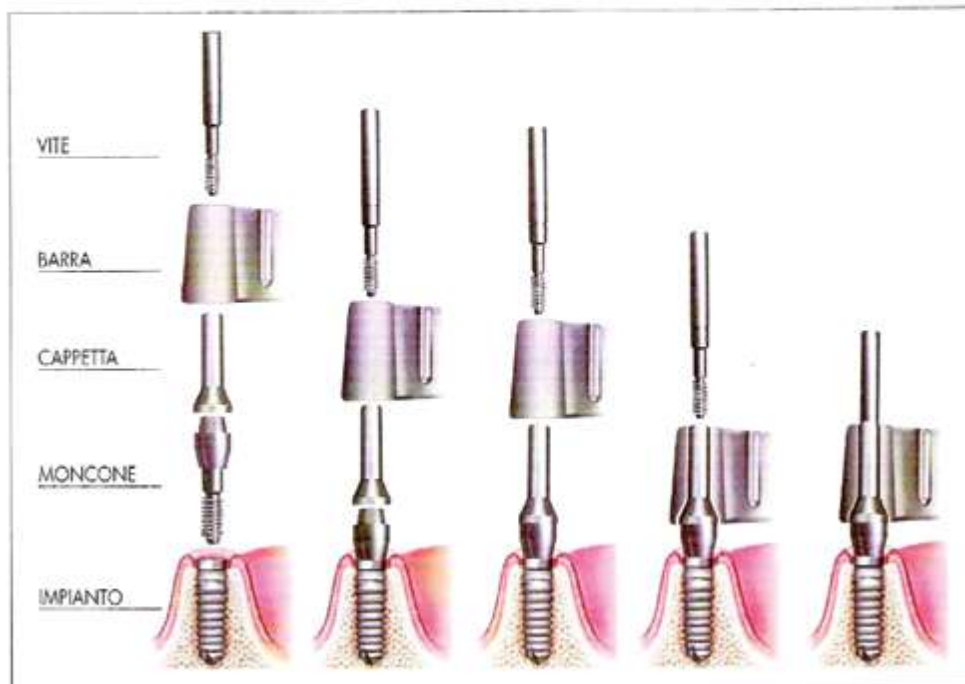
### Tecnica Winsix Free Tense System

Il Free Tence System<sup>TM</sup>, presente sul mercato dal 1994, specifico della sistematica implantare Winsix (Winsix<sup>®</sup> Ltd, London, UK), per risolvere gli inconvenienti della non perfetta adattabilità della mesostruttura protesica alle unità implantari, sia in protesi avvitata sia nelle barre a sostegno di protesi rimovibile, prevede la cementazione delle cappe di passivazione in titanio posizionate su monconi conici alla barra direttamente in bocca con la fondamentale eliminazione delle variabili cliniche e di laboratorio.

Nonostante la metodica sia utilizzata dal 1998, a oggi non sono ancora stati eseguiti studi prospettici a medio-lungo termine sul successo clinico di questa terapia protesica e/o comparativi con altre sistematiche di costruzione di sovrastrutture implantari, ma a nostro avviso e secondo le ricerche di tutto il teamwork della Winsix (che ha realizzato oltre 230 casi), la metodica Free Tense offre innumerevoli vantaggi: semplicità nel protocollo di lavoro, alloggiamen-



IMPLANTOLOGIA ORALE - NUMERO 5 NOVEMBRE 2005



6. Free Tense®. Schema delle componenti protesiche che caratterizzano la sistemica Wisio: impianto, moncone (omia), cappetta Free Tense® da adattare alla barra, barra, vite di serraggio.

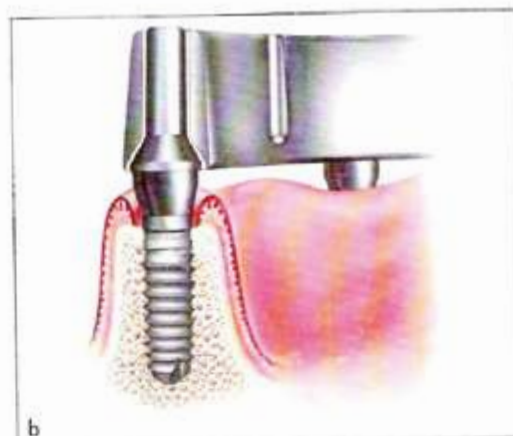
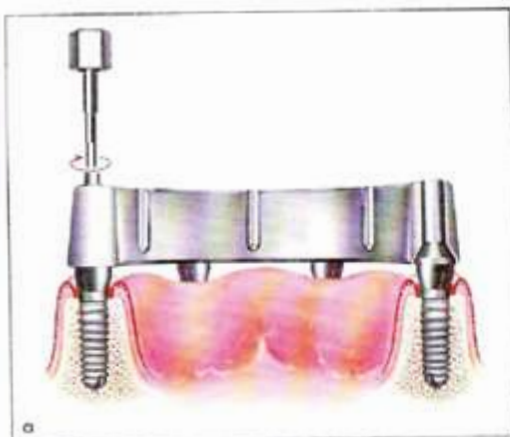to "dolce" e preciso del manufatto protesico sugli abutment, così contenuti per la realizzazione e comfort per il paziente (figura 6).

Come per ogni lavoro implantoprotesico, il protocollo inizia con il rilevamento di una prima impronta in materiale con tecnica indiretta con cucchiaio standard, quindi prosegue con il rilevamento di una seconda impronta con tecnica diretta tipo pick-up, con il portaimpronta individuale forato, ricavato dalla precedente impronta in polietere o gesso da impronta di precisione, e con la registrazione oclusale e con la colatura dei modelli e il loro montaggio in articolatore.

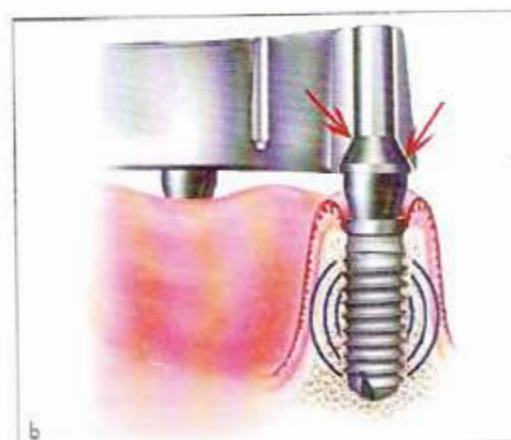
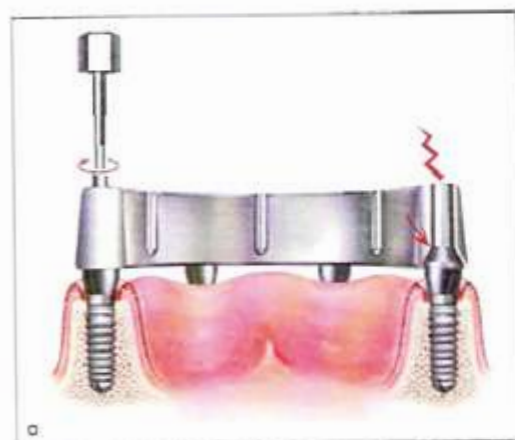
A questo punto, in laboratorio, da un lato vengono montati i denti in resina su una placca base per la prova dell'estetica, della fonazione e dell'occlusione della protesi totale (da effettuarsi nel cavo orale del paziente), e dall'altro vengono posizionate sul modello, dove sono inclusi già gli analoghi conici (conicità di 6°), le corrispondenti cappette Free Tense in titanio con le loro viti oclusali. Per l'adattamento dell'altezza della vite oclusale e della cappetta si devono considerare come riferimento l'altezza e lo spessore decisi per l'estetica finale della protesi. Inoltre, le cap-

pette e le viti devono essere tagliate, preferibilmente una volta montate su un analogo corrispondente, con una fresa separatrice da 0,2 mm di diametro, e rifinite con un gommino, facendo attenzione a non surriscaldare il titanio. Successivamente, le cappette adatte devono essere riposizionate sul modello, visionandole con la mascherina di riferimento, sabbiate con ossido di alluminio a 150 µm a pressione di 6 atm, avendo avuto cura di proteggere il loro colletto con cera collante che verrà eliminata con vapore ad alta pressione, prima di passare alla ceratura della barra con cere idonee a lavori di precisione, previa applicazione sulle cappette Free Tense di una lacca spaziatrice con uno spessore di 50-70 µm, la quale dovrebbe assorbire le distorsioni dimensionali che si possono creare durante il ciclo di lavoro.

Prima di esaminare il fit passivo della barra duplicata in resina sui monconi, gli Autori consigliano di parallelizzare gli eventuali monconi fuori asse, per mezzo di un calcinabile, in modo che l'inserzione della barra sia il più possibile funzionale all'estetica prescelta per la protesi. Poiché dopo la rifinitura della barra in resina si potrebbero riscontrare spessori minimali di 0,2 mm, difficili da riprodurre in fu-



7. a, b. Prova di Sheffield positiva: avvitando una delle viti distali della barra, l'adattamento della stessa è passivo.



8. a, b. Prova di Sheffield negativa: avvitando una delle viti distali della barra, si crea una tensione tra la cappetta e la barra all'eccentricità sinterotatale che si propaga anche nell'osso periimplantare.

22

sione, gli Autori propongono, inoltre, di ispessire queste superfici, per riportarle allo spessore originale solo a fusione ultimata.

In seguito, in una fonderia viene eseguita la fusione della barra con la lega composta Talladium (Talladium, Inc), poi si rifinisce rettificandola nuovamente a 2° e lucidandola, e vengono sabbati i monconi e l'interno della struttura metallica per aumentare l'azione ritentiva del cemento. A questo punto, finalmente il manufatto è pronto per la cementazione nel cavo orale del paziente, previo controllo dell'assenza di qualsivoglia tensione tra la barra e i monco-

ni. L'adattamento passivo dell'armatura viene valutato dagli Autori attraverso i tre parametri clinici utilizzati anche da altri studi clinici sulla passivazione<sup>67</sup>: assenza di sensazioni di tensione o di dolore durante l'inserimento; chiusura finale di tutte le viti con al massimo un terzo di giro senza incontrare alcuna resistenza; controllo dell'adattamento della barra con una singola vite in posizione distale ed esame ispettivo con occhiali di ingrandimento dell'accomodamento dei restanti pilastri dove possibile, oppure con radiografie endorali quando la giunzione moncone-cappetta è subgingivale (figure 7 a, b; 8 a, b).

Durante il processo di cementazione con il Panavia (Kuraray), è importante che si evitino contaminazioni delle superfici interessate con le mani o con l'umidità. Gli Autori suggeriscono anche di ricoprire con un sottile strato di vaselina le viti occlusali delle cappette Free Tense per evitare che il cemento rimanga attaccato a esse, e di cementare le cappette alla barra una a una, seguendo le istruzioni date dalla ditta per quanto riguarda la miscelazione del cemento e la tempistica di adesione e considerando che lo spessore del cemento, per evitare fratture al suo interno, dovrebbe essere minimale, idealmente mantenuto tra 0,1 e 0,3 mm.

Una volta cementata l'armatura, per aver un'ulteriore registrazione dell'occlusione la protesi viene fissata alla barra con la resina. Quindi, in laboratorio, si completa il confezionamento della protesi totale secondo le linee di guida occlusali prescelte (ad esempio Gerber) dopo aver fissato la nuova occlusione sui modelli, rifinito e modellato lo scheletrato della travata, fuso tale mesostruttura sempre in Talladium, e montato i denti secondo le indicazioni della mascherina iniziale.

Ultimamente, dopo la cementazione della barra ai conici, gli Autori preferiscono puntare al laser gli accoppiamenti ottenuti con il Panavia per eliminare la variabile di possibile decentramento nel tempo (figure 9 a-l; 10).

#### METODI CLINICI DI VALUTAZIONE DEL GRADO DI PASSIVITÀ DI UNA PROTESI IMPLANTOSUPPORTATA

Come si è ampiamente spiegato nel corso di questa trattazione, un problema di estrema attualità in campo implantologico è costituito dall'adattamento passivo della sovrastruttura protesica agli impianti, soprattutto nel caso di protesi avvitate, per poter meglio garantire il successo implantare e protesico a lungo termine.

A tutt'oggi non esiste ancora una modalità universalmente accettata per valutare

**WINSIX<sup>®</sup> IMPLANT SYSTEM**

**WINSIX<sup>™</sup> Ltd**

**WINSIX  
un incontro  
esclusivo**

**BioActive Covering<sup>™</sup>**  
Trattamento di superficie  
a sabbatura differenziata.

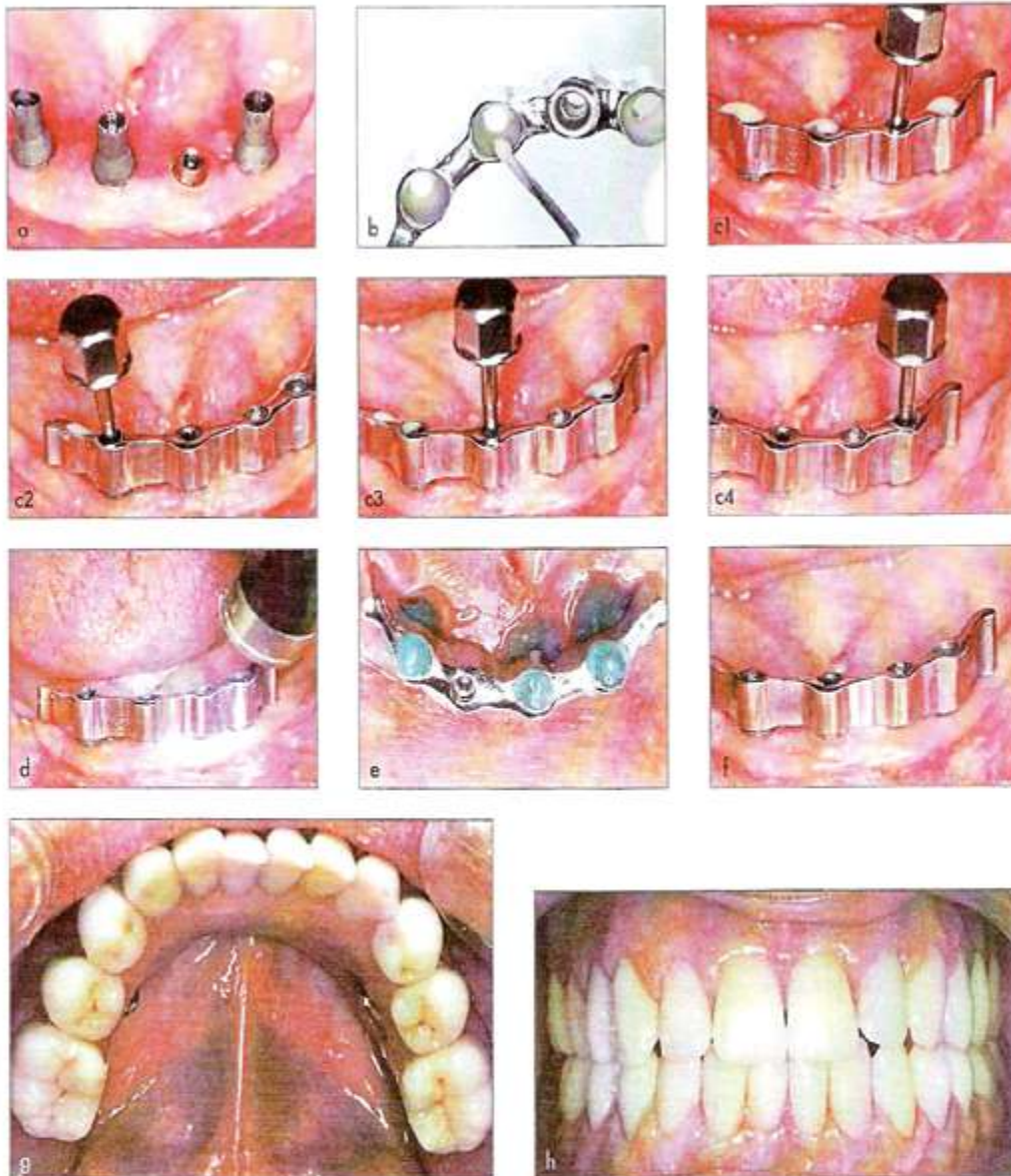
**Free Lock<sup>™</sup>**  
La connessione  
nel perfetto equilibrio di forze  
tra impianto e monconi.

**Free Tense System<sup>™</sup>**  
La protesi avvilita  
senza tensioni.

Esclusivo

**BioB.A.F. S.r.l.**  
Codice legale: Via Isonzo, 8 - 20090 AZZIAGO (VI)  
Tel. +39 02 40969 - Fax +39 02 4988330  
Sede operativa: Via Destefani, 24 - 45035 CASTELMAGNA (MO)  
TEL. +39 0425 647333 - FAX +39 0425 640303  
Internet: www.bio-baf.com - Email: info@bio-baf.com





9. Sistemistica Free Tense<sup>®</sup>, Wintec. a-f. Cementazione clinica della barra con un cemento resinoso (Panavia). Si noti che un menzzone conico è stato inserito nella fessura delle barre per fare da guida, essendo perciò il primo a essere avvitato e a bloccare in sito la barra. Si consiglia di avvitare le altre viti in modo insequenziale partendo da un'estremità distale. g, h. Caso finito. (Cattalini: L. Protopop, M. Sotgiorni, S. Sotgiorni, Bergamo)

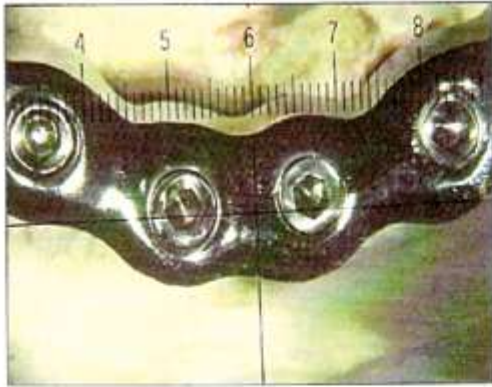
clinicamente il fit della struttura protesica. Henry<sup>25</sup> nel 1987 ha suggerito l'impiego di una pressione digitale alternata, mentre altri Autori<sup>26</sup> consigliano l'esplorazione tattile diretta, passando uno specchio sui margini della ricostruzione protesica. Jemt<sup>26</sup> ha suggerito il test della vite singola, già proposto dal professor White di Sheffield, che prevede il serraggio della vite di uno dei due abutment dista-

li e quindi l'osservazione delle eventuali discrepanze marginali che a quel punto si vengono a creare sugli altri pilastri. Altri Autori<sup>26</sup> ancora suggeriscono l'esecuzione di esami radiografici con centratori di immagine o l'impiego di paste rivelatrici di pressione (Fit Checker).

Entrando nello specifico, in caso di protesi cementata per valutare l'effettivo stato di passività delle strutture protesi-



IMPLANTOLOGIA ORALE NUMERO 5 NOVEMBRE 2005



10. Particolare della barra fotografata allo stereomicroscopio. Si noti l'accoppiamento tramite cementazione delle cappe Free Tense.

che, bisognerebbe pennellare all'interno delle corone un leggero strato di silicone o vernice idonea per precontatti: la protesi può essere giudicata passiva quando lo strato è omogeneo, forma una pellicola continua e non vi sono punti privi di silicone. Invece, in caso di protesi avvitata, il metodo clinico universalmente riconosciuto per valutare la passività della protesi è il test di Sheffield, che, come si diceva poco sopra, consiste nell'avvitamento di una sola vite a un'estremità della struttura: se questa non subisce alcun movimento, vuol dire che la struttura è passiva, intimamente e contemporaneamente in contatto con tutti gli impianti di supporto, in caso contrario la protesi subisce un effetto molla alzandosi nella parte opposta a quella dove è stata posta la vite. Se tutti gli abutment non fossero intimi agli impianti, avvitando la struttura si rischierebbe di obbligare l'impianto a uno spostamento sul piano orizzontale e verticale, compromettendo il processo di osteointegrazione in corso. Infatti, ricordiamo che per passivazione si intende l'annullamento di tutte quelle forze di trazione che si potrebbero trasmettere alle fixture allorché ogni vite viene serrata agli impianti per connettere una struttura imprecisa che causerebbe microspostamenti sul piano verticale e orizzontale mettendo a repentaglio l'osteointegrazione.

Di recente, comunque, è stata messa a punto una metodica computerizzata di monitoraggio del serraggio delle viti protesiche<sup>71</sup>, insita nel sistema OsseoCare<sup>TM</sup> della Nobel Biocare, per valutare oggettivamente il fit implantoprotesico. Essa prevede l'utilizzazione del motore con cui si posizionano gli impianti con un apposito manipolo protesico, il quale permette di avvitare le strutture protesiche con un torque predeterminato (da 20 Ncm a 32 Ncm), mentre il software elabora un grafico della fase di avvitamento in cui si interfaccia la forza di avvitamento stessa (sulle ordinate, espressa in Ncm) con i gradi di avvitamento delle vi-

ti di serraggio (sulle ascisse). Tale grafico, visualizzato sul display della macchina per gli ultimi 240° di avvitamento, viene registrato in una smart card che potrebbe essere scaricata su un computer in qualsivoglia momento tramite un apposito programma fornito dalla casa (MCRead - Nobel Biocare). Il grafico di un avvitamento ideale, ossia di una struttura passiva, prevede una fase di precarico della vite completamente inerte in virtù del buon accoppiamento delle strutture, e una successiva impennata della curva fino al raggiungimento del valore di torque predeterminato che dovrebbe avvenire nel minor range di gradi di avvitamento possibile. Range che teoricamente dovrebbe essere di circa 30°, ossia meno di un decimo di giro di avvitamento. Comunque, si possono considerare clinicamente passivi i serraggi che avvengono fino a circa 60°, ossia fino a circa a 1/6 di giro. Infatti, 1/6 di giro di avvitamento, considerando che il passo medio delle viti di serraggio è di circa 350 µm, significa una discrepanza marginale di circa 60 µm, clinicamente accettabile a livello internazionale. Al di sopra di tali valori l'avvitamento non è sicuramente passivo, ma il preload della vite serve ad accoppiare le superfici tra loro non competenti fino a farle combaciare completamente con il fessaggio finale della vite.

## DISCUSSIONE

Scopo di queste tecniche è garantire il miglior "accomodamento" possibile dell'implantoprotesi, visto che un adattamento controllabile e prevedibile è auspicabile per prevenire possibili complicanze meccaniche. Nonostante i sopracitati studi di Jemt abbiano dimostrato come in casi di edentulia totale possa esistere una certa tolleranza biologica per i maladattamenti della protesi in relazione a forze statiche nell'osso vivo<sup>72</sup> e come, se non si combinano le tensioni derivate dalla mancata passivazione con il carico occlusale, queste forze possano essere stimolanti per l'osso perimplantare, inducendo un rimodellamento osseo positivo<sup>73</sup>, tuttavia esistono in letteratura delle evidenze sul fatto che la mancanza di un buon adattamento della sovrastruttura sugli impianti determina un aumento del rischio di svitamento e/o frattura delle componenti meccaniche<sup>74</sup>. Tale rischio, ovviamente, sarebbe passibile di aumento qualora si sommassero carichi occlusali sproporzionati o non assiali, probabilmente alla base del fallimento degli impianti<sup>9</sup>.

Questa ipotesi sembra compatibile con la teoria "meccanostatica" elaborata da Frost<sup>75</sup> nel 1983, la quale afferma che l'osso reagisce al carico secondo le leggi meccaniche di deformazione indotta, e individua cinque soglie di carico, tutte misurate in microstrain (si tenga conto che l'1% di deformazione corrisponde a 10 000 microstrain):

1. soglia di atrofia da disuso, tra 0 e 200, intervallo in cui l'osso subisce una riduzione della sua massa;
2. soglia di rimodellamento, compresa tra 200 e 2500, range in cui l'osso mantiene inalterata la sua struttura e la sua massa;
3. soglia di ipertrofia, tra 2500 e 4000, condizione in cui il tessuto osseo reagisce al carico aumentando la propria massa e modificando la propria struttura;
4. soglia di sovraccarico, al di sopra di 4000, limite sopra il quale l'osso tende a riassorbirsi per la formazione di microcricche che indurrebbero fenomeni di riparazione e di indebolimento osseo;
5. carico acuto di rottura, tra 10 000 e 25 000, soglia sopra la quale l'osso si frattura.

Una delle fasi in cui potrebbe verificarsi un'alterazione dimensionale dell'adattamento dell'armatura metallica sugli impianti è la trasmissione della situazione clinica al modello di lavoro. L'impronta, infatti, è il principale mezzo di comunicazione tra lo studio e il laboratorio, avendo lo scopo di trasmettere tutte le informazioni necessarie per la realizzazione del manufatto protesico nel modo più preciso possibile. Essa rappresenta la verifica cruciale di tutto il lavoro preparatorio precedente alla riabilitazione protesica del paziente, dovendo fornire la lettura corretta della posizione degli impianti per cercare di "assorbire" tutti gli altri potenziali errori, non controllabili, del processo costruttivo che potrebbero inficiare il "perfetto" fit delle sovrastrutture metalliche sugli abutment. Non si dimentichi che la fixture osteointegrata presenta un alto grado di rigidità e una scarsissima resilienza, caratteristiche che sotto il profilo puramente protesico purtroppo si traducono in un difetto, richiedendo dei manufatti estremamente precisi sia nella componentistica che nell'anatomia, per distribuire equamente i carichi masticatori e garantire una resilienza minima.

Generalmente, per rilevare la posizione delle fixture si utilizzano dei falsi monconi di trasferimento (transfer), che devono essere avvitate alle fixture medesime, i quali possono rimanere inglobati nell'impronta (preferibile utilizzare un polietere - Impregum - come materiale) o essere successivamente riposizionati in essa, a seconda che si ricorra alla tecnica pick-up o a quella tradizionale. La prima, anche se più laboriosa per la lunga manipolazione all'interno del cavo orale che richiede, è preferibile per la grande precisione che garantisce il cucchiaino individuale forato, da cui devono sporgere le viti di fissaggio dei transfer, una volta posizionato il portaimpronta nel cavo orale del paziente per poter essere svitate e rimosse insieme al cucchiaino. Il secondo metodo, invece, nonostante sia di rapida esecuzione, può comportare errori di posizione nel momento in cui si riposizionano i transfer nell'impronta, dopo che il cuc-

chiaino tradizionale è stato rimosso dal cavo orale del paziente. In ambedue i casi, comunque, è necessario disporre di materiali dotati di buona stabilità dimensionale, di limitata contrazione termica, di limitata contrazione di indurimento, di grande rigidità, di ottima memoria elastica, idrofili, capaci di aderire fortemente a tutte le componenti metalliche, in grado di subire i piccoli maltrattamenti derivati dalla necessità di svitare i transfer a impronta non ancora rimossa, o di accoglierli con precisione se si utilizza il secondo metodo (Impregum Penta, 3M ESPE, Italia).

Il moncone per presa da impronta della Winsix presenta una connessione a esigono interno, molto corta e con una conicità di 6°, così da non alterare la rimozione del cucchiaino in caso di impianti non paralleli. Anche la lunghezza del transfer è quasi il doppio di quella normale, proprio per garantire che fuoriesca dal cucchiaino di resina e poterlo fissare con tecnica "sale e pepe" al cucchiaino stesso. Inoltre presenta due sfaccettature parallele contrapposte a 180° che, assieme a un bassorilievo circonferenziale, ne garantiscono la posizione all'interno del materiale da impronta.

La stessa perizia che è richiesta all'odontoiatra deve caratterizzare anche il lavoro dell'odontotecnico, che dovrà prestare la massima attenzione a ogni singola fase di lavorazione: dalla preparazione dei modelli in gesso alla ceratura, alla messa in rivestimento, alla fusione e alla saldatura. Nonostante questi procedimenti di lavorazione siano effettuati e realizzati con estremo controllo, sia da parte dell'operatore sia da parte dell'industria, ci sono, tuttavia, delle variabili che, se considerate singolarmente, sarebbero dimensionalmente influenti, sommate fanno sì che le realtà cliniche siano differenti da quelle di laboratorio, generando manufatti protesici talvolta imperfetti, in grado di produrre tensioni, le quali potrebbero essere la causa di innumerevoli fattori di insuccesso impiantoprotesico: svitamento delle viti di connessione impianto-moncone, frattura dei monconi o dell'armatura, riassorbimento osseo, perimplantiti o addirittura perdita dell'impianto stesso.

In ultima analisi, qualunque sia la metodica utilizzata, quello che conta è il risultato, ossia una sovrastruttura il più possibile priva di tensioni, poco importa se con le saldature al laser, l'elettrodeposizione, l'elettroerosione, la cementazione direttamente nel cavo orale. La cosa veramente importante è conoscere il problema e affrontarlo di volta in volta secondo le operatività meglio funzionanti nelle mani del clinico e del tecnico!

Gli Autori prediligono la tecnica Free Tence, la quale si pone la finalità di eliminare le tensioni intrinseche delle strutture protesiche sviluppate per effetto delle intolleranze di accoppiamento delle travate agli impianti, associando contemporaneamente la cementazione e l'avvitamento della mesostruttura, in modo che il cemento resinoso anaerobico



IMPLANTOLOGIA ORALE NUMERO 5 NOVEMBRE 2005

ottimizzi i rapporti tra i diversi componenti, riducendo gli elementi di tensione e aumentando la resilienza e l'elasticità. Inoltre, l'eliminazione della fase di saldatura è un ulteriore modo con cui la strategia Free Tense prova a ridurre le difficoltà di raggiungere in laboratorio l'adattamento del tutto passivo della barra sui monconi conici. Anche l'uso di elementi pre-lavorati a macchina è un altro vantaggio, in quanto i monconi e cappette Free Tense consentono una notevole resistenza meccanica e caratteristiche di modellazione precisa, garantendo così adattamenti superficiali migliorati rispetto ai monconi calcinabili. Infine, la solidarizzazione direttamente in situ delle cappette, mediante incollaggio con cemento resinoso anaerobico, secondo l'esperienza degli Autori, è un discreto modo di minimizzare e/o annullare gli stress dinamici, ma soprattutto statici, scaricati sugli impianti dalle sovrastrutture protesiche, in quanto elimina le imprecisioni provocate dai vari materiali usati per il trasferimento della situazione clinica su un modello. Inoltre tale metodica ha un'esecuzione molto semplice, se comparata ad altri sistemi più sofisticati sopra presentati, rivelandosi estremamente riproducibile anche per operatori poco esperti e socialmente proponibile per i costi decisamente contenuti.

#### Ringraziamenti

Si ringrazia la signora Sonia Locatelli per i disegni dell'articolo.

**Corrispondenza:** Loris Prosper  
via San Gottardo 84, 20052 Monza  
e-mail: lorisprosper@tin.it

## BIBLIOGRAFIA

- Lindquist LW, Rockler B, Carlsson GE. Bone resorption around fixtures in edentulous patients treated with mandibular fixed tissue-integrated prostheses. *J Prosthet Dent* 1988;59:59-63.
- Jaffin RA, Betman CL. The excessive loss of Brånemark fixtures in type IV bone: a 5-year analysis. *J Periodontol* 1991;62:2-4.
- Eugquist B, Bergendal T, Kallus T, Lindero U. A retrospective multicenter evaluation of osseointegrated implants supporting overdentures. *Int J Oral Maxillofac Implants* 1988;3:129-34.
- Lekholm U, Gunne J, Henry P, et al. Survival of Brånemark implant in partially edentulous jaws: a 10-year prospective multicenter study. *Int J Oral Maxillofac Implants* 1999;14:639-45.
- Esposito M, Thomsen P, Ericson LE, Lekholm U. Histopathologic observations on early oral implants failures. *Int J Oral Maxillofac Implants* 1999;14:798-810.
- Carr A, Gerardi D, Larsen P. The response of bone in primates around unloaded dental implants supporting prostheses with different levels of fit. *J Prosthet Dent* 1996;76:500-9.
- Quirynen M, Naert I, van Steenberghe D. Fixture design and overload influence marginal bone loss and fixture success in the Brånemark system. *Clin Oral Implants Res* 1992;3:104-11.
- Spielermann H. *Implantologie*. Stuttgart: George Thieme Verlag, 1994.
- Isidor F. Loss of osseointegration caused by occlusal load of oral implants. A clinical and radiographic study in monkeys. *Clin Oral Implants Res* 1996;7:143-52.
- Graci S. Considerazioni biomeccaniche e cliniche nella pianificazione delle protesi su impianti osteointegrati. *RIS* 1995;3:213-28.
- Jemt T, Lekholm U. Implant treatment in edentulous maxillae. A 5-year follow-up report on patients with different degrees of jaw resorption. *Int J Oral Maxillofac Implants* 1995;10:303-11.
- Adell R, Lekholm U, Rockler B, Brånemark PI. A 15-year study of osseointegrated implants in the treatment of the edentulous jaw. *Int J Oral Surg* 1981;10:387-416.
- Kallus T, Bessing C. Loose gold screws frequently occur in full-arch fixed prostheses supported by osseointegrated implants after 5 years. *Int J Oral Maxillofac Implants* 1994;9:169-78.
- Balshi TJ. Preventing and resolving complications with osseointegrated implants. *Dent Clin North Am* 1989;33:821-68.
- Rangert B, Jemt T, Jornerus L. Forces and moments on Brånemark implants. *Int J Oral Maxillofac Implants* 1989;4:241-7.
- Skalak R. Biomechanical considerations on osseointegrated prostheses. *J Prosthet Dent* 1983;49:843-8.
- Weinberg LA. The biomechanics of force distribution in implant-supported prostheses. *Int J Oral Maxillofac Implants* 1993;8:19-31.
- Jemt T, Lekholm U. Measurements of bone and framework deformations induced by misfit of implant superstructures. A pilot study in rabbits. *Clin Oral Implants Res* 1993;9:272-80.
- Fenton HA, Zarb GA. Research status of prosthodontic procedures. *Int J Prosthodont* 1993;6:137-44.
- Tan KB, Rubenstein JE, Nicholls JJ, Youdelis RA. Three-dimensional analysis of the casting accuracy of one piece, osseointegrated implant-retained prostheses. *Int J Prosthodont* 1993;6:346-63.
- Wasiewicz GA, Ostrowski JS, Parks VJ. Photoelastic analysis of stress distribution transmitted from a fixed prosthesis attached to osseointegrated implants. *Int J Oral Maxillofac Implants* 1994;9:405-11.
- Jemt T, Lie A. Accuracy of implant supported prostheses in the edentulous jaw. Analysis of precision between cast gold alloy frameworks and master casts by means of a three-dimensional photogrammetric technique. *Clin Oral Implants Res* 1995;6:172-80.
- Clelland NL, Carr AB, Glat A. Comparison of strains transferred to a bone stimulant between as-cast and postsoldered implant frameworks for five implant-supported fixed prosthesis. *J Prosthodont* 1996;5:193-200.
- Iglesia MA, Moreno J. Un metodo volto ad ottenere l'adattamento passivo nelle implantoprotesi: rapporto di un caso. *Int J Prosthodont* 2001;14:570-4 (versione italiana).
- Klineberg JJ, Murray GM. Design of superstructures for osseointegrated fixtures. *Sweed Dent J Suppl* 1985;28:63-9.
- Jemt T, Lekholm U, Johansson CB. Bone response to implant-supported frameworks with differing degrees of misfit preload: in vivo study in rabbits. *Clin Implant Dent Relat Res* 2000;2:129-37.
- Jemt T, Book K. Prosthesis misfit and marginal bone loss in edentulous implant patients. *Int J Oral Maxillofac Implants* 1996;11:620-5.
- Taylor TD. Is nonaxial loading harmful to the bone-implant interface of osseointegrated implants? *Int J Oral Maxillofac Implants* 1995;10:62.
- Schulte W. Implants and the periodontium. *Int Dent J* 1995;45:16-26.
- Rangert B, Gunne J, Sullivan DY. Mechanical aspects of a Brånemark implant connected to a natural tooth: an in vitro study. *Int J Oral Maxillofac Implants* 1991;6:177-86.

31. Cho GC, Chee WWL. Apparent intrusion of natural teeth under an implant-supported prosthesis: a clinical report. *J Prosthet Dent* 1992;68:3-5.
32. Lundgren D, Laurell L. Biomechanical aspects of fixed bridgework supported by natural teeth and endosseous implants. *Periodontol* 2000 1994;4:23-40.
33. Glantz PO, Nöner K. Biomechanical aspects of prosthetic implant-bone reconstructions. *Periodontol* 2000 1998;17:119-24.
34. Sekine H, Komiya Y, Hotta H, Yoshida K. Mobility characteristics and tactile sensitivity of osseointegrated fixture-supporting systems. In: van Steenberghe D (ed). *Tissue integration in oral maxillofacial reconstruction*. Amsterdam: Excerpta Medica, 1986:326-32.
35. Lindhe J, Karring T. Anatomy of periodontium. In: Lindhe J, Karring T, Lang NP (eds). *Clinical periodontology and implant dentistry*. 3rd edition. Copenhagen: Munksgaard, 1998:45-9.
36. Parfitt GJ. Measurement of physiological mobility of individual teeth in an axial direction. *J Dent Res* 1960;39:608-18.
37. Mish CE. Occlusal considerations for implant supported prostheses. In: Mish CE (ed). *Contemporary implant dentistry*. St Louis: Mosby, 1993:705-33.
38. Rächler EJ. In vivo horizontal bending moments on implants. *Int J Oral Maxillofac Implants* 1998;13:232-44.
39. Jacobs R, van Steenberghe D. Comparison between implant-supported prostheses and teeth regarding passive threshold level. *Int J Oral Maxillofac Implants* 1993;8:549-54.
40. Meriöke-Stern R, Assal P, Meriöke E, Burgin W. Occlusal force and oral tactile sensibility measured in partially edentulous patients with ITI implants. *Int J Oral Maxillofac Implants* 1995;10:545-53.
41. Hammerle CH, Wagner CH, Bragger U, et al. Threshold of tactile sensitivity perceived with dental endosseous implants and natural teeth. *Clin Oral Implants Res* 1995;6:83-90.
42. Helldén LB, Dérand T. Description and evaluation of a simplified method to achieve passive fit between cast titanium frameworks and implants. *Int J Oral Maxillofac Implants* 1998;13:190-6.
43. Gardner FM, Vermilyea SG. The variability of die-spacer film thickness. *Gen Dent* 1985;33:502-5.
44. Grajower R, Zubcei Y, Lewinstein I. Improving the fit of crowns with die spacers. *J Prosthet Dent* 1989;61:555-65.
45. Biancoli R. Il laser per uso odontotecnico. Il nuovo laboratorio odontotecnico 1997;XIII:7.
46. Biancoli R. Laser, un nuovo modo di pensare ed agire. *Riv It Odontotecnici* 1997;sett:6.
47. Brems F. Studio preliminare sulla metodologia laser in campo odontoiatrico: valutazione meccanica e strutturale di tecniche di saldatura a confronto. *Quintessenza Odont* 1996;9.
48. Tambasco J. Saldatura mediante laser, un'alternativa alla saldatura tradizionale. *Riv It Odontotecnici* 1997;mag:4.
49. Rubéing G. New techniques in spark erosion: the solution to an accurately fitting screw retained implant restoration. *Quintessence Int* 1999;30:38-48.
50. Haase K. Protesica individuale su impianti Brånemark mediante elettroerosione. *Quintessenza Odont* 2001;18:45-52.
51. Zappala C, Shober I, Barzani P. Microstructural aspects of the captek alloy for porcelain-fused-to-metal restoration. *J Esthet Dent* 1996;8:151-6.
52. Gherlone E. La protesica su impianti osteointegrati. Milano: Masson, 2003:49-63.
53. Tomassella G, Piat PG, Godoni M. Utilizzo della tecnologia capillare per la realizzazione di impiantioprotesi: prove di laboratorio e casi clinici. *Dental Protesi* 2002;8.
54. Redemagni M, Cremonesi S, Calderini A, Simonetti A. Passivazione dei metalli in implantoprotesi. *Il Dentista Moderno* 2002;5:95-111.
55. Helldén LB, Dérand T, Johanson S, Lindberg A. The Cresco-Ti precision method: description of a simplified method to fabricate titanium superstructures with passive fit to osseointegrated implants. *J Prosthet Dent* 1999;82:487-91.
56. Holmgren K, Fornell J. Studio di osservazione clinica e radiologica su 104 ricostruzioni protesiche fisse collocate direttamente su 435 impianti Brånemark. Documentazione Cresco-Ti. Manoscritto II:10, Stoccolma, 1997,02.09.
57. Roggenbuck M, Walter MH, Boring KW. Studies on laser and plasma-welded titanium. *Dent Mater* 1993;9:104-7.
58. Andersson M, Carlsson L, Persson M, Bergman B. Accuracy of machine milling and spark erosion with a cad/cam system. *J Prosthet Dent* 1996;76:187-93.
59. Riedy SJ, Lang BR, Lang BE. Fit of implant frameworks fabricated by different techniques. *J Prosthet Dent* 1997;78:596-604.
60. Levratto F, Gherlone E, Zandonella S. Galvano-doppelsekronen in der Implantatprothetik Teamwork. *Int J Proth Zahn* 1999;Jahr:2,1.
61. Hammerle CH. Marginal fit of porcelain crowns with galvanized frames. *Schweiz Monatsschr Zahnmed* 1994;104:740-5.
62. Solimei GE, Fauci A, Rondini D. L'utilizzo delle corone autogalvaniche (AGC) in implantoprotesi. *Boletín Implantológico de Klockner* 2001;7.
63. Corzani C, Siervo P, Siervo S. Elettroformazione autogalvanica associata a sovrastrutture in titanio per la passivazione in implantoprotesi cementata. *Implantologia Orale* 2002;1:237-43.
64. Quaranta M, D'Addona A, Prosper L. Restaurazioni protesiche fisse. *Dental Cadmos* 1993;7:38-48.
65. Witz J, Jäger K. Galvanoteleskope-prüfung, einfach und klinisch bewährt. *Quintessence* 1998;49:283-92.
66. Buch M, Heckendon H. La corona doppia intermedia nella protesica implantare. Ed MEA, 1995.
67. Aparicio C. A new method to routinely achieve passive fit of ceramic-metal prostheses over Brånemark osseointegrated implants. A two-year report. *Int J Periodont Rest Dent* 1994;14:405-19.
68. Henry PJ. An alternative method for the production of accurate casts and occlusal records in osseointegrated implant rehabilitation. *J Prosthet Dent* 1987;58:694-7.
69. Rosenlicht JL. Fitting and securing abutments to implant heads: technical note. *Implant Dent* 1997;6:117-8.
70. Cameron SM, Joyce A, Brousseau JS, Parker MH. Radiographic verification of implant abutment seating. *J Prosthet Dent* 1998;79:298-303.
71. da Cunha HA, Francischone CE, Fábio HN, de Oliveira RC. A comparison between cutting torque and resonance frequency in the assessment of primary stability and final torque capacity of standard and TiUnite single-tooth implants under immediate loading. *Int J Oral Maxillofac Implants* 2004;19:578-85.
72. Taylor TD, Agar JR, Vogiatzi T. Implant prosthodontics: current perspective and future directions. *Int J Oral Maxillofac Implants* 2000;15:66-75.
73. Frost HM. The skeletal intermediary organization. *Metab Bone Dis Related Res* 1983;4:281-90.





Università degli Studi di Padova
Facoltà di Medicina e Chirurgia
Corso di Laurea in Odontoiatria e Protesi Dentaria
Cattedra di Parodontologia
Prof. G. A. Favero

12° Congresso Nazionale
"Collegio dei Docenti di Odontoiatria"
Roma - Palazzo dei Congressi
16, 17, 18, 19 Marzo 2005



STABILIZZAZIONE DELLA PROTESI MEDIANTE ANCORAGGIO CON MINI IMPIANTI
IN PAZIENTI CON EDENTULIA TOTALE INFERIORE E ATROFIA DEL PROCESSO ALVEOLARE

D. PERAZZOLI, E. CAVALERI, S. PIVOVAR, E. STELLINI, E. D'ANDREA

Obiettivi dello studio
Lo studio ha come primo obiettivo valutare se e in che modo un impianto...

Materiali
Sono stati utilizzati grandi e piccoli impianti...

Metodi
Sono stati utilizzati diversi metodi...

Risultati
Sono stati ottenuti buoni risultati...

Conclusioni
Sono state raggiunte le finalità dello studio...



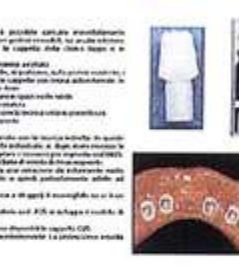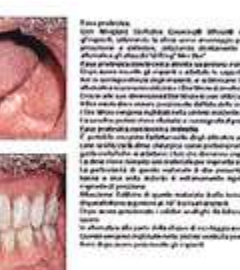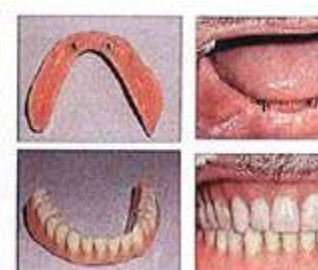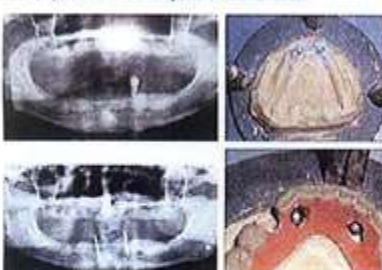
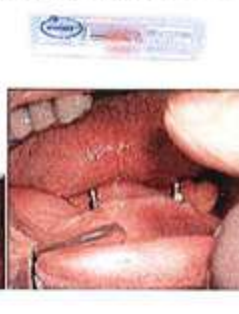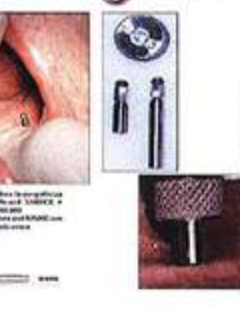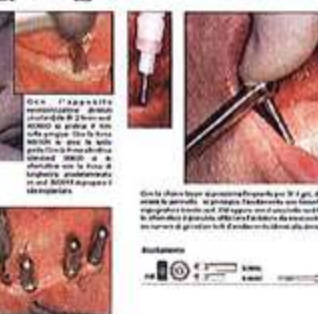
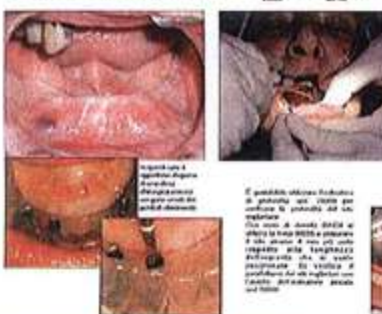
Materiali utilizzati
Sono stati utilizzati diversi materiali...



Metodi
Sono stati utilizzati diversi metodi...



Risultati
Sono stati ottenuti buoni risultati...



Conclusioni
Sono state raggiunte le finalità dello studio...

Conclusioni
Sono state raggiunte le finalità dello studio...

Conclusioni
Sono state raggiunte le finalità dello studio...

Conclusioni
Sono state raggiunte le finalità dello studio...

References
Sono stati citati diversi articoli...

References
Sono stati citati diversi articoli...

References
Sono stati citati diversi articoli...

References
Sono stati citati diversi articoli...



**1 Follow-up a 4 anni di impianti post-estrattivi a diametro maggiorato**

L. Prosper, S. Redaelli, A. D'Addona, E. F. Gherlone

Poster n° 486 11° Congresso Nazionale - Collegio dei docenti di Odontoiatria

---

**2 Follow-up a 4 anni di impianti con diametro maggiore inseriti in alveoli di recente estrazione in combinazione con una membrana riassorbibile o con un materiale alloplastico riassorbibile**

L. Prosper, E. F. Gherlone, S. Redaelli, M. Quaranta

QE Implantologia la rivista per il Clinico anno 2 - Aprile 2004

20  
04





11° Congresso Nazionale "Collegio dei Docenti di Odontoiatria"

Roma 21/24 Aprile 2004

N°486

FOLLOW-UP A 4 ANNI DI IMPIANTI POST-ESTRATTIVI  
A DIAMETRO MAGGIORATO (Winsix®)

L. Prosper, S. Redaelli, A. D'Addona, E. Gherlone,  
ISTITUTO SCIENTIFICO UNIVERSITARIO S. RAFFAELE, MILANO, SERVIZIO DI ODONTOIATRIA

INTRODUZIONE

Gli impianti dentali inseriti al momento dell'estrazione offrono numerosi vantaggi, come ad esempio quello di semplificare il loro posizionamento e di migliorare la resa estetica grazie alla presenza di punti di riferimento, di poterli collocare in zone che altrimenti non sarebbero adatte per una protesi fissa a causa del riassorbimento osseo, di preservare l'osso alveolare e la conformazione della cresta e di ridurre la possibilità di penetrazione nel seno mascellare superiore [1,2], riducono, inoltre, il tempo di trattamento complessivo del paziente. Con l'asportazione della ricca rete capillare dei tessuti sono stati introdotti numerose sostanze per rigenerare in senso verticale ed orizzontale l'osso mascelare in un sito chirurgico. Alcuni esempi sono costituiti dalle membrane riassorbibili a base di copolimeri di acido polilattico e poliglicolico (GHR) [3-7] o dai materiali alloplastici a base di idrossiapatite [8-10].

SCOPO DEL LAVORO

Lo scopo di questo studio randomizzato è quello di valutare e di confermare l'incidenza di successo impiantare a lungo termine di impianti (titanio, cerici e a vite, a diametro maggiorato (5,9 mm), inseriti in siti post-estrattivi, in combinazione con materiali o membrane riassorbibili.

MATERIALI E METODI

Nella ricerca sono stati considerati 83 pazienti adulti di ambolite e sessi, di età compresa tra 21 e 75 anni, selezionati tra quelli trattati nel periodo 1997-98 presso il nostro istituto, ai quali erano stati inseriti uno o più impianti in alcuni post-estrattivi di molari mandibolari o maxillari. In totale sono stati inseriti 111 impianti (Winnix® Ltd, London, UK), 75 nella mandibola e 36 nel maxillare superiore. 56 sono stati gli impianti in combinazione con un allineatore (gruppo HA); 55 quelli con una membrana riassorbibile (gruppo MR). Al momento della risposta e dell'applicazione delle viti di giunzione la mobilità impiantare è stata saggiata mediante Periotest. Successivamente, sono state eseguite radiografie periapicali e controllate a 3, 6, 9 e 12 mesi e quindi con frequenza annuale fino al quarto anno dalla procezione definitiva. Il controllo radiografico è stato eseguito con procedura standardizzata in modo da permettere il rilevamento del grado di osteoraggiografia, considerandolo come punto di riferimento standardizzato in modo da permettere il rilevamento del grado di osteoraggiografia, considerandolo come punto di riferimento calcolato sul 1,4 mm del margine dell'impianto.

RESULTATI

Il follow-up a 4 anni è stato del 100%. Alla risposta dei siti impiantari, successiva al periodo di guarigione di 4-6 mesi, nessun impianto ha mostrato segni di mobilità, perimplantite o perdita ossea. Due impianti sono stati persi nel gruppo MR, uno a 3 mesi e uno a 9 mesi dal loro posizionamento, 1 nel gruppo HA dopo 4 mesi dall'inserimento. Dopo 4 anni, il successo impiantare, definito secondo i criteri di Albrektsson (1986), si è verificato in 108/111 (97,2%) impianti, ed è stato del 98,2% nel gruppo HA e del 96,4% nel gruppo MR.

DISCUSSIONE

L'effetto di impianti di diametro di 5,9 mm ha permesso di aumentare la stabilità, riducendo il rapporto di squilibrio rispetto al diametro di gran lunga superiore della corona (10-17 mm di larghezza) in direzione medio-laterale ed il momento flessante che si esercita sull'impianto per l'applicazione di carichi eccentrici [1], e di riempire quasi completamente il difetto post-estrattivo.

Il materiale alloplastico a riassorbimento controllato utilizzato, la Biostris (Biostris® - Vitas, S. Giuliano Milanese, Italia), è un materiale che si riassorbe con lo stesso ritmo con il quale avviene la riformazione ossea e che al suo interno contiene idrossiapatite (38%) e collagene (9,5%), essendo sia osteoconduttiva che osteoinduttiva [12-15]. In tutti i casi esaminati, finora, non si è avuta una guarigione clinica soddisfacente, senza alcuna reazione da corpo estraneo e con rapida formazione ossea, per quanto deducibile dai ripetuti controlli radiografici.

Le membrane riassorbibili posizionate nel gruppo MR, riassorbibili in 46-24 settimane (Gene Resorb, WI, Gene & Associates, Inc., Flagstaff, Arizona, USA), hanno il vantaggio di evitare il secondo intervento per la loro rimozione e se non ben accostate all'architettura ossea circostante possono essere d'aiuto nella guarigione di difetti, fratture e gap ossei. I pazienti trattati con questa metodica radiograficamente hanno mostrato un completo riempimento osseo attorno agli impianti.

CONCLUSIONI

Sugli impianti post-estrattivi inseriti in combinazione con un bioassorbibile riassorbibile sia quelli ottenuti con una membrana riassorbibile hanno ripetuto risultati soddisfacenti a lungo termine nella riabilitazione mediante protesi parziale fissa.

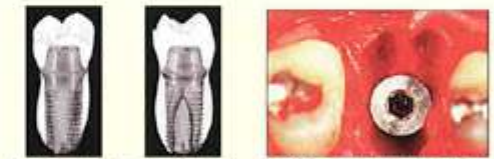

Figura 1. Controllo radiografico di un impianto a diametro maggiorato in un sito post-estrattivo.

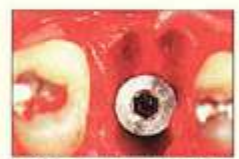

Figura 2. Inclinazione di un impianto a diametro maggiorato in un sito post-estrattivo.

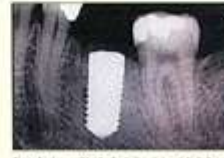

Figura 3. Controllo radiografico di un impianto a diametro maggiorato in un sito post-estrattivo.

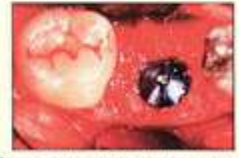

Figura 4. Controllo clinico di un impianto a diametro maggiorato in un sito post-estrattivo.

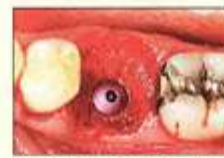

Figura 5. Controllo radiografico di un impianto a diametro maggiorato in un sito post-estrattivo.



Figura 6. Controllo clinico di un impianto a diametro maggiorato in un sito post-estrattivo.

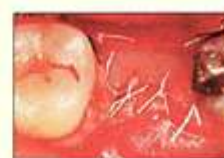

Figura 7. Controllo radiografico di un impianto a diametro maggiorato in un sito post-estrattivo.

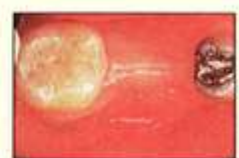

Figura 8. Controllo clinico di un impianto a diametro maggiorato in un sito post-estrattivo.



Figura 9. Controllo radiografico di un impianto a diametro maggiorato in un sito post-estrattivo.

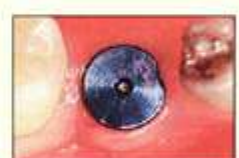

Figura 10. Controllo clinico di un impianto a diametro maggiorato in un sito post-estrattivo.

Tabella 1. Distribuzione degli impianti in base al sesso dei pazienti, del tipo di sito post-estrattivo e del gruppo di trattamento.

Gruppo	Site	Sex	Number
Gruppo HA	Mandibola	M	35
		F	40
	Maxillare	M	15
		F	21
Gruppo MR	Mandibola	M	20
		F	35
	Maxillare	M	10
		F	15
		Total	111

Tabella 2. Distribuzione degli impianti in base al tipo di sito post-estrattivo e al gruppo di trattamento.

Gruppo	Site	Number	
Gruppo HA	Site 1	45	
	Site 2	66	
Gruppo MR	Site 1	35	
	Site 2	76	
		Total	111

Tabella 3. Distribuzione degli impianti in base al gruppo di trattamento e al tipo di sito post-estrattivo.

Gruppo	Site	Number	
Gruppo HA	Site 1	45	
	Site 2	66	
Gruppo MR	Site 1	35	
	Site 2	76	
		Total	111

BIBLIOGRAFIA

1) Dawson PE, Kalk W, Sullivan RW, Van Meurs WJ. Anatomic considerations for posterior implantation. Int J Oral Maxillofac Implants 1993;8:10-6.  
 2) Patakli G, Reda S, Morsani M, Reda S, Reda S. Immediate and delayed implantation for complete restoration of the jaw following resection of ameloblastoma: a retrospective study comparing different types of oral maxillofacial implantation. Int J Oral Maxillofac Implants 1993;8:30-7.  
 3) Reda S, Reda S. Immediate versus immediate for implantation: a retrospective study. Int J Oral Maxillofac Implants 1993;8:30-7.  
 4) Reda S, Reda S, Reda S, Reda S. Immediate versus immediate for implantation: a retrospective study. Int J Oral Maxillofac Implants 1993;8:30-7.  
 5) Reda S, Reda S, Reda S, Reda S. Immediate versus immediate for implantation: a retrospective study. Int J Oral Maxillofac Implants 1993;8:30-7.  
 6) Reda S, Reda S, Reda S, Reda S. Immediate versus immediate for implantation: a retrospective study. Int J Oral Maxillofac Implants 1993;8:30-7.  
 7) Reda S, Reda S, Reda S, Reda S. Immediate versus immediate for implantation: a retrospective study. Int J Oral Maxillofac Implants 1993;8:30-7.  
 8) Reda S, Reda S, Reda S, Reda S. Immediate versus immediate for implantation: a retrospective study. Int J Oral Maxillofac Implants 1993;8:30-7.  
 9) Reda S, Reda S, Reda S, Reda S. Immediate versus immediate for implantation: a retrospective study. Int J Oral Maxillofac Implants 1993;8:30-7.  
 10) Reda S, Reda S, Reda S, Reda S. Immediate versus immediate for implantation: a retrospective study. Int J Oral Maxillofac Implants 1993;8:30-7.

11) Reda S, Reda S, Reda S, Reda S. Immediate versus immediate for implantation: a retrospective study. Int J Oral Maxillofac Implants 1993;8:30-7.  
 12) Reda S, Reda S, Reda S, Reda S. Immediate versus immediate for implantation: a retrospective study. Int J Oral Maxillofac Implants 1993;8:30-7.  
 13) Reda S, Reda S, Reda S, Reda S. Immediate versus immediate for implantation: a retrospective study. Int J Oral Maxillofac Implants 1993;8:30-7.  
 14) Reda S, Reda S, Reda S, Reda S. Immediate versus immediate for implantation: a retrospective study. Int J Oral Maxillofac Implants 1993;8:30-7.  
 15) Reda S, Reda S, Reda S, Reda S. Immediate versus immediate for implantation: a retrospective study. Int J Oral Maxillofac Implants 1993;8:30-7.  
 16) Reda S, Reda S, Reda S, Reda S. Immediate versus immediate for implantation: a retrospective study. Int J Oral Maxillofac Implants 1993;8:30-7.  
 17) Reda S, Reda S, Reda S, Reda S. Immediate versus immediate for implantation: a retrospective study. Int J Oral Maxillofac Implants 1993;8:30-7.  
 18) Reda S, Reda S, Reda S, Reda S. Immediate versus immediate for implantation: a retrospective study. Int J Oral Maxillofac Implants 1993;8:30-7.  
 19) Reda S, Reda S, Reda S, Reda S. Immediate versus immediate for implantation: a retrospective study. Int J Oral Maxillofac Implants 1993;8:30-7.  
 20) Reda S, Reda S, Reda S, Reda S. Immediate versus immediate for implantation: a retrospective study. Int J Oral Maxillofac Implants 1993;8:30-7.

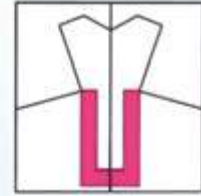


Spedizione in A.P. - 45% - art. 2 comma 20/B legge 662/96 - Milano



# IMPLANTOLOGIA

La rivista per il clinico ■ APRILE 2004 ANNO 2



# 2

## Follow-up a quattro anni di impianti con diametro maggiore inseriti in alveoli di recente estrazione in combinazione con una membrana riassorbibile o con un materiale alloplastico riassorbibile

Loris Prosper, Enrico F. Gherlone, Sara Redaelli, Manlio Quaranta

**Scopo:** Lo scopo di questo studio randomizzato era di valutare e confrontare le percentuali di successo a lungo termine di viti cilindriche in titanio con diametro maggiore (5,9 mm) inserite in alveoli di recente estrazione, in combinazione con materiali osteosostitutivi riassorbibili o con una membrana riassorbibile. **Materiali e Metodi:** Sono stati inclusi nello studio ottantatre pazienti adulti parzialmente edentuli selezionati tra quelli trattati nel 1997 e 1998 all'Istituto San Raffaele, su cui erano stati inseriti 1 o più impianti in alveoli di recente estrazione nelle regioni posteriori della mandibola o del mascellare superiore. Sono stati inseriti 111 impianti in totale: 36 nella mandibola e 75 nel mascellare superiore. 56 impianti sono stati posizionati in combinazione con idrossiapatite riassorbibile (gruppo HA) e 55 con una membrana riassorbibile (gruppo MR). Radiografie endorali ed esami di follow-up, compresa la verifica della stabilità degli impianti mediante il Periotest, sono stati eseguiti durante la seconda fase chirurgica a 3, 6, 9 e a 12 mesi; hanno fatto seguito controlli annuali fino a 4 anni dalla messa in situ della ricostruzione definitiva. L'esame radiografico è stato svolto con una metodica standardizzata per verificare l'avvenuta osteointegrazione. **Risultati:** C'è stata una presenza del 100% all'esame di follow-up dopo 4 anni. All'atto della seconda fase chirurgica, che è stata eseguita dopo un tempo di guarigione di 4-6 mesi, nessun impianto mostrava segni di mobilità, peri-implantite o perdita ossea. Due insuccessi si sono verificati nel gruppo MR, uno a 3 mesi e uno a 9 mesi dall'inserimento; 1 impianto non si è integrato nel gruppo HA a 4 mesi dall'inserimento. Dopo 4 anni la percentuale di successo degli impianti era del 97,3% (108 impianti su 111 sono stati considerati riusciti). Tale percentuale non presentava differenze significative tra il gruppo HA (98,2%) e il gruppo MR (96,4%). **Discussione:** L'utilizzo di impianti di diametro maggiore ha permesso di ridurre al minimo le discrepanze anatomiche che sarebbero derivate dalla sostituzione di un molare con un impianto di diametro standard. In base ai criteri di successo convenzionalmente accettati, la percentuale di successo a 5 anni dovrebbe essere almeno dell'85%, per cui entrambi i metodi possono essere considerati soddisfacenti. **Conclusione:** Gli impianti inseriti in combinazione con un materiale alloplastico riassorbibile o con una membrana riassorbibile hanno permesso di ottenere risultati prevedibili a lungo termine in seguito alla riabilitazione con una protesi parziale fissa. (INT J ORAL MAXILLOFAC IMPLANTS 2003;18:856-864. Pubblicato dalla Quintessence Publishing Co., Chicago, USA. Direttore editoriale William R. Laney.)

**Parole chiave:** Membrane artificiali; Impianti dentari; Rigenerazione guidata dei tessuti; Idrossiapatite; Estrazione dentaria.



## 2. Prosper/Gherlone/Redoelli/Quaranta - Follow-up a quattro anni di impianti con diametro maggiore...

Una serie di studi scientifici ha dimostrato la prevedibilità dell'implantologia osteointegrata conforme ai principi biologici proposti da Adell et al.<sup>1,3</sup>. Tra questi principi si postulava la necessità della completa guarigione dell'osso alveolare prima dell'inserimento di un impianto in un alveolo di recente estrazione, un processo che richiede solitamente da 6 a 12 mesi<sup>1-3</sup>. È stato tuttavia osservato che durante tale periodo può verificarsi un riassorbimento del 44% e oltre<sup>4,5</sup> della cresta alveolare, prevalentemente nei primi 6 mesi<sup>6</sup>. Il grado di riassorbimento dipende generalmente dalla regione interessata, dal lasso di tempo dopo l'estrazione e, in alcuni casi, dalla pressione esercitata dalla protesi rimovibile del paziente<sup>5</sup>. Detta perdita di osso può indurre il clinico ad applicare la rigenerazione guidata dell'osso (GBR) o a introdurre impianti di 8 mm o meno di lunghezza. Entrambe le situazioni sono state associate a una percentuale inferiore di successo implantare a lungo termine<sup>7-14</sup>.

Alcuni autori hanno dimostrato che molti vantaggi possono derivare dall'introduzione di impianti in un alveolo di recente estrazione. Per esempio il posizionamento risulta più facile grazie all'esistenza di punti di riferimento ed è possibile inserire le fixture in alcune regioni non idonee a una protesi fissa. È anche possibile conservare l'osso alveolare e il contorno della cresta, riducendo possibilmente il rischio di penetrazione del seno nella regione posteriore del mascellare superiore<sup>15,16</sup>. Inoltre, ulteriori vantaggi per il paziente risultano non soltanto dalla minor durata del trattamento, riduzione del numero di sedute di chirurgia, minor grado di morbosità, ma anche dalla miglior estetica in virtù del posizionamento ottimale degli impianti.

L'introduzione delle tecniche GBR ha permesso l'utilizzo di membrane in combinazione con impianti immediati post-estrattivi<sup>17-21</sup>. L'uso di membrane per isolare l'epitelio gengivale e le cellule del tessuto connettivo del sito in fase di guarigione può indurre un aumento dell'osteogenesi, un più forte riempimento osseo e l'osteointegrazione<sup>10,17,20,21</sup>. Di recente è stato consigliato l'innesto di materiali alloplastici a base di idrossiapatite<sup>22-24</sup> per evitare il collasso della cresta alveolare, essendo questo composto considerato un buon sostituto di osso nella chirurgia maxillofaciale. Da un punto di vista clinico e pratico sarebbe importante valutare l'esistenza di eventuali differenze tra queste tecniche rigenerative dell'osso nella valutazio-

ne del successo a lungo termine, specialmente quando gli impianti vengono posizionati in alveoli di recente estrazione. Nella letteratura odontoiatrica attuale prevale una carenza di studi sperimentali eseguiti specificatamente per l'esame di questa problematica. Lo scopo del presente studio era di confrontare il potenziale di riempimento osseo e il successo dell'osteointegrazione a 4 anni intorno agli impianti dentari di diametro maggiore (5,9 mm) inseriti direttamente in alveoli di recente estrazione nelle regioni posteriori del mascellare superiore e della mandibola, in combinazione con una membrana riassorbibile o con materiali alloplastici riassorbibili.

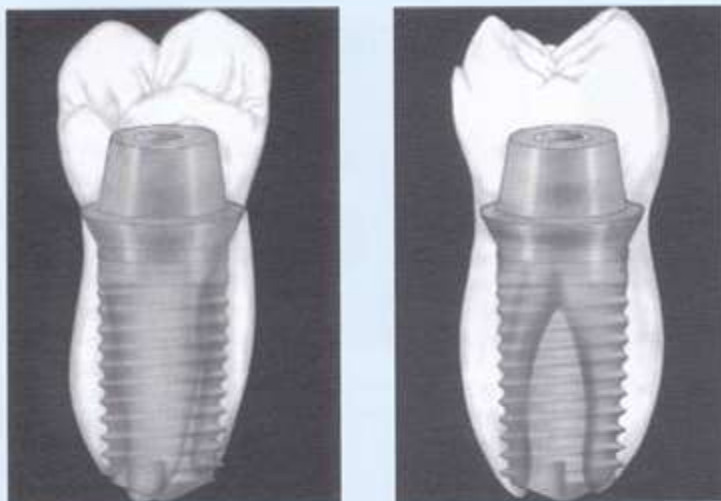
### Materiali e metodi

In questo studio randomizzato sono stati valutati 83 pazienti adulti, che avevano necessità di estrarre e ricostruire 1 o più denti nelle aree posteriori del cavo orale. Le 11 donne e i 39 uomini, con un'età media ( $\pm$  deviazione standard) di  $46,2 \pm 14,3$  anni, sono stati selezionati tra i soggetti trattati nel 1997 e nel 1998, in base ai seguenti criteri di ammissione: età compresa tra 21 e 75 anni; conformità agli standard di igiene orale a domicilio; estrazione dovuta a carie, frattura di elementi dentari, parodontite o insuccesso del trattamento endodontico; presenza di un alveolo di recente estrazione sufficientemente esteso, tale che anche dopo l'inserimento di un impianto del diametro di 5,9 mm ci fosse comunque un difetto osseo residuo; occlusione idonea per la riabilitazione protesica pirificata.

Il criterio di esclusione era la presenza di malattie dismetaboliche, croniche e/o infettive. A ogni paziente è stata fornita una spiegazione dettagliata del piano di trattamento ed è stato richiesto il consenso informato scritto per la partecipazione alla ricerca.

Tutti gli impianti erano in titanio commercialmente puro sabbato (Bioactive Covering, Winsix, London, United Kingdom), specificatamente viti cilindriche autofillettanti, con un diametro di 5,9 mm e una lunghezza di 11 o 13 mm (Fig. 1, Tabella 1). Gli alveoli di recente estrazione sono stati classificati come tipo 1 nella classificazione preoperatoria di Salama<sup>25</sup>:

- tasca post-estrattiva a 4 pareti e riassorbimento minimo dell'osso;



Figg. 1a, 1b La testa dell'impianto dovrebbe rispecchiare il diametro dei denti da sostituire. (Sinistra) veduta anteriore e (destra) sagittale di un molare standard.

Tabella 1 Distribuzione degli impianti in base al sesso dei pazienti, posizione e lunghezza degli impianti.

Gruppo di pazienti/ Posizione	Lunghezza degli impianti	
	11 mm.	12 mm.
<b>Pazienti femmine</b>		
Primo molare superiore ds.	-	9
Secondo molare superiore ds.	-	13
Primo molare superiore sin.	-	14
Secondo molare superiore sin.	-	11
Primo molare inferiore sin.	2	6
Primo molare inferiore ds.	3	4
<b>Totale</b>	<b>5 (8,1%)</b>	<b>57 (91,9%)</b>
<b>Pazienti maschi</b>		
Primo molare superiore ds.	-	10
Secondo molare superiore ds.	-	8
Primo molare superiore sin.	-	10
Secondo molare superiore sin.	-	7
Primo molare inferiore sin.	-	3
Primo molare inferiore ds.	2	9
<b>Totale</b>	<b>2 (4,1%)</b>	<b>47 (95,9%)</b>

Non sono state riscontrate differenze significative nella distribuzione della lunghezza in base al sesso del paziente ( $P > ,839$ )

- presenza di 3-5 mm di osso al di sotto dell'apice dell'impianto;
- discrepanza accettabile ( $< 2$  mm) tra la testa dell'impianto e la giunzione amelo-cementizia dei denti contigui, se presenti, o la porzione più coronale dell'alveolo;
- recessione gengivale curabile.

In termini di perdita di osso marginale, gli alveoli di recente estrazione sono stati assegnati alle classi A1 (nessuna perdita di attacco parodontale), B1 (perdita di non oltre un terzo dell'attacco parodontale) o C1 (perdita di non oltre la metà dell'attacco parodontale) in base alla classificazione di Becker et al.<sup>26</sup>.

I pazienti sono stati divisi a caso in 2 gruppi: nei pazienti del gruppo HA sono stati posizionati impianti in combinazione con l'uso di idrossiapatite sintetica (56 impianti, Biosire, Vebas, Milano, Italia) e in quelli del gruppo MR sono stati



4 Prosper/Gherlone/Redaelli/Quaranta · Follow-up a quattro anni di impianti con diametro maggiore...

**Tabella 2** Distribuzione degli impianti nei 2 gruppi di pazienti.

Posizione impianti	Gruppo	
	HA (n = 56/50,4%)	MR (n = 55, 49,6%)
<b>Mascellare superiore</b>		
Primo molare ds.	7 (6,3%)	7 (6,3%)
Secondo molare ds.	11 (9,9%)	10 (9,1%)
Primo molare sin.	12 (10,8%)	12 (10,8%)
Secondo molare sin.	8 (7,2%)	8 (7,2%)
<b>Mandibola</b>		
Primo molare ds.	8 (7,2%)	9 (8,1%)
Secondo molare ds.	-	1 (0,9%)
Primo molare sin.	8 (7,2%)	8 (7,2%)
Secondo molare sin.	2 (1,8%)	-

Non sono state riscontrate differenze significative tra i gruppi HA e MR ( $P > 001$ ).

posizionati impianti in combinazione con una membrana bioassorbibile a base di copolimeri dell'acido poliglicolico e dell'acido polilattico (55 impianti; Ossequest; W.L. Gore, Flagstaff, AZ). Gli esami radiografici preoperatori comprendevano un ortopantomografia e radiografie periapicali per la valutazione della cresta residua anatomica. È stata eseguita una valutazione protesica completa ai fini di una ricostruzione protesica adeguata.

Tutte le procedure chirurgiche e protesiche sono state svolte dallo stesso clinico. Sono stati introdotti 111 impianti in totale: 36 nella mandibola e 75 nel mascelle superiore (Tabelle 1, 2).

### Fasi chirurgiche

Le estrazioni sono state eseguite con tecniche atraumatiche in anestesia locale, evitando di scollare lembi, conservando le papille e, dove necessario, ricorrendo alla resezione della radice per evitare di distruggere i setti alveolari. Ogni traccia di gengiva aderente è stata rimossa dagli alveoli con appositi stru-

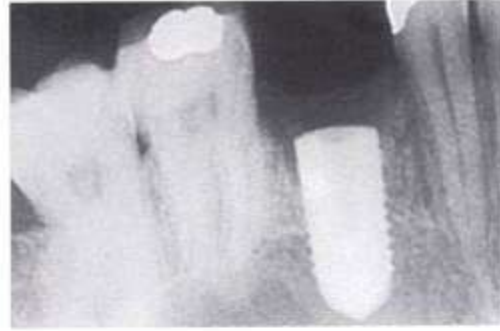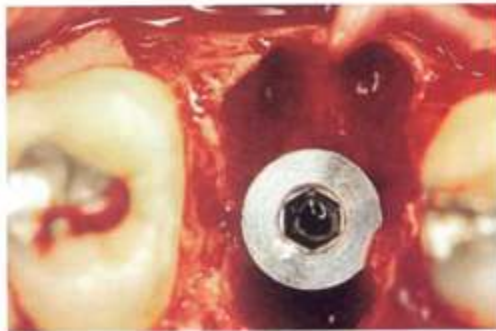
menti, poi le porzioni apicali dell'alveolo stesso sono state preparate per alloggiare le fixture in conformità alle istruzioni del produttore. È stata considerata l'ampiezza biologica dei denti contigui, se presenti, con una velocità media prevista di riassorbimento dell'osso di 1-1,5 mm per il primo anno dall'inserimento degli impianti. Per prevenire l'esposizione del collo lucidato degli impianti, le viti sono state posizionate 2 mm apicalmente al livello dell'osso marginale, per cui i siti implantari erano sovracontornati di 2 mm. Nelle aree posteriori, soprattutto nei primi molari, sono stati effettuati mini rialzi del seno: l'osso residuo è stato carotato con una fresa trephine di 6 mm per arrivare a circa 1 mm dalla membrana di Schneider, poi la membrana è stata sollevata

di circa 2 mm con una leggera pressione.

A questo punto l'obiettivo era di posizionare gli impianti al centro della cavità alveolare residua, in modo da essere equidistanti dalle pareti ossee (Figg. 2a, 2b).

Nel gruppo HA, a questo stadio, il materiale da innesto è stato inserito a contatto diretto con la superficie di osso sanguinante ed è stato condensato per eliminare eventuali bolle (Fig. 3). Nel gruppo MR, dopo che il clinico ha scollato un lembo a tutto spessore, la membrana è stata posta completamente a contatto con la superficie intorno all'area dell'alveolo, evitando il contatto tra i bordi mesiali-distali e i denti adiacenti, dove presenti, ed estendendone il disegno a coprire almeno 3 mm di cresta ossea a livello delle superfici buccali e linguali (Fig. 4).

È stata posta particolare attenzione alla sutura; il chirurgo ha cercato di apporre i due lembi per prima intenzione con suture da materasso orizzontali (Gore-Tex; W. L. Gore, Flagstaff, AZ), ha usato suture verticali o interrotte per le papille, ricorrendo dove necessario a colla di fibrina (Tissucol; Immuno, Pisa, Italia). Dopo le fasi chirurgiche è stata eseguita una radiografia per documentare il rapporto esistente tra l'im-



Figg. 2a, 2b Caso 1: posizionamento dell'impianto nell'alveolo con la porzione coronale 2 mm. apicalmente al livello della cresta ossea immediatamente dopo l'estrazione dentaria. (Sinistra) veduta occlusale; (destra) radiografia perirapicale.

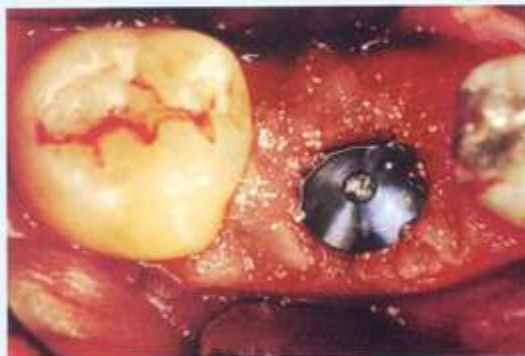
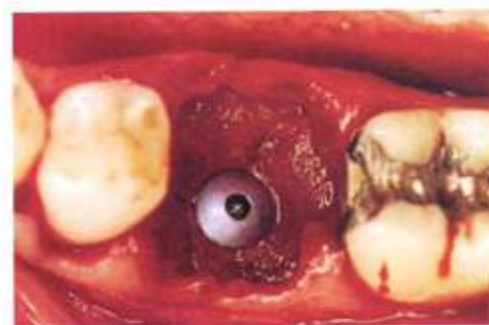
Fig. 3 Caso 2. Il Biosite è stato zeppato tra le pareti dell'alveolo e l'impianto.



Figg. 4a, 4b Caso 3. La membrana è stata tagliata e posizionata in modo da coprire sia l'impianto che l'osso circostante. (Sinistra) veduta occlusale del campo operatorio; (destra) membrana con perno di ancoraggio in situ.

pianto e la cavità alveolare (Figg. 5a, 5b). In seguito è stato prescritto al paziente 1 gr di amoxicillina più potassio clavulanato (Augmentin; Smithkline Beecham, New York, NY) ogni 12 ore per 6 giorni e 100 mg di nimesulide, se necessario. Inoltre sono stati consigliati nelle 2 settimane dopo l'intervento sciacqui postoperatori due volte al giorno con clorexidina digluconato 0,2% (Dentosan Mese; Pagni Raffaello, Firenze, Italia) e l'applicazione topica di un corticosteroide/gel a base di clorexidina (Corsodyl; Smithkline Beecham



6 Prosper/Gherlone/Redoelli/Quaranta · Follow-up a quattro anni di impianti con diametro maggiore...

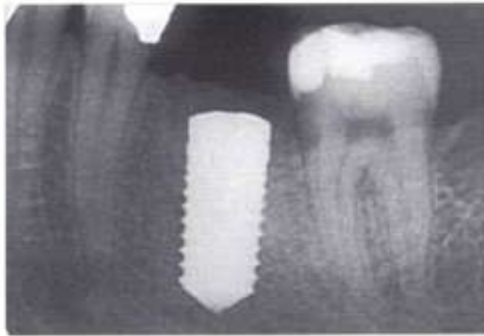


Fig. 5a Caso 2. Radiografia dell'impianto immediatamente dopo l'inserimento nell'alveolo, durante la prima fase chirurgica. Nel terzo coronale è chiaramente visibile la condensazione del biomateriale.



Fig. 5b Caso 3. Radiografia dell'impianto immediatamente dopo l'inserimento nell'alveolo, durante la prima fase chirurgica. Nel terzo coronale è chiaramente visibile uno spazio radiotrasparente, essendo la membrana non opaca.

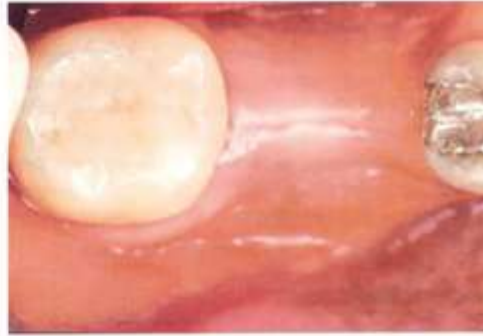

Fig. 6a Caso 2. Guarigione dei tessuti duri e molli a 3 mesi di follow-up.

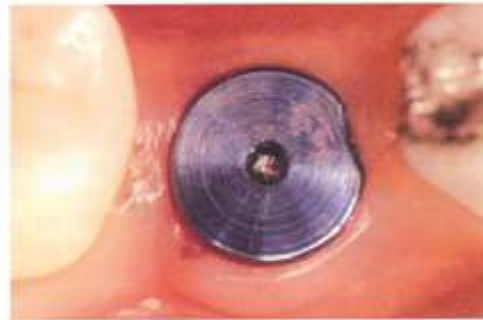
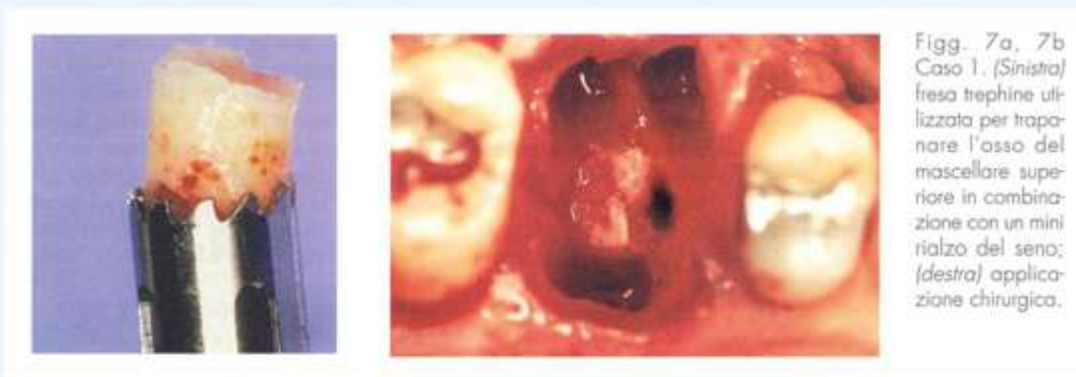


Fig. 6b Caso 2. Esposizione dell'impianto e posizionamento della vite di guarigione.

Farm, Bollate, Italia). La settimana dopo l'operazione le suture sono state rimosse ed è stata introdotta una corretta profilassi dentaria.

I pazienti sono poi stati chiamati ai controlli una volta alla settimana durante le 3 settimane successive per la profilassi, istruzioni d'igiene orale e monitoraggio del processo di guarigione (Fig. 6a). Durante questo periodo è stato chiesto ai pazienti di non portare la protesi parziale rimovibile provvisoria per evitare di tra-

matizzare l'area trattata e poiché non era necessario ai fini estetici. Successivamente i pazienti sono stati sottoposti alla terapia postoperatoria una volta al mese (pazienti con impianti nella mandibola: per 3 mesi; pazienti con impianti nel mascellare superiore: per 5 mesi). Rispettivamente dopo 4 e 6 mesi è stata eseguita la seconda fase chirurgica per l'esposizione degli impianti (Fig. 6b) e sono state effettuate radiografie periapicali per documentare lo stato di guarigione.



Figg. 7a, 7b  
Caso 1. (Sinistra)  
fresa trephine uti-  
lizzata per tro-  
panare l'osso del  
mascellare supe-  
riore in combi-  
nazione con un mini  
rialzo del seno;  
(destra) applica-  
zione chirurgica.

#### Valutazioni di follow-up

Dopo avere alloggiato la ricostruzione definitiva, tutti i pazienti sono stati invitati a presentarsi ad appuntamenti clinici di follow-up previsti ogni 3 mesi per un periodo complessivo di 4 anni dall'inserimento delle viti. Durante questi appuntamenti è stato condotto un esame obiettivo dei tessuti molli, è stata valutata la precisione marginale tra il restauro e l'abutment con un microscopio a ingrandimento 4x e sono state fatte alcune correzioni se necessario; in tale contesto è stata verificata anche l'igiene orale del paziente. Ai fini di valutare l'osseointegrazione di tutti gli impianti è stato stabilito un protocollo, comprendente i test di mobilità mediante il Periotest (Siemens, Bensheim, Germania) e radiografie periapicali (Digora; Soredex, Helsinki, Finlandia), che sono state rilevate su ogni paziente a 3, 6, 9 e 12 mesi e poi una volta all'anno per quattro anni. È stato stimato il grado di riassorbimento del tessuto osseo, prendendo come riferimento il livello della cresta ossea e l'anello circolare sito a 1,4 mm dal bordo dell'impianto in posizione mesiale e distale. Il successo implantare è stato definito su base radiografica, in conformità ai criteri di Albrektsson et al<sup>2</sup>.

#### Analisi statistica

I risultati vengono presentati in forma di numeri e/o percentuali di osservazione. Per le variabili continue sono stati fatti confronti tra i 2 gruppi di impianti utilizzando

il test t di Student per i dati non corrispondenti. Il test del chi-quadrato e il test esatto di Fisher sono stati impiegati per il confronto delle variabili discrete. I valori P al di sotto di ,05 sono stati considerati per indicare la significatività statistica (test 2-tailed).

#### Risultati

La distribuzione in termini di età e di sesso non era differente tra i due gruppi di pazienti, che erano paragonabili anche per quanto riguarda le dimensioni lineari degli impianti e la regione del cavo orale interessata ( $P > ,839$ ) (Tabella 1).

Al termine del periodo di guarigione, al momento dell'esposizione degli impianti nessuna fixture mostrava segni visibili di mobilità, infezione periimplantare o perdita di osso. In particolare, tutti i valori del Periotest erano compresi in un range da -5 a 0 sia per il gruppo HA che per il gruppo MR. La distanza tra il solco del collo dell'impianto e la prima parte visibile dell'osso non presentava differenze significative tra i 2 gruppi di impianti, con variazioni da 0,70 a 0,80 mm nel gruppo HA e da 0,73 a 0,80 mm nel gruppo MR ( $P = ,772$ ).

La tabella 2 mostra, per i 2 gruppi di pazienti, la distribuzione degli impianti in base alla regione d'inserimento; la distribuzione era paragonabile nei due gruppi ( $P > ,981$ ). Il 100% dei pazienti si è presentato al controllo di follow-up dopo 4 anni. La percentuale complessiva del successo implantare a 4 anni dall'in-



### 8 Prosper/Gherlone/Redaelli/Quaranta - Follow-up a quattro anni di impianti con diametro maggiore...

serimento era del 97,3% e non presentava differenze significative tra il gruppo HA (98,2%) e il gruppo MR (96,4%) ( $P = ,986$ ).

I due insuccessi implantari nel gruppo MR sono avvenuti sullo stesso paziente: uno è subentrato nella regione del primo molare inferiore destro prima del carico, l'altro nella regione del primo molare inferiore sinistro 3 mesi dopo il carico funzionale. Non si sono riscontrate reazioni infiammatorie particolari, ma solo una perdita di stabilità implantare. Possibili fattori di rilievo nell'anamnesi del paziente riguardavano i precedenti di cisti odontogene e l'abitudine a fumare oltre 10 sigarette al giorno. L'unico insuccesso nel gruppo HA è avvenuto a carico di un impianto nella regione del secondo molare superiore di sinistra, in un soggetto con osso poco denso.

#### Discussione

L'obiettivo principale di questa indagine era di valutare il successo dell'osteointegrazione di impianti con diametro maggiore inseriti in alveoli di recente estrazione, in combinazione con un biomateriale riassorbibile e con una membrana riassorbibile.

L'utilizzo di impianti di diametro superiore serviva a ridurre al minimo le discrepanze anatomiche date dalla sostituzione di un molare con un impianto di diametro standard<sup>27,28</sup>. I problemi con un impianto di diametro standard potrebbero riguardare non soltanto il profilo d'emergenza, ma anche provocare un allentamento della vite, rotture o mancanza di stabilità primaria<sup>29,31</sup>. La discrepanza tra la sezione trasversale della fixture e quella della radice del dente è spesso causa di marcati sottosquadri a livello del profilo di emergenza, un'area che può diventare inaccessibile per una corretta igiene. Inoltre un rapporto non equilibrato può risultare in conseguenza del diametro superiore (10-12 mm) della corona in direzione mesio-distale, con conseguente aumento dei momenti flettenti esercitati sull'impianto dall'applicazione di forze eccentriche, che possono provocare fratture nella porzione coronale dell'impianto stesso<sup>32</sup>. L'inserimento di viti con diametro 5,9 ha permesso di aumentare la stabilità e di riempire quasi completamente i difetti post-estrattivi, migliorando quindi la prognosi di successo. Il criterio razionale per il leggero rialzo del seno per

gli impianti posizionati nelle aree posteriori del mascellare superiore si basa sull'evidenza che il processo alveolare è più largo nella regione dei molari/premolari. Tuttavia sono frequenti problemi di altezza della cresta, e il seno mascellare alloggia talvolta apici dei secondi premolari e dei primi molari. Per tale motivo, dato che secondo i criteri di Adell et al<sup>1</sup>, si richiedono 6 mesi di guarigione nel mascellare superiore prima di sottoporre gli impianti al carico oclusale e di esercitare stimoli pressori sull'osso, è stato fatto un tentativo per evitare il rischio di riassorbimento fisiologico della cresta alveolare, come avviene dopo l'estrazione attraverso la non stimolazione dell'osso e l'espansione del seno mascellare. La tecnica adottata, relativamente atraumatica, può essere considerata una variante di quella messa a punto da Summers<sup>33</sup>. In questa situazione l'utilizzo di una fresa trephine (ACE, Brockton, MA, Fig. 7) dello stesso diametro dell'impianto era giustificato dalla necessità di preservare il setto alveolare originario, che altrimenti sarebbe andato perso a causa della pressione esercitata dagli osteotomi.

Generalmente le strategie più comuni adottate per evitare il riassorbimento alveolare sono gli innesti alveolari, GBR, o una combinazione di entrambe queste tecniche. Nello studio in questione l'uso di un omo-innesto di idrossiapatite semisintetica è stato paragonato a quello di una membrana riassorbibile. Per la prima metodica si preferisce solitamente estrarre osso autologo dal cavo orale, ma considerando che l'alveolo è un difetto favorevole con 5 pareti e un'elevata capacità rigenerativa si può anche utilizzare un materiale che si riassorba alla stessa velocità con cui avviene la neoformazione di osso nella zona periferica dell'alveolo. Il prodotto usato in questo gruppo (Biossitate) è un materiale alloplastico a riassorbimento controllato. La sua caratteristica fondamentale e innovativa è la presenza non soltanto di idrossiapatite (88%), ma anche di collagene (9,5%), che stimola la fibrinogenesi e inibisce la dispersione di cellule di idrossiapatite e di condroitina-4-solfato (2,5%), un glicosamminoglicano che consente una concentrazione sufficiente di fosfato di calcio per la nucleazione minerale. Per tale motivo il Biossitate sembrerebbe essere sia osteoconduttivo che osteoinduttivo<sup>34,37</sup>.

In tutti i casi esaminati tranne uno è stata ottenuta una guarigione clinica soddisfacente, senza reazioni di cor-



pi estranei e con formazione rapida di osso, come si può dedurre da ripetuti esami radiografici. L'insuccesso dell'impianto nella regione del secondo molare superiore di sinistra, ancora prima del carico funzionale, era probabilmente riconducibile al posizionamento della vite nell'osso morbido (tipo 4), il che sembrerebbe essere un fattore di rischio per il successo impiantare<sup>38,39</sup>. Nonostante la densità dell'osso fosse difficile da valutare, è probabile che l'osso del paziente fosse poco denso vista la facilità con cui la parte terminale della fixture si è impegnata al suo interno.

La base per la GBR consiste invece nell'esclusione selettiva di tessuto connettivo extrascheletrico dalla regione alveolare durante la fase di guarigione, data la sua più lenta velocità di turnover cellulare<sup>33</sup>. L'inserimento di una barriera tra l'osso e il tessuto connettivo può impedire la penetrazione del tessuto all'interno dell'alveolo, per cui gli osteociti non devono competere e possono riempire lo spazio intorno all'impianto. Le membrane riassorbibili posizionate nel gruppo MR, derivate dalla combinazione di copolimeri riassorbibili dell'acido poliglicolico e dell'acido polilattico, hanno consentito l'integrazione ottimale dei tessuti e sono state riassorbite entro 16-24 settimane, cioè in tempi di maturazione dell'osso normali. Il vantaggio principale relativo all'uso di membrane riassorbibili sta nel poter evitare una seconda operazione per rimuovere le membrane. Nei pazienti trattati con questa tecnica l'esame radiografico ha mostrato il riempimento osseo completo intorno agli impianti. I due insuccessi riportati nel gruppo MR, entrambi sulla stessa persona, sono da imputare molto probabilmente non alla tecnica ma ai precedenti di cisti odontogene, oltre al fatto che il paziente fumava oltre 10 sigarette al giorno; il fumo non era considerato un criterio di esclusione per questo studio. Ai pazienti è stato chiesto di smettere di fumare almeno nelle due settimane immediatamente dopo l'intervento.

In entrambi i gruppi un fattore fondamentale per il successo è stato dato dalla guarigione dei lembi per prima intenzione, garantita dalle suture Gore-Tex. Queste suture consentono la massima stabilità del coagulo e mantengono una tensione iniziale stabile<sup>40</sup>. Nei casi in cui non era possibile l'uso di questa sutura, è stata impiegata colla di fibrina (Tissucol), in grado di stimolare i processi riparativi grazie alla capacità di interagire con i meccanismi di coagulazione. Con le due

procedure chirurgiche adottate, gli impianti inseriti in alveoli di recente estrazione in combinazione con un biomateriale riassorbibile hanno fatto registrare una percentuale di successo a 4 anni del 98,2%; mentre la percentuale per gli impianti inseriti in alveoli di recente estrazione in combinazione con una membrana riassorbibile era del 96,4%. Albrektsson et al.<sup>2</sup> hanno suggerito che per definire soddisfacente una protesi su impianti la percentuale di successo a 5 anni dovrebbe essere almeno dell'85%. Sulla base di tale criterio entrambi i metodi possono essere considerati soddisfacenti.

## Conclusioni

Questo studio ha presentato le percentuali di successo degli impianti a 4 anni dall'inserimento, pari al 98,2% per impianti inseriti in alveoli di recente estrazione con idrossiapatite sintetica riassorbibile e del 96,4% per impianti inseriti in alveoli di recente estrazione in combinazione con una membrana riassorbibile. I risultati suggeriscono dunque che entrambe le strategie applicate nel corso di questa indagine per sostituire i denti posteriori nel mascellare superiore o nella mandibola possono essere utilizzate con successo per il supporto a lungo termine di una protesi parziale fissa.

## Autori:

Loris Prosper, Dipartimento di Riabilitazione Orale, Università "Vita e Salute", Ospedale San Raffaele, Milano, Italia.

Enrico F. Gherlone, Professore Associato, Dipartimento di Riabilitazione Orale, Università "Vita e Salute", Ospedale San Raffaele, Milano, Italia.

Sara Redaelli, Libero professionista, Monza, Italia

Manlio Quaranta, Professore, Dipartimento di Protesi Dentaria, Università "La Sapienza", Roma.

Indirizzo per la corrispondenza:

Loris Prosper, Via San Gottardo 84, 20052 Monza (Mi) - Fax: 039 3627766, e-mail: lorisprosper@tin.it

## 10 Prosper/Gherlone/Redaelli/Quaranta - Follow-up a quattro anni di impianti con diametro maggiore...

## Bibliografia

- Adell R, Lekholm U, Rockler B, Brånemark PI. A 15-year study of osseointegrated implants in the treatment of the edentulous jaw. *Int J Oral Surg* 1981;10:387-416.
- Albrektsson T, Zarb GA, Worthington P, Eriksson AR. The long-term efficacy of currently used dental implants: A review and proposed criteria of success. *Int J Oral Maxillofac Implants* 1986;1:1-25.
- Zarb GA, Schmitt A. The longitudinal clinical effectiveness of osseointegrated dental implants. The Toronto study. Part I. Surgical Results. *J Prosthet Dent* 1989;63:451-457.
- Atwood D. Protraction changes in the adult mandible as illustrated by microradiograph of midsagittal section and serial cephalometric roentgenograms. *J Prosthet Dent* 1963;13:810-816.
- Ulri C, Solar T, Bihout R, Matejka M, Gruber H. Reduction of the compact and cancellous bone substances of the edentulous mandible caused by resorption. *Oral Surg Oral Med Oral Pathol* 1992;74:131-136.
- Carsson GE, Persson G. Morphologic changes of the mandible after extraction and wearing of dentures. *Odontol Rev* 1967;18:27-54.
- Bahat O. Treatment planning and placement of implants in the posterior maxillae: Report of 732 consecutive Nobelpharma implants. *Int J Oral Maxillofac Implants* 1993;8:151-161.
- Dahlin C, Gottlow L, Lindhe A, Nyman S. Healing of maxillary and mandibular bone defects using membrane technique. An experimental study in monkeys. *Scand J Plast Reconstr Surg* 1990;24:13-18.
- Dahlin C, Lekholm U, Becker W. Treatment of fenestration and dehiscence bone defect around oral implant using the guided tissue regeneration technique: A prospective multicenter study. *Int J Oral Maxillofac Implants* 1995;3:312-318.
- Dahlin C, Lindhe A, Gottlow J, Nyman S. Healing of bone defects by guided tissue regeneration. *Scand J Plast Reconstr Surg* 1988;81:672-676.
- Dahlin C, Sennerby L, Lekholm U, Lindhe A, Nyman S. Generation of new bone around titanium implants using a membrane technique: An experimental study in rabbits. *Int J Oral Maxillofac Implants* 1989;4:19-25.
- Jovanovic SA, Giovanoli JL. New bone formation by the principle of guided tissue regeneration for periimplant osseous lesion. *J Periodontol* 1992;11:29-36.
- Van Steenberghe D, Lekholm U, Bolender C. The application of osseointegrated oral implants in the rehabilitation of partial edentulism: A prospective multicenter study on 558 fixtures. *Int J Oral Maxillofac Implants* 1990;5:272-280.
- Zarb CA, Schmitt A. The longitudinal clinical effectiveness of osseointegrated dental implants in posterior partially edentulous patients. *Int J Prosthodont* 1993;6:189-196.
- Dennissen HW, Kalk W, Veldhuis HAH, Van Mass MAJ. *Oral Maxillofac Implants* 1993;8:191-196.
- Watzek G, Haider R, Mersdorf-Pouilly N, Haas R. Immediate and delayed implantation for complete restoration of the jaw comparing different types of serial immediate implantation. *Int J Maxillofac Implants* 1995;10:561-567.
- Becker W, Becker B. Guided tissue regeneration for implants placed into extraction sockets and for implant dehiscences: Surgical technique and case reports. *Int J Periodontics Restorative Dent* 1990;10:377-391.
- Brägger U, Hämmerle CHF, Lang NE. Immediate transmucosal implants using the principle of guided tissue regeneration. II. A cross-sectional study comparing the clinical outcome 1 year after immediate to standard implant placement. *Clin Oral Implants Res* 1996;7:268-276.
- Lang NP, Brägger U, Hämmerle CH, Suter E. Immediate transmucosal implants using the principle of guided tissue regeneration. I. Rationale, clinical procedure and 30-month results. *Clin Oral Implants Res* 1994;5:154-163.
- Lazzara RJ. Immediate implant placement into extraction sites: Surgical and restorative advantages. *Int J Periodontics Restorative Dent* 1989;9:333-343.
- Nyman S, Lang NP, Buser D, Brägger U. Bone regeneration adjacent to titanium dental implants using guided tissue regeneration: A report of two cases. *Int J Oral Maxillofac Implants* 1990;5:9-14.
- Mozzati M, Roggia S. L'utilizzo della BioSite in Odontostomatologia. *Pratica odontoiatrica* 1991;5:52-58.
- Schieer P, Boyne PJ. Maintenance of alveolar bone through implantation of bone graft substitutes in tooth extraction sockets. *J Am Dent Assoc* 1987;114:594-597.
- Bahat O, Deeb C, Golden T, Tomarnyckij O. Preservation of ridges utilizing hydroxyapatite. *Int J Periodontics Restorative Dent* 1987;7:35-41.
- Salama H, Salama M. The role of orthodontic extrusive remodeling prior to implant placement: A systematic approach to the management of extraction site defects. *Int J Periodontics Restorative Dent* 1993;13:313-333.
- Becker W, Dahlin C, Becker BE. The use of ePTFE barrier membranes for bone promotion around titanium implants placed into extraction sockets: A prospective multicenter study. *Int J Oral Maxillofac Implants* 1994;9:31-40.
- Langer B, Langer L, Hermann L. The wide fixture: A solution for special bone situation and rescue for the compromised implant. Part 1. *Int J Oral Maxillofac Implants* 1993;8:400-408.
- Lazzara R. Criteria for implant selection. *Pract Periodontics Aesthetic Dent* 1994;6:56-62.
- Aldecoa EA. Scelta del tipo di impianto. Impianti di differenti diametri. In: Aldecoa EA (ed.) *Nuove tecniche di chirurgia e protesi su impianti*. Victoria: Puesta al Dia Publicaciones 1998:26-28.
- Balshi TJ, Hernandez RE, Prizlak MC, Ranger B. A comparative study of one implant versus two replacing a single molar. *Int J Oral Maxillofac Implants* 1996;11:372-378.
- Bahat O, Handelsman M. Use of wide implants and double implants in the posterior jaw: A clinical report. *Int J Oral Maxillofac Implants* 1996;11:379-386.
- Chehrhadi B, McDonnell D, Brunette DM. The effects of micro-machined surfaces on formation of bone-like tissue on subcutaneous implants as assessed by radiography and computer image processing. *J Biomed Mater Res* 1997;34:279-290.
- Summers RB. A new concept in maxillary implant surgery: The osteotome technique. *Compend Contin Educ Dent* 1994;15:152-160.
- Bouvier M, Joffre A, Magloire H. In vitro mineralization of a three-dimensional collagen matrix by human dental pulp cells in the presence of chondroitin sul fate. *Arch Oral Biol* 1990;35:301-309.
- Bouvier M, Couble ML, Haruann DJ, Gauthier JP, Magloire H. Ultrastructural and immunocytochemical study of bone-derived cells cultured in three-dimensional matrices: Influence of chondroitin-4-sulfate on mineralization. *Differentiation* 1990;45:128-137.



36. Palatella G. Utilizzazione della Biotite nel ripristino osseo per il posizionamento di impianti. *Video Rivista di Implantologia e Chirurgia Orale* 1992;6:21-22.
37. Lo Bianco F, Parodi C, Spinato S, Lo Bianco L. Rigenerazione ossea e parodontale: l'uso di nuovi biomateriali. *Dent Cadmos* 1993;40-61.
38. Schwartz Z, Martin JD, Dean DD, Cochran DL, Simpson J, Boyan BD. Effect of titanium surface roughness on chondrocyte proliferation, matrix production, and differentiation depends on the state of cell maturation. *J Biomed Mater Res* 1996;30:340-350.
39. Zitzmann NU, Studer SP, Roger N, Wang J, Schärer P. L'ampliamento delle indicazioni in implantologia vale grazie all'impiego di fixture di diametro maggiore: Risultati preliminari di uno studio clinico. *Quintessenza Int* 1997;7/8:221-230.
40. Checchi L, Armandi M, Franchi M. materiali per accostare i margini delle ferite. In: Checchi L, Armandi M, Franchi M. *Le suture chirurgiche in odontoiatria*. Bologna Edizioni Martina 1995:22-29.

## Four-year Follow-up of Larger-Diameter Implants Placed in Fresh Extraction Sockets Using a resorbable Membrane or a Resorbable Alloplastic Material

Loris Prosper, MD/Enrico F. Gherone, MD, MS/Sara Redaelli, DDS/Manlio Quaranta, MD, MS

**Purpose:** The aim of this randomized study was to evaluate and compare the long-term success rates of cylindrical, screw-type titanium implants with a large diameter (5.9 mm) that were placed in fresh extraction sockets in association with resorbable bone substitutes or a resorbable membrane. **Materials and Methods:** Eighty-three partially edentulous adult patients, selected from among those treated in 1997 and 1998 at the San Raffaele Institute in whom 1 or more implants had been placed into fresh posterior mandibular or maxillary sockets, were included in the study. A total of 111 implants were placed, 36 in mandibles and 75 in maxillae. Fifty-six implants were placed in combination with resorbable hydroxyapatite (HA group) and 55 with a resorbable membrane (MR group). Intraoral radiographs and follow-up examinations, including verification of implant stability via the Periotest, were carried out at second-stage surgery 3, 6, 9 and 12 months later; and then annually up to 4 years after placement of the definitive restoration. The radiographic examination was conducted by means of a standardized procedure to verify osseointegration. **Results:** There was 100% attendance at the follow-up examination after 4 years. At second-stage surgery, which was performed after 4 to 6 months' healing time, none of the implants showed any signs of mobility, peri-implantitis, or bone loss. Two implants failed in the MR group, one at 3 months and one at 9 months after placement; 1 implant failed in the HA group at 4 months after placement. After 4 years, the implant success rate was 97.3% (108 of 111 implants were considered successful). The success rate did not differ significantly between the HA group (98.2%) and the MR group (96.4%). **Discussion:** The use of larger -diameter implants served to minimize the anatomic discrepancies that would have evolved when substituting a molar with a standard - diameter implant. According to the accepted criteria for success, the 5-year success rate should be at least 85%; therefore both methods may be considered satisfactory. **Conclusion:** Implants placed in combination with a resorbable allogeneic material or with a resorbable membrane provided predictable long-term results when restored with a fixed partial denture. *INT J ORAL MAXILLOFAC IMPLANTS* 200; 18:856-864

**Key words:** Artificial membranes; Dental implants; Guided tissue regeneration; Hydroxyapatites; Tooth extraction.



**1 4 Year follow-up of larger diameter implants placed in fresh extraction sockets using a resorbable membrane or a resorbable alloplastic material**

L. Prosper, E. F. Gherlone, S. Redaelli, M. Quaranta

JOMI The international journal of oral & maxillofacial implants volume 18- number 6

---

**2 A system for the diagnosis, placement, and prosthetic restoration of root form implants (U.S. Patent # 5,769,636)**

F. Di Sario

Journal of PROTHODONTICS volume 12 - number 1 March

20  
03

THE INTERNATIONAL JOURNAL OF  
**ORAL & MAXILLOFACIAL IMPLANTS**



OFFICIAL JOURNAL OF THE ACADEMY OF OSSEointegration

Volume 18 • Number 6 • 2003

## Four-year Follow-up of Larger-Diameter Implants Placed in Fresh Extraction Sockets Using a Resorbable Membrane or a Resorbable Alloplastic Material

Loris Prosper, MD<sup>1</sup>/Enrico F. Gherlone, MD, MS<sup>2</sup>/Sara Redaelli, DDS<sup>3</sup>/Manlio Quaranta, MD, MS<sup>4</sup>

**Purpose:** The aim of this randomized study was to evaluate and compare the long-term success rates of cylindrical, screw-type titanium implants with a larger diameter (5.9 mm) that were placed in fresh extraction sockets in association with resorbable bone substitutes or a resorbable membrane. **Materials and Methods:** Eighty-three partially edentulous adult patients, selected from among those treated in 1997 and 1998 at the San Raffaele Institute in whom 1 or more implants had been placed into fresh posterior mandibular or maxillary sockets, were included in the study. A total of 111 implants were placed, 36 in mandibles and 75 in maxillae. Fifty-six implants were placed in combination with resorbable hydroxyapatite (HA group) and 55 with a resorbable membrane (MR group). Intraoral radiographs and follow-up examinations, including verification of implant stability via the Periotest, were carried out at second-stage surgery 3, 6, 9, and 12 months later, and then annually up to 4 years after placement of the definitive restoration. The radiographic examination was conducted by means of a standardized procedure to verify osseointegration. **Results:** There was 100% attendance at the follow-up examination after 4 years. At second-stage surgery, which was performed after 4 to 6 months' healing time, none of the implants showed any signs of mobility, peri-implantitis, or bone loss. Two implants failed in the MR group, one at 3 months and one at 9 months after placement; 1 implant failed in the HA group at 4 months after placement. After 4 years, the implant success rate was 97.3% (108 of 111 implants were considered successful). The success rate did not differ significantly between the HA group (98.2%) and the MR group (96.4%). **Discussion:** The use of larger-diameter implants served to minimize the anatomic discrepancies that would have evolved when substituting a molar with a standard-diameter implant. According to the accepted criteria for success, the 5-year success rate should be at least 85%; therefore both methods may be considered satisfactory. **Conclusion:** Implants placed in combination with a resorbable alloplastic material or with a resorbable membrane provided predictable long-term results when restored with a fixed partial denture. *INT J ORAL MAXILLOFAC IMPLANTS* 2003;18:856-864

**Key words:** artificial membranes, dental implants, guided tissue regeneration, hydroxyapatites, tooth extraction

A number of scientific works have shown the predictability of osseointegrated implant dentistry that complies with the biologic principles proposed by

Adell and others.<sup>1-3</sup> Among these principles was the need for complete healing of the alveolar bone before placing an implant into a fresh extraction socket, a process that usually requires from 6 to 12 months.<sup>1-3</sup> However, it has been observed that during this period, 44% or more<sup>4,5</sup> of the alveolar ridge can be resorbed, mostly in the first 6 months.<sup>6</sup> The degree of resorption generally depends on the dental region involved, on the lapse of time after extraction, and in some cases on the pressure exerted by the patient's removable denture.<sup>5</sup> This bone loss can prompt the clinician to introduce guided bone regeneration (GBR) techniques or the placement of implants 8 mm or less in length. Both situations have been associated with a lower rate of long-term implant success.<sup>7-14</sup>

<sup>1</sup>Visiting Professor, Oral Rehabilitation Department, University "Vita e Salute," Scientific Institute, San Raffaele Hospital, Milan, Italy.

<sup>2</sup>Professor, Oral Rehabilitation Department, University "Vita e Salute," Scientific Institute, San Raffaele Hospital, Milan, Italy.

<sup>3</sup>Private Practice, Monza, Italy.

<sup>4</sup>Professor, Prosthodontic Department, "La Sapienza" University, Rome, Italy.

**Reprint requests:** Dr Loris Prosper, Via San Gottardo 84, I-20052 Monza, Milan, Italy. Fax: +39-039-362766. E-mail: lorisprosper@tin.it

Some authors have argued that many advantages can result from placing dental implants into a fresh extraction socket. For example, it is easier to position them because of existing reference points, and they can be placed in some regions that are not suitable for a fixed restoration. It is also possible to preserve the alveolar bone and contour of the ridge and possibly reduce the risk of sinus penetration in the maxillary posterior region.<sup>15,16</sup> Moreover, further advantages for the patient include not only a shorter treatment time, reduction in the number of surgical appointments, and less morbidity, but also from better esthetic results related to optimal implant placement.

The introduction of GBR techniques has permitted the use of membranes in combination with implant placement in fresh extraction sockets.<sup>17-21</sup> The use of membranes to isolate the gingival epithelium and the connective tissue cells of the healing site can lead to an increase in osteogenesis, to stronger bone filling, and to osseointegration.<sup>10,17,20,21</sup> Recently, to avoid collapse of the alveolar ridge, the use of hydroxyapatite alloplastic graft materials<sup>22-24</sup> has been suggested, since this is a compound that is regarded as a good bone substitute in maxillofacial surgery.

From a clinical and practical point of view, it would be important to evaluate the existence of any differences among these bone-regeneration techniques when assessing long-term success, especially when implants are placed in fresh extraction sockets. In the current dental literature, there is a lack of experimental studies that have been carried out especially for examination of this problem. The aim of this study was to compare the potential for bone filling and success of osseointegration after 4 years around dental implants with a larger (5.9-mm) diameter that were placed directly into fresh extraction sockets in the posterior regions of the maxilla and mandible, in association with a resorbable membrane or with resorbable alloplastic materials.

## MATERIALS AND METHODS

In this randomized study, 83 adult patients, who needed 1 or more teeth in the posterior regions of the mouth extracted and replaced with dental restorations, were evaluated. The 44 women and 39 men, with an average age ( $\pm$  SD) of  $46.2 \pm 14.3$  years, were selected from among those treated in 1997 and 1998, according to the following admission criteria: age between 21 and 75 years; compliance with home oral hygiene standards; extraction because of caries, dental fracture, periodontitis, or

endodontic treatment failure; presence of a sufficiently wide, fresh extraction socket such that even after placement of a 5.9-mm-diameter implant there would still be a residual bone defect; and occlusion suitable for planned prosthodontic treatment. The criterion for exclusion was the presence of any dysmetabolic, chronic, and/or infectious disease. A detailed explanation of the treatment plan was given to each patient, and informed written consent was required for participation in the research.

All implants were sandblasted, commercially pure titanium (Bioactive Covering, Winsix, London, United Kingdom), in the form of a self-threading cylindrical screw, with a diameter of 5.9 mm and a length of 11 or 13 mm (Fig 1, Table 1). The fresh extraction sockets were categorized as type 1 in the Salama preoperative classification<sup>25</sup>:

- Postextraction pocket with 4 walls and minimal bone resorption
- Presence of 3 to 5 mm of bone below the implant apex
- Acceptable discrepancy ( $< 2$  mm) between the head of the implant and the cemento-enamel junction of the adjacent teeth, if present, or the most coronal part of the socket
- Treatable gingival recession

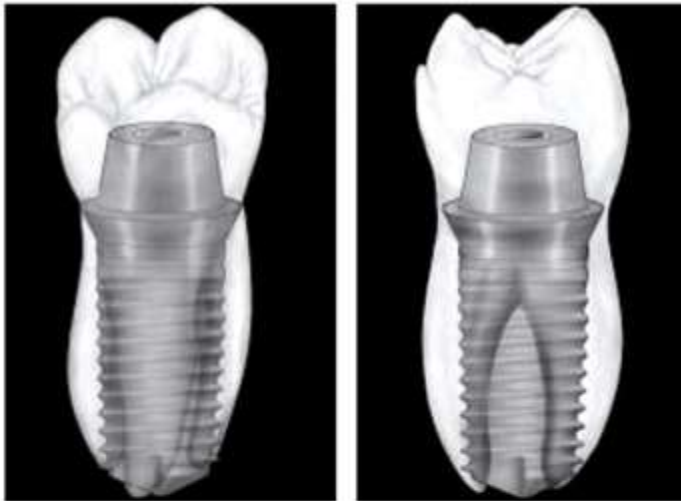
In terms of marginal bone loss, the fresh extraction sockets were assigned to the classes A1 (no loss of periodontal attachment), B1 (loss of no more than one third of periodontal attachment), or C1 (loss of no more than half of periodontal attachment) according to the classification of Becker and coworkers.<sup>26</sup>

The patients were divided randomly into 2 groups: patients in the HA group received implants in combination with the use of synthetic hydroxyapatite (56 implants; Biosite; Vebas, Milan, Italy), and patients in the MR group received implants combined with a bioabsorbable membrane based on polyglycolic and polylactic acid copolymers (55 implants; Osseoquest; W.L. Gore, Flagstaff, AZ). Preoperative radiographic examinations included an orthopantomograph and periapical radiographs for evaluation of the anatomic residual ridge. A complete prosthetic evaluation leading to the fabrication of an appropriate prosthetic restoration was conducted.

All surgical and prosthodontic procedures were carried out by the same clinician. A total of 111 implants were placed, 36 in the mandible and 75 in the maxilla (Tables 1 and 2).



PROSPER ET AL



**Figs 1a and 1b** The head of the implant should reflect the diameter of the teeth to be replaced. (Left) Anterior and (right) sagittal views of a standard molar.

**Table 1** Implant Distribution According to Patient Sex, Implant Location, and Implant Length

Patient group/ location	Implant length	
	11 mm	13 mm
Female patients		
Maxillary right first molar	—	9
Maxillary right second molar	—	13
Maxillary left first molar	—	14
Maxillary left second molar	—	11
Mandibular left first molar	2	6
Mandibular right first molar	3	4
Total	5 (8.1%)	57 (91.9%)
Male patients		
Maxillary right first molar	—	10
Maxillary right second molar	—	8
Maxillary left first molar	—	10
Maxillary left second molar	—	7
Mandibular left first molar	—	3
Mandibular right first molar	2	9
Total	2 (4.1%)	47 (95.9%)

No significant difference was found in distribution by length according to the sex of the patient ( $P > .030$ ).

### Surgical Procedures

The extractions were carried out atraumatically under local anesthesia, avoiding raising flaps, preserving the papillae, and where necessary, resorting to root resection to avoid destroying the alveolar septa. All traces of attached soft tissue were removed from the sockets using instruments, and then the apical portions of the socket itself were prepared to receive implants according to the instructions provided by the manufacturer. The biologic width of the adjacent teeth, if present, was considered, along

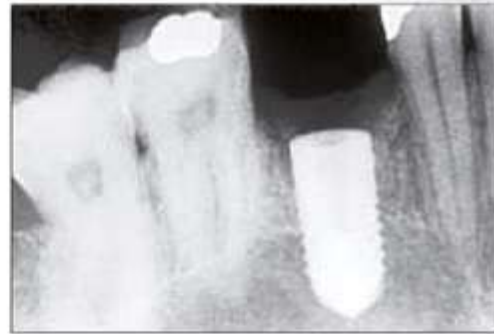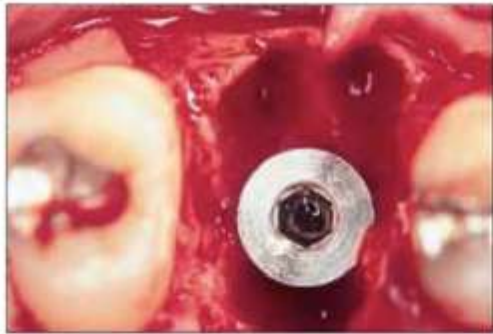
**Table 2** Implant Distribution in the 2 Groups of Patients

Implant location	Group	
	HA (n = 56/50.4%)	MR (n = 55/49.6%)
Maxilla		
Right first molar	7 (6.3%)	7 (6.3%)
Right second molar	11 (9.9%)	10 (9.1%)
Left first molar	12 (10.8%)	12 (10.8%)
Left second molar	8 (7.2%)	8 (7.2%)
Mandible		
Right first molar	8 (7.2%)	9 (8.1%)
Right second molar	—	1 (0.9%)
Left first molar	8 (7.2%)	8 (7.2%)
Left second molar	2 (1.8%)	—

No significant difference was seen between groups HA and MR ( $P > .981$ ).

with a projected average bone resorption rate of 1 to 1.5 mm for the first year after implant placement. To prevent exposure of the implant's polished neck, the implants were positioned 2 mm apical to the marginal bone level. Thus the implant sites were overcontoured by 2 mm. In the posterior regions, especially in first molar areas, miniature sinus lifts were performed: The residual bone was cored with a 6-mm trephine bur to reach approximately 1 mm from the schneiderian membrane, and then the membrane was lifted some 2 mm with slight pressure.

PROSPER ET AL



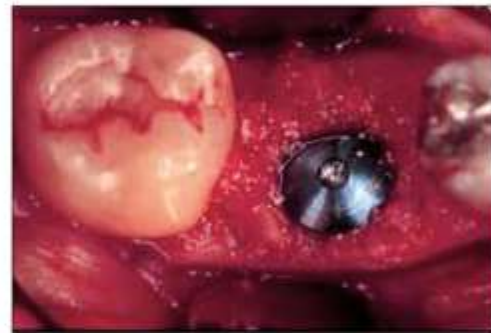**Figs 2a and 2b** Case 1. Placement of the implant into the socket, with the coronal portion 2 mm more apically than the level of the bony ridge crest, immediately after tooth-extraction. (Left) Occlusal view; (Right) periapical radiograph.

Following this, the aim was to place the implants in the center of the residual alveolar cavity, so as to be equidistant from the bony walls (Figs 2a and 2b).

In the HA group at this stage, the graft was located in direct contact with the bleeding bone surface and the material was condensed to eliminate any bubbles (Fig 3). For the MR group, after the clinician raised a full-thickness flap, the membrane was placed in complete contact with the surface surrounding the socket area, avoiding contact between the mesial and distal edges and nearby teeth, where present, and extending its design to cover at least 3 mm of bone crest at the level of the buccal and lingual surfaces (Fig 4).

Particular attention was paid to suturing; the surgeon tried to appose the 2 flaps by first intention with horizontal mattress sutures (Gore-Tex; W. L. Gore, Flagstaff, AZ), used vertical or interrupted sutures for papillae, and resorted to fibrin glue (Tissucol; Immuno, Pisa, Italy) where necessary. After surgery, a radiograph was obtained to document the existing relationship between the implant and the bony socket (Figs 5a and 5b). This was followed by a prescription for 1 g of amoxicillin plus clavulanate potassium (Augmentin; Smithkline Beecham, New York, NY) every 12 hours for 6 days and 100 mg of nimesulide when required. In addition, postoperative rinsing twice a day with 0.2% chlorhexidine digluconate (Dentosan Mese; Pagni Raffaello, Florence, Italy) and the topical application of a corticosteroid/chlorhexidine-based gel (Corsodyl; Smithkline Beecham Farm, Bollate, Italy) were prescribed for 2 weeks following surgery. The week after surgery, sutures were removed and dental prophylaxis was introduced as appropriate.

The patients were then seen once a week for the next 3 weeks for prophylaxis, instruction in oral hygiene, and monitoring of the healing process (Fig



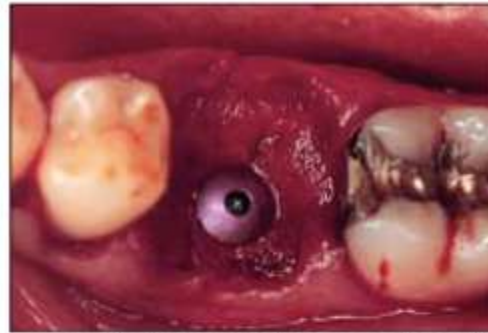**Fig 3** Case 2. Biostite was plugged between the walls of the socket and the implant.

6a). During this time patients were restricted from using removable provisional partial dentures to avoid traumatizing the treated area, since the dentures were not esthetically required. Subsequently, patients received postsurgical therapy once a month (mandibular implant patients for 3 months; maxillary implant patients for 5 months). After 4 and 6 months, respectively, second-stage surgery was performed for implant exposure (Fig 6b), and periapical radiographs were obtained to document healing status.

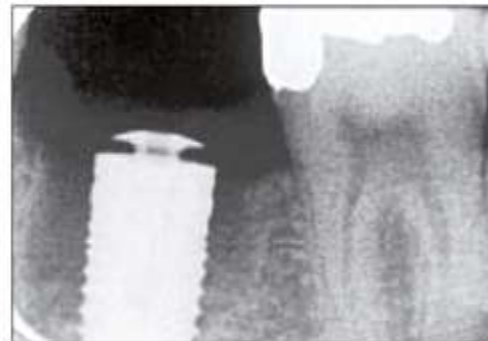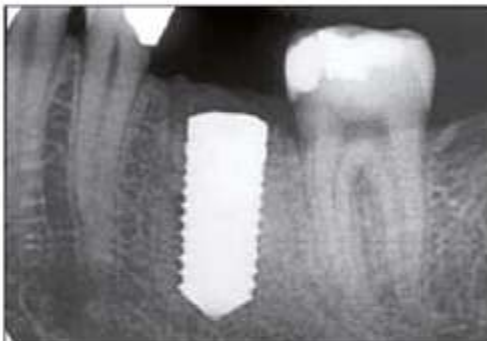#### Follow-up Evaluations

After the definitive restoration was placed, all patients were invited to attend planned clinical follow-up appointments every 3 months for an overall period of 4 years from the time of implant placement. During these appointments, an objective examination of soft tissues was carried out, the marginal precision between restoration and abutment was evaluated using a microscope at 4 $\times$  magnification, and if necessary, corrections were made. In

PROSPER ET AL

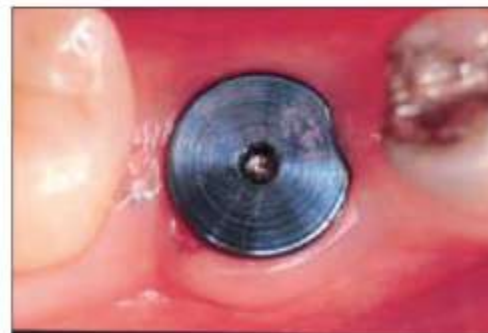
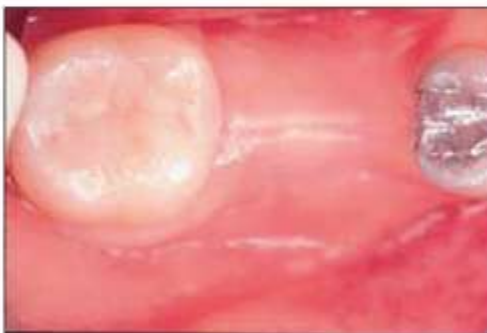
**Figs 4a and 4b** Case 3. The membrane was cut and positioned so as to cover both the dental implant and the surrounding bone. (Left) Occlusal view of the surgical site; (right) membrane with inserted pin for anchorage.



**Fig 5a** Case 2. Radiograph of the implant taken immediately after placement in the socket, during the first surgical stage. In the coronal third, the condensation of the biomaterial is clearly visible.

**Fig 5b** Case 3. Radiograph of the implant taken immediately after placement in the socket, during the first surgical stage. In the coronal third, a radiolucent space is clearly visible, given the non-opacity of the membrane.



**Fig 6a** Case 2. Healing of hard and soft tissues at 3 month follow-up.

**Fig 6b** Case 2. Implant exposure and placement of the healing screw.



this context, the patient's oral hygiene was also verified. To assess the osseointegration of all implants, a protocol was established, including mobility testing by means of Periotest (Siemens, Bensheim, Germany) and periapical radiographs (Digora; Soredex, Helsinki, Finland), which were carried out on every patient at 3, 6, 9, and 12 months and then annually until the fourth year. The degree of resorption of bone tissue was evaluated, using for reference the level of the bony ridge crest and the circular ring located 1.4 mm from the edge of the implant at the mesial and distal positions. Implant success was defined on a radiographic basis, in accordance with the criteria of Albrektsson and associates.<sup>2</sup>

#### Statistical Analysis

The results are presented as a number and/or percentage of observations. For continuous variables, comparisons between the 2 groups of implants were done using the Student *t* test for nonmatching data. The chi-square test and the Fisher exact test were used to compare discrete variables. *P* values below .05 were considered to indicate statistical significance (2-tailed test).

## RESULTS

The distribution in terms of age and sex did not differ between the 2 groups of patients, who were also comparable in terms of the linear dimensions of the implants and the area of the mouth under consideration ( $P > .839$ ) (Table 1).

At the end of the healing period, at implant exposure, no implants showed visible signs of mobility, peri-implant infection, or bone loss. In particular, all Periotest values were in a range from -5 to 0 for both the HA and MR implant groups. The distance between the groove of the implant neck and the first visible part of the bone did not prove to be significantly different between the 2 implant groups, varying from 0.70 to 0.80 mm in the HA group and from 0.73 to 0.80 mm in the MR group ( $P = .772$ ).

Table 2 shows, for the 2 groups of patients, the distribution of implants according to area of placement. Distribution was comparable in the 2 groups ( $P > .981$ ). There was 100% attendance at the follow-up after 4 years. The overall incidence of implant success 4 years after placement was 97.3% and did not differ significantly between the HA group (98.2%) and the MR group (96.4%) ( $P = .986$ ).

The 2 implant failures in the MR group occurred in the same patient; one took place in the mandibular right first molar region before loading, and the

other happened in the mandibular left first molar region 3 months after loading. There were no particular inflammatory reactions, only a loss of implant stability. Possible relevant factors included the patient's history of previous odontogenic cysts and a smoking pattern of more than 10 cigarettes per day. The only failure in the HA group occurred with an implant in the maxillary left second molar region in a patient with low-density bone.

## DISCUSSION

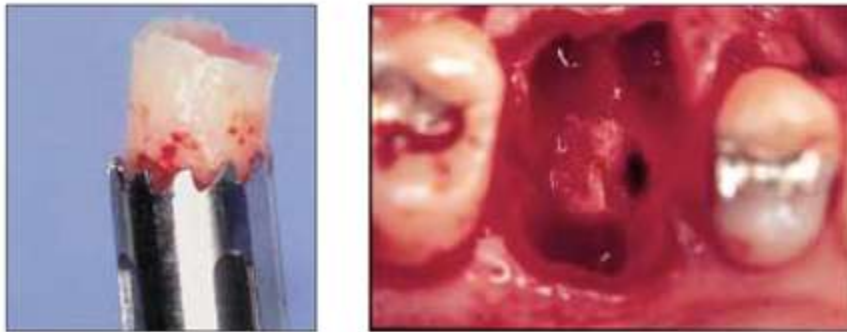
The main aim of this investigation was to evaluate the osseointegration success of implants with a larger diameter when placed into fresh extraction sockets in combination with a resorbable biomaterial or with a resorbable membrane.

The use of larger-diameter implants served to minimize the anatomic discrepancies that would have come about when substituting a molar with a standard-diameter implant.<sup>27,28</sup> Problems with a standard-diameter implant could involve not only the emergence profile, but also screw loosening, breakages, or a lack of primary stability.<sup>29-31</sup> The discrepancy between the cross-section of the implant and that of the tooth root is often the cause of marked undercuts at the emergence profile level, an area that can be inaccessible for hygiene purposes. Furthermore, an unbalanced relationship can result relative to the larger diameter (10 to 12 mm) of the crown in a mesiodistal direction, along with multiplication of the flexure moments exerted on the implant by the application of eccentric loads, which can cause fractures in the coronal part of the implant.<sup>32</sup> The use of 5.9-mm-diameter implants made it possible to increase stability and to almost completely fill postextraction defects, thus enhancing the prognosis.

The rationale behind the slight lifting of the sinus for implants placed in posterior maxillary areas is seen in the evidence that the alveolar process is wider in the molar/premolar region. However, often there are ridge height problems, and the maxillary sinus sometimes hosts apices of the second premolars and first molars. Therefore, given that according to the criteria of Adell and associates<sup>3</sup> 6 months of healing are required in the maxilla before loading the implants and exerting pressure stimuli on the bone, an attempt was made to avoid the risk of physiologic resorption of the alveolar ridge, as occurs after extraction through lack of bone stimulation and the expansion of the maxillary sinus. The technique used, which is relatively atraumatic, may be considered a variation of that developed by Summers.<sup>33</sup> In the present experience, the use of a



PROSPER ET AL



**Figs 7a and 7b** Case 1. (Left) Trephine bur that was used to drill the maxillary bone in conjunction with a mini-sinus lift; (right) surgical application.

trephine bur (ACE, Brockton, MA) (Fig 7) with the same diameter as the implant was justified by the need to preserve the septum of the original dental socket, which would otherwise have been lost because of the pressure exerted by osteotomes.

Generally, the most commonly used strategies for avoiding alveolar resorption are alveolar grafts, GBR, or a combination of these. In the study in question, the use of semisynthetic hydroxyapatite allograft was compared to the use of a resorbable membrane. For the first method, usually autologous bone taken from intraoral sites is preferred, but considering that the socket is a favorable defect, having 5 walls and high regenerative capacity, it is also suitable to use a material that resorbs at the same pace at which new bone formation occurs in the peripheral site of the socket. The product used in this group (Biostite) is a controlled-resorption alloplastic material. Its fundamental and innovative characteristic is the presence not only of hydroxyapatite (88%) but also of collagen (9.5%), which stimulates fibrinogenesis and inhibits the dispersion of hydroxyapatite cells and of chondroitin-4-sulfate (2.5%), a glycosaminoglycan that allows a sufficient concentration of calcium phosphate for mineral nucleation. Thus Biostite would seem to be both osteoconductive and osteoinductive.<sup>34-37</sup>

In all but one of the cases examined, satisfactory clinical healing was attained, without any foreign body reaction and with rapid bone formation, as far as can be deduced from repeated radiographic examination. Failure of the implant in the maxillary left second molar region, even before functional loading, was probably related to the fact that it was placed in soft (type 4) bone, which would appear to be a risk factor for implant success.<sup>38,39</sup> Although it was difficult to evaluate bone density, it is probable that this patient's bone was of low density, judging

by the ease with which the terminal part of the implant engaged.

The basis for GBR, on the other hand, consists of the selective exclusion of extraskelatal connective tissue from the alveolar area during the healing phase, as it has a slower cellular turnover rate.<sup>33</sup> Insertion of a barrier between the bone and the connective tissue can prevent penetration of this into the socket, and thus bone cells do not have to "compete" and can fill the space around the implant. The resorbable membranes placed in the MR group, which were derived from the combination of resorbable copolymers of polyglycolic and polylactic acid, allowed optimum tissue integration and were resorbed within 16 to 24 weeks, ie, within usual bone maturation times. The main advantage of using resorbable membranes is that a second operation for removal of the membranes can be avoided. In patients treated with this method, radiographic examination showed complete bone filling around the implants. The 2 failures reported in the MR group, both in the same patient, are most probably not the result of technique, but of the patient's previous history of odontogenic cysts, as well as, perhaps, to the fact that she smoked over 10 cigarettes per day. Smoking was not an exclusion criterion for this study. The patients were asked to stop smoking for at least the first 2 weeks immediately following implant placement.

In both groups a fundamental factor in success was the achievement of healing of the flaps by first intention, ensured by means of Gore-Tex sutures. These allow maximum clot stability and maintain stable initial tension.<sup>40</sup> In cases where this was not possible, fibrin glue was used (Tissucol); this can stimulate reparative processes because of its ability to interact with coagulation mechanisms. With the 2 surgical procedures adopted, the combination of implants placed in fresh extraction sockets with a

resorbable biomaterial resulted in a 4-year success rate of 98.2%, while that for implants placed in fresh extraction sites combined with a resorbable membrane was 96.4%. Albrektsson and associates<sup>2</sup> suggested that for an implant procedure to be considered satisfactory, the 5-year success rate should be at least 85%. Using this criterion, both methods may be considered to be satisfactory.

## CONCLUSIONS

This study showed implant success rates, at 4 years after implant placement, of 98.2% for implants placed in fresh extraction sockets in combination with resorbable synthetic hydroxyapatite and 96.4% for implants placed in fresh extraction sockets in combination with a resorbable membrane. The results, therefore, suggest that both strategies used in this investigation to replace posterior teeth in either the maxilla or mandible can be successfully used for long-term support of fixed partial dentures.

## REFERENCES

- Adell R, Lekholm U, Rockler B, Brånemark P-I. A 15-year study of osseointegrated implants in the treatment of the edentulous jaw. *Int J Oral Surg* 1981;10:387-416.
- Albrektsson T, Zarb GA, Worthington P, Eriksson AR. The long-term efficacy of currently used dental implants: A review and proposed criteria of success. *Int J Oral Maxillofac Implants* 1986;1:1-25.
- Zarb GA, Schmitt A. The longitudinal clinical effectiveness of osseointegrated dental implants. The Toronto study. Part I. Surgical results. *J Prosthet Dent* 1989;63:451-457.
- Atwood D. Postextraction changes in the adult mandible as illustrated by microradiographs of midsagittal section and serial cephalometric roentgenograms. *J Prosthet Dent* 1963;13:810-816.
- Ulm C, Solar T, Blahout R, Matejka M, Gruber H. Reduction of the compact and cancellous bone substances of the edentulous mandible caused by resorption. *Oral Surg Oral Med Oral Pathol* 1992;74:131-136.
- Carlsson GE, Persson G. Morphologic changes of the mandible after extraction and wearing of dentures. *Odontol Rev* 1967;18:27-54.
- Bahat O. Treatment planning and placement of implants in the posterior maxillae: Report of 732 consecutive Nobelpharma implants. *Int J Oral Maxillofac Implants* 1993;8:151-161.
- Dahlin C, Gottlow J, Lindhe A, Nyman S. Healing of maxillary and mandibular bone defects using a membrane technique. An experimental study in monkeys. *Scand J Plast Reconstr Surg* 1990;24:13-18.
- Dahlin C, Lekholm U, Becker W. Treatment of fenestration and dehiscence bone defects around oral implants using the guided tissue regeneration technique: A prospective multicenter study. *Int J Oral Maxillofac Implants* 1995;3:312-318.
- Dahlin C, Lindhe A, Gottlow J, Nyman S. Healing of bone defects by guided tissue regeneration. *Scand J Plast Reconstr Surg* 1988;81:672-676.
- Dahlin C, Sennerby L, Lekholm U, Lindhe A, Nyman S. Generation of new bone around titanium implants using a membrane technique: An experimental study in rabbits. *Int J Oral Maxillofac Implants* 1989;4:19-25.
- Jovanovic SA, Giovannoli JL. New bone formation by the principle of guided tissue regeneration for periimplant osseous lesions. *J Periodontol* 1992;11:29-36.
- Van Steenberghe D, Lekholm U, Bolender C. The application of osseointegrated oral implants in the rehabilitation of partial edentulism: A prospective multicenter study on 558 fixtures. *Int J Oral Maxillofac Implants* 1990;5:272-280.
- Zarb CA, Schmitt A. The longitudinal clinical effectiveness of osseointegrated dental implants in posterior partially edentulous patients. *Int J Prosthodont* 1993;6:189-196.
- Dennisen HW, Kalk W, Veldhuis HAH, Van Mass MAJ. Anatomic considerations for preventive implantation. *Int J Oral Maxillofac Implants* 1993;8:191-196.
- Watzek G, Haider R, Mensdorf-Pouilly N, Haas R. Immediate and delayed implantation for complete restoration of the jaw following extraction of all residual teeth: A retrospective study comparing different types of serial immediate implantation. *Int J Oral Maxillofac Implants* 1995;10:561-567.
- Becker W, Becker B. Guided tissue regeneration for implants placed into extraction sockets and for implant dehiscences: Surgical techniques and case reports. *Int J Periodontics Restorative Dent* 1990;10:377-391.
- Brigger U, Hämmerle CHF, Lang NE. Immediate transmucosal implants using the principle of guided tissue regeneration. II. A cross-sectional study comparing the clinical outcome 1 year after immediate to standard implant placement. *Clin Oral Implants Res* 1996;7:268-276.
- Lang NP, Brigger U, Hämmerle CH, Sutter E. Immediate transmucosal implants using the principle of guided tissue regeneration. I. Rationale, clinical procedure and 30-month results. *Clin Oral Implants Res* 1994;5:154-163.
- Lazzara RJ. Immediate implant placement into extraction sites: Surgical and restorative advantages. *Int J Periodontics Restorative Dent* 1989;9:333-343.
- Nyman S, Lang NP, Buser D, Brigger U. Bone regeneration adjacent to titanium dental implants using guided tissue regeneration: A report of two cases. *Int J Oral Maxillofac Implants* 1990;5:9-14.
- Mozzati M, Roggia S. L'utilizzo della Biosite in Odontostomatologia. *Practica odontoiatrica* 1991;5:52-58.
- Scheer P, Boyne PJ. Maintenance of alveolar bone through implantation of bone graft substitutes in tooth extraction sockets. *J Am Dent Assoc* 1987;114:594-597.
- Bahat O, Deeb C, Golden T, Komarnyckij O. Preservation of ridges utilizing hydroxyapatite. *Int J Periodontics Restorative Dent* 1987;7:35-41.
- Salama H, Salama M. The role of orthodontic extrusive remodeling in the enhancement of soft and hard tissue profiles prior to implant placement: A systematic approach to the management of extraction site defects. *Int J Periodontics Restorative Dent* 1993;13:313-333.
- Becker W, Dahlin C, Becker BE. The use of ePTFE barrier membranes for bone promotion around titanium implants placed into extraction sockets: A prospective multicenter study. *Int J Oral Maxillofac Implants* 1994;9:31-40.

## PROSPER ET AL

27. Langer B, Langer I, Herrmann L, Jorneus L. The wide fixture: A solution for special bone situations and rescue for the compromised implant. Part 1. *Int J Oral Maxillofac Implants* 1993;8:400-408.
28. Lazzara R. Criteria for implant selection. *Pract Periodontics Aesthet Dent* 1994;6:56-62.
29. Aldecoa EA. Scelta del tipo di impianto. Impianti di differenti diametri. In: Aldecoa EA (ed). *Nuove tecniche di chirurgia e protesistru su impianti*. Vitoria: Pueta al Dia Publicaciones, 1998:26-28.
30. Balshi TJ, Hernandez RE, Prizlak MC, Rangert B. A comparative study of one implant versus two replacing a single molar. *Int J Oral Maxillofac Implants* 1996;11:372-378.
31. Bahat O, Handelsman M. Use of wide implants and double implants in the posterior jaw: A clinical report. *Int J Oral Maxillofac Implants* 1996;11:379-386.
32. Cherhroudi B, McDonnell D, Brunette DM. The effects of micromachined surfaces on formation of bonelike tissue on subcutaneous implants as assessed by radiography and computer image processing. *J Biomed Mater Res* 1997;34:279-290.
33. Summers RB. A new concept in maxillary implant surgery: The osteotome technique. *Compend Contin Educ Dent* 1994;15:152-160.
34. Bouvier M, Joffre A, Magloire H. In vitro mineralization of a three-dimensional collagen matrix by human dental pulp cells in the presence of chondroitin sulfate. *Arch Oral Biol* 1990;35:301-309.
35. Bouvier M, Couble ML, Harunann DJ, Gauthier JP, Magloire H. Ultrastructural and immunocytochemical study of bone-derived cells cultured in three-dimensional matrices: Influence of chondroitin-4-sulphate on mineralization. *Differentiation* 1990;45:128-137.
36. Palattella G. Utilizione della Biotite nel ripristino osseo per il posizionamento di impianti. *Video Rivista di Implantologia e Chirurgia Orale* 1992;6:21-22.
37. Lo Bianco F, Parodi C, Spinato S, Lo Bianco L. Rigenerazione ossea e parodontale: L'uso di nuovi biomateriali. *Dent Cadmos* 1993;10:40-61.
38. Schwartz Z, Martin JD, Dean DD, Cochran DL, Simpson J, Boyan BD. Effect of titanium surface roughness on chondrocyte proliferation, matrix production, and differentiation depends on the state of cell maturation. *J Biomed Mater Res* 1996;30:340-350.
39. Zitzmann NU, Studer SP, Roger N, Wang J, Scharer P. Ampliamento delle indicazioni in implantologia vale grazie all'impiego di fixture di diametro maggiore: Risultati preliminari di uno studio clinico. *Quintessenz Int* 1997; 7/8:221-230.
40. Checchi L, Armandi M, Franchi M. Materiali per accostare i margini delle ferite. In: Checchi L, Armandi M, Franchi M. *Le suture chirurgiche in odontoiatria*. Bologna: Edizioni Martina, 1995:22-29.



## TECHNIQUES AND TECHNOLOGIES

# A System for the Diagnosis, Placement, and Prosthetic Restoration of Root Form Implants (U.S. Patent #5,769,636)

Francesco Di Sario, DDS

It is difficult to achieve a high degree of reproducibility when using a diagnostic wax-up as the template for fabrication of a definitive implant restoration. Here a method for implant prosthesis treatment planning is described that allows fabrication of the provisional restoration before surgical placement of the implant. The method involves 6 steps: (1) determining the mesiodistal inclination of the implant, (2) determining the buccolingual dimension of the alveolar ridge, (3) determining the proper position of the implant, (4) fabricating the surgical guide, (5) fabricating the provisional restoration, and (6) performing surgical placement of the implant followed by immediate placement of the provisional restoration.

*J Prosthodont* 2003;12:2-7. Copyright © 2003 by The American College of Prosthodontists.

**INDEX WORDS:** reproducibility, immediate loading, template, guide pins

VARIOUS PREOPERATIVE planning strategies have been proposed to enable dentists to place implants in a manner that facilitates prosthodontic therapy.<sup>1,2</sup> These techniques are used to support decision making during the surgical phase rather than to determine the definitive position of the implant.<sup>3</sup> Because the ultimate goal is a properly positioned and properly supported restoration,<sup>4</sup> a clinical procedure that produces exact surgical placement of the implant and allows preplacement fabrication of the provisional restoration is desirable. Ideally, this procedure would duplicate the restoration's form and position on the master cast, allowing direct transfer to the patient's mouth. Such a system, which does not call for advanced radiographic techniques or computer programs, is described in this article.

### Technique

The replacement of tooth #13 is described.

*Private practice, Canosa Sannita, Italy.*

*Accepted September 24, 2002.*

*Originally presented at a poster session of The American College of Prosthodontists meeting, Kona, Hawaii, November 2000.*

*Correspondence to Dr. Francesco Di Sario, Via Garibaldi 29, Canosa Sannita 66010, Italy. E-mail: francesco.disario@tin.it.*

*Copyright © 2003 by The American College of Prosthodontists*

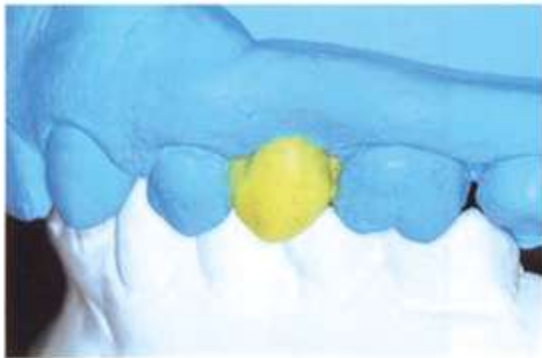
*1059-941X/03/1201-0002\$30.00/0*

*doi:10.1053/jpro.2003.4*

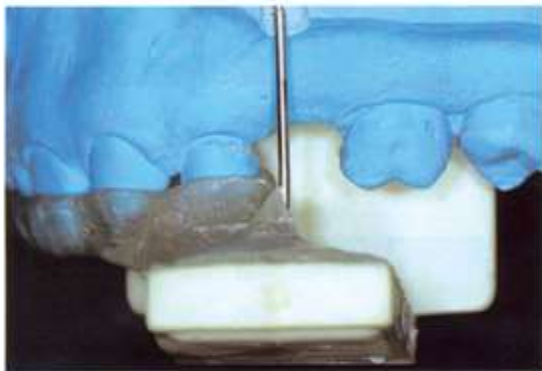
*Step 1: Determining the mesiodistal inclination.* First, a diagnostic wax-up is made (Fig 1). The implant position is simulated by a radiopaque post incorporated into a radiographic stent (Fig 2). The radiographic stent is then transferred to the patient's mouth, and a periapical radiograph is obtained to check whether the position of the post is consistent with the position of adjacent roots and the available bone (Fig 3). If the mesiodistal inclination is considered satisfactory, then the stent is returned to the master cast, which is then sectioned buccolingually through the long axis of the post (Fig 4). During cast fabrication, the cast is pinned using the Pindex system (Coletene/Whaledent, Mahwah, NJ), allowing accurate repositioning of sectioned pieces.

*Step 2: Determining the buccolingual dimension of the alveolar ridge.* With the distal section of the cast removed, the outline of the alveolar crest is transferred to the cross-sectioned cast with the aid of a bone-measure stent. The stent is fabricated to hold tubes at multiple buccal and palatal locations along the alveolar ridge (Fig 5). Under local anesthesia, the tubes are used to guide placement of a probe into contact with the underlying bone. Measurements from the top of the tubes to the bone are directly transferred via the stent to the previously cross-sectioned cast. The buccolingual outline of the

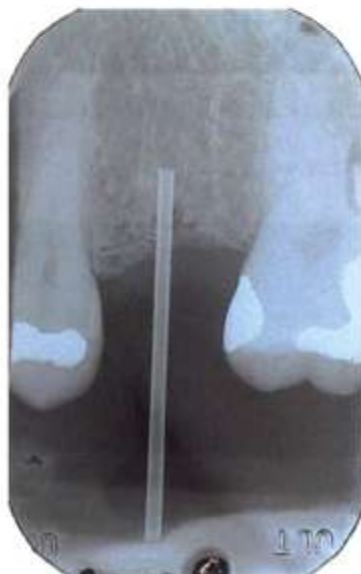



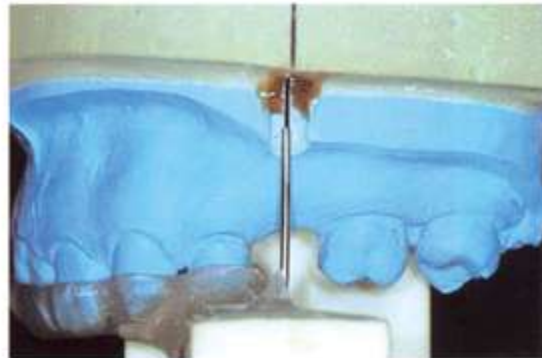**Figure 1.** A diagnostic wax-up is completed in the first phase of implant diagnosis.



**Figure 2.** The radiographic stent is fabricated, incorporating a radiopaque post and a film holder.



**Figure 3.** The periapical radiograph shows the position of the post with respect to the adjacent roots.



**Figure 4.** The radiographic stent guides the sectioning of the cast through the long axis of the post.

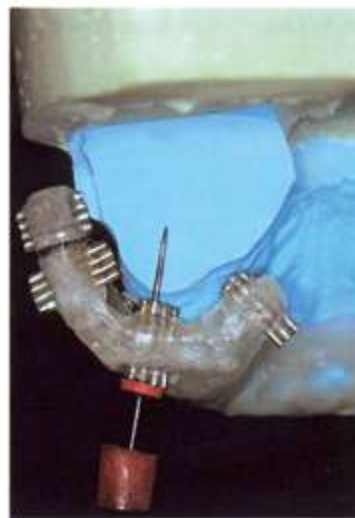
alveolar ridge is created by marking the transferred measurements (Fig 6).

*Step 3: Determining the proper position of the implant.*

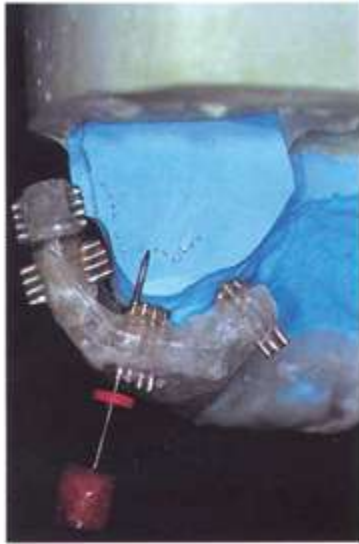
Using the diagnostically waxed tooth position and bone-dimension data, a custom implant prototype is mounted in the cross-sectioned cast, simulating the planned implant's clinical location. The square-shank end holds the cylindrical body of the custom implant prototype in place within the cast. The custom implant prototype is positioned within the buccolingual outline of the alveolar ridge (Fig 7).

*Step 4: Fabricating the surgical guide.*

The surgical guide contains a matched series of 4 circular metal sleeves. The first sleeve (sleeve A) is seated



**Figure 5.** The bone-measure stent is composed of single tubes that guide a probe fitted with a stopper.

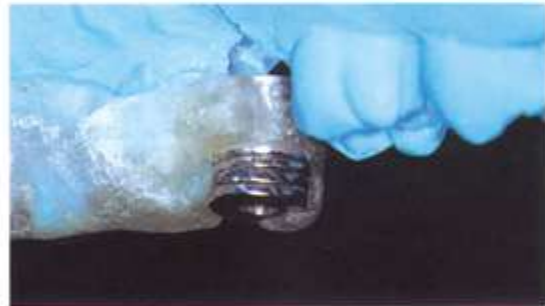

**Figure 6.** The single-probing measurements are marked on the cross-sectioned cast.

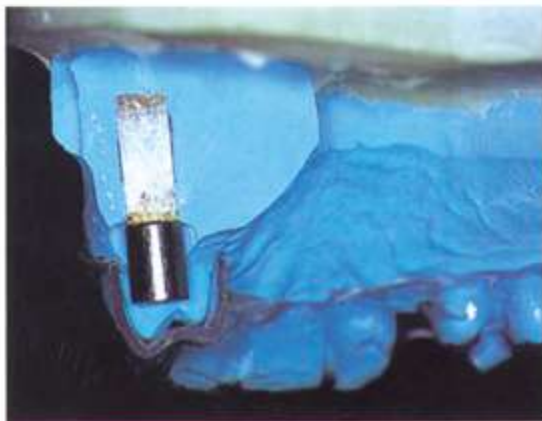

**Figure 8.** A metal sleeve (sleeve A) is attached to the frame during the fabrication of the surgical stent.

onto the custom implant prototype and incorporated into the acrylic resin surgical guide using autopolymerizing resin (Dentaplast KFO; Brent, Senden, Germany) (Fig 8). The custom implant prototype is then removed from the cross-sectioned cast. When the surgical guide is placed intraorally, sleeve A is correctly positioned in space to assist the clinical transfer of the planned implant's location from the cast to the mouth. Sleeves B, C, and D fit within each other and within sleeve A and are held together via an internal locking system (Figs 9 and 10). At the



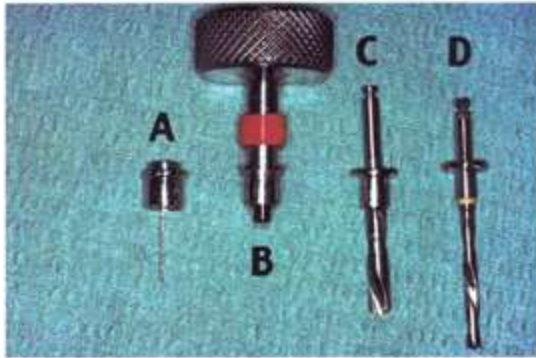
**Figure 9.** Three additional sleeves are assembled onto sleeve A.



**Figure 7.** The prototype implant analog is mounted on the cross-sectioned cast within the limitations of the bone.



**Figure 10.** Additional sleeves (B, C, and D) are attached to sleeve A. The sleeves can be removed 1 at a time.



**Figure 11.** The sleeve components used in the fabrication of the surgical guide are shown; sleeve A is marked. The implant fixture mount inside of sleeve B is identified by the letter "B". A 3-mm-diameter drill within sleeve C is identified by the letter "C"; a 2-mm-diameter drill within sleeve D, by the letter "D".

time of implant placement, the 3 progressively widening sleeves guide the precise delivery of a 2-mm-diameter drill (sleeve D), a 3-mm-diameter drill (sleeve C), and the implant fixture mount (sleeve B) (Fig 11).

*Step 5: Fabricating the provisional restoration.* The provisional restoration is fabricated before surgical placement of the implant. With sleeves C and D temporarily removed, the surgical guide is seated on the cast. The distance between the shoulder of sleeve B and the top of the bony crest is mea-

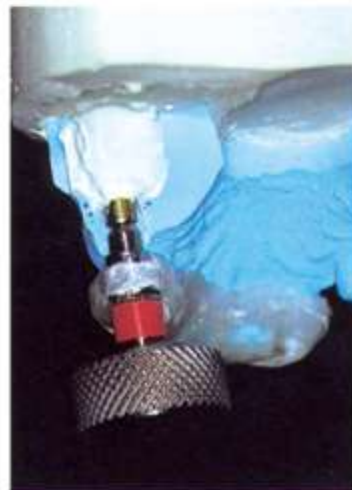

**Figure 12.** The distance between the bone crest and the sleeve shoulder is recorded.



**Figure 13.** The analog is connected to the fixture mount (Winsix Ltd.), with the red band guiding placement depth.

sured and recorded (Fig 12). A laboratory analog (Winsix Ltd., London, UK) is connected to the mount (Fig 13) and positioned through sleeve B to the previously recorded depth. The analog is fixed in place in the cast with plaster (Super stone; Techim Italia s.r.l., Arese, Italy) (Fig 14). Thus the analog is positioned in the cast to simulate the clinical placement of the implant when the top of implant is level with the crest of the bone. The fixture mount and the surgical stent are then removed. After a provisional abutment is attached to the analog, the provisional restoration is fabricated (Fig 15).



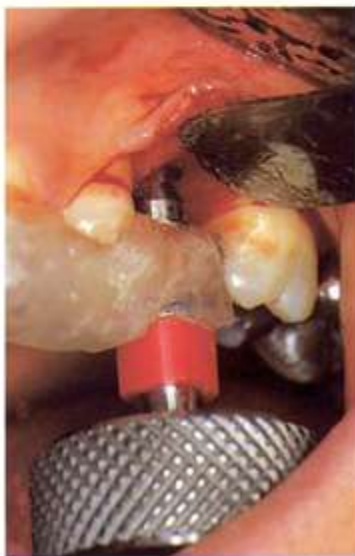**Figure 14.** The analog is affixed with plaster.



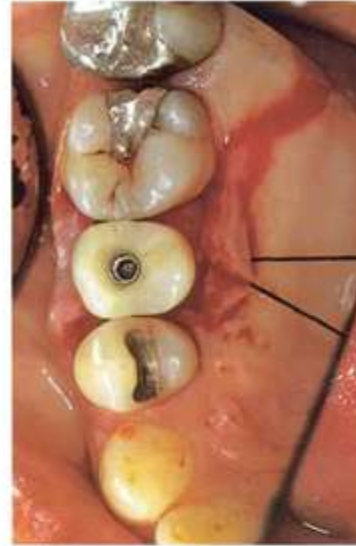


**Figure 15.** The provisional restoration is completed using a hybrid ceramic (Estenia hybrid ceramic; Kuraray Co. Ltd., Tokyo, Japan).

*Step 6: Performing surgical placement of the implant followed by immediate placement of the provisional restoration.* At stage 1 surgery, the surgical stent is seated intraorally. The surgical drills are delivered through the surgical guide using sleeves C and D. The implant (Winsix Ltd.) is placed through sleeve B (Fig 16) using the fixture mount. Once the implant is properly placed, the



**Figure 16.** The implant is placed through sleeve B.

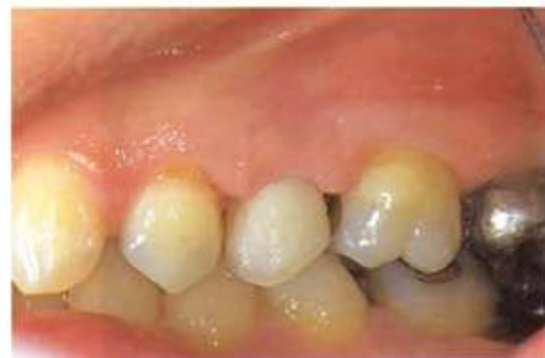

**Figure 17.** The provisional restoration is screwed onto the implant for immediate loading.

provisional restoration is screwed onto the implant (Fig 17). The provisional restoration provides immediate loading and verifies the accuracy of the implant-placement system. The resulting restoration (Fig 18) is positioned consistent with the original wax-up (Fig 1).

### Summary

The basic concept behind this technique is that an implant should be planned with the same approach as a conventional fixed prosthodontic restoration. The technique, with input into both the surgical and prosthetic phases of treatment, allows the cli-



**Figure 18.** The provisional restoration, positioned as determined by the diagnostic wax-up, is shown 2 weeks after implant placement.



nician to determine the best positioning options before implant placement.

The surgical procedures are safer, allowing possible complications, such as bone fenestration or root-to-implant proximity, to be avoided. Although 3 stents must be fabricated (i.e., radiographic, bone-measure, and surgical), the laboratory procedures are simplified because of the accuracy of the technique. In fact, the control of implant placement as demonstrated in this system makes many implant alignment-correcting and position-correcting techniques unnecessary. The system should not be used when a reduced buccolingual dimension of the bone (as determined from the probing process) necessitates a bone augmentation procedure before implant placement. For accuracy and ease of use, only custom-manufactured components, as described in this article, are recommended.

### **Acknowledgment**

The author thanks Mr. Tonino D'Alicandro for practical advice concerning the laboratory process, and Mr. Leo Cinelli and his coworkers for support and assistance in preparing this manuscript.

### **Reference**

1. Edge MJ: Surgical placement guide for use with osseointegrated implants. *J Prosthet Dent* 1987;57:719-722
2. Vorstreken K, Van Cleynenbreugel J, Marchal G, et al: Computer-assisted planning of oral implant surgery: A 3-dimensional approach. *Int J Oral Maxillofac Implants* 1996;11:806-810
3. Sicilia A, Noguerol B, Cobo J, et al: Profile surgical template, a systematic approach to precise implant placement: A technical note. *J Oral Maxillofac Implant* 1998;13:109-114
4. Higginbottom FL, Wilson TG: Three-dimensional templates for placement of root-form dental implants: A technical note. *Int J Oral Maxillofac Implant* 1996;11:787-793



**1 Sistema implantare Winsix: Case-Report  
di un monoimpianto post-estrattivo in zona estetica**

L. Prosper

(QO Quintessenza Odontotecnica anno 19 Marzo 2002 Verona)

---

**2 Osteointegrazione a 5 anni di impianti sabbiati o sabbiati e mordenzati  
ritenenti protesi parziali fisse**

L. Prosper, F. Di Carlo, I. Vozza, M. Quaranta

QI Quintessence International - versione italiana

---

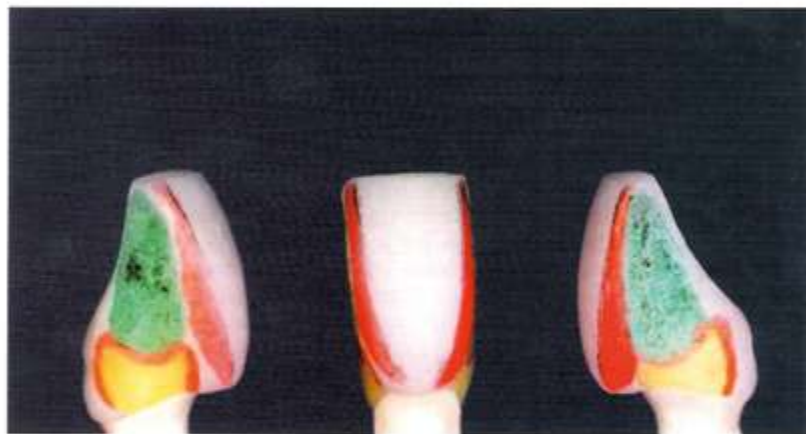
**3 La passivazione implantare diretta secondo la metodica Free Tense TM  
(Winsix Ltd, London, UK)**

S. Redaelli, L. Prosper, E. Gherlone, A. D'Addona

RESCH EDITRICE SRL - VIA BERNARDI, 9 - 37026 SETTIMO DI PESCANTINA (VR) - TEL. 045/7153688 (R.A.) - FAX 045/7153079 - E-MAIL: RESCHEDITRICE@VIRGILIO.IT

# QO

La Quintessenza Odontotecnica

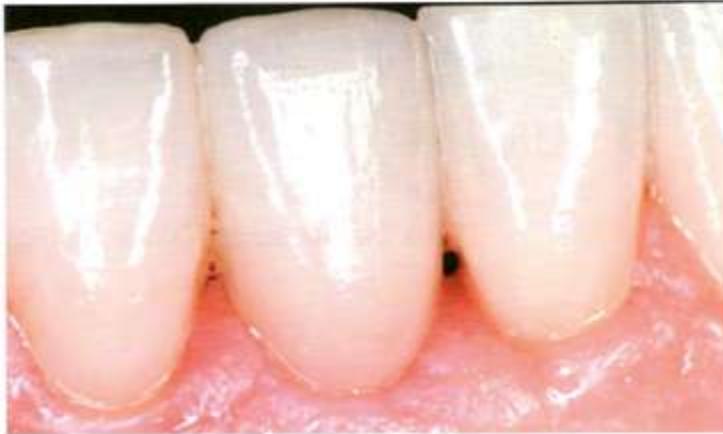

Verona • Anno 19 • Marzo 2002

# 3/2002



## CASE REPORT



In questo articolo si descrivono le possibilità cliniche e tecniche di ricostruzione di un dente singolo in zona frontale secondo il sistema computerizzato Procera su pilastri individuali per sovrafusione del sistema implantare Winsix.

## Sistema implantare Winsix: Case-Report di un monoimpianto post-estrattivo in zona estetica

Loris Prosper

Impianto per dente singolo post-estrattivo, corona interamente in ceramica, Procera, impianto Winsix, moncone per sovrafusione Winsix.

**Parole chiave**

La ricostruzione di elementi mancanti con impianti per dente singolo richiede il massimo impegno da parte di tutti gli interessati: chirurgo, protesista e odontotecnico<sup>1,2</sup>. Infatti, oltre al colore, alla forma e alla tessitura della struttura superficiale della protesi, bisogna tener conto anche delle particolarità di una ricostruzione su impianti<sup>3</sup>, come l'interfaccia tra questo e la struttura protesica, il punto di passaggio tra il margine coronale cervicale e l'abutment vero e proprio o il punto di eruzione gengivale.

**Introduzione**

I settori anteriori sono quelli maggiormente impegnativi dal punto di vista estetico, in quanto i margini delle sovrastrutture metalliche possono risultare visibili qualora non siamo di fronte ad una mucosa spessa, in grado di mascherare il colore del moncone. La possibilità di intravedere l'abutment metallico o i bordi coronali potrebbe compromettere pesantemente l'impressione estetica d'insieme. Inoltre, una colorazione azzurrigna della gengiva renderebbe difficile l'armonia cromatica della ricostruzione su impianto con il resto della dentatura.

Una possibile soluzione al problema appena descritto è data dalle cappette in ceramica di ossido di alluminio altamente resistente, realizzate con la metodica computerizzata Procera sul moncone individuale precedentemente fresato, e poi rivestite con delle ceramiche della nuova generazione (All-Ceramic, Sistema NCC<sup>®</sup>, Shofu Inc., Kyoto, Giappone).

## SPECIALE IMPLANTOPROTESI

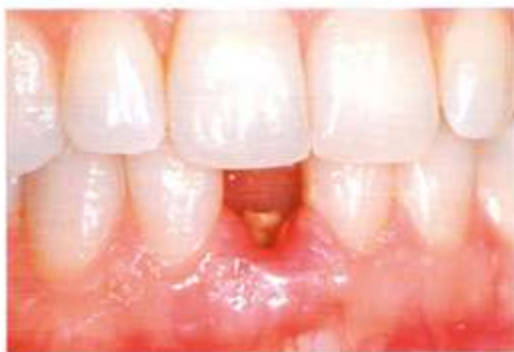

Foto 1 Caso clinico iniziale. La diagnosi è di frattura verticale dell'elemento dentale 41.

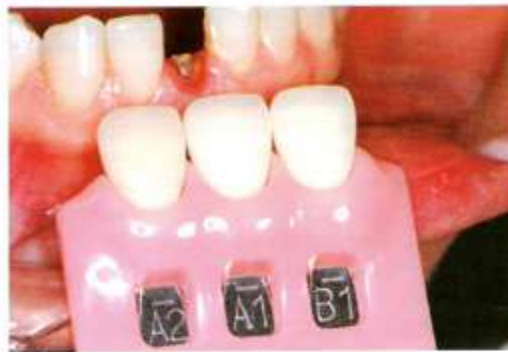

Foto 2 Suelta del colore per la corona integralmente in ceramica con il sistema NCC della Shofu.

Voglio sottolineare l'importanza, per non inficiare il risultato finale dell'implantoprotesi, della stretta collaborazione tra dentista e odontotecnico, che dovrebbe iniziare ancor prima della messa in sito degli impianti, quando si stabiliscono il tipo, il numero e la posizione degli impianti, nonché il tipo di protesi<sup>1</sup>.

#### Documentazione clinica e tecnica di un caso

Il sistema implantare Winsix (Winsix<sup>®</sup> Ltd, London, UK) si caratterizza per la risoluzione dei problemi di relazione tra l'impianto e la struttura protesica, per le tolleranze micrometriche e per la massima facilità d'uso. In particolare, la componentistica protesica è semplice e funzionale, ma al tempo stesso usufruibile in tutte le contingenze cliniche per le molteplici possibilità di configurazione dei pilastri: per provvisori, standard, preinclinati, calcinabili, per sovrافusione, per fresaggio, conici, tutti per protesi avvitate (Free Lock<sup>TM</sup>) ed, infine, per overdenture passivabile direttamente nel cavo orale (Free Tense System<sup>TM</sup>). Nel caso presente voglio illustrare dettagliatamente l'impiego di un moncone per sovrافusione, che consente la sovrافusione di qualsiasi tipo di lega ed è ideale per la costruzione di un profilo di emergenza estetico ed anatomico. Al paziente, che si è presentato alla mia attenzione per una frattura verticale della radice dell'elemento 41 (foto 1), una volta accettato il piano di trattamento di inserzione di un impianto in questa zona, sono state prese le impronte diagnostiche ed il colore per la corona da cementare sulla fixture, utilizzando la tecnica Gumy (Sistema NCC<sup>®</sup>, Shofu Inc., Kyoto, Giappone) (foto 2), che, grazie alle tre gradazioni base disponibili per la finta gengiva, considera direttamente anche gli effetti contrastanti della gengiva, nei modi appropriati e specifici per ogni paziente, nel corso della determinazione della gradazione di colore. Ricordo che presupposto di ogni lavoro implanto-protesico è la realizzazione di una ceratura diagnostica estetico-funzionale, che ci dia subito i tratti essenziali del lavoro finale<sup>2</sup>. Da notare il ruolo del tecnico anche da un punto di vista estetico, in quanto la ceratura diagnostica non serve solo per ricavare la dima chirurgica, ma accompagna tutte le fasi della ricostruzione protesica, dal confezionamento del provvisorio fino alla realizzazione della sovrastruttura definitiva. L'impianto, per fini estetici<sup>10</sup>, è stato inserito 2-3 mm apicalmente rispetto alla giunzione smalto-cemento dei denti adiacenti, affinché il margine coronale fosse ad un livello sufficientemente submarginale (foto 3). Sottolineo che il diametro dell'impianto scelto in questo caso, 3,3 mm, è ideale per tutti i denti anteriori che hanno un piccolo diametro di emergenza.

In seguito, si è provveduto al posizionamento della protesi provvisoria precedentemente preparata in laboratorio utilizzando una mascherina in silicone della ceratura come

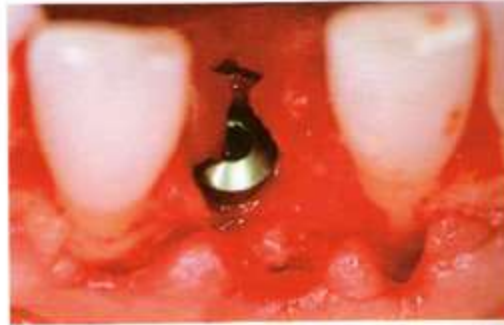

## CASE REPORT

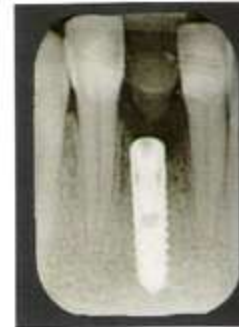riferimento, una corona in materiale composito tipo Maryland splintata ai denti adiacenti mediante Ribbond (foto 4).

Nel primo periodo dalla riapertura dell'impianto, avvenuta dopo 5 mesi, per assicurare la guarigione funzionale della mucosa, sulla fixture è stato avvitato un moncone standard ed è stato adattato, ribasandolo, il precedente provvisorio. Non appena il margine libero della mucosa perimplantare ha assunto una festonatura verosimilmente naturale, dopo circa 2 settimane, è stata rilevata l'impronta per trasferire sul modello l'esatta posizione dell'impianto e per avere un'idea di quella che sarà l'emergenza della corona. Quindi, il laboratorio ha forgiato e scannerizzato con la sonda del sistema Procera il moncone individuale per sovrافusione tipo UCLA, con connessione in platino-iridio. Allorché la cappetta in ossido di alluminio fu pronta, si è

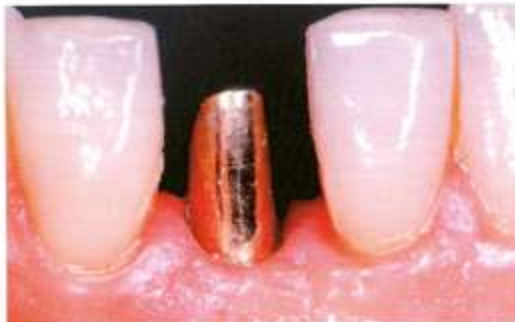proceduti alla prova in bocca del paziente del moncone definitivo, rifinito e lucidato (foto 5), e della cappetta stessa (foto 6). Nella foto 5 è possibile osservare l'attenzione posta, durante la modellazione del moncone, alla riproduzione di una forma ogivale dell'area del margine gengivale il più possibile simile a quella dei denti vicini. Per quanto riguarda la cappetta, è da sottolineare, invece, l'importanza nella scelta del suo colore: il range varia dal translucido al bianco e l'obiettivo deve essere la copertura del moncone aureo, per avere la massima trasparenza della corona. Siamo consapevoli, infatti, del fatto che il colore del dente è uno dei fattori principali che concorre a determinare il risultato estetico del manufatto. Rammento che la trasparenza è la proprietà fisica del dente che definisce il rapporto tra la luce riflessa e la luce trasmessa, dipendendo dalla diffusione della luce attraverso i diversi strati del dente. L'altro vantaggio della tecnologia del Procera, costruendo tridimensionalmente senza alcun errore sistemico il moncone scolpito dal tecnico, è il fit perfetto che si instaura tra le due sovrastrutture impiantari: l'abutment e la cappetta. Per esempio, come si percepisce nella foto 7, in questa contingenza clinica è buona la precisione tra i due elementi. Dopo l'avvitamento dell'UCLA, per i primi mesi al paziente si è fatta calzare la stessa corona provvisoria, ribasata, fissata con cemento provvisorio (Temp Bond, Kerr Manufacturing Co, Romulus, MI, USA) (foto 8). La funzione della protesi provvisoria, applicata per circa 45 giorni, era di rilevare eventuali problemi funzionali, estetici e fonetici, di esercitare un carico progressivo sull'impianto e di guidare i tessuti molli per ottenere un corretto profilo emergente.\* Come osserviamo nella foto 8,



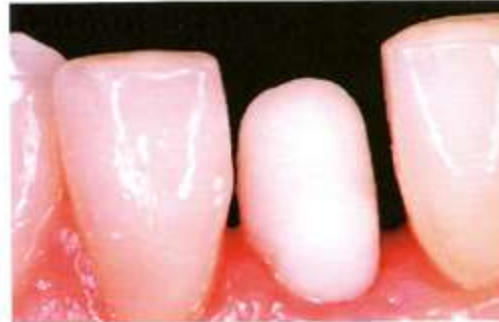**Foto 3** Impianto Wiresix di diametro 3,3 mm e lunghezza 15 mm, inserito nell'alveolo post-estrattivo. Notare la posizione della testa dell'impianto, circa 3 mm apicale alla giunzione amelo-cementizia dei denti adiacenti, per favorire l'estetica dell'emergenza della corona.



**Foto 4** Radiografia periapicale dell'impianto, che mostra il suo inserimento al di sotto della cresta ossea e il provvisorio, tipo Maryland, fissato tramite Ribbond ai denti adiacenti.



**Foto 5** Prova del moncone definitivo personalizzato, tipo UCLA.



**Foto 6** Prova della cappetta in Procera sul moncone definitivo. Possibile vincere la sua capacità coprente.

## SPECIALE IMPLANTOPROTESI



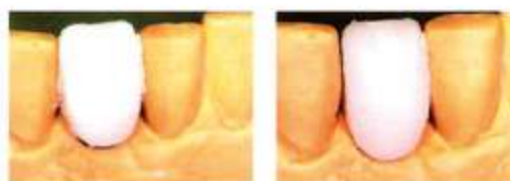**Foto 7** Immagine allo stereomicroscopio, ingrandimento a 32 X della chiusura della capretta in Procera sul moncone definitivo. Buono il livello di precisione.



**Foto 8** Provvisorio rifinito e lucidato con lacca resinosa fotopolimerizzabile: osservare la tessitura compatta e lattescente data dal trattamento.

è importante la fase di lucidatura del provvisorio mediante l'applicazione di una resina protesica fotopolimerizzabile (Plaquit, Dreve-Dentamid GmbH, Unna, Germania) che sigilla e lucida la superficie della protesi con lo scopo di non infiammare i tessuti mucosi. Intanto, non essendoci stata la necessità di rilevare una seconda impronta, il laboratorio ha confezionato la protesi definitiva in ceramica. Essenziale è stata la stratificazione delle varie masse ceramiche scegliendo la gradazione cromatica più verosimile per le varie parti del dente (foto 9). Considerando che esistono anche alcune tonalità che non possono essere riprodotte con i campioni esistenti, è necessario che il tecnico costruisca un campione su misura, che, generalmente, esegue sulla base delle indicazioni ricevute dallo studio delle diapositive che ha a disposizione. Per cercare di rendere meno soggettiva ed aleatoria quest'operazione, ci si è avvalsi del computer per colorimetria ShadeEye-NCC (Sistema NCC®, Shofu Inc., Kyoto, Giappone), in grado di identificare e rilevare rapidamente ed esattamente, indipendentemente dalla luce ambientale, il colore base dei denti naturali e di fornire la miscelazione base, il cosiddetto "Recipe" (foto 10). Particolare attenzione e scrupolosità sono state poste nella rifinitura delle creste vestibolari mesiali e distali (foto 11), che hanno un ruolo significativo per l'anatomia del dente. Rimarchevole, però, anche la differenziazione fatta tra zone di contatto mucoso, stratificate con ceramica a basso punto di fusione (880°C) (ADD-ON, Shofu Inc., Kyoto, Giappone), e zone sopragengivali, che non hanno necessitato di questa vetrificazione perché non interfacciate con i tessuti biologici (foto 12).

Di aiuto nella personalizzazione della corona è stato anche il "modello estetico", copia in poliuretano (Genius, MAX srl, Pogliano Milanese, Milano, Italia) del modello originale sull'impronta di precisione, che ha permesso la riproduzione fedele della gengiva marginale libera (foto 13,14). Infine, dopo l'ultima prova biscotto in bocca al paziente (foto 15), il lavoro definitivo è stato cementato in bocca al paziente. (foto 16). Sulla scorta di questo caso clinico e di altre esperienze similmente positive che ho maturato avvalendomi della sistematica implantare Winsix e del sistema Procera per la ricostruzione senza metallo di impianti di denti singoli, si può ipotizzare una prognosi favorevole per l'impiego di questi impianti, con questa metodica, anche in altri settori del cavo orale.



**Foto 9a-9b** Stratificazione della ceramica sulla capretta in Procera prima (foto a) e dopo (foto b) la cottura.



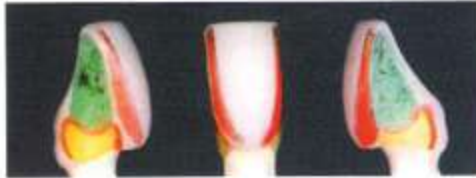**Foto 10a-10 b** Confronto tra il colore della corona integralmente in ceramica ultimata (foto a) e la ricetta - Recipe- ottenuta con il colorimetro computerizzato Shade-Eye NCC.



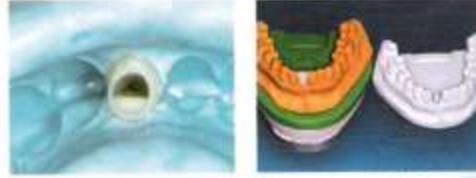
**Foto 11a-11b** Rifinitura della corona, con particolare attenzione nella caratterizzazione delle creste vestibolari mesiali (foto a) e distali (foto b).



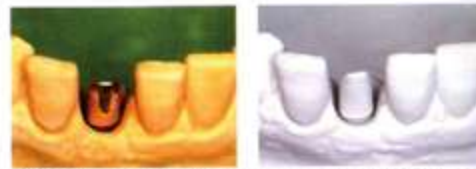## CASE REPORT



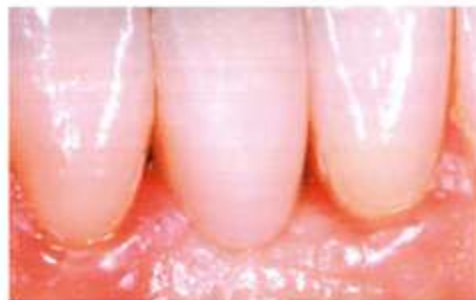**Foto 12** Diverse prospettive – interprossimali e vestibolare – per evidenziare le zone della corona: verde per le aree di contatto, rosso per l'indicazione vestibolare del contorno della cresta marginale e giallo per la zona di rispetto in prossimità della "pseudo-ampiezza biologica". Praticamente dividiamo le zone di contatto mucoso – in appoggio e sottogengivali – da quelle completamente sopragengivali: le prime vengono stratificate con ceramica a basso punto di fusione (880°C sotto vuoto all'inizio e poi 920°C in atmosfera).



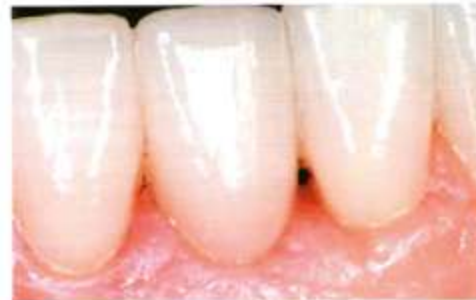**Foto 13a-13b** Copia del modello originale, in poliuretano: "modello estetico" che riproduce fedelmente la mucosa marginale.



**Foto 14a-14b** A dimostrazione dell'avvenuto condizionamento dei tessuti molli e dell'importanza del modello estetico, confronto delle mucose orali sul modello di lavoro iniziale (foto a) e sul modello estetico finale (foto b).



**Foto 15** Prova biscotto finale. Notare il leggero stato ischemico in corrispondenza solo della concavità del margine mucoso perimplantare, obiettivo della stratificazione differenziata.



**Foto 16** Lavoro finito e cementato a 15 giorni.

1. Balshi, T.J.: Candidates and requirements for single tooth prostheses. *Int J Periodontics Restorative Dent* 14, 316-331 (1994).
2. De Lange, G.L.: Aesthetic and prosthetic principles for single tooth procedures: an overview. *Pract Periodontics Aesthet Dent* 7, 51-61 (1995).
3. Holloway, J.A. and McGlumphy, E.A.: Soft tissue contouring for aesthetic single tooth restorations. *Pract Periodontics Aesthet Dent* 5, 41-48 (1993).
4. Lewis, S.G., Beumer, J.D., Peri, O.R. and Nornburg, W.P.: Single tooth implant supported restorations. *Int J Oral Maxillofac Implants* 3, 25-30 (1988).
5. Saadoun, A.P., Sullivan, D.Y., Kirschek, M. and Li G.M.: Single tooth implant-management for success. *Pract Periodontics Aesthet Dent* 6, 73-80 (1994).
6. Sullivan, D.Y. and Sherwood, R.L.: Considerations for

- successful single tooth implant restorations. *J Esthet Dent* 5, 118-124 (1993).
7. Zimmermann, D., Schuler, M.: Protesizzazioni estetiche su impianti- Finzione o realtà? *La Quintessenza Odontotecnica* 2, 107-116 (1995).
8. Chiche, G.J. and Pinault, A.: Il restauro protesico con ponti fissi sostenuti da impianti integrali. *ODT* 69-104 (1992).
9. Szub, J.R., Wikowski, S. and Einsels, F.T.: Enossale orale Implantologie aus prothetischer Sicht. Quintessenz, Berlin (1996).
10. Novins, M. and Meltoning, J.T.: *Implant Therapy: Clinical Approaches and Evidence of success*, Vol. 2, Quintessence Publishing Co., Inc. Berlin, 111-117 (1996).

## Bibliografia

Dr. Loris Prosper, Via S. Gottardo, 84 - 20052 Monza

Indirizzo Autore

QO

**WINSIX®**      **IMPLANT**      **SYSTEM**



**WINSIX**  
un incontro  
esclusivo

**BioActive Covering™**  
Trattamento di superficie  
a sabbatura differenziata.

**Free Lock™**  
La connessione  
nel perfetto equilibrio di forze  
tra impianto e monconi.

**Free Tense System™**  
La protesi avvitata  
senza tensioni.

**BioS.A.F. S.r.l.**  
Sede legale: Via Idorni, 6 - 20090 ASSAGO (MI)  
Tel: +39 02 488669 - Fax: +39 02 48869330  
Sede operativa: Via Castaldini, 24 - 45035 CASTELMASSA (PD)  
TEL: +39 0425 647329 - FAX: +39 0425 640959  
Internet: www.bio-saf.com - E-mail: info@bio-saf.com

# Quintessence International

RIVISTA BIMESTRALE DI

Dental Digest - Edizione Italiana

ODONTOSTOMATOLOGIA, IMPLANTOLOGIA, PARODONTOLOGIA  
THE INTERNATIONAL JOURNAL OF ORAL & MAXILLOFACIAL IMPLANTS

## Osteointegrazione a 5 anni di impianti sabbiati o sabbiati e mordenzati ritenenti protesi parziali fisse

Loris Prosper, MD, DMD\* / Fabio Di Carlo, MD, DMD, PhD\*\* / Iole Vozza DDS, PhD\*\* /  
Manlio Quaranta MD, MS, DMD\*\*

### SOMMARIO

Lo scopo di questa indagine randomizzata è stato di valutare e di confrontare l'incidenza di successo implantare a lungo termine di impianti di titanio, cilindrici e a vite, sabbiati (SL) o sabbiati e mordenzati (SLA) ritenenti protesi parziali fisse. Nella ricerca sono stati inseriti quarantaquattro pazienti adulti di ambedue i sessi, di età compresa tra 21 e 75 anni, selezionati tra quelli trattati durante il 1995 presso l'Istituto di Clinica odontoiatrica di Roma, ai quali erano stati inseriti nei settori posteriori della mandibola o del mascellare superiore, 2 o 3 impianti. Ventitre, sono stati i pazienti controllati e sui quali erano stati inseriti impianti solo sabbiati (SL); ventuno quelli con impianti sabbiati e mordenzati (SLA). In totale sono stati inseriti 107 impianti (54 SL, 53 SLA), 62 nella mandibola e 45 nel mascellare superiore. Il periodo di quiescenza dei siti implantari è stato di 4 mesi per gli impianti inseriti nella mandibola e di 6 mesi per quelli inseriti nel mascellare superiore. Al momento della riapertura e dell'applicazione delle viti di guarigione la mobilità implantare è stata saggiata mediante Periotest. Dopo l'inserimento della protesi fissa definitiva la precisione marginale tra la protesi e l'abutment è stata verificata con microscopio a 4x; successivamente, sono state eseguite radiografie periapicali e controlli a 3, 6, 9 e 12 mesi e quindi con frequenza annuale fino al quinto anno dalla protesizzazione definitiva. Il controllo radiografico è stato eseguito con procedura standardizzata in modo da permettere il rilevamento del grado di osteointegrazione, considerando come punto di repere l'incavo di riferimento collocato ad 1,4 mm dal margine dell'impianto. Il follow-up a 5 anni è stato del 100%. Alla riapertura dei siti implantari, successiva al periodo di guarigione di 4-6 mesi, nessun impianto ha mostrato segni di mobilità, perimplantite o perdita ossea. Sette impianti sono stati persi nel gruppo SLA, a 2 anni dal loro posizionamento; 6 sono stati persi a causa di perimplantite e 1 solo per trauma oclusale. Dopo 5 anni, il successo implantare, definito secondo i criteri di Albrektsson (1986), si è verificato in 100/107 (93,4%) impianti, ed è stato più elevato tra gli impianti SL (100%) che tra quelli SLA (86,8%) ( $p < 0,01$ ). Sia gli impianti sabbiati sia quelli sabbiati e sottoposti a mordenzatura hanno riportato risultati soddisfacenti a lungo termine nella riabilitazione mediante protesi parziale fissa. Sembra, però, ci sia stato un migliore rendimento degli impianti SL, per merito della geometria superficiale prodotta dalla standardizzata tecnica di sabbiatura (Winsix<sup>®</sup>, BioActive Covering<sup>TM</sup>) che favorisce un contatto più intimo con il neoformato tessuto perimplantare.

\* Università degli Studi di Milano, Istituto di Clinica Odontoiatrica e Stomatologica, Odontostomatologia I, Milano, Italia.

\*\* Università degli Studi di Roma "La Sapienza", Istituto di Clinica Odontoiatrica, Cattedra di protesi Dentaria.

Corrispondenza:

Dr Loris Prosper - Via San Gottardo 84 - I-20052 Monza - Milan - Italy -  
E-mail: lorisp@tin.it

### Parole chiave:

Impianti, mordenzatura, sabbiatura,  
osteointegrazione, protesi



Prosper et al

## Introduzione

Negli ultimi 30 anni l'utilizzo d'impianti osteointegrati è divenuto una modalità terapeutica per il trattamento di pazienti parzialmente e totalmente edentuli, efficace, diffusa e consueta.<sup>1\*</sup> Le caratteristiche micro- e macrostrutturali dell'impianto standard di *Brånemark* (Nobel Biocare, Göteborg, Sweden) sono state per lungo tempo considerate essenziali per garantire una soddisfacente rigenerazione ossea intorno all'impianto. Tra queste caratteristiche sono incluse la forma cilindrica e a vite dell'impianto, la sua composizione di titanio commercialmente puro e la superficie liscia.<sup>2</sup> Alla luce dei progressi ottenuti da un punto di vista chirurgico, protesico e tecnologico,<sup>3</sup> ed in considerazione di una semplificazione delle terapie implantari che rispondano a precise esigenze pratiche del clinico e del paziente, soprattutto per quanto concerne tempi di guarigione e prognosi, alcuni autori hanno proposto delle varianti all'impianto standard di *Brånemark*,<sup>4,5</sup> ma il dibattito è ancora aperto e controverso. Le rivalutazioni hanno interessato la qualità della superficie implantare, la morfologia della vite, le condizioni e i tempi di guarigione e di carico. Notevole interesse è stato focalizzato sulla conformazione della superficie implantare, uno dei punti oggi considerato critico per quanto concerne il processo di osteointegrazione. Infatti, è ormai ampiamente condivisa l'opinione secondo la quale la ruvidezza superficiale può influire sul processo di guarigione e di osteointegrazione condizionando anche le funzioni delle cellule, la deposizione della matrice, la sintesi di sostanze autocrine e paracrine e la mineralizzazione.<sup>6,7\*</sup> La superficie degli impianti, d'altronde, è la sola parte della vite a venire in contatto con l'ambiente biologico dell'ospite;<sup>8</sup> essa ne influenza le risposte cellulari e biochimiche e agisce sulla stabilità meccanica dell'interfaccia tra tessuti e impianto.<sup>9</sup>

L'influenza delle caratteristiche della superficie dell'impianto, principalmente della sua ruvidezza, sull'osteointegrazione è stato indagato da diversi autori.<sup>9, 11, 12, 13</sup> Recentemente è stato valutato e confrontato il comportamento in vivo delle superfici sabbiate (SL) e di quelle sabbiate e mordenzate (SLA) durante il periodo di guarigione successivo all'inserimento dell'impianto.<sup>22</sup>

Dal punto di vista clinico e pratico potrebbe essere rilevante valutare l'esistenza di eventuali differenze tra queste superfici rispetto all'osteointegrazione a lungo termine, specialmente nella situazione in cui gli impianti sostengano delle protesi fisse e siano dunque sottoposti a particolari sollecitazioni. Vi è attualmente mancanza,

nella letteratura odontoiatrica, di indagini sperimentali appositamente condotte per esaminare questo problema. Lo scopo dello studio presente è stato di valutare e di confrontare il successo implantare a 5 anni di impianti con superficie solo sabbata o con superficie sabbata e mordenzata, inseriti posteriormente nelle mandibole e nelle mascelle sostenenti protesi parziali fisse.


## Materiali e Metodi

In questo studio randomizzato sono stati valutati 44 soggetti adulti parzialmente edentuli (età media (DS) 46,2 (14,3) anni, range 21-75; 27 donne e 17 uomini), selezionati nel periodo gennaio 1995 - dicembre 1995 per essere sottoposti ad intervento chirurgico implantare e protesico e selezionati in accordo ai seguenti criteri di ammissione. Criteri d'inclusione: età compresa tra 21 e 75 anni; intervento in due fasi chirurgiche con impianti non post-estrattivi; presenza di guida canina o funzione di gruppo nel modulo oclusale delle arcate; 2 o 3 impianti inseriti posteriormente nelle mandibole o nelle mascelle; protesi parziale fissa (ponte) di 3 o 4 elementi senza cantilever. Un criterio d'esclusione è stato la presenza di malattie dismetaboliche e/o croniche e/o infettive. Ad ogni paziente è stato spiegato in modo dettagliato il piano di trattamento ed è stato richiesto il consenso informato scritto per la partecipazione alla ricerca.

Tutti i pazienti sono stati suddivisi in due gruppi: gruppo SL, costituito da pazienti in cui sono stati inseriti impianti di titanio commercialmente puro di forma cilindrica e a vite (Winsix® Ltd, London, UK), con superficie sabbata (23 pz); gruppo SLA, costituito da pazienti i cui impianti avevano superficie sabbata e mordenzata (21 pz). La sabbatura ha utilizzato particelle di biossido di titanio (TiO<sub>2</sub>) (Bioactive covering™, Winsix® Ltd, London, UK), la mordenzatura acido fluoridrico (HF) in soluzione con acqua. Per la costruzione delle protesi sono state utilizzate procedure e materiali standard. Gli abutment utilizzati erano monconi standard, diritti o pre-inclinati, monconi per fresaggio o per sovrapposizione (UCLA), e monconi calcinabili (Free Lock™, Winsix® Ltd, London, UK), (foto 1, Tabella 1). La struttura metallica di sostegno delle protesi era costituita da lega aurea (Portadur P2, Wieland Edelmetalle, Pforzheim, Germania); il materiale di rivestimento dell'armatura era in ceramica ibrida (Estenia, Kuraray, Osaka, Giappone). Per evitare un sovraccarico funzionale dell'impianto è stata sfruttata la naturale mobilità dei denti antagonisti: l'occlusione è stata ricreata lasciando uno spazio minimo di 50 µm per permettere che i denti



Prosper et al



**Foto 1** Tipi di abutment utilizzati. a) standard pre-inclinato 15°; b) standard pre-inclinato 25°; c) standard diritto; d) fresaggio; e) calcinabile; f) sovrafusione (UCLA).

**Tabella 1** Tipo di abutment utilizzato per la connessione protesi-impianto, nei due gruppi d'impianti

Tipo di abutment	SL (n=54)	SLA (n=53)
	n (%)	n (%)
Fresaggio	7 (13,0)	6 (11,3)
Sovrafusione (UCLA)	24 (44,4)	25 (47,2)
Calcinabile	8 (14,8)	9 (17,0)
Standard diritto	8 (14,8)	8 (15,1)
Standard pre-inclinato 15°	4 (7,4)	3 (5,6)
Standard pre-inclinato 25°	3 (5,6)	2 (3,8)

\*Differenza non significativa tra i gruppi SL e SLA (p=0,981).

adiacenti vengano caricati prima che l'unità implantare, più rigida, entri in contatto<sup>5</sup>. Tutte le procedure chirurgiche e di collocamento della protesi sono state eseguite dal medesimo odontoiatra esperto. Nella presente ricerca sono stati inseriti complessivamente 107 impianti, 54 impianti nel gruppo SL e 53 impianti nel gruppo SLA, suddivisi rispettivamente in 62 nella mandibola e 45 nel mascellare superiore; tutti gli impianti avevano una sezione che variava da 3,3 a 4,5 mm e una lunghezza da 11 a 15 mm (Tabella 2).

#### Procedure chirurgiche

La prima fase chirurgica è stata condotta seguendo il protocollo standard suggerito da Brånemark.<sup>3</sup> Durante le prime 3 settimane ai pazienti è stato richiesto di non masticare né di esercitare attrito nell'area chirurgica, e di risciacquare l'area d'intervento 2 volte al giorno con digluconato di clorexidina 0,12 % (Dentosan Mese, Pagni Raffaello, Firenze, Italia). Inoltre, nei primi 7

**Tabella 2** Dimensioni lineari degli impianti e zona dentale d'inserzione, nei due gruppi d'impianti.\*

	SL (n=54)	SLA (n=53)
	n (%)	n (%)
Lunghezza dell'impianto (mm)		
11	13 (24,1)	12 (27,9)
13	39 (72,2)	38 (69,8)
15	2 (3,7)	3 (2,3)
Diametro dell'impianto (mm)		
3,3	7 (13,0)	9 (16,3)
3,8	23 (42,6)	22 (48,8)
4,5	24 (44,4)	22 (34,9)
Zona dentale d'inserzione <sup>b</sup>		
10	13 (24,1) [2,3]	10 (18,9) [2,3]
20	11 (20,4) [2,3]	11 (20,7) [1,3]
30	16 (29,6) [3,4]	16 (30,2) [2,4]
40	14 (25,9) [2,4]	16 (30,2) [2,4]

\* Nessuna differenza significativa tra i gruppi SL e SLA (minimo p=0,839).

<sup>b</sup> Tra parentesi quadrate il numero di protesi, a 3 o 4 elementi, sostenute dagli impianti.

giorni è stata somministrata una profilassi antibiotica, 1 g di amoxicillina (Augmentin<sup>®</sup>, Smithkline Beecham, New York, NY, USA) ogni 12 ore. Le suture sono state rimosse tra 8 e 15 giorni dopo l'intervento. In seguito i pazienti sono stati rivisti clinicamente ogni mese fino al termine del periodo di guarigione (4 mesi per gli impianti inseriti nelle mandibole, 6 mesi per quelli inseriti nelle mascelle). Trascorso il periodo di guarigione si

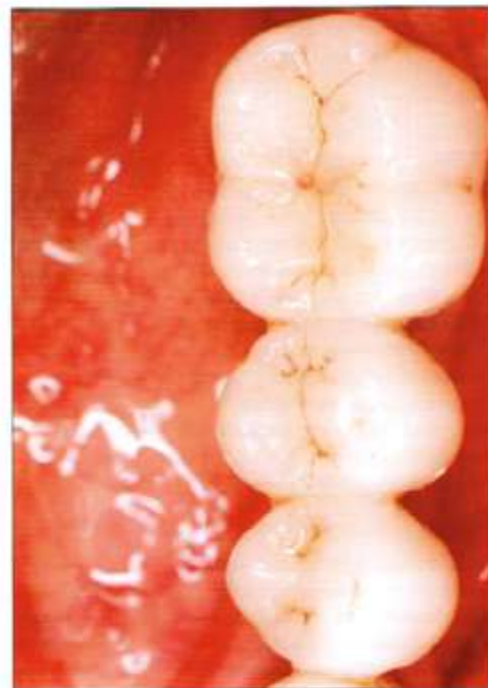**Prosper et al**

è affrontata la seconda fase chirurgica. Nel corso della procedura di esposizione della testa degli impianti, si è scollato un lembo e si è verificata la stabilità dell'impianto mediante Periotest<sup>27</sup> (Periotest, Siemens, Bensheim, Germania) valutando anche lo stato del tessuto osseo perimplantare. Quando non erano presenti segni di mobilità ed il tessuto osseo perimplantare non presentava infezioni o difetti ossei, si è proceduto all'inserimento delle viti di guarigione. Dopo  $14 \pm 2$  giorni dei 44 pazienti osservati soltanto 3 presentavano una guarigione dei tessuti molli non adeguata (1 del gruppo SL e 2 del gruppo SLA); in questi si è dilazionato il tempo per l'applicazione dell'abutment di 15-20 giorni. Una volta applicato l'abutment in tutti i pazienti è stata presa l'impronta per realizzare una protesi provvisoria di resina acrilica successivamente fissata con cemento provvisorio (Temp Bond, Kerr Manufacturing Co, Romulus, MI, USA). La funzione della protesi provvisoria, applicata per  $40 \pm 5$  giorni, era di rilevare eventuali problemi funzionali, estetici e fonetici, di esercitare un carico progressivo sugli impianti e di guidare i tessuti molli per ottenere un corretto profilo emergente.<sup>24</sup> Rimossa la protesi provvisoria si è rilevata una seconda impronta utile per realizzare la protesi definitiva. Questa, una volta confezionata, è stata fissata anch'essa con cemento provvisorio, poco traumatico al momento della rimozione della protesi durante i controlli.

**Valutazioni di follow-up**

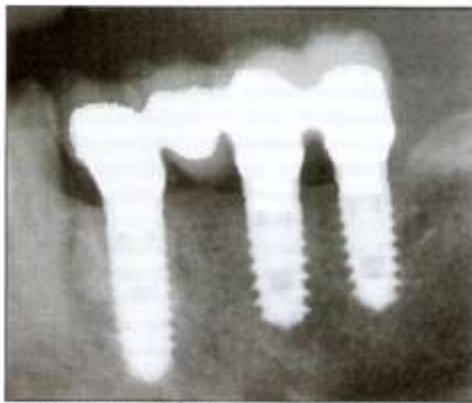
Dopo il collocamento della protesi definitiva, tutti i pazienti sono stati invitati a visite cliniche di controllo programmate ogni 3 mesi per un periodo complessivo di 5 anni dal posizionamento degli impianti. Durante queste visite è stato effettuato l'esame obiettivo dei tessuti molli con il sondaggio parodontale, è stata valutata tramite microscopio a 4x la precisione marginale tra la protesi e l'abutment e dove incongrua corretta. Contestualmente è stata verificata la condizione dell'igiene orale dei pazienti. In quelli in cui si era rilevata la presenza di placca batterica sui tessuti molli questa venne rimossa insieme a quella calcificata depositata sugli abutment tramite lucidatura. Per questi pazienti non sufficientemente motivati nei confronti dell'igiene orale domiciliare i richiami furono anticipati ad 1 mese. Per valutare il grado di osteointegrazione di tutti gli impianti inseriti è stato eseguito un protocollo che prevedeva l'esecuzione di radiografie periapicali (sistema digitale Digora, Soredex) effettuate in ogni paziente a 3, 6, 9 e 12 mesi ed in seguito annualmente fino al quinto anno. Per rendere sovrapponibili i risultati ricavati dall'indagi-

ne radiografica, è stata utilizzata una dima in resina acrilica (Dura Lay, Reliance Dental MFG.CO, Worth, Ill., USA) che era stata precedentemente predisposta per posizionare correttamente gli abutment sugli impianti e sulla quale è stato realizzato un posizionatore individuale in polivinilsilossano, collegato ad un centratore di Rinn (Rinn Corp, Elgin, Ill, USA) che permetteva di riposizionare le radiografie endorali eseguite in tempi diversi nella stessa bisettrice di proiezione radiologica. Per le immagini radiografiche furono utilizzate le pellicole Kodak Ultra-speed size II double film (Eastman Kodak, Rochester, NY, USA). Il grado di riassorbimento del tessuto osseo è stato valutato utilizzando come punti di repere il livello della cresta ossea e l'incavo collocato ad 1,4 mm dal margine dell'impianto in posizione mesiale e distale. Il successo implantare è stato definito su base radiografica in accordo ai criteri di *Albrektsson et al.*<sup>25</sup> Il successo protesico, definito come stabilità continua della protesi, in accordo ai criteri presenti in letteratura,<sup>26</sup> è stato valutato clinicamente ad ogni visita di controllo. Gli aspetti clinici di alcuni impianti utilizzati nella sperimentazione sono illustrati nelle foto 2 e 3.



**Foto 2** Protesi definitiva di 3 elementi, rivestita in Estenia situata in zona 30.

Prosper et al



**Foto 3** Radiografia periapicale di tre impianti sostenenti una protesi. In particolare, gli impianti occupano le sedi 34, 35 e 37.

#### Analisi statistica

I risultati descrittivi sono presentati come numero e/o percentuale di osservazioni. Per le variabili continue, il confronto tra i due gruppi di impianti è stato effettuato tramite il test *t* di Student per dati non appaiati. Il test chi-quadrato e il test esatto di Fisher sono stati usati per il confronto delle variabili discrete. Valori di *p* minori di 0,05 sono stati considerati indicare significatività statistica (test a due code).

#### Risultati

Le distribuzioni dell'età e del sesso dei soggetti non differivano nei due gruppi di pazienti (minimo  $p=0,561$ ). I due gruppi sono inoltre risultati comparabili rispetto alle dimensioni lineari degli impianti ed alla zona dentale d'inserzione (minimo  $p=0,839$ ) (Tabella 2).

Al termine del periodo di guarigione, ossia al momento della riapertura, nessun impianto ha mostrato segni visibili di mobilità, di infezione peri-implantare o di perdita ossea. In particolare, tutti i valori Periotest sono risultati essere compresi nell'intervallo tra -5 e 0 in entrambi i gruppi d'impianti. La distanza tra l'incavo del collo dell'impianto e la prima parte visibile dell'osso non è risultata significativamente diversa tra i due gruppi d'impianti, variando tra 0,70 e 0,80 mm nel gruppo SL e tra 0,73 e 0,80 mm nel gruppo SLA ( $p=0,772$ ).

La Tabella 1 mostra nei due gruppi di pazienti il tipo di abutment utilizzato per la connessione protesi-impianto. Le distribuzioni sono risultate comparabili nei due grup-

pi (minimo  $p=0,818$ ). Si è avuto un follow-up a 5 anni del 100%. L'incidenza complessiva di successo implantare 5 anni dopo il posizionamento è stata del 93,4%, significativamente più elevata nel gruppo SL (100%) che nel gruppo SLA (86,8%) ( $p<0,01$ ). Nei pazienti non si è osservata alcuna rottura degli elementi della protesi. In particolare, nei 37 soggetti nei quali non vi è stato insuccesso implantare il successo protesico a cinque anni è stato del 100% in entrambi i gruppi di impianti. I 7 insuccessi implantari, tutti riguardanti impianti SLA, si sono verificati in pazienti distinti. Due impianti erano stati inseriti nelle mandibole, entrambi in zona 34, e sono falliti a causa di peri-implantiti entro 1 anno dal loro inserimento. Entrambi sostenevano una protesi di 4 elementi. Cinque insuccessi hanno riguardato impianti inseriti nelle mascelle, rispettivamente nelle zone 14, 15, 17, 24, e 25. Uno di questi (zona 24), sostenente una protesi di 3 elementi, è fallito a causa di trauma oclusale, probabilmente dovuto alla presenza di bruxismo<sup>®</sup> nel paziente, 9 mesi dopo l'inserzione dell'impianto. I rimanenti 4 sono falliti a causa di peri-implantite.

#### Discussione

È noto che il successo clinico a lungo termine degli impianti dentali dipende essenzialmente dall'osteointegrazione dell'impianto. Sebbene non è a tutt'oggi chiaro se esistano una composizione, una forma e una morfologia superficiale ottimali per il successo implantare, tuttavia è stato più volte riportato in letteratura che la ruvidezza della superficie influenza positivamente il processo di osteointegrazione.<sup>21,22,23</sup> Durante gli anni più recenti sono state suggerite diverse spiegazioni del perché una maggior ruvidezza superficiale potrebbe aumentare la probabilità di successo implantare. In particolare, sembrerebbe che il processo di rigenerazione e formazione dell'osso tenda ad essere più efficacemente stimolato allorché le cellule osteoblastiche crescano su superfici ruvide.<sup>24</sup> Un problema importante in ambito odontoiatrico clinico è se impianti con una ruvidezza comparabile, ma ottenuta con procedimenti chimico-fisici differenti, possano comunque condurre a risultati a lungo termine equivalenti. Questo, in particolare, quando gli impianti sostengono delle protesi fisse, una circostanza sempre più frequente nell'implantologia protesica.

Lo scopo del presente studio è stato quello di confrontare il successo implantare a lungo termine di impianti di titanio con superficie sabbiata o sabbiata e mordenzata sostenenti protesi parziali fisse. In questo studio sono stati esaminati solo pazienti con protesi senza cantilever e



Prosper et al

sostenute da impianti inseriti posteriormente nelle mandibole o nelle mascelle, per minimizzare possibili problematiche, ancora controverse, riguardanti la connessione dente-impianto, dovute alla rigidità dell'impianto in confronto alla relativa mobilità del dente naturale, e alla presenza del legamento parodontale.<sup>22,23</sup> Gli impianti scelti soddisfacevano ad alcune caratteristiche peculiari standard; erano di titanio commercialmente puro, e avevano una forma cilindrica a vite. Gli impianti SL sono stati considerati quali impianti di riferimento sia perché diffusi nella pratica clinica sia per aver dimostrato un buon ancoraggio nell'osso, fors'anche migliore di quello d'impianti con superficie liscia.<sup>26</sup> Essi inoltre presentano una elevata ruvidezza superficiale media (2 µm). Gli impianti SLA sono stati considerati quali impianti di confronto perché hanno una ruvidezza superficiale comparabile con quella degli impianti SL ed inoltre sembrano ridurre, rispetto agli impianti SL, il periodo di guarigione seguente l'inserzione dell'impianto.<sup>22,24</sup> La differenza fondamentale tra i due tipi d'impianto sta essenzialmente nel fatto che la sabbiatura produce una ruvidezza superficiale piuttosto regolare creando "avvallamenti reticolari", mentre la successiva mordenzatura origina ulteriori anfratti tridimensionali microscopici rendendo la superficie più irregolare e frastagliata.

Il successo implantare è stato valutato radiograficamente e definito secondo i criteri di *Albrektsson et al.*<sup>25</sup> Le radiografie sono state prese preoperativamente, subito dopo l'inserimento e alla successiva apertura dell'impianto, ed in seguito annualmente fino al quinto anno dall'inserimento dell'impianto. Le valutazioni radiografiche sono state eseguite da un operatore non a conoscenza del tipo di impianto utilizzato. Questo ha eliminato la variabilità inter-esaminatori e ha reso non distorto il confronto tra l'incidenza di successo implantare tra i due tipi d'impianto. Al momento della seconda fase chirurgica nessun impianto presentava alcuna infezione peri-implantare e tutti mostravano una buona stabilità.

Complessivamente nel nostro studio tra i 107 impianti si sono verificati, entro 5 anni dal loro inserimento, solo 7 insuccessi. Si è avuta perciò un'incidenza complessiva di successo implantare del 93,4% che è nell'intervallo di valori riportati in letteratura. In un recente studio di meta-analisi<sup>25</sup> è stato stimato, per impianti ritenenti protesi parziali fisse, un successo implantare minimo pari a l'85,7% dopo un anno dall'inserimento dell'impianto, e un successo implantare medio interpolato, sugli studi pubblicati tra il 1986 e il 1996 del 93,6% dopo 6-7 anni. Nel nostro studio, tutti gli insuccessi implantari si sono verificati entro due anni dall'inserzione dell'impianto, con un'inci-

denza tendenzialmente più elevata tra gli impianti inseriti nelle mascelle (5/45) che tra quelli inseriti nelle mandibole (2/62). Questo è un risultato non inaspettato e consistente con i risultati di altri autori (e.g.<sup>26</sup>).

Considerando gli impianti SL e SLA separatamente l'incidenza di successo implantare a 5 anni è stata 100% tra gli impianti SL e 86,8% tra gli impianti SLA *Albrektsson et al.*<sup>25</sup> hanno suggerito che, affinché una procedura implantare possa essere considerata soddisfacente, l'incidenza di successo a 5 anni dovrebbe essere almeno dell'85%. Rispetto a questo criterio entrambi i tipi d'impianto possono dunque essere considerati soddisfacenti. In base al nostro studio non è possibile individuare le ragioni della differenza d'incidenza nel successo a lungo termine trovata tra i due tipi d'impianto. Dovrebbe essere anche osservato che mentre 4 insuccessi hanno mostrato evidenti segni di peri-implantite (sanguinamento al contatto, aumento della profondità della tasca, infezione peri-implantare con lieve o moderata suppurazione), gli altri tre casi potrebbero essere stati dovuti a fattori non direttamente intrinseci alle caratteristiche implantari. In un caso l'insuccesso potrebbe essere stato indotto dalle parafunzioni presenti nel paziente, negli altri due casi dalla scarsa igiene orale praticata dai pazienti e dall'non osservanza alla profilassi prescritta durante il periodo di guarigione. In ogni caso, la non superiorità a lungo termine degli impianti SLA può comunque non essere inaspettata. A tal proposito, *Cochran et al.*<sup>27</sup> confrontando in 6 foxhound la risposta ossea fino a 15 mesi dall'inserzione di impianti SLA e plasma-sprayed, trovarono che sebbene gli impianti SLA favorirono il contatto osseo tuttavia non mostrarono, dopo 15 mesi dall'inserzione, differenze cliniche con gli impianti plasma-sprayed. Tenuto conto che gli impianti SL e SLA hanno una ruvidezza superficiale media comparabile di circa 2 µm, e che, nel nostro studio, i due gruppi d'impianti erano comparabili anche rispetto alla zona dentale d'inserzione, alle dimensioni lineari dell'impianto, al tipo di protesi e di abutment utilizzato per la connessione protesi-impianto, potrebbe forse essere ipotizzato che la differenza di successo a lungo termine possa essere, almeno in parte, dovuta ai differenti procedimenti chimico-fisici utilizzati per il trattamento della superficie dell'impianto e alle conseguenti differenti caratteristiche micro-topografiche. Sebbene questa conclusione debba essere interpretata con cautela, tuttavia essa è consistente con l'osservazione di *Quirynen et al.*<sup>28</sup> che anche minimali cambiamenti nei materiali o nel design di un impianto possono avere notevole influenza sull'esito clinico, ed è confermata da studi sperimentali di laboratorio.<sup>28,29</sup> Quest



hanno infatti suggerito che le cellule ospite possono discriminare tra piccolissime diversità dovute al trattamento chimico-fisico della superficie implantare, alla sua ruvidezza e topografia. Anche Thomas e Ripamonti dal loro studio sperimentale hanno concluso che la geometria di superficie è in grado di condizionare i processi di riconoscimento biologico e, di conseguenza, i processi di guarigione ossea, definendo tale fenomeno "geometric induction of bone formation".<sup>19</sup>

La possibilità di guidare attraverso la sabbiatura una geometria di superficie ideale e favorevole ai processi di guarigione ossea è ad oggi motivo di studio.

In ogni caso, la differenza nell'incidenza a lungo termine osservata nel nostro studio tra gli impianti SL e SLA indica che, almeno nel caso d'impianti sostenenti protesi fisse, gli impianti SL potrebbero essere preferibili agli impianti SLA. Ulteriori studi longitudinali più ampi sono necessari sia per confermare i risultati dell'indagine presente sia per determinare le proprietà chimico-fisiche e topografiche della superficie implantare che potrebbero influenzare positivamente il processo di osteointegrazione a lungo termine.

### Conclusioni

Questo studio ha rilevato un'incidenza di successo implantare, dopo 5 anni dal posizionamento dell'impianto, del 100% tra gli impianti SL e del 86,8% tra gli impianti SLA. I risultati, pur indicando che sia gli impianti SL che gli impianti SLA, quando inseriti posteriormente nelle mandibole o nelle mascelle, possono essere utilizzati con successo per sostenere a lungo termine protesi parziali fisse, suggeriscono anche che, almeno in questa circostanza, gli impianti SL potrebbero essere preferibili agli impianti SLA.

### Ringraziamenti

Si ringraziano i seguenti odontotecnici per la disponibilità e l'aiuto offerti nell'esecuzione dei manufatti protesici, oggetto del presente articolo:

- Enzo Bortolini, Castelmasa, Rovigo
- Massimo e Giuseppe Bitti, Roma
- Sergio e Miriam Sonzogni, Bergamo
- Maurizio Battiston, Parabiago, Milano
- Mauro e Cristian Franzin, San Donato Milanese, Milano
- Roberto Boccalari, Milano
- Beppe Valenzano, Napoli
- Maurizio Farina, Milano
- Stefano Tartaglia, Monza, Milano

### Bibliografia

1. Brånemark PI, Adell R, Breine U, Hansson O, Lindström J, Ohlsson Å. Intra-osseous anchorage of dental prosthesis. Experimental studies. *Scand J Plastic Reconstr Surg* 1969;3:81-100.
2. Schroeder A, Van Der Zypen E, Stich H, Sutter F. The reactions of bone, connective tissue, and epithelium to endosteal implants with titanium-sprayed surfaces. *J Maxillofac Surg* 1981;9:15-25.
3. Brånemark PI, Hansson BO, Adell R, Breine U, Lindström J, Hallén O, Öhman A. Osseointegrated implants in the treatment of the edentulous jaw. Experience from a 10-year period. *Scand J Plastic Reconstr Surg Suppl.* 1977;16:1-132.
4. Brånemark PI, Zarb GA, Albrektsson T. *Tissue integrated prosthesis: osseointegration in clinical dentistry.* Chicago: Quintessence Publishing Co Inc; 1985.
5. Schroeder A, Pohler O, Sutter F. Gewebsreaktion auf ein Titan-Hohlzylinderimplantat mit Titan-Spritzschichtoberfläche. *Schweizerische Monatsschrift für Zahnheilkunde* 1976;96:713-727.
6. Schroeder A, Stich H, Straumann F, Sutter F. Über die Anlagerung von Osteozement an einen belasteten Implantatkörper. *Schweizerische Monatsschrift für Zahnheilkunde* 1978;98:1051-1058.
7. Albrektsson T, Brånemark PI, Hansson BO, Lindström J. Osseointegrated titanium implants: requirements for ensuring a long-lasting direct bone-to-implant anchorage in man. *Acta Orthop Scand* 1981;52:155-170.
8. Schmuckler-Moncier S, Piattelli A, Favero GA, Dubrulle J-H. Considerations preliminary to the application of early and immediate loading protocols in dental implantology. *Clin Oral Impl Res* 2000;11:12-25.
9. Buser D, Weber HP, Brugger U, Balsinger C. Tissue integration of one-stage ITI implants. 3-year results of a longitudinal study with hollow-cylinder and hollow-screw implants. *Int J Oral Maxillofac Implants* 1991;6:405-412.
10. Buser D, Mericskky-Stern R, Bernard JP, Behneke A, Beheke N, Hirt HP, Belser UC, Lang NP. Long-term evaluation of non-submerged ITI implants. Part I: 8-year life table analysis of a prospective multicenter study with 2359 implants. *Clin Oral Implants Res* 1997; 8:161-172.
11. Wilke HJ, Claes L, Steinemann S. The influence of various titanium surfaces on the interface shear strength between implants and bone. In: Heinke G, Soltész U, Lee AJC (eds). *Advances in Biomaterials, Vol 9. Clinical Implants Materials.* Amsterdam: Elsevier Science 1990:309-314.
12. Boyan BD, Hummert TW, Kieswetter K, Schraub D, Dean DD, Schwartz Z. Effect of titanium surface characteristics on chondrocytes and osteoblasts in vitro. *Cell Mater* 1995;5:323-35.
13. Martin JY, Schwartz Z, Hummert TW, Schraub DM, Simpson J, Lankford J, Dean DD, Cochran DL, Boyan BD. Effect of titanium surface roughness on proliferation, differentiation, and protein synthesis of human osteoblast-like cells (MG63). *J Biomed Mater Res* 1995;29:389-401.
14. Schwartz Z, Martin JY, Dean DD, Cochran DL, Simpson J, Boyan BD. Effect of titanium surface roughness on chondrocyte proliferation, matrix production, and differentiation depends on the state of cell maturation. *J Biomed Res* 1996;30:145-55.
15. Glantz PO. Biomaterial considerations for the optimized therapy for the edentulous predicament. *J Prosthet Dent* 1998;79:90-92.
16. Wen X, Wang X, Zhang N. Microrough surface of metallic biomaterials: a literature review. *Biomed Mater Engineering* 1996;6:173-89.
17. Wennerberg A, Ektesabi A, Albrektsson T, Johnson C, Andersson A. A 1-year follow-up of implants of differing surface roughness placed in rabbit bone. *Int J Oral Maxillofac Implants* 1997;12:486-494.
18. Buser D, Schenk RK, Steinemann S, Fiorellini JP, Fox C, Stich H. Influence of surface characteristics on bone reaction to titanium implants: a histomorphometric study in miniature pigs. *J Biomed Mater Res* 1991;25:889-902.
19. Thomas K, Cook S. An evaluation of variables influencing fixation and direct bone apposition. *J Biomed Mater Res* 1985;19:875-901.

## Prosper et al

20. Gotfredsen K, Nimb L, Hjarthing-Hansen E, Jensen JS, Holman A. Histomorphometric and removal torque analysis for TiO<sub>2</sub>-blasted titanium implants: an experimental study on dogs. *Clin Oral Implants Res* 1992;3:77-84.
21. Han CH, Johansson CR, Wennerberg A, Albrektsson T. Quantitative and qualitative investigations of surface enlarged titanium alloy implants. *Clin Oral Implants Res* 1998;9:1-10.
22. Prosper L, Di Carlo F, Redaelli S, Radaelli G, Scaringi R, Quaranta M. Tempo di guarigione ossea per impianti in titanio con superficie solo sabbiata o superficie sabbiata e mordenzata. *Riv Internaz Odontol* 2000;1:79-85.
23. Lundgren D, Laurell L. Biomechanical aspects of fixed bridgework supported by natural teeth and endosseous implants. *Periodontology* 2000 1994;4:23-30.
24. Strub JR, Witkowski S, Einsele FT. *Enossale orale implantologie aus prothetischer Sicht*. Quintessenz Verlags-GmbH. Berlin Copyright 1996.
25. Albrektsson T, Zarb G, Worthington P, Eriksson BA. The long-term efficacy of used dental implants: a review and proposed criteria of success. *Int J Oral Maxillofac Implants* 1986;1:11-25.
26. Schultee W, d'Hoedt B, Lukas D. Periostest- ein neues Messverfahren der Funktion des Parodontiums. *Zahnärztl Mitt* 1983;73:1229.
27. Teerlinck J, Quiryen M, Darius P, van Steenberghe D. Periostest: An objective clinical diagnosis of bone apposition toward implants. *Int J Oral Maxillofac Implants* 1991;6:55-61.
28. Adell R, Lekholm U, Rockler B, Brånemark PI. A 15-year study of osseointegrated implants in the edentulous jaws. *Int J Oral Surg* 1981;10:387-416.
29. Walton JM, McEntee MI. A prospective study on the maintenance of implant prostheses in private practice. *Int J Prosthodont* 1997; 10:453-458.
30. Lytle J.D. Patologia oclusale rivisitata: seconda parte. *Int J Periodontics Restorative Dent* 2001;21:273-279.
31. Kieswetter K, Schwartz Z, Dean DD, Boyan B. The role of implant surface characteristics in the healing bone. *Crit Rev Oral Biol Med* 1996;7:329-345.
32. Becker CM, Kaiser DA, Jones JD. Guidelines for splinting implants. *J Prosthet Dent* 2000;84:210-14.
33. Nishimura RD, Ochiai KT, Caputo AA, Jeong CM. Photoelastic stress analysis of load transfer to implants and natural teeth comparing rigid and semirigid connectors. *J Prosthet Dent* 1999;81:696-703.
34. Cochran DL, Schenk RK, Lussi A, Higginbottom FL, Buser D. Bone response to loaded and unloaded titanium implants with a sand-blasted and acid-etched surface: a histometric study in the canine mandible. *J Biomed Mater Res* 1998;40:1-11.
35. Lindh T, Gunne J, Tillberg A, Molin M. A meta-analysis of implants in partial edentulism. *Clin Oral Implants Res* 1998;9:80-90.
36. De Bruyn H, Collaert B, Linden U, Flygare L. A comparative study of the clinical efficacy of Screw Vent implants versus Brånemark fixtures, installed in a periodontal clinic. *Clin Oral Implants Res* 1992;3:32-41.
37. Quiryen M, Naert I, van Steenberghe D. Fixture design and overload influence marginal bone loss and fixture success in the Brånemark system. *Clin Oral Implants Res* 1992;3:104-111.
38. Hambleton J, Schwartz Z, Khare A, Windeler SW, Luna M, Brooks BP, Dean DD, Boyan DB. Culture surfaces coated with various implant materials affect chondrocyte growth and differentiation. *J Orthop Res* 1994;12:542-552.
39. M.E. Thomas, R.W. Richter, J. Crooks, and U. Ripamonti. Smart Calcium Phosphate-Based Bioceramics with Intrinsic Osteoinductivity. *Key Engineering Materials Vol 192-195(2001)pp441-444* Proceeding of the 13th int. Symposium on ceramics in Medicine. □



**Bioctive Covering™**  
Trattamento a sabbiatura differenziata

**Free Lock™**  
La connessione nel pieno rispetto della relazione  
Impianto - moncone

**Free Tense System™**  
La protesi avvitata senza tensioni



### BioS.A.F. S.r.l.

Sede legale: Via Idioni, 6 - 20090 ASSAGO (MI)

Tel: +39 02 48869 - Fax: +39 02 48869330

Sede operativa:

Via Castaldelli, 24 - 45035 CASTELMASSA (RO)

TEL: +39 0425 847329 - FAX: +39 0425 840959

Internet: www.bio-saf.com - E-mail: info@bio-saf.com

**1 Il carico immediato: studio prospettico e comparativo tra due diverse metodiche terapeutiche**

S. Redaelli

---

**2 Clinical trial on osseointegration using sandblasted or sandblasted and acid-etched implants**

S. Redaelli, L. Prosper, F. Di Carlo, A. Daddona, M. Quaranta

---

**3 Implant-retained mandibolar overdentures with immediate loading: clinical and histological study**

G. Pompa, M. Cassetta, I. Voza, R. Scaringi, M. Quaranta  
JDR Journal of Dental research volume 80 March 2001

---

**4 Healing period of titanium implants with sandblasted and acid-etched surface**

L. Prosper, F. Di Carlo, S. Redaelli, R. Scaringi, M. Quaranta  
3° Word Congress of Osteointegration

## **Il carico immediato: studio prospettico e comparativo tra due diverse metodiche terapeutiche**

S. Redaelli

### **5.1. Premesse e scopi**

Gli scopi di questa indagine sono stati:

- Valutare, mediante uno studio prospettico con *follow-up* di 5 anni, se impianti caricati immediatamente con *overdenture*, in pazienti totalmente edentuli, sono in grado di osteointegrarsi;
- Valutare se esistono differenze biologiche e biomeccaniche nel breve e lungo termine tra le diverse modalità di applicazione del carico immediato: posizionamento in un unico tempo degli impianti dentali e collocamento del restauro protesico nella stessa seduta operatoria, o al più tardi entro 48 ore dall'atto chirurgico vs utilizzo di impianti primari e secondari.

### **5.2. Materiali e metodi**

Nel periodo compreso tra gennaio 1995 e dicembre 1995, sono stati posizionati 32 impianti con la tecnica del carico immediato (CI) e 32 impianti con la tecnica Primari/Secondari (IP/IS), in 16 mandibole



edentule. Il sistema implantare utilizzato è stato Winsix (Winsix® Ltd, London, UK); il tipo di riabilitazione protesica definitiva consisteva in barra più *overdenture*.

#### **5.2.1. Valutazione clinica ed anamnestica**

Tra i 127 pazienti consecutivamente ammessi, nell'anno 1995, sono stati selezionati 16 pazienti adulti che rispondevano ai seguenti criteri di inclusione:

- Edentulia completa della mandibola da almeno 3 mesi
- Difficoltà funzionali nell'adattarsi all'uso di protesi mobili totali
- Livello di igiene orale adeguato
- Quantità dell'osso residuo a livello dell'area interforaminale sufficiente a permettere l'alloggiamento di 4 impianti Winsix di 3,3-3,8 mm di diametro ed almeno 10 mm di lunghezza. La valutazione della quantità e morfologia dell'osso mandibolare è stata effettuata tramite palpazione, OPT e teleradiografie latero-laterali.

I criteri di esclusione sono stati i seguenti:

- Severa discrepanza dei rapporti intermascellari

- Riflesso alla chiusura
- Bruxismo
- Paziente già sottoposto a inserimento di impianti in area interforaminale
- Assunzione abitudinaria di alcool o farmaci
- Moderati o forti fumatori (più di 10 sigarette al giorno)
- Pazienti sottoposti a trattamenti radioterapici
- Pazienti trattati con chemioterapici antiblastici
- Pazienti affetti da malattia renale o epatica cronica
- Diabete
- Emofilia, disordini della coagulazione o terapia cumarinica
- Disordini ossei dismetabolici
- Pazienti immunocompromessi, incluso l'HIV
- Terapia con farmaci steroidei in atto
- Gravidanza in corso all'epoca della valutazione pre-operatoria
- Controindicazione generale alle procedure chirurgiche del paziente
- Handicap fisici o psichici che interferiscano con il mantenimento di un buon livello di igiene orale

- Malattie della mucosa orale (come il Lichen Planus o il Pemfigo).

I pazienti sono stati sottoposti ad una prima visita dove è stata effettuata l'anamnesi, l'esame obiettivo, la valutazione e la registrazione di tutti i dati del paziente. La visita includeva:

- Compilazione da parte del paziente di un questionario sulle condizioni di salute generale
- Esame clinico intra ed extra-orale
- Procedure terapeutiche alternative
- L'informazione del paziente dei rischi e delle possibili complicanze del trattamento
- Valutazione radiografica, che può comprendere:
  - Ortopantomografia
  - Teleradiografia latero-laterale
- Fotografie intraorali
- Esami di laboratorio di routine:
  - Ematocrito
  - Concentrazione di emoglobina
  - Conta dei globuli bianchi
  - Tempo di protrombina (PT)

- Tempo di tromboplastina parziale (PTT)
- Piastrine
- ECG

Allo scopo di agevolare l'analisi dell'anatomia locale e pianificare al meglio la fase chirurgica e protesica, veniva rilevata preoperatoriamente un'impronta con alginato. Dalle impronte rilevate venivano colati i modelli dell'arcata superiore ed inferiore, i quali, grazie alla rilevazione dell'arco facciale e della dimensione verticale, venivano posti in articolatore nella corretta relazione spaziale tra le due arcate stesse. In questo modo è stata possibile la valutazione degli elementi dentari da protesizzare e lo spazio interocclusale disponibile.

Oltre a ciò, a partire dai modelli in gesso, veniva fabbricata una mascherina chirurgica in resina acrilica. Tale manufatto è dotato di fori in corrispondenza dei punti di inserimento ideale, dal punto di vista biomeccanico, degli impianti.

La radiografia panoramica preoperatoria è stata eseguita facendo portare al paziente la mascherina chirurgica con i fori riempiti temporaneamente di materiale radiopaco in modo da poter rilevare sulla panoramica le sedi previste di inserimento degli impianti.

La scelta della lunghezza degli impianti è stata dettata principalmente dalla dimensione verticale residua della mandibola



nella regione interforaminale.

### **5.2.2. Protocollo chirurgico e protesico**

Lo studio è stato condotto su due gruppi di 8 pazienti ciascuno. Il primo gruppo (CI) è stato sottoposto a carico immediato dei 4 impianti inseriti nella zona parasinfisaria. Nel secondo (IP/IS) sono stati utilizzati 2 impianti primari e 2 impianti secondari.

Il protocollo chirurgico è stato lo stesso per entrambi i gruppi, eseguito dal medesimo odontoiatra.

I prerequisiti per l'ottenimento di condizioni di asepsi sono stati i seguenti:

- Manipolo contrangolo autoclavabile con il controllo della velocità di rotazione, provvisto di irrigazione con soluzione fisiologica sterile per il raffreddamento della fresa;
- Procedure chirurgiche, strumenti ed accessori vari sterili;

Poco prima dell'intervento chirurgico, il paziente ha effettuato uno sciacquo per un minuto di una soluzione contenente clorexidina digluconato allo 0,20% di concentrazione allo scopo di ottenere un adeguato grado di asepsi locale. In seguito la cute nella regione periorale è stata disinfettata con del povidone.

Al paziente è stata somministrata una terapia antibiotica profilattica un'ora prima dell'intervento e per la settimana seguente mediante l'associazione di amoxicillina e acido clavulanico (Augmentin). La profilassi includeva anche analgesici non steroidei, al momento del bisogno.

I pazienti sono stati istruiti in modo dettagliato riguardo le misure di igiene orale domiciliare da seguire, quali sciacqui con soluzioni a base di clorexidina 0,20, spazzolamento regolare dei denti, tipo di dieta da seguire.

L'inserimento degli impianti è stato effettuato previa somministrazione di anestetico locale con premedicazione con Diazepam (Valium, 0,2 mg pro kg, fino ad un massimo di 10 mg) 30 minuti prima dell'intervento.

La procedura chirurgica ha previsto un'incisione crestale che si estendeva dalla regione molare di un lato fino al lato opposto con incisioni di rilascio distali sul versante buccale. L'obiettivo è stato di poter identificare agevolmente entrambi i fori mentonieri.

Quindi, dopo aver scollato il periostio da ambedue i versanti, linguale e vestibolare, in modo da permettere l'identificazione ed il controllo visivo di entrambi i lati della sinfisi mentoniera, si è valutato se eseguire o meno un rimodellamento della cresta alveolare per

ottenere una base ossea più larga e piatta. In questo caso, tale accorgimento veniva eseguito con una fresa montata su manico diritto a bassa velocità, sotto irrigazione con soluzione fisiologica sterile.

La qualità dell'osso è stata giudicata clinicamente in entrambi i gruppi durante la preparazione dei siti implantari secondo la classificazione di Lekholm e Zarb<sup>146</sup>.

I siti implantari sono stati preparati seguendo la procedura standard relativa al sistema di impianti osteointegrati Winsix, seguendo per quanto possibile le indicazioni della mascherina in modo da ottenere il miglior asse di inserzione e localizzazione dal punto di vista protesico.

A questo punto, nel gruppo CI, si è provveduto all'avvitamento agli impianti dei monconi conici "*Free Tense System*<sup>®</sup>" e poi alla sutura del lembo attorno ad essi. Nel gruppo IP/IS, invece, sono stati posizionati sui due impianti centrali i monconi sferici "*O-ring*", mentre sugli altri due sono state avvitate le *cover screw*.

Successivamente, nel gruppo CI, è stata presa l'impronta con la tecnica pick-up utilizzando una copia della precedente protesi totale rimovibile del paziente. Lo stesso giorno, il laboratorio ha sviluppato il modello ed unito i *transfert* avvitati con resina autopolimerizzante

standard, che richiede un tempo minimo di 12 ore per indurire. In seconda giornata, per minimizzare gli errori di posizione degli impianti sul modello di lavoro, dovuti alla distorsione del materiale da impronta, è stata utilizzata la tecnica della seconda impronta con i *transfert* avvitati e legati tra di loro con resina autopolimerizzante (Pattern Resin, GC Dental Products Corp, Tokio, Giappone). A tal proposito, è utile sottolineare che l'odontotecnico, scadute le 12 ore, aveva separato con un disco da 0,2 mm di spessore i *transfert* saldati, in seguito riuniti dall'odontoiatra con un velo di resina (tecnica "sale e pepe"). Questo passaggio, estremamente importante, serve per superare il problema della contrazione da indurimento della resina. Successivamente, il laboratorio ha costruito la barra e ribasato la protesi con l'inserimento delle *clip*.

Il terzo giorno, infine, è stata posizionata la barra avvitandola a mano, ed è stato controllato l'adattamento passivo utilizzando il test di Sheffield (l'avvitamento da un lato della barra non determina alcun sollevamento della cassetta dal lato opposto) . Successivamente è stata posizionata la protesi.

Nel gruppo IP/IS l'impronta è stata presa il giorno dell'intervento con la tecnica pick-up, con cucchiaio individuale, una volta che tutti e 4 i *transfert* erano stati connessi agli impianti. A



questo punto, il laboratorio ha sviluppato il modello con gesso di tipo IV e ha progettato sia la protesi totale, da attivare sui due monconi sferici centrali (*O-ring*) entro due giorni dall'intervento, sia il "lavoro protesico" finale su barra, assumendo che si abbia osteointegrazione anche sui due impianti immediatamente caricati.

Passati 3 mesi dalla fase chirurgica, verificata l'osteointegrazione in essere dei due impianti centrali, sono stati montati i 4 monconi conici (*Free Tense System*<sup>®</sup>) e da ultimo sono state posizionate la barra e l'*overdenture*.

Non è stato necessario reimprontare la barra, visto che il combaciamento della barra con i monconi conici era a filo dei tessuti molli.

### **5.2.3. Follow-up**

Nell'immediato post-operatorio è stata effettuata una OPT di controllo a ciascun paziente; inoltre, ai pazienti sono state fornite istruzioni sulle norme igieniche e dietetiche domiciliari da seguire nel decorso post-operatorio: sciacqui con collutorio a base di clorexidina digluconato allo 0,20% 3 volte al dì per 1 minuto circa per 3 settimane e dieta liquida o semiliquida per le 2 settimane successive

all'intervento.

Un primo *check-up* è stato effettuato dopo 7-14 giorni dall'intervento durante la rimozione delle suture. Durante il controllo sono state ripetute le istruzioni sulle norme di igiene orale da mantenere (spazzolino da denti con setole morbide ed applicazioni topiche con gel di clorexidina).

Entrambe le tecniche sono state, successivamente, monitorate mediante radiografie endorali e indice di placca e di sanguinamento al 1°, 3°, 6°, 9°, 12°, 18°, 24° mese dall'applicazione del carico e quindi annualmente fino al termine del periodo di *follow-up* di 5 anni. Ad ogni richiamo annuale, le barre sono state rimosse e ciascun impianto è stato testato individualmente, analizzandone la mobilità ed il riassorbimento osseo. La mobilità implantare è stata controllata manualmente mediante i manici di due specchietti odontoiatrici e strumentalmente tramite Periotest (Periotest, Siemens, Bensheim, Germania). Le misurazioni con il Periotest sono state effettuate per ogni singolo impianto al momento della connessione dell'*abutement*, rispettando le seguenti linee guida:

- Prima di effettuare la misurazione verificare la calibrazione dello strumento (-2/+10 secondo le istruzioni del fabbricante)
- Mantenere il manico del Periotest in posizione orizzontale

con il pulsante di start in alto

- Applicare il manico dello strumento perpendicolarmente alla superficie buccale del moncone, il quale dovrebbe essere posizionato a sua volta perpendicolarmente rispetto al pavimento
- Mantenere la punta del Periotest ad una distanza non maggiore di 4 mm dall'*abutement*
- Effettuare ogni registrazione appena sotto la superficie coronale del moncone
- Eseguire tutte le misurazioni almeno due volte per ciascun impianto. Solo una deviazione del valore di 1 unità periotest tra le due misurazioni per lo stesso impianto può essere accettata (altrimenti deve essere ripetuta)
- Per ogni impianto deve essere considerato il valore medio di periotest. Qualunque impianto che presentasse mobilità clinica al momento della connessione dell'*abutement* deve essere rimosso. Nel nostro caso è stato escluso dallo studio.

Per identificare eventuale perdita di osso verticale attorno agli impianti, visibile solo radiograficamente, sono state effettuate radiografie (OPT ed endorali). Nel caso delle radiografie periapicali, per rendere confrontabili i risultati ricavati dall'indagine radiografica,

è stata utilizzata la dima in resina acrilica, precedentemente predisposta per posizionare correttamente gli impianti, sulla quale è stato realizzato un posizionario individuale in polivinilsilossano, collegato ad un centratore di Rinn che permetteva di riposizionare le radiografie endorali eseguite in tempi diversi nella stessa proiezione radiologica. Il grado di riassorbimento del tessuto osseo è stato valutato utilizzando come punti di repere il livello della cresta ossea e l'incavo collocato ad 1,4 mm dal margine dell'impianto che ne circonda tutto il collo.

Per quanto concerne l'indice di placca si è utilizzato quello modificato da Mombelli<sup>150</sup>, che rivela lo spessore della placca intorno all'impianto (0 = no placca visibile; 1 = placca rimovibile solo attraverso il passaggio della sonda sulla superficie marginale dell'impianto; 2 = placca visibile ad occhio nudo; 3 = depositi molli di placca in abbondanza); così anche per l'indice di sanguinamento, che identifica lo stato di salute dei tessuti gengivali marginali (0 = non sanguinamento al passaggio della sonda parodontale lungo il margine gengivale intorno all'impianto; 1 = sanguinamento isolato; 2 = sanguinamento confluyente lungo tutto il margine; 3 = sanguinamento profuso).

Ricordiamo che i criteri di successo adottati sono stati quelli di



Albrektsson et al<sup>26</sup> :

- Un impianto testato individualmente deve essere clinicamente immobile
- Una radiografia non deve evidenziare alcuna radiotrasparenza implantare
- La perdita ossea verticale deve essere inferiore a 0,2 mm all'anno dopo il primo anno di carico
- Un impianto non deve presentare segni e sintomi quali dolore, infezione, neuropatia o violazione del canale mandibolare.

In questo studio sono state considerate anche eventuali complicanze, le quali potevano essere di due tipi: associate o non associate agli impianti. Le prime comprendono: la rottura dell'estremità di una fresa nel corso della preparazione chirurgica del sito implantare, la frattura dell'impianto o il fallimento della protesi (più precisamente di una delle sue componenti). Le seconde comprendono ogni altro evento avverso, di carattere moderato o severo (ad es. traumi subiti durante il *follow-up* o comparsa di patologie sistemiche). Gli eventi incorsi nello studio sono stati la frattura dell'*abutement* (n=3), la frattura del materiale a livello occlusale (n=1), la rottura della barra o della base protesica in acrilico

(n=1), nessuno dei quali ha influito sul successo implantare.

#### **5.2.4. Metodologia statistica**

La statistica può essere definita come la scienza che studia i fenomeni fisici e sociali suscettibili di variazione numerica. Applicata alle indagini conoscitive, rende misurabile ed esprimibile quantitativamente ciò che altrimenti potrebbe rimanere soltanto un'impressione soggettiva. Essa fornisce una metodologia per valutare i risultati di un esperimento "al di là della variabilità casuale", ad esempio permettendo di stimare sulla base di un campione i valori di parametri riguardanti un'intera popolazione, di comparare più fenomeni e stabilire se essi si diversificano per cause accidentali o per cause sistematiche. Il metodo statistico non garantisce certezze assolute, ma misura la probabilità della "verità" di un'ipotesi.

In pratica è conveniente distinguere tra statistica descrittiva e statistica inferenziale: la prima si limita ad esporre i dati raccolti tramite tabelle, diagrammi, grafici..., con l'obiettivo di permetterne una lettura espressiva e senza equivoci. La seconda, invece, ha il compito di analizzare ed elaborare i dati tramite appositi modelli matematici e di estendere talune delle conclusioni derivabili da

insiemi limitati di dati (campioni) a insiemi più numerosi (popolazioni). Quest'ultimo procedimento è detto di inferenza statistica, cioè di induzione delle conclusioni dal campione all'intera popolazione (rappresentata dal campione).

Le analisi statistiche eseguite in questo studio sono state effettuate applicando il programma SPSS su Personal Computer.

Tutte le variabili del protocollo sono state descritte statisticamente, stimando la media, la deviazione standard, la mediana e l'intervallo di variabilità per le variabili continue ed analizzando le distribuzioni di frequenza per le variabili discrete.

Per confrontare statisticamente i due gruppi rispetto alle variabili esaminate, sono stati utilizzati il test  $\chi^2$  o quello esatto di Fisher (quando corretto) ed il test non parametrico di Mann-Whitney. Il test  $\chi^2$  o quello esatto di Fisher sono stati usati per esaminare la significatività statistica dell'associazione tra due variabili discrete; il test non parametrico di Mann-Whitney per esaminare la significatività statistica dell'associazione tra una variabile continua ed una variabile dicotomica. E' stata anche utilizzata l'analisi della varianza per misure ripetute per esaminare le variazioni dei parametri clinici durante il *follow-up*. Le associazioni sono state considerate significative quando è risultato  $p < 0,05$ . La probabilità "p", usualmente detta livello di

significatività statistica, indica la probabilità che, nella popolazione rappresentata dal campione, non vi sia associazione tra le variabili considerate. Ciò significa che, tanto più  $p$  è piccola, tanto più è probabile che esista, nella popolazione, una effettiva associazione tra le variabili considerate.

### 5.3. Risultati

Durante l'anno 1995, su un totale di 16 pazienti trattati (10 donne e 6 uomini), con mandibole completamente edentule, sono stati inseriti 64 impianti. Si è avuto nel 100% dei casi un *follow-up* a 5 anni.

L'età media dei pazienti era 59,1 anni (range 37-79 anni).

I due gruppi di pazienti sono risultati omogenei rispetto al sesso e all'età (Tabelle 1,2).

Le caratteristiche geometriche lineari degli impianti nei due gruppi sono mostrate nella Tabella 3.

La figura 1 mostra le percentuali di successo implantare al termine del *follow-up*, nei due gruppi.

Tutti i 32 impianti appartenenti al gruppo CI si sono osteointegrati.



Dei 32 impianti inseriti nei pazienti appartenenti al gruppo IP/IS, invece, ne sono falliti due, uno primario ed uno secondario. La percentuale di successo implantare è stata del 93,8%, non differendo significativamente da quella nel gruppo CI. L'impianto secondario fallito era stato posizionato in zona 32: il paziente, dopo 3 mesi, lamentava dolorabilità nella regione dove erano stati inseriti gli impianti, alla visione clinica la gengiva perimplantare si presentava infiammata ed edematosa, la mobilità clinicamente testata era notevole (Periotest +8) ed all'indagine radiografica si notava una radiotrasparenza che circondava l'impianto. Tutte queste alterazioni hanno indotto alla rimozione dell'impianto, che è stato sostituito con uno di diametro maggiore dopo abbondante irrigazione antibiotica. Essendosi il nuovo impianto integrato non è stato necessario modificare la barra. Il secondo impianto perso, un primario in zona 44, è fallito dopo 5 mesi dal carico per mancanza di osteointegrazione. Non presentava, però, una tasca attiva o dolenzia, ma una perdita ossea pari a 3,5 mm. Come nel caso precedente, si è provveduto alla sostituzione dell'impianto con un di diametro maggiore, posizionato con la tecnica standard e l'ausilio di una membrana non riassorbibile rinforzata in titanio. L'*overdenture* per il periodo di quiescenza dell'impianto ha continuato ad essere sostenuta dai due impianti

secondari.

Complessivamente, il successo protesico, definito come stabilità continua della protesi, in accordo ai criteri presenti in letteratura,<sup>15,151</sup> è stato pari al 100%.

Tutti gli impianti osteointegrati, di ambedue i gruppi, hanno soddisfatto i criteri di successo implantare, menzionati nel precedente paragrafo<sup>26</sup>. Le Tabelle 4-7 mostrano l'analisi comparativa tra i due gruppi di pazienti e le statistiche descrittive dei parametri clinici utilizzati nel definire il successo implantare, durante tutto il periodo di *follow-up*. Nessuna differenza significativa è stata rilevata durante il periodo di *follow-up* e tra i due gruppi (minimo  $p>0,41$ ).

In particolare, i valori di Periotest per gli impianti osteointegrati hanno mostrato un intervallo di variabilità compreso tra  $-5,58$  e  $-4,45$  nel gruppo CI, e  $-5,7$  e  $-4,13$  nel gruppo IP/IS (Tabella 6).

I valori del riassorbimento osseo sono risultati tutti consistenti con i criteri di Albrektsson<sup>26</sup>.

#### **5.4. Discussione**

Il protocollo standard che si avvale del carico “differito” rappresenta ancora il trattamento di scelta per ottenere

un'osteointegrazione affidabile nel maggior numero di contingenze cliniche<sup>15,26</sup>. Da alcuni anni è stata proposto il protocollo del caricamento immediato, inizialmente applicato nella pratica clinica nell'ambito della riabilitazione di mandibole completamente edentule<sup>4</sup>. I risultati fin ora ottenuti sono promettenti ma, data l'esiguità, in letteratura, di studi clinici controllati longitudinali e a lungo termine<sup>123,127-132</sup> il problema è ancora controverso. Tuttavia, per soggetti con particolari caratteristiche bio-morfologiche, l'impiego di un protocollo che preveda il carico immediato può essere davvero di aiuto in quanto in grado di ridurre i tempi di attesa per la protesizzazione definitiva<sup>124,131,132</sup>. In questi casi, l'esecuzione delle procedure protesiche comporta l'unico disagio, per il paziente, di non poter indossare la protesi per i primi due giorni dopo l'intervento. Nel contempo, al momento della protesizzazione, si ottiene un'ottima ritenzione che migliora nettamente il *comfort* del paziente<sup>5</sup>.

Scopo principale del presente lavoro è stato quello di indagare l'effettiva efficacia a breve e lungo termine del caricamento immediato di impianti supportanti *overdenture* in pazienti totalmente edentuli.

La pianificazione dello studio e la scelta della tipologia di pazienti ha considerato alcuni dei risultati esistenti in letteratura<sup>132</sup>. Il

livello avanzato nella curva di apprendimento della metodica, derivato da questi risultati, ci ha permesso, tra l'altro, di far propri i presupposti necessari affinché si verifichi l'osteointegrazione. Tra questi vanno riscontrati la necessità dello splintaggio degli impianti inseriti e la scelta di pazienti, da riabilitare con *overdenture* inferiore supportata da quattro impianti, con osso di tipo I o II, tale da permettere il posizionamento di impianti lunghi, con buona stabilità primaria.

Un altro obiettivo è stato di confrontare due diverse modalità di apprestarsi al carico immediato degli impianti. La prima metodica si è avvalsa dell'inserimento di quattro impianti in regione interforaminale, tra di loro splintati con una barra con profilo ad U in titanio. Tale presidio pare essere in grado di conferire una notevole stabilizzazione agli impianti stessi, minimizzando i movimenti di rotazione dell'*overdenture*, poichè trasferisce i carichi prevalentemente in direzione verticale annullando, così, ogni forma di tensione. Per esempio, Graber & Besimo<sup>5</sup> e Ledermann<sup>4</sup>, nei loro studi, hanno mostrato che le *fixture*, in tal maniera, non vengono esposte a movimenti che ne possono compromettere l'osteointegrazione. La seconda metodica ("Impianti Primari/Impianti Secondari") ha, invece, previsto l'utilizzo combinato di due impianti caricati immediatamente, quelli centrali dei quattro posizionati nella



regione interforaminale, con due impianti (i laterali) caricati in due tempi, secondo il protocollo standard<sup>36</sup>.

Complessivamente, nello studio, tra i 64 impianti si sono verificati, entro 5 anni dal loro inserimento, solo 2 insuccessi. Si è avuta perciò un'incidenza complessiva di successo implantare del 96,9% che è nell'intervallo di valori riportati in letteratura. Per esempio, Degidi et al<sup>151</sup>, nella loro indagine clinica ed istologica, comprendente 75 pazienti trattati sia con carico immediato (CI), sia con carico non funzionale (CNF), hanno trovato il 3,1% di fallimento nel gruppo CI e lo 0,9% di insuccesso in quello CNF. Nel nostro studio, gli unici due insuccessi implantari si sono verificati entro un anno dall'inserzione dell'impianto, con un'incidenza di poco più elevata tra gli impianti inseriti nel gruppo IP/IS (2/32) che tra quelli inseriti nel gruppo IC (0/32). Questo è un risultato non inaspettato e consistente con i risultati di altri autori (e.g.<sup>123,133</sup>).

Considerando gli impianti dei gruppi CI e IP/IS separatamente, l'incidenza di successo implantare a 5 anni è stata 100% tra gli impianti appartenenti al gruppo CI e 93,8% tra gli impianti del gruppo IP/IS. Albrektsson et al.<sup>26</sup> hanno suggerito che, affinché una procedura implantare possa essere considerata soddisfacente, l'incidenza di successo a 5 anni dovrebbe essere almeno dell'85%. Rispetto a questo

criterio entrambi i tipi d'impianto possono dunque essere considerati soddisfacenti.

In base ai dati ottenuti non è possibile individuare le ragioni della differenza d'incidenza nel successo a lungo termine trovata tra le due metodiche terapeutiche. Si potrebbe pensare, almeno nel caso degli impianti secondari, che la maggior percentuale di insuccesso della tecnica "Impianti Primari/Secondari" si spieghi con l'elevato carico a cui vengono sottoposti questi impianti, come anche supposto da Schnitman<sup>123</sup> e Balshi<sup>133</sup>. Questi autori hanno trovato una percentuale di insuccesso, entro due anni, rispettivamente del 15% e 20%.

La differenza nell'incidenza a lungo termine osservata nel nostro studio tra la tecnica dei quattro impianti immediatamente caricati e quella degli impianti "IP/IS" indica che, almeno nel caso d'impianti sostenenti un'*overdenture* nella mandibola, la prima metodica potrebbe essere preferibile evitando il potenziale rischio biologico ed economico per il paziente di perdere gli impianti secondari. Ulteriori studi longitudinali più ampi sono comunque necessari per confermare i risultati dell'indagine presente.

In questo contesto, potrebbe essere molto utile la valutazione della "mobilità implantare primaria", in quanto potrebbe consentire di

definire criteri di decisione oggettivi per il caricamento immediato dell'impianto. Alcuni studi<sup>153-156</sup>, per esempio, recentemente hanno sperimentato una metodica strumentale conveniente e accurata che utilizza l'RFA (*Resonance Frequency Analysis; software by Integration Diagnostics Ltd., Göteborg, Sweden*).

#### **1.4.1. Conclusioni**

Dall'analisi dei risultati si è potuto osservare che il “carico immediato”, inteso come metodica terapeutica alternativa al protocollo standard in caso di mandibole completamente edentule da trattare con *overdenture*, soddisfa tutti i criteri di successo clinico, stabiliti da Albrektsson<sup>26</sup>.

Inoltre, entrambe le metodiche terapeutiche utilizzate in questo studio (IC, IP/IS) hanno evidenziato un'efficacia clinica comparabile.

Rispetto alla soluzione protesica complessiva, i pazienti hanno dimostrato notevole soddisfazione per la rapidità dei tempi di lavoro ed il costo relativamente contenuto in termini economici e di sedute operatorie.

**Tabella 1. Età nei pazienti in due gruppi<sup>§</sup>.**

	CI				IP/IS			
	Media	DS	Mediana	Min-Max	Media	DS	Mediana	Min-Max
Età (anni)	58,9	10,9	61	37-78	59,3	11,1	61	39-79

<sup>§</sup>Differenza tra i due gruppi non significativa (p=0,72).

**Tabella 2. Distribuzione per sesso dei pazienti nei due gruppi<sup>§</sup>.**

	CI n (%)	IP/IS n (%)
Femmine	5 (62,5%)	5 (62,5%)
Maschi	3 (37,5%)	3 (37,5%)

<sup>§</sup>Differenza tra i due gruppi non significativa (p=0,99).



**Tabella 3. Caratteristiche implantari nei due gruppi di pazienti<sup>§</sup>.**

	CI n (%)	IP/IS n (%)
Lunghezza impianto (mm)		
10	1 (3,1)	0 (0)
11	4 (12,5)	3 (9,4)
13	22 (68,8)	21 (65,6)
15	5 (15,6)	8 (25)
Diametro impianto (mm)		
3.3	12 (37,5)	15 (46,9)
3.8	20 (62,5)	17 (63,1) <sup>+</sup>

<sup>§</sup>Differenza tra i due gruppi non significativa ( $p>0,60$ ).

<sup>+</sup>2 di questi impianti, falliti, sono stati sostituiti da impianti con diametro 4.5mm.

**Tabella 4. Indice di placca nei due gruppi, durante il *follow-up*.<sup>§</sup>**

Mese dopo il carico	CI			IP/IS		
	Media	DS	Min-Max	Media	DS	Min-Max
6	0,46	0,64	0-3	0,53	0,70	0-3
12	0,62	0,71	0-3	0,44	0,62	0-3
24	0,51	0,60	0-3	0,49	0,64	0-3
36	0,57	0,69	0-3	0,55	0,68	0-3
48	0,48	0,53	0-3	0,60	0,56	0-3
60	0,54	0,48	0-3	0,51	0,63	0-3

<sup>§</sup>Differenza tra i valori durante il *follow-up* e tra i due gruppi non significativa ( $p>0,41$ ).

**Tabella 5. Indice di sanguinamento nei due gruppi, durante il follow-up.<sup>§</sup>**

Mese dopo il carico	CI			IP/IS		
	Media	DS	Min-Max	Media	DS	Min-Max
6	0,56	0,57	0-3	0,51	0,62	0-3
12	0,52	0,66	0-3	0,50	0,70	0-3
24	0,51	0,58	0-3	0,59	0,57	0-3
36	0,48	0,61	0-3	0,63	0,61	0-3
48	0,57	0,59	0-3	0,52	0,55	0-3
60	0,49	0,62	0-3	0,49	0,54	0-3

<sup>§</sup>Differenza tra i valori durante il *follow-up* e tra i due gruppi non significativa ( $p>0,66$ ).

**Tabella 6. Valori medi Periotest (u.p.) nei due gruppi, durante il follow-up.<sup>§</sup>**

Mese dopo il carico	CI	IP/IS
0	- 4,45	- 4,13
12	- 4,53	- 4,52 <sup>+</sup>
24	- 5,41	- 5,7
36	- 5,58	- 5,48
48	- 5,17	- 4,99
60	- 4,96	- 5,16

<sup>§</sup>Differenza tra i valori durante il *follow-up* e tra i due gruppi non significativa ( $p=0,75$ ).

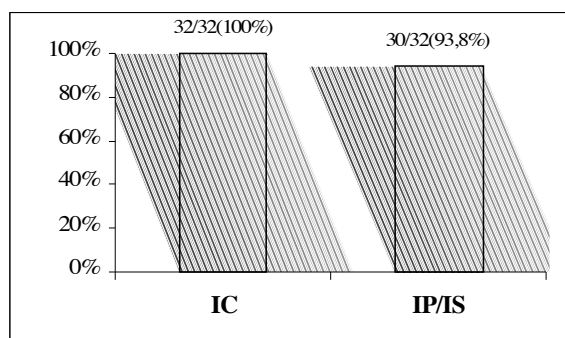
<sup>+</sup>I valori dal 12 mese sono quelli relativi ai 30/32 impianti non persi.

**Tabella 7. Riassorbimento medio osseo nei due gruppi, durante il follow-up.<sup>§</sup>**

Mese dopo il carico	CI (mm)	IP/IS (mm)
6	0,80	0,90
12	1,20	1,10
24	1,25	1,20
36	1,30	1,30
48	1,40	1,30
60	1,40	1,35

<sup>§</sup>Differenza tra i valori durante il *follow-up* e tra i due gruppi non significativa ( $p > 0,82$ ).

**Figura 1. Successo implantare nei due gruppi<sup>§</sup>.**



<sup>§</sup> Differenza tra i due gruppi non significativa ( $p = 0,51$ , test esatto di Fisher).

**Clinical trial on osseointegration using sandblasted or sandblasted and acid-etched implants**

L. PROSPER<sup>3</sup>, F. DI CARLO<sup>1</sup>, A. DADDONA<sup>2</sup>, S. REDAELLI<sup>3\*</sup>, M. QUARANTA<sup>1</sup>

(<sup>1</sup>University of Rome "La Sapienza" ; <sup>2</sup>University of Rome "Tor Vergata"; <sup>3</sup>University of Milan)

The aim of this prospective and randomized trial was to evaluate the long-term success rate of sandblasted (SL) or sandblasted and acid-etched (SLA) implants retaining fixed partial prostheses. Forty four partially edentulous adult patients were consecutively recruited during 1995 and randomized to receive 2-3 SL (23 pts) or SLA (21 pts) implants in posterior mandibles or maxillae. A total of 107 (54 SL, 53 SLA) implants was placed, 62 in mandibles and 45 in maxillae. Patients were restored with a fixed partial prosthesis and revisited every 3 months during the first year; thereafter periapical radiographs were taken annually up to 5 years. A 100% five-year follow-up was obtained. At second-stage surgery, which was performed after a 4- to 6-month healing period, none of implants showed signs of mobility, peri-implant infection, or bone loss. Seven SLA implants failed within 2 years after placement, 6 because of a peri-implantitis and 1 caused by an occlusal trauma. Based on annual assessments 100/107 (93.4%) of implants were considered successful according to Albrektsson's (1986) criteria. The success rate was higher in SL (100%) than SLA (86.8%) implants ( $p < 0.01$ ). Both sandblasted and sandblasted and acid-etched implants retaining fixed partial prostheses provide predictable long-term osseointegration results, but sandblasted implants might be more successfully used.



**JDR**  
THE OFFICIAL JOURNAL OF THE  
INTERNATIONAL ASSOCIATION  
FOR DENTAL RESEARCH

**JOURNAL OF  
DENTAL RESEARCH<sup>®</sup>**  
Volume 80 Special Issue (IADR Abstracts) March 2001

ABSTRACTS OF PAPERS

**IADR 79th General Session & Exhibition  
June 27-30, 2001  
Chiba, Japan**

Held in conjunction with the annual meetings of the Japanese Association for Dental Research and the following IADR Divisions: Australian/New Zealand, Chinese, Korean, and Southeast Asian

1877

**Implant-retained mandibular overdentures with immediate loading: clinical and histological study.**G. POMPA\*, M. CASSETTA, I. VOZZA, R. SCARINGI and M. QUARANTA  
(Dental school, Prost. Dept., La Sapienza University, Rome, Italy).

The aim of this study was a clinical and histological evaluation of immediately loaded implants used in mandibular overdentures.

Ten completely edentulous patients were selected with adequate bone in the mandibular intraforaminal area and a past medical history with no contraindications to implant therapy.

In each patient 4 osseointegrated implants 3,3 mm in diameter and a 11 mm long (Winxix Tm Ltd, London, UK) were inserted in 3.4, 3.3, 4.3, 4.4 sites.

Two implants were connected with an U-shaped gold bar, and were immediately loaded with mandibular overdentures. The other two implants, placed in 3.3 and 4.3 sites were left sleeping.

After 6 months from the immediate loading, a new mandibular overdentures was made supported by all the 4 osseointegrated implants.

In two cases, the inadequate placement of 2 immediately loaded implants, did not allow to use them prosthodontically, making necessary their removal for the final rehabilitation. In the implants removed no mobility or soft tissue peri-implant inflammation were clinically detectable. No peri-implant radiolucency was present on the radiographs, and the reduction in crestal bone levels adjacent to the implants between baseline and 6 months wasn't significant.

The histologic examination of the 2 retrieved implants showed no inflammatory dense connective tissue in the central and coronal portion, while apical portion was surrounded by newly formed bone tissue. In this connective tissue there were many active osteoblasts with osteoid matrix.

Our clinical and histological results show that immediately loaded implants can be used with no untoward effects occurring such as the formation of a fibrous tissue at the interface or crestal bone resorption.

3<sup>rd</sup> World Congress of Osteointegration

## Healing period of titanium implants with sandblasted and acid-etched surface

L Prosperi,<sup>a</sup> F Di Carlo,<sup>a</sup> S Radaelli,<sup>b</sup> G Radaelli,<sup>c</sup> R Scaringi,<sup>d</sup> M Quaranta<sup>a</sup>

<sup>a</sup> Department of Clinical Dentistry, University 'La Sapienza', Rome, <sup>b</sup> Department of Special Surgery, University of Milan, <sup>c</sup> Department of Informative System, University of Milan, <sup>d</sup> San Raffaele Hospital, Department of Oral Surgery, Milan, Italy.

### Objective

The aim of this multicenter, prospective, randomized controlled trial was to evaluate the healing period of sandblasted and acid-etched (SLA) titanium screw shaped implants in comparison to sandblasted (SL) implants. (WIN SIX L.T.D. London).

### Methods

**SUBJECTS:** 106 females and 70 males; mean±SD age 41.8±11.2; recruited in a five-year period (1995-1999) by three dental practices.

**IMPLANTS:** 235 SLA and 241 SL randomly placed in the maxilla and mandible of patients who underwent two-stage non-immediate surgery.

**BONE RESPONSE:** was examined at 1, 2, 3, 4 and 6 months after placement of implants evaluating:

- peri-implant radiolucency (by standardized periapical radiographies)
- implant stability (by Periotest).

### Results

Figure 3. Bone response at month 2 (absence of radiolucencies and Periotest>0) according to the implant surface and class of bone density. SLA vs SL. SL: p<0.0001 for class I; p<0.0001 for classes II, III and IV.

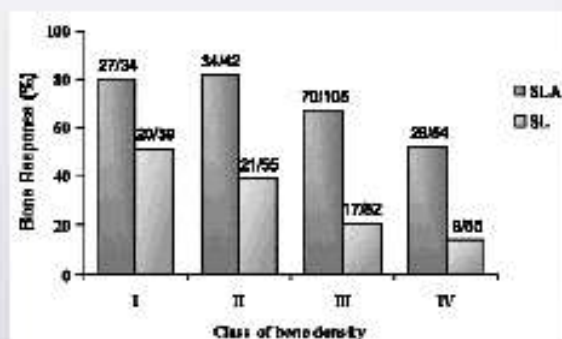


Figure 1. Scanning electron microscope (SEM) 1000x magnification of SL surface

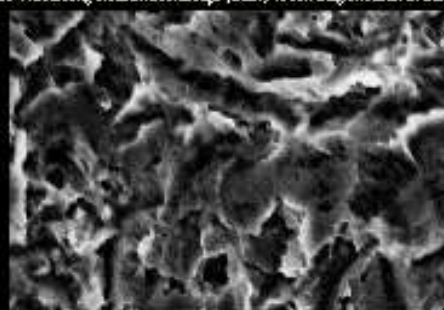


Figure 2. Scanning electron microscope (SEM) 1000x magnification of SLA surface

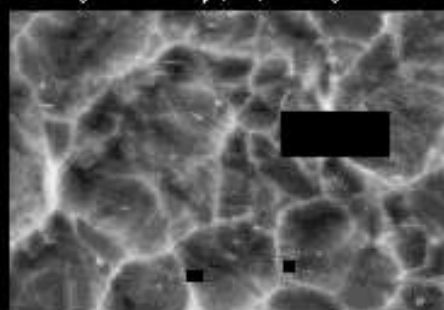


Table 1. Bone response (absence radiolucencies) in two groups of implants

Month after placement of implant	SLA (n=233) n (%)	SL (n=241) n (%)	p‡
1	115 (48.9)	35 (14.5)	<0.0001
2	159 (67.6)	67 (27.8)	<0.0001
3	193 (82.1)	121 (50.2)	<0.0001
4	222 (94.5)	155 (64.3)	<0.0001
6	235 (100)	241 (100)	1

†SLA vs. SL, overall comparison p<0.001 (Fisher's test).

‡Chi-square test.

Multiple Cox regression analysis showed that the SLA surface improved the bone response during the healing period as compared to the SL surface (p<0.001).

### Conclusion

Titanium screw shaped implants with SLA surface showed a better bone response during healing period as compared to the SL surface.

**1 Tempo di guarigione ossea per impianti di titanio con superficie sabbiata o superficie sabbiata e mordenzata**

L. Prosper, F. Di Carlo, S. Redaelli, G. Redaelli, R. Scaringi, M. Quaranta  
IJP La rivista Internazionale di Odontoiatria volume 13 - numero 1

---

**2 Using of Gore Resolut Membrane in 223 post-extraction Winsix implants**

L. Prosper, S. Redaelli, G. Pompa, A. Palattella, M. Quaranta  
Atti 4TH Joint meeting 24-27 August, Warsaw-Poland

---

**3 Gore Resolut membrane and implantation below the crest in postextraction surgery**

F. Di Carlo, L. Prosper, S. Redaelli, I. Guadagno, M. Quaranta

---

**4 Analisi in vivo su tre superfici implantari: valutazione istomorfometrica**

S. Redaelli, L. Prosper, F. Di Carlo, A. Scarano, I. Vozza



# IJP

*La Rivista Internazionale di Odontoiatria Protesica*



Nuova edizione Italiana,  
contenente l'edizione integrale  
statunitense

1

Gennaio/Febbraio  
2000



## Tempo di guarigione ossea per impianti di titanio con superficie sabbata o superficie sabbata e mordenzata

Dr. L. Prosper<sup>a</sup>  
 Dr. F. Di Carlo<sup>c</sup>  
 S. Redaelli<sup>f</sup>  
 Dr. G. Radaelli<sup>e</sup>  
 Dr. R. Scaringi<sup>d</sup>  
 Prof. M. Quaranta<sup>b</sup>

**Scopo:** Lo scopo di questo studio clinico multicentrico, prospettico e randomizzato fu determinare e confrontare i tempi di guarigione ossea, dopo l'inserzione nelle mascelle in interventi a due stadi non post-estrattivi, di impianti di titanio con superficie sabbata (SL) o superficie sabbata e mordenzata (SLA). **Materiali e Metodi:** In 156 soggetti adulti d'età compresa tra 18 e 75 anni e parzialmente o totalmente edentuli furono inseriti 214 impianti SL e 207 impianti SLA. La guarigione ossea fu valutata tramite radiografia endorale 1 mese dopo l'inserzione dell'impianto, e anche tramite Periotest 2, 4 e 6 mesi dopo. Si ebbe un follow-up a sei mesi del 100%. **Risultati:** Durante il periodo di guarigione ossea nessun impianto mostrò alcun visibile segno di mobilità, di infezione peri-implantare o di perdita ossea. Il tempo di guarigione fu significativamente più breve nel gruppo SLA che nel gruppo SL (media 1,5 vs 3,2 mesi,  $p < 0,0001$ ). Due mesi dopo l'inserzione dell'impianto, l'incidenza di guarigione ossea fu del 68,1% tra gli impianti SLA e del 25,7% tra quelli SL ( $p < 0,0001$ ). Dopo quattro mesi le corrispondenti percentuali furono 94,2% e 62,6% rispettivamente ( $p < 0,0001$ ). Dopo sei mesi la guarigione ossea fu del 100% in entrambi i gruppi. L'analisi di regressione logistica confermò l'esistenza di un'associazione indipendente tra la guarigione ossea due mesi dopo l'inserzione dell'impianto e il tipo di impianto ( $p < 0,001$ ). **Conclusioni:** Il trattamento della superficie di un impianto di titanio tramite sabbatura e mordenzatura riduce, rispetto alla sola sabbatura, il tempo di guarigione ossea e potrebbe perciò permettere di caricare più precocemente l'impianto. Prima pubblicazione. Versione originale in Lingua italiana.

Durante gli ultimi decenni, ad iniziare dagli studi di Brånemark e Coll.<sup>1,2</sup> e di Schroeder e Coll.,<sup>3-5</sup> l'implantologia ha assunto in ambito odontoiatrico protesico un ruolo sempre più rilevante, non solo per la riabilitazione clinica e funzionale del paziente edentulo ma pure per il miglioramento del suo aspetto estetico.

Diversi studi hanno dimostrato la stabilità a lungo termine degli impianti di titanio commercialmente puri.<sup>6-14</sup> Tut-

tavia, come osservato da Thomas e Cook<sup>15</sup> e confermato da altri autori,<sup>16-19</sup> l'effettivo ancoraggio di tali impianti nell'osso dipende essenzialmente dalla conformazione della loro superficie, in particolare dalla ruvidezza, in quanto essa potrebbe avere un ruolo diretto sulla proliferazione e sulla differenziazione degli osteoblasti, come anche sulla matrice di produzione.<sup>20-31,47</sup> Di fatto, una maggior ruvidezza è ottenibile trattando la superficie dell'impianto con appositi procedimenti chimico-fisici. Nell'odontoiatria clinica, ai metodi additivi sono forse preferibili quelli sottrattivi, che consentono di eliminare il rischio di contaminazione e di ridurre il rischio di diffusione di particolato durante l'inserzione dell'impianto.<sup>32</sup> In verità, mentre alcuni studi<sup>33-36</sup> hanno evidenziato che la superficie non trattata aumenta il rischio di insuccesso, soprattutto nelle aree dentali a bassa densità e/o con ridotta altezza ossea, numerosi altri studi in vitro<sup>20-22,26,28,30</sup> e in vivo<sup>16-19,37-39</sup> hanno mostrato che dal punto di vista istometrico e biomeccanico i migliori risultati si ricavano sabbando e mordenzando la superficie dell'impianto. Gli impianti così trattati danno prestazioni uguali o

<sup>a</sup>Docente Corso di Perfezionamento in Implantoprotesi Università di Roma "La Sapienza"

<sup>b</sup>Titolare di Cattedra di Protesi Dentaria Università di Roma "La Sapienza"

<sup>c</sup>Prof. A Contratto di Protesi Dentaria Università di Roma "La Sapienza"

<sup>d</sup>Ospedale San Raffaele Milano Chirurgia Orale

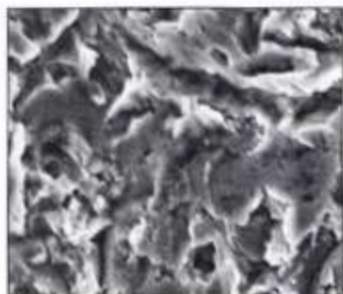
<sup>e</sup>Divisione Sistemi Informativi, Università degli Studi di Milano

<sup>f</sup>Università di Milano Dipartimento di Chirurgia Speciale

**Indirizzo per la corrispondenza:** Dr. Loris Prosper, Via San Gottardo 84, 20052 Monza, Fax 039 362766.  
 e-mail: lorisp@tin.it

Tempo di guarigione ossea per impianti di titanio


Prosper e Coll.



**Fig. 1** Fotografia al SEM di impianto SL 1000x.



**Fig. 2** Fotografia al SEM di impianto SLA 50x.



**Fig. 2a** Fotografia al SEM di impianto SLA 250x.

anche migliori sia di quelli con superficie plasma-sprayed,<sup>16-19,37,39</sup> sia di quelli, recentemente introdotti, con superficie direttamente mordenzata (Osseotite), e questo specialmente nel primo periodo di osteointegrazione.<sup>38</sup> Una più rapida osteointegrazione potrebbe essere riflesso di un più breve periodo di guarigione ossea, una condizione vantaggiosa affinché l'impianto possa essere proficuamente caricato. L'esame di eventuali relazioni tra il tempo di guarigione ossea ed il tipo d'impianto potrebbe perciò avere rilevanti implicazioni cliniche e di benessere per il paziente.

Lo scopo di questo studio fu determinare e confrontare i tempi di guarigione ossea di impianti di titanio con superficie solo sabbiata (SL) o superficie sabbiata e mordenzata (SLA).

### Materiali e Metodi

Questo studio clinico multicentrico, prospettico e randomizzato fu condotto tra i soggetti parzialmente o totalmente edentuli consecutivamente ammessi, nel periodo compreso tra il gennaio 1995 e il giugno 1999, ad uno di tre studi professionali odontoiatrici per essere sottoposti ad intervento chirurgico implantare. I criteri di inclusione furono: età compresa tra 18 e 75 anni; appartenenza alla razza caucasica; compliance con le norme d'igiene orale domestica; intervento a due stadi non post-estrattivo. I criteri di esclusione furono: presenza di patologie dismetaboliche e/o croniche e/o infettive; abitudine al fumo (>3 sigarette/die); abuso di alcool (>30g/die).

Complessivamente, 156 pazienti, 98 donne e 58 uomini, età media (DS) 42,3 (11,5) anni, risultarono eleggibili e parteciparono allo studio.

Il protocollo, approvato da un Comitato Etico composto da membri dei centri partecipanti, fu spiegato in dettaglio a ciascun soggetto, che firmò un consenso informato scritto per la sua partecipazione.

Ai pazienti, stratificati rispetto al centro di appartenenza (n=73,40,43), furono posizionati, in modo randomizzato (stessa chance), impianti di titanio cilindrici a vite (Win-six™, Ltd, London, UK) aventi superficie solo sabbiata o su-

perficie sabbiata e mordenzata. La sabbiatura utilizzò particelle di biossido di titanio (TiO<sub>2</sub>) con diametro 150µm, la mordenzata acido fluoridrico (HF) in soluzione con acqua. Le caratteristiche superficiali dei due tipi di impianto, come evidenziate dalla microscopia elettronica a scansione (SEM), sono mostrate nella Figura 1. Entrambe le superfici mostrano una simile topografia superficiale primaria dovuta alla sabbiatura, ma la superficie mordenzata presenta in più microanfratti, prodotti dal processo di acidificazione, dal diametro compreso tra 1 e 2µm. La ruvidezza media, valutata tramite l'analisi profilometrica risultò di 2µm per entrambi i tipi d'impianto (Figure 2-2a).

L'inserzione degli impianti nei mascellari dei pazienti fu effettuata da tre (uno per centro) odontoiatri esperti (più di 5 anni di esperienza chirurgica implantare al momento dell'inizio dello studio) seguendo un protocollo chirurgico standard.<sup>40</sup> In totale, furono inseriti 421 impianti (214 SL e 207 SLA), con una media di 2,7 impianti per paziente, intervallo di variabilità 1-5.

Lo stato di guarigione ossea fu esaminato 1, 2, 4 e 6 mesi dopo l'inserzione dell'impianto. A un mese esso fu valutato tramite radiografia endorale, a 2, 4 e 6 mesi anche tramite Periotest (Periotest, Medizintechnik Gulden, Bensheim, Germany). La guarigione ossea fu definita, un mese dopo l'inserzione dell'impianto, come presenza di radiodensità ricoprente tutte le spire dell'impianto. Due, 4 e 6 mesi dopo l'inserzione, essa fu definita come presenza di radiodensità e valore Periotest minore di zero. Le diagnosi di guarigione furono effettuate per tutti gli impianti da esperti odontoiatri che non erano a conoscenza del tipo d'impianto inserito. In particolare, tutte le radiografie furono lette da due odontoiatri separatamente, e si assunse la guarigione ossea (radiologica) quando la diagnosi di entrambi concordò in tal senso.

### Analisi statistica

I dati descrittivi sono mostrati come numero di osservazioni e/o percentuale. Le curve del tempo di guarigione ossea sono state costruite secondo il metodo di Kaplan-Meier e



Prosper e Coll.

Tempo di guarigione ossea per impianti di titanio

confrontate tramite il test di Breslow. Il confronto tra i due gruppi di impianti (SL e SLA), due mesi dopo l'intervento, è stato effettuato tramite il test chi-quadrato o il test esatto di Fisher quando appropriato. È stata inoltre condotta un'analisi di regressione logistica multivariata, corretta per il sesso e l'età dei soggetti e per altri potenziali fattori di confondimento (centro di appartenenza, classe di densità ossea, arcata dentale d'inserzione, zona dentale d'inserzione, dimensioni lineari dell'impianto) per valutare l'esistenza di un'effettiva associazione indipendente tra la guarigione ossea e il tipo d'impianto. Valori di  $p$  minori di 0,05 sono stati considerati indicare una significatività statistica (test a due code). Per l'analisi statistica è stato utilizzato il programma SPSS 8.0 per Windows (SPSS Inc., Chicago, IL, USA).

### Risultati

Si ebbe un follow-up a sei mesi del 100%. La Tabella 1 riporta le caratteristiche dentali ed implantari nei due gruppi di impianti. In entrambi i gruppi, la classe di densità ossea più frequente fu la III, con una prevalenza complessiva del 40,6%. Sia tra gli impianti sabbiati che tra quelli mordenzati il numero d'impianti inseriti nell'arcata dentale superiore è risultato maggiore del numero d'impianti inseriti nell'arcata inferiore, con un rapporto approssimativamente di 1,2:1 nel gruppo SL e 2,1:1 nel gruppo SLA. Un risultato simile è stato trovato per la zona dentale, con un rapporto tra zona posteriore ed anteriore pari a 5,3:1 nel gruppo SL e 2,3:1 nel gruppo SLA. In particolare, nel gruppo SL il 12,1% degli impianti fu inserito nella zona incisiva, il 3,8% nella zona canina, il 43,9% nella zona premolare e il 40,2% in quella molare. Tra gli impianti sabbiati e mordenzati, le percentuali corrispondenti furono 22,7%, 7,8%, 32,8% e 36,7%. Rispetto alle dimensioni lineari dell'impianto, le lunghezze più prevalenti sono state, in entrambi i gruppi, 11 e 13mm, che rappresentano circa il 90% degli impianti. Il diametro più frequente è stato 3,8mm (circa 60% in entrambi i gruppi), mentre i diametri 3,3 e 4,5mm sono risultati essere similmente distribuiti.

Durante il periodo di guarigione ossea nessun impianto mostrò alcun visibile segno di mobilità, di infezione peri-implantare o di perdita ossea. L'incidenza di guarigione nei sei mesi successivi all'inserzione dell'impianto è mostrata nella Tabella 2. Il periodo di guarigione ossea fu significativamente più breve tra gli impianti SLA che tra quelli SL (media 1,5 vs 3,2 mesi,  $p < 0,0001$ ). In particolare, la proporzione di guarigioni è stata superiore nel gruppo SLA sia 1 che 2 e 4 mesi dopo l'inserzione dell'impianto ( $p < 0,0001$ ). A sei mesi l'incidenza di guarigione ossea è stata del 100% in entrambi i gruppi.

L'analisi statistica post-hoc ha mostrato che, due mesi dopo l'inserzione dell'impianto, in tutte le classi di densità ossea la guarigione è più prevalente tra gli impianti SLA che

**Tabella 1.** Caratteristiche dentali ed implantari nei due gruppi d'impianti.

	SL (n=214) n(%)	SLA (n=207) n (%)
<b>Classe di densità ossea</b>		
I	35 (16,3)	29 (14)
II	50 (23,4)	33 (15,9)
III	70 (32,7)	101 (48,8)
IV	59 (27,6)	44 (21,3)
<b>Arcata dentale d'inserzione</b>		
Superiore	114 (53,3)	141 (68,1)
Inferiore	100 (46,7)	66 (31,9)
<b>Zona dentale d'inserzione</b>		
Anteriore	34 (12,1)	63 (30,4)
Posteriore	180 (88,9)	144 (69,6)
<b>Lunghezza dell'impianto (mm)</b>		
11	95 (44,4)	68 (32,9)
13	101 (47,2)	110 (53,1)
15	16 (7,5)	24 (11,6)
17	2 (0,9)	5 (5,4)
<b>Diametro dell'impianto (mm)</b>		
3,3	43 (20,1)	37 (17,9)
3,8	131 (61,2)	118 (57,0)
4,5	40 (18,7)	52 (25,1)

**Tabella 2** Incidenza (%) di guarigione ossea nei due gruppi d'impianti.\*

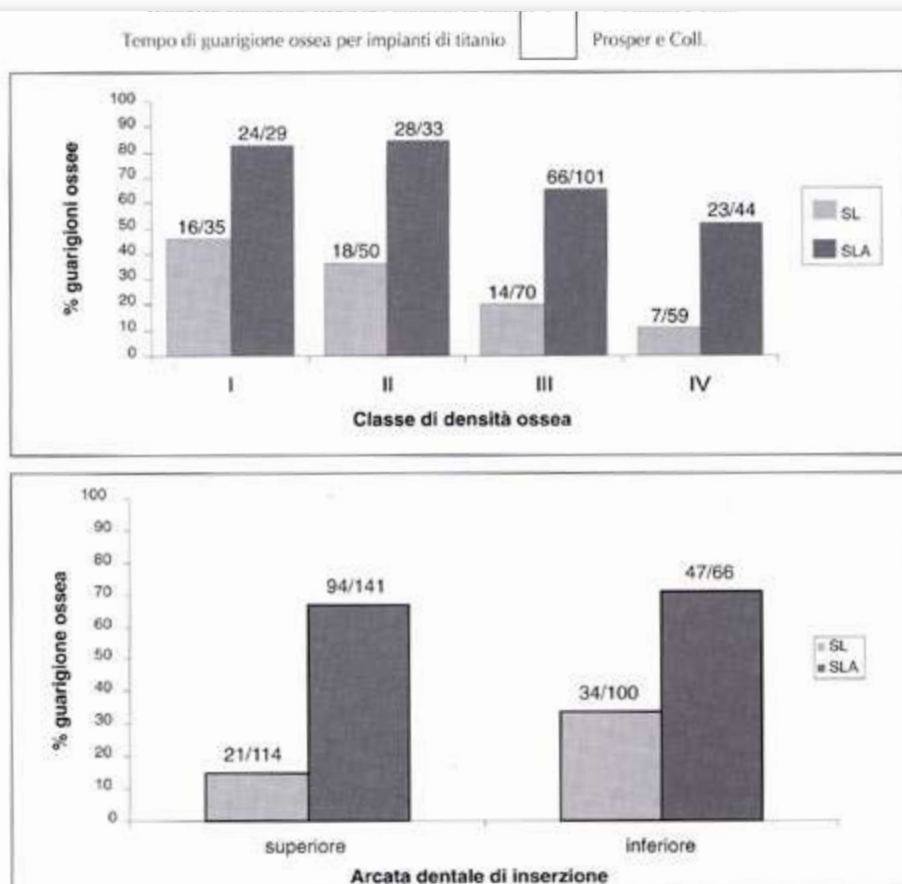
Mesi <sup>†</sup>	SL (n=214) n (%)	SLA (n=207) n (%)	p <sup>‡</sup>
1	29 (13,5)	102 (49,3)	<0,0001
2	55 (25,7)	141 (68,1)	<0,0001
4	134 (62,6)	195 (94,2)	<0,0001
6	214 (100)	207 (100)	1

\*SLA vs SL,  $p < 0,001$  (test di Breslow).

<sup>†</sup> Mesi successivi all'inserzione dell'impianto

<sup>‡</sup> Test chi-quadrato o test esatto di Fischer.

tra quelli SL (classe di densità I, 82,8% vs 45,7%,  $p < 0,001$ ; classe II, 84,8% vs 36,0%,  $p < 0,0001$ ; classe III, 65,3% vs 20%,  $p < 0,0001$ ; classe IV, 52,3% vs 11,9%,  $p < 0,0001$ ) (Figura 3). La Figura 4 e la Figura 5 mostrano i risultati di un'analoga analisi effettuata considerando rispettivamente l'arcata e la zona dentale d'inserzione. Due mesi dopo l'inserzione dell'impianto l'incidenza di guarigione ossea è stata significativamente maggiore nel gruppo SLA che nel gruppo SL, sia per gli impianti inseriti nell'arcata dentale superiore (66,7% vs 18,4%,  $p < 0,0001$ ) sia per quelli inseriti nell'arcata inferiore (71,2% vs 34,0%,  $p < 0,0001$ ) (Figura 3). Similmente, l'incidenza di guarigione ossea fu significativamente maggiore nel gruppo SLA che in quello SL tanto tra gli impianti inseriti anteriormente (71,4% vs 26,5%,  $p < 0,0001$ ) che tra quelli inseriti posteriormente (66,7% vs 25,5%,  $p < 0,0001$ ). L'analisi di regressione logistica multivariata confermò l'esistenza di un'associazione indipendente tra la guarigione ossea, due mesi dopo l'inserzione dell'impianto, ed il tipo d'impianto (odds ratio 2,7,  $p < 0,001$ ),



**Fig. 3** Distribuzione delle guarigioni ossee, 2 mesi dopo l'inserzione degli impianti, rispetto alla classe di densità ossea. SLA vs SL,  $p < 0,001$  per la classe I;  $p < 0,0001$  per le classi II, III e IV.

**Fig. 4** Distribuzione delle guarigioni ossee, 2 mesi dopo l'inserzione degli impianti, rispetto all'arcata dentale di inserzione. SLA vs SL,  $p < 0,0001$  per entrambe le arcate di inserzione.

mostrando che la probabilità di una più precoce guarigione è maggiore tra gli impianti sabbiati e mordenzati.

La Tabella 3 mostra infine l'incidenza di guarigione ossea tra gli impianti SLA, rispetto alle caratteristiche dentali. Il periodo medio di guarigione fu tendenzialmente più breve nelle classi di densità ossea normale (I,II,III) che nella classe IV (1,4 vs 2 mesi), ma la differenza non fu significativa ( $p > 0,05$ ). L'incidenza di guarigione a due mesi fu comunque maggiore del 50% in tutte le classi di densità ossea. Non vi furono differenze significative nel tempo medio di guarigione né tra le arcate, né tra le zone dentali d'inserzione. In tutti questi gruppi il periodo medio di guarigione fu approssimativamente di 1,5 mesi.

### Discussione

Negli ultimi anni, diverse metodi sono stati utilizzati per aumentare la ruvidezza superficiale di impianti di titanio commercialmente puri, in quanto questa caratteristica è stata trovata essere associata positivamente con il processo di osteointegrazione.<sup>17-20</sup> Sebbene non è a tutt'oggi chiaro se esista una superficie ottimale rispetto al successo impiantare, una questione importante in ambito odontoiatrico clinico è se una maggiore ruvidezza unita a particolari to-

pografie superficiali possa determinare una più precoce guarigione ossea dopo l'inserzione dell'impianto nella mascella. Lo scopo della presente indagine fu esaminare l'esistenza di possibili relazioni tra il tempo di guarigione ossea e la topografia superficiale dell'impianto.

In questo studio furono testati due tipi d'impianto di titanio cilindrici a vite, rispettivamente con superficie solo sabbiata e superficie sabbiata e mordenzata, inseriti nelle mascelle di pazienti parzialmente o totalmente edentuli. Gli impianti furono scelti in base alle proprietà specifiche, di ritenzione primaria da noi riscontrate negli impianti Win-six; va inoltre aggiunto che entrambi i metodi di trattamento della superficie eliminano il rischio di contaminazione e riducono quello di diffusione di particelle di titanio durante l'intervento chirurgico.<sup>32</sup> Inoltre, gli impianti SLA sono stati dimostrati avere un buon ancoraggio nell'osso e un comportamento complessivo uguale se non migliore di quello di impianti plasma-sprayed.<sup>16-19,37,39</sup> Gli impianti solo sabbiati sono stati considerati quali impianti di confronto sia perché tra i più diffusi nella pratica clinica sia perché essi presentano una ruvidezza media (2 $\mu$ m) comparabile con quella degli impianti SLA. La differenza topografica fondamentale tra i due tipi d'impianto sta essenzialmente nel fatto che la sabbiatura produce una ruvidezza superficiale



Tempo di guarigione ossea per impianti di titanio

Prosper e Coll.

sioni lineari comparabili, erano privi, per la loro struttura a vite autofillettante, di qualsiasi elemento di ritenzione macroscopica, e quindi, di fatto, differivano essenzialmente per il diverso trattamento della superficie. Si potrebbe perciò supporre che il miglior risultato mostrato dagli impianti SLA sia principalmente dovuto al trattamento di acidificazione. Questa conclusione è in accordo con numerose indagini biomeccaniche condotte su animali.<sup>16-19,37-39,46,47</sup> Per esempio, Klokkevold e Coll.<sup>46</sup> studiarono la resistenza alla rimozione di impianti dentali di titanio a vite, due mesi dopo la loro inserzione nel femore di conigli. Essi trovarono che tale resistenza è 4 volte maggiore tra gli impianti con superficie mordenzata che tra gli impianti non trattati, suggerendo che l'acidificazione della superficie aumenta l'intensità dell'osteointegrazione. Più recentemente, Buser e Coll.<sup>18</sup> inserirono e confrontarono nei mascellari di maiali impianti di titanio a vite con superficie solo mordenzata ed impianti con superficie sabbata e mordenzata. Essi trovarono che fino al terzo mese di guarigione gli impianti SLA richiedono una forza di torsione di rimozione tra il 75% e il 125% maggiore di quella degli impianti solo mordenzati, mostrando che l'effetto positivo dell'acidificazione è ulteriormente accentuato se sovrapposto alla sabbatura. A tal proposito, potremmo forse ipotizzare che negli impianti SLA la presenza di anfratti microscopici, sovrapposti alla geometria reticolare dovuta alla sabbatura, aumenti la forza d'attrito statico tra l'impianto e il tessuto osseo, e favorisca l'adesione superficiale. Una conseguenza potrebbe essere una più marcata stimolazione ed intensificazione del processo osteoblastico, e quindi una riduzione del periodo di guarigione ossea e una più efficace osteointegrazione. Quest'ultima ipotesi è consistente con numerosi risultati sperimentali che hanno dimostrato l'esistenza di relazioni dirette tra la topografia della superficie implantare, la proliferazione e la differenziazione osteoblastica.<sup>20-31</sup> Nei nostri dati, l'ipotesi di una più marcata stimolazione del processo osteoblastico tra gli impianti SLA è rafforzata dal fatto che si osservò una notevole riduzione del periodo di guarigione ossea anche nella classe di densità IV e nell'arcata dentale superiore.

Il nostro studio, oltre a confermare l'importanza della ruvidezza quale fattore che favorisce l'osteointegrazione di impianti di titanio, evidenzia che le caratteristiche topografiche superficiali potrebbero avere un ruolo molto rilevante nel ridurre il periodo di guarigione ossea.

### Conclusione

Il periodo di guarigione ossea di impianti di titanio a vite inseriti nelle mascelle di pazienti adulti è più breve tra gli impianti sabbati e mordenzati che tra quelli solo sabbati, indipendentemente dal sito d'inserzione e dalla densità ossea. Entro due mesi dall'inserzione dell'impianto quasi il 70% dei casi SLA raggiunse la guarigione ossea, e la percentuale di guarigioni fu soddisfacente (>50%) anche nelle zone

dentali a più bassa densità. L'uso d'impianti di titanio sabbati e mordenzati potrebbe perciò consentire di caricare precocemente l'impianto, con notevoli benefici clinici e di conforto per il paziente. Studi longitudinali sono auspicabili per valutare la possibilità di introdurre nella pratica clinica nuovi tipi d'impianti di titanio con topografie superficiali che migliorino ulteriormente le proprietà di stabilità, di guarigione ossea e d'osteointegrazione dell'impianto.

### Ringraziamenti.

Gli autori ringraziano per il contributo scientifico il Dr. Paolo De Mar, libero professionista a Montebelluna (Treviso).

### Bibliografia

1. Brånemark P-I, Breine U, Adell R, Hansson BO, Lindström J, Olsson A. Intraosseous anchorage of dental prostheses. I. Experimental studies. *Scand J Plast Reconstr Surg* 1969; 3:81-100.
2. Brånemark P-I, Hansson BO, Adell R, Breine U, Lindström J, Hallen O, Ohman A. Osseointegrated implants in the treatment of the edentulous jaw. Experience from a 10-year period. *Scand J Plast Reconstr Surg* 1977; 11(suppl.16):1-132.
3. Schroeder A, Pohler O, Sutter F. Gewebereaktion auf ein Titan-Hohlzylinderimplantat mit Titan-Spritzschichtoberfläche. *Schweiz Monatsschr Zahnheilk* 1976; 86:713-727.
4. Schroeder A, Stich H, Straumann F, Sutter F. Über Die Anlagerung von Osteozement an einen belasteten Implantatkörper. *Schweiz Monatsschr Zahnheilk* 1978;88:1051-1058.
5. Schroeder A, van der Zypen E, Stich H, Sutter F. The reaction of bone, connective tissue and epithelium to endosteal implants with sprayed titanium surfaces. *J Maxillofac Surg* 1981;9:15-25.
6. Adell R, Lekholm U, Rockler B, Brånemark P-I. A 15-year study of osseointegrated implants in the treatment of the edentulous jaw. *J Oral Surg* 1981;10:387-416.
7. Babbush CA, Kent JN, Misiek DJ. Titanium plasma-sprayed (TPS) screw implants for the reconstruction of the edentulous mandible. *J Oral Maxillofac Surg* 1986;44:274-282.
8. Behneke A, Behneke N, d'Hoedt B, Wagner W. Hard and soft tissue reactions to ITI screw implants: 3-year longitudinal results of a prospective study. *Int J Oral Maxillofac Implants* 1987;12:749-757.
9. Adell R, Eriksson B, Lekholm U, Brånemark P-I, Jemt T. A long-term follow-up study of osseointegrated implants in the treatment of totally edentulous jaws. *Int J Oral Maxillofac Implants* 1990;5:347-359.
10. Buser B, Weber HP, Lang NP. Tissue integration of non-submerged implants. 1-year results of a longitudinal study with ITI hollow-screw and hollow-cylinder implants. *Clin Oral Implants Res* 1990;1:78-85.
11. van Steenberghe D, Lekholm U, Bolender C, Folmer T, Henry P, Herrmann J, Higuchi K, Laney W, Linden U, Astrand P. Applicability of osseointegrated oral implants in the rehabilitation of partial edentulism: a prospective multicenter study on 558 fixtures. *Int J Oral Maxillofac Implants* 1990;5:272-281.
12. Buser B, Weber HP, Brugger U, Balsiger C. Tissue integration of one-stage ITI implants. 3-year results of a longitudinal study with hollow-cylinder and hollow-screw implants. *Int J Oral Maxillofac Implants* 1991;6:405-412.
13. Mericske-Stern R, Steinlin-Schaffner T, Marti P, Geering AH. Peri-implant mucosal aspects of ITI implants supporting overdentures. A 5-year longitudinal study. *Clin Oral Implants Res* 1994;5:9-18.

14. Buser D, Mericske-Stern R, Bernard JP, Behneke A, Behneke N, Hirt HP, Belser UC, Lang NP. Long-term evaluation of non submerged ITI implants. Part I: 8-year life table analysis of a prospective multi-center study with 2359 implants. *Clin Oral Implants Res* 1997;8:161-172.
15. Thomas KA, Cook S. An evaluation of variables influencing implant fixation by direct bone apposition. *J Biomed Mater Res* 1985;19:875-901.
16. Cochran DL, Schenk RK, Lussi A, Higginbottom FL, Buser D. Bone response to unloaded and loaded titanium implants with a sandblasted and acid-etched surface. A histometric study in the canine mandible. *J Biomed Mater Res* 1988;40:1-11.
17. Wilke HJ, Claes L, Steinemann S. The influence of various titanium surfaces on the interface shear strength between implants and bone. In: Heimke G, Soltész U, Lee AJC (eds). *Advances in Biomaterials, Vol 9: Clinical Implants Materials*. Amsterdam: Elsevier Science 1990:309-314.
18. Buser B, Schenk RK, Steinemann S, Fiorellini JP, Fox CH, Stich H. Influence of surface characteristics on bone integration of titanium implants. A histometric study in miniature pigs. *J Biomed Mater Res* 1991;25:889-902.
19. Wong M, Eulenberger J, Schenk RK, Hunziker E. Effect of surface topography on the osseointegration of implant materials in trabecular bone. *J Biomed Mater Res* 1995;29:1567-1575.
20. Cochran DL, Simpson J, Weber HP, Buser D. Attachment and growth of periodontal cells on smooth and rough titanium. *Int J Oral Maxillofac Implants* 1994;9:289-297.
21. Martin JY, Schwartz Z, Hummert TW, Schraub DM, Simpson J, Lankford J Jr, Dean DD, Cochran DL, Boyan BD. Effect of titanium surface roughness on proliferation, differentiation, and protein synthesis of human osteoblast-like cells (MG63). *J Biomed Mater Res* 1995;29:389-401.
22. Kieswetter K, Schwartz Z, Hummert TW, Cochran DL, Simpson J, Dean DD, Boyan BD. Surface roughness modulates the local production of growth factors and cytokines by osteoblast-like MG-63 cells. *J Biomed Mater Res* 1996;32:55-63.
23. Kornu R, Maloney WJ, Kelly MA, Smith RL. Osteoblast adhesion to orthopaedic implant alloys: effects of cells adhesion molecules and diamond-like carbon coating. *J Orthopaedic Res* 1996;14:871-877.
24. Lind M, Overgaard S, Ongipattanakul B, Nguyen T, Bunker C, Soballe K. Transforming growth factor-b1 stimulates bone on growth to weight-loaded tricalcium phosphate coated implants: an experimental study in dogs. *J Bone Joint Surg* 1996;78:377-382.
25. Martin JY, Dean DD, Cochran DL, Simpson J, Boyan BD, Schwartz Z. Proliferation, differentiation and protein synthesis of human osteoblast-like cells (MG63) cultured on previously exposed titanium surfaces. *Clin Oral Implants Res* 1996;7:27-37.
26. Schwartz Z, Martin JY, Dean DD, Simpson J, Cochran DL, Boyan BD. Effect of titanium surface roughness on chondrocyte proliferation, matrix production, and differentiation depends on the state of cell maturation. *J Biomed Mater Res* 1996;30:145-155.
27. Batzer R, Liu Y, Cochran DL, Szmuckler-Moncler S, Dean DD, Boyan BD, Schwartz Z. Prostaglandins mediate the effects of titanium surface roughness on MG63 osteoblast-like cells and alter cell responsiveness to 1  $\alpha$ , 25-(OH) 2D3. *J Biomed Mater Res* 1998;41:489-496.
28. Boyan BD, Batzer R, Kieswetter K, Liu Y, Cochran DL, Szmuckler-Moncler S, Dean DD, Schwartz Z. Titanium surface roughness alters responsiveness of MG63 osteoblast-like cells to 1  $\alpha$ , 25-(OH) 2D3. *J Biomed Mater Res* 1998; 39: 77-85.
29. Degasne I, Basle MF, Demais V, Hure G, Lesourd M, Grolleau B, Mercier L, Chappard D. Effects of roughness, fibronectin and vitronectin on attachment, spreading, and proliferation of human osteoblast-like cells (Saos-2) on titanium surfaces. *Calcif Tissue Int* 1999;64:499-507.
30. Noth U, Hendrich C, Merklein F, Altwater T, Rader CP, Schutze N, Eulert J, Thull R. [Standardized testing of bone implant surfaces with an osteoblast cell culture system. II. Titanium surfaces of different degrees of roughness]. (German). *Biomed Tech (Berl)* 1999;44:6-11.
31. Cooper LF, Masuda T, Whitson SW, Yliheikkilä P, Felton DA. Formation of mineralizing osteoblast cultures on machined, titanium oxide grit-blasted, and plasma-sprayed titanium surfaces. *Int J Oral Maxillofac Implants* 1999;14:37-47.
32. Spiekermann H, Donath K, Jovanovic S, Richter J. *Implantologie*. Georg Thieme Verlag 1994:18-21.
33. Jaffin RA, Berman CL. The excessive loss of Brånemark fixtures in type IV bone: A 5-year analysis. *J Periodontol* 1991;62:2-4.
34. Quirynen M, Naert I, van Steenberghe D, Schepers E, Calberson I, Theuniers G, et al. The cumulative failure rate of the Brånemark system in the overdenture, the fixed partial, and the fixed full prostheses design: A prospective study on 1273 fixtures. *J Head Neck Pathol* 1991;10:43-53.
35. Jemt T. Implant treatment in resorbed edentulous upper jaws. A three-year follow-up study in 70 patients. *Clin Oral Maxillofac Implants* 1993;4:187-194.
36. Jemt T, Chai J, Hamett J, Heath MR, Hutton JE, Johns RB, McKenna S, McNamara DC, van Steenberghe D, Taylor R, Watson RM, Herrman I. A 5-year prospective multicenter follow-up report on overdentures supported by osseointegrated implants. *Int J Oral Maxillofac Implants* 1996;11:291-298.
37. Cochran DL, Nummikoski PV, Higginbottom FL, Hermann JS, Makins SR, Buser D. Evaluation of endosseous titanium implant with a sandblasted and acid-etched surface in the canine mandible: radiographic results. *Clin Oral Implants Res* 1996;7:240-252.
38. Buser D, Nydegger T, Oxland T, Cochran DL, Schenk RK, Hirt HP, Snevety D, Nolte LP. Interface shear strength of titanium implants with a sandblasted and acid-etched surface. A biomedical study in the maxilla of miniature pigs. *J Biomed Mater Res* 1999; 45: 75-83.
39. Buser D, Nydegger T, Hirt HP, Cochran DL, Nolte LP. Removal torque values of titanium implants in the maxilla of miniature pigs. *Int J Oral Maxillofac Implants* 1998;13:611-619.
40. Adell R, Lekholm U, Brånemark P-I. Surgical procedure. In: Brånemark P-I, Zarb GA, Albrektsson T (eds). *Tissue-Integrated Prostheses: Osseointegration in Clinical Dentistry*. Chicago, Quintessence, 1985:211-232.
41. Lukas D, Schulte W. Periotest - a dynamic procedure for the diagnosis of the human periodontium. *Clin Phys Physiol Meas* 1990;11:65-75.
42. Schulte W, Lukas D. The Periotest method. *Int Dent J* 1992;42:433-440.
43. Manz MC, Morris HF, Ochi S. An evaluation of the Periotest system. Part I: examiner reliability and repeatability of readings. *Implant Dent* 1992;1:142-146.
44. Manz MC, Morris HF, Ochi S. An evaluation of the Periotest system. Part II: reliability and repeatability of instruments. *Dental Implant Clinical Group (Planning Committee)*. *Implant Dent* 1992;1:221-226.
45. Cranin AN, Degrado J, Kaufman M, Baraoidan M, Digregorio R, Batgitis G, Lee Z. Evaluation of the Periotest as a diagnostic tool for dental implants. *J Oral Implant* 1998;24:139-146.
46. Klökkevoeld PR, Nishimura RD, Adachi M, Caputo A. Osseointegration enhanced by chemical etching of the titanium surface. A torque removal study in the rabbit. *Clin Oral Implants Res* 1997;8:442-447.
47. Redaelli S, Prosper L, Di Carlo F, Scarano A, Vozza I. Analisi in vivo su tre superfici implantari. Valutazione istomorfo metrica. Roma 7° Congresso Nazionale del Collegio di Odontoiatria, Sessione Poster 2000.





**4<sup>th</sup> joint meeting**  
 CONTINENTAL EUROPEAN  
 AND SCANDINAVIAN DIVISIONS  
 OF THE INTERNATIONAL  
 ASSOCIATION  
 FOR DENTAL  
 RESEARCH

WARSAW 2000

24-27 August 2000, Warsaw, Poland

## ABSTRACT

220


**Using of Gore Resolut membrane in 223 post-extraction Winsix implanta**  
 L. PROSPER\*, S. REDAELLI, G. POMPA, A. PALATTELLA, M. QUARANTA  
 (Dental School, Univ. I and II, Rome and Milan, Italy)

In post-extraction implants the problem of dehiscences is a source of continuous clinical research. For this reason we have developed a surgical protocol where we have combined the use of membranes and a different surgical technique in implant insertion. We inserted 223 Winsix osseointegrated implants with a diameter from 3.8mm to 4.5mm and length from 11mm to 15mm. After 7 days from tooth extraction, surgical toilet and washing with Rifocin®, we inserted implants where the head has to be 1 mm under the residuary ridge and then we placed a non - resorbable membrane (Gore Resolut). Postoperatively we prescribed systemic antibiotics and a local mouthwash with Chlorhexidine 0,12% for 2 weeks plus Corsodyl® gel to massage the gingiva. After 4 - 6 months an X - ray control was performed by two different operators, then we reopened the flap to verify osseointegration. The results were verified through clinical examination, clinical photographs (Mellonig and Triplett 1993), Periotest and X - ray examination. We lost 2 fixtures from perimplantitis due to the load of temporary prostheses during the first 6 months and we lost 2 implants after functional loads. In 24 cases there was a membrane dehiscence solved without its displacement. After 12 months, with Periotest we noticed stability and then osseointegration in 98 % of cases, with an average between -8 and +9. On the X - ray bone resorption was not over 0,2 - 0,4mm on the distal and mesial site in 85 % of cases. With this surgical protocol we have verified that clinical and radiographic results in post-extraction implants are good making possible their use immediately after extraction.

# WINSIX<sup>®</sup>

PERFORMING IMPLANT SYSTEM 

Certificazioni prodotto WINSIX<sup>®</sup>:



**BIOSAFIN**

Partner of



Making Your Life Better.

**BIOSAF IN srl**  
info@biosafin.com - biosafin.com